EUROPEAN RESPIRATORY *journal*

FLAGSHIP SCIENTIFIC JOURNAL OF ERS

Early View

Review

A contemporary practical approach to the multidisciplinary management of unclassifiable interstitial lung disease

Christopher J. Ryerson, Tamera J. Corte, Jeffrey L. Myers, Simon L. F. Walsh, Sabina A. Guler

Please cite this article as: Ryerson CJ, Corte TJ, Myers JL, *et al*. A contemporary practical approach to the multidisciplinary management of unclassifiable interstitial lung disease. *Eur Respir J* 2021; in press (https://doi.org/10.1183/13993003.00276-2021).

This manuscript has recently been accepted for publication in the *European Respiratory Journal*. It is published here in its accepted form prior to copyediting and typesetting by our production team. After these production processes are complete and the authors have approved the resulting proofs, the article will move to the latest issue of the ERJ online.

Copyright ©The authors 2021. For reproduction rights and permissions contact permissions@ersnet.org

source: https://doi.org/10.48350/157437 | downloaded: 12.10.2024

A contemporary practical approach to the multidisciplinary management of unclassifiable interstitial lung disease

Christopher J Ryerson[1]
Tamera J Corte[2]
Jeffrey L Myers[3]
Simon LF Walsh[4]
Sabina A Guler[5]

[1] Department of Medicine, University of British Columbia and Centre for Heart Lung Innovation, St. Paul's Hospital, Vancouver, Canada

[2] Department of Respiratory Medicine, Royal Prince Alfred Hospital, Sydney; University of Sydney; Centre of Research Excellence for Pulmonary Fibrosis, Sydney, Australia

[3] Department of Pathology, Michigan Medicine, Ann Arbor, Michigan, United States

[4] National Heart and Lung Institute, Imperial College, London, United Kingdom

[5] Department of Pulmonary Medicine, Inselspital, Bern University Hospital, University of Bern, Bern, Switzerland

Corresponding author
Christopher J Ryerson
St. Paul's Hospital, Ward 8B
1081 Burrard St.
Vancouver, BC, Canada, V6Z 1Y6
chris.ryerson@hli.ubc.ca
604-806-8818

Key words: Interstitial lung disease, pulmonary fibrosis, diagnosis, management, classification

ABSTRACT

Fibrotic interstitial lung diseases (ILDs) frequently have nonspecific and overlapping clinical and radiological features, resulting in approximately 10-20% of patients with ILD lacking a clear diagnosis and thus being labelled with unclassifiable ILD. The objective of this review is to describe how patients with unclassifiable ILD should be evaluated and what impact specific clinical, radiological, and histopathological features may have on management decisions, focusing on patients with a predominantly fibrotic phenotype. We highlight recent data that have suggested an increasing role for antifibrotic medications in a variety of fibrotic ILDs, but justify the ongoing importance of making an accurate ILD diagnosis given the benefit of immunomodulatory therapies in many patient populations. We provide a practical approach to support management decisions that can be used by clinicians and tested by clinical researchers, and further identify the need for additional research to support a rational and standardized approach to the management of patients with unclassifiable ILD.

BACKGROUND

Interstitial lung disease (ILD) is a collection of diseases that result in fibrosis and/or inflammation of the lung parenchyma. Fibrotic ILDs frequently have nonspecific and overlapping clinical and radiological features, resulting in a challenging diagnostic process. In some cases, a confident ILD diagnosis may require invasive procedures such as a surgical lung biopsy; however, this procedure is associated with substantial risk of complications that is prohibitive in many patients,(1, 2) and may also yield nonspecific findings that preclude a confident diagnosis. As a result, approximately 10-20% of patients with fibrotic ILD lack a clear diagnosis and are thus labeled as having unclassifiable ILD.(3)

Despite greater focus on this population over the last decade, the management of patients with unclassifiable ILD remains particularly challenging for clinicians due to the limited understanding of the biological basis for the disease and the consequent uncertain treatment approach. This challenge is amplified by the different treatment approaches taken for various ILD subtypes, with recent evidence substantially changing previous approaches. The objective of this review is to describe how patients with unclassifiable ILD should be evaluated and what impact specific features have on management decisions, focusing on patients with a predominantly fibrotic phenotype. Our overall goal is to provide a practical approach to support management decisions that can be used by clinicians caring for these patients and tested by clinical researchers to further validate these approaches. We have based this proposed approach on direct evidence whenever available, indirect evidence where possible, and clinical experience and informal consensus where data are even more limited.

DEFINITION OF UNCLASSIFIABLE ILD

Unclassifiable ILD has been described in multiple previous reports, but with varying definitions.(3) Early reports defined unclassifiable ILD as the absence of a confident diagnosis, typically using either diagnostic criteria from guidelines where available or multidisciplinary discussion as the standard for ILD diagnosis.(4) This approach formed the basis of a ‘working diagnosis’,(5-7) with multiple potential reasons for patients to arrive at a low-confidence diagnosis (**Figure 1**).(8) The concept of a working diagnosis is

complemented by the disease behaviour classification that was proposed in the 2013 consensus statement on the idiopathic interstitial pneumonias.(9) This approach grouped patients with ILD according to their observed and/or anticipated disease behaviour, with these major categories being reversible and self-limited, reversible with risk of progression, stable with residual disease, progressive and irreversible disease with potential for stabilization, and progressive irreversible disease despite therapy.

A recent international working group further described the issue of diagnostic confidence, producing a structured framework for estimating and documenting diagnostic confidence (likelihood) that is ideally based on a gestalt integration of clinical, radiological, and pathological data within a multidisciplinary discussion.(10) This group defined unclassifiable ILD as the absence of a leading diagnosis that is considered more likely than not, with a provisional diagnosis corresponding to 51-89% likelihood of a given diagnosis, and a confident diagnosis corresponding to ≥ 90% likelihood. This practical approach to incorporating diagnostic confidence into evaluation and management decisions has been adopted in recent clinical practice guidelines.(11) These central concepts of diagnostic confidence and disease behaviour serve as the scaffolding upon which the remainder of this perspective is structured.

EVALUATION AND MONITORING OF UNCLASSIFIABLE ILD

A thorough diagnostic evaluation and, if possible, accurate classification of patients with fibrotic ILD is crucial to inform management and prognosis.(9) The general approach considers the diagnostic confidence that is achieved at each stage of the diagnostic process, balancing the potential benefit against the potential risk of additional investigations. Virtually all patients with ILD should undergo a thorough history, physical examination, high resolution computed tomography of the chest (HRCT), and autoimmune serologies. If these yield a confident diagnosis, then more invasive tests such as bronchoscopy or surgical lung biopsy may not provide sufficient information to justify their potential complications. Conversely, if initial non-invasive diagnostic steps fail to yield a confident diagnosis, then the expected benefits of additional tests may outweigh their potential risks. This is particularly true if the differential diagnosis includes possibilities that would mandate different therapies.

Patients with mild ILD who have minimal symptoms and preserved pulmonary function may have nondiagnostic pathology, and it may also be appropriate to forgo or delay a surgical lung biopsy in situations where pharmacological therapy would not be initiated regardless of the specific ILD diagnosis. This approach must be balanced against the risk for irreversible disease progression, which is a particular concern in patients with the potential to have IPF.(12, 13) These and other examples highlight the need to ensure that the diagnostic approach taken for a patient with unclassifiable ILD is appropriate considering the multitude of potential ILD subtypes that remain on the differential diagnosis.

Key information might emerge during long-term follow-up of patients with unclassifiable ILD that can help secure a confident diagnosis, including identification of exposures, new connective tissue disease (CTD) features, or abnormal autoimmune serology. For example, questioning for exposures and evaluation of new symptoms and signs should be performed every 6-12 months, and repeating non-invasive tests such as autoimmune serologies should be considered approximately annually, particularly in many patients with an idiopathic interstitial pneumonia or previously unclassifiable ILD.

It is also possible to characterize patients with unclassifiable ILD according to their previous or anticipated disease behaviour, with multiple potential approaches used to define progressive fibrosis.(9, 14, 15) The relatively rapid progression frequently observed in many patients with unclassifiable ILD likely indicates a high percentage of patients with an unproven diagnosis of IPF.(3, 4, 16, 17) Accordingly, risk factors for progression and mortality in unclassifiable ILD include features typical for IPF such as older age, male sex, crackles on lung auscultation, low lung function, and traction bronchiectasis.(4, 16-19) As described below, these and other features may have management implications beyond their prognostic significance.

MANAGEMENT OF UNCLASSIFIABLE ILD

Non-pharmacological management of patients with unclassifiable ILD is similar to other ILD subtypes. The decision to initiate pharmacotherapy in patients with unclassifiable ILD is most strongly influenced by the anticipated response to therapy, including the potential for improvement, stabilization, or merely slowing of progression. This potential benefit from an ILD medication is closely related to the future risk of disease progression, which is in turn strongly predicted by the presence of previous progression. Although there are no widely accepted criteria for what constitutes ILD progression,(20) eligibility criteria of recent clinical trials suggest the importance of integrating the evolution of symptoms, pulmonary function tests, and radiological extent of fibrosis.(21-23)

Patients needed to have previous progression defined by a decrease in absolute FVC >5% or worsening symptoms attributed to ILD progression over 6 months to be included in a recent phase 2 trial of pirfenidone in unclassifiable ILD.(21) The inclusion criteria of the INBUILD trial of nintedanib in progressive fibrosing ILD defined ILD progression as a relative FVC decline of ≥10% over ≤2 years, or having at least two of a 5-10% decline in FVC, worsening symptoms, or worsening radiological fibrosis, despite management as deemed appropriate in clinical practice.(22) Some groups have advocated for a focus on decline in DLCO,(24) with the caveat that measurement variability and concomitant pulmonary hypertension can complicate interpretation. Similarly, the deterioration of physical performance (e.g., 6-minute walk distance) can be attributed to ILD progression, but also to deconditioning and cardiovascular or musculoskeletal comorbidities. Although none of these criteria have thus far been adopted in consensus definitions, these examples provide a reasonable starting point for how to define patients with clinically meaningful progression who may warrant medication to prevent or slow future progression.

The choice of which medication to initiate in patients with unclassifiable ILD has, to date, primarily been based on whether the most likely diagnosis is thought to be IPF or a non-IPF diagnosis. Previous clinical trials have convincingly shown that both nintedanib and

pirfenidone slow the rate of FVC decline compared to placebo in IPF.(25-27) Although the evidence is weaker, there are multiple studies supporting the use of immunomodulatory medications in patients with a variety of non-IPF ILDs, including CTD-ILD and fibrotic hypersensitivity pneumonitis (HP).(28-30)

The management of unclassifiable ILD has been complicated by these divergent approaches, and in particular the finding that prednisone and likely other immunomodulatory medications are harmful in IPF despite their frequent use in other fibrotic ILDs.(31, 32) Choices for pharmacotherapy of unclassifiable ILD have thus primarily been driven by balancing potential benefits of therapy against the possibility of causing harm, recognizing the uncertain and likely heterogeneous underlying biology of patients with unclassifiable ILD. This approach has recently been altered by evidence that nintedanib and pirfenidone have benefit beyond IPF. This has been tested most robustly in the INBUILD study that showed nintedanib had a similar benefit in a variety of progressive fibrosing ILDs (including unclassifiable ILD) compared to what had previously been demonstrated in IPF.(22, 33) Similar data exist for pirfenidone, which slowed the rate of FVC decline in unclassifiable ILD when this was measured using conventional pulmonary function testing, although the unconventional primary endpoint of home-based spirometry was not met in this phase 2 study.(21)

Although these studies suggest a role for antifibrotic medications in non-IPF ILDs, a major limitation is the lack of head-to-head comparison with immunomodulatory medication and the small percentage of patients on such therapies in these trials. It is therefore uncertain what management option should be considered first-line in patients with non-IPF ILDs, and clinicians continue to struggle with identifying features that suggest a greater likelihood of benefit from one approach or the other. This is a particular challenge in patients with unclassifiable ILD in which there is very limited direct evidence. In the following sections, we identify the multiple potential factors that can influence this decision and suggest a general approach to the integration of these considerations into a single therapeutic recommendation.

Clinical features

Clinical features of ILD are important in determining both the need for pharmacotherapy and the choice of medication, recognizing that these are not simple dichotomous decisions (**Figure 2**). Clinical features of unclassifiable ILD are generally non-specific, including increasing exertional dyspnea, dry cough, weight loss, and impaired exercise tolerance. Physical examination findings frequently include hypoxemia, inspiratory crackles, and digital clubbing. The severity of these features and their rate of progression are important factors in determining the need for pharmacotherapy to improve lung function or slow progression. This assessment is most often based on clinical assessment (e.g., dyspnea), pulmonary function tests (especially FVC and DLCO), and HRCT. Patients with very mild and stable disease may not require any intervention. Disease-modifying pharmacotherapy is most often considered in patients with moderately severe and/or progressive disease. Patients will also benefit from early referral for lung transplant assessment, and for palliative care and symptomatic management when appropriate.

There are multiple clinical features that can help inform which therapeutic approach is most appropriate as a pragmatic first-line option in patients with unclassifiable ILD, particularly when these factors are considered in combination. For example, male former smokers over 70 years of age are more likely to have a diagnosis of IPF, even if this diagnosis is unable to made confidently, and it is likely appropriate to treat many of these patients as though they have a working diagnosis of IPF.(6, 34) Conversely, female patients under 50 years of age are more likely to have an autoimmune cause of their ILD even if they lack definitive evidence of a specific CTD, and these patients may instead be more appropriately managed with immunomodulatory medication, similar to patients with a defined CTD-ILD. Patients with subtle features of CTD often meet criteria for ‘interstitial pneumonia with autoimmune features’ (IPAF), which has been proposed as a research entity to describe this group of patients.(35) Although IPAF remains a research entity not yet recommended for clinical use, this general concept can be helpful for supporting management considerations of patients with subtle autoimmune features who would otherwise be labelled with unclassifiable ILD. A number of additional non-diagnostic clinical features may provide support for or against specific ILD subtypes (e.g., a possible environmental or occupational exposure, BAL

lymphocytosis), in turn suggesting which treatment options are most appropriate to consider in a real-world setting for patients with unclassifiable ILD.(36-38)

Radiological features

Imaging features and patterns are often crucial in both the decision to start pharmacotherapy and the choice of medication (**Figures 2 and 3**). Early studies reported that patients with ground glass opacification on CT, reflecting inflammation on surgical lung biopsy, were more responsive to treatment with immunomodulatory medication.(39) Based on these findings, it has been presumed that ground glass opacification on HRCT represents reversible disease even without biopsy confirmation;(40) however, this approach can be misleading if a qualitative assessment of the *type* of ground glass opacification is not carefully performed.(41) Fine fibrosis, below the spatial resolution of HRCT, may occasionally manifest as areas of increased lung density containing subtle reticulation, sometimes mistaken for ground glass opacification (REF).(42, 43) The coexistence of traction bronchiectasis helps to separate this entity from isolated ground glass opacities that are more likely reversible.(44, 45) The presence of multicompartment, mixed, or overlapping patterns of disease raises the possibility of CTD-ILD,(35) while a specific form of mosaic attenuation labelled the “three-density pattern” has recently been reported as highly specific for fibrotic HP, regardless of the pattern of fibrosis.(11, 46, 47) In these situations, first-line treatment with an immunomodulatory medication is likely a more appropriate choice despite limited direct evidence.

Imaging features suggestive of a usual interstitial pneumonia (UIP) pattern indicate a high likelihood of future progression and may support decisions to initiate antifibrotic therapy even when a confident diagnosis of IPF is not achieved. For example, the INBUILD study showed higher risk of progression and greater overall benefit from nintedanib in patients with a UIP-like pattern.(22) However, this is a cohort distinction that may be difficult to apply to individual patients given the heterogeneous outcomes that occur within major imaging categories.(48) Similarly, individual HRCT features are associated with progressive disease (e.g., extent of fibrosis, honeycombing, traction bronchiectasis, and volume loss),(49-52) but there is limited evidence on how to optimally use these poorly standardized variables to help support

management decisions. Dendriform ossification, coexistent pleuroparenchymal fibroelastosis (PPFE), and asymmetry are all HRCT features associated with UIP on surgical lung biopsy, and these suggest a diagnosis of IPF in the appropriate clinical setting even if a confident diagnosis of IPF cannot otherwise be obtained (e.g., in the context of a probable UIP pattern on HRCT) (53-55).

Pathological features

Similar to imaging findings, ILD classification is predicated in large part on histopathology;(9) however, the potential of morphological features to inform treatment decisions is still uncertain. Common pathological patterns of UIP and fibrotic NSIP show substantial overlap with fibrotic HP, and these three patterns are sometimes morphologically indistinguishable.(56, 57) Uncertainty regarding histologic patterns of fibrosis is less likely to interfere with a confident diagnosis in patients with underlying CTD, in whom other clinical and laboratory findings tend to be weighted more heavily; however, this type of uncertainty frequently prohibits a confident clinical diagnosis in most other settings. The differentiation of UIP, fibrotic NSIP, fibrotic HP, and other diffuse fibrotic ILDs is particularly important given their potential for progression,(58) which often impacts the decision to initiate pharmacotherapy.

“Unclassifiable” as it pertains to histopathologic assessment refers to the absence of features typical for a specific pattern which in turn predicts a high likelihood of poor agreement between qualified reviewers. This differs from “unclassifiable” as defined at MDD and also from “non-diagnostic”, a circumstance often attributed to sampling error that results in the absence of abnormalities sufficient to explain the respiratory syndrome. Cases that are histopathologically “unclassifiable” may be “classifiable” at MDD. For example, patients with a biopsy showing overlapping features of UIP and NSIP can still be diagnosed with IPF if clinical and radiological features support IPF. The converse may also be true. For example, a patient with a histologic UIP pattern can still be labelled as unclassifiable ILD if integration with clinical and radiological findings result in equal likelihoods of IPF and fibrotic HP.

The histopathologic features of UIP and non-UIP are the predominant drivers of the decision between antifibrotic and immunomodulatory medication (**Figures 2 and 4**); however, there are currently limited data to support this approach. It is intuitively appealing to assume that biopsies showing paucicellular collagen fibrosis, with or without architectural distortion, are logical candidates for anti-fibrotic therapy, while biopsies showing more cellular disease, with or without associated lymphoid hyperplasia, might be more reasonably selected for immunomodulatory therapy. Lymphocytosis on bronchoalveolar lavage cellular analysis similarly suggests a non-IPF diagnosis,(37, 59) and may suggest a preferred role for immunomodulatory medication. Additional data are needed to support these hypotheses.

Multidisciplinary integration of features

It is important to note that there are few radiological or histopathological findings that can categorically distinguish clinical subtypes of fibrotic ILD, and that having high confidence in a specific imaging or biopsy pattern can still result in a case remaining unclassifiable following multidisciplinary discussion. For example, major discordance between clinical, radiological, and/or histopathologic features may lead to diagnostic uncertainty (*e.g.*, long-term stability in a patient with an imaging pattern of definite UIP).(60) And although dynamic exchange of information between experts typically increases diagnostic confidence and often provides a specific diagnosis in patients previously considered unclassifiable,(61-63) additional discussion occasionally creates diagnostic uncertainty in cases that initially seemed straightforward.(64) These situations highlight the second major goal of multidisciplinary discussion, which is to consider which management option is most appropriate even if it is acknowledged that a confident diagnosis is unattainable (**Figure 2**).

Similar to the challenges in establishing a diagnosis,(64-66) providing a specific treatment recommendation is a challenging goal that is likely best accomplished through a dynamic and collaborative discussion among experts. Proposing a specific treatment approach in patients with unclassifiable ILD requires the weighting of various features that in combination may support a specific therapeutic option even when the diagnosis is unclear, with each feature being only a small part of a bigger picture. This requires a collaborative approach; however, there is currently no standardized way to integrate the many features that should

be considered for a given patient, indicating the need for experts to approach this challenge on a case-by-case basis.

DISCUSSION

The diagnosis and management of ILD continues to evolve rapidly. As additional evidence accumulates, there are several key questions that clinicians should consider and that should be the subject of study by clinical and translational researchers.

1. Is it still worthwhile to make a specific ILD diagnosis for patients with fibrotic ILD?

There has been considerable debate about whether certain subtypes of fibrotic ILD should be lumped or split; however, it is prematurely fatalistic to lump all fibrotic ILDs because of overlapping survival curves or similar treatment options. Had oncology taken a similar approach, many aggressive tumors for which there are now effective targeted therapies would instead be lumped together as one heterogeneous collection of patients, thus complicating understanding of disease biology and limiting potential for drug discovery. Care of patients with ILD will never fully evolve unless we continue to work toward understanding and defining discrete diagnostic categories even if the outcomes of these groups remain similar for the foreseeable future. It is therefore imperative that specific ILD subtypes are classified as thoroughly as possible and that unclassifiable ILD cases are thoroughly phenotyped in order to continuously learn from similarities and differences of various ILDs.

2. What novel techniques can be used to increase diagnostic confidence?

There are several novel techniques that have potential to increase diagnostic confidence or at least support management decisions. These have primarily included assessment of genetics and various blood biomarkers. For example, a molecular or genomic classifier can predict a UIP pattern based on analysis of lung tissue,(67) including on transbronchial biopsy,(68) with the goal that this objective test can be used to overcome some of the limitations in qualitative assessment of morphology. Although this test predicts a UIP pattern, the implication for treatment decisions is unknown. HRCT features can be combined with

clinical markers of disease severity (*e.g.*, lung function) to facilitate prognostication and staging in multiple ILDs.(69, 70) Advances in computer-based HRCT analysis will also likely improve our ability to predict disease behavior irrespective of radiologic diagnosis.(71, 72) Although many of these tools are promising, there are generally insufficient data to justify their use in directing management decisions at this time. Transbronchial lung cryobiopsy is a relatively new and less invasive sampling technique compared to surgical lung biopsy, which appears to have clinical utility when used by experts in the appropriate clinical setting.(73) Many additional tests are under study that may further improve our ability to distinguish specific ILD subtypes.

3. What are the research priorities for unclassifiable ILD?

There are many uncertainties in unclassifiable ILD that require further study, with major research priorities including improvement in non-invasive diagnostics and identification of novel techniques to better direct management decisions.

Studies to improve ILD diagnosis are limited by the complexity of the multistep and multidisciplinary approach that is the current reference standard for fibrotic ILDs. This makes it critically important that studies adhere to rigorous methods, such as those described in the Standards for Reporting Diagnostic Accuracy (STARD) statement.(74) Recognizing the absence of an objective gold standard test to confirm most ILD diagnoses, previous studies have often used interobserver agreement in diagnosis as a surrogate of diagnostic accuracy (64-66, 75). This common practice highlights the need for new approaches to ILD classification that are carefully validated against meaningful outcomes. An additional uncertainty is how to weight individual diagnostic components such as imaging or pathological findings. For example, when a clinical diagnosis of fibrotic HP is assigned to a patient with a pathological pattern of UIP, is the clinical diagnosis or pathological pattern of greater importance for therapeutic decisions and prognostication?

Recent clinical trials of antifibrotic therapies have specifically included patients with diagnostic uncertainty,(21, 22) and suggest a potential role of these medications in patients with unclassifiable ILD. However, these trials have not compared immunomodulatory versus antifibrotic treatment approaches, and additional studies need to establish which approach is preferable for which patient. A particularly important research priority is the question of whether a trial of corticosteroids for several weeks in an attempt to identify “steroid-responsive” disease is a useful clinical tool in patients with fibrotic ILD, or whether such trials of corticosteroid could instead cause more harm than good. Similarly, additional research is needed to determine whether certain morphological aspects (e.g., a UIP pattern on imaging or biopsy, significant BAL lymphocytosis) are more valid to predict response to specific pharmacotherapy than the clinical diagnosis. This particularly applies to patients with unclassifiable ILD, in whom management-directed phenotyping strategies still need to be established, validated, and implemented in clinical care.

CONCLUSIONS

Recent data have suggested relatively broad clinical utility of antifibrotic medications, but it remains important to still make an accurate ILD diagnosis for multiple reasons. In patients unable to be confidently diagnosed with a specific ILD, there are clinical, radiological, and pathological features that can be integrated to direct the physician towards the most appropriate management approach. This is a challenging task given the absence of direct evidence, with the need for additional research to support establishment of a rational and standardized approach to the management of patients with unclassifiable ILD.

Acknowledgements
The author(s) meet criteria for authorship as recommended by the International Committee of Medical Journal Editors (ICMJE). Boehringer Ingelheim approached the authorship about creating a manuscript on this topic and convened the initial meeting of the authors. The authors did not receive payment for the development of this article or any editorial assistance. As per the agreement made at the time of convening the first meeting, Boehringer Ingelheim reviewed this article for medical and scientific accuracy, during which they confirmed our accurate definition of progressive fibrosing ILD in the INBUILD trials.

Financial support and sponsorship
None

Conflicts of interest
CJR has received research funding, grant support, and speaking honoraria from Boehringer Ingelheim and Hoffmann-La Roche, speaking honoraria from Cipla Ltd., and consultancy fees from Pliant Therapeutics.

TJC has received grant support, consultancy fees, and speaking honoraria from Boehringer Ingelheim and Hoffman-La Roche; grant support from Gilead, Biogen, Bayer, InterMune, Actelion; and consultancy fees from AstraZeneca, Bristol-Myers Squibb, Promedior, and Ad Alta.

JLM has no conflicts of interest relevant to the content of this manuscript.

SLFW has received research funding from the National Institute of Health and Research; research funding, consultancy fees, and speaking honoraria from Boehringer Ingelheim, Hoffmann-La Roche and Galapagos; consultancy fees from The Open Source Imaging Consortium, FLUIDDA, Medscape and Sanofi-Genzyme.

SAG has received grant support and speaking honoraria from Boehringer Ingelheim and Hoffmann-La Roche.

REFERENCES

1. Hutchinson JP, Fogarty AW, McKeever TM, Hubbard RB. In-Hospital Mortality after Surgical Lung Biopsy for Interstitial Lung Disease in the United States. 2000 to 2011. Am J Respir Crit Care Med. 2016;193(10):1161-7.
2. Hutchinson JP, McKeever TM, Fogarty AW, Navaratnam V, Hubbard RB. Surgical lung biopsy for the diagnosis of interstitial lung disease in England: 1997-2008. Eur Respir J. 2016;48(5):1453-61.
3. Guler SA, Ellison K, Algamdi M, Collard HR, Ryerson CJ. Heterogeneity in Unclassifiable Interstitial Lung Disease. A Systematic Review and Meta-Analysis. Annals of the American Thoracic Society. 2018;15(7):854-63.
4. Ryerson CJ, Urbania TH, Richeldi L, Mooney JJ, Lee JS, Jones KD, et al. Prevalence and prognosis of unclassifiable interstitial lung disease. Eur Respir J. 2013;42(3):750-7.
5. Lynch DA, Sverzellati N, Travis WD, Brown KK, Colby TV, Galvin JR, et al. Diagnostic criteria for idiopathic pulmonary fibrosis: a Fleischner Society White Paper. The lancet Respiratory medicine. 2018;6(2):138-53.
6. Walsh SLF, Lederer DJ, Ryerson CJ, Kolb M, Maher TM, Nusser R, et al. Diagnostic Likelihood Thresholds That Define a Working Diagnosis of Idiopathic Pulmonary Fibrosis. Am J Respir Crit Care Med. 2019;200(9):1146-53.
7. Wells AU. "Any fool can make a rule and any fool will mind it". BMC medicine. 2016;14:23.
8. Cottin V, Wells A. Unclassified or unclassifiable interstitial lung disease: confusing or helpful disease category? Eur Respir J. 2013;42(3):576-9.
9. Travis WD, Costabel U, Hansell DM, King TE, Jr., Lynch DA, Nicholson AG, et al. An official American Thoracic Society/European Respiratory Society statement: Update of the international multidisciplinary classification of the idiopathic interstitial pneumonias. Am J Respir Crit Care Med. 2013;188(6):733-48.
10. Ryerson CJ, Corte TJ, Lee JS, Richeldi L, Walsh SLF, Myers JL, et al. A Standardized Diagnostic Ontology for Fibrotic Interstitial Lung Disease. An International Working Group Perspective. Am J Respir Crit Care Med. 2017;196(10):1249-54.
11. Raghu G, Remy-Jardin M, Ryerson CJ, Myers JL, Kreuter M, Vasakova M, et al. Diagnosis of Hypersensitivity Pneumonitis in Adults. An Official ATS/JRS/ALAT Clinical Practice Guideline. Am J Respir Crit Care Med. 2020;202(3):e36-e69.
12. Noble PW, Albera C, Bradford WZ, Costabel U, du Bois RM, Fagan EA, et al. Pirfenidone for idiopathic pulmonary fibrosis: analysis of pooled data from three multinational phase 3 trials. Eur Respir J. 2016;47(1):243-53.
13. Kolb M, Richeldi L, Behr J, Maher TM, Tang W, Stowasser S, et al. Nintedanib in patients with idiopathic pulmonary fibrosis and preserved lung volume. Thorax. 2017;72(4):340-6.
14. George PM, Spagnolo P, Kreuter M, Altinisik G, Bonifazi M, Martinez FJ, et al. Progressive fibrosing interstitial lung disease: clinical uncertainties, consensus recommendations, and research priorities. The lancet Respiratory medicine. 2020;8(9):925-34.
15. Nasser M, Larrieu S, Si-Mohamed S, Ahmad K, Boussel L, Brevet M, et al. Progressive fibrosing interstitial lung disease: a clinical cohort (the PROGRESS study). Eur Respir J. 2021;57(2).
16. Hyldgaard C, Bendstrup E, Wells AU, Hilberg O. Unclassifiable interstitial lung diseases: Clinical characteristics and survival. Respirology. 2017;22(3):494-500.
17. Jacob J, Bartholmai BJ, Rajagopalan S, Egashira R, Brun AL, Kokosi M, et al. Unclassifiable-interstitial lung disease: Outcome prediction using CT and functional indices. Respir Med. 2017;130:43-51.
18. Krauss E, El-Guelai M, Pons-Kuehnemann J, Dartsch RC, Tello S, Korfei M, et al. Clinical and Functional Characteristics of Patients with Unclassifiable Interstitial Lung Disease (uILD): Long-Term Follow-Up Data from European IPF Registry (eurIPFreg). J Clin Med. 2020;9(8).
19. Nakamura Y, Sugino K, Kitani M, Hebisawa A, Tochigi N, Homma S. Clinico-radio-pathological characteristics of unclassifiable idiopathic interstitial pneumonias. Respiratory investigation. 2018;56(1):40-7.

20. Wong AW, Ryerson CJ, Guler SA. Progression of fibrosing interstitial lung disease. Respir Res. 2020;21(1):32.
21. Maher TM, Corte TJ, Fischer A, Kreuter M, Lederer DJ, Molina-Molina M, et al. Pirfenidone in patients with unclassifiable progressive fibrosing interstitial lung disease: a double-blind, randomised, placebo-controlled, phase 2 trial. The lancet Respiratory medicine. 2020;8(2):147-57.
22. Flaherty KR, Wells AU, Cottin V, Devaraj A, Walsh SLF, Inoue Y, et al. Nintedanib in Progressive Fibrosing Interstitial Lung Diseases. N Engl J Med. 2019;381(18):1718-27.
23. Cottin V, Hirani NA, Hotchkin DL, Nambiar AM, Ogura T, Otaola M, et al. Presentation, diagnosis and clinical course of the spectrum of progressive-fibrosing interstitial lung diseases. European respiratory review : an official journal of the European Respiratory Society. 2018;27(150).
24. Khanna D, Mittoo S, Aggarwal R, Proudman SM, Dalbeth N, Matteson EL, et al. Connective Tissue Disease-associated Interstitial Lung Diseases (CTD-ILD) - Report from OMERACT CTD-ILD Working Group. J Rheumatol. 2015;42(11):2168-71.
25. Richeldi L, du Bois RM, Raghu G, Azuma A, Brown KK, Costabel U, et al. Efficacy and safety of nintedanib in idiopathic pulmonary fibrosis. N Engl J Med. 2014;370(22):2071-82.
26. King TE, Jr., Bradford WZ, Castro-Bernardini S, Fagan EA, Glaspole I, Glassberg MK, et al. A phase 3 trial of pirfenidone in patients with idiopathic pulmonary fibrosis. N Engl J Med. 2014;370(22):2083-92.
27. Noble PW, Albera C, Bradford WZ, Costabel U, Glassberg MK, Kardatzke D, et al. Pirfenidone in patients with idiopathic pulmonary fibrosis (CAPACITY): two randomised trials. Lancet. 2011;377(9779):1760-9.
28. Morisset J, Johannson KA, Vittinghoff E, Aravena C, Elicker BM, Jones KD, et al. Use of Mycophenolate Mofetil or Azathioprine for the Management of Chronic Hypersensitivity Pneumonitis. Chest. 2017;151(3):619-25.
29. Tashkin DP, Elashoff R, Clements PJ, Goldin J, Roth MD, Furst DE, et al. Cyclophosphamide versus placebo in scleroderma lung disease. New England Journal of Medicine. 2006;354(25):2655-66.
30. Tashkin DP, Roth MD, Clements PJ, Furst DE, Khanna D, Kleerup EC, et al. Mycophenolate mofetil versus oral cyclophosphamide in scleroderma-related interstitial lung disease (SLS II): a randomised controlled, double-blind, parallel group trial. The lancet Respiratory medicine. 2016;4(9):708-19.
31. Idiopathic Pulmonary Fibrosis Clinical Research N, Raghu G, Anstrom KJ, King TE, Jr., Lasky JA, Martinez FJ. Prednisone, azathioprine, and N-acetylcysteine for pulmonary fibrosis. N Engl J Med. 2012;366(21):1968-77.
32. King TE, Jr., Albera C, Bradford WZ, Costabel U, Hormel P, Lancaster L, et al. Effect of interferon gamma-1b on survival in patients with idiopathic pulmonary fibrosis (INSPIRE): a multicentre, randomised, placebo-controlled trial. Lancet. 2009;374(9685):222-8.
33. Wells AU, Flaherty KR, Brown KK, Inoue Y, Devaraj A, Richeldi L, et al. Nintedanib in patients with progressive fibrosing interstitial lung diseases-subgroup analyses by interstitial lung disease diagnosis in the INBUILD trial: a randomised, double-blind, placebo-controlled, parallel-group trial. The lancet Respiratory medicine. 2020;8(5):453-60.
34. Brownell R, Moua T, Henry TS, Elicker BM, White D, Vittinghoff E, et al. The use of pretest probability increases the value of high-resolution CT in diagnosing usual interstitial pneumonia. Thorax. 2017;72(5):424-9.
35. Fischer A, Antoniou KM, Brown KK, Cadranel J, Corte TJ, du Bois RM, et al. An official European Respiratory Society/American Thoracic Society research statement: interstitial pneumonia with autoimmune features. Eur Respir J. 2015;46(4):976-87.
36. De Sadeleer LJ, Hermans F, De Dycker E, Yserbyt J, Verschakelen JA, Verbeken EK, et al. Impact of BAL lymphocytosis and presence of honeycombing on corticosteroid treatment effect in fibrotic hypersensitivity pneumonitis: a retrospective cohort study. Eur Respir J. 2020;55(4).
37. Adderley N, Humphreys CJ, Barnes H, Ley B, Premji ZA, Johannson KA. Bronchoalveolar lavage fluid lymphocytosis in chronic hypersensitivity pneumonitis: a systematic review and meta-analysis. Eur Respir J. 2020;56(2).

38. Tzilas V, Tzouvelekis A, Bouros E, Karampitsakos T, Ntasiou M, Katsaras M, et al. Diagnostic value of BAL lymphocytosis in patients with indeterminate for usual interstitial pneumonia imaging pattern. Eur Respir J. 2019;54(5).
39. Wells AU, Rubens MB, du Bois RM, Hansell DM. Serial CT in fibrosing alveolitis: prognostic significance of the initial pattern. AJR American journal of roentgenology. 1993;161(6):1159-65.
40. Leung AN, Miller RR, Muller NL. Parenchymal opacification in chronic infiltrative lung diseases: CT-pathologic correlation. Radiology. 1993;188(1):209-14.
41. Remy-Jardin M, Giraud F, Remy J, Copin MC, Gosselin B, Duhamel A. Importance of ground-glass attenuation in chronic diffuse infiltrative lung disease: pathologic-CT correlation. Radiology. 1993;189(3):693-8.
42. Raghu G, Remy-Jardin M, Myers JL, Richeldi L, Ryerson CJ, Lederer DJ, et al. Diagnosis of Idiopathic Pulmonary Fibrosis. An Official ATS/ERS/JRS/ALAT Clinical Practice Guideline. Am J Respir Crit Care Med. 2018;198(5):e44-e68.
43. Nishimura K, Kitaichi M, Izumi T, Nagai S, Kanaoka M, Itoh H. Usual interstitial pneumonia: histologic correlation with high-resolution CT. Radiology. 1992;182(2):337-42.
44. Hansell DM, Bankier AA, MacMahon H, McLoud TC, Muller NL, Remy J. Fleischner Society: glossary of terms for thoracic imaging. Radiology. 2008;246(3):697-722.
45. Austin JH, Muller NL, Friedman PJ, Hansell DM, Naidich DP, Remy-Jardin M, et al. Glossary of terms for CT of the lungs: recommendations of the Nomenclature Committee of the Fleischner Society. Radiology. 1996;200(2):327-31.
46. Morisset J, Johannson KA, Jones KD, Wolters PJ, Collard HR, Walsh SLF, et al. Identification of Diagnostic Criteria for Chronic Hypersensitivity Pneumonitis: An International Modified Delphi Survey. Am J Respir Crit Care Med. 2018;197(8):1036-44.
47. Barnett J, Molyneaux PL, Rawal B, Abdullah R, Hare SS, Vancheeswaran R, et al. Variable utility of mosaic attenuation to distinguish fibrotic hypersensitivity pneumonitis from idiopathic pulmonary fibrosis. Eur Respir J. 2019;54(1).
48. Wells AU, Brown KK, Flaherty KR, Kolb M, Thannickal VJ, Group IPFCW. What's in a name? That which we call IPF, by any other name would act the same. Eur Respir J. 2018;51(5).
49. Lynch DA, Godwin JD, Safrin S, Starko KM, Hormel P, Brown KK, et al. High-resolution computed tomography in idiopathic pulmonary fibrosis: diagnosis and prognosis. Am J Respir Crit Care Med. 2005;172(4):488-93.
50. Walsh SL, Sverzellati N, Devaraj A, Keir GJ, Wells AU, Hansell DM. Connective tissue disease related fibrotic lung disease: high resolution computed tomographic and pulmonary function indices as prognostic determinants. Thorax. 2014;69(3):216-22.
51. Walsh SL, Wells AU, Sverzellati N, Devaraj A, von der Thusen J, Yousem SA, et al. Relationship between fibroblastic foci profusion and high resolution CT morphology in fibrotic lung disease. BMC Med. 2015;13:241.
52. Robbie H, Wells AU, Jacob J, Walsh SLF, Nair A, Srikanthan A, et al. Visual and Automated CT Measurements of Lung Volume Loss in Idiopathic Pulmonary Fibrosis. AJR Am J Roentgenol. 2019;213(2):318-24.
53. Egashira R, Jacob J, Kokosi MA, Brun AL, Rice A, Nicholson AG, et al. Diffuse Pulmonary Ossification in Fibrosing Interstitial Lung Diseases: Prevalence and Associations. Radiology. 2017:152419.
54. Oda T, Ogura T, Kitamura H, Hagiwara E, Baba T, Enomoto Y, et al. Distinct characteristics of pleuroparenchymal fibroelastosis with usual interstitial pneumonia compared with idiopathic pulmonary fibrosis. Chest. 2014;146(5):1248-55.
55. Raghu G, Remy-Jardin M, Myers JL, Richeldi L, Ryerson CJ, Lederer DJ, et al. Diagnosis of Idiopathic Pulmonary Fibrosis. An Official ATS/ERS/JRS/ALAT Clinical Practice Guideline. Am J Respir Crit Care Med. 2018;198(5):e44-e68.
56. Morell F, Villar A, Montero MA, Munoz X, Colby TV, Pipvath S, et al. Chronic hypersensitivity pneumonitis in patients diagnosed with idiopathic pulmonary fibrosis: a prospective case-cohort study. The lancet Respiratory medicine. 2013;1(9):685-94.

57. Churg A, Sin DD, Everett D, Brown K, Cool C. Pathologic patterns and survival in chronic hypersensitivity pneumonitis. The American journal of surgical pathology. 2009;33(12):1765-70.
58. Katzenstein AL, Mukhopadhyay S, Myers JL. Diagnosis of usual interstitial pneumonia and distinction from other fibrosing interstitial lung diseases. Hum Pathol. 2008;39(9):1275-94.
59. Patolia S, Tamae Kakazu M, Chami HA, Chua A, Diaz-Mendoza J, Duggal A, et al. Bronchoalveolar Lavage Lymphocytes in the Diagnosis of Hypersensitivity Pneumonitis among Patients with Interstitial Lung Disease. Annals of the American Thoracic Society. 2020;17(11):1455-67.
60. Jacob J, Hirani N, van Moorsel CHM, Rajagopalan S, Murchison JT, van Es HW, et al. Predicting outcomes in rheumatoid arthritis related interstitial lung disease. Eur Respir J. 2019;53(1).
61. Grewal JS, Morisset J, Fisher JH, Churg AM, Bilawich AM, Ellis J, et al. Role of a Regional Multidisciplinary Conference in the Diagnosis of Interstitial Lung Disease. Annals of the American Thoracic Society. 2019;16(4):455-62.
62. Jo HE, Glaspole IN, Levin KC, McCormack SR, Mahar AM, Cooper WA, et al. Clinical impact of the interstitial lung disease multidisciplinary service. Respirology. 2016;21(8):1438-44.
63. De Sadeleer LJ, Meert C, Yserbyt J, Slabbynck H, Verschakelen JA, Verbeken EK, et al. Diagnostic Ability of a Dynamic Multidisciplinary Discussion in Interstitial Lung Diseases: A Retrospective Observational Study of 938 Cases. Chest. 2018;153(6):1416-23.
64. Walsh SL, Wells AU, Desai SR, Poletti V, Piciucchi S, Dubini A, et al. Multicentre evaluation of multidisciplinary team meeting agreement on diagnosis in diffuse parenchymal lung disease: a case-cohort study. The lancet Respiratory medicine. 2016;4(7):557-65.
65. Flaherty KR, Andrei AC, King TE, Jr., Raghu G, Colby TV, Wells A, et al. Idiopathic interstitial pneumonia: do community and academic physicians agree on diagnosis? Am J Respir Crit Care Med. 2007;175(10):1054-60.
66. Flaherty KR, King TE, Jr., Raghu G, Lynch JP, 3rd, Colby TV, Travis WD, et al. Idiopathic interstitial pneumonia: what is the effect of a multidisciplinary approach to diagnosis? Am J Respir Crit Care Med. 2004;170(8):904-10.
67. Kim SY, Diggans J, Pankratz D, Huang J, Pagan M, Sindy N, et al. Classification of usual interstitial pneumonia in patients with interstitial lung disease: assessment of a machine learning approach using high-dimensional transcriptional data. The lancet Respiratory medicine. 2015;3(6):473-82.
68. Raghu G, Flaherty KR, Lederer DJ, Lynch DA, Colby TV, Myers JL, et al. Use of a molecular classifier to identify usual interstitial pneumonia in conventional transbronchial lung biopsy samples: a prospective validation study. The lancet Respiratory medicine. 2019;7(6):487-96.
69. Ley B, Elicker BM, Hartman TE, Ryerson CJ, Vittinghoff E, Ryu JH, et al. Idiopathic pulmonary fibrosis: CT and risk of death. Radiology. 2014;273(2):570-9.
70. Goh NS, Desai SR, Veeraraghavan S, Hansell DM, Copley SJ, Maher TM, et al. Interstitial lung disease in systemic sclerosis: a simple staging system. American Journal of Respiratory & Critical Care Medicine. 2008;177(11):1248-54.
71. Walsh SLF, Calandriello L, Silva M, Sverzellati N. Deep learning for classifying fibrotic lung disease on high-resolution computed tomography: a case-cohort study. Lancet Respir Med. 2018;6(11):837-45.
72. Humphries SM, Swigris JJ, Brown KK, Strand M, Gong Q, Sundy JS, et al. Quantitative high-resolution computed tomography fibrosis score: performance characteristics in idiopathic pulmonary fibrosis. Eur Respir J. 2018;52(3).
73. Troy LK, Grainge C, Corte TJ, Williamson JP, Vallely MP, Cooper WA, et al. Diagnostic accuracy of transbronchial lung cryobiopsy for interstitial lung disease diagnosis (COLDICE): a prospective, comparative study. The lancet Respiratory medicine. 2020;8(2):171-81.
74. Bossuyt PM, Reitsma JB, Bruns DE, Gatsonis CA, Glasziou PP, Irwig L, et al. STARD 2015: an updated list of essential items for reporting diagnostic accuracy studies. BMJ. 2015;351:h5527.
75. Walsh SLF, Maher TM, Kolb M, Poletti V, Nusser R, Richeldi L, et al. Diagnostic accuracy of a clinical diagnosis of idiopathic pulmonary fibrosis: an international case-cohort study. Eur Respir J. 2017;50(2).

FIGURE LEGENDS

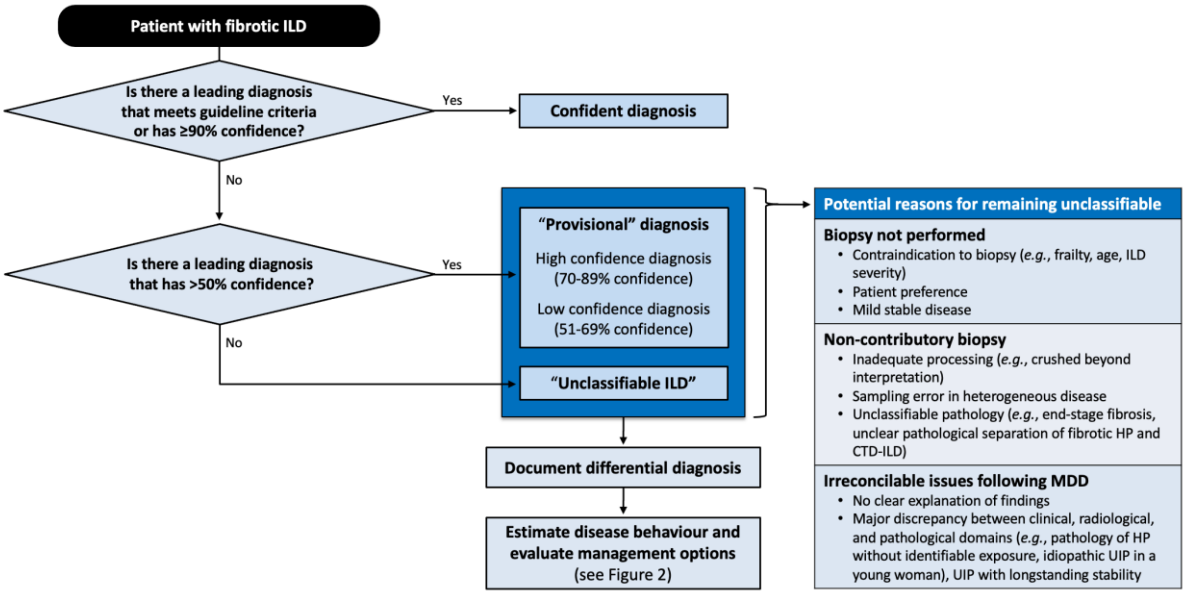

Figure 1. Proposed approach to the classification of fibrotic ILD. The establishment of diagnostic confidence is based on the proposal from Ryerson *et al*, 2017.(10) The selected list of potential reasons for remaining unclassifiable is modified from Cottin & Wells, 2013.(8)

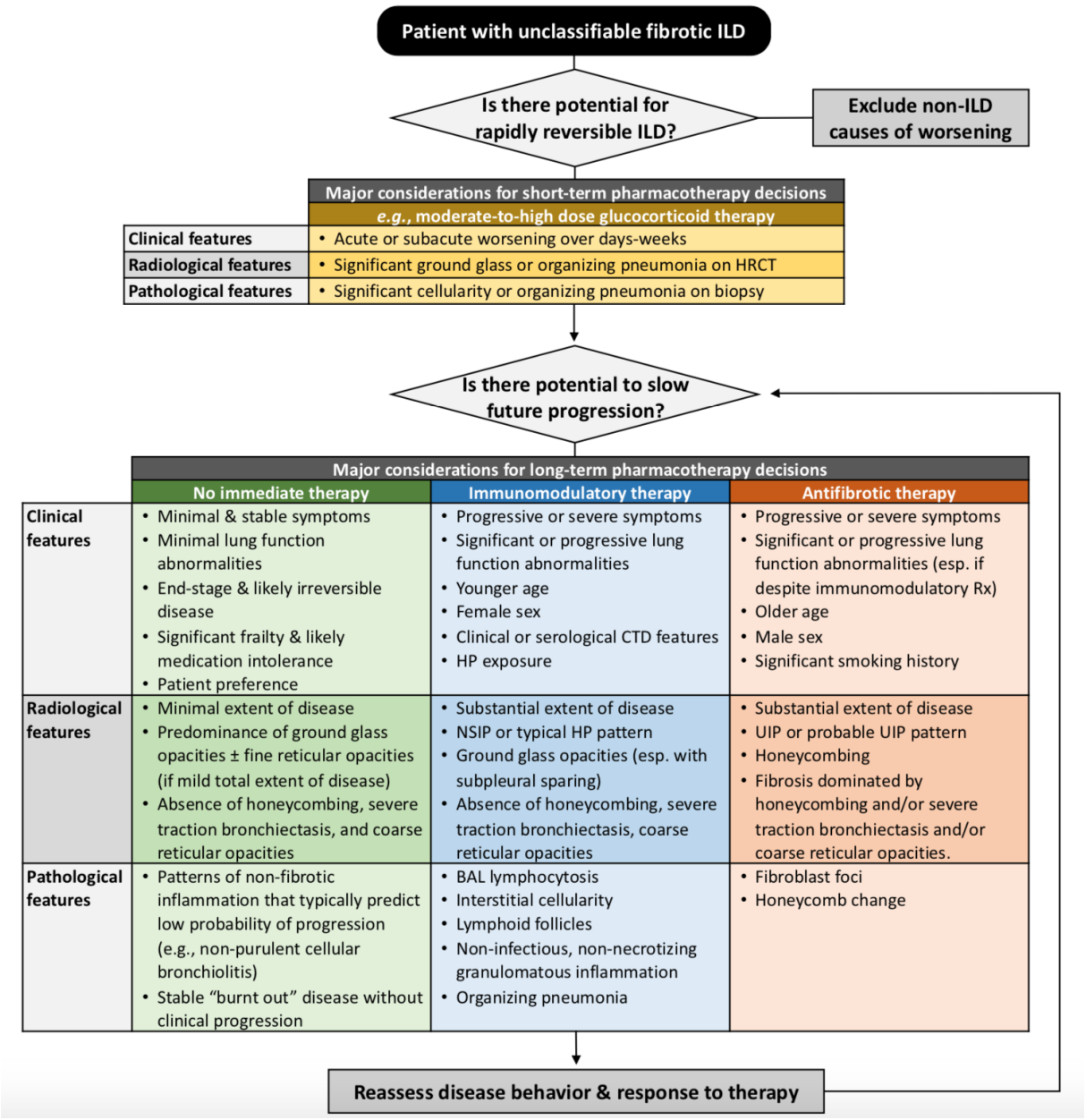

Figure 2. Proposed algorithm for assessment and management of patients with unclassifiable ILD. The algorithm is divided into two phases that generally represent short-term and long-term management approaches. Short-term management is typically based on features that have developed over days to weeks, with corresponding potential for substantial improvement over days-to-weeks. Long-term management is typically based on features that have evolved over months, with corresponding potential to improve manifestations or slow progression over several months or more.

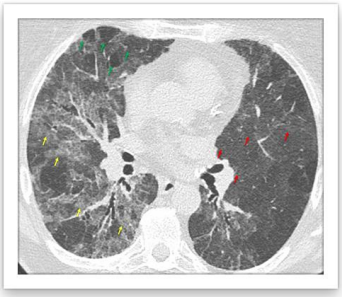

Rad_FIG2A - Rad_Density_pattern_labelled.tif

Rad_FIG2B - PureAmorphousGGO_NSIP.tif

Rad_FIG2C - TexturedGGO_in_IPF_2.tif

Rad_FIG2D - TexturedGGO_in_NSIP.tif

Rad_FIG2E - UIP_1.tif

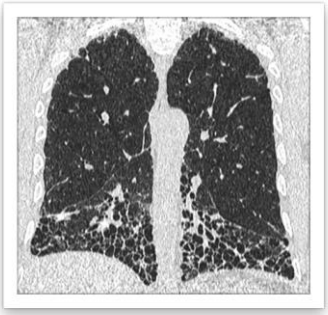

Rad_FIG2F - UIP_2.tif

Figure 3. Single slice axial and coronal HRCT images demonstrating different parenchymal patterns that may influence multidisciplinary assessment of unclassifiable ILD. **A.** The three-density pattern is present when normal density lung (red arrows), high-density ground-glass opacities (yellow arrows) and low-density areas due to small airways disease (green arrows) co-exist. When signs of fibrosis are also present, this pattern is specific for fibrotic hypersensitivity pneumonitis. **B.** Diffuse ground-glass opacities in a patient with non-fibrotic NSIP. The absence of traction bronchiectasis as well as the homogenous, amorphous quality of the ground glass opacification suggests this pattern reflects a non-fibrotic, inflammatory infiltrate. **C.** Fine reticulation mimicking ground-glass opacities in a patient with IPF. In contrast to B, this pattern has a coarse quality caused by fine intralobular septal thickening. The presence of traction bronchiectasis confirms the presence of fibrosis. **D.** Fine reticulation mimicking ground-glass opacities in a patient with fibrotic NSIP. The reticular quality of this pattern is more subtle than in C, but the presence of severe traction bronchiectasis helps to classify it as fibrotic. **E and F.** Axial and coronal HRCT images depicting basal subpleural honeycombing, traction bronchiectasis, and coarse reticular opacities typical of UIP.

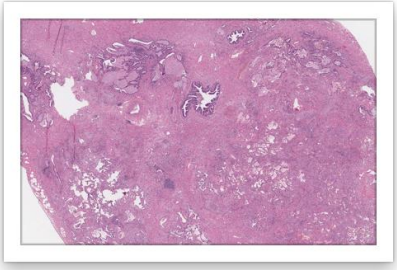

Path_FIG3A.tif

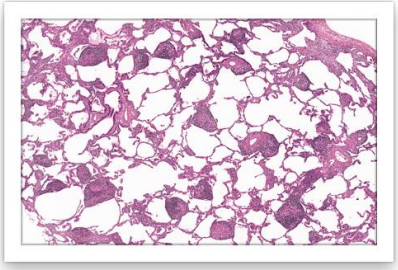

Path_FIG3B.tif

Figure 4. Photomicrographs illustrating a range of fibrotic and non-fibrotic features that may influence multidisciplinary assessment of unclassifiable ILD. **A.** A low magnification image of a surgical lung biopsy shows features typical of usual interstitial pneumonia (UIP), including patchy fibrosis, scarring and honeycomb change, and fibroblast foci (hematoxylin and eosin stain; original magnification 1.5x). **B.** Non-necrotizing granulomatous inflammation and lymphoid aggregates in a surgical lung biopsy from a patient with Sjogren syndrome. The biopsy findings are typical of neither lymphoid interstitial pneumonia (LIP) nor follicular bronchiolitis, two overlapping forms of pulmonary lymphoid hyperplasia common in this setting. While this makes this lesion difficult to classify, assuming that an infectious etiology has been vigorously excluded one might reasonably predict that immunomodulatory strategies are likely to be more effective than anti-fibrotic medications (hematoxylin and eosin stain; original magnification 3.3x).