Int J CARS (2012) 7 (Suppl 1):S141–S145
DOI 10.1007/s11548-012-0713-6

IMAGE GUIDED LIVER SURGERY

Towards higher precision in instrument guided liver surgery: automatic registration of 3D ultrasound with pre-operative MeVis-CT

D. Ribes[1], M. Peterhans[1], S. Anderegg[2], D. Wallach[1], V. Banz[3], C. Kim-Fuchs[3], D. Candinas[3], S. Weber[1]
[1]Bern University, ISTB, Bern, Switzerland
[2]CAScination AG, Bern, Switzerland
[3]Department of Visceral Surgery and Medicine, Clinic for Visceral and Transplantation Surgery, Inselspital, Bern University, Hospital and University of Bern, Bern, Switzerland

Keywords Liver surgery · Registration · CALS · Ultrasound

Purpose

Liver cancer is the 5th most common cancer and shows poor prognosis [1]. Surgical removal of liver tumours, the only existing curative treatment, can merely be used in 10–20 % of the case [2]. Increasing surgical precision is a key-challenge to give more patients access to a potentially curative treatment. Recent progress in computer science enables the use of instrument guidance systems for open liver surgery by providing improved orientation and guidance support during planning and intraoperative realization [3]. However, challenge remains when precise alignment between preoperative image data and the intraoperative situation is required, since the liver is subject to deformation and movements during the surgical treatment. The CAS-One liver navigation system (CAScination AG, Switzerland) applies a landmark based registration technic to perform the alignment. Major drawbacks of this technic reside in the difficulties of identifying accurately correspondences between the preoperative image data and the intraoperative situation. In a recent study, including more than 50 surgeries performed with the CALS system, the authors measure a median alignment precision of 6.3 mm. We present a framework to improve such alignment using intraoperative ultrasound imaging (US) and preoperative computed tomography (MeVis-CT) data.

Methods

The CAS-One liver navigation system (CAScination AG, Switzerland) is composed of an optical tracking system (Polaris Vicra, Northern Digital Inc., Canada), a miniaturized ultrasound system (Terason T3000 system with a 8IOA intra-operative probe, Terason Inc, Burlington MA, USA), a shuttle PC, a touch screen monitor and a set of custom tools for liver surgery. Navigated ultrasound imaging is acquired accurately through a clinically applicable calibration framework [4]. The initial alignment between the preoperative image data and the intraoperative situation is achieved via a locally-rigid, landmark-based registration on the organ surface and/or within the organ. The proposed method for improving this alignment is detailed below.

A total of 14 corresponding MeVis-CT and US datasets (both in 3D) were collected during open liver surgery of nine patients (58 ± 28 years, 3 males, 6 females) using the liver navigation system developed at ARTORG CCAS. The following protocol was performed: (1) Pre-alignment of the MeVis-CT model with the real patient using manually selected landmarks. (2) Acquisition of 3D volumes of B-mode navigated US images on a desired region of interest (ROI) (e.g. around tumours). (3) Real-time segmentation of available vessel in the US images [5]. (4) Compounding of the US images to create a 3D US vessel model. (5) Computation of a 6 degrees of freedom registration between the compounded US vessel models and the preoperative MeVis-CT data. (6) Measurement of success of the alignment process (Fig. 1).

The automatic segmentation algorithm applied a Gaussian Naives classifier using a combination of three statistical features (standard deviation, median and local range with a kernel size of 10, 4 and 2, respectively). The segmentation algorithm was trained over a set of 40 liver US images and tested on a separate set of 219 images. The compounding algorithm uses the position of the navigated US to set the vessel probability value obtained from the segmented algorithm at the correct location into the ROI. The registration process applied the VTK Iterative Closest Point (VTK-ICP) algorithm between the surfaces of the vessel models from the US and the MeVis-CT.

Results

Manual pre-alignment was performed with a mean accuracy of 11 mm. Applied on the test dataset the segmentation algorithm

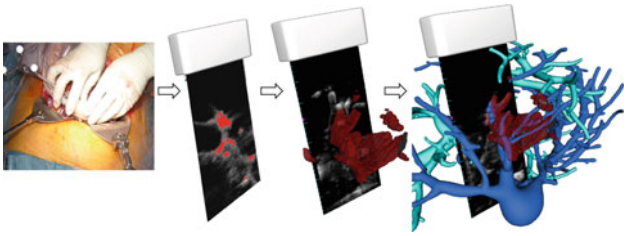

Fig. 1 From *left* to *right*: Acquisition of US images data on a desired ROI, automatic real-time segmentation, compounding of the US images and 6d of registration between the vessel surfaces of the compounded US model and the MeVis-CT

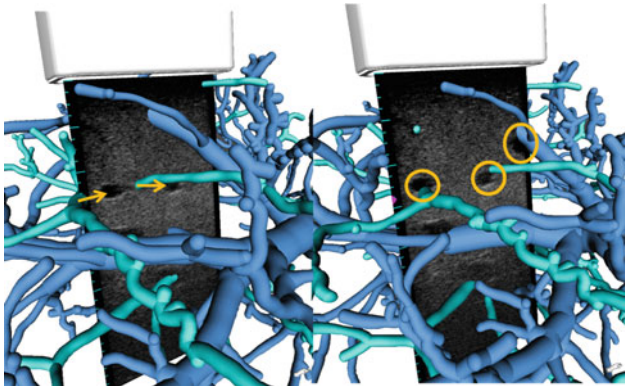

Fig. 2 *Top*: Example of registration results framework, *left*: Pre-alignment results, *right*: alignment improvement after registration framework

achieved a mean sensitivity and specificity of 39 and 98 % respectively. Large vessels (e.g. cross of the portal vein) were visually identifiable on the 3D US generated model. In 8/14 (57 %) datasets, alignment between the preoperative image data and the intraoperative situation was improved according to visual inspection (Fig. 2). Alignment did not improve in 34 % of the cases, attributed to insufficient amount of vessel information in the acquired ROI (e.g. large tumours) (28 %), non-convergence of alignment algorithm due to poor US image quality (7 %), and an unclear technical failure of the algorithm (7 %). US acquisition, vessel segmentation and automatic registration required 49 s of time on average. A more quantitative assessment for alignment accuracy is currently under development.

Conclusion

We present the first results on the evaluation of an automatic US based registration approach. This will allow for precise alignment of the intraoperative situation with the pre-operative image data. First qualitative results indicate that its precision is better than those in existing (manual) alignment approaches. Involved clinicians confirmed the general usability of the presented framework in clinical routine. More data sets are currently collected to assess the precision of the approach.

References

[1] Bosch FX, Ribes J, Diaz M et al. (2004), Primary liver cancer: worldwide incidence and trends. Gastroenterology 127: 5–16.
[2] Petrowsky H, Gonen M, Jarnagin W, et al. (2002), Second liver resections are safe and effective treatment for recurrent hepatic metastases from colorectal cancer: a bi-institutional analysis. Ann Surg. 235:863–871.
[3] Peterhans, M., vom Berg, A., Dagon, B., Inderbitzin, D., Baur, C., Candinas, D. and Weber, S. (2011), A navigation system for open liver surgery: design, workflow and first clinical applications. The International Journal of Medical Robotics and Computer Assisted Surgery, 7: 7–16.
[4] Peterhans M, Anderegg S, Gaillard P, Oliveira-Santos T, Weber S. (2010), A fully automatic calibration framework for navigated ultrasound imaging. Conf Proc IEEE Eng Med Biol Soc., 1242–1245.
[5] Aparicio J, Peterhans M, Ribes D, Weber S. (2011), Classification of different tissue types in ultrasound images of the liver. Conf Proc SSBE, 6.

Development of a surgical template system for application in image guided liver surgery

D. Wallach[1], M. Peterhans[1], B. Brun[1], V. Banz[2], D. Candinas[2], S. Weber[1]
[1]University of Bern, Artorg Center for Computer Aided Surgery, Bern, Switzerland
[2]Inselspital, University Hospital and University of Bern, Department for Visceral Surgery and Medicine, Bern, Switzerland

Keywords Liver surgery · CALS · Patient-specific template

Purpose

Although surgical resection remains the treatment of choice for malignant liver tumors, around 80 % of patients are considered unresectable because of various reasons, among which the size and location of the lesion [1]. By increasing the effective spatial accuracy during surgical resections and ablations of liver tumors, surgical instrument guidance systems may increase the number of patients eligible for surgery, and thus substantially improve patient outcome. A main challenge of their application is the transfer of the preoperative planning data (based on CT or MRI) to the intraoperative setting. This is particularly challenging in liver surgery, as the liver shape and size can differ greatly between the preoperative imaging and the surgery.

Patient-specific 3D templates are routinely used in the context of implant placement in dental and orthopedic surgery. Such templates are created from the negative 3D surface of the bone and can be used as guides for cutting, milling or drilling the bone according to the preoperative planning [2, 3].

In this work, we propose such a template for liver surgery. Placed around the liver, it can exactly reproduce the shape of the liver (known at the time of imaging) and enable the tracking of the organ during the surgery.

Methods

A first mesh was designed and produced for a patient scheduled for surgical resection of liver metastases.

The liver surface was segmented in the pre-operative CT and then meshed, resulting in a 3D grid reproducing the shape of the liver. The mesh was reduced to the parts relevant for maintaining the organ shape and separated in 3 sub parts to be mounted on the liver. From this 3D model, a biocompatible, sterilisable, polymer-based plastic mesh was produced using a rapid-prototyping process. In the final step, four retro-reflective spheres were added on the surface of the mesh (Fig. 1) in order to enable its tracking by a surgical instrument guidance system (CAScination, Bern, CH) using optical tracking [4].

Results

The mesh was successfully placed around the liver and mounted during surgery. It was qualitatively observed that the template successfully constrained the organ to its preoperative shape and size, even after complete mobilization (Fig. 2).

The liver was co-registered to its image data (MeVis, Bremen, Germany) by identifying corresponding landmarks on the model and in the situs. Landmarks were chosen both on the liver and on the mesh, leading to a fiducial registration error of 1.8 mm, compared to a median error of 6.3 mm when the registration uses standard anatomical landmark registration. After registration, the system was used to navigate the ultrasound imaging (Fig. 3).



Fig. 1 Unmounted (*top*) and mounted (*bottom*) 3D mesh