

Case Report

Peptide Receptor Radionuclide Therapy for a Phosphaturic Mesenchymal Tumor

Simon Häfliger^a Ann-Katrin Seidel^a Eric Schoch^b Jan Reichmann^c
Damian Wild^c Stephanie Steinmann-Schwager^d Miklos Pless^a

^aDepartment of Medical Oncology, Kantonsspital Winterthur, Winterthur, Switzerland;

^bDepartment of Radiology, Kantonsspital Winterthur, Winterthur, Switzerland; ^cDivision of Nuclear Medicine, University Hospital Basel, Basel, Switzerland; ^dHausärzte am Bahnhofplatz, General Medicine Office, Winterthur, Switzerland

Keywords

Phosphaturic mesenchymal tumor · Tumor-induced osteomalacia · DOTATOC · Peptide receptor radionuclide therapy · Radiofrequency ablation

Abstract

Tumor-induced osteomalacia is a very rare paraneoplastic syndrome. It can be caused by phosphaturic mesenchymal tumor (PMT), a generally benign tumor that produces fibroblast growth factor 23 (FGF-23), which can cause a severe renal phosphate wasting syndrome. Upon complete surgical removal of the tumor, FGF-23 normalizes and the osteomalacia is cured. In cases in which surgery is not feasible, radiofrequency ablation (RFA) is the treatment of choice. We describe a case with a PMT situated in the sacrum, in close proximity to the sacral plexus. Both surgery and RFA were considered potentially nerve damaging. Since the tumor showed expression of somatostatin receptors, we opted for a peptide receptor radionuclide therapy (PRRT) with ¹⁷⁷Lu-DOTATOC. However, the therapy did not show the expected success, since the FGF-23 level had even temporarily increased. The patient was then successfully treated with RFA. A partial remission of the tumor was achieved and FGF-23 levels nearly normalized. Despite some severe neurological side effects, the patient showed a remarkable clinical improvement, with no symptoms of osteomalacia within a few weeks.

© 2020 The Author(s).
Published by S. Karger AG, Basel

Simon Häfliger
Department of Medical Oncology, Kantonsspital Winterthur
Brauerstrasse 15
CH-8400 Winterthur (Switzerland)
simon.haefliger@ksw.ch

Introduction

Phosphaturic mesenchymal tumors (PMTs) are rare, endocrine active tumors. They cause severe renal phosphate wasting, which in turn can lead to critical osteomalacia [1]. PMTs are typically small and mostly benign tumors [2] producing fibroblast growth factor 23 (FGF-23) [3]. FGF-23 lowers the expression of sodium/phosphate cotransporters (NaPi-IIa/NaPi-IIc) [4], which are the primary transport proteins responsible for phosphate reabsorption in the kidneys [3]. The paraneoplastic overproduction of FGF-23 lowers reabsorption of phosphate and causes severe paraneoplastic renal phosphate wasting and hypophosphatemia [1]. FGF-23 also affects vitamin D levels by lowering 25-hydroxyvitamin D 1-alpha-hydroxylase in the proximal renal tubules and by increasing the expression of vitamin D 24-hydroxylase, a mitochondrial enzyme responsible for inactivating vitamin D metabolites [4].

Patients with PMT suffer from unspecific but progressive symptoms such as bone and muscle pain, and are therefore commonly misdiagnosed with rheumatic (e.g., seronegative rheumatoid arthritis) or neuropsychiatric illnesses [2, 5]. In most cases, it takes up to 5 years until the correct diagnosis is made [6]. Since phosphate levels are not tested regularly, pathological fractures due to loss of bone density, which occur after several years of pain, are often a key symptom leading to the diagnosis [1].

PMT typically demonstrates expression of somatostatin receptors. Therefore, if a PMT is suspected and a high serum FGF-23 level has been shown, patients may undergo ⁶⁸Ga-DOTA-octreotate (DOTATATE) PET/CT to locate the tumor [7]. The tumor occurs mainly in bones (40%) and soft tissues (55%), and may be located in the thighs and femurs (22.7%), craniofacial region (20.7%), ankles and feet (8.8%), pelvis (8.2%), tibiae and fibulae (6.5%), and arms (6.5%) [3].

To reduce symptoms, a substitution of phosphate and vitamin D can be initiated. Standard care is the surgical removal of the tumor. After the tumor has been removed and the FGF-23 level has normalized, the symptoms disappear and most patients recover quickly [2]. If surgical removal is not feasible, radiofrequency ablation (RFA) or cryoablation seem to be the best options, and they have been performed successfully in several cases [8]. So far, there has been no gold standard for systemic treatment if a surgical or interventional approach is impossible.

The somatostatin receptor expression observed in PMT suggests use of the somatostatin analog octreotide. Octreotide binds to the somatostatin receptor and could therefore down-regulate the endocrine activity of PMT cells – similar to neuroendocrine tumors (NETs). In 2001, a case was reported with a short neoadjuvant octreotide intervention before surgical removal of a PMT. Brief normalization of renal phosphate clearance was achieved [9]. The use of octreotide, however, remains controversial. First, the therapy in the case above was used only for a limited time. Second, 2 subsequently reported cases could not confirm these results. Neither of these cases showed a clinical or biochemical response. Thus, the current value of octreotide for the treatment of PMT remains unclear [10, 11].

Similarly to PMTs, NETs, which are much more prevalent tumors, express high levels of somatostatin receptors. Metastatic NET can be treated successfully with peptide receptor radionuclide therapy (PRRT), using ¹⁷⁷Lu- or ⁹⁰Y-DOTATOC. In PRRT, the somatostatin receptor is targeted with a radionuclide conjugated to a somatostatin analog. Frequently, the beta emitter ¹⁷⁷Lu is used as a radionuclide. In the NETTER-1 trial – a randomized phase III study with a total of 229 patients – the overall response rate to PRRT was 18% [12].

So far there have only been few published cases of patients undergoing PRRT for the treatment of PMT [13, 14]. Due to the lack of data, it is currently uncertain if or when an experimental approach with PRRT is a promising option.

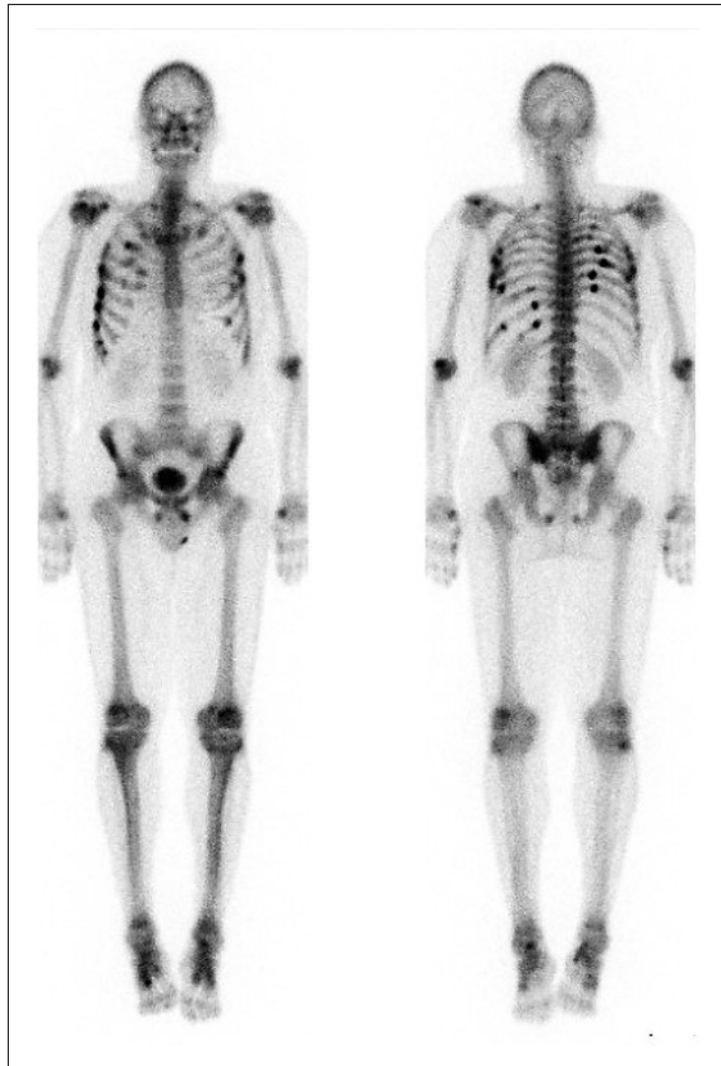

Fig. 1. Whole-body bone scintigraphy showing multiple pathological fractures.

Case Report

Our 58-year-old male patient and former marathon runner had a history of nearly 10 years of increasing lower back and joint pain. He was diagnosed with and treated for seronegative rheumatoid arthritis. However, the symptoms got worse and he developed muscle pain, paresthesias, and increasing concentration difficulties. Ultimately his performance status became very poor and he had to move into a wheelchair-accessible house.

After the patient's back pain had worsened to an unacceptable level without any adequate trauma, his new general practitioner decided to question the diagnosis and ordered a new panel of diagnostic tests.

An MRI of the thoracic and lumbar spine and pelvis revealed a 5-cm-large bone lesion in the sacrum, and metastatic malignancy was suspected. The sacral bone lesion had direct contact to the neuroforamina of S1 and S2 and reached into the canalis sacralis, also affecting the plexus sacralis.

A CT scan and a bone scintigraphy showed several pathological fractures of different age but no evidence of any metastatic malignancy. The known bone lesion in the sacrum was

Table 1. ^{177}Lu -DOTATOC regimen used

Time point	Substance	Dosage
Week 0	^{177}Lu -DOTATOC	7.2 GBq (9.7 Gy)
Week 9	^{177}Lu -DOTATOC	7.1 GBq
Week 19	^{177}Lu -DOTATOC	5.7 GBq
Week 29	^{177}Lu -DOTATOC	6.9 GBq
Total	^{177}Lu -DOTATOC	26.9 GBq

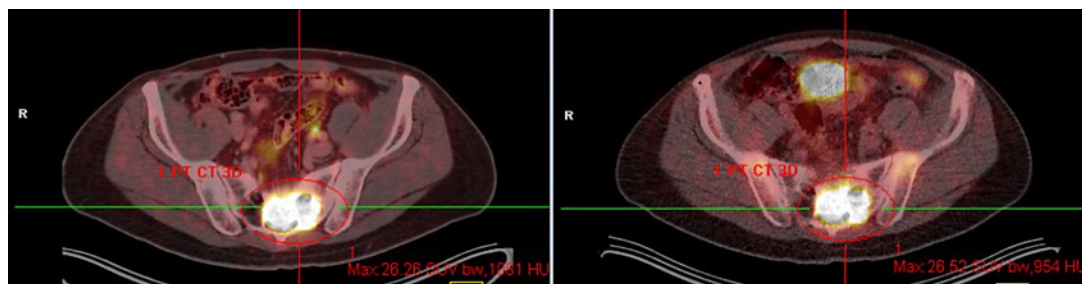


Fig. 2. ^{68}Ga -DOTATATE-PET before (left) and after (right) peptide receptor radionuclide therapy, with no difference in tumor size and ^{68}Ga -DOTATATE avidity.

unspecific, and no discrimination between a pathological fracture and a tumor could be made. Further diagnostics were needed (Fig. 1).

A biopsy was performed and a preliminary diagnosis of PMT was put forward. With an elevated serum FGF-23 level of 215 kRU/L (Ref. 26–110) and a low serum phosphate level of 0.3 mmol/L (Ref. 0.74–1.52), the diagnosis was confirmed. A ^{68}Ga -DOTATATE-PET-CT – the most specific diagnostic imaging for a PMT – showed a solitary tumor in the sacrum measuring $5 \times 5 \times 5$ cm and being highly ^{68}Ga -DOTATATE avid, without any other manifestations.

Standard therapy – surgical removal – was not feasible without severe nerve damage that would have resulted in bladder, rectal and sexual dysfunction. RFA was initially considered too risky for the same reasons. Phosphate and calcitriol supplementation was initiated to diminish the symptoms.

After considering all the available options and in view of the high avidity to somatostatin on ^{68}Ga -DOTATATE-PET, we opted for an experimental ^{177}Lu -DOTATOC treatment. Over a period of 6 months, a total of 4 therapies were administered (Table 1). During the first treatment cycle, tumor dosimetry was done, which revealed a tumor dose of 9.7 Gy after injection of 7.2 GBq ^{177}Lu -DOTATOC. After the 4 cycles of PRRT, another ^{68}Ga -DOTATATE-PET-CT was performed, which showed stable disease, with an identical tumor size and gallium uptake (SUV 26.5 before and 26.3 after treatment) (Fig. 2).

During PRRT, the FGF-23 level temporarily increased from around 200 to over 400 kRU/L (Ref. 26–110). It is likely that a tumor lysis syndrome was involved in this increase, as the FGF-23 values slowly decreased after termination of the ^{177}Lu -DOTATOC treatment. However, FGF-23 remained above the normal level and the phosphate waste continued, which led us to the conclusion that the therapy did not show the expected success (Fig. 3).

Even though the substitution therapy could improve the symptoms, the patient still suffered from fatigue and had a reduced quality of life. Unfortunately, we had to conclude that the ^{177}Lu -DOTATOC treatment had failed.

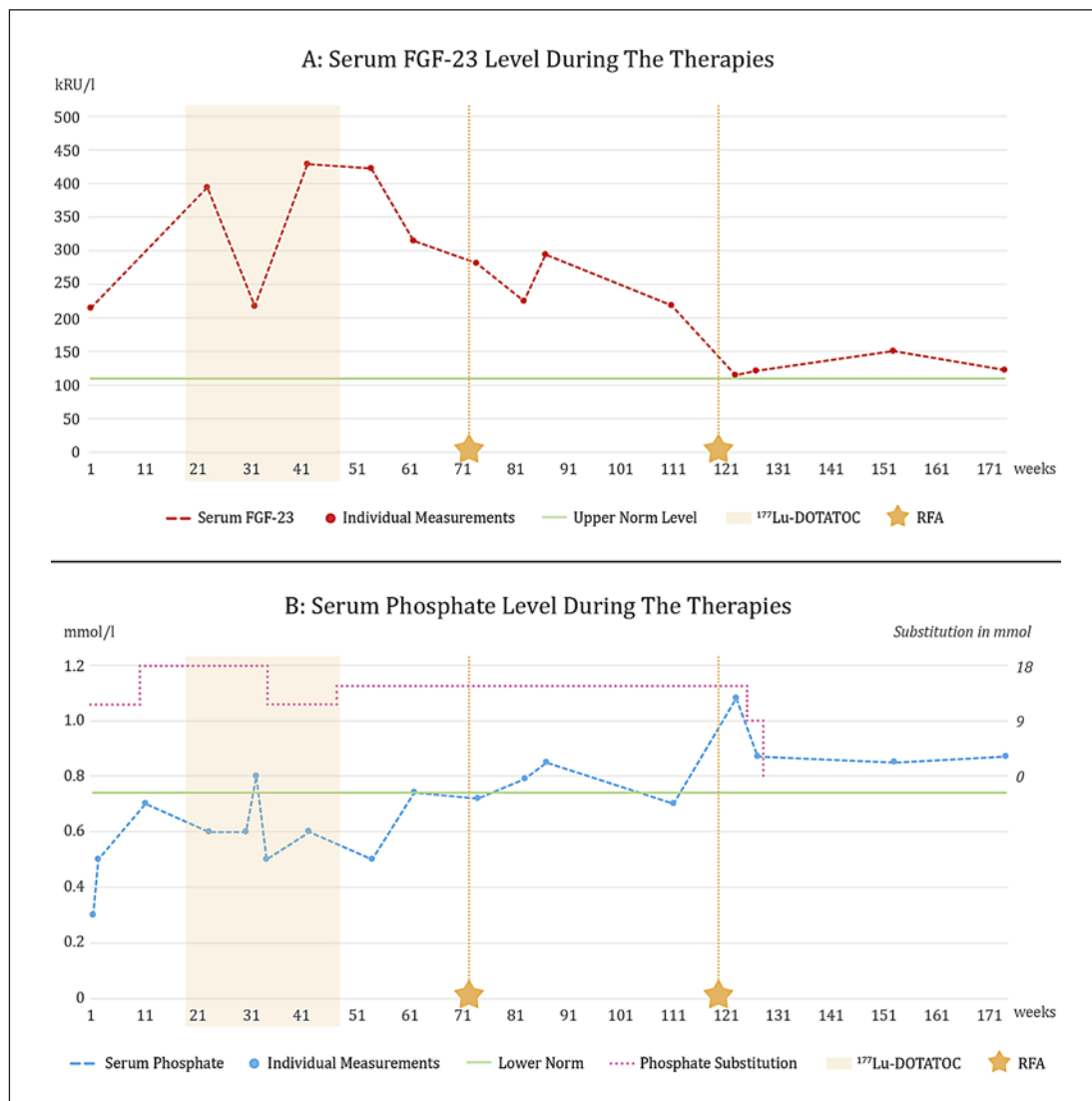


Fig. 3. Serum fibroblast growth factor 23 (FGF-23; **A**) and serum phosphate (**B**) during the therapies.

Due to the lack of any promising alternative, we reviewed the option of RFA. A first RFA was performed in May 2018. The approach was planned and performed successfully without damaging the nerves. A slight reduction of FGF-23 (from 315 to 225 kRU/L) and an increase to the low end of the normal range in the still substituted serum phosphate was seen, albeit without significant clinical improvement. On ⁶⁸Ga-DOTATATE-PET-CT, only a minor reduction in size of less than 10% of the tumor volume was detectable.

Since the symptoms persisted, serum phosphate had again decreased to below the normal level even though substituted, and quality of life was still deemed insufficient, another RFA was attempted. The second RFA was more successful, resulting in partial remission of the tumor, from 5 × 5 × 5 cm to 1.9 × 0.6 × 2.7 cm.

The serum FGF-23 level had almost normalized to a level of 108 kRU/L and renal phosphate waste had stopped. The substitution therapy could be terminated. One year after the intervention, the tumor size remained in partial remission, serum FGF-23 was stable at

slightly above the low end of the normal range, and the phosphate level still was within the normal range without substitution. The patient still had a good quality of life without tumor-related symptoms and an ongoing improvement of the tumor-induced osteomalacia.

Unfortunately, the second RFA had caused neurological damage. The patient suffered permanent loss of surface sensibility on both inner thighs and an acute bladder dysfunction. He also required a transurethral catheter due to urinary retention. After several unsuccessful attempts of voluntary voiding, a suprapubic catheter had to be put in place. Due to the neuronal impairment of the bladder, a previously asymptomatic prostate hyperplasia became symptomatic. Following transurethral prostate resection, the patient is now able to release urine without a catheter again. Finally, a rectal dysfunction occurred, initially requiring enemas. At present, normal voiding is possible with laxatives. Despite these side effects, the patient recovered from the osteomalacia within a few weeks. Pain and muscle weakness disappeared completely, and the patient is now able to do sports again.

In conclusion, despite some serious neurological side effects, the quality of life improved dramatically.

Discussion

To the best of our knowledge, we reported the third case of PMT treated with ^{177}Lu -DOTATOC. Unfortunately, this treatment was not successful, the size of the tumor remained unchanged, and we found no relevant improvement in endocrine activity. In contrast, RFA led to partial remission of the tumor mass and to a significant reduction in endocrine activity, as measured by serum FGF-23 levels. This resulted in a remarkable symptomatic improvement.

There are only 2 previously published reports of cases of DOTATOC therapy for PMT, and both describe some success using DOTATOC [13, 14]. The first paper describes a case of recurrent PMT with good symptomatic improvement and a reduction in SUV on both ^{68}Ga -DOTATATE-PET-CT and FDG-PET/CT upon ^{177}Lu -DOTATOC treatment. According to the RECIST, only stable disease was achieved, but a clear clinical improvement was observed. Unfortunately, no post-treatment serum FGF-23 or phosphate levels were published [13].

The second case describes a metastatic PMT. After resection of the primary tumor in the tarsal region, the tumor was recurrent locally and metastases in both lungs were found. After resection of both metastases, a first ^{177}Lu -DOTATATE therapy was initiated before amputation of the foot to treat micrometastases, and 3 more ^{177}Lu -DOTATATE therapies were administered postoperatively. After the amputation and during the PRRT, a temporary normalization of serum phosphorus levels without supplementation was seen. No metastasis could be found on a ^{68}Ga -DOTANOC-PET-CT scan after the 4 cycles of ^{177}Lu -DOTATATE. However, the patient had to restart phosphorus supplementation 2 months after the last PRRT in order to maintain serum phosphorus levels within the normal range. This indicates that active micrometastases probably persisted after the PRRT. Additionally, it is possible that the temporary normalization of serum phosphate was to a large degree due to the amputation and not to the ^{177}Lu -DOTATATE therapy [14].

There are some important differences between the 2 previously prescribed cases and our case. The tumors in the previous cases were locally recurrent and showed a potential to grow, and one even metastasized, whereas in our case the tumor remained stable in size over the whole observation period of more than 2 years. Thus, the former tumors presumably had a different and more malignant biology, whereas our case displayed the more typical benign course of PMT [2].

In a recurrent and growing tumor, targeted radiotherapy might be more effective. The achievement of stable disease in such a case is a success, whereas in a nongrowing and benign tumor, radiotherapy is less likely to cause critical damage to the tumor. Stable disease as the best response represents the natural course and can be interpreted as ineffective treatment. Surgery, the standard treatment, was not feasible in this case due to the anatomical location of the PMT. RFA, the alternative therapeutic option, was very efficacious, even though several neurological side effects occurred.

At present, no other systemic treatment is available. KRN23, a newly designed investigational recombinant fully human monoclonal IgG1 antibody against the phosphaturic hormone FGF-23, is currently in clinical evaluation. Interim data from a phase II study published in April 2016 showed improved serum phosphorus levels and other bone metabolism measures. The study was then extended to 15 patients, but final data are pending [15].

PMT is a very rare entity. Most cases can be successfully treated with surgery or RFA. It will be very difficult to perform randomized prospective studies on relapsing or refractory PMTs. While there is an obvious rationale for treating these tumors with PRRT, the published case reports so far have shown no or only moderate efficacy of PRRT, since none of the 3 patients were cured.

However, further cases will be needed to investigate whether and in which cases PRRT could be an option for treating PMTs. In this sense, our case provides an important, albeit negative, piece of evidence.

Acknowledgments

We would like to thank Prof. Dr. med. Beata Bode-Lesniewska, who was asked for her expert opinion on sarcoma-like tumors and has put the diagnosis of the PMT forward. We also would like to thank Dr. Cornelia Keller, Kantonsspital Winterthur, for her expert opinion on tumor-induced osteomalacia. Last, we would like to thank Michèle Krüsi, graphic designer, for her extraordinary skills to combine several data into a single graph.

Statement of Ethics

We declare that we comply with the guidelines for human studies and confirm that the research was conducted ethically in accordance with the World Medical Association Declaration of Helsinki. We have obtained informed written consent from the patient to publish his case (including publication of images).

Conflict of Interest Statement

The authors declare that they have no conflicts of interest.

Funding Sources

This paper was not funded by external resources.

Author Contributions

S. Häfliger – research on similar cases, interpretation of the available patient data, design of the work, and writing. A.-K. Seidel – treatment and long-term documentation of the case, research on similar cases, and critical revision of this case report. E. Schoch – RFA treatment and its documentation, MRI follow-up, and critical revision of this case report. S. Steinmann-Schwager – documentation and research on the patient’s medical history, start of the diagnostic chain, and critical revision of this case report. J. Reichmann – treatment and documentation of the DOTATOC therapy. D. Wild – expert opinion on DOTATOC therapy, contribution by providing similar cases and interpretation of these cases, and critical revision of this case report. M. Pless – decision-making, treatment, design of the work, interpretation of the previous cases, and critical revision of this case report.

References

- 1 Jan de Beur SM. Tumor-induced osteomalacia. *JAMA*. 2005;294(10):1260–7.
- 2 Florenzano P, Gafni RI, Collins MT. Tumor-induced osteomalacia. *Bone Rep*. 2017;7:90–7.
- 3 Dadoniene J, Miglinas M, Miltiniene D, Vajauskas D, Seinins D, Butenas P, et al. Tumour-induced osteomalacia: a literature review and a case report. *World J Surg Oncol*. 2016 Jan;14(1):4.
- 4 Shimada T, Hasegawa H, Yamazaki Y, Muto T, Hino R, Takeuchi Y, et al. FGF-23 is a potent regulator of vitamin D metabolism and phosphate homeostasis. *J Bone Miner Res*. 2004;19(3):429–35.
- 5 Lewiecki EM, Urig EJ, Williams RC. Tumor-induced osteomalacia: lessons learned. *Arthritis Rheum*. 2008;58(3):773–7.
- 6 Shah R, Lila AR, Jadhav RS, Patil V, Mahajan A, Sonawane S, et al. Tumor induced osteomalacia in head and neck region: single center experience and systematic review. *Endocr Connect*. 2019;8(10):1330–53.
- 7 Bhavani N, Reena Asirvatham A, Kallur K, Menon AS, Pavithran PV, Nair V, et al. Utility of gallium-68 DOTANOC PET/CT in the localization of tumour-induced osteomalacia. *Clin Endocrinol (Oxf)*. 2016 Jan;84(1):134–40.
- 8 Mishra SK, Kuchay MS, Sen IB, Garg A, Baijal SS, Mithal A. Successful management of tumor-induced osteomalacia with radiofrequency ablation. *A case series. JBMR Plus*. 2019 Feb;3(7):e10178.
- 9 Seufert J, Ebert K, Müller J, Eulert J, Hendrich C, Werner E, et al. Octreotide therapy for tumor-induced osteomalacia. *N Engl J Med*. 2001;345(26):1883–8.
- 10 Paglia F, Dionisi S, Minisola S. Octreotide for tumor-induced osteomalacia. *N Engl J Med*. 2002;346(22):1748–9.
- 11 Ulas A, Dede DS, Sendur MA, Akinci MB, Yalcin B. Expectations of response from octreotide therapy in recurrent phosphaturic mesenchymal tumors – do they reflect reality? *Asian Pac J Cancer Prev*. 2014;15(24):10997–8.
- 12 Strosberg J, El-Haddad G, Wolin E, Hendifar A, Yao J, Chasen B, et al. Phase 3 trial of 177Lu-DOTATATE for midgut neuroendocrine tumors. *N Engl J Med*. 2017;376(2):125–35.
- 13 Basu S, Fargose P. 177Lu-DOTATATE PRRT in recurrent skull-base phosphaturic mesenchymal tumor causing osteomalacia: a potential application of PRRT beyond neuroendocrine tumors. *J Nucl Med Technol*. 2016;44(4):248–50.
- 14 Nair A, Chakraborty S, Dharmshakti P, Tandon N, Gupta Y, Khadgawat R, et al. Peptide receptor radionuclide and octreotide: a novel approach for metastatic tumor-induced osteomalacia. *J Endocr Soc*. 2017;1(6):726–30.
- 15 Ultragenyx Pharmaceutical. Ultragenyx reports positive interim data from phase 2 study of KRN23 for the treatment of tumor-induced osteomalacia. *Globe Newswire*. 2016. Available from: <http://ir.ultragenyx.com/news-releases/news-release-details/ultragenyx-reports-positive-interim-data-phase-2-study-krn23-0>.