Sonography, My Personal Assistant at Hand Outpatient Clinic

Samuel Christen, MD[a], Esther Vögelin, MD[b,*]

KEYWORDS

• Clinical impact • Sonographic diagnosis • Hand • Wrist • Ultrasound

KEY POINTS

- Ultrasonography is an important diagnostic tool in the daily practice of a hand surgeon in evaluating traumatic and degenerative lesions of bones, joints, ligaments, tendons, annular pulleys, nerves, and vessels; detection of foreign bodies; and evaluation of small tumors.
- Ultrasonography offers an internal image of anatomic structures in axial, coronal, and transversal planes as well as observing dynamic changes during motion.
- Ultrasonography is examiner dependent but allows a direct, noninvasive view of anatomic structures in the best suitable way of the examiner with regard to the pathology of the patient.
- Ultrasonography immediately allows to infiltrate precisely in joint or tendon spaces, to plan surgery, or to perform sonographically assisted miniinvasive surgery.

Video content accompanies this article at http://www.hand.theclinics.com.

INTRODUCTION

Ultrasonography (US) is an easily accessible, rapid, radiation-free, noninvasive imaging technique with useful dynamic capabilities suitable to study small (<3 cm) and superficial structures. If a lesion is previously suspected at clinical assessment US may add useful information confirming or modifying the diagnostic and therapeutic path. In the literature, US has been shown to confirm the diagnosis in 40% of patients with a history of previous trauma, 21% with a history of overuse, 16% after previous surgery, 13% with a history of neuropathy, and in 10% with diffuse pain.[1] However, most of the patients with hand problems are still referred to radiologists, rheumatologists, or neurologists who perform US and then send back the patient to the referring institution with a delay of possible treatment. Using US in the hands of the treating physician, a direct patient feedback and history during examination is available influencing a possible immediate treatment. In examination of tendon and ligamentous injuries, dynamic imaging can be obtained, which is invaluable in the assessment of annular pulley injuries, joint stability, and tendon subluxations or adhesions. With the use of a high-frequency linear array transducer in the range of 15 to 18 MHz, imaging of all interesting structures in both longitudinal and cross-sectional axes is available. It is important to learn to interpret lateral spatial resolution, tissue contrast, and posterior shadowing as well as to decrease artifacts related to reverberation and noise. In soft tissue masses, inflammatory or infectious tenosynovitis, color and power Doppler imaging may demonstrate hyperemic conditions differentiating granulation tissue, hypervascular tumors, or arteriovenous fistulae.[2] With the following case series, I would like to demonstrate the advantage of US in the hands of the treating physician for the patient in order to

[a] Hand, Plastic and Reconstructive Surgery, Cantonal Hospital St. Gallen, Rorschacherstrasse 95, 9007 St.Gallen, Switzerland; [b] Hand Surgery and Surgery of Peripheral Nerves, Plastic and Surgery, Inselspital, University Hospital of Bern, Freiburgstrasse 10, CH-3010 Bern, Switzerland
* Corresponding author.
E-mail address: esther.voegelin@insel.ch

Hand Clin 38 (2022) 19–29
https://doi.org/10.1016/j.hcl.2021.08.002

diagnosis the problem immediately, to initiate conservative treatment such as precise infiltration or to plan surgery without any delay.

Traumatic Disorders of Bones, Joints, and Tendons

Ultrasound has additive value in diagnosis of minimally displace fracture with high sensitivity and specificity.[3] We started to use it in suspicion of fractures such as subcapital metacarpal, scaphoid, or phalangeal fractures as a first or additional diagnostic tool. US may identify fractures shadowed by adjacent bones.[4] Osseous structures including avulsed fragments can be distinctively recognized by their pronounced posterior acoustic shadow and strongly reflective hyperechoic surface. Acute nondisplaced fractures appear as a focal hypoechoic interruption with an otherwise hyperechoic cortex. For a patient, it may be important to diagnose a nondisplaced fracture (**Fig. 1**, Video 1), especially when this fracture is not visible on anteroposterior or lateral conventional radiograph. US helped to initiate conservative functional treatment with buddy taping without the necessity to perform a computed tomography (CT) scan or a dynamic radiograph to check the stability of the present fracture pattern.

With US the extent of intraarticular osseous avulsion injuries of small joints (interphalangeal and metacarpal phalangeal joints) may be assessed. In proximal interphalangeal joint dislocation, US allows to localize preoperatively the intraarticular fragments in relation to the collateral ligaments as in this example (**Fig 2**, Video 2). It was possible to differentiate the cause of joint instability by the osseous dislocated fragment from the radial side of the middle phalanx and not by ligament disruption or avulsion and an additional fracture. With the preoperative US information, surgery is better planable, also in more complex injuries involving the palmar plate, pulleys as well as osseous avulsion of the central slip.[5]

A common injury involves the ulnar collateral ligament (UCL) at the level of the first metacarpophalangeal (MCP) joint. The torn UCL may retract proximally allowing the overlying tendinous aponeurosis of the adductor pollicis muscle to slip underneath its proximal margin, forming the so-called Stener lesion and hindering nonoperative healing. US may identify not only a Stener lesion but allows to differentiate nondisplaced from displaced UCL tears and to distinguish partial tears from complete tears.[6] A ligamentous sprain is seen as diffuse hypoechoic thickening without focal disruption, whereas tears are seen as a discrete hypoechoic partial or complete discontinuity within the thickened ligament. With a Stener lesion, the UCL is retracted and balled-up proximally due to displacement by the interposed adductor aponeurosis (**Fig 3**, Video 3). The smooth outline of the thin hyperechoic adductor aponeurosis will be identified distal and deep to the proximally retracted UCL in a transversal US scan. Partial or full-thickness ligament tears have immediate consequences for conservative or surgical treatment.

Similar to collateral ligament injury, partial tearing of the palmar plate manifests with

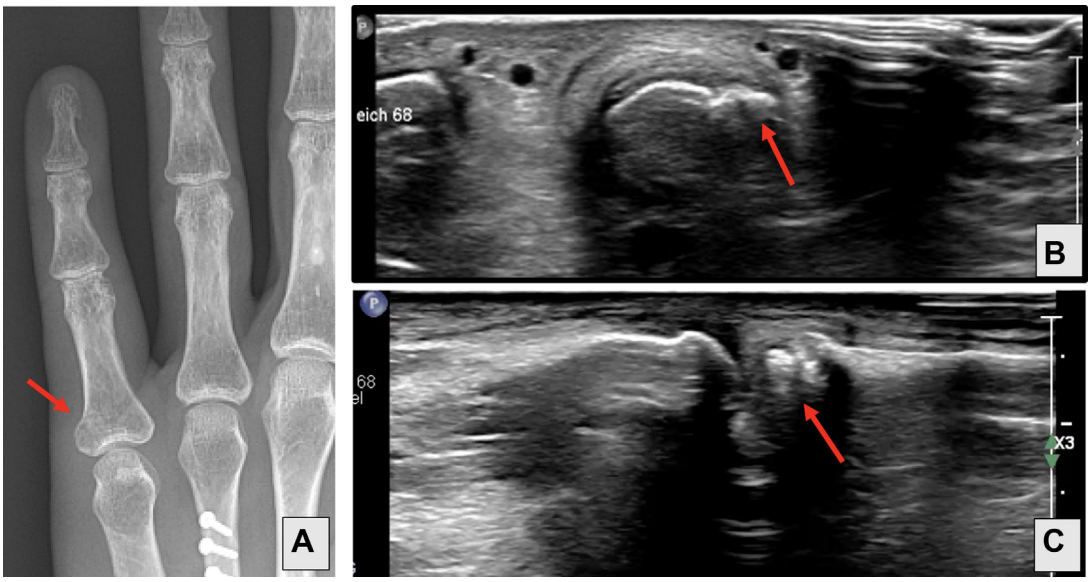

Fig. 1. Arrows pointing to fracture. (*A*) Radiograph without obvious fracture of proximal phalanx. (*B*) Axial view of dorsoulnar fracture. (*C*) Longitudinal view of dorsal fracture.

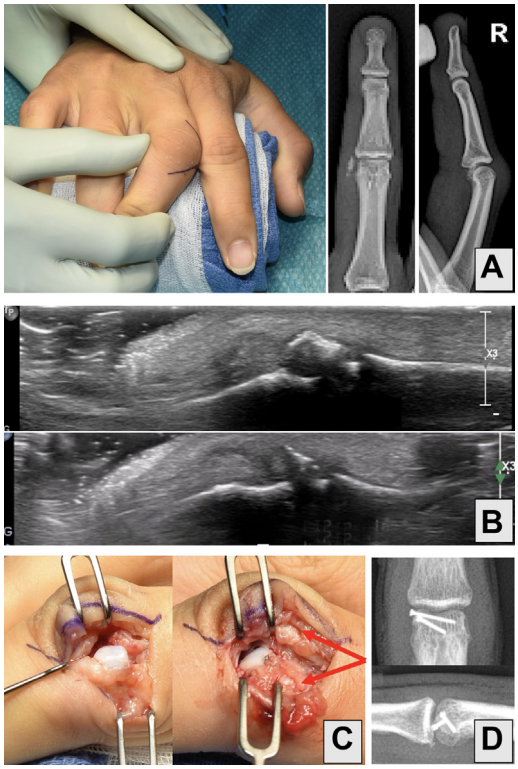

Fig. 2. (*A*) Unstable PIP joint, radiograph with osseous avulsion injury of radial collateral ligament. (*B*) Longitudinal view of US with intraligament fracture fragment from the base of middle phalanx. (*C*) Intraoperative 1 mm screw fixation of the thin fragment at the base of middle phalanx with partially divided collateral ligament (*arrows*). (*D*) Postoperative radiograph.

hypoechoic edematous thickening. Complete tears occur at the distal insertion and will appear as focal structural discontinuity with pericapsular edema and fluid.[7] Accompanying intraarticular avulsion fractures commonly occur, appearing as a hyperechoic focus with prominent posterior acoustic shadowing adjacent to the PIP joint. Partial and complete osseous avulsion of the palmar plate as well as its stability and stiffness including the subcutaneous edema in the involved digit may be assessed by US after trauma (**Fig 4**, Video 4). According to the US findings, the treatment plan may be adapted. With a sonographically and clinically stable palmar plate, a splint in extension may be used instead of an extension-stop-splint, to avoid flexion contracture. According to the edema seen in US early and in due course, local compression bandages (Coban) or lymph-tapes may be used to reduce swelling.[8]

US has proved utility in assessing the extent of tendon discontinuity and retraction as well as adhesion formation and in identifying associated osseous avulsion injuries or multitendon injury. In this case with complete inability to flex the finger after a proximal phalanx fracture, only US could demonstrate which flexor tendon (superficial, deep tendon) was involved and whether there was a rupture with a gap or rather posttraumatic adhesions (**Fig 5**, Video 5 + 6). The probability of a 1-stage or 2-stage tendon reconstruction compared with a tenolysis could be estimated, and the patient was accordingly informed.

With careful attention to scanning technique and anatomic detail, partial tendon tears can be

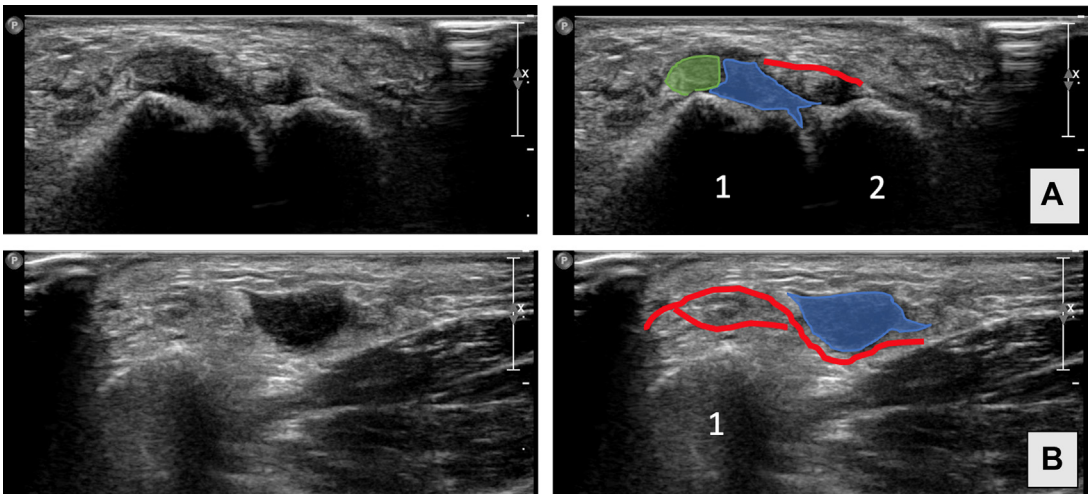

Fig. 3. (*A*) Longitudinal view of the head of MC I and basis of proximal phalanx I. Green = proximal UCL stump. Blue = hematoma, red line = adductor aponeurosis. (*B*) Transversal view of the head of MC I; red line = adductor aponeurosis with sagittal band and extensor tendon (Stener lesion); blue = hematoma over adductor aponeurosis. MC, metacarpal.

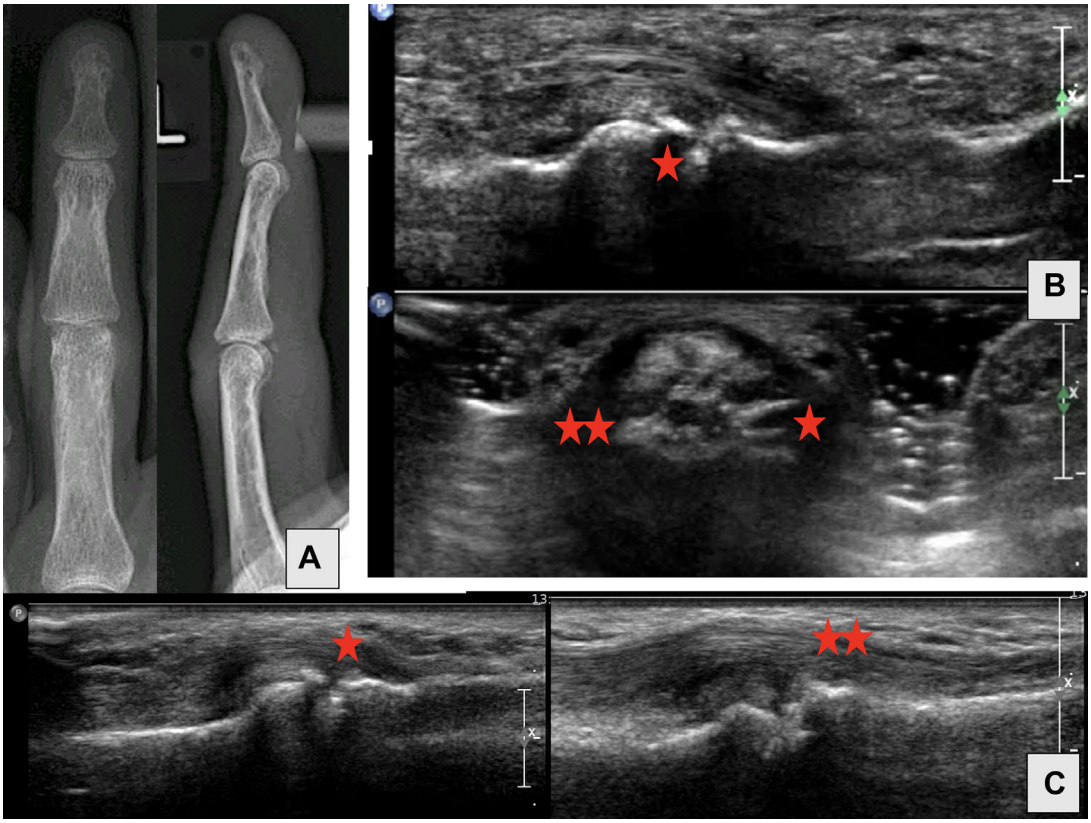

Fig. 4. (*A*) Palmar plate avulsion, little fragment on radiograph. (*B*) Radial palmar plate fragment* with 1 mm dehiscence from base of middle phalanx, longitudinal, and additional small impression on ulnar side** in axial view. (*C*) Radial* and ulnar** stable fragments after 5 months.

quantified, aiding in surgical planning. Postoperative repair sites may demonstrate lasting attritional changes and loss of the normal hyperechoic fibrillar pattern due to granulation tissue and scarring, complicating the assessment for reinjury.[9] Noting the presence or absence of secondary signs such as surrounding edema and fluid as well as using real-time dynamic techniques to directly evaluate morphologic integrity is useful in distinguishing chronic injury.

Degenerative Disorders of Joints and Tendons

Wrist

Although conventional radiography is the current referenced standard imaging modality for evaluation of bone changes (osteophytes subchondral sclerosis, cysts, and joint space narrowing), US has been proved more sensitive than conventional radiography in detecting certain bone changes and joint space narrowing.[10] Painful degenerative wrist conditions include lesions such as scapholunate advanced collapse conditions. In this 50-year-old lady with massive wrist pain after monotonic laboratory work, radiograph and CT scan demonstrated an osteophyte at the dorsal horn of the lunate bone. Only US demonstrated the localization of the osteophyte dorsal to the SL ligament toward the midcarpal joint and indicated the surgical procedure including diagnostic arthroscopy and miniarthrotomy to remove the osteophyte without the necessity of SL ligament reconstruction (**Fig 6**, Video 7).

In this other painful swollen wrist after overuse of the hand a week ago, it was necessary to discriminate an inflammatory wrist condition from an infection. Sonographically, fluid was detected in the radiocarpal joint apart from hyperechogenic changes also in the triangular fibrocartilage complex (TFCC) joint (**Fig 7**), assuming calcium pyrophosphate deposition (CPPD) deposits. With US even small deposits of CPPD, with high specificity and sensitivity, and no irradiation risks can be detected. This is important, especially because CPPD generally may be present in more than one joint and not strictly related to clinical presentation. The hyperechoic spots are the most frequent US pattern, and fibrocartilage is more

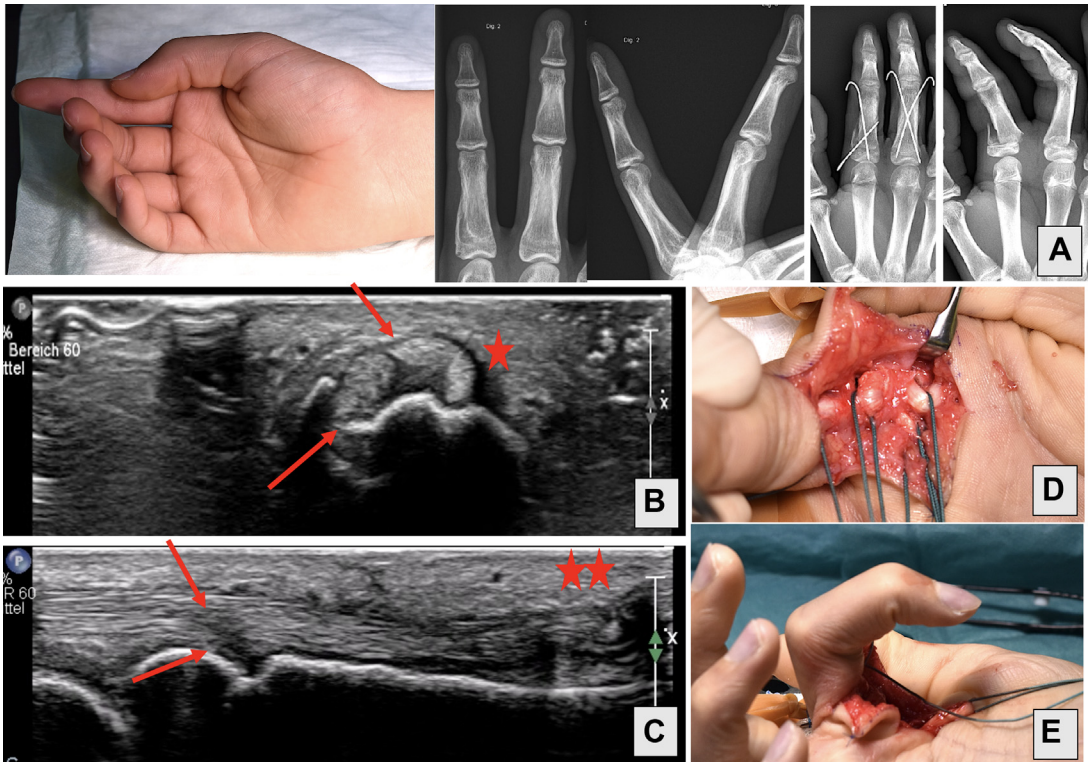

Fig. 5. (*A*) No active flexion of index finger 5 months after removal of K-wires for fixing proximal phalanx fractures II and III. (*B*) Radial FDS and FDP (*arrows*) adherent to fracture site in axial view. *Ulnar FDS tendon slip. (*C*) No discontinuation of tendons in longitudinal view but accordion phenomenon** due to tenodesis at fracture site. (*D*) Intraoperative adherence of radial FDS and FDP tendon at fracture site. (*E*) After tenolysis. FDP, flexor digitorum profundus; FDS, flexor digitorum superficialis.

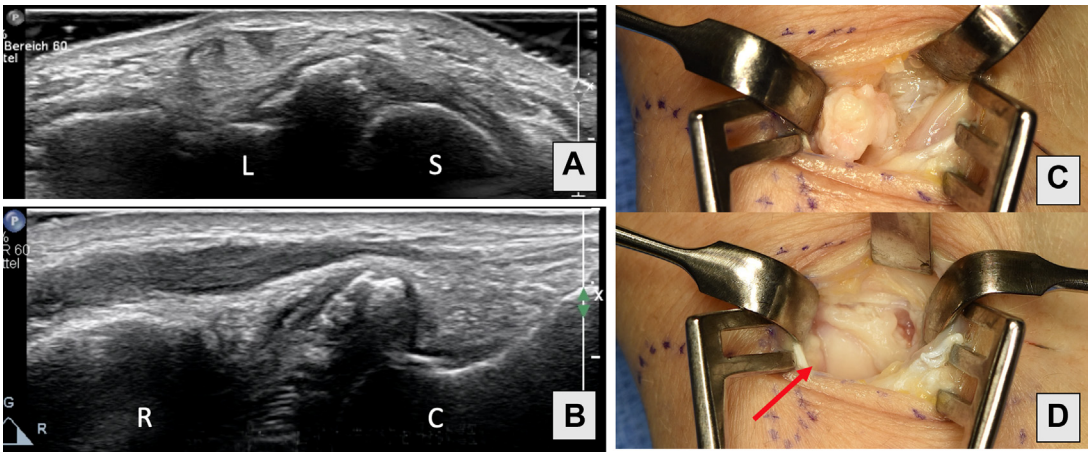

Fig. 6. (*A*) Osteophyte over dorsal horn of lunate dorsal and distal of SL ligament, axial plane. (*B*) Osteophyte over midcarpal joint at capitate, longitudinal plane. (*C*) Intraoperative view of osteophyte over dorsal horn of lunate. (*D*) Arrow at intact SL interval. SL, scapholunate.

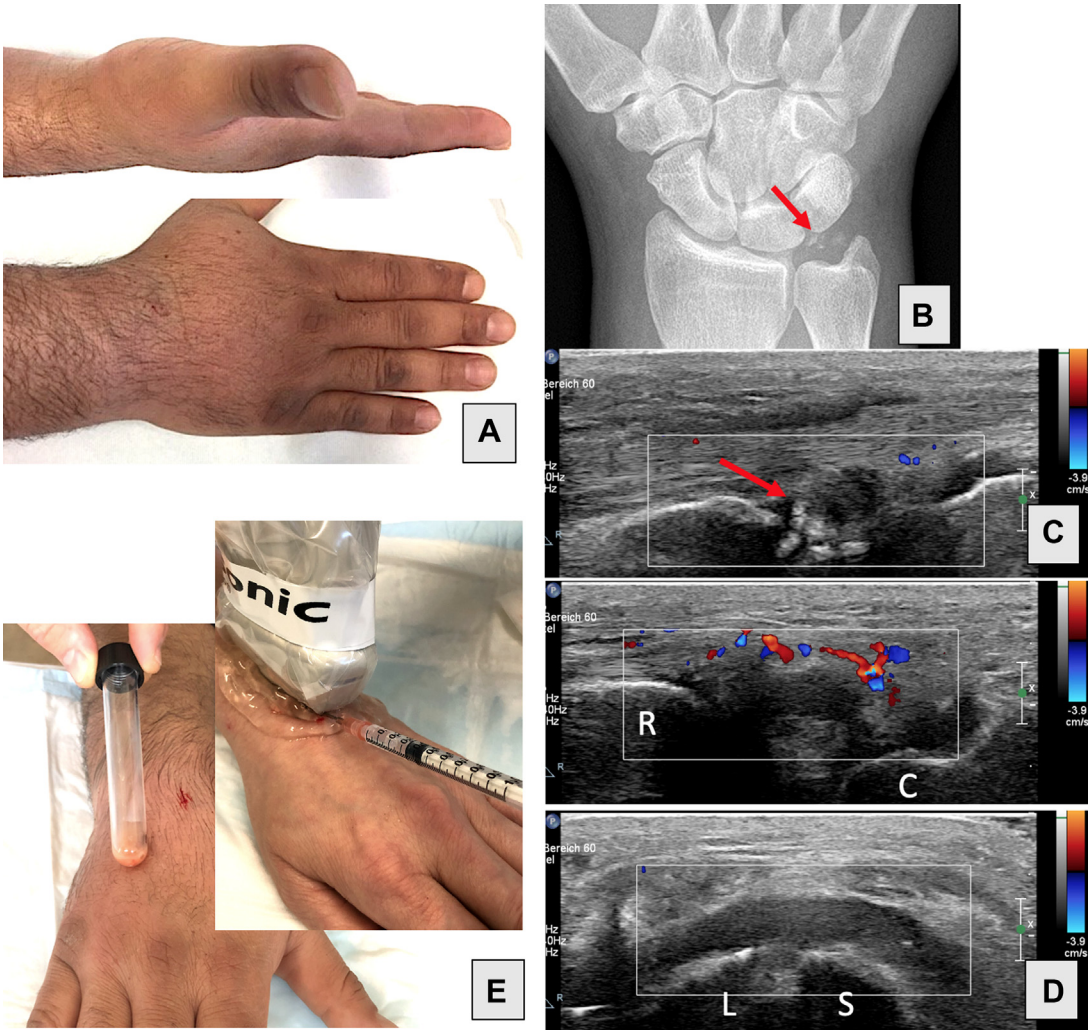

Fig. 7. (*A*) Swelling at wrist and dorsum of the hand without trauma. (*B*) Hyperechogenic changes (*arrow*) in radiograph. (*C*) Hyperechogenic spots (*arrow*) and hypervascularity radiocarpal and midcarpal, longitudinal plane. (*D*) Hypoechogenic fluid over SL interval, axial plane. (*E*) Sterile sonographic puncture of fluid at dorsal radiocarpal joint, crystals confirmed by microscopy, bacterial infection excluded.

frequently affected compared with the hyaline cartilage. The presence of CPPD crystals is usually confirmed by microscopy.[11]

Small joints

Disruption of the sagittal bands or juncturae tendinum results mainly in ulnar subluxation due to preferential tearing of the radial-sided sagittal band[12] after a closed trauma or spontaneously in rheumatoid arthritis. The dynamic, real-time capabilities of ultrasound are of great utility in establishing the diagnosis. Discontinuity, asymmetric thickening, and hypoechogenicity of the paramedian sagittal band may be seen particularly well on short-axis views through the MCP region (**Fig 8**, Video 8 + 9) in this young lady with rheumatoid arthritis. US revealed a lesion of the radial sagittal bands and attenuation but not a rupture of the juncturae tendinum.[13] Because of the attenuation and general laxicity of the tissue, surgical treatment was initiated. Follow-up US can be used after a trial of nonoperative immobilization therapy or surgical repair to evaluate the integrity of the sagittal bands and assess for residual radial/ulnar instability.

Lesions to the collateral ligaments of the MCP joints are less common in the fingers than in the thumb. The slightly hypoechoic appearance of the normal collateral ligaments may be due to an artifact and may be related to the oblique course of their fibers.[14] They are difficult to assess especially in central rays. In this patient (**Fig 9**, Video 10), US was helpful to diagnose the prominent

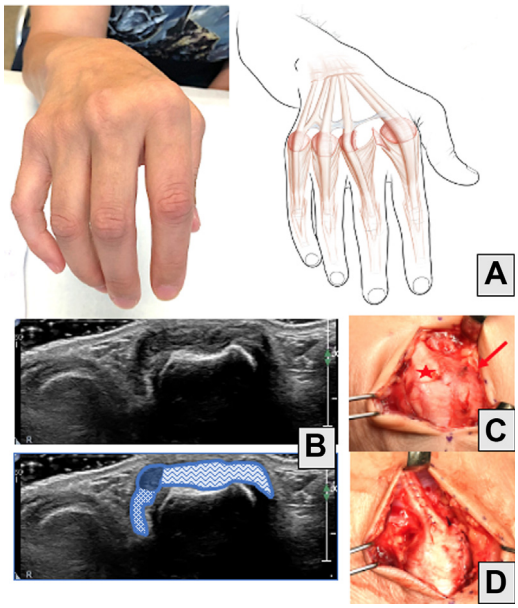

Fig. 8. (*A*) Ulnar subluxation of extensor tendon (EDC III, *arrow*) of middle finger. (*B*) Axial plane of extensor tendon hood with ulnar subluxation and scarring of both attenuated and ruptured sheath of sagittal bands. (*C*) Attenuated external sheath (*arrow*), subluxated EDC III*. (*D*) Repaired, recentered extensor hood by strip of proximal EDC III. EDC, *extensor* digitorum communis.

changes in the involved radial collateral ligament in comparison to the ligaments of the neighbor finger. Chronic steroid infiltration resulted in an instability of the radial collateral ligament of the middle finger but not in the index finger. Hyperechogenic changes with US proposed a chondrocalcinosis and a thickened ligament appearance but no interruption. The clinical snapping and the instability of the central digit suggested an incompetent ligament. However, with US only the dorsal and palmar aspects of the ligament of central rays may be assessed but not the hole ligament course, demonstrating one of the limitations of US.

Tendons

Similarly, suppurative tenosynovitis manifest often with internal fluid, capsular/sheath thickening, and hyperemia. Although the appearance is closely mimicked by noninfectious, inflammatory tendinopathy, the clinical context, presentation, and laboratory findings are frequently discriminatory. Fluid sampling and drainage is typically warranted when the cause remains indeterminate to exclude purulent infection,[15] as seen in the following patient with a chronic swelling 5 weeks after A1 pulley release in the middle finger (Fig 10). Sonographic findings of rheumatoid tenosynovitis include thickening of the tendon sheath, intrasynovial fluid, and alterations in the tendon echo texture

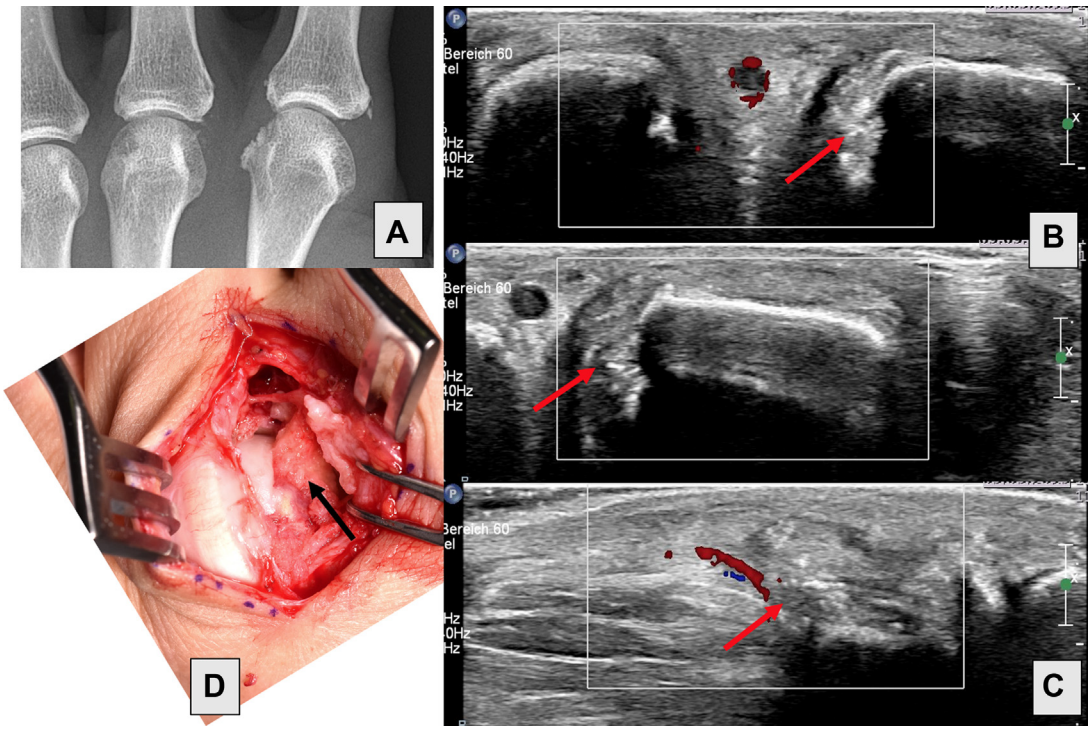

Fig. 9. (*A*) Calcifications in the radial collateral ligament (CL) origin at MCP III, ulnar and radial CL at MCP II. (*B*) Calcification and thickening of radial CL at MCP III (*arrow*), axial plane. (*C*) Longitudinal plane of thickened CL at radial MCP III (*arrow*). (*D*) Complete destruction (*arrow*) of radial collateral CL at MCP III, intact EDC III, cartilage, and sagittal bands.

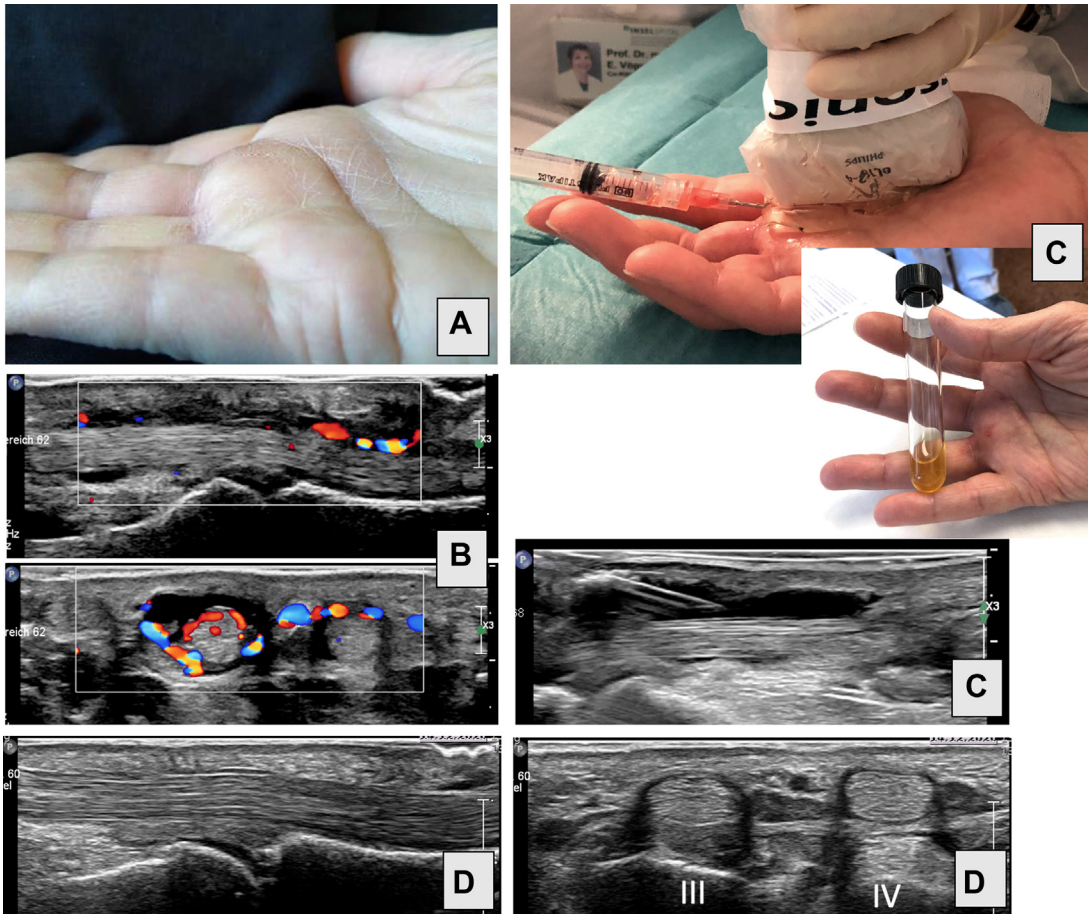

Fig. 10. (*A*) Swelling and synovitis third finger and at A1 pulley, 5 weeks after A1 pulley release. (*B*) Hypervascularity and an echogenic fluid around flexor tendons of third finger, longitudinal and axial plane. (*C*) Sterile puncture of synovial fluid sonographically controlled, bacterial infection excluded. (*D*) Five months later normal appearance of A1 pulley and tendons longitudinal and axial.

ranging from diffuse blurring to focal defects. Doppler imaging reveals synovial hyperemia as a sign of active inflammation; a decrease in synovial vascularization indicates fibrous pannus formation as well as a good response to treatment.[16]

Lumps and Bumps

Foreign bodies

US, with its high sensitivity, is an excellent first-line imaging modality to analyze tumors and foreign bodies. Depending on surface characteristics and composition, foreign bodies will have a generally hyperechoic imaging appearance with variable acoustic shadowing. In the case of glass or metal fragments, reverberation artifact and dirty acoustic shadowing are found. Abscess or granuloma formation may occur in subacute to chronic cases, appearing respectively as an ill-defined hypoechoic halo surrounding the central foreign body locus or as a complex heterogeneous fluid collection with peripheral mural hypervascularity.[17] In this patient (**Fig 11**, Video 11), chronic swelling and decreased motion of his index finger over 2 years after a closed trauma caused by a wooden splinter encapsulated by granulation tissue is detected with US. The rather weird localization of the splinter including the granulation tissue dorsoradially to the flexor tendons and the A2 pulley demonstrated by US helped to plan surgery accordingly.

Soft tissue mass

Posttraumatic vascular anomalies presenting as tumors in the adult population are rare and may occur as extravascular and or intravascular pyogenic granulomas. With US, it is possible to differentiate highly vascularized tumors such as granulation tissue from tumors with changes in the vascular flow of an intravascular pyogenic granuloma or a venous malformation. US demonstrates a hypoechoic mass with monophasic

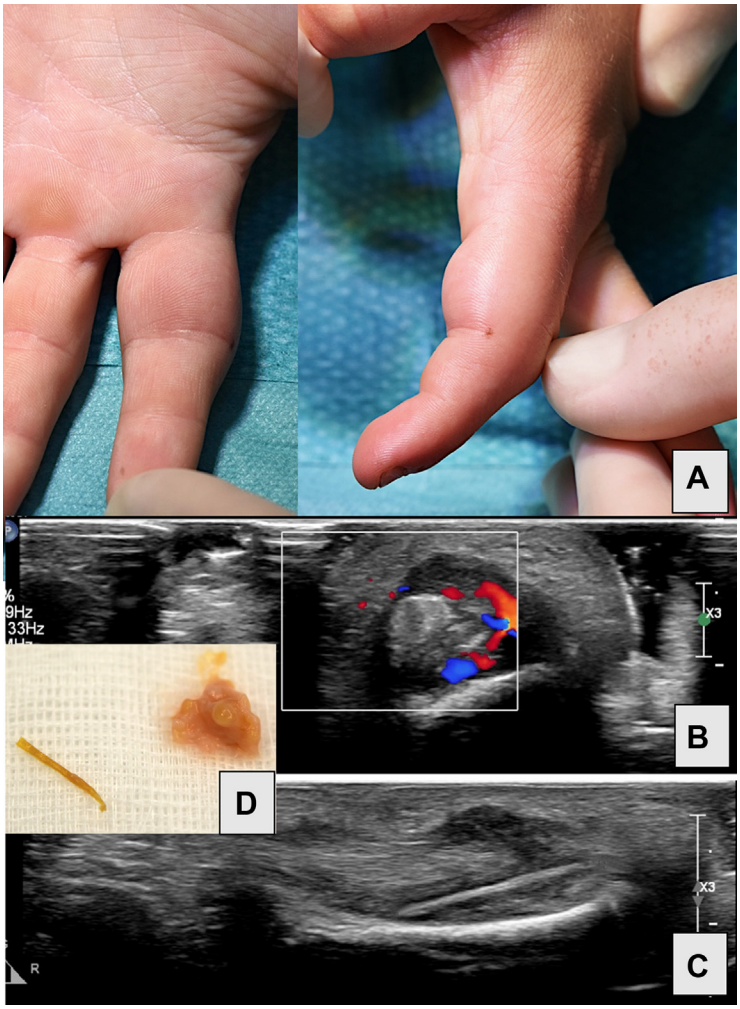

Fig. 11. (*A*) Chronic swelling proximal phalanx of left index finger 2 years after closed trauma. (*B*) Granulation tissue dorsoradial of flexor tendons, axial plane of proximal phalanx. (*C*) Longitudinal plane with foreign body dorsoulnar of flexor tendons. (*D*) Surgery revealed wooden splinter (10 × 1 mm), granulation tissue.

low-velocity flow or occasionally no flow with the Doppler mode.[18] If there is flow within these tumors, a vascular venous or arterial signal using color Doppler may indicate an arteriovenous fistula feeding the tumor as in this patient (Fig 12). Vascular malformations present sonographically as hypervascular tumors with an arterial or venous flow differentiating from hypervascular tumor without flow such as granuloma tissue. The subcutaneous mass around the PIP joint in this patient was diagnosed by US as a vascular malformation tumor due to the Doppler signal and surgery with looking for a vascular stalk feeding the tumor could be planned.

DISCUSSION

US has the potential to affect diagnostic thinking and therapeutic management, especially in a posttraumatic setting but also in degenerative lesions. Sonography plays a pivotal role in the management of inflammatory, traumatic, and neoplastic lesions of the hand and wrist. Good anatomic delineation, pathologic correlation, and the opportunity to perform procedures using real-time imaging makes US the desirable imaging modality in the diagnosis and management of these lesions. The US technology therefore became an essential diagnostic tool in our daily practice for diagnosing posttraumatic sequelae, degenerative or overuse problems, planning surgeries, or even to perform precise infiltrations or sonographically assisted surgeries. US is appropriate for diagnosing superficial lesions, as they occur in the fingers and hand. It can discriminate cystic from solid lesions and identify tenosynovitis, vascular lesions, and foreign bodies. However, it requires a trained operator, and tissue characterization of other masses is often limited. If lesions overcome a size of more than 3 cm,

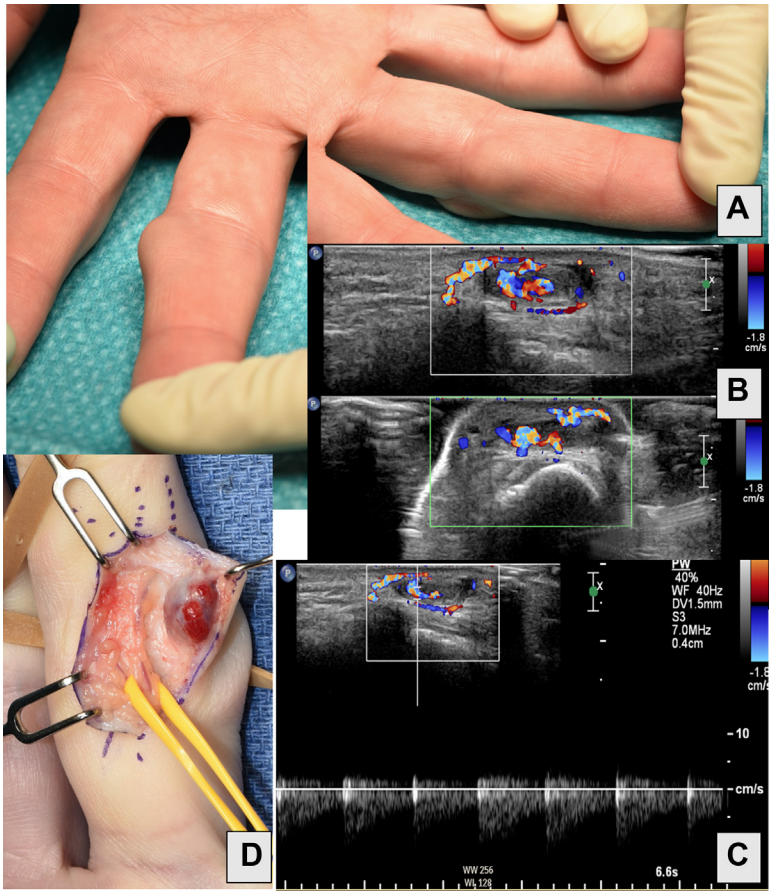

Fig. 12. (*A*) Progressive swelling with minimal tenderness on the radial side at the base of the middle phalanx after a small wound 6 months ago. (*B*) US color Doppler mode longitudinal and axial plane with vascularized tumor. (*C*) US color power Doppler arterial signal suggesting an arteriovenous connection within the tumor. (*D*) Intraoperative: vascular tumor, histologic pyogenic granuloma with a vascular stalk from the digital artery (*yellow band*).

they are more difficult to diagnose including the dignity but also the involvement of the surrounding tissue. Another limitation of US is the fact that we see only a certain depth of a structure and we do not get a complete 3-dimensional image from an anatomic structure as a bone or a joint or the TFCC, and this makes it difficult to assess collateral ligaments or the interosseous muscles of the hand in the central rays of the fingers from the dorsal to the palmar insertion. On the other hand, posttraumatic lesions are well demonstrated with US. We can look for fractures but it is only possible to judge one plane of a fracture at once (ie, lateral, posterior or anterior) in comparison to CT scans and MRI. Tendon injuries such as avulsion injuries of the flexus digitorum profundus (FDP), extensor tendon injuries, such as central slip or mallet fingers, sagittal band injuries, subluxation of tendons, pulley injuries, and ligamentous and volar plate injuries may be assessed dynamically by US. Foreign bodies may not only be localized but characterized whether there is a metal, glass, or wooden splinter. Inflammatory process or infections may be investigated by US. The presence of hyperemia on color or power Doppler imaging may not always distinguish cellulitis from abscess, suppurative tenosynovitis, and or septic arthritis. Although the appearance is closely mimicked by noninfectious, inflammatory process, only fluid sampling and drainage is typically warranted when the cause remains indeterminate to exclude purulent infection.

SUMMARY

With the help of US in the outpatient clinics, traumatic and degenerative lesions are not only localized but the problem diagnosed and immediate conservative or surgical treatment initiated.

CLINICS CARE POINTS

- US is the third eye of hand surgery.
- Examiner-dependent examination in 3 planes, noninvasive.
- With US, precise infiltration of joints or tendon spaces and exact planning of surgical procedures.

DISCLOSURE STATEMENT

I hereby declare that I have no potential conflicts of interest to disclose.

SUPPLEMENTARY DATA

Supplementary data to this article can be found online at https://doi.org/10.1016/j.hcl.2021.08.002.

REFERENCES

1. Tagliafico A, Bignotti B, Rossi F, et al. Clinical Contribution of Wrist and Hand Sonography. J Ultrasound Med 2019;38:141–8.
2. Olubaniyi B, Bhatnagar G, Vardhanabhuti V, et al. Comprehensive musculoskeletal sonographic evaluation of the hand and wrist. J Ultrasound Med 2013;32:901–14.
3. Vreju F, Ciurea M, Popa D, et al. Ultrasonography in the diagnosis and management of noninflammatory conditions of the hand and wrist. Med Ultrasound 2016;18(1):90–5.
4. Hennecke B, Umbricht R, Vögelin E. „Top ten"-Indikationen zur Ultraschalldiagnostik an der Hand. Ther Umsch 2014;71(7):415–21.
5. Vögelin E. Ultrasonography: the third eye of hand surgeons. J Hand Surg 2020;45(3):219–25.
6. Melville D, Jacobson JA, Haase S, et al. Ultrasound of displaced ulnar collateral ligament tears of the thumb: the Stener lesion revisited. Skeletal Radiol 2013;42(5):667–73.
7. Rettig A. Athletic injuries of the wrist and hand: part II—overuse injuries of the wrist and traumatic injuries to the hand. Amj Sports Med 2004;32(1):262–73.
8. Leclère FM, Mathys L, Juon B, et al. The role of dynamic ultrasound in the immediate conservative treatment of volar plate injuries of the PIP Joint: A Series of 78 Patients. Plast Surg 2017;25(3):151–6.
9. Chun K, Cho K. Postoperative ultrasonograhy of the musculoskeletal system. Ultrasonography 2015;34:195–205.
10. Vele P, Simon S-P, Damian L, et al. Clinical and ultrasound findings in patients with calcium pyrophosphate dihydrate deposition disease. Med Ultrason 2018;20(2):159–63.
11. McMurtry J, Isaacs J. Extensor tendons injuries. Clin Sports Med 2015;34(1):167–80.
12. Chinchalkar SJ, Barker CA, Owsley B. Relationship between Juncturae tendinum and sagittal bands. J Hand Microsurg 2015;7(1):96–101.
13. Draghi F, Gitto S, Bianchi S. Injuries to the Collateral Ligaments of the Metacarpo-phalangeal and Interphalangeal Joints. J Ultrasound Med 2018;37:2117–33.
14. Padrez K, Bress J, Johnson B, et al. Bedside ultrasound identification of infectious flexor tenosynovitis in the emergency department. West J Emerg Med 2015;16(2):260–2.
15. Gitto S, Draghi AG, Draghi F. Sonography of Nonneoplastic Disorders of the Hand and Wrist tendons. J Ultrasound Med 2018;37:51–68.
16. Bianchi S, Della Santa D, Glauser T, et al. Sonography of masses of the wrist and hand. AJR Am J Roentgenol 2008;191:1767–75.
17. Stacy GS, Bonham J, Chang A, et al. Soft-Tissue Tumors of the Hand – Imaging Features. Can Assoc Radiol J 2020;71(2):161–73.