Trauma Case Reports 37 (2022) 100573

Contents lists available at ScienceDirect

Trauma Case Reports

journal homepage: www.elsevier.com/locate/tcr

Case Report

Intraoperative color-coded duplex ultrasound for safe surgical reduction of displaced hangman fractures in patients with atypical course of the vertebral artery: A case report of two patients

Katharina A.C. Oswald [a,*], Moritz C. Deml [a], Mirjam R. Heldner [b], David Seiffge [b], Sebastian F. Bigdon [a], Christoph E. Albers [a]

[a] Department of Orthopaedic Surgery & Traumatology, Inselspital, Bern University Hospital, University of Bern, Bern, Switzerland
[b] Department of Neurology, Inselspital, Bern University Hospital, University of Bern, Bern, Switzerland

ARTICLE INFO

Keywords:
Spine
Spine surgery
Cervical spine
Atypical course vertebral artery
Hangman fracture
Duplex ultrasound

ABSTRACT

An atypical course of the vertebral artery can be medically relevant in displaced Hangman fractures, especially if the artery course runs within the fracture gap of the C2 isthmus. During surgical reduction, the artery can be occluded inside the fracture, potentially leading to ischemic conditions of the brain. The aim of this study was to report two cases according to the CARE (case reporting) guidelines, in which intraoperative color-coded duplex-ultrasound was performed to secure safe surgical reduction of hangman fractures in two patients with an atypical course of the vertebral artery. Two patients with displaced hangman fractures (Effendi-Levine type II) were diagnosed with an atypical course of the vertebral artery running inside the fracture gap. This endangered safe surgical management with the risk of iatrogenic occlusion or injury during reduction through entrapment of the vessel inside the fracture gap. Therefore, an intraoperative color-coded duplex-ultrasound of the vertebral artery was conducted before and after reduction of the fracture, as well as at the end of the surgery. The surgical treatment in both cases included posterior unilateral spondylodesis, followed by anterior cervical discectomy and fusion (ACDF). In both patients, a safe reduction of the fracture was performed. Neither occlusion nor dissection of the vertebral artery occurred. The duplex ultrasound before and after reduction, and at the end of the procedure showed normal blood flow and morphology of both vertebral arteries. At follow-up examinations, the patients showed a favorable clinical outcome, radiographic signs of fusion, and no irregularity of the vertebral arteries. This case report serves as proof-of-concept, demonstrating the feasibility of this regimen to minimize the risk of entrapment or occlusion of the vertebral artery in the surgical management of displaced Hangman fractures with atypical course of the vertebral artery running inside the fracture gap.

Introduction

An atypical course of the vertebral artery, occurring in 2.3 up to 25.3% [1,2], can be medically relevant in displaced Hangman fractures, especially if the artery course runs within the fracture gap of the isthmus of the second cervical vertebra (C2) [3]. During

* Corresponding author at: Department of Orthopaedic Surgery & Traumatology, Inselspital, Bern University Hospital, University of Bern, Freiburgstrasse, 3010 Bern, Switzerland.
E-mail address: katharina.oswald@insel.ch (K.A.C. Oswald).

https://doi.org/10.1016/j.tcr.2021.100573
Accepted 5 December 2021
Available online 9 December 2021
2352-6440/© 2021 The Authors. Published by Elsevier Ltd. This is an open access article under the CC BY-NC-ND license (http://creativecommons.org/licenses/by-nc-nd/4.0/).

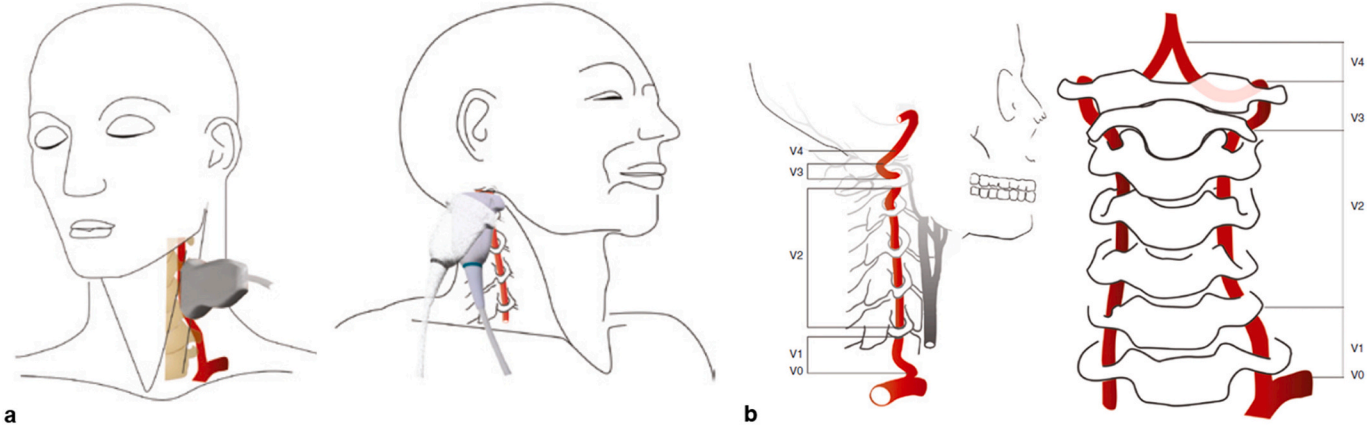

Fig. 1. (a) Showing the linear array transducer positioned for cervical examination of the vertebral artery (V2 segment on the left side and V3 segment on the right side) and (b) the anatomical view of the course of the vertebral arteries.
(Copyright Manual of Neurosonology. Cambridge Medicine. Apr 2016. ISBN 9781107659155).

surgical reduction of the fracture, it can cause early to late complications such as entrapment, dissection, rupture and occlusion of the artery, potentially leading to transient ischemic attacks or ischemic strokes [3,4]. Color-coded duplex ultrasound of the vertebral artery is a safe and noninvasive technique to investigate anatomical variations of vessel diameter, course, hemodynamics and morphology and is commonly used as a neurovascular diagnostic method [5]. Thus, an intraoperative color-coded duplex ultrasound before and after reduction and directly postoperatively can contribute to a safe surgical management. We report two cases in which intraoperative vascular ultrasound was successfully used to provide safe reduction of displaced hangman fractures with the vertebral artery running close to the fracture line. These cases highlight the benefit that this regimen may have on the surgical management of hangman fractures in patients with an atypical course of the vertebral artery.

Case report

Vascular ultrasound of the vertebral arteries

Color-coded duplex ultrasound was performed with a standard ultrasound unit (Toshiba Aplio 500, Toshiba Medical Systems, Neuss, Germany). A linear array transducer (9 MHz) was placed in the cervical region in vertical and paramedian position for examination of the vertebral arteries in the V0 to V2 segments. The probe was moved cranially along the course of the arteries up to the angle of the jaw, where it was rotated to a transverse position to insonate the vertical as well as the horizontal part of the V3 segments (Fig. 1). The arteries were examined in B-mode and by color and pulsed Doppler signal. Peak systolic and diastolic velocities were measured and vessel wall morphology was assessed. The sonographers were certified by the Swiss Society of Neurophysiology.

Case 1

A 64-year-old woman with a history of multiple venous thrombosis and embolism tripped and fell on the backside of her head under anticoagulation with a selective factor Xa-Inhibitor. The patient presented with neck pain and without any neurological deficits. The whole body trauma Computed-Tomography-Scan (CT-Scan) in the emergency room revealed a hangman's fracture Effendi-Levine Type II [6,7], as well as a high riding right vertebral artery, with the course of the fracture line through the right vertebral foramen (Fig. 2). A two-step surgical approach was chosen. Firstly, a reduction and unilateral posterior fixation of the cervical segments 2 and 3 was performed. Preoperatively, a color-coded duplex ultrasound, performed by neurosonographers, showed regular flow and morphology – as far as technically assessable due to limitations such as the rather deep location and the acoustic shadow of the transverse processes of cervical vertebrae – of both vertebral arteries in the V2 and V3 segments, the segments proximal and distal of the injury. After the reduction of the fracture and prior to internal fixation, another color-coded duplex ultrasound was conducted revealing regular unchanged blood flow and morphology of both vertebral arteries. Lastly, after completion of the surgery, another final ultrasound was performed, again showing normal blood flow and morphology of the vertebral arteries. In the second step, the surgical therapy was completed by anterior cervical discectomy and fusion (ACDF) of the cervical segments 2 and 3 using an intersomatic spacer and a cervical locking plate. The postoperative course was unremarkable, without any transient ischemic attack or ischemic stroke and without any peripheral neurological deficits. The patient was dismissed on postoperative day 6 with a semi-rigid cervical collar. At 6-weeks and 6-months follow-up visits, the patient presented with a favorable clinical outcome, without any neurological symptoms in the meantime and with favorable radiographic signs of fusion and no irregularity of the vertebral arteries.

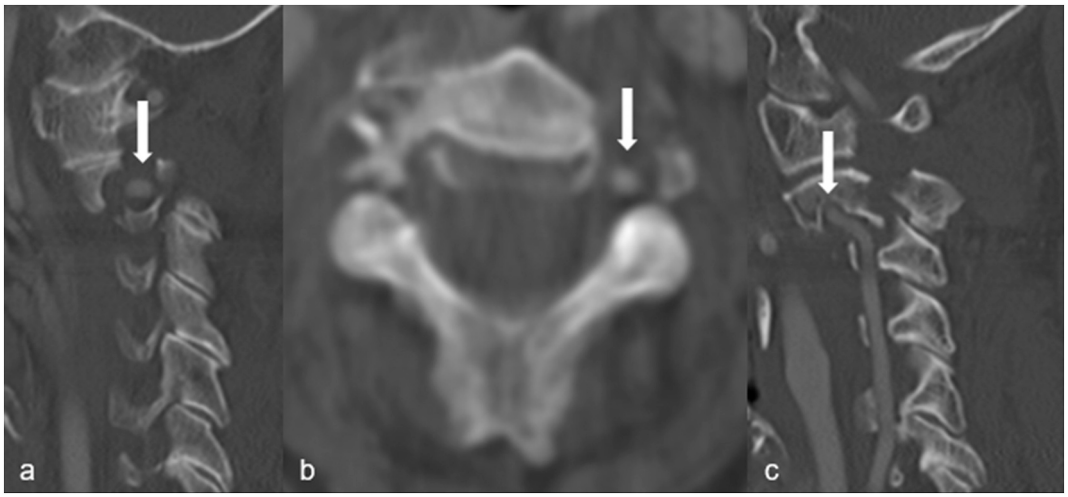

Fig. 2. CT-angiography of Case 1 in (a) sagittal and (b) axial view, with the arrow pointing at the vertebral artery running inside the fracture gap and (c) sagittal view of the high riding right vertebral artery, indicated by the arrow.

Case 2

Due to a car accident, a 42-year-old woman suffered from multiple injuries, including a displaced hangman's fracture Effendi-Levine Type II [6–8] (Fig. 3a, b) with the fracture line close to the vertebral artery. In the resuscitation room, the patient presented with neck pain and without any neurological deficits. CT-Angiography showed an intact left vertebral artery and a hypoplastic right vertebral artery as an anatomical variant (Fig. 3c, d). Because of this vascular asymmetry, a conservative regimen was followed initially using a Halo-fixateur. Two weeks later the patient was readmitted to the hospital with psychological decompensation, intolerance and self-removal of the Halo-fixateur. Due to the instability of the fracture, a two-step surgical approach was chosen. The preoperative color-coded duplex ultrasound of the vertebral arteries showed normal blood flow bilaterally (in relation to the vessel lumens) in the segments proximal and distal of the fracture. For surgery, fracture reduction and an ACDF with discectomy and replacement was performed firstly. The color-coded duplex ultrasound before reduction and after wound closure showed normal blood flow and morphology of the vertebral arteries. The surgery was completed by a posterior spondylodesis of the segments C2 and C3 afterwards. Postoperatively, the clinical course was unremarkable, without any transient ischemic attack, ischemic stroke or peripheral neurological deficits. The patient was dismissed prematurely upon her own wish. At 6-weeks, 12-weeks and 6-months follow-up visits, the patient presented with a favorable clinical outcome without any neurological symptoms in the meantime, with favorable radiographic signs of fusion and no irregularity of the vertebral arteries.

Discussion

This is the first report documenting the successful use of intraoperative color-coded duplex ultrasound of the vertebral arteries contributing to a safe reduction of displaced hangman fractures in patients with an atypical course of the vertebral arteries. A safe reduction of the fracture was performed in both patients. No entrapment, occlusion nor dissection of the vertebral arteries occurred. The pre- and post-reduction, as well as the post-operative color-coded duplex ultrasound showed a normal blood flow and intact morphology of both vertebral arteries. Neurovascular ultrasound is a standard diagnostic imaging method to investigate anatomical variations of diameter and vessel course and hemodynamics with high accuracy. Also morphology can be assessed, limited however by the rather deep location of the vertebral arteries and the acoustic shadow of the transverse processes of cervical vertebrae. Overall, neurovascular ultrasound can be implemented for detection of entrapment, disruption or dissection of the vertebral arteries [9–11]. Takahashi et al. described the use of intraoperative angiography for the same purpose [12]. In comparison to angiography, color-coded duplex ultrasound is a non-invasive diagnostic tool, which does not necessarily require application of contrast agents. This can be medically relevant especially if patients suffer from reduced kidney function or have allergies to the contrast agents needed for angiography. Additional advantages of this method lay in the high availability and low costs. Extensions of this technique may include monitoring after C2 screw placement for indications other than Hangman fractures. Fig. 4 shows an intraoperative algorithm for the use of color-coded duplex ultrasound, providing a step-by-step-guidance. Limitations of this diagnostic method are an experienced examiner; a board certified vascular sonographer is strongly recommended [10]. However, it shows a sensitivity of up to 86% [11,13]. An ultrasound device with a standard linear array transducer, capable of color-coded duplex ultrasound, is required. Tubbs et al. described common variations of the vertebral artery relevant for C2 instrumentation [14]. Additionally, we did not observe any post-reduction nor postoperative impairment of the vertebral arteries. This raises the question, how good this method is if the arteries are altered from reduction. In summary, using intraoperative color-coded duplex sonography of the vertebral arteries may significantly reduce the risk of entrapment, dissection or occlusion of the vertebral artery. Therefore, it may reduce the risk of transient ischemic attack, ischemic stroke or peripheral neurological symptoms in surgical management of displaced hangman fractures with an atypical course of the vertebral artery or with a fracture line close to the course of the vertebral arteries. Future studies with larger patient numbers are warranted to proof its validity in case of iatrogenic injury of the vertebral arteries.

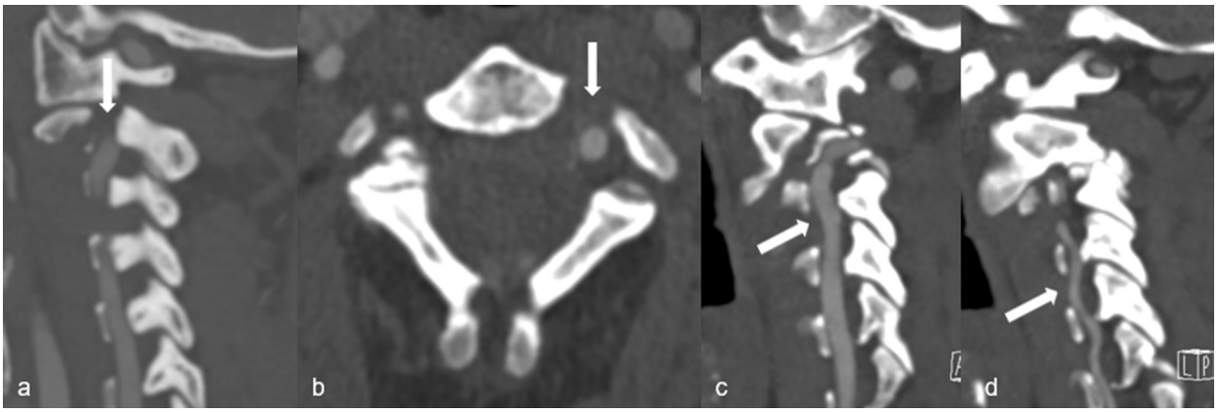

Fig. 3. CT-angiography of Case 2 in (a) sagittal and (b) axial view, with the arrow pointing at the vertebral artery running inside the fracture gap and (c) sagittal view, showing the left vertebral artery and (d) showing the hypoplastic right vertebral artery, both indicated with arrows.

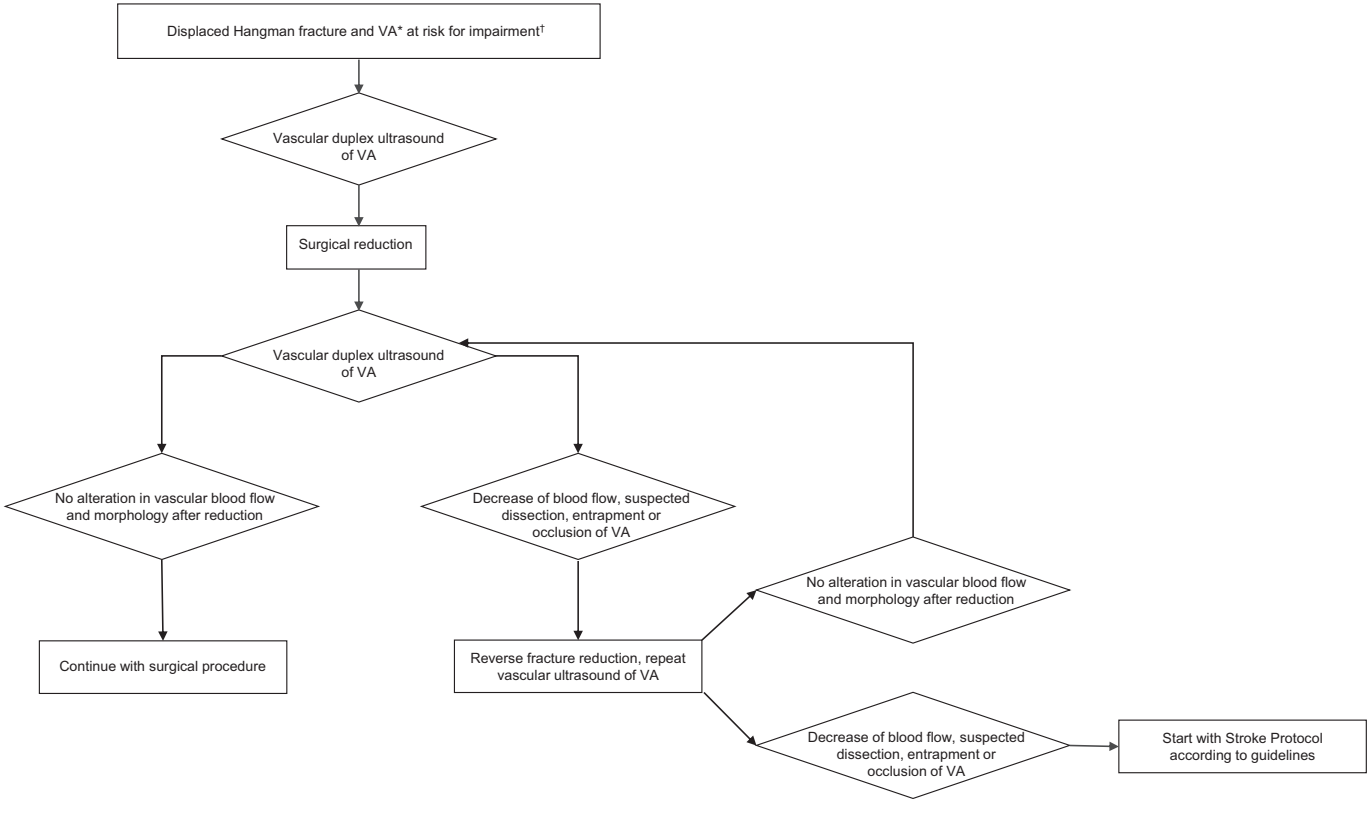

Fig. 4. Flow chart showing the intraoperative algorithm using color-coded duplex ultrasound. *VA = vertebral artery; †atypical/normvariant artery course (i.e. high-riding vertebral artery, hypoplastic vertebral artery); †fracture line through vertebral foramen.

Presentations of work at meetings

The case report has been presented in form of a presentation at the Swiss orthopedics (SGOT) annual meeting in June 2021. Additionally, two e-poster presentations were held: One at the German Congress of Orthopedics and Traumatology (DKOU) in October 2021 and one at the German Spine Medicine Congress (DWG) in December 2021.

Availability of data and material

All data generated or analyzed during this study are included in this published article.

Authors' contributions

All authors contributed to the study conception and design. Material preparation, data collection and analysis were performed by Katharina A. C. Oswald, Christoph E. Albers and Mirjam R. Heldner. The first draft of the manuscript was written by Katharina A. C. Oswald and all authors revised the first draft and the following versions of the manuscript critically. All authors read and approved the final manuscript.

Ethics approval, consent to participate and for publication

Both Patients included in this case report have given written informed consent for Spine Tango, which has been approved by the local ethics committee (KEK-2016-01078). Patients signed the informed consent regarding participation in the study and publishing their data and photographs.

Declaration of competing interest

The authors indicate no potential conflict of interest. The authors have no relevant financial or non-financial interests to disclose.

Acknowledgements

We thank Prof. Dr. Lorin M. Benneker and Dr. Alexander Maurer for their contribution to the patients care, surgery and examinations.

References

[1] T. Klepinowski, B. Pala, J. Cembik, L. Sagan, Prevalence of high-riding vertebral artery: a meta-analysis of the anatomical variant affecting choice of craniocervical fusion method and its outcome, World Neurosurg. 143 (2020) e474–e481.
[2] M. Yamazaki, A. Okawa, T. Furuya, T. Sakuma, H. Takahashi, K. Kato, et al., Anomalous vertebral arteries in the extra- and intraosseous regions of the craniovertebral junction visualized by 3-dimensional computed tomographic angiography: analysis of 100 consecutive surgical cases and review of the literature, Spine 37 (2012) E1389–E1397.
[3] R. Henkelmann, C. Josten, S. Glasmacher, C.E. Heyde, U.J.A. Spiegl, Vertebral artery caught in the fracture gap after traumatic C2/3 spondylolisthesis, Case Rep. Orthop. 2017 (2017) 9179647.
[4] A. AlBayar, P.Z. Sullivan, R. Blue, J. Leonard, D.K. Kung, A.K. Ozturk, et al., Risk of vertebral artery injury and stroke following blunt and penetrating cervical spine trauma: a retrospective review of 729 patients, World Neurosurg. 130 (2019) e672–e679.
[5] M WBG, Doppler- and Duplexsonography of the Brain Supplying Arteries, 6 ed., Springer, Berlin, 2006.
[6] D. Dreizin, M. Letzing, C.W. Sliker, F.H. Chokshi, U. Bodanapally, S.E. Mirvis, et al., Multidetector CT of blunt cervical spine trauma in adults, in: Radiographics : a review publication of the Radiological Society of North America, Inc 34, 2014, pp. 1842–1865.
[7] M.D. Ryan, J.J. Henderson, The epidemiology of fractures and fracture-dislocations of the cervical spine, Injury 23 (1992) 38–40.
[8] K. Horst, F. Hildebrand, P. Kobbe, R. Pfeifer, P. Lichte, H. Andruszkow, et al., Detecting severe injuries of the upper body in multiple trauma patients, J. Surg. Res. 199 (2015) 629–634.
[9] P.J. Bendick, V.P. Jackson, Evaluation of the vertebral arteries with duplex sonography, J. Vasc. Surg. 3 (1986) 523–530.
[10] S. Khan, G.C. Cloud, S. Kerry, H.S. Markus, Imaging of vertebral artery stenosis: a systematic review, J. Neurol. Neurosurg. Psychiatry 78 (2007) 1218–1225.
[11] J. Nebelsieck, C. Sengelhoff, I. Nassenstein, D. Maintz, G. Kuhlenbaumer, D.G. Nabavi, et al., Sensitivity of neurovascular ultrasound for the detection of spontaneous cervical artery dissection, J. Clin. Neurosci. 16 (2009) 79–82.
[12] T. Takahashi, T. Tominaga, M. Ezura, K. Sato, T. Yoshimoto, Intraoperative angiography to prevent vertebral artery injury during reduction of a dislocated hangman fracture. Case report, J. Neurosurg. 97 (2002) 355–358.
[13] M. Sturzenegger, H.P. Mattle, A. Rivoir, F. Rihs, C. Schmid, Ultrasound findings in spontaneous extracranial vertebral artery dissection, Stroke 24 (1993) 1910–1921.
[14] R.S. Tubbs, A. Granger, C. Fisahn, M. Loukas, M. Moisi, J. Iwanaga, et al., The vertebral artery cave at C2: anatomic study with application to C2 pedicle screw placement, World Neurosurg. 94 (2016) 368–374.