

Prolapse and sexual function 8 years after neovagina according to Shears: a study of 43 cases with Mayer–von Rokitansky–Küster–Hauser syndrome

Annette Kuhn · Corinne Neukomm ·
Ekkehard F. Dreher · Jeannine Imobersteg ·
Michael D. Mueller

Received: 13 June 2012 / Accepted: 14 October 2012 / Published online: 16 November 2012
© The International Urogynecological Association 2012

Abstract

Introduction and hypothesis To investigate sexual and anatomical outcome after Shears neovagina in patients with Mayer–von Rokitansky–Küster–Hauser syndrome (MRKH).

Methods Forty-three consecutive patients with MRKH syndrome underwent surgery creating a neovagina according to Shears. Follow-up was 8 years. Sexual function was assessed using the Female Sexual Function Index (FSFI) as patient reported outcome; anatomical results were assessed measuring anterior, posterior and apical prolapse using the ICS Pelvic Organ Prolapse Score (ICS-POP Score). Pelvic floor contraction was measured applying the Oxford grading system.

Results Thirty-seven of the patients were regularly sexually active and filled in the FSFI; mean total FSFI was 27.2 (range 24–28). No significant prolapse of the neovagina was noted, 11 patients had a grade I cystocele, rectocele or apical descent that was asymptomatic. Oxford grading of the pelvic floor contraction was 4 in median (range 2–5).

Conclusion The neovagina according to Shears is a valuable surgical option with good sexual and anatomical outcome 8 years after therapy.

Keywords Mayer–von Rokitansky–Küster–Hauser syndrome · Neovagina · Sexual function · Prolapse · Anatomical outcome

Introduction

Mayer–von Rokitansky–Küster–Hauser syndrome (MRKH) is a condition in which the Müllerian ducts fail to develop resulting in the absence of a normal vagina and uterus, but with normal tubes and ovaries usually located at the pelvic brim and a normal 46, XX karyotype. The external genitalia show a very shallow vaginal pouch and secondary sex characteristics are normal [1, 2]. Additional anomalies of the urinary tract and skeleton are often associated [3].

The absence of the vagina results in primary amenorrhoea, which is usually the reason why patients seek medical help. MRKH is the second most common reason for primary amenorrhoea [4]. The combination of gynaecological examination and MRI or other imaging techniques usually leads to the correct diagnosis [4].

A variety of operations for the creation of a neovagina have been suggested; however, there is to date no consensus which procedure should be considered the gold standard [1]. Open transabdominal surgery, laparoscopic access or vaginal dilation of the Müllerian ducts are suggested [1], the latter creating a neovagina according to Shears [5]. The major differences among the various methods for creating a neovagina are access, mode of dilatation, and type of tissue used to cover the neovaginal cavity. For the creation of a neovagina according to Shears, the surgical trauma is limited to the area of the neovagina in comparison to intestinal vaginoplasty and the Davydov procedure. As a consequence, postoperative discomfort and pain can be kept to a

A. Kuhn · C. Neukomm · E. F. Dreher · J. Imobersteg ·
M. D. Mueller
Department of Gynaecology, Frauenklinik,
University Hospital and University of Bern,
Bern, Switzerland

A. Kuhn (✉)
Frauenklinik, University Hospital,
Effingerstrasse 102,
3010 Bern, Switzerland
e-mail: annette.kuhn@insel.ch

minimum. Additionally, an advantage of this surgical technique is that the functional axis of the neovagina is identical to the anatomical axis of a natural vagina, allowing for satisfactory intercourse [6].

The Female Sexual Function Index (FSFI) is a brief, self-reported measure of female function, which evaluates six different domains of sexual function: desire, subjective arousal, lubrication, orgasm, satisfaction, and pain. It was first described by Rosen et al. in 2000 [7] and is widely used for the assessment of sexual function. The FSFI has been validated in many languages, including the Swiss national languages German, French, and Italian, which makes it an ideal tool to assess sexual function in our setting.

The International Continence Society Pelvic Organ Prolapse Score (ICS POP score) is a validated tool for assessing vaginal length, perineal body and the stage of any prolapse from the anterior and/or the posterior wall as well as the apex [8]. To date, no studies have been published describing the incidence of prolapse and sexual function after neovaginae that were created according to the Shears method [5]. The normal vagina is a complex structure made of connective and epithelial tissue, which in the upper two thirds derives from the Müllerian ducts and which depends on the paracolpos and pelvic walls through the connective fibres lining the vaginal wall. Neovaginae do not have these physiological support structures, and therefore prolapse may be a problem.

The aim of this study was to determine sexual function and anatomical outcome as described by the ICS POP score after the creation of a neovagina according to Shears in a young population with MRKH syndrome.

Patients and methods

Ethical consent for this study was obtained (KEK Bern, Switzerland).

Between December 1998 and December 2011, 43 consecutive patients with MRKH syndrome underwent the surgical formation of a neovagina as described by Shears performed by two surgeons (MDM; ED) and their team. The study took place in the Department of Gynaecology, Frauenklinik, University Hospital of Bern, Switzerland, a tertiary referral centre. All patients were gynaecologically examined preoperatively and received a thorough preoperative work-up including imaging of the pelvis and the upper urinary tract.

The surgical procedure was performed under general anaesthesia; peridural anaesthesia was inserted preoperatively to ensure postoperative pain management and a broad spectrum antibiotic was applied (amoxicillin/clavulanic acid 2 g).

The rudimentary Müllerian ducts were identified using colposcopy as two dimples below the external urethral meatus and small 1 French Hegar dilators were inserted dilating

the ducts by carefully pushing and rotating the dilators that were increased up to a size 15 each. The median bridge was intersected using diathermy and a soft two-channel water-filled vaginal prosthesis was inserted after careful haemostasis. The vaginal prosthesis remained inside the neovagina for 5 days and was then removed for the first time; the patient was instructed to repeat this and reinsert the prosthesis after washing with tap water (Figs. 1, 2, 3, 4).

Immediate postoperative follow-up was performed after 2, 5 and 6 weeks. If wound healing was established the soft prosthesis was exchanged to a rigid prosthesis and the patient was advised to wear the prosthesis if she was not having intercourse on a regular basis. Patients were followed up 6 weeks after the operation and afterwards on a yearly basis, the FSFI questionnaire in the patients' native language was distributed before the consultation in 2011 and the ICS POP score was also performed during the follow-up visit in 2011.

Prolapse staging was performed using the ICS POP-Q in the lithotomy position, semi-recumbent. Additionally, pelvic floor contraction was digitally assessed using the Oxford grading system [8] with 0 points corresponding to no levator contraction and 5 points being the maximum possible voluntary levator contraction [9].

For statistical analysis, Graph Pad Prism version 5.0 for Windows was used (Graph Pad, La Jolla, CA, USA).

Results

Forty-three patients with the diagnosis of MRKH were operated on and received a neovagina according to Shears. In the majority diagnosis ($n=41$) the leading symptom was amenorrhoea. Two patients had tried to have intercourse, which was not possible and that had led to a medical consultation.

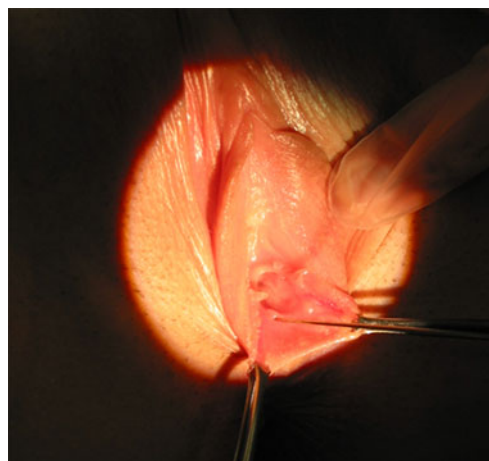


Fig. 1 Identifying the Müllerian ducts

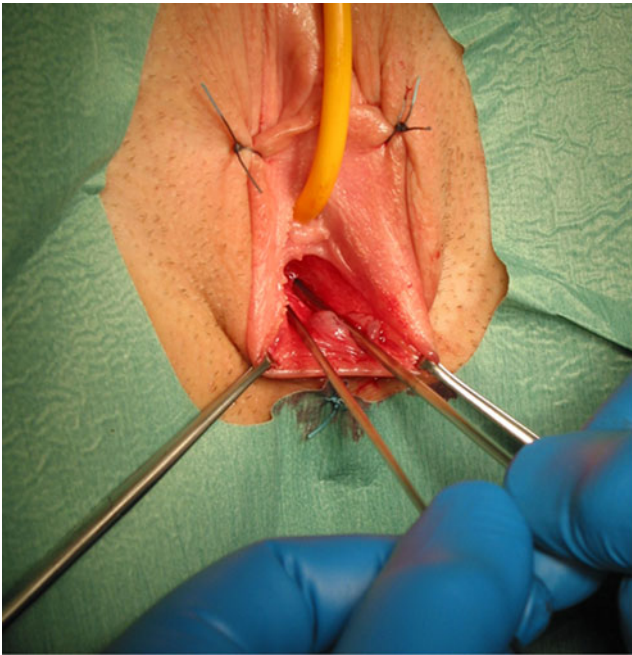

Fig. 2 Dialatation of the Muellerian ducts

Median operating time was 95 min (range 55–140 min) and median blood loss 80 ml (range 20–1,200 ml). In all cases, it was possible to identify the Müllerian ducts. None of the patients declined gynaecological examination, and a full set of ICS POP score measurements could be obtained in 36 patients.

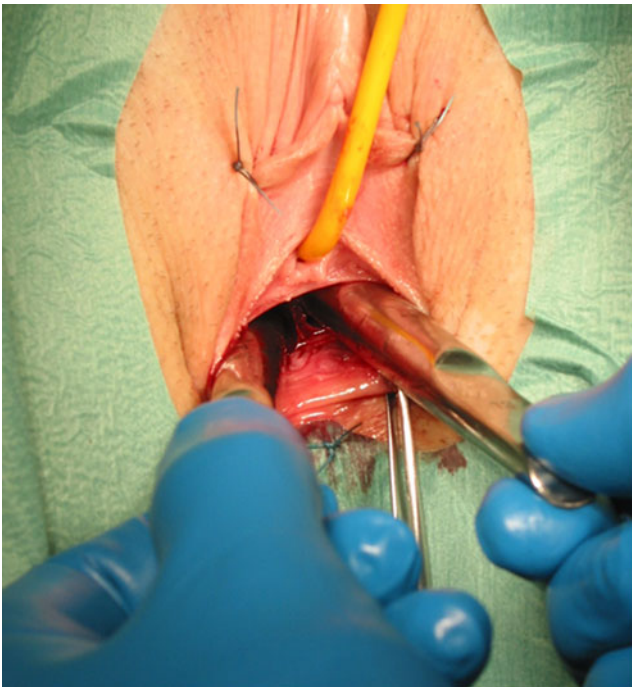


Fig. 3 Removing the midline septum

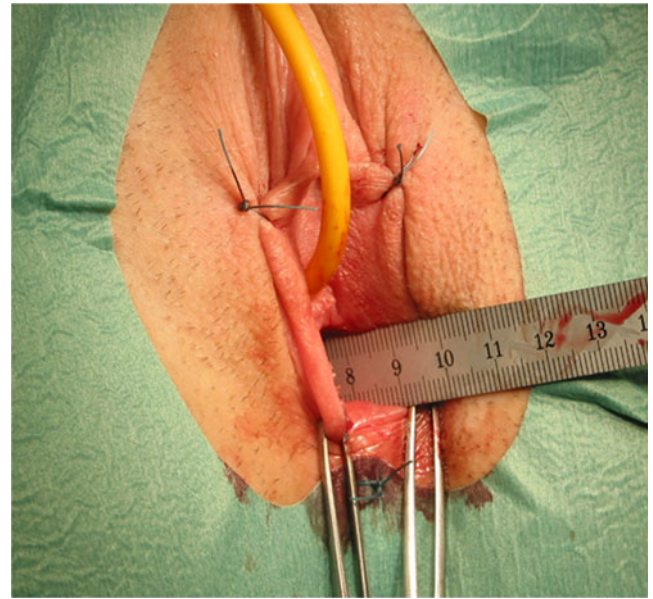


Fig. 4 Final vaginal length

Three patients had to be reoperated on owing to stenosis of the introitus that had to be surgically revised under general anaesthesia. Complete epithelialisation of the neovagina occurred after a median of 18 weeks (range 9–23 weeks). In 1 patient, the use of the vaginal prosthesis remained unclear and she was seen 14 months after her surgery as she was unable to reinsert the prosthesis. The neovagina was obliterated and she received a rectosigmoid vaginoplasty. Creation of a perineal cavity for vaginal replacement was performed using a simultaneous approach through the abdomen and the perineum.

Table 1 summarises the demographic data, POPQ and sexual function, as determined by the FSFI questionnaire.

One patient showed a small stage II rectocele that was asymptomatic. Oxford grading of the pelvic floor contraction was 4 in median (range 2–5). Thirty-seven of the patients were sexually active and filled in the FSFI; 6 were inactive and declined to fill in the questionnaire. The three patients with stenosis of the introitus complained of pain, but this was resolved after surgical correction. There were no patients with persistent dyspareunia, but the patient with rectosigmoid vaginoplasty complained of excessive mucous secretion.

Discussion

In patients with MRKH, prolapse of the neovagina that was created either surgically or non-surgically has been reported in the literature, although the incidence is not known. The majority of cases were previously treated with bowel vaginoplasty [10].

Table 1 Demographic data, prolapse and sexual function. Demographic data and POPQ data are given as median and range, FSFI results as mean±SD

| Parameter | Data |
|-----------------------------|---------------------|
| Demographic data | |
| Age at operation (years) | 17 (14–22) |
| Age at follow-up (years) | 25 (18–29) |
| BMI | 21 (19–29) |
| Follow-up interval (months) | 97 (8–123) |
| POPQ | |
| Stage 0 (<i>n</i>) | 31 |
| Stage 1 (<i>n</i>) | 11 |
| Stage 2 (<i>n</i>) | 1 |
| Aa | −2.5 (−1 to −3) |
| Ba | −2 (0 to −3) |
| C | na |
| GH | 4 (2.5 to 6) |
| PB | 3.1 (0.9 to 4.5) |
| Tvl | 9 (6 to 12) |
| Ap | −2 (−0.5 to −3) |
| Bp | −2 (−1.5 to 3) |
| D | −5 (−3 to −9) |
| FSFI scores (mean ± SD) | |
| Total | 27.2 (24 to 28) |
| Desire | 5.083 (4.8 to 5.3) |
| Arousal | 4.472 (4.03 to 4.9) |
| Lubrication | 4.67 (4.36 to 4.97) |
| Orgasm | 3.47 (3.05 to 3.9) |
| Satisfaction | 2.23 (1.9 to 2.65) |
| Pain | 5.56 (5.37 to 5.54) |

Edmonds [11] describes in a review 11 papers in which the outcome of 179 patients with bowel neovagina was described. Of those, 9 patients had a subsequent neovaginal prolapse. Case reports of neovaginal prolapse following surgical or non-surgical interventions for the creation of a neovagina have been reported in the literature, e.g. after mechanical dilatation, 1 case after the McIndoe procedure and another after William's vaginoplasty [12]. It is unclear why intestinal neovaginae tend to prolapse as the intestinal segments maintain their original vascular support and connective tissue [10]. Prolapse is probably caused by loosening of the paravaginal supporting tissue, which is not the same as in natural vaginae.

Of interest, no cases of neovaginal prolapse after laparoscopic or open Vecchietti procedures have been reported.

In the current study, symptomatic prolapse was not yet detected 8 years after neovagina creation. It will be of interest what happens to the pelvic floor and its organs including the vagina and sexual health when the patients described in this study are ageing as the Shears neovagina

creates an epithelial pouch that consists of only a thin sub-mucous layer and does not have solid structures of connective fibres linking the endopelvic fascia.

The current study shows long-term data regarding sexual function in a large group of female patients who received a neovagina according to Shears owing to vaginal absence in MRKH syndrome. Eighty-six percent of patients were sexually active, and in these patients pain was not a major issue, lubrication was considered adequate by the patients despite not having an additional lining of the vagina, as suggested by other authors who used amnion vaginoplasty [1].

The total vaginal length and the perineal body was appropriate at 9 cm and 3.1 cm respectively. A large epidemiological study of gynaecological patients with a natural vagina reported a mean total vaginal length of 9.6 cm and a mean genital hiatus of 2.9 cm [13]. However, anatomy and function of the vagina are not synonymous and the relationship of these measurements to sexual function is unknown.

The question of vaginal capacity and length is relevant to pelvic reconstructive surgeons; the challenge of reconstructive surgery in prolapse patients is to restore function through the correction of anatomical defects. Creating a new vagina per se is a great challenge [14, 15].

Various reports about the creation of neovaginae using different approaches are described. D'Alborton and Santi [16] emphasises the functional approach of creating a neovagina by the repetitive efforts of sexual intercourse, which can succeed in creating a neovagina. In our group, 2 patients had repetitively tried to have intercourse, but these trials were not successful.

Trials with a partner or self-dilatation may be dangerous. Even urethral penetration may occur, with its serious consequences such as urethral injury, infections and incontinence [17]. We may assume that only a few specialists support this approach to the treatment of MRK syndrome, as other, most likely more effective surgical treatments are available.

The Williams vaginoplasty [18], the McIndoe operation [19], the Davydov procedure [20] and the Vecchietti method [21] are frequently used. Some data regarding sexual function are available: a recent study analysing 25 sexually active patients after the modified Vecchietti procedure [22] found similar results concerning sexual function using the same FSFI questionnaire as the current study, but our data are slightly in favour of the Shears vagina with less pain. This may be explained by the differing techniques with the modified Vecchietti placing two tension threads through the anatomically vaginal place coming from the perineum. With the perineum being a sensitive place for dyspareunia [23] this may explain the difference. After modified Vecchietti, Czsermely et al. [22] found higher scores for orgasm, with 4.6 compared with 3.5 in our study. At a maximum of 26 years, patients were older in the Vecchietti study [23] than in the current study.

Allen et al. [24] investigated psychosexual outcomes in patients after the laparoscopic Davydov procedure with lower FSFI scores for desire, orgasm and pain resulting in poorer sexual function; however, this study [24] included only 6 patients.

One strength of the current study is that we used validated tools such as the FSFI and the ICS POP score to evaluate sexual function, vaginal length and prolapse. Another strength is that this study involves a large group of patients; the population of patients with a neovagina is rather stable and we have long-term follow-up data available. This will probably help to obtain data in an ageing group of patients with MRKH syndrome and a neovagina.

A weakness of the study is that we have not enquired about sexual orientation in this group of young patients; however, we do not consider this a major draw-back, but rather an aspect of missing data that will be collected in the future. Another weakness is that we cannot compare sexual function before and after the surgical intervention as we are used to doing. This is because of the background of the MRKH syndrome that does not allow patients to have penetrative vaginal intercourse before the creation of the neovagina. Two patients had tried to have intercourse, and failure had led to diagnosis; however, assessment of sexual function is not possible in this situation.

It is difficult to say which procedure is best for the patient; in the 21st century, minimally invasive procedures with determined organ outcome must be favoured [25–27]. The function of the vagina is to have sexual intercourse, and studies focussing on neovaginal function must also determine sexual outcome.

With the current study including a large number of patients and long-term follow-up we may conclude that the neovagina according to Shears is a valuable option for patients with Mayer–von Rokitansky–Kuster–Hauser syndrome. Currently, prolapse is not yet an issue, but may become one in the future. The patients' compliance during the postoperative period using the vaginal prosthesis is essential and should be recommended as long as the patient is not yet having regular intercourse.

Despite this study presenting long-term results, we do not know what is going to happen to the pelvic floor and the incidence of prolapse when these patients grow older [28], and longitudinal studies are currently being undertaken to evaluate pelvic floor and sexual function, prolapse and incontinence in patients with neovagina according to Shears

Conflicts of interest None.

Source of financial support This study was not financially supported, but is investigator-driven.

References

1. Fotopoulou C, Sehouli J, Gehrmann N, Schoenborn I, Lichtenegger W (2010) Functional and anatomic results of amnion vaginoplasty in young women with Mayer-Rokitansky-Küster-Hauser syndrome. *Fertil Steril* 94:317–323
2. Griffin J, Edwards C, Madden J, Harrod M, Wilson J (1976) Congenital absence of the vagina, Mayer-Rokitansky-Küster-Hauser syndrome. *Ann Intern Med* 85:224–226
3. Ulrich U, Schrickel J, Dorn C, Richter O, Lewalter T, Lüderitz B, Rhiem K (2004) Mayer-von-Rokitansky-Küster Hauser syndrome in association of hitherto undescribed variant of the Holt-Oram syndrome with an aorto-pulmonary window. *Hum Reprod* 19:1201–1203
4. Giusti S, Fruzzetti E, Perini D, Fruzzetti F, Giusti P, Bartolozzi C (2011) Diagnosis of a variant of Myer-Rokitansky-Kuster Hauser syndrome: useful MRI findings. *Abdom Imaging* 36:753–755
5. Shears BH (1960) Congenital atresia of the vagina: a technique for tunnelling in the space between bladder and rectum and construction of a new vagina by a modified Wharton technique. *J Obstet Gynaecol Br Emp* 67:24–31
6. Walch K, Kowarik E, Leithner K, Schätz T, Dörfler D, Wenzl R (2011) Functional and anatomical results after creation of a neovagina according to Wharton-Shears George in patients with Mayer-Rokitansky-Küster-Hauser syndrome—long-term follow-up. *Fertil Steril* 96(2):492–497
7. Rosen R, Brown C, Heiman J, Leiblum S, Meston C, Shabsigh R, Ferguson D, D'Agostino R Jr (2000) The Female Sexual Function Index [FSFI]: a multidimensional self-report instrument for the assessment of female sexual function. *J Sex Marital Ther* 26(2):191–208
8. Bump RC, Mattiasson A, Bo K, Brubaker LP, DeLancey JOL, Klarskov P, Shull BL, Smith ARB (2002) Standardisation of terminology Female Pelvic Organ Prolapse and Pelvic Floor Dysfunction. *Am J Obstet Gynecol* 175(1006):10–11
9. BØ K, Finckenhagen HB (2001) Vaginal palpation of pelvic floor muscle strength: inter-test reproducibility and comparison between palpation and vaginal squeeze pressure. *Acta Obstet Gynecol Scand* 80(10):883–887
10. Fedele L, Frontino G, Motta F, Peruzzi E (2011) Davydov's procedure for the treatment of neovaginal prolapse in Rokitansky syndrome. *J Minim Invasive Gynecol* 18(4):503–506
11. Edmonds DK (2003) Congenital malformations of the genital tract and their management. *Best Pract Res Clin Obstet Gynaecol* 17:19–40
12. Schaffer J, Fabricant C, Carr BR (2002) Vaginal vault prolapsed after surgical and nonsurgical treatment of müllerian agenesis. *Obstet Gynecol* 99:947–949
13. Swift S, Woodman PL, O'Boyle A, Kahn M, Valley M, Bland D (1980) Pelvic organ support study (POSS): the distribution, clinical definitions and epidemiologic conditions of pelvic organ support defects. *Am J Obstet Gynecol* 192(3):795–806
14. Hage JJ (1999) Vaginoplasty in male-to-female transsexuals by inversion of penile and scrotal skin. In: Ehrlich RM, Alter GJ (eds) *Reconstructive and plastic surgery of the external genitalia*. Saunders, Philadelphia, pp 294–300
15. Belgrano E, Lissiani A (1999) La familizzazione dei genitali esterni e la colazione della neovagina. In: Belgrano E, Fabris B and Trombetta C (eds) *Il transsessualismo*. Editrice Kurtis, Milan, pp 87–97
16. D'Alberon A, Santi F (1972) Formation of a neovagina by coitus. *Obstet Gynecol* 40:763
17. Deniz N, Perk H, Serel T (2002) Urethral coitus and urinary incontinence in a case of Mayer-Rokitansky-Kuster-Hauser syndrome: an alternative surgical procedure. *Eur J Obstet Gynecol Reprod Biol* 103:95

18. Williams EA (1964) Congenital absence of the vagina: a simple operation for relief. *J Obstet Gynaecol Br Commonw* 71:511
19. McIndoe AH, Banister JB (1938) An operation for the cure of congenital absence of the vagina. *J Obstet Gynecol Br Commonw* 45:490–494
20. Davydoff SN (1969) Colpopoiesis from the peritoneum of the uterorectal space. *Akush Gynecol [Mok]* 45:55
21. Vecchietti G (1965) Neovagina nella syndrome di Rokitanski Kuster Hauser attual. *Obstet Ginecol* 11:131
22. Czsermely T, Halvax L, Sarkany A, Jeges S, Vizer M, Bosza S, Farkas B, Bodis J (2011) Sexual function after modified laparoscopic Vecchietti's vaginoplasty. *J Pediatr Adolesc Gynecol* 24:147–152
23. Ng CC, Ham WH (2004) Comparison of effectiveness of vaginal and abdominal routes in treating severe uterovaginal or vault prolapse. *Singapore Med J* 45(10):475–481
24. Allen L, Lucco KL, Brown CM, Spritzre RF, Kives S (2010) Psychosexual and functional outcomes after creation of a neovagina with laparoscopic Davydoff in patients with vaginal agenesis. *Fertil Steril* 94:2272–2276
25. Fedele L, Bianchi S, Frontino G (2008) The laparoscopic Vecchietti's modified technique in Rokitansky syndrome: anatomic, functional and sexual long term results. *Am J Obstet Gynecol* 198:377
26. Darai E, Toullalan O, Besse O (2003) Anatomic and functional results of laparoscopic—perineal neovagina construction by sigmoid colpoplasty in women with Rokitansky's syndrome. *Hum Reprod* 18:2454
27. Ota H, Tanaka J, Murakami M (2000) Laparoscopic assisted Ruge procedure for the creation of a neovagina. *Fertil Steril* 73:641
28. Nygard I, Bradley C, Brand D (2004) Pelvic organ prolapse in older women: prevalence and risk factors. *Obstet Gynecol* 104:489–497