Journal Pre-proof



Patient-Specific Instrumentation Reduces Deviations Between Planned and Post-Osteotomy Humeral Retrotorsion and Height in Shoulder Arthroplasty

J Tomás Rojas, MD, Bernhard Jost, MD, Ralph Hertel, MD, Claudio Zipeto, M Eng, Floris Van Rooij, MSc, Matthias A. Zumstein, MD

PII: S1058-2746(22)00330-5

DOI: https://doi.org/10.1016/j.jse.2022.02.025

Reference: YMSE 5939

To appear in: *Journal of Shoulder and Elbow Surgery*

Received Date: 1 December 2021

Revised Date: 23 January 2022

Accepted Date: 8 February 2022

Please cite this article as: Rojas JT, Jost B, Hertel R, Zipeto C, Van Rooij F, Zumstein MA, Patient-Specific Instrumentation Reduces Deviations Between Planned and Post-Osteotomy Humeral Retrotorsion and Height in Shoulder Arthroplasty, *Journal of Shoulder and Elbow Surgery* (2022), doi: https://doi.org/10.1016/j.jse.2022.02.025.

This is a PDF file of an article that has undergone enhancements after acceptance, such as the addition of a cover page and metadata, and formatting for readability, but it is not yet the definitive version of record. This version will undergo additional copyediting, typesetting and review before it is published in its final form, but we are providing this version to give early visibility of the article. Please note that, during the production process, errors may be discovered which could affect the content, and all legal disclaimers that apply to the journal pertain.

© 2022 Published by Elsevier Inc. on behalf of Journal of Shoulder and Elbow Surgery Board of Trustees.

source: https://doi.org/10.48350/168411 | downloaded: 12.10.2024

Journal Pre-proof

Title: Patient-Specific Instrumentation Reduces Deviations Between Planned and Post-Osteotomy Humeral Retrotorsion and Height in Shoulder Arthroplasty

Running Title: Humeral Osteotomy Using PSI in Shoulder Arthroplasty

J Tomás Rojas, MD[1,2]; Bernhard Jost, MD[3]; Ralph Hertel, MD [4]; Claudio Zipeto, M Eng[5]; Floris Van Rooij, MSc [6] Matthias A Zumstein, MD[1,7-9]

Affiliations

1) Shoulder, Elbow and Orthopaedic Sports Medicine, Sonnenhof Orthopaedics, Bern, Switzerland

2) Department of Orthopaedics and Trauma Surgery, Hospital San José – Clínica Santa María, Santiago, Chile

3) Department of Orthopaedics and Trauma Surgery, Kantonsspital, Saint Gallen, Switzerland

4) Department of Orthopaedics and Trauma Surgery, Lindenhofspital, Bern, Switzerland

5) Medacta international, Castel San Pietro, Switzerland

6) ReSurg, Lyon, France

7) Shoulder, Elbow Unit, Sportsclinicnumber1, Papiermuehlestrasse 73, 3014 Bern, Switzerland

8) Shoulder, Elbow and Orthopaedic Sports Medicine, Department of Orthopaedic Surgery and Traumatology, Inselspital, Bern University Hospital, Bern, Switzerland

9) Campus Stiftung Lindenhof Bern, Swiss Institute for Translational and Entrepreneurial Medicine, Bern, Switzerland

Journal Pre-proof

Journal Pre-proof

Corresponding author

Matthias A. Zumstein, MD

Shoulder, Elbow and Orthopaedic Sports Medicine, Orthopädie Sonnenhof,

Salvisbergstrasse 4, 3006 Bern, Switzerland.

Email: ses@sonnenhof.ch; Phone: +41 (0) 31 358 17 81

Disclaimers:

Funding: No funding was disclosed by the authors.

Conflicts of interest: The authors, their immediate families, and any research foundation with which they are affiliated have not received any financial payments or other benefits from any commercial entity related to the subject of this article.

Acknowledgments: The authors are grateful to Andrea Rosa for his technical help during the experimental procedure of this study and to Mo Saffarini for the manuscript preparation.

Institutional review board approval was not required for this basic science study.

Journal Pre-proof

Journal Pre-proof

Title: Patient-Specific Instrumentation Reduces Deviations Between Planned and Post-Osteotomy Humeral Retrotorsion and Height in Shoulder Arthroplasty

Running Title: Humeral Osteotomy Using PSI in Shoulder Arthroplasty

Abstract

Background: Patient-specific instrumentation (PSI) may potentially improve humeral osteotomy in shoulder arthroplasty. The purpose of this study was to compare the deviation between planned and post-osteotomy humeral inclination, retrotorsion and height in shoulder arthroplasty, using PSI versus standard cutting guides (SCG).

Methods: Twenty fresh-frozen cadaveric specimens were allocated to undergo humeral osteotomy using either PSI or SCG, such that the two groups have similar age, gender and side. Pre-osteotomy computed tomography (CT) scan was performed and used for the three-dimensional (3D) planning. The osteotomy procedure was performed using a PSI designed for each specimen or a SCG depending on the group. A post-osteotomy CT scan was performed. The pre-osteotomy and post-osteotomy 3D CT scan reconstructions were superimposed to calculate the deviation between planned and post-osteotomy inclination, retrotorsion and height. Outliers were defined as cases with one or more of the following deviations: >5° inclination, >10° retrotorsion, and >3 mm height. The deviation and outliers in inclination, retrotorsion and height were compared between the two groups.

Results: The deviations between planned and post-osteotomy parameters were similar among the PSI and SCG groups for inclination ($p=0.260$), while they were significantly greater in the SCG group for retrotorsion ($p<0.001$) and height ($p=0.003$). There were 8

outliers in the SCG group, compared to only 1 outlier in the PSI group (p=0.005). Most outliers in the SCG group were due to deviation >10° in retrotorsion.

Conclusion: After 3D planning PSI compared to SCG reduces the deviation between planned and post humeral osteotomy retrotorsion and height.

Level of evidence: Basic Science Study; Computer Modeling and Surgical Planning

Keywords: Shoulder Arthroplasty, Patient-specific instrumentation, PSI, Standard cutting guide, Humeral osteotomy

Humeral osteotomy is a key intraoperative step in shoulder arthroplasty, as it has been shown to affect shoulder function and long-term survival of total shoulder arthroplasty (TSA)[10,18], as well as range of motion and scapular notching following reverse shoulder arthroplasty (RSA)[19]. The accuracy of humeral osteotomy is even more important in stemless shoulder arthroplasty, where the orientation of the prosthetic head depends entirely on the resected surface[1,17].

In a comparative study of 125 stemmed and 43 stemless TSAs, Alolabi et al.[1] observed malpositioning of the prosthetic humeral head in 31% and 65% of shoulders respectively, and noted that the most important cause was improper humeral osteotomy. In a more recent series of 100 stemless TSAs, Grubhofer et al.[12] also observed malpositioning of the prosthetic humeral head in 65% of shoulders, operated on by experienced surgeons using three-dimensional (3D) preoperative planning but standard cutting guides, most of which were

Journal Pre-proof

attributed to improper humeral osteotomy. In another recent series of 157 stemmed RSAs, Lädermann et al.[20] observed humeral stem malalignment in 47% of shoulders.

Patient-specific instrumentation (PSI)[21,34] and computer-assisted surgery (CAS)[27] have both been shown to improve implant positioning in shoulder arthroplasty, though most studies focused on glenoid component positioning[11,15]. The purpose of this study was therefore to compare the deviation between planned and post-osteotomy humeral inclination, retrotorsion and height in shoulder arthroplasty using PSI versus standard cutting guides (SCG). The hypothesis was that PSI compared to SCG would reduce the deviation between planned and post-osteotomy humeral inclination, retrotorsion and height.

Materials and Methods

For this biomechanical study, twenty fresh frozen human cadaveric shoulders, free from fractures or other bony pathologies were used (mean age of 70.4 ± 7.7 years, 12 males and 8 females). The specimens were allocated to undergo humeral osteotomy using either PSI or SCG, such that the two groups had similar age, gender and side distributions (Table I).

Cadaveric preparation

All specimens were scanned using computed tomography (CT) (140 kV, 180mAs and an image of 512 X 512 with 0.5 mm slice interval) to enable 3D planning and confirm that none had fractures or other bony pathologies. The complete humerus was scanned to enable measurement of humeral head retrotorsion relative to the trans-epicondylar axis[2]. Each

Journal Pre-proof

specimen was thawed for 24 hours at room temperature and all adjacent soft tissues were removed. The glenohumeral joint was disarticulated and the humerus was fixed in an extremity holder (Sawbones, Vashon Island, WA, USA) (Figure 1).

Definition of landmarks, axes and planes

The CT images of each shoulder were imported in Digital Imaging and Communications in Medicine (DICOM) format. Automatic segmented 3D reconstructions with manual correction (aka semi-automatic) of the proximal and distal humerus were performed using Mimics 16.0 (Materialise, Leuven, Belgium), validated for anatomic measurements[3]. The 3D reconstructions were then imported into SolidWorks 2016 (Dassault Systèmes, Waltham, MA, USA) which was used to create the reference coordinate system and establish the following landmarks, axes and planes[33]. The two most distant points of the medial and lateral elbow epicondyles were used to define the 'trans-epicondylar axis' (TEA)[2,33]. The mid-epicondylar point was used to define the origin of the reference coordinate system. The distance between the origin and the superior margin of the humeral head was used to define the humeral length. Two sets of 3 points were then digitized on cross-sections at 20% and 40% of the humeral length from cranial to caudal, on the inner cortex of the intramedullary humeral canal[26]. Each set was used to create a circle, and the centers of the two circles were used to define the proximal 'humeral shaft axis' (HSA)[26] (Figure 2). The reference coordinate system was established with all axes and planes passing through the origin:

(i) Craniocaudal (CC) axis parallel to the HSA

(ii) Transverse plane normal to the CC axis

(iii) Mediolateral (ML) axis using the projection of the TEA onto the transverse plane

(iv) Sagittal plane normal to the ML axis

Journal Pre-proof

Journal Pre-proof

(v) Anteroposterior (AP) axis perpendicular to the CC and ML axes[26,36]

(vi) Frontal plane normal to the AP axis

The 'humeral head center' (HHC) was determined by fitting a sphere to 4 points digitized as far apart on the articular surface as described by Delude et al[7] (Figure 3). The 'articular margin plane'[33] (AMP) was defined by fitting a plane to 3 points digitized on the anterior, medial and lateral articular margins of the humeral head as described by Youderian et al[38]. The anatomic humeral neck axis (HNA) was defined by the normal to AMP that passes through HHC[26,33].

Pre-osteotomy humeral anatomy

The pre-osteotomy humeral anatomy was defined as follows (Figure 4):

- Anatomic inclination was the angle between the HSA and HNA[26,33]
- Anatomic retrotorsion was the angle between the projections of TEA and HNA onto the transverse plane as described by Raniga et al[26]
- Anatomic height was measured along the HNA, between the AMP and the humeral head cortex[7,33,38]

Humeral osteotomy planning

Humeral osteotomy was planned in agreement among three experienced and fellowship-trained shoulder surgeons (BJ, RH, MZ) and was identical in both PSI and SCG groups:

- Planned inclination was planned at 135° to the CC axis (135° to the HSA), which is the default angulation of SCG

Journal Pre-proof

- Planned retrotorsion was adjusted to match pre-osteotomy humeral anatomy
- Planned osteotomy plane was defined by the planned inclination and retrotorsion, and planned HNA normal to it and passing through the HHC
- Planned osteotomy level was chosen by scrolling along the planned HNA, from proximal to distal, until the insertion of the supraspinatus (aka critical point)[14] (Figure 4)

In both groups, the surgical plan was printed for each humerus to provide surgeons a visual representation of the exact position of the osteotomy.

Humeral osteotomy procedure

For the PSI group, the pre-osteotomy planning was used to design and manufacture personalized humeral cutting guides with 4 congruent contact zones to be placed on the humeral head, its anteroinferior and anterosuperior borders, and on the lateral border of the bicipital groove (Figure 5). For the SCG group, standard humeral cutting guides (Medacta international, Castel San Pietro, Switzerland) were placed on the anterior surface of the proximal humerus (Figure 6). In both groups, osteotomies were performed by one of the three aforementioned surgeons, using a pair of 2.0-mm pins to place the humeral cutting guides, and using an oscillating saw. The surgeons were not allowed to correct their humerus cut in both the SCG and PSI group after the first osteotomy. For each specimen, a post-osteotomy CT scan was acquired and 3D models were reconstructed in Mimics in the same way as prior to osteotomy.

Journal Pre-proof

Comparison between planned and post-osteotomy measurements

The planned and post-osteotomy models were superimposed using SolidWorks to calculate deviations in inclination, retrotorsion and height using the same anatomic landmarks and reference coordinates (Figure 7). Three points were digitized on the anterior, medial and lateral margins of the resected surface[38] to define the post-osteotomy plane. The post-osteotomy HNA was established by the post-osteotomy plane that passes through the anatomic (pre-osteotomy) HHC:

- Post-osteotomy inclination was the angle between the HSA and post-osteotomy HNA[26,33]
- Post-osteotomy retrotorsion was the angle between the projections of the TEA and post-osteotomy HNA onto the transverse plane
- Post-osteotomy height was measured along the post-osteotomy HNA, between the post-osteotomy plane and the humeral head cortex

Outliers were defined as cases with one or more of the following deviations: >5° inclination[1,17], >10° retrotorsion[26], and >3 mm height[4,5,21].

Inter-observer and intra-observer repeatability

For inter-observer repeatability, all measurements were performed by 3 independent observers (JR, CZ, MZ) that were blinded to one-another. Each observer received simple instructions on how to perform the measurements in SolidWorks. The observers used the same methodology as the post-osteotomy measurements. For intra-observer repeatability, one observer (CZ) repeated the measurements 3 months after the first measurement.

Journal Pre-proof

Statistical analysis

A sample size calculation indicated that 9 specimens per group were needed to determine a significance of a difference in the inclination of 3°[5], assuming equal standard deviation of 1°, with a statistical power of 0.90.

Descriptive statistics were used to summarize the data and Shapiro-Wilk test was used to assess the distribution of the samples. Values were expressed in mean and standard deviation (SD). Differences between PSI and SCG groups were assessed using Wilcoxon-Mann-Whitney for quantitative variables and Fisher´s exact test for categorical variables with a significance level of p=0.05. Inter- and intra-observer repeatability were expressed in terms of intraclass correlation coefficients (ICC), which can be interpreted as follows: <0.40 poor; 0.40–0.59 fair; 0.60–0.74 good, and 0.75–1.00 excellent[6]. All statistical analysis was performed using STATA 14.1 (STATACorp, Texas, TX, USA).

Journal Pre-proof

Results

Inter- and intra-observer repeatability of measurements were excellent for all parameters (Table II).

The deviations between planned and post-osteotomy parameters were similar among the PSI and SCG groups for inclination (p=0.260), while they were significantly greater in the SCG group for retorsion (p<0.001) and height (p=0.003) (Table I). The maximum deviations in

inclination, retrotorsion and height were considerably greater in the SCG group (respectively, 11.1°, 17.4° and 4.5 mm), compared to the PSI group (respectively, 5.6°, 6.7° and 1.3 mm).

Using the aforementioned definition, there were 8 (80%) outliers in the SCG group, compared to only 1 (10%) outlier in the PSI group (p=0.005). Most outliers in the SCG group were due to deviation >10° in retrotorsion (Table III).

Discussion

The most important findings of this study were that, in the context of shoulder arthroplasty, PSI could reduce deviations between planned and post-osteotomy humeral retrotorsion and height. Moreover, PSI could reduce the proportions of outliers, which are often observed when using SCG due to deviations between planned and post-osteotomy retrotorsion. These findings therefore partly confirm the hypothesis of this cadaveric study.

Both PSI[21,34] and CAS[27] have shown to improve implant positioning in shoulder arthroplasty. Many studies validated the use of PSI for glenoid component placement by showing better accuracy in both TSA and RSA[4,11,15,16,21,22,30–32,34]. For humeral osteotomy, only one recent study evaluated the accuracy of PSI for humeral osteotomy during shoulder arthroplasty[5]. Cavanagh et al[5] compared the deviation between planned and post-osteotomy using PSI versus CAS on plastic models, and found that CAS reduces deviations in humeral inclination, but not in retrotorsion and height. In the present study, comparing PSI to SCG, the former significantly reduced deviations in humeral retrotorsion and height, but did not significantly reduced deviations in humeral inclination. Comparing the findings of Cavanagh et al. to those

Journal Pre-proof

Journal Pre-proof

of the present study suggests that CAS and PSI could be beneficial for different and complimentary aspects.

Implant positioning is of paramount importance for the success of shoulder arthroplasty. In TSA and hemiarthroplasty, non-anatomic reconstruction of the humeral head leads to changes in shoulder biomechanics[13,17,23,29,37] and worse clinical outcomes[10,18]. Franta et al[10] showed that in a series of 282 patients that had unsatisfactory shoulder arthroplasties, 65% had implant malpositioning. In RSA, implant positioning of the humeral and the glenoid component affects the range of motion[19,24], stability[9] and may lead subacromial impingement[35] and scapular notching[19].

Humeral osteotomy influences implant positioning[28], especially in modern stemless implants where the implant poses solely on the resected surface. Alolabi et al[1] found that 20.5% of malpositioning was attributed to improper humeral neck osteotomy in stemmed implants, compared to 89.3% in stemless implants. In a more recent study, Grubhofer et al[12] found that with 3D preoperative planning but using standard cutting guides, the postoperative center of rotation deviates by a mean of 4.3mm (range 0-22.5) from the preoperative humeral head center, mainly attributed to humeral osteotomy.

The findings of the present study should be interpreted with the following limitations in mind. First, this is a cadaveric study without clinical and radiological long-term data which does not allow direct extrapolation of the findings *in-vivo*. Second, the glenohumeral joint was disarticulated and the soft tissue attached to the humerus was removed prior to osteotomy. This could create a less representative situation of the challenges faced during humeral

osteotomy in real world. This was done because by removing the soft tissue, we could isolate the effect of the different guides on the osteotomy without the soft tissue effect that varies from specimen to specimen. Additionally, we think that the use of fresh frozen cadavers gives more representative and realistic results compared to sawbones. Third, this study only analyzed the accuracy of the humeral osteotomy during shoulder arthroplasty, but other factors such as implant size and position may also influence the outcomes were not considered[1,10,12,17,25,29]. Fourth, the present study utilized the three dots method to define the articular margin plane. Although this methodology has been previously used[38], this method has shortcomings and other methods to define this plane could be considered[33]. Finally, the authors deemed it important to report the utility and reliability of PSI and SCG on shoulders with no osteoarthritis to establish normal values, and with osteotomies by 3 experienced shoulder specialists to eliminate potential sources of errors at the initial step. Nevertheless, further studies should investigate the reproducibility of PSI in shoulder with osteoarthritic deformities. Furthermore, there is no consensus regarding the exact position of the implants, and clinical randomized studies are required to determine whether a change of >5° inclination[1,17], >10° retrotorsion[26], and >3 mm height[4,5,21] could influence clinical outcomes.

Conclusions

Compared to SCG, PSI could reduce deviations between planned and post-osteotomy humeral retrotorsion and height in the context of shoulder arthroplasty. Moreover, PSI could reduce the proportions of outliers, which are often observed when using SCG due to deviations between planned and post-osteotomy retrotorsion.

Journal Pre-proof

References

1. Alolabi B, Youderian AR, Napolitano L, Szerlip BW, Evans PJ, Nowinski RJ, et al. Radiographic assessment of prosthetic humeral head size after anatomic shoulder arthroplasty. J. Shoulder Elbow Surg. 2014;23(11):1740–1746. doi:10.1016/j.jse.2014.02.013
2. Boileau P, Bicknell RT, Mazzoleni N, Walch G, Urien JP. CT scan method accurately assesses humeral head retroversion. Clin. Orthop. Relat. Res. 2008;466(3):661–669. doi:10.1007/s11999-007-0089-z
3. Bryce CD, Pennypacker JL, Kulkarni N, Paul EM, Hollenbeak CS, Mosher TJ, et al. Validation of three-dimensional models of in situ scapulae. J. Shoulder Elbow Surg. 2008;17(5):825–832. doi:10.1016/j.jse.2008.01.141
4. Cabarcas BC, Cvetanovich GL, Espinoza Orías AA, Inoue N, Gowd AK, Bernardoni E, et al. Novel 3-dimensionally printed patient-specific guide improves accuracy compared with standard total shoulder arthroplasty guide: a cadaveric study. JSES Open Access 2019;3(2):83–92. doi:10.1016/j.jses.2019.04.001
5. Cavanagh J, Lockhart J, Langohr GDG, Johnson JA, Athwal GS. A comparison of patient-specific instrumentation to navigation for conducting humeral head osteotomies during shoulder arthroplasty. JSES Int. 2021;5(5):875–880. doi:10.1016/j.jseint.2021.05.009
6. Cicchetti D V. Interreliability standards in psychological evaluations. Psychol. Assess. 1994;6(4):284–290.
7. DeLude JA, Bicknell RT, MacKenzie GA, Ferreira LM, Dunning CE, King GJW, et al. An anthropometric study of the bilateral anatomy of the humerus. J. Shoulder Elbow Surg. 2007;16(4):477–483. doi:10.1016/j.jse.2006.09.016
8. Favre P, Moor B, Snedeker JG, Gerber C. Influence of component positioning on impingement in conventional total shoulder arthroplasty. Clin. Biomech. 2008;23(2):175–183. doi:10.1016/j.clinbiomech.2007.09.009
9. Ferle M, Pastor MF, Hagenah J, Hurschler C, Smith T. Effect of the humeral neck-shaft angle and glenosphere lateralization on stability of reverse shoulder arthroplasty: a cadaveric study. J. Shoulder Elbow Surg. 2019;28(5):966–973. doi:10.1016/j.jse.2018.10.025

Journal Pre-proof

10. Franta AK, Lenters TR, Mounce D, Neradilek B, Matsen FA. The complex characteristics of 282 unsatisfactory shoulder arthroplasties. J. Shoulder Elbow Surg. 2007;16(5):555–562. doi:10.1016/j.jse.2006.11.004

11. Gauci MO, Boileau P, Baba M, Chaoui J, Walch G. Patient-specific glenoid guides provide accuracy and reproducibility in total shoulder arthroplasty. Bone Jt. J. 2016;98-B(8):1080–1085. doi:10.1302/0301-620X.98B8.37257

12. Grubhofer F, Muniz Martinez AR, Haberli J, Selig ME, Ernstbrunner L, Price MD, et al. Does computerized CT-based 3D planning of the humeral head cut help to restore the anatomy of the proximal humerus after stemless total shoulder arthroplasty? J. Shoulder Elbow Surg. 2020; doi:10.1016/j.jse.2020.08.045

13. Harryman DT, Sidles JA, Harris SL, Lippitt SB, Matsen FA. The effect of articular conformity and the size of the humeral head component on laxity and motion after glenohumeral arthroplasty: A study in cadavera. J. Bone Jt. Surg. - Ser. A. 1995;77(4):555–563.

14. Hertel R, Knothe U, Ballmer FT. Geometry of the proximal humerus and implications for prosthetic design. J. Shoulder Elbow Surg. 2002;11(4):331–338. doi:10.1067/mse.2002.124429

15. Heylen S, Van Haver A, Vuylsteke K, Declercq G, Verborgt O. Patient-specific instrument guidance of glenoid component implantation reduces inclination variability in total and reverse shoulder arthroplasty. J. Shoulder Elbow Surg. 2016;25(2):186–192. doi:10.1016/j.jse.2015.07.024

16. Iannotti JP, Walker K, Rodriguez E, Patterson TE, Jun BJ, Ricchetti ET. Accuracy of 3-Dimensional Planning, Implant Templating, and Patient-Specific Instrumentation in Anatomic Total Shoulder Arthroplasty. J. Bone Jt. Surg. - Am. Vol. 2019;101(5):446–457. doi:10.2106/JBJS.17.01614

17. Kadum B, Hassany H, Wadsten M, Sayed-Noor A, Sjödén G. Geometrical analysis of stemless shoulder arthroplasty: a radiological study of seventy TESS total shoulder prostheses. Int. Orthop. 2016;40(4):751–758. doi:10.1007/s00264-015-2935-z

18. Kadum B, Wahlström P, Khoschnau S, Sjödén G, Sayed-Noor A. Association of lateral humeral offset with functional outcome and geometric restoration in stemless

Journal Pre-proof

total shoulder arthroplasty. J. Shoulder Elbow Surg. 2016;25(10):e285–e294. doi:10.1016/j.jse.2016.02.021

19. Lädermann A, Chiu JCH, Cunningham G, Hervé A, Piotton S, Bothorel H, et al. Do short stems influence the cervico-diaphyseal angle and the medullary filling after reverse shoulder arthroplasties? Orthop. Traumatol. Surg. Res. 2020;106(2):241–246. doi:10.1016/j.otsr.2019.12.010

20. Lädermann A, Denard PJ, Collin P, Zbinden O, Chiu JCH, Boileau P, et al. Effect of humeral stem and glenosphere designs on range of motion and muscle length in reverse shoulder arthroplasty. Int. Orthop. 2020;44(3):519–530. doi:10.1007/s00264-019-04463-2

21. Levy JC, Everding NG, Frankle MA, Keppler LJ. Accuracy of patient-specific guided glenoid baseplate positioning for reverse shoulder arthroplasty. J. Shoulder Elbow Surg. 2014;23(10):1563–1567. doi:10.1016/j.jse.2014.01.051

22. Marcoin A, Nerot C, Lestra T, Blasco L, Ferrier A, Siboni R, et al. The precision of patient-specific instrumentation guides for the positioning of the glenoid component in total reverse shoulder arthroplasty: an in vivo scanographic study. Int. Orthop. 2020;44(9):1761–1766. doi:10.1007/s00264-020-04524-x

23. Nyffeler RW, Sheikh R, Jacob HAC, Gerber C. Influence of Humeral Prosthesis Height on Biomechanics of Glenohumeral Abduction: An in Vitro Study. J. Bone Jt. Surg. - Ser. A. 2004;86(3):575–580. doi:10.2106/00004623-200403000-00017

24. Oh JH, Sharma N, Rhee SM, Park JH. Do individualized humeral retroversion and subscapularis repair affect the clinical outcomes of reverse total shoulder arthroplasty? J. Shoulder Elbow Surg. 2020;29(4):821–829. doi:10.1016/j.jse.2019.08.016

25. Pinto MC, Archie AT, Mosher ZA, Ransom EF, McGwin G, Fehringer E V., et al. Radiographic restoration of native anatomy: a comparison between stemmed and stemless shoulder arthroplasty. J. Shoulder Elbow Surg. 2019;28(8):1595–1600. doi:10.1016/j.jse.2019.01.015

26. Raniga S, Knowles NK, West E, Ferreira LM, Athwal GS. The Walch type B humerus: glenoid retroversion is associated with torsional differences in the humerus. J. Shoulder Elbow Surg. 2019;28(9):1801–1808.

Journal Pre-proof

doi:10.1016/j.jse.2019.02.010

27. Schoch BS, Haupt E, Leonor T, Farmer KW, Wright TW, King JJ. Computer navigation leads to more accurate glenoid targeting during total shoulder arthroplasty compared with 3-dimensional preoperative planning alone. J. Shoulder Elbow Surg. 2020;29(11):2257–2263. doi:10.1016/j.jse.2020.03.014

28. Suter T, Kolz CW, Tashjian RZ, Henninger HB, Gerber Popp A. Humeral head osteotomy in shoulder arthroplasty: a comparison between anterosuperior and inferoanterior resection techniques. J. Shoulder Elbow Surg. 2017;26(2):343–351. doi:10.1016/j.jse.2016.07.010

29. Terrier A, Ramondetti S, Merlini F, Pioletti DD, Farron A. Biomechanical consequences of humeral component malpositioning after anatomical total shoulder arthroplasty. J. Shoulder Elbow Surg. 2010;19(8):1184–1190. doi:10.1016/j.jse.2010.06.006

30. Throckmorton TW, Gulotta L V., Bonnarens FO, Wright SA, Hartzell JL, Rozzi WB, et al. Patient-specific targeting guides compared with traditional instrumentation for glenoid component placement in shoulder arthroplasty: A multi-surgeon study in 70 arthritic cadaver specimens. J. Shoulder Elbow Surg. 2015;24(6):965–971. doi:10.1016/j.jse.2014.10.013

31. Verborgt O, Hachem AI, Eid K, Vuylsteke K, Ferrand M, Hardy P. Accuracy of patient-specific guided implantation of the glenoid component in reversed shoulder arthroplasty. Orthop. Traumatol. Surg. Res. 2018;104(6):767–772. doi:10.1016/j.otsr.2018.01.010

32. Villatte G, Muller AS, Pereira B, Mulliez A, Reilly P, Emery R. Use of Patient-Specific Instrumentation (PSI) for glenoid component positioning in shoulder arthroplasty. A systematic review and meta-analysis. PLoS One. 2018;13(8):1–17. doi:10.1371/journal.pone.0201759

33. Vlachopoulos L, Dünner C, Gass T, Graf M, Goksel O, Gerber C, et al. Computer algorithms for three-dimensional measurement of humeral anatomy: Analysis of 140 paired humeri. J. Shoulder Elbow Surg. 2016;25(2):e38–e48. doi:10.1016/j.jse.2015.07.027

34. Walch G, Vezeridis PS, Boileau P, Deransart P, Chaoui J. Three-dimensional

Journal Pre-proof

planning and use of patient-specific guides improve glenoid component position: An in vitro study. J. Shoulder Elbow Surg. 2015;24(2):302–309. doi:10.1016/j.jse.2014.05.029

35. Werner BS, Chaoui J, Walch G. The influence of humeral neck shaft angle and glenoid lateralization on range of motion in reverse shoulder arthroplasty. J. Shoulder Elbow Surg. 2017 Oct;26(10):1726–1731. doi:10.1016/j.jse.2017.03.032

36. West EA, Knowles NK, Athwal GS, Ferreira LM. A 3D comparison of humeral head retroversion by sex and measurement technique. Shoulder Elbow 2018;10(3):192–200. doi:10.1177/1758573217711897

37. Williams GR, Wong KL, Pepe MD, Tan V, Silverberg D, Ramsey ML, et al. The effect of articular malposition after total shoulder arthroplasty on glenohumeral translations, range of motion, and subacromial impingement. J. Shoulder Elbow Surg. 2001;10(5):399–409.

38. Youderian AR, Ricchetti ET, Drews M, Iannotti JP. Determination of humeral head size in anatomic shoulder replacement for glenohumeral osteoarthritis. J. Shoulder Elbow Surg. 2014;23(7):955–963. doi:10.1016/j.jse.2013.09.005

Legends for figures and tables

Figure 1:

For cadaver preparation, the glenohumeral joint was disarticulated and the humerus was fixed in an extremity holder.

Figure 2:

a. The two most distant points of the medial and lateral elbow epicondyles were used to define the 'trans-epicondylar axis' (TEA). Two sets of 3 points were then digitized on cross-sections at 20% and 40% of the humeral length. Each set was used to create a circle, and the centers of the two circles were used to define the proximal 'humeral shaft axis' (HSA). **b.** The reference coordinate system was established with all axes and planes passing through the origin: (i) Craniocaudal (CC) axis (green arrow) parallel to the HSA; (ii) Transverse plane normal to the CC axis; (iii) Mediolateral (ML) axis (blue arrow) using the projection of the

Journal Pre-proof

TEA onto the transverse plane; Anteroposterior (AP) axis (red arrow) perpendicular to the CC and ML axes.

Figure 3:

The 'humeral head center' (HHC) was determined by fitting a sphere on the articular surface. The 'articular margin plane' (AMP) was defined by fitting a plane to 3 points digitized on the anterior, medial and lateral articular margins of the humeral head. The anatomic 'humeral neck axis' (HNA) was defined by the normal to AMP that passes through HHC.

Figure 4:

a. Anatomic inclination was the angle between the HSA and HNA. Anatomic height was measured along the HNA, between the AMP and the humeral head cortex. **b.** Anatomic retrotorsion was the angle between the projections of TEA and HNA onto the transverse. **c.** Planned inclination was planned at 135°. Planned osteotomy plane was defined by the planned inclination and retrotorsion, and planned HNA normal to it. Planned osteotomy level was chosen by scrolling along the planned HNA, from proximal to distal, until the critical point.

Figure 5:

a. For the PSI group, the pre-osteotomy planning was used to design and manufacture personalized humeral cutting guides with 4 congruent contact zones to be placed on the humeral head, its anteroinferior and anterosuperior borders, and on the lateral border of the bicipital groove. **b.** The PSI was placed manually and was secured using a pair of 2.0-mm pins. **c.** The oscillating saw was used over the flattened surface of the guide.

Figure 6:

a. For the SCG group, standard humeral cutting guides were used. **b.** The guide was placed manually in the anterior surface of the proximal humeral head and was secured using a pair of 2.0-mm pins. **c.** The oscillating saw was used over the flattened surface of the guide.

Journal Pre-proof

Journal Pre-proof

Figure 7:

The planned and post-osteotomy models were superimposed to calculate deviations in inclination, retrotorsion and height using the same landmarks and reference coordinates.

Table I:

Demographic data, planned, postoperative and deviation values between PSI and SCG group.

Table II:

Inter-observer and intra-observer repeatability

Table III: Outliers

Journal Pre-proof

Journal Pre-proof

Table I: Demographic data, planned, postoperative and deviation values between PSI and SCG group.

	PSI group (n=10)				SCG group (n=10)				
	mean n	SD (%)	Range min	max	mean n	SD (%)	Range min	max	p value*
Demographics									
Age	70.7	±7.5	(59	- 84)	70.1	±8.3	(58	- 80)	0.867
Male gender	6	(60%)			6	(60%)			
Right side	5	(50%)			5	(50%)			
Inclination (°)									
Pre-osteotomy	133.2	±2.3	(128.9	- 135.1)	134.4	±3.0	(131.1	- 139.9)	0.523
Planned osteotomy	135.0	±0.0	(135.0	- 135.0)	135.0	±0.0	(135.0	- 135.0)	1.000
Post-osteotomy	134.0	±3.4	(129.4	- 137.7)	136.4	±5.9	(127.6	- 146.1)	0.579
Deviation (post *minus* planned)	1.9	±1.5	(0.6	- 5.6)	3.8	±3.4	(0.5	- 11.1)	0.260
Retrotorsion (°)									
Pre-osteotomy	32.9	±6.4	(19.8	- 40.2)	27.7	±10.6	(19.3	- 36.2)	0.101
Planned osteotomy	32.8	±6.2	(20.0	- 40.0)	27.8	±5.6	(19.5	- 35.0)	0.072
Post-osteotomy	33.9	±8.3	(18.6	- 44.7)	30.0	±10.3	(14.1	- 45.5)	0.364
Deviation (post *minus* planned)	2.6	±2.2	(0.0	- 6.7)	11.7	±3.8	(5.1	- 17.4)	**<0.001**
Height (mm)									
Pre-osteotomy	17.1	±2.7	(12.5	- 21.2)	16.8	±3.8	(10.1	- 22.7)	0.813
Planned osteotomy	17.1	±2.4	(12.5	- 19.5)	16.7	±2.8	(11.0	- 20.0)	0.768
Post-osteotomy	17.1	±2.6	(11.4	- 19.8)	17.4	±3.2	(12.5	- 21.4)	0.844
Deviation (post *minus* planned)	0.6	±0.5	(0.1	- 1.3)	2.1	±1.2	(0.3	- 4.5)	**0.003**

Abbreviations: SD, Standard Deviation; min, Minimum Value; max, maximum value

*Wilcoxon-Mann-Whitney test

Journal Pre-proof

Journal Pre-proof

Journal Pre-proof

Journal Pre-proof

Table II: Inter-observer and intra-observer repeatability

	Inter-observer			Intra-observer		
	ICC	95% CI	p value	ICC	95% CI	p value
Inclination	0.96	(0.89 - 0.98)	**<0.001**	0.89	(0.76 - 0.96)	**<0.001**
Retrotorsion	0.99	(0.99 - 0.99)	**<0.001**	0.98	(0.97 - 0.99)	**<0.001**
Height	0.99	(0.98 - 0.99)	**<0.001**	0.97	(0.94 - 0.99)	**<0.001**

ICC (intraclass correlation coeficient)

ICC can be interpreted as follows: < 0.40 poor; 0.40–0.59 fair; 0.60–0.74 good, and 0.75–1.00 excellent

Journal Pre-proof

Journal Pre-proof

Table III: Outliers

	PSI group n=10 (%)	SCG group n=10 (%)	p value*
Any of the 3 parameters	1 (10%)	8 (80%)	**0.005**
Inclination (deviation >5°)	1 (10%)	2 (20%)	0.531
Retrotorsion (deviation >10°)	0 (0%)	6 (60%)	**0.011**
Height (deviation >3 mm)	0 (0%)	1 (10%)	0.305

*Fisher's Exact test

Journal Pre-proof

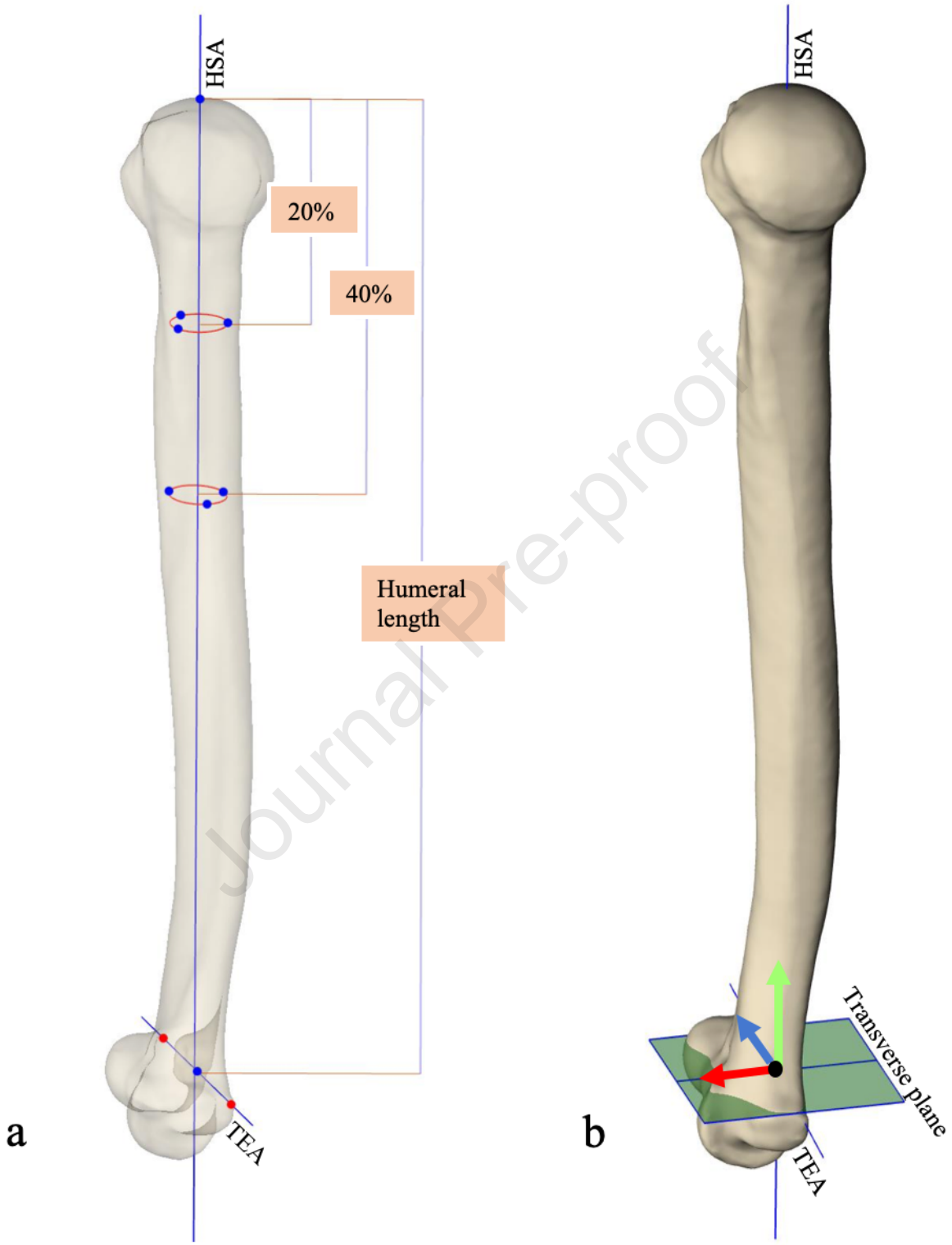

Journal Pre-proof

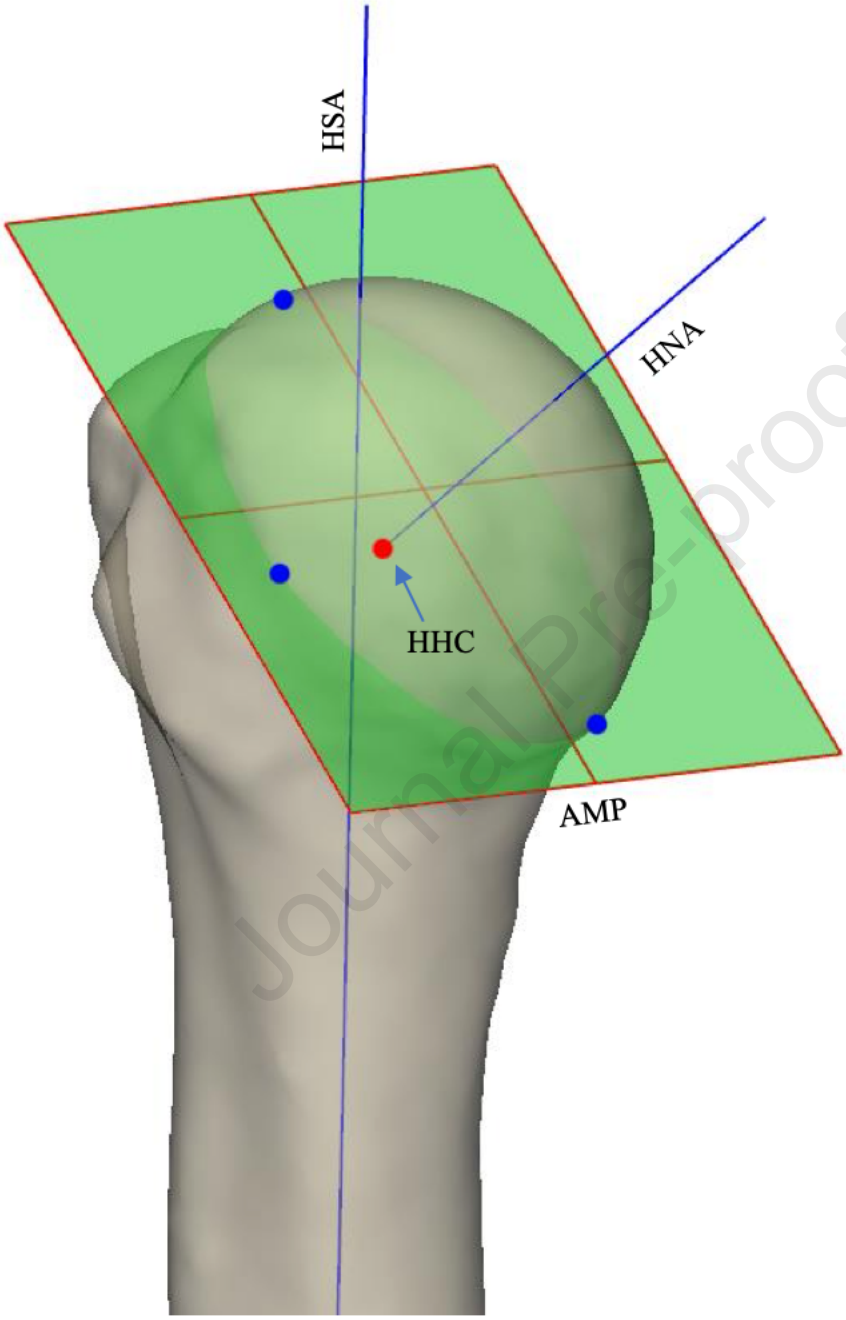

Journal Pre-proof

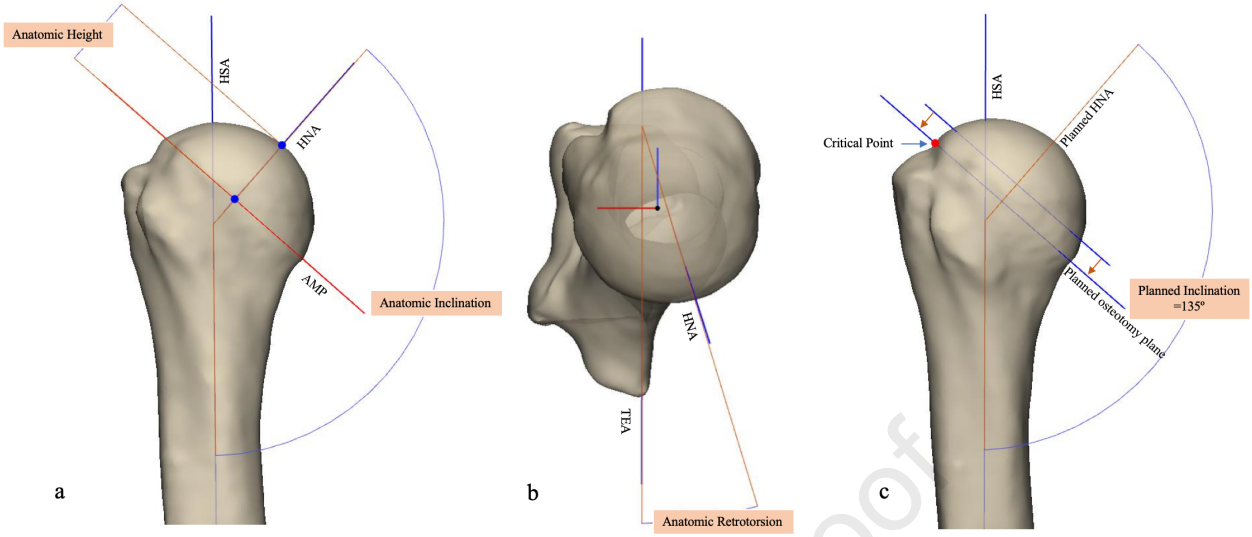

Journal Pre-proof

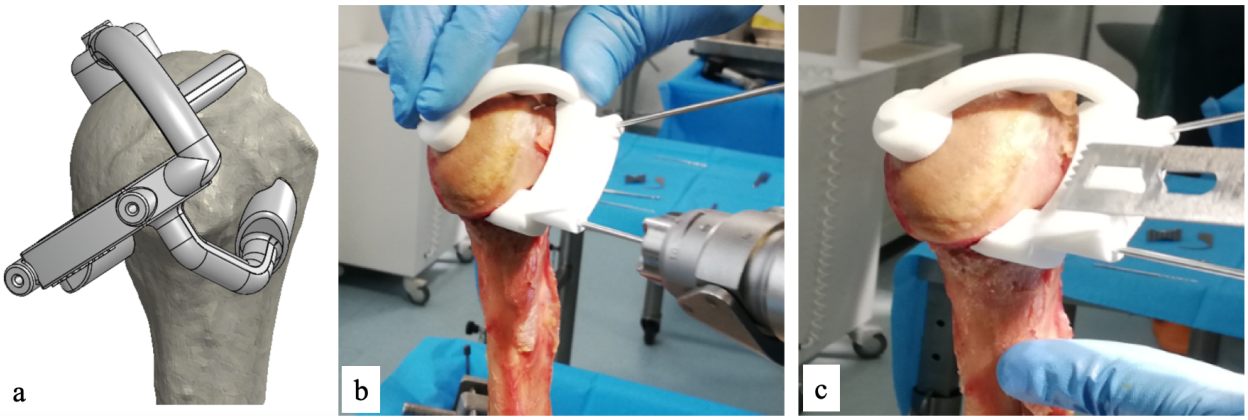

Journal Pre-proof

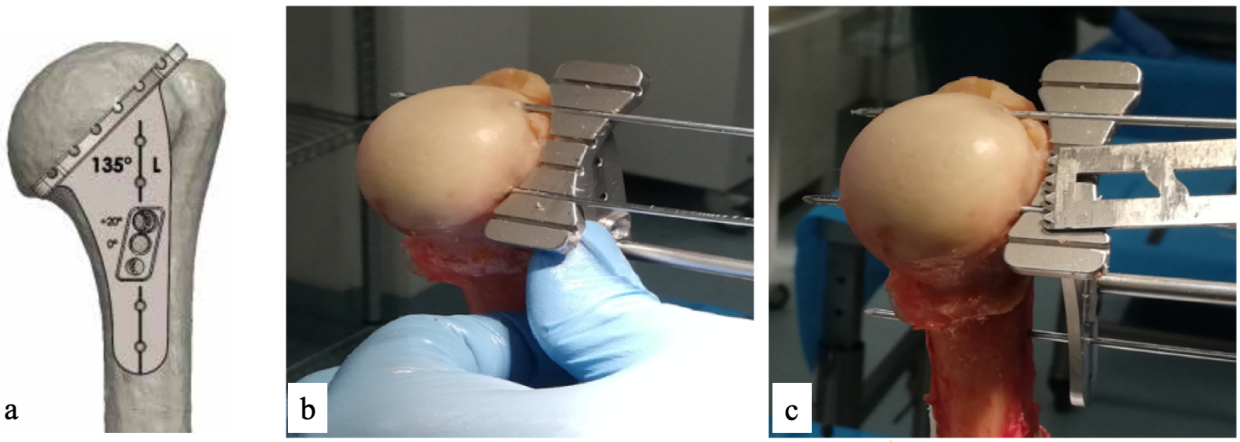

Journal Pre-proof

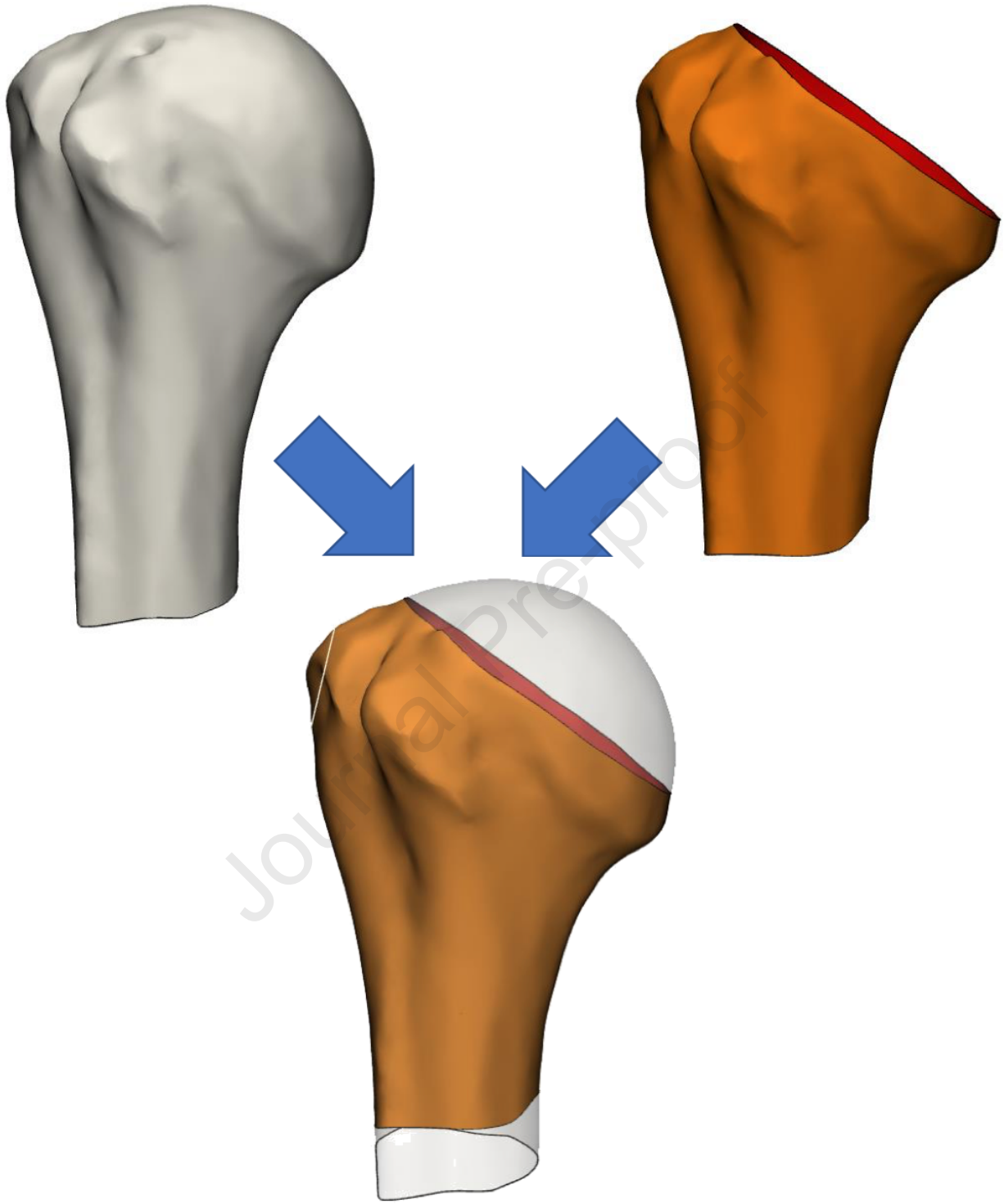

Journal Pre-proof