



OPEN ACCESS

Original research

# Evaluation of time-resolved whole brain flat panel detector perfusion imaging using RAPID ANGIO in patients with acute stroke: comparison with CT perfusion imaging

Christoph C Kurmann ,<sup>1</sup> Johannes Kaesmacher ,<sup>1</sup> Daniel L Cooke,<sup>2</sup> Marios Psychogios,<sup>3</sup> Johannes Weber,<sup>4</sup> Demetrius K Lopes,<sup>5</sup> Gregory W Albers,<sup>6</sup> Pasquale Mordasini<sup>1</sup>

► Additional supplemental material is published online only. To view, please visit the journal online (<http://dx.doi.org/10.1136/neurintsurg-2021-018464>).

For numbered affiliations see end of article.

## Correspondence to

Dr Pasquale Mordasini, University of Bern, Bern, Switzerland; [pasquale.mordasini@insel.ch](mailto:pasquale.mordasini@insel.ch)

Received 29 November 2021

Accepted 23 March 2022

## ABSTRACT

**Background** In contrast to conventional CT perfusion (CTP) imaging, flat panel detector CT perfusion (FD-CTP) imaging can be acquired directly in the angiosuite.

**Objective** To evaluate time-resolved whole brain FD-CTP imaging and assess clinically important qualitative and quantitative perfusion parameters in correlation with previously acquired conventional CTP using the new RAPID for ANGIO software.

**Methods** We included patients with internal carotid artery occlusions and M1 or M2 occlusions from six centers. All patients underwent mechanical thrombectomy (MT) with preinterventional conventional CTP and FD-CTP imaging. Quantitative performance was determined by comparing volumes of infarct core, penumbral tissue, and mismatch. Eligibility for MT according to the perfusion imaging criteria of DEFUSE 3 was determined for each case from both conventional CTP and FD-CTP imaging.

**Results** A total of 20 patients were included in the final analysis. Conventional relative cerebral blood flow (rCBF) <30% and FD-CTP rCBF <45% showed good correlation ( $R^2=0.84$ ). Comparisons of conventional CTP Tmax >6 s versus FD-CTP Tmax >6 s and CTP mismatch versus FD-CTP mismatch showed more variability ( $R^2=0.57$ , and  $R^2=0.33$ , respectively). Based on FD-CTP, 16/20 (80%) patients met the inclusion criteria for MT according to the DEFUSE 3 perfusion criteria, in contrast to 18/20 (90%) patients based on conventional CTP. The vessel occlusion could be correctly extrapolated from the hypoperfusion in 18/20 cases (90%).

**Conclusions** In our multicenter study, time-resolved whole brain FD-CTP was technically feasible, and qualitative and quantitative perfusion results correlated with those obtained with conventional CTP.

## INTRODUCTION

In patients with acute ischemic stroke, perfusion imaging facilitates detection of the occluded vessels,<sup>1 2</sup> influences decision-making regarding therapy options, and is recommended especially in delayed time windows.<sup>3 4</sup> Perfusion imaging helps to delineate infarct core and hypoperfused, but not yet infarcted, tissue (tissue at risk, penumbra), with generally accepted thresholds of relative cerebral

blood flow (rCBF) <30% and time to maximum (Tmax) >6 s.<sup>5</sup>

In contrast to conventional CT perfusion (CTP), flat panel detector CT can be acquired directly in the angiosuite and can generate angiograms (FD-CTA) and perfusion maps (FD-CTP) directly on the intervention-table. This allows direct transport of patients to the angiosuite ('direct to the angio' workflow), reduces time to puncture, and increases the likelihood of clinical improvement.<sup>6-11</sup> It is an essential precondition that FD-CTP provides comparable data to that obtained from validated conventional CTP.

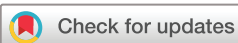Until recently, FD-CTP was limited to the acquisition of parenchymal cerebral blood volume or FD-CBV maps using a two-sweep C-arm rotation protocol lacking the temporal resolution needed for time-resolved dynamic perfusion imaging such as CBF or Tmax.<sup>12</sup> Many studies have investigated dynamic perfusion imaging in the angiosuite.<sup>13 14</sup> The recent clinical introduction of a multiphase FD perfusion acquisition protocol (*syngo* DynaCT Multiphase, Siemens Healthineers AG) enables the acquisition of time-resolved whole brain FD-CTP datasets that overcome this technical limitation. RAPID for ANGIO (RAPID, iSchemaView, USA) is the first, and currently only, clinically available postprocessing software for multiphase FD-CTP acquisitions based on the RAPID software.<sup>6</sup>

To evaluate FD-CTP imaging, we assessed clinically important qualitative and quantitative perfusion parameters in correlation to prior acquired conventional multislice CTP using the new RAPID for ANGIO software.

## METHODS

### Patient population

We included patients from six centers: San Francisco General Hospital covered by the University of California San Francisco (San Francisco, USA), University Hospital of Bern (Switzerland), Kantonsspital St Gallen (Switzerland), University Medical Center Göttingen (Germany), Advocate Lutheran General Hospital (Chicago, USA), and University Hospital of Basel (Switzerland) from October 2016 to February 2021. All patients underwent



© Author(s) (or their employer(s)) 2022. Re-use permitted under CC BY-NC. No commercial re-use. See rights and permissions. Published by BMJ.

**To cite:** Kurmann CC, Kaesmacher J, Cooke DL, et al. *J NeuroIntervent Surg* Epub ahead of print: [please include Day Month Year]. doi:10.1136/neurintsurg-2021-018464

**Table 1** Patient characteristics at baseline

Overall (N)	20
Age (median (IQR))	74.00 (64.75, 82.25)
Female (%)	6 (30.0)
Baseline NIHSS score (median (IQR))	11.50 (7.00, 17.00)
Specific occluded vessel (%)	
ICA	5 (25.0)
M1	13 (65.0)
M2	2 (10.0)
Time between scans (min) (mean (SD))	42.88 (22.53)
CTP rCBF <30% (mL) (median (IQR))	13.00 (0.00, 25.00)
FD-CTP rCBF <45% (mL) (median (IQR))	21.00 (3.75, 44.50)
CTP Tmax >6s (mL) (median (IQR))	127.50 (93.75, 173.50)
FD-CTP Tmax >6s (mL) (median (IQR))	127.00 (112.25, 175.00)
CTP mismatch (mL) (median (IQR))	104.50 (82.00, 137.50)
FD-CTP mismatch (mL) (median (IQR))	110.50(82.25, 131.25)

CTP, CT perfusion; FD-CTP, flat panel detector CT perfusion; ICA, internal carotid artery; IQR, interquartile range; NIHSS, National Institutes of Health Stroke Scale; rCBF, relative cerebral blood flow; SD, standard deviation.

mechanical thrombectomy (MT), had preinterventional FD-CTP imaging and met the following inclusion criteria:

- ▶ Intracranial internal carotid artery, M1, or M2 occlusion
- ▶ No complete or partial recanalization between the scans (eg, M1 occlusion in the initial scan and M2 occlusion in the FD-CT scan)
- ▶ Technically adequate baseline conventional CTP and FD-CTP imaging without serious motion or imaging artifacts
- ▶ A maximum of 120 min delay between conventional CTP and FD-CTP

Approval for this multicenter study was obtained from the institutional review board. The requirement for informed consent was waived owing to the retrospective nature of the study.

## Imaging protocol

### Workflow

After clinical examination by a neurologist at the emergency department, patients underwent conventional stroke CT imaging, including CT angiography (CTA) and CTP. If the eligibility criteria for MT were fulfilled, patients were either transferred to a thrombectomy center (transfer patients) or directly to the angiosuite (mothership patients) and received FD-CT imaging, including FD-CTP, preinterventionally at the discretion of the treating physician. The decision whether to perform FD-CT imaging was based on clinical reasoning and provided additional valuable information that allowed the involved physicians to adjust the treatment strategy accordingly.

### FD-CTP acquisition

Biplane flat panel detector angiographic systems (ARTIS Icono and Artis Q, Siemens Healthineers AG, Forchheim, Germany) were used to acquire imaging data for the whole brain. Ten rotational sweeps (with a duration of 5 s each and a turnaround of about 1 s) of the angiographic C-arm system around the patient were performed (the multi-sweep acquisition on Artis Q is based on a research prototype). Z-axis coverage of the FD-CTP was full brain. The first two rotations served as mask runs, whereas the following eight rotations recorded inflow and outflow of

contrast agent, creating time–density curves with eight time points (online supplemental figure I). Injection of contrast agent (60 mL Iopamiro 400 or 300 or 70 mL Omnipaque 350) was started at the same time as the mask run via an 18 G left or right cubital venous line and was followed by a chaser of 40–60 mL saline flush (mono or dual-head power injector at an injection rate of 5 mL/s).

### CTP and FD-CTP postprocessing

Pos-processing of conventional CTP and FD-CTP scans was performed using dedicated software based on RAPID (RAPID for ANGIO, iSchemaView). Reconstruction of the CTP and FD-CTP datasets was performed on the vendor's product software and then transferred to RAPID and RAPID for ANGIO for further processing. The default threshold for infarct core used for conventional CTP using RAPID is rCBF <30% and for FD-CTP using the RAPID for ANGIO software rCBF <45%. The rationale behind using a different threshold for FD-CTP was based on phantom data, which showed that FD-CTP is less sensitive than conventional CTP for detecting CBF values below 30 mL/100 g/min. The phantom data are presented in online supplemental figure II. In addition, a pilot study using the <45% threshold for FD-CTP in patients with acute stroke demonstrated a strong correlation with conventional CTP (Pearson=0.91, Spearman=0.87) with an intraclass correlation coefficient of 0.89 (95% CI 0.67 to 0.96).<sup>13</sup>

### Outcome

Quantitative performance was determined by comparing volumes of infarct core (defined as rCBF <30% for conventional CTP using RAPID and <45% for FD-CTP using RAPID for ANGIO), penumbral tissue (defined as Tmax >6 s for both modalities), and mismatch (penumbral tissue (mL) – infarct core (mL)). In addition, the influence of time between the scans was evaluated continuously and for different groups (<30 min, 30–60 min, and >60 min) and depicted graphically.

Eligibility for MT according to the perfusion imaging criteria of DEFUSE 3 was determined for each patient and for both modalities (infarct core <70 mL, mismatch volume ≥15 mL, and mismatch ratio ≥1.8).<sup>15</sup>

### Statistical analysis

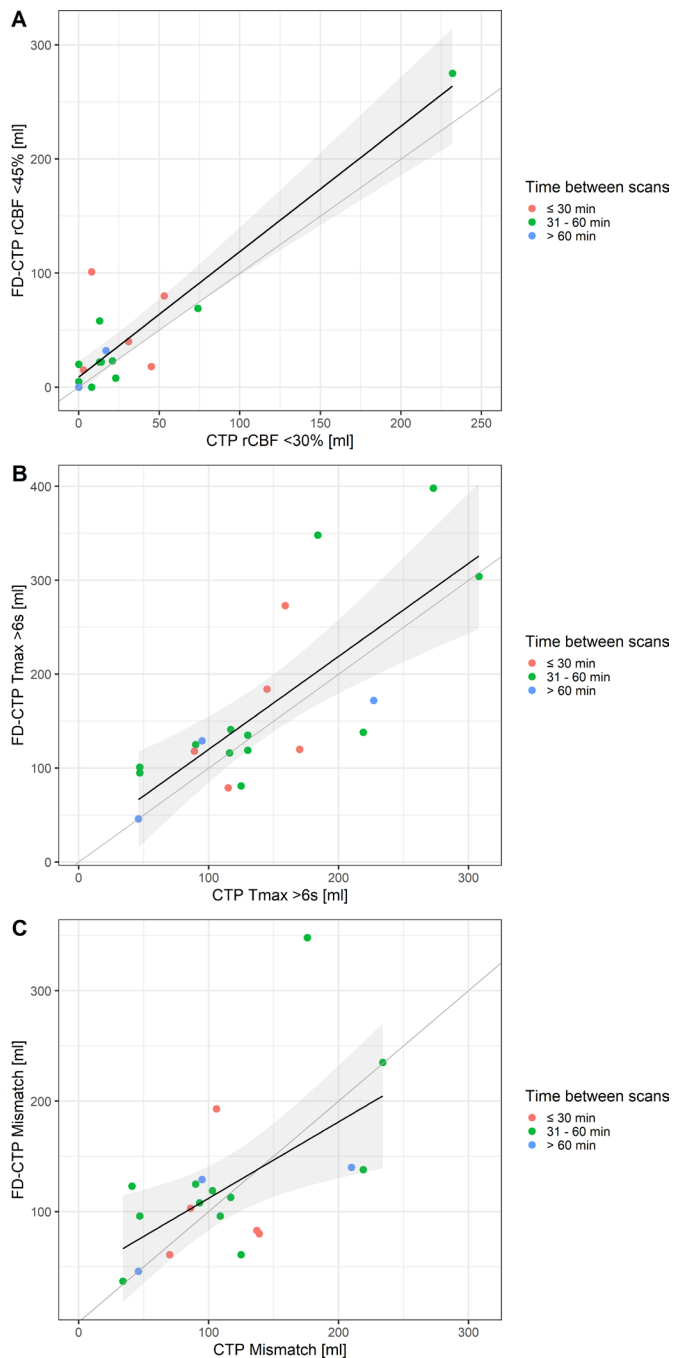
Baseline characteristics of the groups were compared using the Kruskal-Wallis test for continuous variables or Fisher's exact test for categorical variables. Data are displayed as median (IQR) and n (%) if not otherwise specified.

Correlation of baseline CTP volumes (rCBF <30%, Tmax >6 s, mismatch) with FD-CTP volumes (rCBF <45%, Tmax >6 s, mismatch), stratified by the time between the scans, was graphically depicted in scatter plots and R<sup>2</sup> (coefficient of determination) was calculated. Bland-Altman analysis was conducted using the 'BlandAltmanLeh' (version 0.3.1) package for R. The x-axis of the Bland-Altman plots displays the mean of the two measurements (volume measured by CTP and by FD-CTP), and the y-axis shows the difference between the two measurements.

A two-tailed p value of <0.05 was considered statistically significant. Statistical analysis was performed using R (version 4.0.2).<sup>16</sup>

## RESULTS

Of 29 patients with adequate conventional CTP and FD-CTP, two had to be excluded owing to reperfusion between the scans,

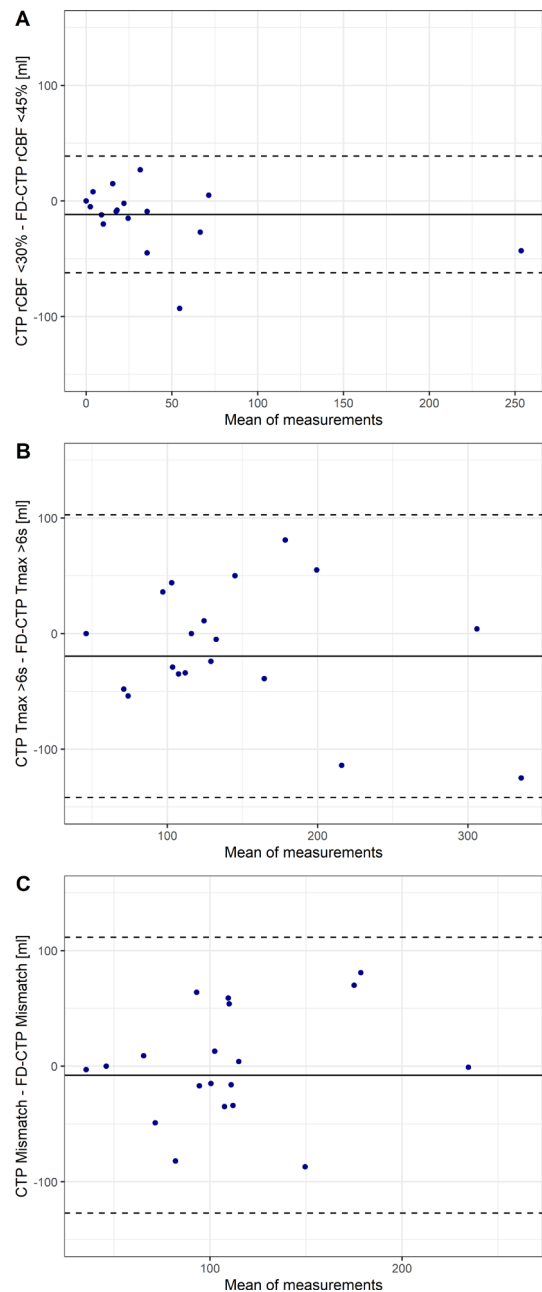


**Figure 1** Comparison of different perfusion volumes between conventional CT perfusion (CTP) and flat panel detector perfusion (FD-CTP), stratified by times between the scans. (A) For relative cerebral blood flow (rCBF;  $R^2=0.84$ ), (B) for Tmax ( $R^2=0.57$ ), and (C) for mismatch ( $R^2=0.33$ ). Regression lines and 95% CI are displayed.

two owing to vessel occlusions of the posterior circulation, two because the time limit between the scans (>2 hours) was exceeded, and three patients received magnetic resonance perfusion as baseline imaging, leaving a final population of 20 (online supplemental figure III). Of these 20 patients, the majority were treated in Bern (12 patients). Baseline characteristics are shown in table 1.

#### Quantitative correlation FD-CTP versus conventional CTP

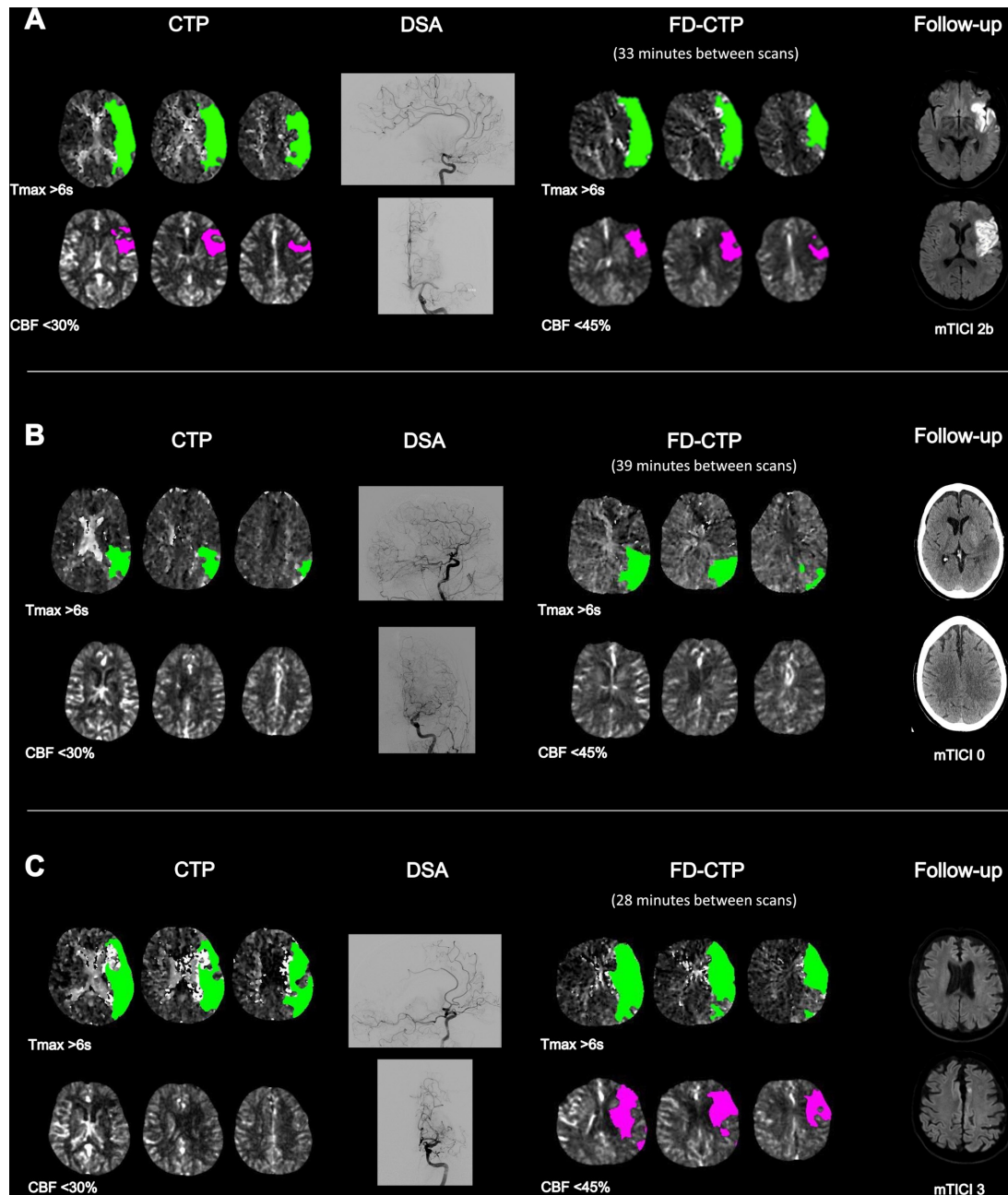
Conventional rCBF <30% and FD-CTP rCBF <45% generally showed good correlation ( $R^2=0.84$ , figure 1A). Underestimation



**Figure 2** Bland-Altman plots showing the differences in perfusion volumes obtained with conventional CT perfusion (CTP) and flat panel detector perfusion (FD-CTP) (A) for relative cerebral blood flow (rCBF), (B) for Tmax, and (C) for mismatch. The mean difference (bias, continuous line) and 95% CI of agreement (dashed lines) are displayed.

of infarct core in FD-CTP occurred in two cases and infarct core was missed in one case, all with low volumes of infarct core (<50 mL). Conventional CTP Tmax >6s versus FD-CTP Tmax >6s (figure 1B) and CTP mismatch versus FD-CTP mismatch (figure 1C) showed more variability and a lower correlation ( $R^2=0.57$ , and  $R^2=0.33$ , respectively).

Bland-Altman analysis for rCBF showed a bias of  $-11.7$  mL (95% CI  $-23.7$  to  $0.4$  mL) but had the smallest range of agreement levels of  $-62.1$  to  $38.8$  mL (figure 2A). FD-CTP Tmax >6s was also lower on average than Tmax >6s derived from CTP (bias =  $-19.5$  mL, 95% CI  $-48.7$  to  $9.7$  mL; agreement levels  $-141.8$  to  $102.8$  mL) (figure 2B). However, agreement on mismatch between the two modalities showed the smallest bias



**Figure 3** (A) M1 occlusion left, shown in the digital subtraction angiography (DSA), with corresponding hypoperfusion patterns in CT perfusion (CTP) and in flat panel detector perfusion (FD-CTP). After modified Thrombolysis in Cerebral Infarction (mTICI) 2b was achieved, the first follow-up diffusion-weighted imaging (DWI) showed infarction of the anterior portion of the left M1 territory. (B) M2 occlusion left, as shown in the DSA scan, with corresponding CTP and FD-CTP hypoperfusion patterns. Follow-up CT showed complete infarction of the affected M2 territory after mTICI 0. (C) M1 occlusion left with corresponding CTP and FD-CTP hypoperfusion patterns and corresponding capillary blush deficit in the DSA scan (28 min between scans). The increase between CTP and FD-CTP may indicate rapid infarct progression but follow-up DWI showed no infarction, probably due to rapid and complete reperfusion (mTICI 3). CBF, cerebral blood flow.

of  $-7.9$  mL (95% CI  $-36.3$  to  $20.64$  mL) and agreement levels of  $-127.2$  to  $111.5$  mL (figure 2C).

Overall, the differences in perfusion volumes between CTP and FD-CTP did not change with increasing time between the scans (online supplemental figure IV).

Based on FD-CTP, 16/20 (80%) patients met the inclusion criteria for MT according to the DEFUSE 3 perfusion criteria, in contrast to 18/20 (90%) patients based on conventional CTP. The reasons for exclusion based on FD-CTP were infarct core  $>70$  mL ( $n=3$ ) and mismatch ratio of  $<1.8$  ( $n=2$ ), and,

based on conventional CTP, infarct core  $>70$  mL ( $n=2$ ) and mismatch ratio  $<1.8$  ( $n=1$ ).

Illustrative examples are shown in figure 3.

## DISCUSSION

This exploratory study has the following main findings: (1) time-resolved whole brain FD-CTP is technically feasible, (2) overall, quantitative FD-CTP maps showed good agreement and correlated well with conventional CTP maps, and (3)

identification of MT-eligible patients according to the DEFUSE 3 criteria was feasible in most cases.

The Bland-Altman analyses showed that, on average, volumes of tissue with rCBF <45%, Tmax >6s, and mismatch were larger in FD-CTP than when derived from conventional CTP (with rCBF <30%, respectively). This could be due to measurement error or because, despite the relatively short time between the scans, infarct core and tissue with Tmax >6s tend to become larger with longer duration of vessel occlusion. Furthermore, we saw no signs of systematic errors or biases in the Bland-Altman plots as the differences showed a tendency to increase with larger average measurements (in the sense of a random relative error) and our biases were even smaller than those reported in a similar single-center study comparing rCBF and Tmax from CTP and FD-CTP.<sup>13</sup>

Although measurement of penumbra volumes showed a smaller correlation between the two scans, mismatch volume showed the smallest mean error in the Bland-Altman analyses. Also, there was agreement in every case regarding the presence or absence of a favorable mismatch profile (ie, penumbral tissue) and only a few patients who would not have been eligible for MT according to the perfusion imaging criteria of DEFUSE 3, where penumbra volume plays a key role. Furthermore, depiction of the infarct core and penumbra worked well and determination of the occlusion site was reasonably straightforward. This is particularly important from a clinical standpoint and helps in the decision-making for diagnosis and choice of therapy.

Previous work comparing conventional CTP and FD-CTP mainly examined CBV as another perfusion parameter, with values of CBV <2 mL/100 g indicating infarct core.<sup>17</sup> Fiorella *et al* reported 100% sensitivity and 81.3% specificity for detecting any CBV deficit.<sup>18</sup> Other studies reported a correlation coefficient of  $R^2=0.79$  when comparing six regions of interest (ROIs)<sup>19</sup> and  $R^2=0.85$  when comparing CBV and CBF ROIs directly in the perfusion deficit.<sup>20</sup> Immediately after MT, correlation of ROIs of FD-CTP CBV and follow-up CTP CBV was even better ( $R^2=0.9$ ).<sup>21</sup> Given that CBV can be calculated as CBF  $\times$  mean transit time<sup>22</sup> and is therefore related to CBF, our findings are in line with these results and further strengthen the viewpoint that FD-CTP is clinically applicable.

To the best of our knowledge, the present multicenter study evaluated the largest cohort to date of patients with acute ischemic stroke undergoing time-resolved whole brain FD-CTP. Our results reiterate the validity of technically adequate FD-CTP using the first commercially available software as compared with conventional CTP.

Our results also support the establishment and further evaluation of direct-to-angio approaches in everyday clinical practice, as FD-CT can produce FD-CTP as well as soft tissue brain imaging and multiphase FD-CT angiography, similar to conventional CT 'stroke protocol' sequences. This, in turn, can speed up in-hospital workflows and may ultimately increase the chances of good clinical outcome.<sup>6-11</sup> Of paramount importance to the success of the direct-to-angio workflow is the familiarity of the technical and nursing staff as well as the diagnostic neuroradiologists with the practice. Understanding how to effectively use the angiosuite as a conventional CT scanner and interpret its imaging output will be central to translating trials into improved general practice.<sup>23</sup>

The use of FD-CTP post-thrombectomy is another possible application and the next frontier where FD-CTP could add significant value. In cases of incomplete thrombectomy with residual occlusion—for example, the decision whether to perform rescue maneuvers (eg, with distal stent retrievers<sup>24 25</sup> or

administration of a thrombolytic drug<sup>26 27</sup>) or to stop, is currently open to discussion. Intraprocedural magnetic resonance may also aid in such real-time treatment decision-making,<sup>28</sup> although FD-CT is considerably simpler from a workflow standpoint. FD-CTP could delineate penumbra and infarcted tissue and help to prevent futile (no more salvageable brain tissue) or unnecessary angiographic improvement (no infarction would have developed if no rescue maneuver had been performed).<sup>29</sup>

### Limitations

We selected only patients with vessel occlusions in the intracranial internal carotid artery, M1 or M2 segments and further validation for occlusions of the posterior circulation and of peripheral occlusions is warranted. Also, our study had a relatively small sample size. To overcome these limitations, studies including larger populations would be needed. FD-CTP is derived from fewer time points than CTP and this could potentially influence the resulting perfusion calculations. Finally, all patients had recently received a bolus of intravenous contrast. One report has suggested that contemporaneous contrast administration may affect core estimation.<sup>30</sup>

### CONCLUSIONS

In our multicenter study, time-resolved whole brain FD-CTP was technically feasible, and qualitative and overall quantitative perfusion results correlated well with those obtained using conventional CTP. This suggests that establishment of a direct-to-angio approach is feasible and may increase the chances of good clinical outcome. Application of FD-CTP post-thrombectomy could be the next frontier where FD-CTP could add significant value by helping in decision-making in cases of incomplete thrombectomy.

### Author affiliations

- <sup>1</sup>Department of Diagnostic and Interventional Neuroradiology, Inselspital, University Hospital Bern, Bern, Switzerland
- <sup>2</sup>Department of Radiology and Biomedical Imaging, University California San Francisco, San Francisco, California, USA
- <sup>3</sup>Department of Neuroradiology, Clinic of Radiology and Nuclear Medicine, University Hospital Basel, Basel, Switzerland
- <sup>4</sup>Clinic of Radiology and Nuclear Medicine, Diagnostic and Interventional Neuroradiology, Kantonsspital St Gallen, St. Gallen, Switzerland
- <sup>5</sup>Department of Neurosurgery, Rush University Medical Center, Chicago, Illinois, USA
- <sup>6</sup>Department of Neurology and Neurosurgery, Stanford University, Stanford, California, USA

**Twitter** Christoph C Kurmann @chris\_kurmann

**Contributors** CCK contributed to concept and design, data acquisition, analysis and interpretation of data, and writing of the initial draft. JK and PM contributed to concept and design, data acquisition, interpretation of data, revision of the manuscript for important intellectual content, and supervision. PM acted as the guarantor. All other authors contributed to concept and design, data acquisition, interpretation of data, and revision of the manuscript for important intellectual content.

**Funding** The authors have not declared a specific grant for this research from any funding agency in the public, commercial or not-for-profit sectors.

**Competing interests** PM reports receipt of research support from Siemens, Cerenovus, Medtronic, Stryker, the Swiss Heart Foundation, and the Swiss National Foundation; receipt of consultant fees from Medtronic, Cerenovus, Phenox, and Microvention, unrelated to the submitted work. DLC reports funding by a Siemens Healthineers-Grant. MP reports research collaboration with Siemens. DKL is a member of the advisory board of Siemens and honoraria/consultant for RAPID. AI, Stryker, Medtronic, Siemens, Phenox, Asahi. He reports stock options of Three Rivers, QAPL, Methinks, Bendit, Synchron, Vastrax, NTI, VizAI, ELUM. GWA is a consultant for Gentech and is a consultant for, and has equity interests in, iSchemaView. JK reports grants from the Swiss Academy of Medical Sciences/Bangerter Foundation, Swiss Stroke Society, and Clinical Trials Unit Bern during the conduct of the study.

**Patient consent for publication** Not applicable.

**Provenance and peer review** Not commissioned; externally peer reviewed.

**Data availability statement** Data are available upon reasonable request.

**Supplemental material** This content has been supplied by the author(s). It has not been vetted by BMJ Publishing Group Limited (BMJ) and may not have been peer-reviewed. Any opinions or recommendations discussed are solely those of the author(s) and are not endorsed by BMJ. BMJ disclaims all liability and responsibility arising from any reliance placed on the content. Where the content includes any translated material, BMJ does not warrant the accuracy and reliability of the translations (including but not limited to local regulations, clinical guidelines, terminology, drug names and drug dosages), and is not responsible for any error and/or omissions arising from translation and adaptation or otherwise.

**Open access** This is an open access article distributed in accordance with the Creative Commons Attribution Non Commercial (CC BY-NC 4.0) license, which permits others to distribute, remix, adapt, build upon this work non-commercially, and license their derivative works on different terms, provided the original work is properly cited, appropriate credit is given, any changes made indicated, and the use is non-commercial. See: <http://creativecommons.org/licenses/by-nc/4.0/>.

#### ORCID iDs

Christoph C Kurmann <http://orcid.org/0000-0001-5770-5675>

Johannes Kaesmacher <http://orcid.org/0000-0002-9177-2289>

#### REFERENCES

- Becks MJ, Manniesing R, Vister J, *et al*. Brain CT perfusion improves intracranial vessel occlusion detection on CT angiography. *J Neuroradiol* 2019;46:124–9.
- Campbell BCV, Weir L, Desmond PM, *et al*. CT perfusion improves diagnostic accuracy and confidence in acute ischaemic stroke. *J Neurol Neurosurg Psychiatry* 2013;84:613–8.
- Turc G, Bhogal P, Fischer U, *et al*. European Stroke Organisation (ESO) - European Society for Minimally Invasive Neurological Therapy (ESMINT) guidelines on mechanical thrombectomy in acute ischemic stroke. *J Neurointerv Surg* 2019;neurintsurg-2018-014569.
- Ma H, Campbell BCV, Parsons MW, *et al*. Thrombolysis guided by perfusion imaging up to 9 hours after onset of stroke. *N Engl J Med* 2019;380:1795–803.
- Vagal A, Wintermark M, Nael K, *et al*. Automated CT perfusion imaging for acute ischemic stroke: pearls and pitfalls for real-world use. *Neurology* 2019;93:888–98.
- Brehm A, Tsogkas I, Maier IL, *et al*. One-stop management with perfusion for transfer patients with stroke due to a large-vessel occlusion: feasibility and effects on in-hospital times. *AJNR Am J Neuroradiol* 2019;40:1330–4.
- Psychogios M-N, Maier IL, Tsogkas I, *et al*. One-stop management of 230 consecutive acute stroke patients: report of procedural times and clinical outcome. *J Clin Med* 2019;8:2185.
- Mendez B, Requena M, Aires A, *et al*. Direct transfer to angio-suite to reduce workflow times and increase favorable clinical outcome. *Stroke* 2018;49:2723–7.
- Ribo M, Boned S, Rubiera M, *et al*. Direct transfer to angiosuite to reduce door-to-puncture time in thrombectomy for acute stroke. *J Neurointerv Surg* 2018;10:221–4.
- Sarraj A, Goyal N, Chen M, *et al*. Direct to angiography vs repeated imaging approaches in transferred patients undergoing endovascular thrombectomy. *JAMA Neurol* 2021;78:916.
- Requena M. Evaluation of direct transfer to angiography suite vs. computed tomography suite in endovascular treatment of stroke: ANGIO-CAT randomized clinical trial. *Present Int Stroke Conf* 2021:Abstract L [https://professional.heart.org/-/media/phd-files/meetings/isc/2021/science-news/isc21\\_angiocat\\_summary\\_slide.pdf?la=en](https://professional.heart.org/-/media/phd-files/meetings/isc/2021/science-news/isc21_angiocat_summary_slide.pdf?la=en)
- Stille EL, Viozzi I, Ter Laan M, *et al*. Diagnostic accuracy of flat-panel computed tomography in assessing cerebral perfusion in comparison with perfusion computed tomography and perfusion magnetic resonance: a systematic review. *Neuroradiology* 2019;61:1457–68.
- Quispe-Orozco D, Farooqui M, Zevallos C, *et al*. Angiography suite cone-beam computed tomography perfusion imaging in large-vessel occlusion patients using rapid software: a pilot study. *Stroke* 2021;52:e542–4.
- Struffert T, Deuerling-Zheng Y, Kloska S, *et al*. Dynamic angiography and perfusion imaging using flat detector CT in the angiography suite: a pilot study in patients with acute middle cerebral artery occlusions. *AJNR Am J Neuroradiol* 2015;36:1964–70.
- Albers GW, Marks MP, Kemp S, *et al*. Thrombectomy for stroke at 6 to 16 hours with selection by perfusion imaging. *N Engl J Med* 2018;378:708–18.
- R Core Team. *R: a language and environment for statistical computing*, 2019.
- Wintermark M, Flanders AE, Velthuis B, *et al*. Perfusion-CT assessment of infarct core and penumbra: receiver operating characteristic curve analysis in 130 patients suspected of acute hemispheric stroke. *Stroke* 2006;37:979–85.
- Fiorella D, Turk A, Chaudry I, *et al*. A prospective, multicenter pilot study investigating the utility of flat detector derived parenchymal blood volume maps to estimate cerebral blood volume in stroke patients. *J Neurointerv Surg* 2014;6:451–6.
- Struffert T, Deuerling-Zheng Y, Kloska S, *et al*. Cerebral blood volume imaging by flat detector computed tomography in comparison to conventional multislice perfusion CT. *Eur Radiol* 2011;21:882–9.
- Royalty K, Manhart M, Pulfer K, *et al*. C-arm CT measurement of cerebral blood volume and cerebral blood flow using a novel high-speed acquisition and a single intravenous contrast injection. *AJNR Am J Neuroradiol* 2013;34:2131–8.
- Struffert T, Deuerling-Zheng Y, Engelhorn T, *et al*. Feasibility of cerebral blood volume mapping by flat panel detector CT in the angiography suite: first experience in patients with acute middle cerebral artery occlusions. *AJNR Am J Neuroradiol* 2012;33:618–25.
- Hoeffner EG, Case I, Jain R, *et al*. Cerebral perfusion CT: technique and clinical applications. *Radiology* 2004;231:632–44.
- Pfaff JAR, Schöenberger S, Herweh C, *et al*. Direct transfer to angio-suite versus computed tomography-transit in patients receiving mechanical thrombectomy: a randomized trial. *Stroke* 2020;51:2630–8.
- Grossberg JA, Rebello LC, Haussen DC, *et al*. Beyond large vessel occlusion strokes: distal occlusion thrombectomy. *Stroke* 2018;49:1662–8.
- Kaesmacher J, Maegerlein C, Zibold F, *et al*. Improving mTICI2b reperfusion to mTICI2c/3 reperfusion: a retrospective observational study assessing technical feasibility, safety and clinical efficacy. *Eur Radiol* 2018;28:274–82.
- Anadani M, Ajinkya S, Alawieh A, *et al*. Intra-arterial tissue plasminogen activator is a safe rescue therapy with mechanical thrombectomy. *World Neurosurg* 2019;123:e604–8.
- Kaesmacher J, Kurmann C, Jungi N, *et al*. Infarct in new territory after endovascular stroke treatment: a diffusion-weighted imaging study. *Sci Rep* 2020;10:1–10.
- Narsinh KH, Kilbride BF, Mueller K, *et al*. Combined use of X-ray angiography and intraprocedural MRI enables tissue-based decision making regarding revascularization during acute ischemic stroke intervention. *Radiology* 2021;299:167–76.
- Kaesmacher J, Ospel JM, Meinel TR, *et al*. Thrombolysis in cerebral infarction 2b reperfusion: to treat or to stop? *Stroke* 2020;51:3461–71.
- Copelan AZ, Smith ER, Drocton GT, *et al*. Recent administration of iodinated contrast renders core infarct estimation inaccurate using RAPID software. *AJNR Am J Neuroradiol* 2020;41:2235–42.