

Pathophysiological Considerations in Periorbital Necrotizing Fasciitis: A Case Report

Yalda Hadizamani, Stefano Anastasi, Anouk Schori, Rudolf Lucas, Justus G. Garweg & Jürg Hamacher

To cite this article: Yalda Hadizamani, Stefano Anastasi, Anouk Schori, Rudolf Lucas, Justus G. Garweg & Jürg Hamacher (2022): Pathophysiological Considerations in Periorbital Necrotizing Fasciitis: A Case Report, Ocular Immunology and Inflammation, DOI: [10.1080/09273948.2022.2032190](https://doi.org/10.1080/09273948.2022.2032190)

To link to this article: <https://doi.org/10.1080/09273948.2022.2032190>



© 2022 The Author(s). Published with license by Taylor & Francis Group, LLC.



Published online: 11 Apr 2022.



Submit your article to this journal [↗](#)




View related articles [↗](#)



View Crossmark data [↗](#)

Pathophysiological Considerations in Periorbital Necrotizing Fasciitis: A Case Report

Yalda Hadizamani^{a,b}, Stefano Anastasi, MD^{c*}, Anouk Schori^{a,b}, Rudolf Lucas^d, Justus G. Garweg ^{e,c,*}, and Jürg Hamacher, MD^{a,b,f,g*}

^aLungen-und Atmungsstiftung Bern, Bern, Switzerland; ^bPneumology, Clinic for General Internal Medicine, Lindenhofspital Bern, Bern, Switzerland; ^cBerner Augenklinik Am Lindenhofspital, Bern, Switzerland; ^dVascular Biology Center, Medical College of Georgia, University of Augusta, Augusta, Georgia, USA; ^eDepartment of Ophthalmology, Inselspital, University of Bern, Bern, Switzerland; ^fMedical Clinic V-Pneumology, Allergology, Intensive Care Medicine and Environmental Medicine, Faculty of Medicine, Saarland University, University Medical Centre of the Saarland, Homburg, Germany; ^gInstitute for Clinical & Experimental Surgery, Faculty of Medicine, Saarland University, Homburg, Germany

ABSTRACT

Background: Periorbital necrotizing fasciitis (PNF) is a rare complication of bacterial infection, associated with irreversible inflammatory destruction of soft tissues like subcutaneous tissue and superficial fascia. PNF can cause visual loss, septic shock and death within hours to days. Since the infection progresses rapidly from a local disease to septic shock, prompt identification and decisive interventions are mandatory.

Aim: Considering pathophysiology, differential diagnosis, and treatment options, we report a case of PNF and its outcome. **Methods:** A 69 years old male with febrile periorbital swelling had been diagnosed with bilateral PNF, caused by dual infection with *Streptococcus pyogenes* (*S. pyogenes*) and *Staphylococcus aureus* (*S. aureus*) based on conjunctival swabs.

Results: The superantigens produced by *S. pyogenes* have been identified as key to the rapid dissemination of infection and severity of systemic manifestations.

Conclusions: A combination of intravenous antibiotics and regular surgical debridements resulted in a beneficial outcome in our patient.

ARTICLE HISTORY

Received 14 December 2020

Revised 12 October 2021

Accepted 26 October 2021



KEYWORDS

Periorbital necrotizing fasciitis; *Streptococcus pyogenes*; *Staphylococcus aureus*; superantigens; toxic shock syndrome; antibiotic; surgical debridement

Necrotizing fasciitis is an uncommon, severe, primarily superficial bacterial infection that rapidly spreads into the surrounding tissue, inducing extensive necrosis of the superficial fascial layers. When associated with systemic disorders, NF can be potentially lethal. If not treated quickly with antibiotics and debridement of the infected tissue, the patient may develop septic shock within hours, which can progress to multi-organ failure (MOF).^{1–4} NF can affect any part of the body, but the highest prevalence occurs in the extremities and perineum.^{5,6} NF is uncommon in the periorbital region because of its excellent blood supply.^{1,3} The specific anatomy of the eyelids and anterior orbita including the orbital septa generally usually prevents a rapid spread of infection and superficial necrosis of the skin in this region. The dermis adheres to the nasojugal fold and laterally to the cheek fold (malar fold) on the periost. Together with the musculus orbicularis oculi, it acts as an anatomical barrier toward the spread of infection into the lower regions. Once the anatomical barriers of the dermis and muscles are compromised, however, the infection may rapidly spread to the orbital apex and the throat. Periorbital NF (PNF) may cause disfigurement,^{7,8} loss of vision,^{2,3} MOF, disseminated intravascular coagulation, and death in about 6% to 15% of patients.^{2,9–12} A summary of literature review on clinical presentation and related pathophysiology of periocular or periorbital necrotizing fasciitis are presented in Table 1.

Based on the infectious agents involved, NF has been categorized into four types.²⁰ Type I is characterized by polymicrobial infections with mixed anaerobic and aerobic bacteria, including *Streptococcus* species, *Klebsiella* species (*Klebsiella pneumoniae*), *S. aureus* and *Escherichia coli*. Apart from the live pathogens, a pathogenic role has also been reported for superantigens of *S. aureus* and *S. pyogenes*.^{8,14,21} In type II a monomicrobial infection is at the source, predominantly caused by group A beta-hemolytic *Streptococcus* species, such as *S. pyogenes* and either accompanied or not by *S. aureus*.¹⁴ Methicillin-resistant *S. aureus* (MRSA) has been reported in the same category.¹⁴ The rare type III is caused by exposure to marine Gram-negative pathogens, like *Vibrio vulnificus* or *Aeromonas hydrophila*^{5,14,20} and *Clostridium* species.⁷ Type IV is linked to fungi like *Apophysomyces* (Mucorales) and *Aspergillus* species.^{22,23} So far, types I, II and IV have been documented in periorbital necrotizing fasciitis.^{2,7,11,24}

Due to the high potential of this infection to cause irreversible destruction in a short time, rapid diagnosis and treatment, based on the knowledge of the etiological agents involved and their influence on the host's immune defense are mandatory. Based on a case of periorbital necrotizing fasciitis with the contribution of a superantigen-producing *S. pyogenes* in our clinics, we provide a review of the literature including differential diagnostic considerations and a treatment approach based on the pathophysiology of the infection.

CONTACT Jürg Hamacher  hamacher@greenmail.ch  Lindenhofspital Bern, Bremgartenstrasse 119, Bern CH-3012, Switzerland.

*These authors contributed equally to this work and therefore share the first authorship.

© 2022 The Author(s). Published with license by Taylor & Francis Group, LLC.

This is an Open Access article distributed under the terms of the Creative Commons Attribution-NonCommercial-NoDerivatives License (<http://creativecommons.org/licenses/by-nc-nd/4.0/>), which permits non-commercial re-use, distribution, and reproduction in any medium, provided the original work is properly cited, and is not altered, transformed, or built upon in any way.

Table 1. Clinical presentation and related pathophysiology of periocular and periorbital necrotizing fasciitis.

Feature or clinical presentation	Pathogenic mechanisms and clinical context
Compromised skin integrity	Inoculation (local angiothrombotic bacterial invasion) especially in immunocompromised hosts. ^{7,13}
Local tissue necrosis Need of combination of therapy with high levels of antibiotics and surgical debridement	Bacterial proliferation and release of bacterial toxins, superantigens, etc. leads to the secretion of local cytokines and activation of platelets, which triggers inflammatory response including activation and diapedesis of white cells, while platelet clumps lead to microvascular occlusion. ¹³ A huge amount of cutaneous blood vessels and lymphatic channels undergo thrombosis. ¹³ Local hypoxia and local inflammatory mediators including TNF, interleukin-6 and Interleukin-8 are released, causing cellular dysfunction and cell death leading to bullae and extended tissue necrosis. ¹³ In diagnostic uncertainty, such tissue necrosis can be shown by biopsy with frozen section emergency work-up. The very limited local perfusion and extensive necrosis impede a high antibiotic tissular drug level, making surgical debridement as additional infection limiting therapy mandatory. ^{12,14}
Infectious spread in the surrounding tissue as a rather anatomically distinct small-volume space-immune evasive bacterial effects	An anatomically rather confined space, typically rather frequently allowing an infectious spread to the contralateral periorbital space Break of the anatomical barriers of the dermis and muscles and bacterial spread into to surrounding tissues. ³ Rapid thrombosis of local vasculature causes a lack of vascular/lymphatic spread that leads to the horizontal spread of infection. ¹³ Immune evasive mechanisms of bacterial structures and toxins with neutrophils including mediators and chemokines, and lymphocytes. ¹⁵⁻¹⁷
Lid edema, severe pain disproportionate to the apparent area involved erythema and raised temperature	Continuous local necrotizing infection maintaining mediators of local inflammation Consecutive whole-body inflammation leading to systemic inflammatory response syndrome, possibly to sepsis or septic shock. ^{7,13} Swollen eyelids usually impede visual orientation, thus predispose to delirium in the context of severe inflammation
Periocular skin necrosis and visual loss	Necrosis develops as a consequence of pathogenic invasion and polymorphonuclear leukocyte infiltration leading to vascular thrombosis and ischemia with subsequent gangrene of the subcutaneous fat and dermis resulting in severe ocular surface disease. ⁷
Multiorgan involvement with potential multiorgan failures, however with better overall outcome than at most other anatomic sites	Systemic mediators may lead to septic shock with its inherent prognosis ⁷ ; generally high serum interleukin-6, Granulocyte colony-stimulating factor (G-CSF) and the inflammatory alarmin protein S100A8 seem associated with disease severity ^{18,19} and interleukin-1 β with mortality. ¹⁸ Better overall prognosis of periorbital necrotizing fasciitis if compared to most other necrotizing fasciitis, Hypotheses: sites predispose to better outcome possibly due to a) small, rather confined infected and necrotic anatomical site and b) due to rather high and therefore potentially early nociception by the locally high sensible nervous supply of the orbital region.

A 69-year-old male patient with rapidly increasing eyelid edema on both sides and in critical general condition presented to the hospital's emergency department. A history of wasp venom allergy with a pronounced local reaction, urticaria and photodermatitis were known. Initially, steroids and antihistamines were administered because of a suspected diagnosis of angioedema under treatment of an angiotensin-converting enzyme inhibitor for arterial hypertension. The patient is a smoker with a history of alcohol abuse. His medical history includes a COPD GOLD II and diabetes mellitus type II treated since about 5 years with lifestyle modification and metformin, and in addition, he suffers from chronic rhinitis and rosacea.

Antibiotic therapy was initiated a few hours after admission due to septic signs that occurred, including tachycardia, fever, confusion, a C-reactive protein (CRP) level of 157 mg/l (normal <5), a leukocytosis of 24.8 x10⁹/l (normal <10), creatinine of 58 μ mol/l and a blood glucose of 11.7 mmol/l. Based on progressive inflammatory signs, the diagnosis of PFN was suspected, and microbiological swabs from the eyelid region was obtained before treatment with meropenem and clarithromycin was initiated. The antibiotics were selected according to the differential diagnosis of sepsis and pneumonia, and supplemented by intravenous acyclovir because of herpesvirus

infection including encephalitis in the differential diagnosis. Computer tomography excluded any cerebral affection, orbital phlegmon, sinusitis or sinus vein thrombosis.

Despite these measures, the local orbital condition worsened within hours with increasing edema of both eyelids, skin blushing and the formation of blisters and purulent secretions along with necrotic spots on both upper and lower eyelids. A severe four-day continuous delirium developed, possibly aggravated in the context of blinding due to the progressive swelling with complete occlusion of the eyelids. *S. aureus* and a superantigen-producing *S. pyogenes* were grown from the conjunctival swab. After 5 days, debridement of necroses was initiated on a daily to bi-daily basis until day 10 after hospitalization. The patient was slowly recovering and was discharged after 15 days of hospitalization. As illustrated in [Figure 1](#), the eyelid area recovered without the need for primary skin grafts. In the following months, relevant scarring of the lids was unpreventable, resulting in lid malposition with brow ptosis, upper lid dermatochalasis and inferior lid ectropium that became a functional and cosmetic issue for the patient. Secondary surgical correction of the eyelids was performed in two stages: first, a direct brow lift with upper lid blepharoplasty and lateral tarsal strip was performed to restore

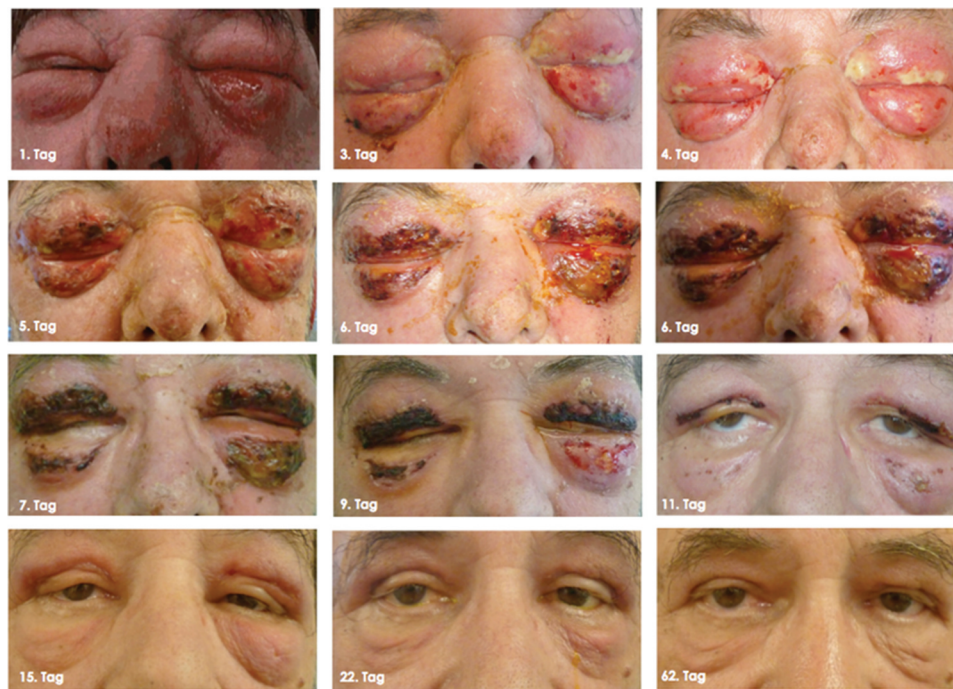

Figure 1. Evolution of the local findings overtime.

the upper lid. Later a resection of the malar festoons and scarring tissue restored the normal appearance of the inferior lid.

Discussion

As our case indicates, the differential diagnosis of NF with its rapid periorbital spread is of considerable importance because regular surgical debridement on top of an antibiotic treatment strategy are crucial to ultimately achieve a satisfying outcome. Even after a supportive early control of infection, tissue response to the severe destructive process may require secondary interventions to correct functional anatomic changes during the healing process. From the clinical perspective, the diagnosis of PNF is a challenge, since there are several medical conditions with similar early presentations. As such, ophthalmic zoster must be excluded in the early stages. As the infection progresses, other less common differential diagnoses, including vasculitis of Wegener's granulomatosis type, erysipelas, Quincke's edema to preseptal cellulitis, and other inflammatory disorders affecting the lids and orbit have to be considered. Generally, acute fulminant skin infection and pyoderma gangraenosum, as well as other infectious etiologies, including orbital cellulitis, staphylogenic Lyell syndrome, endogenous endophthalmitis, cavernous sinus thrombosis, and rhino-orbital mucormycosis, have to be excluded.^{2,25,26} Beyond the most important differences between NF of the periorbital region and other parts of the body is the frequently bilateral occurrence in the periorbital region.^{2,3,5,9} Despite rigid anatomical barriers, pathogens frequently seem to spread across the nasal bridge to the contralateral eyelids, which may best explain the frequent bilateral occurrence of PNF.⁹

As such the proper diagnosis of PNF is generally not primarily established, as was the case with our patient. A delayed diagnosis may add to a systemic bacterial spread and septicemia, that may lead to multi-organ failure and increase mortality rates to 30%–70%.²⁷ The high mortality is, among other factors, associated with the production of bacterial toxins, including Streptococcal superantigens, which were detected in our patient's case. Not surprisingly, a correct early diagnosis and subsequent early start of a proper antibiotic and debridement therapy can significantly reduce morbidity and fatality.²⁰

That the diagnosis was initially missed triggered us to revise and communicate the current knowledge of pathophysiology and clinical presentation of PNF. Mechanical damage to the skin as entry path is considered the most frequent cause of PNF,³ though not reported in our case. After penetrating the dermis, the pathogens release their exotoxins, which fosters their rapid spread into the systemic circulation.^{28–30} Group A beta-hemolytic *Streptococcus* and *S. aureus* are the most important causes of PNF.^{3,31,32} Both pathogens express highly immunogenic surface proteins. These virulence factors, such as Group A streptococcal M1 as a neutrophil, monocyte and T cell activator, and M3, both offering protection against phagocytosis, the superantigens like exotoxin A and C, the cell pore forming streptolysin O that may lead neutrophils, macrophages and epithelial cells to apoptosis,^{33,34} substantially contribute to the immunopathogenesis of the invasive disease.²⁸ Regular microbial antigens are phagocytized by antigen-presenting cells such as B lymphocytes, upon which their peptide fragments are presented to T cells using MHC Class II.³⁵ Upon detection by T cell receptors, a specific immune response is mounted to the peptide antigen.³⁵ By contrast, superantigens, non-glycosylated low-molecular weight bacterial proteins resistant to heat, proteolysis and acid denaturation,³⁷ bind in parallel to MHC class II and T cell receptor, resulting, even at low superantigen

concentrations, in a fast and exaggerated release of pro-inflammatory cytokines such as interleukin(IL)-1 β , IL-2, tumor necrosis factor and interferon- γ .^{36,36} Accordingly, antigen presentation is widely switched off, whereas an unspecific, but more aggressive immune response is triggered by unspecific T lymphocytes before a specific immune response by recruiting antigen-specific T cells is mounted.^{25,38} The superantigens are moreover powerful activators of the complement cascade, the bradykinin-kallikrein system, and the coagulation cascade, which leads to thrombosis of the small vessels and contributes to tissue ischemia and necrosis.³⁹ Streptococcal and staphylococcal superantigens are also capable to induce toxic shock syndromes. This non-specific manifestation in the whole body, independently of the location of the infection, is the result of a local depression of the neutrophil granulocytes and thus of the local signs and symptoms at the site of the infection. Staphylococcus-induced toxic shock syndrome is typically associated with fever, vomiting, diarrhea, flu-like symptoms such as headache, difficulty in swallowing and sore throat, as well as confusion and somnolence in younger patients.⁴⁰ Other factors that add to the fulminant course of NF include the initial rapid degradation of pro-inflammatory chemokines like IL-8 by bacterial proteases, which blunts the subsequent recruitment of neutrophils, necessary to mount an efficient anti-bacterial response.⁴¹

These microenvironmental effects well explain the negative impact on the physiological antibacterial defense mechanisms and the insufficient penetration of antibiotics into the affected tissue,³⁹ which facilitates bacterial colonization at an early stage of infection.⁴²

Accordingly, debridement is essential in the treatment of NF, as antibiotics do not reach effective concentrations in the necrotic tissues,¹⁴ while surgical debridement of the necrotic areas effectively decreases the bacterial load.¹²

Risk factors increasing susceptibility to develop NF include diabetes mellitus, chronic renal failure, cardiovascular disease, drug abuse and alcoholism.^{2,3,8,43,44} The patient's general condition, risk factors and underlying comorbidities as well as pathogenic virulence factors determine the outcome of NF. Around 45% of patients with arterial hypotension and streptococcal-induced toxic shock syndrome develop acute respiratory distress syndrome.⁴⁵ Morbidity and mortality of the *Streptococcus*-induced toxic shock syndrome are higher than for the *Staphylococcus*-induced toxic shock syndrome and are in a range of 30–80%.^{45,46} Patients who have neutralizing antibodies against superantigens are less likely to develop NF.³⁷ If superantigens however enter the bloodstream of patients devoid of neutralizing antibodies from previous exposures, they can trigger a sudden, significant and non-specific T cell stimulation and consequently a cytokine storm,³⁷ resulting in systemic toxicity, multi-organ failure and septic shock.^{38,47} The *Streptococcus*-induced toxic shock syndrome can present with locally invasive *Streptococcal* infections such as pharyngitis or more violent diffuse disorders like arthritis, bacteremia, endocarditis, meningitis, pneumonia, sinusitis, cellulitis, myositis and necrotizing fasciitis.⁴⁸

Our patient ultimately experienced a favorable outcome of his bilateral PNF though this was initially misdiagnosed as angioedema. The rapid clinical evolution allowed to exclude most differential diagnoses and recognize the underlying

infectious etiology, triggering a multidisciplinary approach with antibiotics and repeated debridement, followed by a plastic surgical reconstruction of the eyelids to achieve a virtually complete anatomic recovery. In a similar case reported by Leonardo *et al.* the patient's primary symptoms were bilateral acute painful swelling and redness of the eyelids.³² PNF due to group A *Streptococcus* was diagnosed,³² but a determination of superantigens was not reported. Similar to our case, intravenous antibiotic treatment and surgical debridement of the necrotic tissue resulted in a successful outcome.³² Another case of methicillin-resistant *S. aureus* (MRSA)-associated PNF was reported by Cameron *et al.*⁴⁹ primarily presenting with left eye and nostril redness and swelling after opening of a small nasal skin abscess a few days before.⁴⁹ Despite a timely diagnosis of facial cellulitis antibiotic therapy, the situation worsened with bilateral leg pain and redness, and shortness of breath progressing to pneumonia, sepsis and bilateral thigh cellulitis.⁴⁹ Finally, MRSA was recovered from blood cultures and treatment changed to meropenem, vancomycin and clindamycin.⁴⁹ Though an indurated swelling, but no crepitus or necrosis were present⁴⁹ surgical exploration and debridement of the face and thighs were implemented along with wound monitoring on a daily basis until the wounds were clean. This case highlights the importance of imaging, rigorous exploration of the tissue and regular debridement of necrotic tissue.⁴⁹

Surgical removal of the infected or damaged tissue limits the spread of the infection and enables to maintain a maximal amount of tissue. This facilitates local healing and thus maintains the highest amount of neighboring healthy tissue. In such a case, the affected areas should initially be inspected and probably debrided at least every 1–2 days until no more necrotic tissue can be found.²⁰ In conjunction with surgical and antibiotic therapy, hyperbaric oxygenation and intravenous gamma globulins have been suggested in specifically severe instances.^{50,51} The latter has also been discussed with the aim of neutralizing extracellular toxins.^{20,22,52} The effectiveness of both, hyperbaric oxygenation and intravenous immunoglobulins has been suggested, but also due to missing randomized studies in a rather infrequent disease, not been clearly demonstrated.^{53,54}

A limitation of the current study is that microbiological analysis was only performed from a conjunctival swab, but not from the necrotic tissue. As such, histological investigations have not been accomplished. Both analyses are not considered specific standards of care. Whether they might foster a better understanding of this severe infection remains to be investigated.

In conclusion, early establishment of an aggressive antibiotic and debridement therapy, driven by the pathophysiological observation of a severe inflammatory and ischemic tissue destruction reduce morbidity and mortality in PNF and serve the basis for a functionally and anatomically satisfying outcome of this infection.

Acknowledgments

The authors are indebtedly grateful to Dr. phil. II Angelika Ströhle, MCL, Niederwangen, Switzerland, and M.P.G. van der Linden, PhD, German National Reference Center for Streptococci, Department of Medical Microbiology, University Hospital RWTH Aachen, Germany, for their

support with identification of the pathogens and the efforts in identifying the superantigens of *S. pyogenes* contributing to the severity of this case and for critical reading and commenting on this manuscript which clearly contributed to the quality of this manuscript.

Disclosure statement

No potential conflict of interest was reported by the author(s).

Funding

The work was supported from the Lungen- und Atmungsstiftung Bern to YH. The work was further supported by a grant from the Stiftung Lindenhof Bern (13-09-F) to JH.

ORCID

Justus G. Garweg  <http://orcid.org/0000-0003-3973-5082>

References

- Shindo ML, Nalbone VP, Dougherty WR. Necrotizing fasciitis of the face. *Laryngoscope*. 1997;107:1071–1079. doi:10.1097/00005537-199708000-00013.
- Lazzeri D, Lazzeri S, Figus M, et al. Periorbital necrotizing fasciitis. *Br J Ophthalmol*. 2010;94:1577–1585. doi:10.1136/bjo.2009.167486.
- Amrith S, Hosdurga Pai V, Ling WW. Periorbital necrotizing fasciitis – a review. *Acta Ophthalmol*. 2013;91:596–603. doi:10.1111/j.1755-3768.2012.02420.x.
- Chou PY, Hsieh YH, Lin CH. Necrotizing fasciitis of the entire head and neck: literature review and case report. *Biomed J*. 2020;43:94–98. doi:10.1016/j.bj.2019.08.002.
- Pasternack MS, Schwartz MN. *Skin and Soft Tissues Infections*. Aus Madnell, Douglas and Benett's Principles and Practice of Infectious Diseases. 8th ed. 2015.
- Tong Y-T, Mak M-S, Ho H-C, Poon T-L, Mak Y-W, Choi W-K. Necrotizing fasciitis of bilateral eyelids: a case report and review of the literature. *Surg Pract*. 2019;23:117–120. doi:10.1111/1744-1633.12381.
- Eiben P, Rodriguez-Villar S. A case of periorbital necrotizing fasciitis rapidly progressing to severe multiorgan failure. *J Surg Case Rep*. 2018;2018:rjy083. doi:10.1093/jscr/rjy083.
- Sud R, Sharma P, Garg G, Takkar B, Khanduja S. Periorbital necrotizing fasciitis due to klebsiella pneumoniae in an immunocompetent patient. *Indian J Ophthalmol*. 2019;67:1721–1722. doi:10.4103/ijo.IJO_360_19.
- Elnor VM, Demirci H, Nerad JA, Hassan AS. Periocular necrotizing fasciitis with visual loss pathogenesis and treatment. *Ophthalmology*. 2006;113:2338–2345. doi:10.1016/j.ophtha.2006.06.037.
- Kronish JW, McLeish WM. Eyelid necrosis and periorbital necrotizing fasciitis. Report of a case and review of the literature. *Ophthalmology*. 1991;98:92–98. doi:10.1016/s0161-6420(91)32334-0.
- Deneubourg DL, Catherine Z, Lejuste P, Breton P. Periorbital necrotizing fasciitis induced by streptococcus pyogenes: a case report and clarification. *J Oral Maxillofacial Surg*. 2018;76:154.e151–154.e155. doi:10.1016/j.joms.2017.09.004.
- Nadal J, Galatoire O, Laouar K, et al. Periorbital necrotizing fasciitis without initial trauma: a rare case report. *J Francais D'ophtalmologie*. 2019;42:e209–e211. doi:10.1016/j.jfo.2018.09.022.
- Harrison WD, Kapoor B. Necrotizing soft tissue infection: principles of diagnosis and management. *Orthop Trauma*. 2016;30:223–231. doi:10.1016/j.morth.2016.05.001.
- Sarani B, Strong M, Pascual J, Schwab CW. Necrotizing fasciitis: current concepts and review of the literature. *J Am Coll Surg*. 2009;208:279–288. doi:10.1016/j.jamcollsurg.2008.10.032.
- Liu M, Lei B. Pathogenesis of hypervirulent group a streptococcus. *Jpn J Med*. 2018;1:269–275. doi:10.31488/jjm.1000127.
- Würtz NS, Mikkelsen LH, Jørgensen JS, et al. Periocular necrotizing soft tissue infection in greater Copenhagen. *Acta Ophthalmol*. 2020;98:207–212. doi:10.1111/aos.14205.
- Anand A, Sharma A, Ravins M, et al. Unfolded protein response inhibitors cure group a streptococcal necrotizing fasciitis by modulating host asparagine. *Sci Transl Med*. 2021;13. doi:10.1126/scitranslmed.abd7465.
- Hansen MB, Rasmussen LS, Svensson M, et al. Association between cytokine response, the Irinec score and outcome in patients with necrotising soft tissue infection: a multicentre, prospective study. *Sci Rep*. 2017;7:42179. doi:10.1038/srep42179.
- Palma Medina LM, Rath E, Jahagirdar S, et al. Discriminatory plasma biomarkers predict specific clinical phenotypes of necrotizing soft-tissue infections. *J Clin Invest*. 2021;131. doi:10.1172/jci149523.
- Stevens DL, Bryant AE. Necrotizing soft-tissue infections. *N Engl J Med*. 2017;377:2253–2265. doi:10.1056/NEJMra1600673.
- Ting CF, Lam J, Anastas C. Subgaleal haematoma as a cause of periorbital necrotising fasciitis: a case report. *Orbit*. 2020;39:143–146. doi:10.1080/01676830.2019.1606834.
- Herr M, Grabein B, Palm HG, et al. Nekrotisierende fasziitis. *Unfallchirurg*. 2011;114:197–216. doi:10.1007/s00113-010-1893-6.
- Chander J, Stchigel AM, Alastruey-Izquierdo A, et al. Fungal necrotizing fasciitis, an emerging infectious disease caused by apophysomyces (mucorales). *Revista iberoamericana de micología*. 2015;32:93–98. doi:10.1016/j.riam.2014.06.005.
- Abdul Kadir N, Ahmad SS, Abdul Ghani S, Paramananda M. A case of acute periorbital necrotizing fasciitis. *J Acute Dis*. 2016;5:174–176. doi:10.1016/j.joad.2015.10.005.
- Sachsenweger M. *Augenheilkunde*. Thiemen Verlag; 2003:16–27, 60–64.
- Jensen SL, Amato JE, Hartstein ME, Breer WA. Bilateral periorbital necrotizing fasciitis. *Arch Dermatol*. 2004;140:664–666. doi:10.1001/archderm.140.6.664.
- Stevens DL. Streptococci and enterococci. In: *Oxford Textbook of Medicine*. 5th ed. 2005:671–674.
- Commons RJ, Smeesters PR, Proft T, Fraser JD, Robins-Browne R, Curtis N. Streptococcal superantigens: categorization and clinical associations. *Trends Mol Med*. 2014;20:48–62. doi:10.1016/j.molmed.2013.10.004.
- Proft T, Fraser JD. Streptococcal superantigens: biological properties and potential role in disease. In: Ferretti JJ, Stevens DL, Va F, eds. *Streptococcus Pyogenes: Basic Biology to Clinical Manifestations*. Oklahoma City: University of Oklahoma Health Sciences Center; 2016 Feb 10. <https://www.ncbi.nlm.nih.gov/books/NBK333435/>. [Internet].
- King P. Haemophilus influenzae and the lung (haemophilus and the lung). *Clin Transl Med*. 2012;1:10. doi:10.1186/2001-1326-1-10.
- McCabe Ga, Hardy T, Campbell TG. Bilateral periorbital necrotising fasciitis associated with invasive group: a Streptococcus infection. *BMJ Case Rep*. 2020;13:e236800. doi:10.1136/bcr-2020-236800.
- Leonardo FHL, Anabuki M, Gonçalves ACP. Bilateral periorbital necrotizing fasciitis: case report. *Arq Bras Oftalmol*. 2018;81:239–241. doi:10.5935/0004-2749.20180047.
- Humar D, Datta V, Bast DJ, Beall B, De Azavedo JC, Nizet V. Streptolysin s and necrotising infections produced by group g streptococcus. *Lancet*. 2002;359:124–129. doi:10.1016/s0140-6736(02)07371-3.
- Shumba P, Mairpady Shambat S, Siemens N. The role of streptococcal and staphylococcal exotoxins and proteases in human necrotizing soft tissue infections. *Toxins (Basel)*. 2019;11:332. doi:10.3390/toxins11060332.
- Mantegazza AR, Magalhaes JG, Amigorena S, Marks MS. Presentation of phagocytosed antigens by mhc class i and ii. *Traffic*. 2013;14:135–152. doi:10.1111/tra.12026.
- Spaulding AR, Salgado-Pabón W, Kohler PL, Horswill AR, Leung DYM, and Schlievert PM. Staphylococcal and streptococcal superantigen exotoxins. *Clin Microbiol Rev*. 2013;26:422. doi:10.1128/CMR.00104-12.

37. Muldrew KL, Simpson JF, Stratton CW, Tang YW. Molecular diagnosis of necrotizing fasciitis by 16s rRNA gene sequencing and superantigen gene detection. *J Mol Diagn.* 2005;7:641–645. doi:10.1016/s1525-1578(10)60599-5.
38. Fraser JD. Clarifying the mechanism of superantigen toxicity. *PLoS Biol.* 2011;9:e1001145. doi:10.1371/journal.pbio.1001145.
39. Salcido RS. Necrotizing fasciitis: reviewing the causes and treatment strategies. *Adv Skin Wound Care.* 2007;20:288–293; quiz 294–285. doi:10.1097/01.ASW.0000269317.76380.3b.
40. Quach GT, Frisby J, Kralovich K, Bohra M. First necrotizing fasciitis caused by haemophilus influenza serotype a. *J Investig Med High Impact Case Rep.* 2017;5:2324709617736791. doi:10.1177/2324709617736791.
41. Hidalgo-Grass C, Dan-Goor M, Maly A, et al. Effect of a bacterial pheromone peptide on host chemokine degradation in group a streptococcal necrotising soft-tissue infections. *Lancet.* 2004;363:696–703. doi:10.1016/s0140-6736(04)15643-2.
42. Siemens N, Norrby-Teglund A. Shocking superantigens promote establishment of bacterial infection. *Proc National Acad Sci.* 2017;201713451. doi:10.1073/pnas.1713451114.
43. Hasham S, Matteucci P, Stanley PR, Hart NB. Necrotising fasciitis. *BMJ.* 2005;330:830–833. doi:10.1136/bmj.330.7495.830.
44. Pal B, Evans S, Walters RF. Necrotising fasciitis of the periorbital region. *Eye.* 2001;15:676–677. doi:10.1038/eye.2001.216.
45. Lappin E, Ferguson AJ. Gram-positive toxic shock syndromes. *Lancet Infect Dis.* 2009;9:281–290. doi:10.1016/s1473-3099(09)70066-0.
46. Gottlieb M, Long B, Koyfman A. The evaluation and management of toxic shock syndrome in the emergency department: a review of the literature. *J Emerg Med.* 2018;54:807–814. doi:10.1016/j.jemermed.2017.12.048.
47. Walker MJ, Barnett TC, McArthur JD, et al. Disease manifestations and pathogenic mechanisms of group a streptococcus. *Clin Microbiol Rev.* 2014;27:264–301. doi:10.1128/cmr.00101-13.
48. Stevens D, Bryant A. Severe group a streptococcal infections. In: Ferretti JJ, Fischetti VA, eds. *Streptococcus Pyogenes: Basic Biology to Clinical Manifestations.* Oklahoma City: University of Oklahoma Health Sciences Center; 2016.
49. Cameron CA, Juniat V, Pyragius M, Selva D. Conservative management of periorbital necrotizing fasciitis caused by methicillin-resistance staphylococcus aureus. *Can J Ophthalmol. Journal canadien d'ophtalmologie.* 2021;56:e86–e88. doi:10.1016/j.jcjo.2020.10.011.
50. Singam NV, Rusia D, Prakash R. An eye popping case of orbital necrotizing fasciitis treated with antibiotics, surgery, and hyperbaric oxygen therapy. *Am J Case Rep.* 2017;18:329–333. doi:10.12659/ajcr.902535.
51. Krenk L, Nielsen HU, Christensen ME. Necrotizing fasciitis in the head and neck region: an analysis of standard treatment effectiveness. *Euro Arch Oto-rhino-laryngol.* 2007;264:917–922. doi:10.1007/s00405-007-0275-3.
52. Raithatha AH, Bryden DC. Use of intravenous immunoglobulin therapy in the treatment of septic shock, in particular severe invasive group a streptococcal disease. *Indian J Crit Care Med.* 2012;16:37–40. doi:10.4103/0972-5229.94433.
53. Bruun T, Rath E, Oppegaard O, Skrede S. Beta-hemolytic streptococci and necrotizing soft tissue infections. *Adv Exp Med Biol.* 2020;1294:73–86. doi:10.1007/978-3-030-57616-5_6.
54. Soh CR, Pietrobon R, Freiburger JJ, et al. Hyperbaric oxygen therapy in necrotising soft tissue infections: a study of patients in the United States nationwide inpatient sample. *Intensive Care Med.* 2012;38:1143–1151. doi:10.1007/s00134-012-2558-4.