



Video-Clinical Corners

Frequent, complex and vivid dream-like/hallucinatory experiences during NREM sleep parasomnia episodes



Anna Castelnovo ^{a, b, c, *}, Giuseppe Loddo ^d, Federica Provini ^{e, f}, Mauro Manconi ^{a, b, g}

^a Sleep Medicine Unit, Neurocenter of Southern Switzerland, Ospedale Civico, Lugano, Switzerland

^b Faculty of Biomedical Sciences, Università Della Svizzera Italiana, Lugano, Switzerland

^c University Hospital of Psychiatry, University of Bern, Bern, Switzerland

^d Azienda USL di Bologna, Bologna, Italy

^e Department of Biomedical and Neuromotor Sciences, University of Bologna, Bologna, Italy

^f IRCSS Istituto Delle Scienze Neurologiche di Bologna, Bologna, Italy

^g Department of Neurology, University Hospital, Inselspital, Bern, Switzerland

ARTICLE INFO

Article history:

Received 3 November 2020

Received in revised form

20 January 2021

Accepted 6 March 2021

Available online 2 April 2021

Keywords:

NREM sleep Parasomnias

Disorders of arousal

Dreams

Consciousness

Night terrors

Somnambulism

1. Introduction

It is known from previous systematic studies and case reports [1–5] that adults with NREM parasomnia can have dreams associated with their episodes, usually shorter and more fragmentary than RBD dreams. We report the case of an adult young man with a long history of sleepwalking, who was able to recollect an extraordinary amount of long, vivid and complex dreams composed of multiple visual scenes that matched both the reports by his bed-partner and home-camera recordings. Such prolonged and intense dreams have been rarely described during NREM sleep parasomnia episodes [6–11].

* Corresponding author. Sleep Medicine Unit, Neurocenter of Southern Switzerland, Ospedale Civico, Via Tesserete 46, 6900, Lugano, Switzerland.

E-mail address: anna.castelnovo@eoc.ch (A. Castelnovo).

2. Case description

A 28-year-old Caucasian right-handed male, with a positive family history for disorders of arousal, experienced sleepwalking, sleep terrors and confusional arousals since childhood. At the time of his first evaluation at our sleep center he reported several episodes per week, up to 3 times per night, usually occurring between 0.5 and 3 hours after sleep onset. According to his bed-partner, friends and family members, during his more complex episodes he used to stand up abruptly and leap outside the bed, running or wandering around the house quietly, with a vacant expression, performing complex behaviors like feeding the cat or doing the laundry. More frequently, he just sat on the bed yelling (or rarely laughing) or looking around mumbling unintelligible words, and/or pointing to non-existing objects (Fig. 1). The sleep interview did not reveal any precipitating factor, except for a slightly irregular sleep-wake schedule. His medical and psychiatric interview, neurologic examination, routine blood test and brain magnetic resonance were unremarkable. Two in-lab full-montage (10–20 system) video-polysomnographies (v-PSG) showed normal sleep architecture, no other sleep disorders or EEG abnormalities and captured 3 IB-type events [12] (Fig. 2).

He never hurt himself or others, and he did not feel psychologically upset, ashamed or worried about his nocturnal behaviors and considered his condition benign. He therefore refused any pharmacological treatment. However, he recognized he disrupted his girlfriend's sleep and he felt sleepier the day after a night with many episodes compared to “episode-free” nights. The patient often woke up at the end of his major episodes and almost invariably recollected mental imageries connected to his behaviors. He called them “dreams”, as they completely resembled his normal dreams. He was able to distinguish between acted and not acted dreams just when he woke up sitting in bed or out of the bed. The great majority of these “dreams” had a negative/threatening content (about 80%), while a minority were neutral or positive. Recurrent characters of his dreams were thieves or men without




Fig. 1. **A)** During this episode the patient sat on the bed staring at an inexistent presence or object with a scared expression. **B)** During this episode the patient laughed and displayed positive emotions; **C)** During this episode, the patient stared and pointed towards an invisible object in the room with his finger, as if hallucinated. All these pictures are taken from home video-recordings brought by the patient at his first visit).

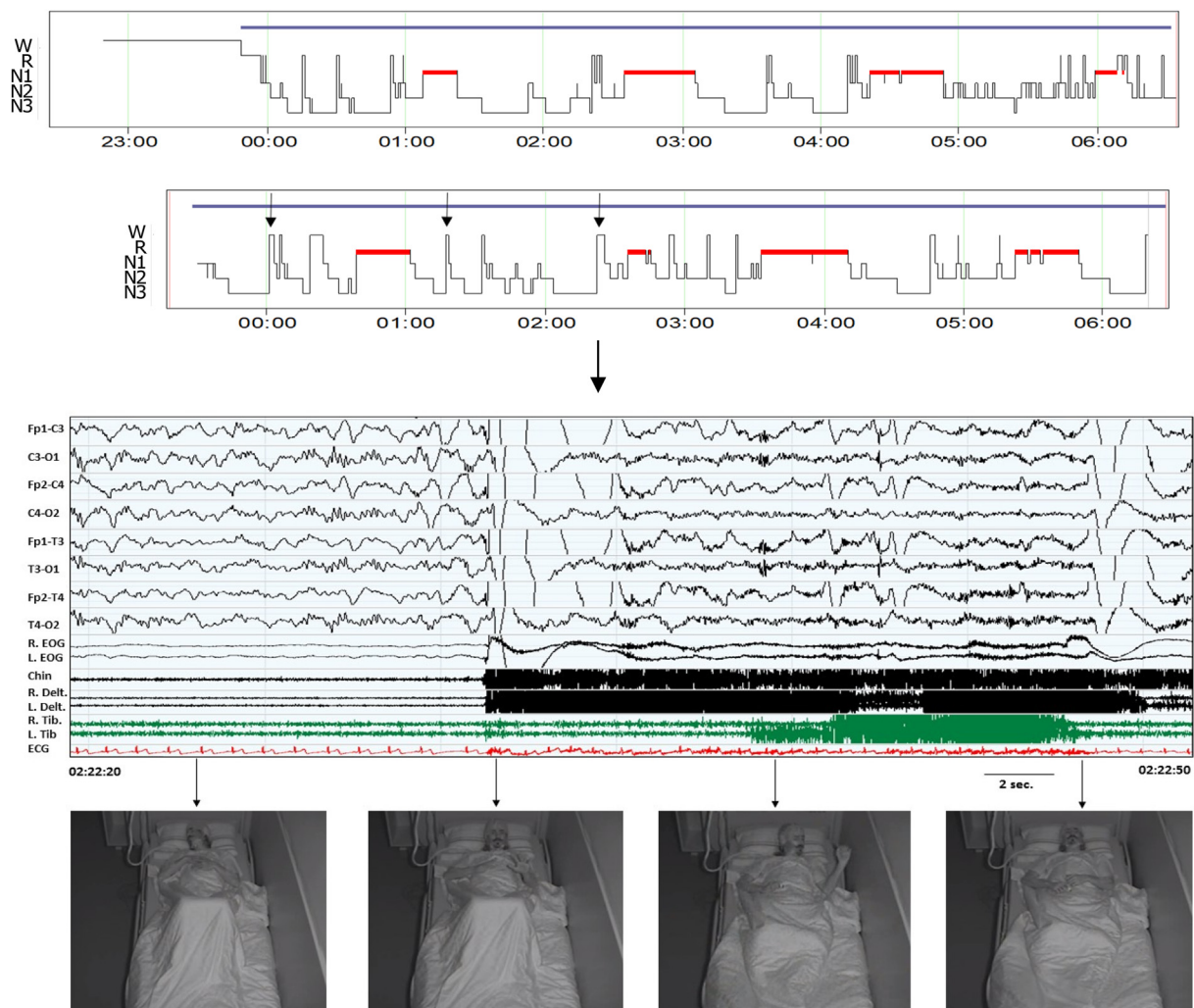


Fig. 2. Upper panel: Hypnograms of the first and second PSG nights. Black arrows indicate minor NREM sleep parasomnia episodes. The blue lines at the top of each hypnogram represent the time in bed period (from lights off to lights on). The x-axis represents time expressed in hours. Y-axis represents sleep stages: W = wakefulness, N1 = NREM sleep stage 1, N2 = NREM sleep stage 2, N3 = NREM sleep stage 3, R = REM sleep. Sleep architecture was preserved on both nights (N1 = 12% and 10%, N2 = 39% and 39%, N3 = 26% and 26%, REM = 23% and 25%, sleep efficiency = 94% and 93%, REM sleep latency = 70 and 69 min - in the first and night, respectively), but characterized by several abrupt awakenings out of NREM sleep (21 and 12 awakenings - with and arousal index (AI) of 13.6 and 11.5 - in the first and night, respectively). Central panel: 30 s-epoch of the v-PSG during a Type 1B episode, illustrating the dissociated sleep-wake state. The PSG montage included 8 EEG bipolar traces from fronto-polar (Fp), temporal (T), central (C), occipital (O) leads, two electrooculograms (EOG), electromyograms from the chin, left and right deltoids (L and R Delt) and left and right tibialis anterior muscles (L and R Tib). The EEG shows diffuse slow wave activity (N3 stage) before the activation of EMG, then a movement artifact, followed by slow waves of small amplitude in the frontal leads, mixed with higher mixed and largely artifactual frequencies in the central, temporal and occipital leads. Lower panel: The black vertical line indicates the time of the picture shown in the bottom-right corner. In the first capture the subject was still sleeping, in the second capture he opened his eyes and flexed his neck, his arms, and extended his fingers, and stared perplexedly at his hands. In the third capture he turned his head and partially his trunk to one side (left) and in the last capture he went back lying in the bed. The episode lasted about 20 s and the patient gradually woke up soon after it. He told to the technician he had a dream but he could remember only brief sketches of it. The technician did not interview him more thoroughly and he fell asleep rapidly soon after the technician left the room. (For interpretation of the references to colour in this figure legend, the reader is referred to the Web version of this article.)

Table 1
Sleep-related dream-like hallucinations in different sleep disorders.

	HHH	DOA	RBD	Nightmares	SHE
Stage	N1/Wake	Usually N3	REM	Usually REM	Usually N2
Time of the night	Beginning/end of the night	Usually first part of the night	Usually second part of the night	Usually second part of the night	Any
Awakening	Always	Possible and short	Unusual	Typical and prolonged	Usual
Recall rate	Always	Rare	Frequent	Almost always	Unusual
Modality	Mainly monomodal	Mainly monomodal	Multimodal	Multimodal	Monomodal
	Mainly visual	Mainly visual	Mainly visual	Mainly visual	Somato-esthetic, auditory or visual
Complexity	Simple or complex	Complex but usually fragmentary	Complex, usually coherent story	Extremely complex in fast-changing sequences	Usually simple
Insight	Usually preserved	Absent	Absent	Absent	Present

HHH = Hypnagogic and hypnopompic hallucinations; DOA = Disorders of Arousal; RBD = REM sleep Behavior Disorder; SHE = Sleep-Hypermotor Epilepsy.

faces wandering in his house. In another frequent dream, his bedroom was invaded by snakes, insects or rats, with the walls covered by mice teeth, and he usually woke up while trying to escape out. Other possible landscapes were: the house invaded by flames, the ceiling collapsing because of an earthquake or because he hit it with a slingshot. Notably, he clearly described he was able to see his room exactly as wide awake, but sometimes with additional overlapping elements - eg, shadows, snakes - depending on the content of the dream, which he was unable to doubt before waking up.

He kept a diary of his episodes for 41 days, where he recorded 16 events, of which 11 were witnessed by his bed-partner (Supplementary Table 1). Subsequently, his nocturnal behaviors were monitored with an infrared camera for non-consecutive 14 nights. The camera caught abnormal behaviors in 10 out of 14 nights. The majority of them were simple motor behaviors (Video clip 1–2), while others were more complex (Video clip 3), and/or associated with isomorphic sleep mentations (Video clip 4–6).

Supplementary video related to this article can be found at <https://doi.org/10.1016/j.sleep.2021.03.032>

3. Discussion

Formal diagnostic criteria for NREM sleep parasomnias require the absence or only little recollection of cognition or dream imagery (one visual scene) associated with events and subsequent partial to complete amnesia. Although the intense RBD-like dream activity spoke against these criteria (see Table 1), our patient fulfilled all other criteria for a diagnosis of Disorder of Arousal (mainly sleep-walking subtype). Moreover, the v-PSG recording captured minor behavioral events out of NREM sleep and ruled out the loss of physiological REM sleep atonia or epileptic abnormalities. The MRI scan was negative. Home-video recordings provided further evidence in support of the diagnosis of NREM sleep parasomnia against the possible differential diagnosis of sleep hyper-motor epilepsy [13]. Given its peculiarity, this case raises some important thought-provoking issues.

First of all, it adds support to the idea that current diagnostic criteria are tailored for typical cases in children, but might not always fit the diagnosis of NREM sleep parasomnias in adults. Second, it is in its kind unique, as the recall rate of event-associated mental contents in this patient was exceptionally high (perhaps due to the frequent awakenings at the end of his episodes). The diary of the episodes and some home-video recordings testified dream-enacting behaviors. It might be possible that for this patient, unusually vivid, emotionally charged and complex dreams during NREM sleep acted as internal triggers that favored the occurrence of partial arousals and dissociated states. The background brain

activity of NREM sleep over which the episodes occurred, may explain why events manifested only episodically and only in NREM sleep. Even more notably, behaviors captured by home-video recordings - like finger pointing - indirectly suggested the presence of visual hallucinations in association with dream-enacting behaviors. Remarkably, this patient was able to report his subjective experience during episodes and to describe clear hallucinations - ie, sustained false experiences with the qualities of real perceptions in the absence of real objects, associated with failure of reality testing. This precious insight into the mind-state of this patient suggests a defective integration of internal (“top-down”) and external (“bottom-up”) sensory experiences during NREM parasomnias, and indirectly hints that consciousness re-emerges, although in an altered form. In support of this hypothesis, active wake-like EEG states have been described in motor and limbic brain regions (like the amygdala and the cingulate cortex) during NREM sleep parasomnia episodes [14], as well as in the thalamus [15], but not over higher-order associative areas [14,16], which instead displayed slow wave activity or “mixed” states in between sleep and wakefulness [17].

Credit author statement

AC conceived the idea of writing this case report; AC, MM, contributed to data collection, AC and GL drafted the paper and contributed to data visualization, all authors contributed to the final version of the case report, revised critically the manuscript and provided relevant intellectual content, and approved it in its final version.

Financial support

This case report has been collected within the context of a study supported by an ABREOC grant (Advisory Board of Scientific Research of the Ente Ospedaliero Cantonale).

Conflict of interest

None to declare.

The ICMJE Uniform Disclosure Form for Potential Conflicts of Interest associated with this article can be viewed by clicking on the following link: <https://doi.org/10.1016/j.sleep.2021.03.032>.

Appendix A. Supplementary data

Supplementary data to this article can be found online at <https://doi.org/10.1016/j.sleep.2021.03.032>.

References

- [1] Oudiette D, Leu S, Pottier M, et al. Dreamlike mentations during sleepwalking and sleep terrors in adults. *Sleep* 2009;32:1621–7. <https://doi.org/10.1093/sleep/32.12.1621>.
- [2] Uguccioni G, Golmard JL, de Fontréaux AN, et al. Fight or flight? Dream content during sleepwalking/sleep terrors vs rapid eye movement sleep behavior disorder. *Sleep Med* 2013;14:391–8. <https://doi.org/10.1016/j.sleep.2013.01.014>.
- [3] Bhat S, Chokroverty S, Kabak B, et al. Dream-enacting behavior in non-rapid eye movement sleep. *Sleep Med* 2012;13:445–6. <https://doi.org/10.1016/j.sleep.2011.10.029>.
- [4] Mwenge B, Brion A, Uguccioni G, et al. Sleepwalking: long-term home video monitoring. *Sleep Med* 2013;14:1226–8. <https://doi.org/10.1016/j.sleep.2013.04.027>.
- [5] Pilon M, Montplaisir J, Zadra A. Precipitating factors of somnambulism symbol: impact of sleep deprivation and forced arousals. *Neurology* 2008;70:2284–90. <https://doi.org/10.1212/01.wnl.0000304082.49839.86>.
- [6] Szucs A, Kamondi A, Zoller R, et al. Violent somnambulism: a parasomnia of young men with stereotyped dream-like experiences. *Med Hypotheses* 2014;83:47–52. <https://doi.org/10.1016/j.mehy.2014.04.012>.
- [7] Fisher C, Kahn AE, Davis D. A psychophysiological study of nightmares and night terrors. *Psychoanal Contemp Sci* 1974;3:317–98. <https://doi.org/10.1109/APMC.2009.5384284>.
- [8] Pillmann F. Complex dream-enacting behavior in sleepwalking. *Psychosom Med* 2009;71:231–4. <https://doi.org/10.1097/PSY.0b013e318190772e>.
- [9] Rocha AL, Arnulf I. NREM parasomnia as a dream enacting behavior. *Sleep Med* 2020;75:103–5. <https://doi.org/10.1016/j.sleep.2020.02.024>.
- [10] Loddo G, Sessagesimi E, Mignani F, et al. Specific motor patterns of arousal disorders in adults: a video-polysomnographic analysis of 184 episodes. *Sleep Med* 2018;41:102–9. <https://doi.org/10.1016/j.sleep.2017.08.019>.
- [11] Baldini T, Loddo G, Sessagesimi E, et al. Clinical features and pathophysiology of disorders of arousal in adults: a window into the sleeping brain. *Front Neurol* 2019;10:1–9. <https://doi.org/10.3389/fneur.2019.00526>.
- [12] Loddo G, Sessagesimi E, Mignani F, et al. Specific motor patterns of arousal disorders in adults: a video-polysomnographic analysis of 184 episodes. *Sleep* 2009;32:936–40. <https://doi.org/10.1093/sleep/32.12.1637>.
- [13] Derry CP, Harvey AS, Walker MC, et al. NREM arousal parasomnias and their distinction from nocturnal frontal lobe epilepsy: a video EEG analysis. *Sleep* 2009;32:1637–44. <https://doi.org/10.1093/sleep/32.12.1637>.
- [14] Terzaghi M, Sartori I, Tassi L, et al. Evidence of dissociated arousal states during nrem parasomnia from an intracerebral neurophysiological study. *Sleep* 2009;32:409–12. <https://doi.org/10.1093/sleep/32.3.409>.
- [15] Sarasso S, Pigorini A, Proserpio P, et al. Fluid boundaries between wake and sleep: experimental evidence from Stereo-EEG recordings. *Arch Ital Biol* 2014;152:169–77. <https://doi.org/10.12871/0002982920142311>.
- [16] Terzaghi M, Sartori I, Tassi L, et al. Dissociated local arousal states underlying essential clinical features of non-rapid eye movement arousal parasomnia: an intracerebral stereo-electro. *J Sleep Res* 2012;21:502–6. <https://doi.org/10.1111/j.1365-2869.2012.01003.x>.
- [17] Flamand M, Boudet S, Lopes R, et al. Confusional arousals during non-rapid eye movement sleep: evidence from intracerebral recordings. *Sleep* 2018;41:1–11. <https://doi.org/10.1093/sleep/zsy139>.