


Less in-toeing after femoral derotation osteotomy in adult patients with increased femoral version and posterior hip impingement compared to patients with femoral retroversion

Till D. Lerch ^{1*}, Adam Boschung², Christiane Leibold², Roger Kalla³, Hassen Kerkeni³, Heiner Baur⁴, Patric Eichelberger⁴, Klaus A. Siebenrock², Moritz Tannast^{2,5}, Simon D. Steppacher^{2†} and Emanuel F. Liechti^{2†}

¹Department of diagnostic, interventional and pediatric Radiology, Inselspital, Bern University Hospital, University of Bern, Freiburgstrasse 10, Bern 3010, Switzerland, ²Department of Orthopaedic Surgery, Inselspital, Bern University Hospital, University of Bern, Freiburgstrasse 10, Bern 3010, Switzerland, ³Department of Neurology, Bern University Hospital, University of Bern, Freiburgstrasse 10, Bern 3010, Switzerland, ⁴Department of Physiotherapy, Bern University of Applied Sciences Health, Stadtbachstrasse 64, Bern 3012, Switzerland and ⁵Department of Orthopaedic Surgery and Traumatology, Fribourg Cantonal Hospital, HFR, University of Fribourg, Chem. des Pensionnats 2-6, Villars-sur-Glâne, Fribourg 1752, Switzerland

[†]Shared last authorship, equal contribution of these two authors.

Each author certifies that his or her institution approved the human protocol for this investigation, that all investigations were conducted in conformity with ethical principles of research and that informed consent for participation in the study was obtained.

*Correspondence to: T. Lerch. E-mail: till.lerch@insel.ch

ABSTRACT

In-toeing of the foot was associated with high femoral version (FV), while Out-toeing was associated with femoral-retroversion. Therefore, we report on (i) foot-progression-angle (FPA), (ii) prevalence of In-toeing and Out-toeing, and (iii) clinical outcome of patients treated with femoral-derotation-osteotomy (FDO). We performed a retrospective analysis involving 20 patients (20 hips) treated with unilateral FDO (2017–18). Of them, 14 patients had increased FV, 6 patients had femoral-retroversion. Follow-up time was mean 1 ± 1 years. All patients had minimal 1-year follow-up and the mean age was 29 ± 8 years. Patients with increased FV ($FV > 35^\circ$) presented with positive posterior-impingement-test and mean FV was $49 \pm 11^\circ$ (Murphy method). Six patients with femoral-retroversion ($FV < 10^\circ$) had positive anterior impingement test and mean FV of $5 \pm 4^\circ$. Instrumented gait analysis was performed preoperatively and at follow-up using the Gaitrite system to measure FPA and was compared to a control group of 18 healthy asymptomatic volunteers (36 feet, mean age 29 ± 6 years). (i) Mean FPA increased significantly ($P = 0.006$) from preoperative $1.3 \pm 7^\circ$ to $4.5 \pm 6^\circ$ at follow-up for patients with increased FV and was not significantly different compared to the control group ($4.0 \pm 4.5^\circ$). (ii) In-toeing decreased from preoperatively (five patients) to follow-up (two patients) for patients with increased FV. Out-toeing decreased from preoperatively (two patients) to follow-up (no patient) for patients with femoral-retroversion. (iii) Subjective-hip-value of all patients increased significantly ($P < 0.001$) from preoperative 21 to 78 points at follow-up. WOMAC was 12 ± 8 points at follow-up. Patients with increased FV that underwent FDO walked with less In-toeing. FDO has the potential to reduce In-toeing and Out-toeing and to improve subjective satisfaction at follow-up.

INTRODUCTION

Variations in the femoral version (FV) are potential contributing factors of symptomatic femoroacetabular impingement (FAI) [1–3]. FV can influence the hip range of motion (ROM), especially internal and external rotation (ER) [1]. Increased FV was recently associated with posterior extraarticular ischiofemoral hip impingement [4, 5] and treatment with femoral derotational osteotomy (FDO) was reported [6–8]. It was associated with damage of the acetabular labrum and cartilage and eventually osteoarthritis [1, 9, 10]. Furthermore, increased FV can cause

a decreased length of the abductor lever arm [11] and in-toeing gait [12].

Patients with increased FV show an osseous impingement conflict that is located extraarticular between the ischial tuberosity and the lesser/greater trochanter [4, 13]. Clinically, some of these patients exhibit in-toeing gait, increased internal rotation (IR) and decreased ER of the hip [14]. These rotational deformities may occur as isolated deformities or combined with hip dysplasia [15, 16]. For patients with posterior extraarticular hip impingement with increased FV that were treated with FDO,

Submitted 29 September 2021; Revised 9 December 2021; Accepted 4 January 2022

© The Author(s) 2022. Published by Oxford University Press.

This is an Open Access article distributed under the terms of the Creative Commons Attribution-NonCommercial License (<https://creativecommons.org/licenses/by-nc/4.0/>), which permits non-commercial re-use, distribution, and reproduction in any medium, provided the original work is properly cited. For commercial re-use, please contact journals.permissions@oup.com

METHODS

gait analysis and outcomes of this novel treatment were rarely investigated for adult patients so far [6, 7]. On the other hand, for patients with anterior FAI and decreased FV (or femoral retroversion), a previous study reported inferior clinical outcomes after hip arthroscopy [17]. The effect of decreased FV or femoral retroversion is discussed controversially because others reported similar outcomes (compared to FAI patients with normal FV) [18]. Recently, treatment with femoral osteotomy using intramedullary nailing with improved short-term outcomes were reported [19].

In-toeing gait is associated with increased FV, while out-toeing is associated with decreased FV [14]. Gait disorders including in-toeing gait are a common cause for consultations for paediatric patients [20, 21]. Up to 30% of 4-year old normal children have an in-toeing gait, ranging up to a prevalence of 64% in children with cerebral palsy [22]. For children with cerebral palsy, treatment with FDO is performed routinely [23, 24]. In-toeing can be present in children with Perthes' disease [25], children with cerebral palsy [26, 27] and even in children with isolated increased FV [28]. But for adult patients with abnormal FV, only a few outcome studies were performed.

Therefore, we report on (i) foot progression angle (FPA), (ii) prevalence of in-toeing, and (iii) clinical outcome of adult patients treated with FDO.

This is an Institutional Review Board (IRB)–approved retrospective case series seeking to investigate gait analysis and the clinical outcome of adult patients that underwent FDO. We performed a retrospective analysis of 20 patients (20 hips) treated with unilateral FDO (January 2017–December 2018). Of them, 14 patients had increased FV ($>35^\circ$) and posterior hip impingement while 6 patients had decreased FV ($<10^\circ$) and anterior hip impingement. Follow-up time was mean 1 ± 1 years (range 1–2). All patients had minimal 1-year follow-up and underwent gait analysis preoperatively and at follow-up. The mean age was 29 ± 8 years (range 19–45 years).

Patient selection

We included patients who underwent FDO (subtrochanteric osteotomies) to treat symptomatic anterior or posterior extra-articular hip impingement in a 2-year period (January 2017–December 2018). Exclusion criteria were concomitant symptomatic hip dysplasia treated with periacetabular osteotomy (PAO) [29], concomitant valgus deformity (neck-shaft angle $>139^\circ$, measured on CT scans), post-traumatic deformity, patients with cerebral palsy, skeletally immature patients, avascular necrosis of the femoral head or sequelae of childhood diseases. In this 2-year period, 43 patients were treated

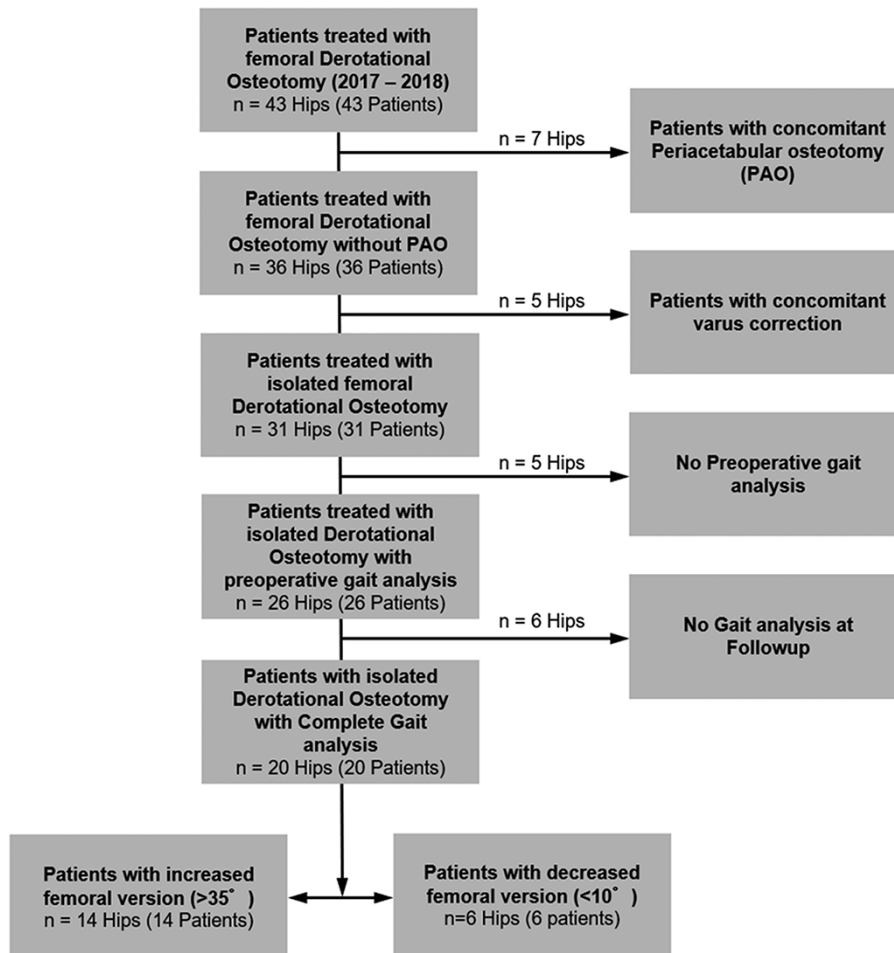


Fig. 1. Flowchart of the patient series is shown.

with FDO, we excluded 7 patients with concomitant PAO, 5 patients with concomitant varus correction (Fig. 1). Five patients did not undergo preoperative gait analysis, and 6 patients refused gait analysis at follow-up (Fig. 1). Some of the patients were included in a previous study [59].

Clinical examination

As part of the routine workup, all patients were clinically evaluated by one of our attending hip surgeons with >10 years of experience in hip preservation surgery MT and KAS. This included the acquisition of the patient's history, measurement of hip ROM in prone and supine position, the evaluation of the anterior and posterior impingement test [30], and the assessment of hip instability (based on the apprehension/FABER test in combined flexion, abduction and ER), abductor strength and joint hypermobility. The 14 patients with increased FV had a history of posterior (buttock) or posterolateral hip pain and restricted ER (<20°) of the hip in extension. During clinical examination, the posterior impingement test was positive (for all 14 patients with increased FV), signifying reproducible posterior hip pain in ER in full extension in supine position. Some patients with increased FV presented with a positive FABER (Flexion, Abduction and external rotation) test and the mean FV was 49 ± 11° (range 35–68, Table I). Some patients with posterior extraarticular ischiofemoral impingement reported pain with long stride walking [31].

The six patients with decreased FV showed anterior hip (groin) pain and limited IR in 90° of flexion. The anterior impingement test (also called FADIR test) was positive in all patients, meaning reproducible anterior hip pain in maximal IR in 90° of flexion. Most of the patients with femoral-retroversion reported pain in deep flexion or while donning shoes or during sports. Some patients with femoral-retroversion presented with limited sitting tolerance <30 min and mean FV was 5 ± 4° (range -1–8, Table I).

Indication for surgery

Patients with increased FV had symptomatic posterior hip impingement, while the six patients with decreased FV had anterior hip impingement. Surgery was offered if the patient had failed all nonsurgical treatment options such as physical therapy and if the ROM abnormality correlated with FV in prone position. This means increased hip IR was found in patients with increased FV and vice versa (decreased IR was present in patients with decreased FV). Surgery was only performed in patients with symptoms >6 months.

Diagnosis of anterior hip impingement was based on the combination of clinical symptoms (hip or groin pain, positive anterior impingement test, reduced hip IR and decreased FV). Diagnosis of posterior hip impingement was based on the combination of clinical symptoms (posterior hip pain or buttock pain), posterior apprehension test or posterior impingement test or positive FABER test and radiographic findings (increased FV on computed tomography [CT] scan). Diagnosis of anterior and posterior extraarticular impingement was based on dynamic impingement conflict during 3D impingement simulation (Fig. 2). Posterior extraarticular impingement could be located between the ischial tuberosity and/or the lesser and/or

Table I. Demographic and radiographic data of the patient series is shown below

Parameter	Patients with increased FV	Patients with decreased FV	Control group
Patients (hips)	14 (14)	6 (6)	18 (36)
Age at operation (years)	30 ± 9 (19–45)	26 ± 5 (21–32)	29 ± 6 (18–40)
Gender (% female of all hips)	100	50	56
Side (% right of all hips)	71	66	50
Height (cm)	168 ± 8 (155–183)	178 ± 9 (167–192)	176 ± 11 (154–191)
Weight (kg)	70 ± 10 (50–93)	80 ± 31 (49–131)	75 ± 18 (44–120)
Body mass index (kg/m ²)	25 ± 4 (20–32)	25 ± 8 (17–36)	24 ± 4 (19–35)
Radiographic			
Femoral version (°)	49 ± 10 (35–68)	5 ± 4 (-1–7)	N/A
Acetabular version (°)	21 ± 6 (12–34)	11 ± 6 (3–19)	N/A
Tibial torsion (°)	39 ± 10 (29–61)	30 ± 3 (27–34)	N/A
McKibbin index (°)	70 ± 10 (51–83)	16 ± 9 (6–27)	N/A
LCE-angle (°)	28 ± 7 (21–45)	32 ± 8 (19–44)	N/A

N/A = not applicable.

Continuous values are expressed as mean ± SD and range in parenthesis.

greater trochanter. Anterior extraarticular subspine impingement was located between the anterior inferior iliac spine (AIIS) and the proximal femur. Some of the patients with increased FV showed edema in the quadratus femoris muscle or reduced ischiofemoral distance on magnetic-resonance-imaging (MRI) [32, 33] or both. Six patients had previous surgery, four patients underwent previous hip arthroscopy. Two patients underwent two times hip arthroscopy for cam resection in another institution. Two other patients underwent hip arthroscopy for cam resection and acetabular rim trimming. Some of the patients were part of a previous study [59].

Gait analysis

Gait analysis was performed using an instrumented walkway system (GAITRite, CIR Systems, Inc. 12 Cork Hill Road, Franklin, NJ, USA) to measure the foot-progression-angle (FPA). The GAITRite system is a computer-based instrumented roll-up walkway with embedded pressure sensors to measure spatial and temporal gait characteristics [34]. The roll-up walkway with 18 432 embedded pressure sensors [34] used for this study is 6 m long. The walkway's active measurement area is 61 cm wide and 488 cm long. Sensors are arranged in a grid pattern (48 × 384) and placed 1.27 cm in the center (sampling rate varies between 32.2 and 38.4 Hz). Data are

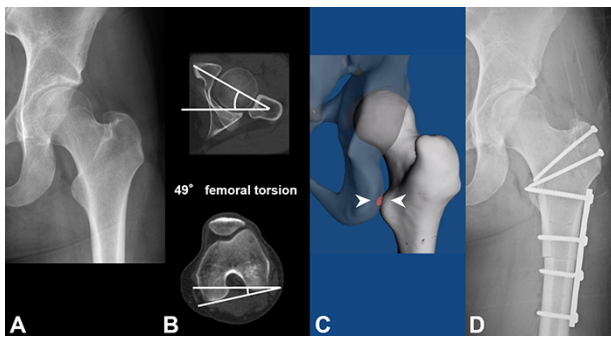


Fig. 2. (A–D) Pre- (A) and postoperative pelvic radiograph (D) of a female patient with increased femoral version (49° on preoperative CT, B) that underwent femoral derotation osteotomy are shown (D). 3D impingement simulation (C) shows posterior extraarticular ischiofemoral impingement conflict. Figure reprinted with permission [59].

uploaded to a computer for automatic footstep identification and parameter calculations. This system provides quantitative information about the patient's gait. Several authors reported high validity of the GAITRite® system for measuring both spatial and temporal characteristics [34, 35].

The main outcome parameter was the FPA. This is a common parameter to detect in- and out-toeing gait (Fig. 3). The FPA was defined as the angle of out-toeing of the foot during the stance phase compared to the line of gait progression [20]. Normal FPA was defined as 0° – 15° (Fig. 3C) adapted from a previous study [14]. Out-toeing was defined as $FPA > 15^\circ$. In-toeing was defined as $FPA < 0^\circ$. The normal FPA ranges from 5° in children [36] to 13° in adults [37]. Other definitions for normal FPA had a slightly wider range of 4° – 15° [26], while others reported a normal FPA of 8° [38].

Radiographic evaluation

Routine radiographic evaluation pre-, postoperatively and at follow-up consisted of an anteroposterior (AP) pelvic radiograph and a cross-table lateral view of the hip and preoperative MRI and CT scans [30]. Acetabular and femoral standard radiographic parameters (Table 1) were analysed by one observer (TDL) not involved in surgical care. Some patients underwent preoperative traction MR arthrography of the hip [39]. Cam deformity was defined with an alpha angle $> 50^\circ$ [40]. No radiographic signs of osteoarthritis (OA) (OA \geq grade 1 according to Tönnis) were present preoperatively. FV was measured on CT scans (Fig. 2) according to Murphy *et al.* [41, 42] using three reference points at three different femoral locations: the femoral head center, the center of the base of the femoral neck and the posterior condylar axis. FV was considered normal between 10 – 25° and considered increased $FV > 35^\circ$ and decreased $FV < 10^\circ$ [2].

Normal tibial torsion (TT) was defined between 25 – 40° [43] and was measured according to the 'Ulm' method described previously [43]. This method showed high interobserver reliability for measuring TT [44]. Mean TT was $39 \pm 10^\circ$ (range 29–61) of patients with increased FV and mean TT was $30 \pm 3^\circ$ (range 27–34, Table) of six patients with decreased FV. The femorotibial index was calculated with TT minus FV according to

Out-Toeing

In-Toeing



Fig. 3. (A and B) Schematic view of out-toeing (A) and in-toeing (B) is shown. Figure reprinted with permission [14].

Goutallier *et al.* [45]. The ischiofemoral distance was evaluated for patients with increased FV on preoperative MRI and was lower (17 ± 5 mm, range 12–25) compared to the reported normal ischiofemoral distance [46] of 30.6 mm. A preoperative 3D-CT-scan was performed for 3D simulation of hip impingement (Fig. 2) and hip ROM [32, 33]. No radiographic information of the control group was available.

Surgical procedure

The FDO was performed on the subtrochanteric level for all patients with the patient positioned in lateral position and the FDO was performed using the subvastus approach [6]. Mean intraoperative correction of FDO was $19 \pm 3^\circ$ (range 15–25) and was planned with two K-wires. The intraoperative correction was evaluated intraoperatively and decided individually based on the amount of IR and ER and FV. Fixation of subtrochanteric osteotomies was predominantly done with 6-hole DCP-plates. The detailed surgical technique was described previously [1, 6]. In addition to this description, we tested intraoperatively for patients with increased FV, if the posterior impingement can lead to an anterior hip instability through anterior levering out of the femoral head [47]. FDO was performed with the aim to decrease IR and to increase ER of the hip for patients with increased FV and vice versa for patients with decreased FV.

The FDO was performed in combination with SHD for most patients (18 patients, 90%), while two patients had concomitant hip arthroscopy (without intraoperative ROM testing). We used concomitant SHD because it allows dynamic evaluation of hip ROM and visualisation of intra/extraarticular impingement and cartilage and labrum lesions. Cam resection was performed in patients with a cam-deformity (15 patients, 75%) before correction of FV. The intraoperative surgical goal was to achieve 30° of IR in 90° of hip flexion. IR was tested after FDO and if IR was below 30°, an additional cam resection was improved. Two patients had subsequent PAO. During the hospital stay, patients were kept on a continuous passive motion to prevent adhesions postoperatively.

Evaluation at follow-up

All patients were contacted and were invited for clinical and radiographic follow-up. The clinical examination and gait analysis at follow-up was performed by one of the authors (TDL) not involved in surgical care. To evaluate the hip function, the Subjective-hip-value (SHV), the Merle d'Aubigné and Postel (MDA) score and full goniometric ROM was assessed. The MDA score was graded as 'poor' < 12, as 'fair' from 12–14, as 'good' from 15–17 and as 'excellent' with 18 points.

All patients were asked for subjective satisfaction using the SHV [48] using the visual analogue scale (VAS) scale ranging from 0 (minimum) to 100 (maximum). PROMS were evaluated at follow-up. Self-reported outcome instruments were collected with questionnaires using questions regarding the affected hip for the Harris-hip-scores (HHS) and the Hip Disability and Osteoarthritis Outcome Score (HOOS) [49]. For the HHS and the HOOS, the maximum is 100 points. For the HHS, a score of 91–100 points corresponded to excellent hip function; 81–90 points, good function; 71–80 points, fair function; and

≤70 points, poor hip function. We used the Western-Ontario-and-McMaster-Universities-Osteoarthritis-Index (WOMAC) and the University of California Los Angeles Activity-score (UCLA).

Sample size calculation was performed for continuous variables of two groups with a level of significance of 5% and beta error of 10%, given previously reported mean values for FPA of 13° for volunteers [37] and 5° for patients with increased

Table II. (A) Results preoperatively and at most recent follow-up for 14 patients with increased FV. (B) Results preoperatively and at most recent follow-up for 6 patients with decreased FV

Parameter	Preoperative	At follow-up	<i>P</i> value preoperative versus follow-up
(A)			
Foot progression angle (°)	1.3 ± 7 (-13–10)	4.5 ± 6 (-8–12)*	0.006
In-toeing (% of all hips)	5	2	0.021
Out-toeing (% of all hips)	0	0	NS
(B)			
Foot progression angle (°)	8.2 ± 8 (3–18)	0.5 ± 5 (-5–9)*	0.028
In-toeing (% of all hips)	0	1	NS
Out-toeing (% of all hips)	2	0	NS

NS = not significant; FPA = foot progression angle.

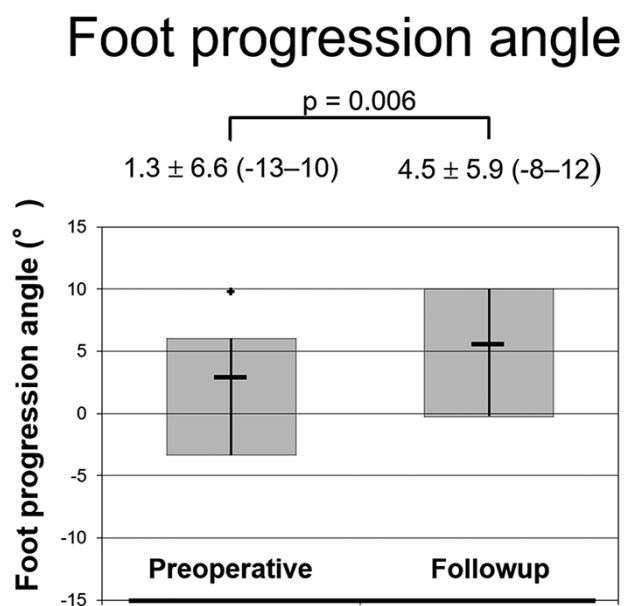


Fig. 4. A significantly ($P < 0.001$) increased foot progression angle was found at follow-up compared to preoperatively for 14 patients with increased femoral version.

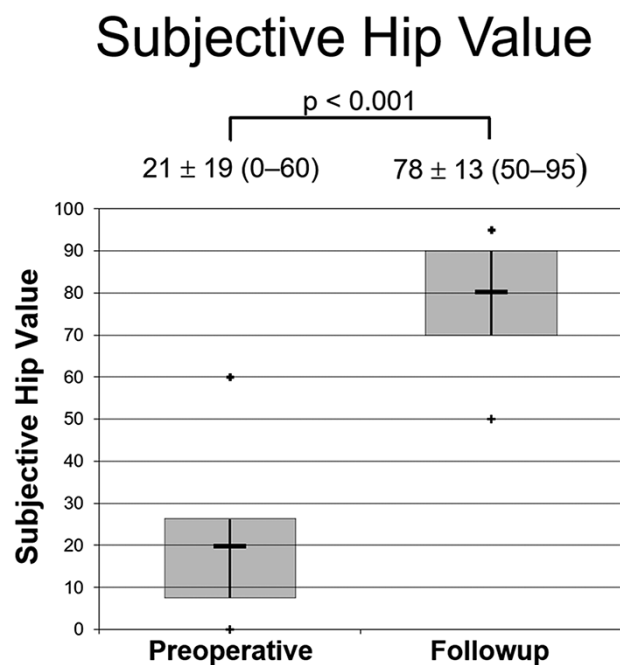


Fig. 5. A significantly ($P < 0.001$) increased subjective hip value was found at follow-up compared to preoperatively for all 20 patients that underwent femoral derotation osteotomy.

Table III. (A) Clinical results preoperatively and at most recent follow-up of 14 patients with posterior impingement and increased FV. (B) Clinical results preoperatively and at most recent follow-up of 6 patients with anterior impingement and decreased FV

Parameter	Preoperative	At follow-up	P value preoperative versus follow-up
(A)			
Merle d'Aubigné—Postel score (18–0) [58]	14 ± 1 (13–15)	17 ± 1 (16–18)*	<0.001
Subjective hip value (0–100)	20 ± 22 (0–60)	81 ± 11 (60–95)*	<0.001
Anterior impingement test (% of all hips) [30]	71	0*	<0.001
Posterior impingement test (% of all hips) [30]	100	0*	<0.001
FABER test (% of all hips)	86	0*	<0.001
Range of motion (°)			
Flexion	103 ± 12 (90–120)	106 ± 8 (100–120)	NS
Internal rotation in 90° of flexion	48 ± 12 (30–70)	28 ± 8 (20–40)*	0.003
External rotation in 90° of flexion	31 ± 16 (0–50)	38 ± 9 (30–60)	NS
Internal rotation in extension	57 ± 14 (30–70)	34 ± 5 (30–40)*	0.002
External rotation in extension	17 ± 9 (5–30)	39 ± 14 (30–60)*	0.003
(B)			
Merle d'Aubigné—Postel score (18–0) [58]	14 ± 1 (12–15)	17 ± 1 (17–18)*	<0.001
Subjective hip value (0–100)	23 ± 13 (10–45)	72 ± 15 (50–90)*	<0.001
Anterior impingement test (% of all hips) [30]	100	17*	<0.001
Range of motion (°)			
Flexion	94 ± 7 (85–100)	107 ± 12 (90–120)	NS
Internal rotation in 90° of flexion	10 ± 7 (0–20)	30 ± 6 (20–40)	0.028
External rotation in 90° of flexion	50 ± 22 (20–80)	35 ± 8 (30–50)	NS

NS = not significant; FABER = Flexion, Abduction and external rotation; FV = femoral version.

Continuous values are expressed as mean ± SD and range in parenthesis.

*signifies statistical significant difference.

Table IV. Clinical scores at follow-up for both patient groups are shown below

Parameter	Patients with increased FV	Patients with decreased FV
Patients (hips)	14 (14)	6 (6)
Modified Harris hip score	75 ± 11 (64–95)	77 ± 10 (67–92)
HOOS total	72 ± 13 (50–85)	70 ± 8 (62–81)
HOOS pain	76 ± 17 (50–95)	72 ± 7 (63–83)
HOOS ADL	94 ± 7 (79–99)	90 ± 8 (78–96)
HOOS Sports	61 ± 17 (31–88)	61 ± 11 (50–75)
HOOS Other	77 ± 19 (45–100)	70 ± 8 (62–81)
UCLA	6 ± 2 (3–9)	5 ± 1 (4–7)
WOMAC score	12 ± 9 (3–25)	13 ± 7 (8–23)

Continuous values are expressed as mean ± SD and range in parenthesis.

FV [14]. This resulted in 8 patients per group (clincalc.com, accessed on 7 September 2021).

Statistical analysis

Normal distribution was not tested due to the small number in this patient series, therefore we used only nonparametric tests. To detect differences between the continuous values (e.g. FPA) preoperatively and postoperatively we used the Wilcoxon signed rank test and the chi-square test for binominal data. Clinical parameters were compared preoperatively and at follow-up using the Wilcoxon signed rank test for continuous data and the chi-square test for binominal data.

RESULTS

- (i) Mean FPA increased significantly ($P = 0.006$) from preoperative $1.3 \pm 7^\circ$ to $4.5 \pm 6^\circ$ at followup for patients with increased FV (Fig. 4) and was not significantly different compared to the control group (FPA of $4.0 \pm 4.5^\circ$, Table 2A). Mean FPA decreased significantly ($P = 0.021$) from preoperative $8.2 \pm 8^\circ$ to $0.5 \pm 6^\circ$ at a follow-up of patients with femoral-retroversion (Table 2B).
- (ii) Prevalence of in-toeing (FPA $< 0^\circ$) decreased from preoperatively (five patients) to follow-up (two patients, Table 2A) for patients with increased FV. Prevalence of in-toeing at follow-up was similar compared to the control group (one volunteer had in-toeing). Of the 14 patients with increased FV, 12 patients had normal FPA at follow-up. Of the patients with decreased FV, the prevalence of out-toeing (FPA $> 15^\circ$) decreased from preoperatively (two patients) to follow-up (no patient had out-toeing), but one patient had in-toeing at follow-up (Table 2B).
- (iii) SHV of all patients increased significantly ($P < 0.001$) from preoperative 21 to 78 points at follow-up (Fig. 5). Mda score increased significantly ($P < 0.001$) from preoperative 14 to 17 points at follow-up (Table 3). WOMAC was 12 ± 8 points, mean HHS was 76 ± 10 points at follow-up (Table 4). IR in 90° of flexion increased significantly ($P = 0.028$) in patients with decreased FV (Table 3B) and was normalized at follow-up. IR in extension decreased significantly ($P = 0.002$) in patients with increased FV (Table 3A).

3D impingement simulation showed limited IR in 90° of flexion of $26 \pm 7^\circ$ (16–33) and flexion of $115 \pm 6^\circ$ (108–121) for patients with femoral-retroversion. For patients with increased FV, increased IR in 90° of flexion of $63 \pm 9^\circ$ (49–74) but a limited extension of $17 \pm 12^\circ$ (7–42) and limited ER in the extension of $18 \pm 6^\circ$ (8–27) was observed 3D impingement simulation.

DISCUSSION

We performed a retrospective study investigating gait analysis and clinical outcome of 20 patients that underwent FDO with symptomatic anterior or posterior hip impingement. We performed instrumented gait analysis preoperatively and at a follow-up to detect patients with in- or out-toeing (Fig. 3). Most importantly, we found a significantly increased FPA at follow-up (Fig. 4) and significantly decreased prevalence of in-toeing of patients with posterior hip impingement (Table II). Mean FPA at follow-up of patients with increased FV did not differ significantly compared to FPA of the control group.

There is inconsistent literature regarding normal values of FPA and the definition of in-toeing [23, 28, 50, 51]. For adolescents with increased FV, a lower FPA of $<0^\circ$ was described [28] compared to preoperative FPA of our patients with increased FV. Comparing FPA of patients with increased FV, another study reported a higher FPA of 5° [14] using 3D motion analysis (Vicon system). While other studies reported in-toeing of the foot in patients with increased FV, some studies did not report the exact values of the FPA [25, 52] that impairs direct comparison. In-toeing was described in children with Perthes' disease [25], children with cerebral palsy [26, 27] and even in children with isolated increased FV [28]. In a previous study investigating FPA before and after FDO in patients with cerebral palsy, they reported a larger difference of pre- and postoperative FPA of 12.6 to 12.9° after FDO [23] compared to the current study. Other studies investigating clinical outcomes after FDO for adult patients did not evaluate the FPA [6, 7].

Compared to previous studies [50, 51] investigating healthy asymptomatic volunteers using the same system for gait analysis (Gaitrite), we found comparable FPA. They described normal FPA of $4.5 \pm 5.6^\circ$ for males and $1.4 \pm 5.4^\circ$ for females [51]. Another study [37] described a higher mean FPA for asymptomatic volunteers (13 – 14°), but measurements were performed without instrumented gait analysis.

Improved knowledge and recognition of posterior extraarticular hip impingement in hips with increased FV in recent years has led to increasing FDO. All patients were treated between January 2017–December 2018. Diagnosis and surgical decision-making to treat symptomatic posterior hip impingement in hips with increased FV is challenging and increased during the study period. Recognition of posterior hip impingement in a previous study evaluating 3D-CT-based dynamic impingement simulation [4] led to the awareness of this problem. Future studies could investigate MRI-based techniques for 3D modelling to avoid radiation exposure [33]. To improve detection and for a more consistent diagnosis of abnormalities of FV, measurement of FV is routinely included since 2011 in any CT or MRI protocol of the hip in our institution.

The limitations of the current study are inherent to the retrospective study design. First, there is no control group with

increased FV without surgical treatment. Second, the clinical parameters (anterior impingement test, ROM, MDA) were assessed by different observers preoperatively and at follow-up. This is unavoidable for a retrospective study. There are some limitations of the MDA score because the score was not validated for these patients. However, in the literature, substantial inter- and intra-observer agreements have been reported for these parameters and should not affect our main results [53–55].

In addition, we captured the FPA during the stance phase only (Fig. 3C). The stance phase is more robust for FPA measurements compared to the toe-off-phase [56]. We did not quantify any potential concomitant foot deformity. However, based on the clinical examination, none of our patients presented with foot pain, which should therefore not jeopardize our results. Our measurements were done at one single time point. Theoretically, the FPA could change during the daytime and with activities of daily living. Given the reported mean error of $<1^\circ$ for the measurement of FPA at two different time points [34] and the high accuracy of the Gaitrite system [34, 35], this should not influence our results. In addition, the concomitant procedures performed (e.g. cam resection) are a potential source of bias.

Correction of abnormal FV successfully relieved hip pain and eliminated the anterior and positive posterior impingement in most of the patients. Recently, a follow-up study of closed, subtrochanteric FDO reported 75% excellent results at 7-year follow-up [7]. Tönnis reported overall pain relief in 83% and a good short-term outcome evaluating FDO and rotational osteotomies [1]. Kamath *et al.* [6] reported good short-term clinical outcomes in 93% (same surgical technique with subtrochanteric FDO combined with SHD).

FDO could normalize ER and IR (Table III). A more balanced IR and ER of the hip were also described by others [7]. In predominantly paediatric studies, a significant decrease in IR and increase in ER was reported too after FDO [1, 57]. Tönnis reported a normalization of IR and ER after rotational osteotomies and FDO [1]. Others reported a decrease of IR from 84° to 41° and an increase of ER from 16° to 51° after FDO [57].

Subjective satisfaction increased significantly (Fig. 5) in our series after short-term follow-up (Table III). We found few previous studies that investigated the SHV in patients undergoing FDO [59]. High subjective satisfaction was similar to a previous report [7] investigating the outcome after FDO (75% excellent results). They reported a higher mean HHS of 93 points at follow-up.

CONCLUSION

It is important to identify abnormal FV to optimize treatment outcomes after hip preservation surgery. Abnormalities of FV should be assessed because of the potential extraarticular hip impingement. Subtrochanteric derotation osteotomy of the femur is an effective procedure to treat abnormal FV and to normalize gait and ROM. This treatment resulted in improvements in subjective satisfaction and of the FPA.

FUNDING

Till D. Lerch has received funding from the University of Bern and of the Swiss National Science Foundation, Grant number 195241.

CONFLICT OF INTEREST STATEMENT

None declared.

REFERENCES

- Tönns D, Heinecke A. Acetabular and femoral anteversion: relationship with osteoarthritis of the hip. *J Bone Joint Surg Am* 1999; **81**: 1747–70.
- Lerch TD, Todorski IAS, Steppacher SD *et al*. Prevalence of femoral and acetabular version abnormalities in patients with symptomatic hip disease: a controlled study of 538 hips. *Am J Sports Med* 2018; **46**: 122–34.
- Ganz R, Parvizi J, Beck M *et al*. Femoroacetabular impingement: a cause for osteoarthritis of the hip. *Clin Orthop Relat Res* 2003; **417**: 112–20.
- Siebenrock KA, Steppacher SD, Haefeli PC *et al*. Valgus hip with high antetorsion causes pain through posterior extraarticular FAI. *Clin Orthop Relat Res* 2013; **471**: 3774–80.
- Gómez-Hoyos J, Schröder R, Reddy M *et al*. Femoral neck anteversion and lesser trochanteric retroversion in patients with ischiofemoral impingement: a case-control magnetic resonance imaging study. *Arthroscopy* 2016; **32**: 13–8.
- Kamath AF, Ganz R, Zhang H *et al*. Subtrochanteric osteotomy for femoral mal-torsion through a surgical dislocation approach. *J Hip Preserv Surg* 2015; **2**: 65–79.
- Buly RL, Sosa BR, Poultsides LA *et al*. Femoral derotation osteotomy in adults for version abnormalities. *J Am Acad Orthop Surg* 2018; **26**: e416–25.
- Tönns D, Heinecke A. Diminished femoral antetorsion syndrome: a cause of pain and osteoarthritis. *J Pediatr Orthop* 1991; **11**: 419–31.
- Eckhoff DG. Effect of limb malrotation on malalignment and osteoarthritis. *Orthop Clin North Am* 1994; **25**: 405–14.
- Terjesen T, Benum P, Anda S *et al*. Increased femoral anteversion and osteoarthritis of the hip joint. *Acta Orthop Scand* 1982; **53**: 571–5.
- Scheys L, Van Campenhout A, Spaepen A *et al*. Personalized MR-based musculoskeletal models compared to rescaled generic models in the presence of increased femoral anteversion: effect on hip moment arm lengths. *Gait Posture* 2008; **28**: 358–65.
- Svenningsen S, Terjesen T, Auflem M *et al*. Hip rotation and in-toeing gait. A study of normal subjects from four years until adult age. *Clin Orthop Relat Res* 1990; **251**: 177–82.
- Lerch TD, Zwingerstein S, Schmaranzer F *et al*. Posterior extra-articular ischiofemoral impingement can be caused by the lesser and greater trochanter in patients with increased femoral version: dynamic 3D CT-based hip impingement simulation of a modified FABER test. *Orthop J Sports Med* 2021; **9**: 2325967121990629.
- Lerch TD, Eichelberger P, Baur H *et al*. Prevalence and diagnostic accuracy of in-toeing and out-toeing of the foot for patients with abnormal femoral torsion and femoroacetabular impingement: implications for hip arthroscopy and femoral derotation osteotomy. *Bone Joint J* 2019; **101-B**: 1218–29. <https://pubmed.ncbi.nlm.nih.gov/31564157/>.
- Trousdale RT, Ekkernkamp A, Ganz R *et al*. Periacetabular and intertrochanteric osteotomy for the treatment of osteoarthritis in dysplastic hips. *J Bone Joint Surg Am* 1995; **77**: 73–85.
- Spiker AM, Fields KG, Nguyen JT *et al*. Characterization of version in the dysplastic hip and the need for subsequent femoral derotational osteotomy after periacetabular osteotomy. *J Hip Preserv Surg* 2020; **7**: 575–82.
- Fabricant PD, Fields KG, Taylor SA *et al*. The effect of femoral and acetabular version on clinical outcomes after arthroscopic femoroacetabular impingement surgery. *J Bone Joint Surg Am* 2015; **97**: 537–43.
- Lall AC, Battaglia MR, Maldonado DR *et al*. Does femoral retroversion adversely affect outcomes after hip arthroscopy for femoroacetabular impingement syndrome? A midterm analysis. *Arthroscopy* 2019; **35**: 3035–46.
- Mastel MS, El-Bakoury A, Parkar A *et al*. Outcomes of femoral derotation osteotomy for treatment of femoroacetabular impingement in adults with decreased femoral anteversion. *J Hip Preserv Surg* 2020; **7**: 755–63.
- Staheli LT, Corbett M, Wyss C *et al*. Lower-extremity rotational problems in children. Normal values to guide management. *J Bone Joint Surg Am* 1985; **67**: 39–47.
- Svenningsen S, Apalset K, Terjesen T *et al*. Regression of femoral anteversion. A prospective study of intoeing children. *Acta Orthop Scand* 1989; **60**: 170–3.
- Wren TAL, Rethlefsen S, Kay RM. Prevalence of specific gait abnormalities in children with cerebral palsy: influence of cerebral palsy subtype, age, and previous surgery. *J Pediatr Orthop* 2005; **25**: 79–83.
- Kim HY, Cha YH, Byun JY *et al*. Changes in gait parameters after femoral derotational osteotomy in cerebral palsy patients with medial femoral torsion. *J Pediatr Orthop B* 2018; **27**: 194–9.
- Aminian A, Vankoski SJ, Dias L *et al*. Spastic hemiplegic cerebral palsy and the femoral derotation osteotomy: effect at the pelvis and hip in the transverse plane during gait. *J Pediatr Orthop* 2003; **23**: 314–20.
- Yoo WJ, Choi IH, Cho T-J *et al*. Out-toeing and in-toeing in patients with Perthes disease: role of the femoral hump. *J Pediatr Orthop* 2008; **28**: 717–22.
- Presedo A, Simon A-L, Mallet C *et al*. Correlation between transverse plan kinematics and foot progression angle in children with spastic diplegia. *J Pediatr Orthop B* 2017; **26**: 211–6.
- Rethlefsen SA, Healy BS, Wren TAL *et al*. Causes of intoeing gait in children with cerebral palsy. *J Bone Joint Surg Am* 2006; **88**: 2175–80.
- Bruderer-Hofstetter M, Fenner V, Payne E *et al*. Gait deviations and compensations in pediatric patients with increased femoral torsion. *J Orthop Res* 2015; **33**: 155–62.
- Lerch TD, Steppacher SD, Liechti EF *et al*. One-third of hips after periacetabular osteotomy survive 30 years with good clinical results, no progression of arthritis, or conversion to THA. *Clin Orthop Relat Res* 2017; **475**: 1154–68.
- Tannast M, Siebenrock KA, Anderson SE. Femoroacetabular impingement: radiographic diagnosis—what the radiologist should know. *AJR Am J Roentgenol* 2007; **188**: 1540–52.
- Audenaert EA, Duquesne K, De Roeck J *et al*. Ischiofemoral impingement: the evolutionary cost of pelvic obstetric adaptation. *J Hip Preserv Surg* 2020; **7**: 677–87.
- Lerch TD, Boschung A, Todorski IAS *et al*. Femoroacetabular impingement patients with decreased femoral version have different impingement locations and intra- and extraarticular anterior subspace FAI on 3D-CT-based impingement simulation: implications for hip arthroscopy. *Am J Sports Med* 2019; **47**: 3120–32.
- Lerch TD, Degonda C, Schmaranzer F *et al*. Patient-specific 3-D magnetic resonance imaging-based dynamic simulation of hip impingement and range of motion can replace 3-D computed tomography-based simulation for patients with femoroacetabular impingement: implications for planning open hip preservation surgery and hip arthroscopy. *Am J Sports Med* 2019; **47**: 2966–77.
- van Uden CJT, Besser MP. Test-retest reliability of temporal and spatial gait characteristics measured with an instrumented walkway system (GAITRite). *BMC Musculoskelet Disord* 2004; **5**: 13.
- Webster KE, Wittwer JE, Feller JA. Validity of the GAITRite walkway system for the measurement of averaged and individual step parameters of gait. *Gait Posture* 2005; **22**: 317–21.
- Lai Y-C, Lin H-S, Pan H-F *et al*. Impact of foot progression angle on the distribution of plantar pressure in normal children. *Clin Biomech* 2014; **29**: 196–200.
- Seber S, Hazer B, Köse N *et al*. Rotational profile of the lower extremity and foot progression angle: computerized tomographic examination of 50 male adults. *Arch Orthop Trauma Surg* 2000; **120**: 255–8.
- Ho CS, Lin CJ, Chou YL *et al*. Foot progression angle and ankle joint complex in preschool children. *Clin Biomech* 2000; **15**: 271–7.
- Schmaranzer F, Lerch TD, Steppacher SD *et al*. Femoral cartilage damage occurs at the zone of femoral head necrosis and can be accurately detected on traction MR arthrography of the hip in patients

- undergoing joint preserving hip surgery. *J Hip Preserv Surg* 2021; **8**: 28–39.
40. Lerch TD, Novais EN, Schmaranzer F *et al.* What is the prevalence of cam deformity after prophylactic pinning of the contralateral asymptomatic hip in unilateral slipped capital femoral epiphysis? A 10-year minimum followup study. *Clin Orthop Relat Res* 2019; **477**: 1111–22.
 41. Murphy SB, Simon SR, Kijewski PK *et al.* Femoral anteversion. *J Bone Joint Surg Am* 1987; **69**: 1169–76.
 42. Schmaranzer F, Lerch TD, Siebenrock KA *et al.* Differences in femoral torsion among various measurement methods increase in hips with excessive femoral torsion. *Clin Orthop Relat Res* 2019; **477**: 1073–83.
 43. Waidelich HA, Strecker W, Schneider E. Computed tomographic torsion-angle and length measurement of the lower extremity. The methods, normal values and radiation load. *Rofo* 1992; **157**: 245–51.
 44. Liodakis E, Doxastaki I, Chu K *et al.* Reliability of the assessment of lower limb torsion using computed tomography: analysis of five different techniques. *Skeletal Radiol* 2012; **41**: 305–11.
 45. Goutallier D, Van Driessche S, Manicom O *et al.* Influence of lower-limb torsion on long-term outcomes of tibial valgus osteotomy for medial compartment knee osteoarthritis. *J Bone Joint Surg Am* 2006; **88**: 2439–47.
 46. Bredella MA, Azevedo DC, Oliveira AL *et al.* Pelvic morphology in ischiofemoral impingement. *Skeletal Radiol* 2015; **44**: 249–53.
 47. Schmaranzer F, Todorski IAS, Lerch TD *et al.* Intra-articular lesions: imaging and surgical correlation. *Semin Musculoskelet Radiol* 2017; **21**: 487–506.
 48. Zingg PO, Ulbrich EJ, Buehler TC *et al.* Surgical hip dislocation versus hip arthroscopy for femoroacetabular impingement: clinical and morphological short-term results. *Arch Orthop Trauma Surg* 2013; **133**: 69–79.
 49. Nilsson AK, Lohmander LS, Klässbo M *et al.* Hip disability and osteoarthritis outcome score (HOOS)—validity and responsiveness in total hip replacement. *BMC Musculoskelet Disord* 2003; **4**: 10.
 50. Hudson D. The rotational profile: a study of lower limb axial torsion, hip rotation, and the foot progression angle in healthy adults. *Gait Posture* 2016; **49**: 426–30.
 51. Cibulka MT, Winters K, Kampwerth T *et al.* Predicting foot progression angle during gait using two clinical measures in healthy adults, a preliminary study. *Int J Sports Phys Ther* 2016; **11**: 400–8.
 52. Radler C, Kranzl A, Manner HM *et al.* Torsional profile versus gait analysis: consistency between the anatomic torsion and the resulting gait pattern in patients with rotational malalignment of the lower extremity. *Gait Posture* 2010; **32**: 405–10.
 53. Kirit L, Karatosun V, Unver B *et al.* The reliability of hip scoring systems for total hip arthroplasty candidates: assessment by physical therapists. *Clin Rehabil* 2005; **19**: 659–61.
 54. Martin RL, Sekiya JK. The interrater reliability of 4 clinical tests used to assess individuals with musculoskeletal hip pain. *J Orthop Sports Phys Ther* 2008; **38**: 71–7.
 55. McWhirk LB, Glanzman AM. Within-session inter-rater reliability of goniometric measures in patients with spastic cerebral palsy. *Pediatr Phys Ther* 2006; **18**: 262–5.
 56. Schwartz MH, Trost JP, Werve RA. Measurement and management of errors in quantitative gait data. *Gait Posture* 2004; **20**: 196–203.
 57. Staheli LT, Clawson DK, Hubbard DD. Medial femoral torsion: experience with operative treatment. *Clin Orthop Relat Res* 1980; **146**: 222–5.
 58. D'aubigne RM, Postel M. Functional results of hip arthroplasty with acrylic prosthesis. *J Bone Joint Surg Am* 1954; **36-A**: 451–75.
 59. Lerch T, Schmaranzer F, Steppacher F *et al.* Most of patients with femoral derotation osteotomy for posterior extraarticular hip impingement and high femoral version would do surgery again. *Hip Int* 2022; **32**: 253–64. Epub 2020 Aug 31.