



Clinical neuroanatomy

Lesion-symptom mapping corroborates lateralization of verbal and nonverbal memory processes and identifies distributed brain networks responsible for memory dysfunction

Nadia Mock^{a,b,c,*}, Christian Balzer^a, Klemens Gutbrod^d, Bianca De Haan^e, Lutz Jäncke^b, Thierry Ettlin^a and Wiebke Trost^a

^a Research Department, Reha Rheinfelden, Rheinfelden, Switzerland

^b Department of Psychology, University of Zurich, Zurich, Switzerland

^c Department of Neurology, Zurich University Hospital, Zurich, Switzerland

^d Department of Neurology, Inselspital, Bern University Hospital, University of Bern, Bern, Switzerland

^e Division of Psychology, Department of Life Sciences, College of Health, Medicine and Life Sciences, Brunel University London, Uxbridge, UK

ARTICLE INFO

Article history:

Received 8 July 2021

Reviewed 30 September 2021

Revised 10 December 2021

Accepted 28 April 2022

Action editor Asaf Gilboa

Published online 16 May 2022

Keywords:

Verbal memory

Nonverbal memory

Lateralization

Lesion-symptom mapping

Clinical neuropsychology

ABSTRACT

Memory disorders are a common consequence of cerebrovascular accident (CVA). However, uncertainties remain about the exact anatomical correlates of memory impairment and the material-specific lateralization of memory function in the brain.

We used lesion-symptom mapping (LSM) in patients with first-time CVA to identify which brain structures are pivotal for verbal and nonverbal memory and to re-examine whether verbal and nonverbal memory functions are lateralized processes in the brain.

The cognitive performance of a relatively large cohort of 114 patients in five classic episodic memory tests was analysed with factor analysis. Two factors were extracted that distinguished the verbal and nonverbal components of these memory tests, and their scores were subsequently tested for anatomical correlates by combining univariate and multivariate LSM.

LSM analysis revealed for the verbal factor exclusively left-hemispheric insular, subcortical and adjacent white matter regions and for the nonverbal factor exclusively right-hemispheric temporal, occipital, insular, subcortical and adjacent white matter structures.

These results corroborate the long-standing hypothesis of a material-specific lateralization of memory function in the brain and confirm a robust association between right temporal lobe lesions and nonverbal memory dysfunction. The right-hemispheric correlates for the nonverbal aspects of episodic memory include not only classic memory structures in the medial temporal lobe but also a more distributed network that includes cortical and subcortical structures also known for implicit memory processes.

© 2022 The Author(s). Published by Elsevier Ltd. This is an open access article under the CC BY-NC-ND license (<http://creativecommons.org/licenses/by-nc-nd/4.0/>).

* Corresponding author. Frauenklinikstrasse 26, CH-8091, Zurich, Switzerland.

E-mail address: nadia.mock@usz.ch (N. Mock).

<https://doi.org/10.1016/j.cortex.2022.04.017>

0010-9452/© 2022 The Author(s). Published by Elsevier Ltd. This is an open access article under the CC BY-NC-ND license (<http://creativecommons.org/licenses/by-nc-nd/4.0/>).

1. Introduction

Remembering facts and events represents a cognitive function essential to establishing and maintaining personal identity. Episodic memory has been defined as the conscious recollection of personally lived experiences (Tulving, 1972, 2002). A cerebrovascular accident (CVA) can compromise memory, which can manifest in focal impairment of various memory functions, depending on the underlying brain lesion. The medial temporal lobe, and the hippocampus in particular, has traditionally been regarded as the brain structure most prominent in episodic memory, which is a form of explicit memory (Moscovitch, 1992; Scoville & Milner, 1957; Spiers et al., 2001; Squire, 2004). In contrast, subcortical structures such as the basal ganglia have been associated with implicit memory and more unconscious memory processes (Graf & Schacter, 1985; Heindel et al., 1989; Squire, 1987; Tranel et al., 1994). However, research over the years has suggested that memory processes are not organized by individual brain structures; instead, a network of brain regions is responsible for human memory (Ferguson et al., 2019; Jeong et al., 2015).

A classic distinction is made of the material that must be memorized: verbal memory, such as remembering a list of words, is distinguished from nonverbal visuospatial memory, such as remembering a previously copied set of figures. The predominance of the left hemisphere in verbal processing and of the right hemisphere in visuospatial processing has been known for decades (Wada & Rasmussen, 1960). Therefore, lateralization for verbal and nonverbal memory has been suggested (Milner, 1966) and confirmed in patient studies (Bellgowan et al., 1997; Binder et al., 2008; Chelune et al., 1991; Hermann et al., 1995; Milner, 1968, 1972; Pillon et al., 1999; Sabsevitz et al., 2001). Nonetheless, the dichotomy of verbal and nonverbal memory and their hemispheric lateralized representation in the brain is not entirely clear-cut. Whereas several studies of patients with intractable temporal lobe epilepsy have demonstrated a consistent relationship between the left temporal lobe and verbal memory performance, a reliable neuropsychological marker of the right temporal lobe for nonverbal memory has been lacking (Barr et al., 1997; Bell & Davies, 1998; Bell et al., 2011; Kneebone et al., 2007; Lee et al., 2002; Saling, 2009). Furthermore, studies with healthy subjects using functional brain imaging techniques such as functional magnetic resonance imaging (fMRI) have found that verbal and nonverbal memory functions correlate with activity in both left- and right-hemispheric structures (Blanchet et al., 2001; Manenti et al., 2011). However, study results from patients with intractable temporal lobe epilepsy cannot easily be generalized to other patient groups, such as CVA patients, because of adaptation processes and reorganization in the brain related to the common early onset of seizure disorders (Bell et al., 2011; Binder et al., 2008; Hermann et al., 1997; Marques et al., 2007). Conversely, fMRI paradigms potentially activate structures that are not absolutely necessary for a task (Godefroy et al., 2009; Richardson et al., 2004; Rorden & Karnath, 2004). Thus, investigating causal relationships for the contribution of a certain brain structure on a behavioural function demands other methodological approaches such as

lesion-symptom mapping (LSM) (Bates et al., 2003; de Haan & Karnath, 2018; Karnath et al., 2020; Medina et al., 2010).

LSM allows the statistical association of behavioural data with lesion data and permits the identification of the brain structures critical for specific behaviours. This method has been successfully applied for the investigation of various cognitive functions and neuropsychological conditions, including aphasia, neglect, decision making, working memory, and visuospatial construction (Bates et al., 2003; Biesbroek et al., 2014; Bowren et al., 2020; Gläscher et al., 2012; Paulraj et al., 2018; Preisig et al., 2016; Verdon et al., 2010). Moreover, LSM has been further refined in recent years and now consists not only of mass-univariate voxel-based lesion-symptom mapping (VLSM) approaches (Bates et al., 2003; Rorden & Brett, 2000) but also of more sophisticated multivariate methods that can account for the network character of anatomical correlates of specific cognitive functions (DeMarco & Turkeltaub, 2018; Karnath et al., 2020; Pustina et al., 2018; Zhang et al., 2014).

In this study, we applied univariate and multivariate LSM in a relatively large cohort of neurological patients with single first-time right- and/or left-hemispheric CVA (ischaemic or haemorrhagic; $n = 114$) to identify which brain structures are crucial for verbal and nonverbal memory functions. In contrast to previous studies of this type, we applied a comprehensive neuropsychological test battery comprising several verbal and nonverbal memory tests, thereby providing various memory metrics. This enabled us to more precisely delineate the brain areas involved in memory performance. A further aim of our study was to re-examine whether verbal and nonverbal memory functions are indeed controlled predominantly by left- and right-hemispheric brain areas.

2. Materials and methods

2.1. Subjects

Patients were recruited as inpatients at the Reha Rheinfelden rehabilitation clinic in Switzerland between December 2013 and December 2019. Written informed consent was obtained from each participant in accordance with the guidelines of the local ethics committee (Ethikkommission Nordwest-und Zentralschweiz EKNZ). Patients ($n = 145$) were recruited if they had suffered a single first-time ischaemic or haemorrhagic CVA and undergone standard neuropsychological testing during clinical care. Patients with severe acute CVA symptoms such as global aphasia were not considered. All patients were fluent German speakers and right-handed. No other previous cerebral damage, including neurodegenerative processes, no obstructive sleep apnoea syndrome, nor any psychiatric illnesses were reported in their medical histories. Patients had no prior history of drug or alcohol abuse. Patients ($n = 31$) that had at least one value missing from one of the five episodic memory tests were excluded. The final sample comprised 114 patients (40 female). Their age ranged from 20 years to 69 years (mean 54.30 years, SD 10.71 years) with on average 13.72 years of education (SD 3.30) (Table 1). The mean time between neuropsychological testing and CVA onset was 32.59 days (SD 25.49 days). Cognitive deficits were thus

assessed in the acute and subacute stages, when they are most pronounced. Brain imaging was performed in the acute stage, with a mean time of 4.11 days (SD 10.95 days) after CVA onset. The ratio of patients with left-hemispheric CVA and right-hemispheric CVA was almost balanced (Table 1): patients with right-hemispheric CVA accounted for 43.86% of the sample, compared to 40.35% of patients with left-hemispheric CVA and 15.79% with bilateral CVA. For additional information on frequencies of territories affected in each hemisphere, see Table 1.

2.2. Neuropsychological assessment

Neuropsychological testing was performed as standard during each patient's clinical stay for rehabilitation. For this purpose, the Materialien und Normwerte für die neuropsychologische Diagnostik (MNND) neuropsychological test battery (<http://www.normdaten.ch/>; Balzer et al., 2011) was used. The battery includes standardized and frequently used classic neuropsychological tests that assess memory, executive functions, attention, and visuospatial functions. The MNND contains five standard episodic memory tests that are administered orally and in paper-and-pencil versions (Table 2). To assess the verbal aspects of memory, we used two subtests: (i) Auditory-Verbal Learning Test (AVLT): patients hear a list of 15 words five times. After each repetition, they must recall the words. After the learning procedure, the patients must remember a second orally presented interfering word list. Then the first wordlist is asked again, once directly after the interfering list and once after a break of 30 min. (ii) Logical Memory (LM): patients hear a short story and have to

Table 1 – Characteristics of the study cohort. It should be noted that lesions can occur in multiple territories and that the exact numbers and the percentages of the territories do not sum up to the total of all patients with lesions in one hemisphere.

Characteristics	Study cohort <i>n</i> = 114 (%)
Demographic characteristics	
Age, mean (SD)	54.30 (10.71)
Female, <i>n</i> (%)	40 (35.09)
Education in years (SD)	13.72 (3.30)
CVA lesion location	
Right	50 (44)
ACA	3 (6)
MCA	37 (74)
PCA	9 (18)
I	6 (12)
Left	46 (40)
ACA	5 (11)
MCA	29 (63)
PCA	9 (20)
I	9 (20)
Bilateral	18 (16)
ACA	2 (11)
MCA	3 (17)
PCA	7 (39)
I	13 (72)

ACA = anterior cerebral artery, MCA = middle cerebral artery, PCA = posterior cerebral artery, I = infratentorial (including cerebellum and brainstem).

reproduce the content using as many of the same words as possible, once immediately after story presentation and once after a break of 30 min. To assess the nonverbal aspects of memory, we used three subtests: (iii) visual design learning test (VDLT): 15 abstract figures are presented five times, and patients must draw the figures from memory on a sheet of paper after each presentation. Following an interfering list of 15 figures, the first list of figures must be remembered and reproduced directly after, then again after a 30 min break. (iv) Nonverbal Learning and Memory Test for Routes (NLMTR; a modification of the Ruff-Light Trial Learning Test): a route is shown five times on a schematic map. The patient must draw the route on the map after each presentation. After the learning procedure, a second interfering route is presented and must again be reproduced on the map. Following the interfering route, the patient must remember and reproduce the originally learned route, once directly after the interfering route and once after a 30 min break. (v) The delayed recall of the Rey Complex Figure Test (RCFT): patients are asked to copy a complex figure. After a distraction of 20 min, the figure must be drawn from memory on a sheet of paper. For a more detailed description of these tests, see Lezak et al. (2004).

After each neuropsychological testing, the examiner was asked to rate the influence of acute CVA symptoms such as aphasia, neglect, and hemianopia on the test results on a scale from 0 to 3 (Supplement Table S1). The influence of these acute CVA symptoms was described as generally low; in only three cases was the impact described as possible to have influenced the results. To test the impact of these most symptomatic cases, the analyses described below were repeated without these cases. The results showed that this exclusion did not substantially affect the outcome of the LSM analyses (Supplement Table S2). We therefore present the analyses and results from the original sample of 114 patients.

2.3. Behavioural analysis

The patients' behavioural performance in the five episodic memory tests was transformed to *z* scores according to the normative data provided by the MNND, stratified by age, sex, and education (Table S3). Some of the memory tests do not provide one single outcome but measure several aspects of memory processes. All memory tests used here measure recall performance, but AVLT, VDLT, and NLMTR also measure learning performance and AVLT, VDLT, and NLMTR recognition performance. All these measures were entered as individual variables in the analyses. To reduce the number of variables for subsequent analyses, a factor analysis was performed on the *z* scores of the five memory tests. The factor analysis was performed with the Statistical Package for the Social Sciences 26 (<https://www.ibm.com/ch-de/products/spss-statistics>). A varimax rotation of the factor solution was chosen to obtain orthogonal factors. A two-dimensional structure of the data was assumed that would separate the verbal and nonverbal aspects of memory, so two factors were extracted. The relative magnitude of each resulting factor was then extracted for each patient with the Anderson-Rubin method to ensure that the factor scores were uncorrelated. The resulting factor scores were subsequently used as behavioural variables for further lesion-symptom analyses.

Table 2 – Test procedures for episodic memory which are included in the neuropsychological test battery MNND.

Subtest	Adapted from	Description	Test parameter
Memory tests			
Auditory-Verbal Learning Test (AVLT)	RAVLT (Rey, 1958, 1964)	Word list learning	<ul style="list-style-type: none"> ✓ Sum of learned words (1–5) ✓ Short delay ✓ Long delay ✓ Recognition
Visual Design Learning Test (VDLT)	RVDLT (Rey, 1964; Spreen & Strauss, 1991)	Figure list learning	<ul style="list-style-type: none"> ✓ Sum of learned figures (1–5) ✓ Short delay ✓ Long delay ✓ Recognition
Nonverbal Learning and Memory Test for Routes (NLMTR)	RULIT (Ruff & Allen, 1999; Ruff et al., 1996)	Route learning	<ul style="list-style-type: none"> ✓ Sum of learned path sections (1–5) ✓ Short delay ✓ Long delay
Logical Memory (LM)	WMS-R/WMS-III (Wechsler, 1987, 1997)	Text recall	<ul style="list-style-type: none"> ✓ Short delay ✓ Long delay
Rey Complex Figure Test (RCFT)	RCFT (Rey, 1941; Taylor, 1969)	Figural memory	<ul style="list-style-type: none"> ✓ Long delay

2.4. Lesion maps

Each patient underwent a standard radiological examination in the acute CVA stage, from which MR ($n = 108$) and CT images ($n = 37$) were obtained. Because the brain images were acquired in different primary care hospitals, the scanning procedure for image acquisition was not uniform. Images were acquired on 1.5T or 3T scanners. The lesions were drawn directly onto the MR or CT image with MRICron software (Rorden & Brett, 2000; <https://www.nitrc.org/projects/mricron>) by a trained clinical neuropsychologist blind to the patient's diagnosis. All lesion maps were double-checked by a neuroradiologist. Brain images and lesions were then reoriented to the anterior commissure using Statistical Parametric Mapping SPM8 (<http://www.fil.ion.ucl.ac.uk/spm>) running in Matlab (<http://www.mathworks.com/>) and were then mapped into $1 \times 1 \times 1$ mm stereotaxic space with the spatial normalization algorithms provided by the Clinical Toolbox (Rorden et al., 2012). Because no high-resolution T1 brain images were available, no segmentation-based normalization procedure could be applied. The quality of normalization was evaluated through visual inspection and was judged satisfactory for all patients. The normalized lesion images were then used for further statistical analysis.

2.5. Brain imaging and lesion analysis

LSM was employed in this study to investigate the relationship between performance in standard clinical memory tests and the localization of brain lesions (Rorden & Karnath, 2004). We applied two lesion analysis approaches: VLSM, a standardized mass-univariate approach, identifies relationships between behaviour and lesion in each voxel individually (Bates et al., 2003), whereas a more recent multivariate LSM approach (Pustina et al., 2018) examines the joint contribution of multiple voxels, representing brain networks, to account for a given behaviour (Karnath et al., 2020). Both univariate and multivariate approaches have advantages and disadvantages (for an overview, see Ivanova et al., 2021). Therefore, a recent

suggestion is to obtain the most robust results by combining concordant findings from the two approaches (Ivanova et al., 2021).

For the voxel-wise mass-univariate analyses, we used the Non-Parametric Mapping (NPM) software, which is provided as part of the MRICron package (version 1.0.20190902) (Rorden et al., 2007), with nonparametric Brunner-Munzel (BM) tests. The factor scores for the two memory factors were entered as continuous variables in two analyses, one for each factor separately. Only voxels with lesions in at least 5% of the patients were included in the analyses. We adopted a significance threshold of $P < .05$ with false discovery rate (FDR) correction for multiple comparisons.

For the multivariate approach, we used the Lesymap package (version 0.0.0.9221), which runs in R (version 4.0.2; 2020-06-22) and is based on the ANTsR packages (version 0.5.6.2) to apply the sparse canonical correlation analysis for neuroimaging (SCCAN) technique (Pustina et al., 2018). SCCAN is a technique that gradually selects a multivariate model of voxels that correlate optimally with behaviour by identifying optimal sparseness through cross-validations. This procedure proposes a group of voxels as a multivariate solution that provides the best explanation of the behavioural data with one significance value for the entire solution. Therefore, the significance threshold does not have to be corrected for multiple comparisons. Only voxels affected by lesions in at least 5% of the patients were considered for the analyses, and a significance threshold of $P < .05$ was adopted.

2.6. Control analysis

To evaluate the potential specificity of the obtained LSM results for episodic memory, we calculated a control analysis (see Supplement material). Following the same methodological procedure as for the main analysis of episodic memory tests, we computed a factor analysis from six verbal and nonverbal non-mnemonic tests (Supplement Tables S4 and S5), again resulting in two factors that distinguished verbal

and nonverbal aspects (Supplement Tables S6 and S7). The LSM analyses were calculated subsequently with the impact of these control factors regressed out from the original verbal and nonverbal memory factors.

2.7. Preregistration, reporting, and availability

No part of the study procedure or analyses was preregistered prior to the research being conducted. We report how we determined our sample size, all data exclusions, all inclusion and exclusion criteria, whether inclusion and exclusion criteria were established prior to data analysis, all manipulations, and all measures in the study. The conditions of our ethics approval do not permit public archiving of the data. The datasets generated and analysed during the current study are available from the corresponding author on reasonable request and on prior consultation with the ethics committee.

3. Results

3.1. Behavioural results

Factor analysis of the z scores in the five memory tests with a fixed number of factors reveals that the two factors explain 66.57% of the total variance (Supplement Table S8). Table 3 shows the factor loadings of each test for these two independent factors. The factor loadings of the individual tests indicate that the two factors separate verbal and nonverbal memory tests quite accurately. AVLT and LM, which are usually classified as verbal memory tests, show higher loadings on the first factor, subsequently called the verbal factor; NLMTR and RCFT, usually classified as nonverbal memory tests, show higher loadings on the second factor, subsequently called the nonverbal factor. However, the VDLT nonverbal memory test shows medium loadings for both factors.

3.2. Lesion analysis

The overlap of cerebral lesions in all 114 patients is shown in Fig. 1. The distribution of lesions was inhomogeneous across the brain with the highest prevalence of lesions in the right-sided vascular territory of the middle cerebral artery and with substantially less coverage in left-hemispheric regions (Fig. 1). This is also borne out by the results of a power analysis (Figure S1) for the univariate approach, which finds a lower number of voxels with sufficient power to detect an effect in the left hemisphere than in the right. For the multivariate

Table 3 – Relative loading of each clinical test for the two factors identified by the factorial analysis. Extraction Method: Principal Component Analysis. Rotation Method: Varimax with Kaiser Normalization (Rotation converged in 3 iterations).

Rotated Component Matrix	Component	
	1	2
AVLT_15	.85	.16
AVLT_SD	.84	.18
AVLT_LD	.87	.14
AVLT_RecFP	.84	.13
LM_SD	.68	-.08
LM_LD	.70	-.01
VDLT_15	.70	.55
VDLT_SD	.70	.51
VDLT_LD	.65	.55
VDLT_RecFP	.41	.58
NLMTR_15	-.05	.80
NLMTR_SD	.02	.90
NLMTR_LD	.01	.88
RCFT_LD	.34	.51

Abbreviations: Auditory-Verbal Learning Test (AVLT); Logical Memory (LM); Visual Design Learning Test (VDLT); Nonverbal Learning and Memory Test for Routes (NLMTR); Rey Complex Figure Test (RCFT); Sum of learned items (15); Short Delay (SD); Long Delay (LD); Recognition without false-positives (RecFP).

approach, the Lesymap software does not provide power calculations (Pustina et al., 2018).

Univariate and multivariate LSM analyses identified several clusters of voxels where damage significantly predicted poorer memory performance.

3.2.1. Memory factors

The univariate analysis with NPM for the verbal factor revealed significant involvement only of left-hemispheric brain regions, the left insula and the left putamen, with an extension into the adjacent white matter of the anterior corona radiata and the external capsule (see yellow voxels in Fig. 2A). For the nonverbal factor, significant involvement of right-hemispheric brain areas was evident only in temporal structures (hippocampus, fusiform gyrus, inferior temporal gyrus), the insula, inferior frontal gyrus (pars opercularis), subcortical structures (caudate nucleus, putamen, pallidum, thalamus), and occipital structures (calcarine fissure, lingual gyrus). Right-sided white matter involvement was also found in the fornix, superior longitudinal fasciculus, superior fronto-

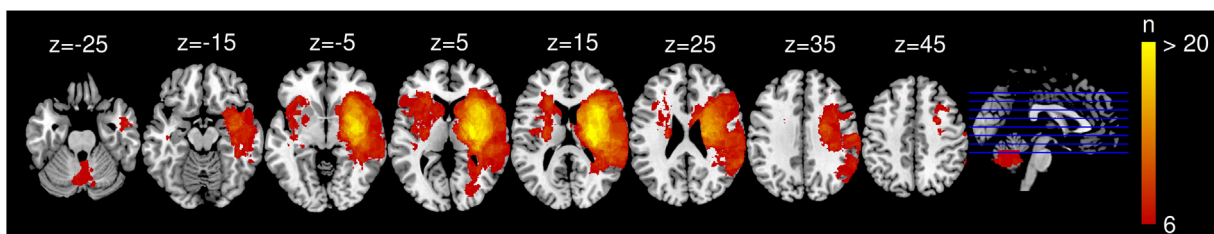


Fig. 1 – Lesion overlap for $n = 114$ patients. Voxels that are damaged in at least 6 patients are projected on a T1 template in MRIcron. Images shown in neurological orientation (right = right).

occipital fasciculus, internal capsule (anterior and posterior limb, retrolenticular part), corona radiata (anterior, posterior and superior), posterior thalamic radiation, sagittal stratum, body of corpus callosum, and external capsule (see yellow voxels in Fig. 2B). The univariate results for the verbal and nonverbal factor are provided in Table 4.

Multivariate analysis with Lesymap produced similar results for the verbal factor: an exclusively left-hemispheric solution with involvement of the anterior insula, the inferior frontal gyrus (pars triangularis), the putamen, the anterior corona radiata, the internal (anterior limb), and external capsule (see blue voxels in Fig. 2A). In contrast, an exclusively right-hemispheric solution was found for the nonverbal factor (see blue voxels in Fig. 2B), where damage to temporal structures (hippocampus, fusiform gyrus), the insula, subcortical structures (caudate nucleus, putamen, pallidum, thalamus), and occipital structures (calcarine fissure, lingual gyrus, middle occipital lobe) again significantly predicted poorer behavioural scores. In addition, white matter involvement was again found, where damage to fornix, superior fronto-occipital fasciculus, internal capsule (posterior limb and retrolenticular part), superior corona radiata, posterior thalamic radiation, sagittal stratum, and external capsule significantly predicted poorer behavioural results. The multivariate results for the verbal and nonverbal factors are provided in Table 4.

The anatomical correlates of the verbal and nonverbal factor overlapped strongly in the univariate and multivariate

lesion analyses (Fig. 2). Because combining concordant results has been recommended to identify particularly robust findings (Ivanova et al., 2021), we only discuss further regions that were identified in both analyses (Fig. 2 and Table 4).

3.2.2. Control analysis

The control analysis of the memory factors with the impact of non-mnemonic control factors regressed out, subsequently called adjusted memory factors, found no significant result for the adjusted verbal factor. For the adjusted nonverbal factor, a significant solution was obtained in the uni- and multivariate LSM analyses that largely overlapped with the LSM results of the original nonverbal memory factor (see supplement material, supplement Table S9 and supplement Figure S2). The concordant findings of the two methods for the adjusted nonverbal memory factor showed only right-hemispheric brain regions that include temporal (hippocampus), insular, frontal (inferior frontal gyrus pars opercularis), subcortical (caudate nucleus, pallidum, thalamus), and occipital structures (calcarine fissure) with adjacent white matter structures (internal capsule, corona radiata, external capsule, superior fronto-occipital fasciculus).

4. Discussion

The aim of the present study was to identify anatomical correlates of episodic memory and to re-examine material-

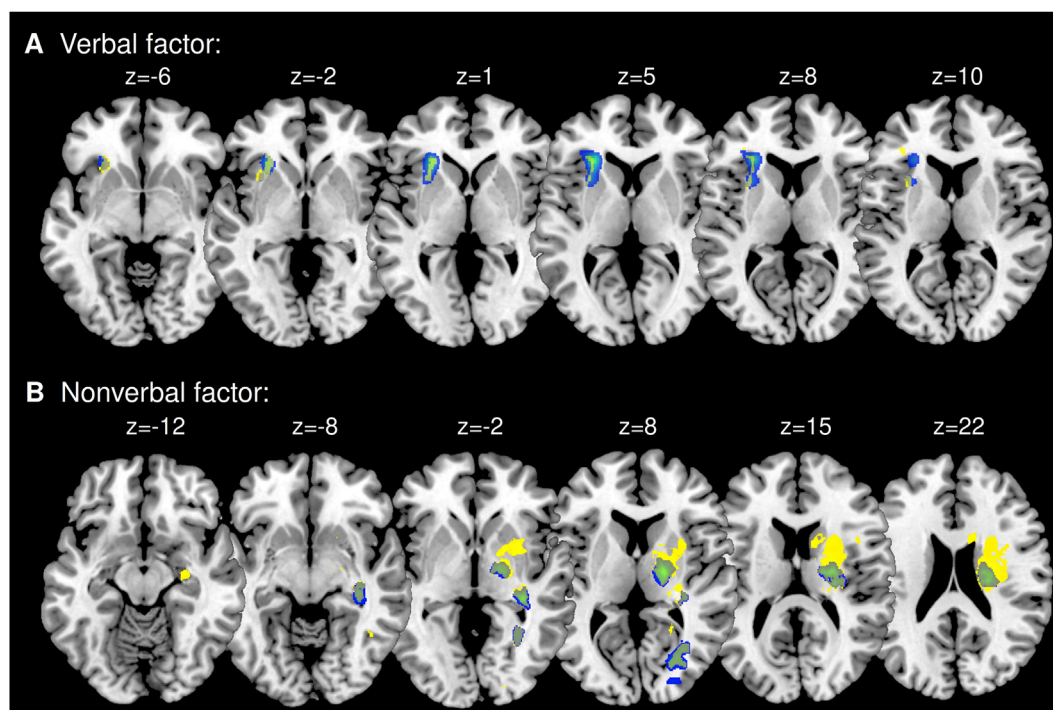


Fig. 2 – Univariate (NPM) and multivariate (Lesymap) LSM results for verbal factor (A) and nonverbal factor (B). Anatomical correlates resulting from univariate LSM are shown in yellow, structures resulting from multivariate LSM in blue. The overlap of significant voxels that were part of the univariate and the multivariate LSM results are depicted in green. Only statistically significant voxels ($P \leq .05$) are shown. Slices correspond with MNI-152 z coordinates. Images shown in neurological orientation.

Table 4 – Univariate (NPM) and multivariate (Lesymap) LSM results for the verbal and nonverbal factor.

Anatomical regions (AAL & JHU Atlas)	Region size in voxels (n)	NPM		Lesymap	
		Significant voxels (n)	Significant voxels (%)	Significant voxels (n)	Significant voxels (%)
Verbal factor					
Grey matter					
Insula_L*	15,025	474	3.2	1336	8.9
Frontal_Inf_Tri_L	20,104			105	.5
Putamen_L*	7942	61	.8	403	5.1
White matter					
Anterior_limb_of_internal_capsule_L	3138			102	3.3
Anterior_corona_radiata_L*	6849	315	4.6	975	14.2
External_capsule_L*	5611	351	6.3	662	11.8
Nonverbal factor					
Grey matter					
Hippocampus_R*	7606	632	8.3	662	8.7
Fusiform_R*	20,227	134	.7	112	.6
Temporal_Inf_R	28,468	63	.2		
Insula_R*	14,128	685	4.8	268	1.9
Frontal_Inf_Oper_R	11,174	60	.5		
Caudate_R*	7941	971	12.2	232	2.9
Putamen_R*	8510	2543	29.9	89	1
Pallidum_R*	2188	1346	61.5	221	10.1
Thalamus_R*	8399	1402	16.7	1509	18
Calcarine_R*	14,885	472	3.2	609	4.1
Lingual_R*	18,450	161	.9	138	.7
Occipital_Mid_R	16,512			152	.9
White matter					
Body_of_corpus_callosum_R	13,711	53	.4		
Anterior_limb_of_internal_capsule_R	3018	854	28.3		
Posterior_limb_of_internal_capsule_R*	3752	2146	57.2	2082	55.5
Retrolecticular_part_of_internal_capsule_R*	2469	584	23.7	525	21.3
Anterior_corona_radiata_R	6852	142	2.1		
Superior_corona_radiata_R*	7508	3031	40.4	1441	19.2
Posterior_corona_radiata_R	3714	84	2.3		
Posterior_thalamic_radiation_(include_optic_radiation)_R*	3978	763	19.2	888	22.3
Sagittal_stratum_(include_inferior_longitudinal_fasciculus_and_inferior_fronto-occipital_fasciculus)_R*	2231	135	6.1	178	8
External_capsule_R*	5587	1476	26.4	248	4.4
Fornix_(cres)/_Stria_terminalis_R*	1125	142	12.6	71	6.3
Superior_longitudinal_fasciculus_R	6605	624	9.4		
Superior_fronto-occipital_fasciculus_R*	507	215	42.4	82	16.2

Regions with a cluster threshold of at least 50 significant voxels are listed. Asterisks mark the concordant findings for the univariate and multivariate LSM results.

specific lateralization in the brain. In a relatively large cohort of patients ($n = 114$) with first-time ischaemic or haemorrhagic CVA, we used univariate (VLSM) and multivariate (Lesymap) LSM coupled with a factor analytic approach. The factor analysis of the performances across several memory tests allowed the identification of two independent factors that explained 67% of the variance observed in these tests. The first factor could be assigned to verbal memory aspects and the second factor to nonverbal memory aspects. In line with this behavioural data, concordant findings in both univariate and multivariate LSM analyses revealed two independent clusters of anatomical correlates, with the verbal factor involving exclusively left-hemispheric insular and subcortical and adjacent white matter regions and the nonverbal factor involving exclusively right-hemispheric regions with temporal, occipital, insular, subcortical and adjacent white matter

structures. These results corroborate the lateralization of memory frequently discussed in the literature and show a distributed neural network of cortical and subcortical structures relevant to diminished memory performance.

4.1. Verbal memory factor

The verbal aspects of memory were manifested in this factor by high loadings of two verbal memory tests, logical memory and the auditory verbal memory test, and medium loadings of the visual design learning test. The verbal factor explained 40% of the total variance. The visual design learning test, traditionally classified as a typical nonverbal memory test, surprisingly contributes to both verbal and nonverbal factors almost equally, suggesting that a predominantly nonverbal test seems also to include a verbal component. This finding

could explain why aphasic patients sometimes show deficits in nonverbal memory tests: they might be impaired in using helpful verbalization techniques (Brewer, 1969; Gainotti et al., 1978, 1983; Zannino et al., 2020).

LSM analyses revealed the anatomical correlates for the verbal factor to be the left insula and putamen with extension into the adjacent white matter structures, namely the projection fibres, corona radiata and external capsule. These results are consistent with findings that CVA patients with left insular lesions (Manes et al., 1999) show impaired verbal-episodic memory performance and that Alzheimer's patients display insular atrophy (Fan et al., 2008; Xie et al., 2012) and lower activation of the anterior insula during verbal memory retrieval (Dhanjal & Wise, 2014). Insular activation is also found in memory tasks in patients with hippocampal sclerosis and discussed as a compensatory memory structure in hippocampal dysfunction (de Paula França Resende et al., 2021; Sidhu et al., 2013). In addition, several studies have shown the role of basal ganglia (Sadeh et al., 2011; Vakil et al., 2004), especially the putamen (Adcock et al., 2006; Prince et al., 2005; Sperling et al., 2003), in memory performance. Furthermore, the disruption of cortico-subcortical connectivity by a lesion in projection fibres can lead to loss of memory information and disruption of control processes that coordinate encoding and retrieval (Sullivan & Pfefferbaum, 2006).

Due to the relatively low lesion density in the left hemisphere of the brain and especially in the medial temporal lobe, the anatomical correlates obtained from our sample can be described as sufficient for the verbal memory process. However, we cannot exclude the possibility that other left hemispheric regions beyond those we identified also play a role in verbal memory processes but that we were unable to detect these due to insufficient statistical power.

4.2. Nonverbal memory factor

The nonverbal aspects of memory were manifested in this factor by high loadings of the nonverbal learning and memory test for routes and the delayed recall of the Rey Complex Figure and medium loadings for the visual design learning test. The nonverbal factor explained 27% of the total variance. LSM analysis revealed the anatomical correlate for this factor to be in right-hemispheric temporal (hippocampus, fusiform gyrus), occipital (calcarine fissure, lingual gyrus), insular, and subcortical structures (caudate nucleus, putamen, pallidum, thalamus) and adjacent white matter tracts.

4.3. Temporal and occipital structures

The LSM analyses show involvement of the right hippocampus for the nonverbal factor, which was expected given the prominent role of the medial temporal lobe and the hippocampus in memory processes such as learning, memory, and spatial navigation (Burgess et al., 2002; Diana et al., 2007; Moscovitch, 1992; Scoville & Milner, 1957; Spiers et al., 2001; Squire, 2004). Our result that lesions in the hippocampus are associated with worse memory performance therefore is in line with the assumption that the hippocampus is crucial to episodic memory. Another temporal structure revealed by the LSM analysis is the right fusiform gyrus. The fusiform gyrus is

part of the secondary visual cortex and has connections to medial temporal and frontal lobes (Palejwala et al., 2020); it has thus been identified as a key structure for the processing, storage, and holistic recognition of faces (Gerrits et al., 2019; Kanwisher et al., 1997) and for the memory of object properties (Moscovitch et al., 1995). The involvement of the fusiform gyrus in nonverbal memory performance seems plausible given that in nonverbal memory tests the encoding not only of the individual components of an object but also the holistic perception of its indecomposable whole is favourable for memory performance (Barr, 1997; Tanaka et al., 2019).

The occipital anatomical correlates for the nonverbal factor include both brain structures associated with higher-order visual processing such as the lingual gyrus (Machielsen et al., 2000), and the calcarine fissure, which contains the primary visual cortex. The primary visual cortex, responsible for low-level visual processing and discrimination (Engel et al., 1997), has also been associated with implicit memory such as unconscious priming effects, recognition memory (Rosenthal et al., 2016; Rosenthal & Soto, 2016; Slotnick & Schacter, 2004), and mental imagery (Stephan-Otto et al., 2017).

The fact that damage in visual processing areas can be associated with functional impairment of nonverbal memory suggests that a lesion in early and higher-order visual processing pathways can disrupt the storage and recall of visual information. This might be due to an impaired sensory-specific reactivation, which seems to be necessary for successful memory performance (Wheeler et al., 2000, 2006). Conversely, the involvement of visual processing pathways in our LSM results could be the consequence of visual impairment, as in hemianopia. Performing the LSM analysis without the most symptomatic cases of such sequelae of CVA revealed largely overlapping anatomical correlates, including temporal, insular, occipital (calcarine fissure), and subcortical structures (see Supplement Table S4). However, the right fusiform gyrus and the lingual gyrus were indeed no longer part of the LSM results. Lesions in these structures may lead to hemianopia (Bogousslavsky et al., 1987). Accordingly, the anatomical correlates identified in the fusiform and lingual gyrus seem to be due to the symptoms of hemianopia compromising the performance in nonverbal memory tests.

4.4. Insula

As discussed for the verbal factor, the insula plays an important role in memory processes due to its functional reciprocal connections with the temporal lobe (Xie et al., 2012).

4.5. Subcortical structures

Apart from the involvement of cortical structures, we also identified several subcortical structures that play a role in nonverbal aspects of memory tests, including the thalamus, putamen, caudate nucleus, and pallidum. Lesions in the thalamus have been shown to impair the formation of memory (Kopelman et al., 2009; Marchand et al., 2014; Wolff & Vann, 2019). In particular, the anterior thalamus, due to its connections to the hippocampus and its involvement in the Papez-circuit, represents an important memory structure

(Aggleton et al., 1986, 2016; Hyman et al., 1990; Leszczyński & Staudigl, 2016; Tsivilis et al., 2008).

The basal ganglia (caudate nucleus, putamen, pallidum) have often been shown to play a role in implicit memory processes such as skill learning and habit formation (H. H. Yin & Knowlton, 2006). The contribution of striatal regions to explicit memory has only recently received attention (Clos et al., 2015; Duff et al., 2010; Herweg et al., 2016; Scimeca & Badre, 2012). The striatum is now known to interact with such other brain regions as the hippocampus and prefrontal cortex and acts as a selective filter for representations to be encoded (Frank et al., 2001; Grahn et al., 2009; Lisman & Grace, 2005), such as promoting goal-relevant decisions in recall and guiding cognitive control in episodic and semantic memory (Scimeca & Badre, 2012). Furthermore, the basal ganglia and their important involvement in time tracking and temporal order processing (Grahn & Rowe, 2009; Nozaradan et al., 2017) also seem to play a prominent role in implicit sequence learning (Janacek et al., 2020; Rosenthal et al., 2016).

The fact that our LSM results for the nonverbal factor involve subcortical structures such as the basal ganglia suggests that these structures also play a role in nonverbal memory performance. In the nonverbal memory tests we used, the visual material must first be learned by manually reproducing the pictorial information and then storing it, possibly as a series of short movement sequences. One reason for impaired memory performance might be that the information about the order of these sequences is no longer available due to basal ganglia damage (Reber et al., 2011).

4.6. White matter fibre tracts

In our study, various projection (capsula interna, capsula externa, corona radiata, thalamic radiation, fornix) and association tracts (sagittal stratum with inferior longitudinal fasciculus and inferior fronto-occipital fasciculus, superior fronto-occipital fasciculus) were found to be critical for memory function. The integrity of white matter tracts is known to be crucial for cognitive functioning (Biesbroek et al., 2016, 2013; Gunning-Dixon & Raz, 2000; Rizvi et al., 2020; Smith et al., 2011; M. Yin et al., 2019) and for long-term and short-term memory in particular (Begré et al., 2007; Brickman et al., 2006; Charlton et al., 2010; Li et al., 2018; Nordahl et al., 2006; Smith et al., 2011). Within projection tracts, the fornix as part of the Papez-circuit, the corticospinal and anterior thalamic tract, and the anterior internal capsule have been shown to be related to memory performance (Aggleton et al., 2016; Rizvi et al., 2020; Smith et al., 2011). For association tracts, lesions in the inferior fronto-occipital fasciculus and the inferior longitudinal fasciculus have been associated with memory deterioration (Niogi et al., 2008; Rizvi et al., 2020).

In our results, the white matter structures that showed the most extended lesion involvement for the nonverbal factor were the posterior limb and the retrolenticular part of the internal capsule and the posterior thalamic radiation. These parieto-occipital projection fibres link the thalamus and the occipital cortex, and thus seem to play a role in visual processing. It thus seems that lesions in these white matter fibres might lead to a disconnection syndrome, impairing nonverbal memory function.

4.7. Lateralization

Our findings that the anatomical correlates of the verbal factor were exclusively left-sided regions and of the nonverbal factor exclusively right-sided regions reinforce Milner's (Milner, 1966) longstanding hypothesis that verbal memory is controlled by the left hemisphere and nonverbal memory by the right hemisphere. This confirmation stands even though we could identify fewer brain regions for the verbal factor than for the nonverbal factor, most likely due to lower levels of lesion overlap in the left than the right hemisphere in our patient cohort. Several studies have demonstrated material-specific lateralization, mostly in patients with intractable temporal lobe epilepsy (Bonelli et al., 2010; Milner, 1970, 1972) and in healthy individuals (Chi et al., 2010; Kelley et al., 1998; Sidhu et al., 2013). However, although previous research has demonstrated a robust association of left temporal lobe dysfunction with verbal memory tasks, the detection of right temporal lobe dysfunction with nonverbal memory tasks has remained elusive (Kneebone et al., 2007; Saling, 2009). Several reasons have been proposed for this incongruity. The right temporal regions have been suggested to be less strongly associated with their functional correlates than those of the left hemisphere (Rausch, 1991). Some authors also argue that stimuli can often be verbalized in nonverbal memory tests and that therefore individuals with right hemispheric damage are able to use preserved verbal processing in these tests (Gillespie et al., 2006; Golby et al., 2001; Helmstaedter et al., 1995; Zannino et al., 2020). Furthermore, the construction of nonverbal memory tests may not allow aspects of right temporal functioning to be measured (Barr et al., 1997; McDermid Vaz, 2004). Due to our factor-analytical procedure and the extraction of two orthogonally independent factors, we were able to circumvent these issues by extracting pure verbal and nonverbal memory components across several memory tests and identifying their anatomical correlates. One strength of our study is that our statistical approach enables the demonstration of a robust association between right temporal lobe lesions and nonverbal memory dysfunction.

4.8. Distributed brain network for disrupted memory function

The anatomical correlates of the verbal and nonverbal memory factors include not only typical memory structures but also a distributed network of cortical and subcortical structures. This is in line with previous research that described networks of interconnected brain regions relevant to memory performance such as the Papez circuit (Aggleton & Brown, 1999; Papez, 1937), the default mode network (Sestieri et al., 2011), and the functional network linking presubiculum and retrosplenial cortex (Ferguson et al., 2019). Closer examination of the right-sided network revealed by our nonverbal factor indicates that not only cortical brain regions such as the medial temporal lobe typically known for explicit episodic memory processes are involved but also subcortical structures such as the basal ganglia, previously known to be responsible for more unconscious and implicit memory processes such as visual priming, skill, and sequence learning. Traditionally, the distinction between the explicit and the implicit memory

systems is based on the degree of awareness (Berry et al., 2014; Tulving & Schacter, 1990). However, this division into independently functioning memory systems by the criterion of awareness has repeatedly been questioned (Henke, 2010; Kinder & Shanks, 2001). More recent models refer to a single memory system and suggest a continuity between implicit and explicit memory (Berry et al., 2014; Mazancieux et al., 2020; Park & Donaldson, 2016). Others propose two interlocking processes in remembering and assume an initial unconscious rapid recall followed by a slower conscious recall (Moscovitch, 2008). Our results, which reveal anatomical correlates for episodic memory performance in regions known for both explicit and implicit memory processes, are congruent with this modern view of rather overlapping explicit and implicit processes, but more research is needed to test this aspect explicitly.

It is important to note that even if the distributed anatomical correlates obtained with LSM are causally related to a diminished memory performance in the clinical memory tests applied, we do not claim that the anatomical correlates are specific for memory. Performance in a clinical memory test is dependent on other cognitive functions such as attention and executive functions (Chun & Turk-Browne, 2007; Duff et al., 2005; Tremont et al., 2000). The control analysis presented in the [supplement material](#) represents an attempt to remove the impact of verbal and nonverbal aspects of the non-mnemonic tests of attention span and executive functions. Although our findings indicate a crucial role of the right-hemispheric regions identified here in episodic memory, a parallel role cannot be confirmed for the left-hemispheric regions because they do not reach significance in the control analysis. However, the interrelatedness of cognitive functions render disentangling these impacts without losing essential components of memory function very challenging. Furthermore, the impact of other cognitive functions, such as visual perception, could have been controlled for; consequently, such a control analysis should be treated with caution and regarded as suboptimal proof of specificity for memory function.

4.9. Limitations

Our study exhibits several limitations. Despite a similar number of patients with left- and right-hemispheric lesions (Table 1), the overlap of all lesions shows that substantially fewer regions were covered in the left hemisphere (Fig. 1). One reason for this might be that patients with global aphasia were not assigned for neuropsychological testing at this early stage of rehabilitation, because standard neuropsychological testing would have been biased by compromised speech production or language comprehension. Therefore, the patients included, who suffered only from relatively mild aphasia, if any, could have had smaller lesion sizes in the left hemisphere, resulting in a reduced lesion overlap. This clear shortcoming of our study leads to a reduced statistical power to detect significant results in left-hemispheric brain structures. Thus, we cannot claim to have investigated the entire cerebral network that could lead to verbal amnesia. Nonetheless, we assume the anatomical correlates obtained here to be sufficient for the memory process, especially because our sample provides enough statistical power in the regions

concerned (Figure S1). In addition, we were able to corroborate our results with two different methodological approaches: a standard univariate method that has widely been used in the literature and a more recently developed multivariate method, which further affirms the robustness of our findings. This procedure of corroborating the results across the two methods and considering regions overlapped by both analyses has recently also been suggested to increase confidence in the results (Ivanova et al., 2021).

Another limitation is that we used the factor loadings of a factor analysis that combines the contribution of various clinical memory tests as a behavioural variable instead of using individual test parameters. This procedure has the disadvantage that the results cannot be interpreted for each individual memory test and that memory processes such as encoding, retrieval, and recognition cannot be distinguished. Instead, we opted to use a factor-analytic approach to avoid the issue of multiple testing with our synthesized but orthogonal factors. However, our approach also allows the identification of brain regions whose impairment leads to a worsening of memory performance irrespective of the individual memory process. This is particularly relevant because in everyday life, the type of memory deficit is less important than its mere presence and consequences.

Another limitation is that our approach did not enable us to quantify the hemispheric contribution to verbal and nonverbal aspects of memory. Future work could apply more recent methods that allow the quantification of hemisphere-specific aspects, for example using machine learning and Bayesian hierarchical modelling (Bonkhoff et al., 2021).

Finally, we did not systematically check for the presence of depression. Consequently, we cannot exclude the negative influence of emotional stress on cognition. However, the fact that our patients could be clinically examined, and that compliance was sufficient relativizes this limitation, in our view.

5. Conclusion

Our results show that verbal and nonverbal memory processes are anatomically distinct lateralized processes in the brain. Importantly, our data allowed in-depth investigation of right-hemispheric brain structures and confirmed a robust association between right temporal lobe lesions and nonverbal memory dysfunction. The neuroanatomical correlates of nonverbal memory involve not only classical memory structures in the medial temporal lobe but also a more distributed network of posterior cortical and subcortical structures, including the basal ganglia. This seems to suggest that lesions in regions also known to be responsible for implicit memory processes such as visual priming and skill learning are sufficient to disrupt nonverbal episodic memory performance.

Funding

This research did not receive any specific grant from funding agencies in the public, commercial, or not-for-profit sectors.

Declaration of interest

None.

CRediT author statement

Nadia Mock: Conceptualization, Methodology, Investigation, Data Curation, Writing-Original Draft, Project administration.

Christian Balzer: Conceptualization, Writing-Review & Editing.

Klemens Gutbrod: Conceptualization, Methodology, Writing-Review & Editing.

Bianca De Haan: Methodology, Writing-Review & Editing.

Lutz Jäncke: Methodology, Writing-Review & Editing.

Thierry Ettlin: Resources, Methodology, Supervision.

Wiebke Trost: Conceptualization, Methodology, Investigation, Data Curation, Writing-Original Draft.

Acknowledgements

Members of the psychology service at Reha Rheinfelden contributed to patient recruitment and neuropsychological assessments (in alphabetical order): Marie Gachet, Moritz Geiger, Thomas Grenal, Dr. Katrin Lunke, Julia Näf, Franziska Ruegger-Frei, Dr. Céline Tanner-Eggen, and Dr. Brigitte Weiermann. We thank Prof. Ernst-Wilhelm Radü of Biomedical Research and Training for verifying the delineated lesions. Further, we thank Dr. Corina Schuster-Amft and Prof. Jasmin Wandel for valuable advice on the project. Finally, we would like to thank Louise Charles for proofreading the manuscript.

Supplementary data

Supplementary data to this article can be found online at <https://doi.org/10.1016/j.cortex.2022.04.017>.

REFERENCES

- Adcock, R. A., Thangavel, A., Whitfield-Gabrieli, S., Knutson, B., & Gabrieli, J. D. E. (2006). Reward-motivated learning: mesolimbic activation precedes memory formation. *Neuron*, 50(3), 507–517. <https://doi.org/10.1016/j.neuron.2006.03.036>
- Aggleton, J. P., & Brown, M. W. (1999). Episodic memory, amnesia, and the hippocampal-anterior thalamic axis. *The Behavioral and Brain Sciences*, 22(3), 425–444. <https://doi.org/10.1017/S0140525X99002034>
- Aggleton, J. P., Desimone, R., & Mishkin, M. (1986). The origin, course, and termination of the hippocampothalamic projections in the macaque. *Journal of Comparative Neurology*, 243(3), 409–421. <https://doi.org/10.1002/cne.902430310>
- Aggleton, J. P., Pralus, A., Nelson, A. J. D., & Hornberger, M. (2016). Thalamic pathology and memory loss in early Alzheimer's disease: Moving the focus from the medial temporal lobe to Papez circuit. *Brain: a Journal of Neurology*, 139(7), 1877–1890. <https://doi.org/10.1093/brain/aww083>
- Balzer, C., Berger, J.-M., Caprez, G., Gonser, A., Gutbrod, K., & Keller, M. (2011). *Materialien und Normwerte für die Neuropsychologische Diagnostik (MNND)*. Rheinfelden: Verlag Normdaten.
- Barr, W. B. (1997). Examining the right temporal lobe's role in nonverbal memory. *Brain and Cognition*, 35, 26–41. <https://doi.org/10.1006/brcg.1997.0925>
- Barr, W. B., Chelune, G. J., Hermann, B. P., Loring, D. W., Perrine, K., Strauss, E., Trenerry, M. R., & Westerveld, M. (1997). The use of figural reproduction tests as measures of nonverbal memory in epilepsy surgery candidates. *Journal of the International Neuropsychological Society*, 3(5), 435–443. <https://doi.org/10.1017/s1355617797004359>
- Bates, E., Wilson, S. M., Saygin, A. P., Dick, F., Sereno, M. I., Knight, R. T., & Dronker, N. F. (2003). Voxel-based lesion-symptom mapping. *Nature Neuroscience*, 6(5), 448–450. <https://doi.org/10.1038/nn1050>
- Begré, S., Frommer, A., von Känel, R., Kiefer, C., & Federspiel, A. (2007). Relation of white matter anisotropy to visual memory in 17 healthy subjects. *Brain Research*, 1168(1), 60–66. <https://doi.org/10.1016/j.brainres.2007.06.096>
- Bell, B., & Davies, K. (1998). Anterior temporal lobectomy, hippocampal sclerosis, and memory: Recent neuropsychological findings. *Neuropsychology Review*, 8(1), 25–41. <https://doi.org/10.1023/A:1025679122911>
- Bellgowan, P. S. F., Binder, J. R., Swanson, S. J., Hammeke, T. A., Springer, J. A., Frost, J. A., Mueller, W. M., & Morris, G. L. (1997). Side of seizure focus predicts left medial temporal lobe activation during verbal encoding. *Neurology*, 51(2), 479–484. <https://doi.org/10.1212/WNL.51.2.479>
- Bell, B., Lin, J. J., Seidenberg, M., & Hermann, B. (2011). The neurobiology of cognitive disorders in temporal lobe epilepsy. *Nature Reviews Neurology*, 7(3), 154–164. <https://doi.org/10.1038/nrneurol.2011.3>
- Berry, C. J., Kessels, R. P., Wester, A. J., & Shanks, D. R. (2014). A single-system model predicts recognition memory and repetition priming in amnesia. *Journal of Neuroscience*, 34(33), 10963–10974. <https://doi.org/10.1523/JNEUROSCI.0764-14.2014>
- Biesbroek, J. M., Kuijf, H. J., van der Graaf, Y., Vincken, K. L., Postma, A., Mali, W. P., Biessels, G. J., & Geerlings, M. I. (2013). Association between subcortical vascular lesion location and cognition: A voxel-based and tract-based lesion-symptom mapping study. The SMART-MR study. *Plos One*, 8(4), Article e60541. <https://doi.org/10.1371/journal.pone.0060541>
- Biesbroek, J. M., van Zandvoort, M. J., Kuijf, H. J., Weaver, N. A., Kappelle, L. J., Vos, P. C., Velthuis, B. K., Biessels, G. J., & Postma, A. (2014). The anatomy of visuospatial construction revealed by lesion-symptom mapping. *Neuropsychologia*, 62(1), 68–76. <https://doi.org/10.1016/j.neuropsychologia.2014.07.013>
- Biesbroek, J. M., Weaver, N. A., Hilal, S., Kuijf, H. J., Ikram, M. K., Xu, X., Tan, B. Y., Venketasubramanian, N., Postma, A., Biessels, G. J., & Chen, C. P. (2016). Impact of strategically located white matter hyperintensities on cognition in memory clinic patients with small vessel disease. *Plos One*, 11(11), Article e0166261. <https://doi.org/10.1371/journal.pone.0166261>
- Binder, J. R., Sabsevitz, D. S., Swanson, S. J., Hammeke, T. A., Raghavan, M., & Mueller, W. M. (2008). Use of preoperative functional MRI to predict verbal memory decline after temporal lobe epilepsy surgery. *Epilepsia*, 49(8), 1377–1394. <https://doi.org/10.1111/j.1528-1167.2008.01625.x>
- Blanchet, S., Desgranges, B., Denise, P., Lechevalier, B., Eustache, F., & Faure, S. (2001). New questions on the hemispheric encoding/retrieval asymmetry (HERA) model assessed by divided visual-field tachistoscopy in normal subjects. *Neuropsychologia*, 39(5), 502–509. [https://doi.org/10.1016/S0028-3932\(00\)00119-6](https://doi.org/10.1016/S0028-3932(00)00119-6)

- Bogousslavsky, J., Miklossy, J., Deruaz, J. P., Assal, G., & Regli, F. (1987). Lingual and fusiform gyri in visual processing: A clinico-pathologic study of superior altitudinal hemianopia. *Journal of Neurology, Neurosurgery, and Psychiatry*, 50(5), 607–614. <https://doi.org/10.1136/jnnp.50.5.607>
- Bonelli, S. B., Powell, R. H., Yogarajah, M., Samson, R. S., Symms, M. R., Thompson, P. J., Koepp, M. J., & Duncan, J. S. (2010). Imaging memory in temporal lobe epilepsy: Predicting the effects of temporal lobe resection. *Brain: a Journal of Neurology*, 133(4), 1186–1199. <https://doi.org/10.1093/brain/awq006>
- Bonkhoff, A. K., Lim, J.-S., Bae, H.-J., Weaver, N. A., Kuijff, H. J., Biesbroek, J. M., Rost, N. S., & Bzdok, D. (2021). Generative lesion pattern decomposition of cognitive impairment after stroke. *Brain Communications*, 3(2), fcab110. <https://doi.org/10.1093/braincomms/fcab110>
- Bowren, M., Adolphs, R., Bruss, J., Manzel, K., Corbetta, M., Tranel, D., & Boes, A. D. (2020). Multivariate lesion-behavior mapping of general cognitive ability and its psychometric constituents. *Journal of Neuroscience*, 40(46), 8924–8937. <https://doi.org/10.1523/JNEUROSCI.1415-20.2020>
- Brewer, W. F. (1969). Visual memory, verbal encoding and hemispheric localization. *Cortex; a Journal Devoted To the Study of the Nervous System and Behavior*, 5(2), 145–151. [https://doi.org/10.1016/S0010-9452\(69\)80025-0](https://doi.org/10.1016/S0010-9452(69)80025-0)
- Brickman, A. M., Zimmerman, M. E., Paul, R. H., Grieve, S. M., Tate, D. F., Cohen, R. A., Williams, L. M., Clark, C. R., & Gordon, E. (2006). Regional white matter and neuropsychological functioning across the adult lifespan. *Biological Psychiatry*, 60(5), 444–453. <https://doi.org/10.1016/j.biopsych.2006.01.011>
- Burgess, N., Maguire, E., & O'keefe, J. (2002). The human hippocampus and spatial and episodic memory. *Neuron*, 35(4), 625–641. [https://doi.org/10.1016/S0896-6273\(02\)00830-9](https://doi.org/10.1016/S0896-6273(02)00830-9)
- Charlton, R. A., Barrick, T. R., Markus, H. S., & Morris, R. G. (2010). The relationship between episodic long-term memory and white matter integrity in normal aging. *Neuropsychologia*, 48(1), 114–122. <https://doi.org/10.1016/j.neuropsychologia.2009.08.018>
- Chelune, G., Naugle, R., Luders, H., & Awad, I. (1991). Prediction of cognitive change as a function of preoperative ability status among temporal lobectomy patients seen at 6-month follow-up. *Neurology*, 41(3), 399–404. <https://doi.org/10.1212/WNL.41.3.399>
- Chi, R. P., Fregni, F., & Snyder, A. W. (2010). Visual memory improved by non-invasive brain stimulation. *Brain Research*, 1353, 168–175. <https://doi.org/10.1016/j.brainres.2010.07.062>
- Chun, M. M., & Turk-Browne, N. B. (2007). Interactions between attention and memory. *Current Opinion in Neurobiology*, 17(2), 177–184. <https://doi.org/10.1016/j.conb.2007.03.005>
- Clos, M., Schwarze, U., Gluth, S., Bunzeck, N., & Sommer, T. (2015). Goal- and retrieval-dependent activity in the striatum during memory recognition. *Neuropsychologia*, 72, 1–11. <https://doi.org/10.1016/j.neuropsychologia.2015.04.011>
- de Haan, B., & Karnath, H. O. (2018). A hitchhiker's guide to lesion-behaviour mapping. *Neuropsychologia*, 115, 5–16. <https://doi.org/10.1016/j.neuropsychologia.2017.10.021>
- de Paula França Resende, E., Hornberger, M., Guimarães, H. C., Gambogi, L. B., Mariano, L. I., Teixeira, A. L., Caramelli, P., & Cruz de Souza, L. (2021). Different patterns of gray matter atrophy in behavioral variant frontotemporal dementia with and without episodic memory impairment. *International Journal of Geriatric Psychiatry*, 36(12), 1848–1857. <https://doi.org/10.1002/gps.5503>
- DeMarco, A. T., & Turkeltaub, P. E. (2018). A multivariate lesion-symptom mapping toolbox and examination of lesion-volume biases and correction methods in lesion-symptom mapping. *Human Brain Mapping*, 39(11), 4169–4182. <https://doi.org/10.1002/hbm.24289>
- Dhanjal, N. S., & Wise, R. J. S. (2014). Frontoparietal cognitive control of verbal memory recall in Alzheimer's disease. *Annals of Neurology*, 76(2), 241–251. <https://doi.org/10.1002/ana.24199>
- Diana, R. A., Yonelinas, A. P., & Ranganath, C. (2007). Imaging recollection and familiarity in the medial temporal lobe: A three-component model. *Trends in Cognitive Sciences*, 11(9), 379–386. <https://doi.org/10.1016/j.tics.2007.08.001>
- Duff, K., Paulsen, J., Mills, J., Beglinger, L. J., Moser, D. J., Smith, M. M., Langbehn, D., Stout, J., Queller, S., & Harrington, D. L. (2010). Mild cognitive impairment in prediagnosed Huntington disease. *Neurology*, 75(6), 500–507. <https://doi.org/10.1212/WNL.0b013e3181eccfa2>
- Duff, K., Schoenberg, M. R., Scott, J. G., & Adams, R. L. (2005). The relationship between executive functioning and verbal and visual learning and memory. *Archives of Clinical Neuropsychology*, 20(1), 111–122. <https://doi.org/10.1016/j.acn.2004.03.003>
- Engel, S. A., Glover, G. H., & Wandell, B. A. (1997). Retinotopic organization in human visual cortex and the spatial precision of functional MRI. *Cerebral Cortex*, 7(2), 181–192. <https://doi.org/10.1093/cercor/7.2.181>
- Fan, Y., Resnick, S. M., Wu, X., & Davatzikos, C. (2008). Structural and functional biomarkers of prodromal Alzheimer's disease: A high-dimensional pattern classification study. *Neuroimage*, 41(2), 277–285. <https://doi.org/10.1016/j.neuroimage.2008.02.043>
- Ferguson, M. A., Lim, C., Cooke, D., Darby, R. R., Wu, O., Rost, N. S., Corbetta, M., Grafman, J., & Fox, M. D. (2019). A human memory circuit derived from brain lesions causing amnesia. *Nature Communications*, 10(1), 1–9. <https://doi.org/10.1038/s41467-019-11353-z>
- Frank, M. J., Loughry, B., & O'Reilly, R. C. (2001). Interactions between frontal cortex and basal ganglia in working memory: A computational model. *Cognitive, Affective & Behavioral Neuroscience*, 1(2), 137–160. <https://doi.org/10.3758/CABN.1.2.137>
- Gainotti, G., Caltagirone, C., & Miceli, G. (1978). Immediate visual-spatial memory in hemisphere-damaged patients: Impairment of verbal coding and of perceptual processing. *Neuropsychologia*, 16(4), 501–507. [https://doi.org/10.1016/0028-3932\(78\)90074-X](https://doi.org/10.1016/0028-3932(78)90074-X)
- Gainotti, G., Silveri, M. C., Villa, G., & Caltagirone, C. (1983). Drawing objects from memory in aphasia. *Brain: a Journal of Neurology*, 106(3), 613–622. <https://doi.org/10.1093/brain/106.3.613>
- Gerrits, R., van der Haegen, L., Brysbaert, M., & Vingerhoets, G. (2019). Laterality for recognizing written words and faces in the fusiform gyrus covaries with language dominance. *Cortex; a Journal Devoted to the Study of the Nervous System and Behavior*, 117, 196–204. <https://doi.org/10.1016/j.cortex.2019.03.010>
- Gillespie, D. C., Bowen, A., & Foster, J. K. (2006). Memory impairment following right hemisphere stroke: A comparative meta-analytic and narrative review. *Clinical Neuropsychologist*, 20(1), 59–75. <https://doi.org/10.1080/13854040500203308>
- Gläscher, J., Adolphs, R., Damasio, H., Bechara, A., Rudrauf, D., Calamia, M., Paul, L. K., & Tranel, D. (2012). Lesion mapping of cognitive control and value-based decision making in the prefrontal cortex. *Proceedings of the National Academy of Sciences of the United States of America*, 109(36), 14681–14686. <https://doi.org/10.1073/pnas.1206608109>
- Godefroy, O., Roussel, M., Leclerc, X., & Leys, D. (2009). Deficit of episodic memory: Anatomy and related patterns in stroke patients. *European Neurology*, 61(4), 223–229. <https://doi.org/10.1159/000197107>
- Golby, A. J., Poldrack, R. A., Brewer, J. B., Spencer, D., Desmond, J. E., Aron, A. P., & Gabrieli, J. D. E. (2001). Material-specific lateralization in the medial temporal lobe and

- prefrontal cortex during memory encoding. *Brain: a Journal of Neurology*, 124(9), 1841–1854. <https://doi.org/10.1093/brain/124.9.1841>
- Graf, P., & Schacter, D. L. (1985). Implicit and explicit memory for new associations in normal and amnesic subjects. *Journal of Experimental Psychology. Learning, Memory, and Cognition*, 11(3), 501–518.
- Grahn, J. A., Parkinson, J. A., & Owen, A. M. (2009). The role of the basal ganglia in learning and memory: Neuropsychological studies. *Behavioural Brain Research*, 199(1), 53–60. <https://doi.org/10.1016/j.bbr.2008.11.020>
- Grahn, J. A., & Rowe, J. B. (2009). Feeling the beat: Premotor and striatal interactions in musicians and nonmusicians during beat perception. *Journal of Neuroscience*, 29(23), 7540–7548. <https://doi.org/10.1523/JNEUROSCI.2018-08.2009>
- Gunning-Dixon, F. M., & Raz, N. (2000). The cognitive correlates of white matter abnormalities in normal aging: A quantitative review. *Neuropsychology*, 14(2), 224–232. <https://doi.org/10.1037/0894-4105.14.2.224>
- Heindel, W. C., Salmon, D. P., Shults, C. W., Walicke, P. A., & Butters, N. (1989). Neuropsychological evidence for multiple implicit memory systems: A comparison of Alzheimer's, Huntington's, and Parkinson's disease patients. *The Journal of Neuroscience*, 9(2), 582–587. <https://doi.org/10.1523/JNEUROSCI.09-02-00582.1989>
- Helmstaedter, C., Pohl, C., & Elger, C. E. (1995). Relations between verbal and nonverbal memory performance: Evidence of confounding effects particularly in patients with right temporal lobe epilepsy. *Cortex; a Journal Devoted To the Study of the Nervous System and Behavior*, 31, 345–355. [https://doi.org/10.1016/S0010-9452\(13\)80367-X](https://doi.org/10.1016/S0010-9452(13)80367-X)
- Henke, K. (2010). A model for memory systems based on processing modes rather than consciousness. *Nature Reviews Neuroscience*, 11(7), 523–532. <https://doi.org/10.1038/nrn2850>
- Hermann, B. P., Seidenberg, M., Haltiner, A., & Wyler, A. R. (1995). Relationship of age at onset, chronologic age, and adequacy of preoperative performance to verbal memory change after anterior temporal lobectomy. *Epilepsia*, 36(2), 137–145. <https://doi.org/10.1111/j.1528-1157.1995.tb00972.x>
- Hermann, B. P., Seidenberg, M., Schoenfeld, J., & Davies, K. (1997). Neuropsychological characteristics of the syndrome of mesial temporal lobe epilepsy. *Archives of Neurology*, 54(4), 369–376. <https://doi.org/10.1001/archneur.1997.00550160019010>
- Herweg, N. A., Apitz, T., Leicht, G., Mulert, C., Fuentemilla, L., & Bunzeck, N. (2016). Theta-alpha oscillations bind the hippocampus, prefrontal cortex, and striatum during recollection: Evidence from simultaneous EEG–fMRI. *Journal of Neuroscience*, 36(12), 3579–3587. <https://doi.org/10.1523/JNEUROSCI.3629-15.2016>
- Hyman, B. T., van Hoesen, G. W., & Damasio, A. R. (1990). Memory-related neural systems in Alzheimer's disease: An anatomic study. *Neurology*, 40(11), 1721–1722. <https://doi.org/10.1212/WNL.40.11.1721>
- Ivanova, M. v., Herron, T. J., Dronkers, N. F., & Baldo, J. v. (2021). An empirical comparison of univariate versus multivariate methods for the analysis of brain–behavior mapping. *Human Brain Mapping*, 42(4), 1070–1101. <https://doi.org/10.1002/hbm.25278>
- Janacek, K., Shattuck, K. F., Tagarelli, K. M., Lum, J. A. G., Turkeltaub, P. E., & Ullman, M. T. (2020). Sequence learning in the human brain: A functional neuroanatomical meta-analysis of serial reaction time studies. *Neuroimage*, 207, 116387. <https://doi.org/10.1016/j.neuroimage.2019.116387>
- Jeong, W., Chung, C. K., & Kim, J. S. (2015). Episodic memory in aspects of large-scale brain networks. *Frontiers in Human Neuroscience*, 9(454). <https://doi.org/10.3389/fnhum.2015.00454>
- Kanwisher, N., McDermott, J., & Chun, M. M. (1997). The fusiform face area: A module in human extrastriate cortex specialized for face perception. *Journal of Neuroscience*, 17(11), 4302–4311. <https://doi.org/10.1523/JNEUROSCI.17-11-04302.1997>
- Karnath, H. O., Sperber, C., Wiesen, D., & de Haan, B. (2020). Lesion-behavior mapping in cognitive neuroscience: A practical guide to univariate and multivariate approaches. In *Neuromethods* (Vol. 151, pp. 209–238). Humana Press. https://doi.org/10.1007/7657_2019_18
- Kelley, W. M., Miezin, F. M., McDermott, K. B., Buckner, R. L., Raichle, M. E., Cohen, N. J., Ollinger, J. M., Akbudak, E., Conturo, T. E., & Snyder, A. Z. (1998). Hemispheric specialization in human dorsal frontal cortex and medial temporal lobe for verbal and nonverbal memory encoding. *Neuron*, 20, 927–936. [https://doi.org/10.1016/S0896-6273\(00\)80474-2](https://doi.org/10.1016/S0896-6273(00)80474-2)
- Kinder, A., & Shanks, D. R. (2001). Amnesia and the declarative/nondeclarative distinction: A recurrent network model of classification, recognition, and repetition priming. *Journal of Cognitive Neuroscience*, 13(5), 648–669. <https://doi.org/10.1162/089892901750363217>
- Kneebone, A. C., Lee, G. P., Wade, L. T., & Loring, D. W. (2007). Rey complex figure: Figural and spatial memory before and after temporal lobectomy for intractable epilepsy. *Journal of the International Neuropsychological Society*, 13(4), 664–671. <https://doi.org/10.1017/S1355617707070828>
- Kopelman, M. D., Thomson, A. D., Guerrini, I., & Marshall, E. J. (2009). The Korsakoff syndrome: Clinical aspects, psychology and treatment. *Alcohol and Alcoholism*, 44(2), 148–154. <https://doi.org/10.1093/alcalc/agn118>
- Lee, T. M. C., Yip, J. T. H., & Jones-Gotman, M. (2002). Memory deficits after resection from left or right anterior temporal lobe in humans: A meta-analytic review. *Epilepsia*, 43(3), 283–291. <https://doi.org/10.1046/j.1528-1157.2002.09901.x>
- Leszczynski, M., & Staudigl, T. (2016). Memory-guided attention in the anterior thalamus. *Neuroscience and Biobehavioral Reviews*, 66, 163–165. <https://doi.org/10.1016/j.neubiorev.2016.04.015>
- Lezak, M. D., Howieson, D. B., Loring, D. W., & Fischer, J. S. (2004). *Neuropsychological assessment* (4th ed.). USA: Oxford University Press.
- Li, X. R., de Ren, Y., Cao, B., & Huang, X. L. (2018). Analysis of white matter characteristics with tract-based spatial statistics according to diffusion tensor imaging in early Parkinson's disease. *Neuroscience Letters*, 675, 127–132. <https://doi.org/10.1016/j.neulet.2017.11.064>
- Lisman, J. E., & Grace, A. A. (2005). The hippocampal-VTA loop: Controlling the entry of information into long-term memory. *Neuron*, 46(5), 703–713. <https://doi.org/10.1016/j.neuron.2005.05.002>
- Machielsen, W. C. M., Rombouts, S. A. R. B., Barkhof, F., Scheltens, P., & Witter, M. P. (2000). fMRI of visual encoding: Reproducibility of activation. *Human Brain Mapping*, 9(3), 156–164. [https://doi.org/10.1002/\(SICI\)1097-0193\(200003\)9](https://doi.org/10.1002/(SICI)1097-0193(200003)9)
- Manentes, R., Cotelli, M., & Miniussi, C. (2011). Successful physiological aging and episodic memory: A brain stimulation study. *Behavioural Brain Research*, 216(1), 153–158. <https://doi.org/10.1016/j.bbr.2010.07.027>
- Manes, F., Springer, J., Jorge, R., & Robinson, R. G. (1999). Verbal memory impairment after left insular cortex infarction. *Journal of Neurology, Neurosurgery, and Psychiatry*, 67(4), 532–534. <https://doi.org/10.1136/jnnp.67.4.532>
- Marchand, A., Faugère, A., Coutureau, E., & Wolff, M. (2014). A role for anterior thalamic nuclei in contextual fear memory. *Brain Structure & Function*, 219(5), 1575–1586. <https://doi.org/10.1007/s00429-013-0586-7>
- Marques, C. M., Caboclo, L. O. S. F., da Silva, T. I., da Silva Noffs, M. H., Carrete, H., Lin, K., Lin, J., Sakamoto, A. C., & Yacubian, E. M. T. (2007). Cognitive decline in temporal lobe epilepsy due to unilateral hippocampal sclerosis. *Epilepsy &*

- Behavior: E&B, 10(3), 477–485. <https://doi.org/10.1016/j.yebeh.2007.02.002>
- Mazancieux, A., Pandiani, T., & Moulin, C. J. A. (2020). Perceptual identification task points to continuity between implicit memory and recall. *Cognition*, 197, 104168. <https://doi.org/10.1016/j.cognition.2019.104168>
- McDermid Vaz, S. A. (2004). Nonverbal memory functioning following right anterior temporal lobectomy: A meta-analytic review. *Seizure: the Journal of the British Epilepsy Association*, 13(7), 446–452. <https://doi.org/10.1016/j.seizure.2003.12.004>
- Medina, J., Kimberg, D. Y., Chatterjee, A., & Coslett, H. B. (2010). Inappropriate usage of the Brunner-Munzel test in recent voxel-based lesion-symptom mapping studies. *Neuropsychologia*, 48(1), 341–343. <https://doi.org/10.1016/j.neuropsychologia.2009.09.016>
- Milner, B. (1966). Amnesia following operation on the temporal lobes. *Amnesia*.
- Milner, B. (1968). Disorders of memory after brain lesions in man: Preface: Material-specific and generalized memory loss. *Neuropsychologia*, 6, 175–179. [https://doi.org/10.1016/0028-3932\(68\)90017-1](https://doi.org/10.1016/0028-3932(68)90017-1)
- Milner, B. (1970). Memory and the medial temporal regions of the brain. *Biology of Memory*, 23, 31–59.
- Milner, B. (1972). Disorders of learning and memory after temporal lobe lesions in man. *Neurosurgery*, 19(CN_suppl_1), 421–446. https://doi.org/10.1093/neurosurgery/19.CN_suppl_1.421
- Moscovitch, M. (1992). Memory and working-with-memory: A component process model based on modules and central systems. *Journal of Cognitive Neuroscience*, 4(3), 257–267. <https://doi.org/10.1162/jocn.1992.4.3.257>
- Moscovitch, M. (2008). The hippocampus as a “stupid,” domain-specific module: Implications for theories of recent and remote memory, and of imagination. *Canadian Journal of Experimental Psychology*, 62(1), 62–79. <https://doi.org/10.1037/1196-1961.62.1.62>
- Moscovitch, M., Kapurtt, S., Köhler, S., & Houlet, S. (1995). Distinct neural correlates of visual long-term memory for spatial location and object identity: A positron emission tomography study in humans. *Psychology*, 92, 3721–3725. <https://doi.org/10.1073/pnas.92.9.3721>
- Niogi, S. N., Mukherjee, P., Ghajar, J., Johnson, C. E., Kolster, R., Lee, H., Suh, M., Zimmerman, R. D., Manley, G. T., & McCandliss, B. D. (2008). Structural dissociation of attentional control and memory in adults with and without mild traumatic brain injury. *Brain: a Journal of Neurology*, 131(12), 3209–3221. <https://doi.org/10.1093/brain/awn247>
- Nordahl, C. W., Ranganath, C., Yonelinas, A. P., DeCarli, C., Fletcher, E., & Jagust, W. J. (2006). White matter changes compromise prefrontal cortex function in healthy elderly individuals. *Journal of Cognitive Neuroscience*, 18(3), 418–429. <https://doi.org/10.1162/jocn.2006.18.3.418>
- Nozaradan, S., Schwartze, M., Obermeier, C., & Kotz, S. A. (2017). Specific contributions of basal ganglia and cerebellum to the neural tracking of rhythm. *Cortex; a Journal Devoted to the Study of the Nervous System and Behavior*, 95, 156–168. <https://doi.org/10.1016/j.cortex.2017.08.015>
- Palejwala, A. H., O'Connor, K. P., Milton, C. K., Anderson, C., Pelargos, P., Briggs, R. G., Conner, A. K., O'Donoghue, D. L., Glenn, C. A., & Sughrue, M. E. (2020). Anatomy and white matter connections of the fusiform gyrus. *Scientific Reports*, 10(1). <https://doi.org/10.1038/s41598-020-70410-6>
- Papez, J. W. (1937). A proposed mechanism of emotion. *Archives of Neurology & Psychiatry*, 38(4), 725–743. <https://doi.org/10.1001/archneurpsyc.1937.02260220069003>
- Park, J. L., & Donaldson, D. I. (2016). Investigating the relationship between implicit and explicit memory: Evidence that masked repetition priming speeds the onset of recollection. *Neuroimage*, 139, 8–16. <https://doi.org/10.1016/j.neuroimage.2016.06.013>
- Paulraj, S. R., Schendel, K., Curran, B., Dronkers, N. F., & Baldo, J. V. (2018). Role of the left hemisphere in visuospatial working memory. *Journal of Neurolinguistics*, 48, 133–141. <https://doi.org/10.1016/j.jneuroling.2018.04.006>
- Pillon, B., Bazin, B., Deweer, B., Ehrlé, N., Baulac, M., & Dubois, B. (1999). Specificity of memory deficits after right or left temporal lobectomy. *Cortex; a Journal Devoted to the Study of the Nervous System and Behavior*, 35, 561–571. [https://doi.org/10.1016/S0010-9452\(08\)70819-0](https://doi.org/10.1016/S0010-9452(08)70819-0)
- Preisig, B. C., Eggenberger, N., Zito, G., Vanbellinghen, T., Schumacher, R., Hopfner, S., Gutbrod, K., Nyffeler, T., Cazzoli, D., Annoni, J. M., Bohlhalter, S., & Müri, R. M. (2016). Eye gaze behavior at turn transition: How aphasic patients process speakers' turns during video observation. *Journal of Cognitive Neuroscience*, 28(10), 1613–1624. https://doi.org/10.1162/jocn_a_00983
- Prince, S. E., Daselaar, S. M., & Cabeza, R. (2005). Neural correlates of relational memory: Successful encoding and retrieval of semantic and perceptual associations. *Journal of Neuroscience*, 25(5), 1203–1210. <https://doi.org/10.1523/JNEUROSCI.2540-04.2005>
- Pustina, D., Avants, B., Faseyitan, O. K., Medaglia, J. D., & Coslett, H. B. (2018). Improved accuracy of lesion to symptom mapping with multivariate sparse canonical correlations. *Neuropsychologia*, 115, 154–166. <https://doi.org/10.1016/j.neuropsychologia.2017.08.027>
- Rausch, R. (1991). Effects of temporal lobe surgery on behavior. *Advances in Neurology*, 55, 279–292.
- Reber, P. J., Sanchez, D. J., & Gobel, E. W. (2011). Models of sequential learning. In *Proceedings of the eighth international conference on complex systems*. NECSI (This Volume) <https://www.researchgate.net/publication/228756767>.
- Rey, A. (1941). L'examen psychologique dans les cas d'encéphalopathie traumatique. *Archives de Psychologie*, 28, 286–340.
- Rey, A. (1958). Mémorisation d'une série de 15 mots en 5 répétitions. In A. Rey (Ed.), *L'examen clinique en psychologie*. Presses Universitaires de France.
- Rey, A. (1964). *L'examen clinique en psychologie*. Presses Universitaires de France.
- Richardson, M. P., Strange, B. A., Thompson, P. J., Baxendale, S. A., Duncan, J. S., & Dolan, R. J. (2004). Pre-operative verbal memory fMRI predicts post-operative memory decline after left temporal lobe resection. *Brain: a Journal of Neurology*, 127(11), 2419–2426. <https://doi.org/10.1093/brain/awn293>
- Rizvi, B., Lao, P. J., Colón, J., Hale, C., Igwe, K. C., Narkhede, A., Budge, M., Manly, J. J., Schupf, N., & Brickman, A. M. (2020). Tract-defined regional white matter hyperintensities and memory. *NeuroImage: Clinical*, 25, 102143. <https://doi.org/10.1016/j.nicl.2019.102143>
- Rorden, C., Bonilha, L., Fridriksson, J., Bender, B., & Karnath, H. (2012). Age-specific CT and MRI templates for spatial normalization. *Neuroimage*, 61(4), 957–965. <https://doi.org/10.1016/j.neuroimage.2012.03.020>
- Rorden, C., Bonilha, L., & Nichols, T. E. (2007). Rank-order versus mean based statistics for neuroimaging. *Neuroimage*, 35(4), 1531–1537. <https://doi.org/10.1016/j.neuroimage.2006.12.043>
- Rorden, C., & Brett, M. (2000). Stereotaxic display of brain lesions. *Behavioural Neurology*, 12(4), 191–200. www.fil.ion.ucl.ac.uk/spm/
- Rorden, C., & Karnath, H.-O. (2004). Using human brain lesions to infer function: A relic from a past era in the fMRI age? *Nature Reviews Neuroscience*, 5(10), 812–819. <https://doi.org/10.1038/nrn1521>
- Rosenthal, C. R., Andrews, S. K., Antoniadis, C. A., Kennard, C., & Soto, D. (2016). Learning and recognition of a non-conscious

- sequence of events in human primary visual cortex. *Current Biology*, 26(6), 834–841. <https://doi.org/10.1016/j.cub.2016.01.040>
- Rosenthal, C. R., & Soto, D. (2016). The anatomy of non-conscious recognition memory. *Trends in Neurosciences*, 39(11), 707–711. <https://doi.org/10.1016/j.tins.2016.09.005>
- Ruff, R. M., & Allen, C. C. (1999). *Ruff-light trail learning test: Professional manual*. Odessa, FL: Psychological Assessment Resources, Inc.
- Ruff, R. M., Light, R., & Parker, S. (1996). Visuospatial learning: Ruff light trail learning test. *Archives of Clinical Neuropsychology*, 11(4), 313–327.
- Sabsevitz, D., Swanson, S., Morris, G., Mueller, W., & Seidenberg, M. (2001). Memory outcome after left anterior temporal lobectomy in patients with expected and reversed Wada memory asymmetry scores. *Epilepsia*, 42(11), 1408–1415. <https://doi.org/10.1046/j.1528-1157.2001.38500.x>
- Sadeh, T., Shohamy, D., Levy, D. R., Reggev, N., & Maril, A. (2011). Cooperation between the hippocampus and the striatum during episodic encoding. *Journal of Cognitive Neuroscience*, 23(7), 1597–1608. <https://doi.org/10.1162/jocn.2010.21549>
- Saling, M. (2009). Verbal memory in mesial temporal lobe epilepsy: Beyond material specificity. *Brain: a Journal of Neurology*, 132, 570–582. <https://doi.org/10.1093/brain/awp012>
- Scimeca, J. M., & Badre, D. (2012). Striatal contributions to declarative memory retrieval. *Neuron*, 75(3), 380–392. <https://doi.org/10.1016/j.neuron.2012.07.014>
- Scoville, W. B., & Milner, B. (1957). Loss of recent memory after bilateral hippocampal lesions. *Journal of Neurology, Neurosurgery, and Psychiatry*, 20(1), 11. <https://doi.org/10.1136/jnnp.20.1.11>
- Sestieri, C., Corbetta, M., Romani, G. L., & Shulman, G. L. (2011). Episodic memory retrieval, parietal cortex, and the default mode network: Functional and topographic analyses. *Journal of Neuroscience*, 31(12), 4407–4420. <https://doi.org/10.1523/JNEUROSCI.3335-10.2011>
- Sidhu, M. K., Stretton, J., Winston, G. P., Bonelli, S., Centeno, M., Vollmar, C., Symms, M., Thompson, P. J., Koepp, M. J., & Duncan, J. S. (2013). A functional magnetic resonance imaging study mapping the episodic memory encoding network in temporal lobe epilepsy. *Brain: a Journal of Neurology*, 136(6), 1868–1888. <https://doi.org/10.1093/brain/awt099>
- Slotnick, S. D., & Schacter, D. L. (2004). A sensory signature that distinguishes true from false memories. *Nature Neuroscience*, 7(6), 664–672. <https://doi.org/10.1038/nn1252>
- Smith, E. E., Salat, D. H., Jeng, J., McCreary, C. R., Fischl, B., Schmahmann, J. D., Dickerson, B. C., Viswanathan, A., Albert, M. S., Blacker, D., & Greenberg, S. S. M. (2011). Correlations between MRI white matter lesion location and executive function and episodic memory. *Neurology*, 76(17), 1492–1499. <https://doi.org/10.1212/WNL.0b013e318217e7c8>
- Sperling, R., Chua, E., Cocchiarella, A., Rand-Giovannetti, E., Poldrack, R., Schacter, D. L., & Albert, M. (2003). Putting names to faces: Successful encoding of associative memories activates the anterior hippocampal formation. *Neuroimage*, 20(2), 1400–1410. [https://doi.org/10.1016/S1053-8119\(03\)00391-4](https://doi.org/10.1016/S1053-8119(03)00391-4)
- Spiers, H. J., Maguire, E. A., & Burgess, N. (2001). Hippocampal amnesia. *Neurocase*, 7(5), 357–382. <https://doi.org/10.1076/neur.7.5.357.16245>
- Spreen, O., & Strauss, E. (1991). *A compendium of neuropsychological tests. Administration, norms, and commentary*. Oxford University Press.
- Squire, L. R. (1987). The organization and neural substrates of human memory. *International Journal of Neurology*, 21, 218–222.
- Squire, L. R. (2004). Memory systems of the brain: A brief history and current perspective. *Neurobiology of Learning and Memory*, 82(3), 171–177. <https://doi.org/10.1016/j.nlm.2004.06.005>
- Stephan-Otto, C., Siddi, S., Senior, C., Muñoz-Samons, D., Ochoa, S., Sánchez-Laforga, A. M., & Brébion, G. (2017). Visual imagery and false memory for pictures: A functional magnetic resonance imaging study in healthy participants. *Plos One*, 12(1). <https://doi.org/10.1371/journal.pone.0169551>
- Sullivan, E. v., & Pfefferbaum, A. (2006). Diffusion tensor imaging and aging. *Neuroscience and Biobehavioral Reviews*, 30(6), 749–761. <https://doi.org/10.1016/j.neubiorev.2006.06.002>
- Tanaka, J. W., Heptonstall, B., & Campbell, A. (2019). Part and whole face representations in immediate and long-term memory. *Vision Research*, 164, 53–61. <https://doi.org/10.1016/j.visres.2019.07.007>
- Taylor, L. B. (1969). Localization of cerebral lesions by psychological testing. *Clinical Neurosurgery*, 16, 269–287.
- Tranel, D., Damasio, A. R., Damasio, H., & Brandt, J. P. (1994). Sensorimotor skill learning in amnesia: Additional evidence for the neural basis of nondeclarative memory. *Learning & Memory*, 1(3), 165–179. <https://doi.org/10.1101/lm.1.3.165>
- Tremont, G., Halpert, S., Javorsky, D. J., & Stern, R. A. (2000). Differential impact of executive dysfunction on verbal list learning and story recall. *Clinical Neuropsychologist*, 14(3), 295–302. [https://doi.org/10.1076/1385-4046\(200008\)14:3:1-P;FT295](https://doi.org/10.1076/1385-4046(200008)14:3:1-P;FT295)
- Tsvivilis, D., Vann, S. D., Denby, C., Roberts, N., Mayes, A. R., Montaldi, D., & Aggleton, J. P. (2008). A disproportionate role for the fornix and mammillary bodies in recall versus recognition memory. *Nature Neuroscience*, 11(7), 834–842. <https://doi.org/10.1038/nn.2149>
- Tulving, E. (1972). In E. Tulving, & E. Donaldson (Eds.), *Episodic and semantic memory. Organization of memory*. Academic Press.
- Tulving, E. (2002). Episodic memory: From mind to brain. *Annual Review of Psychology*, 53(1), 1–25. <https://doi.org/10.1146/annurev.psych.53.100901.135114>
- Tulving, E., & Schacter, D. L. (1990). Priming and human memory systems. *Science*, 247(4940), 301–306. <https://doi.org/10.1126/science.2296719>
- Vakil, E., Blachstein, H., & Soroker, N. (2004). Differential effect of right and left basal ganglionic infarctions on procedural learning. *Cognitive and Behavioral Neurology: Official Journal of the Society for Behavioral and Cognitive Neurology*, 17(2), 62–73. <https://doi.org/10.1097/01.wnn.0000094553.44085.25>
- Verdon, V., Schwartz, S., Lovblad, K. O., Hauert, C. A., & Vuilleumier, P. (2010). Neuroanatomy of hemispatial neglect and its functional components: A study using voxel-based lesion-symptom mapping. *Brain: a Journal of Neurology*, 133(3), 880–894. <https://doi.org/10.1093/brain/awp305>
- Wada, J., & Rasmussen, T. (1960). Intracarotid injection of sodium amyltal for the lateralization of cerebral speech dominance: Experimental and clinical observations. *Journal of Neurosurgery*, 17(2), 266–282. <https://doi.org/10.3171/jns.1960.17.2.0266>
- Wechsler, D. (1987). *Wechsler memory scale-revised*. The Psychological Corporation.
- Wechsler, D. (1997). *WMS-III. Administration and scoring manual*. (Issue c). The Psychological Corporation.
- Wheeler, M. E., Petersen, S. E., & Buckner, R. L. (2000). Memory's echo: Vivid remembering reactivates sensory-specific cortex. *Proceedings of the National Academy of Sciences*, 97(20), 11125–11129. <https://doi.org/10.1073/pnas.97.20.11125>
- Wheeler, M. E., Shulman, G. L., Buckner, R. L., Miezin, F. M., Velanova, K., & Petersen, S. E. (2006). Evidence for separate perceptual reactivation and search processes during remembering. *Cerebral Cortex*, 16(7), 949–959. <https://doi.org/10.1093/cercor/bhj037>

- Wolff, M., & Vann, S. D. (2019). The cognitive thalamus as a gateway to mental representations. *Journal of Neuroscience*, 39(1), 3–14. <https://doi.org/10.1523/JNEUROSCI.0479-18.2018>
- Xie, C., Bai, F., Yu, H., Shi, Y., Yuan, Y., Chen, G., Li, W., Chen, G., Zhang, Z., & Li, S. J. (2012). Abnormal insula functional network is associated with episodic memory decline in amnesic mild cognitive impairment. *Neuroimage*, 63(1), 320–327. <https://doi.org/10.1016/j.neuroimage.2012.06.062>
- Yin, H. H., & Knowlton, B. J. (2006). The role of the basal ganglia in habit formation. *Nature Reviews Neuroscience*, 7(6), 464–476. <https://doi.org/10.1038/nrn1919>
- Yin, M., Wang, H., Hu, X., Li, X., Fei, G., & Yu, Y. (2019). Patterns of brain structural alteration in COPD with different levels of pulmonary function impairment and its association with cognitive deficits. *BMC Pulmonary Medicine*, 19(1), 1–10. <https://doi.org/10.1186/s12890-019-0955-y>
- Zannino, G. D., Murolo, R., Grammaldo, L., de Risi, M., di Gennaro, G., Esposito, V., Caltagirone, C., & Carlesimo, G. A. (2020). Visuo-verbal distinction revisited: New insights from a study on temporal lobe epilepsy patients in the debate over the lateralization of material-specific and process-specific aspects of memory. *Journal of Clinical and Experimental Neuropsychology*, 42(10), 1085–1098. <https://doi.org/10.1080/13803395.2020.1844868>
- Zhang, Y., Kimberg, D. Y., Coslett, H. B., Schwartz, M. F., & Wang, Z. (2014). Multivariate lesion-symptom mapping using support vector regression. *Human Brain Mapping*, 35(12), 5861–5876. <https://doi.org/10.1002/hbm.22590>