Check for updates

Arizono-Shimada Keira (Orcid ID: 0000-0003-4966-9162)

Title

The effect of masseter muscle mass on the rate of experimental tooth movement in rats

Short tittle: Masseter muscle mass and tooth movement

Keira Arizono-Shimada[1], Hitoshi Hotokezaka[2*], Yukiko Morita[3], Airi Ino-Kondo[4], Yuika Ueda-Ichinose[4], Yukako Nashiro[1], Yuka Hotokezaka[5], Keiko Yoshimi[6], Stavros Kiliaridis[7], Noriaki Yoshida[8]

1 Postgraduate student, Department of Orthodontics and Dentofacial Orthopedics, Graduate School of Biomedical Sciences, Nagasaki University, Nagasaki, Japan.

2 Associate Professor, Department of Orthodontics and Dentofacial Orthopedics, Graduate School of Biomedical Sciences, Nagasaki University, Nagasaki, Japan.

3 Assistant Professor, Department of Orthodontics and Dentofacial Orthopedics, Graduate School of Biomedical Sciences, Nagasaki University, Nagasaki, Japan.

4 Visiting researcher, Department of Orthodontics and Dentofacial Orthopedics, Graduate School of Biomedical Sciences, Nagasaki University, Nagasaki, Japan.

5 Senior Assistant Professor, Department of Clinical Oral Oncology, Graduate School of Biomedical Sciences, Nagasaki University, Nagasaki, Japan.

6 Medical practitioner, Yoshimi Skin Clinic, Nagasaki, Japan.

7 Professor Emeritus, Division of Orthodontics, University Clinics of Dental Medicine, University of Geneva, Geneva, and Adjunct Professor, Department of Orthodontics, Dentofacial Orthopedics, University of Bern, Bern, Switzerland.

8 Professor and Chair, Department of Orthodontics and Dentofacial Orthopedics, Graduate School of Biomedical Sciences, Nagasaki University, Nagasaki, Japan.

*Corresponding author: Dr Hitoshi Hotokezaka, Associate Professor, Department of Orthodontics and Dentofacial Orthopedics, Graduate School of Biomedical Sciences, Nagasaki University, 1-7-1 Sakamoto, Nagasaki 852-8588, Japan (e-mail: hotoke@nagasaki-u.ac.jp)

Acknowledgements

We thank Takanobu Kondo, Tomoko Yoshimi-Kobayashi for their helpful assistances and suggestions for this study. This work was supported by research grants from Japanese Grant-in-Aid for Scientific Research 17K11943 to H.H., 18K09837 to H.K., 15K20602 to Y. M., and 18K17263 to K.A.

This article has been accepted for publication and undergone full peer review but has not been through the copyediting, typesetting, pagination and proofreading process which may lead to differences between this version and the Version of Record. Please cite this article as doi: 10.1111/joor.13357

This article is protected by copyright. All rights reserved.

Accepted Article

source: https://doi.org/10.48350/171356 | downloaded: 7.5.2024

Accepted Article

COI statement
The authors declare that they have no conflict of interest.

Data Availability Statement
The data that support the findings of this study are available from the corresponding author upon reasonable request.

Abstract
Background: Previous clinical observational studies have suggested that orthodontic tooth movement (OTM) is related, at least partly, to the mass and/or capabilities of the masticatory muscles.
Objectives: Our study aimed to examine the influence of masticatory muscle mass on the OTM in an animal experimental model in which the masseter muscle was modulated by botulinum neurotoxin type A (BTX) injection.
Methods: Eighteen Wistar rats were equally divided into two groups: BTX injection and control. BTX was injected bilaterally into the masseter muscles. Three days after the injection, the maxillary left first molars were orthodontically moved for 14 days. At the end of the experiment, micro-computed tomography. was performed to evaluate the rate of OTM and bone morphometry. The masseter muscles were weighed and prepared for histological analyses.
Results: The masseter muscle mass in the BTX group was less than that in the control group, and histological findings showed atrophy of muscle fibers. The rate of OTM was significantly higher in the BTX group than in the control group. Furthermore, a negative correlation was detected between masseter muscle mass and OTM in the BTX group. Bone morphometry showed no difference between the control and BTX groups.
Conclusion: Decreased masseter muscle mass was found to be closely related to an increase in the rate of OTM in rats using BTX injection to modify the masseter muscle mass. Masseter muscle mass could be a predictive factor for OTM in rats injected with BTX.

Keywords: masseter muscle, botulinum neurotoxin type A, orthodontic tooth movement, micro-computed tomography, masticatory muscle, bone morphometry

Background
Clinical and animal experimental studies have shown that the rate of orthodontic tooth movement (OTM) varies significantly among individuals, even under the same applied

force magnitude.[1, 2] For example, in a study conducted to investigate factors that might influence the amount of OTM, younger patients showed greater tooth movement velocity than older patients, and an inter-arch or intra-arch obstacle decreased tooth displacement.[3] Furthermore, a study on the functional capability of the masticatory musculature in treatment outcomes of children with Class II malocclusion demonstrated that children with lower pre-treatment maximal molar bite force showed more mesial movement of mandibular first molars, distal movement of maxillary first molars, and a larger change in molar Class II relationship during treatment.[4] In addition, children with lower pre-treatment maximal molar bite force were more prone to anteroposterior dentoalveolar relapse following functional appliance treatment.[5]

Moreover, previous clinical studies on the treatment of dental Class II malocclusion with functional appliances led to mild atrophy of the masticatory muscles after treatment, possibly owing to their decreased functional activity.[6] Decreased masticatory muscle mass is linked to less contractile force and could lead to a lower bite force. Children with a thinner pre-treatment masseter muscle mass demonstrated more mandibular first molar mesialization and mandibular incisor proclination during treatment.[4]

These findings led us to hypothesize that masticatory muscle mass and functional capability, such as molar bite force, may be important factors that influence the velocity of OTM. However, confounding factors other than the masticatory muscle mass and functional capability may influence the rate of OTM, while various observational clinical studies have suggested a close relationship between masticatory muscle mass and tooth movement.

Therefore, we attempted to test our hypothesis using an experimental model in which a single factor, the masticatory muscle mass that regulates the magnitude of the muscle capability, could influence the rate of OTM. In this study, to modify the masticatory muscle mass, we used botulinum neurotoxin type A (BTX) injection to the masseter muscles because BTX injection has been reported to reduce its mass, weight and functional capability.[7, 8] The rat maxillary first molar was used as an experimental model for OTM; this model has often been used to elucidate the biological mechanisms linked to the OTM in the previous experimental studies.[9, 10, 11]

Our investigation aimed to study the effect of masticatory muscle mass on OTM, where the masseter muscle was modified by BTX injection in rats.

Methods

This study was approved by the Animal Care and Use Committee of Nagasaki University Graduate School of Biomedical Sciences (no. 1803301444-3). Eighteen 10-

Accepted Article

week-old female Wistar rats (SLC, Shizuoka, Japan; body weight, 150–160 g) were used in this study.

To determine the number of rats required for this investigation, 10 rats were used in a pilot study to define the parameters to be used in the power analysis. Ten animals were randomly and blindly divided into two groups: one group received BTX injection in both sides of the masseter muscle (BTX group) and a control group that received saline injection. After OTM, the difference of mean values between the two groups was 0.15 mm and the standard deviation obtained from all samples was 0.11 mm, respectively. Then, a power analysis was performed (two-tailed test, type I error $p = 0.05$ and type II error $p = 0.80$). Since it was estimated that seven rats in each group were required for this study, we used ten more rats that were randomly and blindly divided into two groups: BTX and control groups. Thus, ten rats were included in each group, and one rat in each group died during the experiment; finally, nine rats in each group were analyzed. All rats were housed in plastic cages in a colony room and fed a soft diet and water ad libitum. The rats were allowed to acclimate for 1 week before initiation of the experiments.

BTX injection in the masseter muscle

Under general anesthesia, BTX (BOTOX Vista® ALLERGAN JAPAN) was injected into the bilateral masseter muscles of rats in the BTX group, 3 days before the placement of the orthodontic appliance (Figure 1A). Two-units of BTX dissolved in 40 μL of saline were injected into each side of the masseter muscle using a Hamilton syringe with a 32-gauge needle, and a total of four units were injected bilaterally. The same volume of saline was injected into the rats in the control group (Figure 1B). Intraperitoneal injection of ketamine hydrochloride 87 mg/kg (Ketalar 50, Sankyo, Tokyo, Japan) combined with xylazine hydrochloride 13 mg/kg (Celactal 2%, Bayer-Japan, Tokyo, Japan) was used for general anesthesia.

Placement of the orthodontic appliance and micro-computed tomography (μCT) images

Placement of the orthodontic appliance and μCT scans were performed under general anesthesia as described above. A force of 10 cN was applied for 14 days using a nickel-titanium closed-coil spring (Sentalloy, Tomy, Fukushima, Japan) to move the maxillary left first molar in the mesial direction. To position the spring, a 0.008-inch stainless steel ligature wire was ligated around the cervical part of the maxillary left first molar on one side of the spring, and through the transverse hole drilled on the incisors on the other side (Figure 1C). The μCT (R_mCT, Rigaku, Tokyo, Japan) images were acquired on days 0 and 14. The parameters for μCT were as follows: voltage, 90 kV; current, 100

Accepted Article

Accepted Article

μA; exposure time, 2 min; resolution, 10 μm/pixel.

Measurement of weight and histological examination of the masseter muscle

After completion of OTM, the rats were sacrificed, the bilateral masseter muscles were dissected, and the muscle mass was weighed. The masseter muscles of rats in each group were immersed in a fixative solution of 4% paraformaldehyde in 50 mM sodium cacodylate buffer pH 7.4 for 1 day. After fixation, the specimens were subjected to routine histological processing, embedded in paraffin wax, and sectioned at 3 μm. Sections were prepared perpendicularly at the midpoint of muscle bundle along the direction of the superficial masseter muscle. The plane of the tissue sections was placed at the same level as the BTX injection. Hematoxylin and eosin staining was performed to observe the myofibers. The muscle fibers and stromal tissues were separated in the image of the tissue photographs taken by optical microscopy at the center of the muscle. The histological image of muscle fibers (40 × magnification) was measured using Image J,[12] and the ratio of muscle fiber area/total area (400 μm × 400 μm) was determined.

Measurement of tooth movement

The amount of OTM was measured on μCT images using a three-dimensional (3D) image reconstruction software (i-view, J. Morita, Kyoto, Japan). Changes between days 0 and 14 were measured. To evaluate OTM precisely, the following three parameters were defined: 1). The shortest distance: the shortest distance between the distal surface of the left maxillary first molar (UM1) and mesial surface of the left maxillary second molar (UM2) (Figure 2B). 2) Distance between contact points: the distance between the distal contact point of UM1 and the mesial contact point of UM2, identified on the image on day 0 (Figure 2C). 3) Mesial tipping angle: an angle expressing the change in the tooth axis inclination is determined by the mesial root axis of UM1 with respect to the occlusal plane defined by the second and third molars (Figure 2D).

Bone morphometry

Bone morphometric parameters, such as bone mineral density (BMD), bone mineral content (BMC), bone volume (BV), and bone volume per tissue volume (BV/TV) were measured and compared between the BTX and control groups. To compare the measurements of bone morphometric parameters, the volume of interest (VOI) was created in the μCT image. For the maxillary trabecular bone of UM1 which received orthodontic force, VOI was set at the center of the alveolar septum parallel to and surrounded by the five roots of UM1 (250 × 250 × 500 μm) (Figure 3A, B). In addition, a similar VOI was set for the mandibular trabecular bone. Bone morphometry analysis was performed using a 3D image analysis software (TRI-BONE; Ratoc System

Accepted Article

Engineering, Tokyo, Japan).

Statistical analyses

All measurements were performed for three times by the same investigator (KS), and the mean values were used for the final determination.

Statistical analyses were performed using EZR (Saitama Medical Center, Jichi Medical University, Saitama, Japan). A paired t-test was used to test the differences between the two groups. One-way analysis of variance (ANOVA) was used to compare the mean changes in bone morphometry. All presented data are shown as mean ± standard deviation. Statistical significance was set at $P < 0.05$. Pearson correlation was carried out to investigate a possible correlation between tooth movement and masseter muscle mass.

Results

Bodyweight

On day 14, the weight of the control group was 175.4 ± 7.8 g, and that of the BTX group was 162.3 ± 21.5 g. The rats in the BTX group did not gain as much weight as those in the control group and showed a significantly lower body weight during the first week after BTX injection. However, they regained weight thereafter and no significant differences in body weight between the two groups were observed on day 14 (Figure 4A).

Masseter muscle mass and histologic sections

On day 14, the masseter muscle was obviously thinner in the BTX group than in the control group. The masseter muscle mass was 0.62 ± 0.03 g in rats in the control group (right side, 0.63 ± 0.01 g; left side, 0.60 ± 0.05 g), and 0.31 ± 0.05 g in rats in BTX group (right side, 0.32 ± 0.06 g; left side masseter, 0.29 ± 0.04 g). There was no significant difference between the right and left masseter muscle masses of rats in either group. In contrast, the masseter muscle mass in the BTX group was 50% less than that in the control group (Figure 4B).

Histological sections of the masseter muscles obtained on day 14 showed a dense alignment of the muscle fibers and less stromal tissue in the control group. In contrast, obvious atrophy of the muscle fibers and more spacious stromal tissue was observed in the masseter muscle of the BTX group (17 days after BTX injection). Thus, the proportion of muscle fibers in the total muscle tissue in the BTX group was 55.7 ± 7.7 %, while that of the control group was 84.3 ± 2.5% ($p < 0.01$). Furthermore, the cross-section of the healthy masseter muscles was composed of muscle fibers with relatively similar cross-sectional sizes, in contrast to the masseter muscles injected with

Accepted Article

BTX where a large variation in the size of the fibers was found (Figure 4C).

Tooth movement

The shortest distance between UM1 and UM2 was 0.27 ± 0.10 mm in the control group, and 0.37 ± 0.05 mm in the BTX group (Figure 5A). The distance between contact points was 0.31 ± 0.10 mm in the control group and 0.40 ± 0.07 mm in the BTX group (Figure 5B). Similar differences between the two groups were observed in the mesial tipping of the molars that underwent OTM. The mesial tipping of the molars in the BTX group was 7.9 ± 3.6°, which was larger than 3.9 ± 2.8° in the control group (Figure 5C).

Correlation between masseter muscle mass and tooth movement

We investigated whether masseter muscle mass was associated with the rate of molar movement (Figure 5D). Negative correlations were observed between the weight of the masseter muscle mass and OTM in the BTX group: r = -0.73 in the shortest distance between UM1 and UM2, r = -0.82 in the distance between contact points, and r = -0.63 in the mesial tipping of the molars. In contrast, no significant correlation was observed in the control rats.

Bone morphometry

BMD of the alveolar septum at the center surrounded by the five roots of UM1 after OTM was 1074.3 mg/cm^3 in the control group and 1042.9 mg/cm^3 in the BTX group. There was no significant difference in the BMD of the alveolar bone between the control and BTX groups (Table 1). Also, other bone morphometric values, such as BMC, BV, and BV/TV, showed no significant differences between the control and BTX groups. In addition, there was no significant difference in the bone morphometric parameters of the mandible between the two groups.

Discussion

The present study is the first, as far as we know, to show that bilateral BTX injection into rat masseter muscles increases the amount of OTM of the first maxillary molar. Furthermore, a significant correlation was found between the weight of the masseter muscle and the OTM in BTX rats.

BTX binds to the nerve endings and inhibits the release of acetylcholine, which inhibits muscle contraction of muscle fibers innervated by the affected nerve.[7] It was previously found that injection of BTX in the masseter muscles decreased the size, weight, and functional capability of the masseter muscles.[13, 14] In the present study, we confirmed the effect of BTX injection on masseter muscle weight in rats: BTX-injected masseter muscles decreased their weight by 50% compared to the control group. Moreover, significant atrophy of muscle fibers was observed in histological sections of

Accepted Article

BTX-injected rats.

Observed reduced mass and muscle fiber atrophy in the masseter muscle could lead to diminished contractile force and, consequently, may weaken mastication of food. Masseter muscles have been reported to play a principal role in the mastication and grinding of foods in rats.[15] In fact, the BTX group rats in this study did not gain as much bodyweight as the control group rats during the first week after BTX injection despite being fed a soft diet, which suggests that the rats in the BTX group could not chew sufficiently, that is, the functional capability of the masseter muscle was reduced, and they consequently ingested less food in the BTX group. However, 2 weeks after BTX injection, the body weight of rats in the BTX group increased and reached the same level as that in the control group at the end of the experiment. This may indicate the recovery of food ingestion and the recovery of functional capability of the masseter muscle 2 week after BTX injection, although a decrease in muscle mass and an obvious atrophy of the muscle fibers were observed in the masseter muscle of the BTX group 17 days after BTX injection. However, we did not determine the functional capability of the masseter muscle, such as electromyography, bite force, ability to incise foodstuffs, number of chews per bolus, and time required to finish the pellet.

We showed an inverse correlation between masseter muscle weight and orthodontic tooth movement in the BTX group. Supporting our results, previous clinical studies have suggested that masseter muscle thickness could be a predictive variable in the successful treatment of Class II malocclusion.[4] However, the weight and/or volume of the masseter muscles have not been examined. In addition, the correlation between masseter muscle capability and OTM was not analyzed. In this study, we measured the tooth movement in three different ways to precisely evaluate tooth movement. Furthermore, to ensure that there would be no compensatory effect from the healthy contralateral side, bilateral injections in both masseters were performed. Masseter muscle weight was significantly correlated with all three tooth movement indices in the BTX group. Contrary to expectations, there was no significant correlation between masseter muscle weight and orthodontic tooth movement in the control group. This may be due to the small variation in masseter muscle weights in the control group. Alternatively, there may be a threshold masseter muscle weight at which it affects tooth movement. There was a large difference in masseter muscle weights between the BTX and control groups. Further studies with a larger sample size are required to confirm this hypothesis.

Three methods were used in this study to evaluate tooth movement. While the shortest distance between teeth is the most commonly used method, the distance

between contact points includes the factors of tooth inclination and extrusion. The correlation coefficient with the amount of masseter muscle was highest for the distance between the contact points. This may indicate that it better reflects tooth movement than the shortest distance or the mesial tipping angle. Alternatively, BTX injections may have reduced the occlusal force and promoted tooth eruption which may have strengthened the correlation between the amount of masseter muscle and distance between the contact points.

Regarding bone morphometry, it was previously found that a decrease in BMD is a factor that increases the rate of OTM.[16] BTX injection in the masseter muscle has been reported to reduce the BMD of the mandible as well as the masticatory muscle thickness more than 45 days after the injections.[14, 17] Thus, the effect of BTX injection on BMD per se could influence orthodontic tooth movement, in addition to muscle mass. However, in this study, there was no statistically significant difference in the BMD of the maxillary alveolar bone in the BTX group compared to the control after OTM for 14 days following BTX injection (Table 1). Nevertheless, OTM in BTX rats in this study showed greater tooth movement than that in control rats. This finding suggests that the bone morphometry on day 17 after BTX injection may not be directly linked to the greater tooth movement observed in BTX-injected rats. The difference in the effect of BTX on BMD between this study and previous studies may be due to the shorter period after the BTX injection. Additionally, we cannot rule out the possibility of a better VOI location that is more suitable for the measurement of bone morphometry and precisely reflects tooth movement.

In addition to BMD, several possible mechanisms have been suggested to elucidate the effect of masseter muscle mass on OTM velocity. One possibility is that the BTX injection weakens the bite force during mastication. As weaker masticatory muscles have been reported to be associated with a larger amount of molar displacement in clinical studies, reduction in the functional capability of the masseter muscle could influence the OTM rate observed in this study. Additionally, mandibular movements have been reported to be unstable during mastication after BTX injection into the masseter muscles in mice.[18] Unstable occlusion could loosen the tight biting contacts of the maxillary and mandibular teeth and lead to easier tooth movement. However, we did not determine the functional capability of the masseter muscle in this experiment. Another possible mechanism of masseter mass affecting the OTM rate includes the periodontal ligament space. Widened periodontal space would accelerate orthodontic tooth movement. However, it was reported that the space in the periodontal ligament becomes narrowed by occlusal hypofunction.[19] Further studies are needed to elucidate

Accepted Article

the mechanism by which masseter mass affects the OTM rate.

Finally, this study was conducted in animals in which BTX injection was used to decrease their masseter muscle mass. Thus, we cannot directly extrapolate the results of this study: masseter muscle mass is closely related to the rate of OTM in clinical situations.

Conclusion

BTX injection in the masseter muscles accelerated OTM in rats. The rate of OTM was inversely correlated with the masseter muscle mass in BTX-injected rats. Masseter muscle mass may be a predictive factor for OTM in rats with decreased masseter muscle mass after BTX injection.

References

1. Giannopoulou C, Dudic A, Pandis N, Kiliaridis S. Slow and fast orthodontic tooth movement: an experimental study on humans. *Eur J Orthod*. 2016;38(4):404-408.
2. Pilon JJGM, Kuijpers-Jagtman AM, Maltha JC. Magnitude of orthodontic forces and rate of bodily tooth movement. An experimental study. *Am J Orthod Dentofacial Orthop*; 1996;110(1):16-23.
3. Dudic A, Giannopoulou C, Kiliaridis S. Factors related to the rate of orthodontically induced tooth movement. *Am J Orthod Dentofacial Orthop*. 2013;143(5):616-621.
4. Antonarakis GS, Kiliaridis S. Predictive value of masseter muscle thickness and bite force on Class II functional appliance treatment: a prospective controlled study. *Eur J Orthod*. 2015;37(6):570-577.
5. Antonarakis GS, Kjellberg H, Kiliaridis S. Bite force and its association with stability following Class II/1 functional appliance treatment. *Eur J Orthod*. 2013;35:434-441.
6. Kiliaridis S, Mills CM, Antonarakis GS. Masseter muscle thickness as a predictive variable in treatment outcome of the twin-block appliance and masseteric thickness changes during treatment. *Orthod Craniofac Res*. 2010;13:203-213.
7. Balanta-Melo J, Toro-Ibacache V, Torres-Quintana MA, Kupczik K, Vega C, Morales C, Hernández-Moya N, Arias-Calderon M, Beato C, Buvinic S. Early molecular response and microanatomical changes in the masseter muscle and mandibular head after botulinum toxin intervention in adult mice. *Ann Anat*. 2018;216:112-119.

Accepted Article

Accepted Article

8. Nemani S, Putchha UK, Periketi M, Pothana S, Nappanveettil G, Nemani H. Botulinum neurotoxin effects on masseter muscle fibre in WNIN obese rats-Scanning electron microscope analysis. *Scanning*. 2016;38:396-402.
9. Ren Y, Maltha JC, Kuijpers-Jagtman AM. The rat as a model for orthodontic tooth movement - a critical review and a proposed solution. *Eur J Orthod*. 2004;26:483-490.
10. Gonzales C, Hotokezaka H, Yoshimatsu M, Yozgatian JH, Darendeliler MA, Yoshida N. Force magnitude and duration effects on amount of tooth movement and root resorption in the rat molar. *Angle Orthod*. 2008;78:502-509.
11. Tengku BS, Joseph BK, Harbrow D, Taverne AAR, Symons AL. Effect of a static magnetic field on orthodontic tooth movement in the rat. *Eur J Orthod*. 2000;22:475-487.
12. Rasband WS, ImageJ, U. S. National Institutes of Health, Bethesda, Maryland, USA, http://rsb.info.nih.gov/ij/, 1997-2012
13. Tsai CY, Lin YC, Su B, Yang LY, Chiu WC. Masseter muscle fibre changes following reduction of masticatory function. *Int J Oral Maxillofac Surg*. 2012;41(3):394-399
14. Seok WH, Jeong HK. Decreased mandibular cortical bone quality after botulinum toxin injections in masticatory muscles in female adults. *Sci Rep*. 2020;10:3623 https://doi.org/10.1038/s41598-020-60554-w
15. Utsumi D, Nakamura A, Matsuo K, Zeredo JL, Koga Y, Yoshida N. Motor coordination of masseter and temporalis muscle during mastication in mice. Int J Stomatol Occlusion Med. 2011;3:187–194.
16. Hashimoto M, Hotokezaka H, Sirisoontorn I, et al. The effect of bone morphometric changes on orthodontic tooth movement in an osteoporotic animal model. *Angle Orthod*. 2013;83:766-773.
17. Tsai CY, Shyr YM, Chiu WC, Lee, CM. Bone changes in the mandible following botulinum neurotoxin injections. *Eur J Orthod*. 2011;33:132–138.
18. Yoshimi T, Koga Y, Nakamura A, Fujishita A, Kohara H, Moriuchi E, Yoshimi K, Tsai CY, Yoshida N. Mechanism of motor coordination of masseter and temporalis muscles for increased masticatory efficiency in mice. *J Oral Rehabil*. 2017;44:363–374.
19. Matokawa M, Terao A, Karadeniz EI, Kaku M, Kawata T, Matsuda Y, Gonzales C, Darendeliler MA, Tanne K. Effects of long-term occlusal hypofunction and its recovery on the morphogenesis of molar roots and the periodontium in rats. *Angle Orthod*. 2013;83(4):597-604.

Accepted Article

Figure legends

Figure 1

A: Experimental design. botulinum toxin type A (BTX) or saline is injected 3 days before placement of the orthodontic appliance. The orthodontic force is applied for 14 days. B: Points for BTX injection. BTX or saline is injected at two points on the line between the oral commissure (point a) and the gonial angle (point b). C: Design of orthodontic appliance.

Figure 2

Measurements of tooth movements in the sagittal view in the upper molars. A: μCT image of day 0. B: Shortest distance indicated in the μCT image of day 14; arrowheads indicate the closest points between the left maxillary first molar (UM1) and left maxillary second molar (UM2). C: Distance between the contact points of UM1 and UM2 indicated in the μCT image of day 14. D: Mesial tipping angle indicated in the μCT image of day 14: an angle expressing the change of the tooth axis of UM1 in respect to the occlusal plane defined by the second and third molars (broken line). The dotted line indicates the root axis before OTM.

Figure 3

Volume of interest (VOI) of bone morphometry (μm) parallel to and surrounded by the five roots of the left maxillary first molar (UM1). A, Sagittal view of UM1. A dotted line indicates the slicing plane whose image is shown in the axial view. B, Axial view of UM1. The dotted line is the slicing plane whose image is shown in the sagittal view. M, mesial; D, distal; L, lingual; B, buccal.

Figure 4

A: Changes in body weight during the experimental period. B: Masseter muscle mass on day 14. C: Histological images of the masseter muscles on day 14. The graph shows the ratio of muscle fiber area/total area. CNT: control group. BTX: BTX group. *$P < 0.01$ compared to the control group.

Figure 5

Tooth movements (mean ± standard deviation) and correlation coefficients. A: Shortest distance. B: Distance between contact points. C: Mesial tipping. D: Correlation coefficients between the weight of masseter muscles and tooth measurements. CNT: control group. BTX: BTX group. *$P < 0.05$ compared to the control group.

Table 1. Bone morphometry after tooth movement for 2 weeks

	BMD	BMC	BV	BV/TV（%）
UM1 (Trabecular Bone)				
control	1074.3±36.7	2.28±0.49	2.12±0.41	67.7±13.2
BTX	1042.9±21.9	2.12±0.19	2.03±0.17	65.1±5.4
LM1 (Trabecular Bone)				
control	1097.86±28.01	4.84±0.27	4.41±0.24	48.8±2.20
BTX	1077.71±10.55	4.55±0.28	4.23±0.27	47.2±2.14

BMD, bone mineral density (mg/cm^3). BMC, bone mineral content (mg). BV, bone volume ($x10^{-3}$). BV/TV, bone volume/trabecular tissue volume (%). Values are presented as means ± SD.

Accepted Article

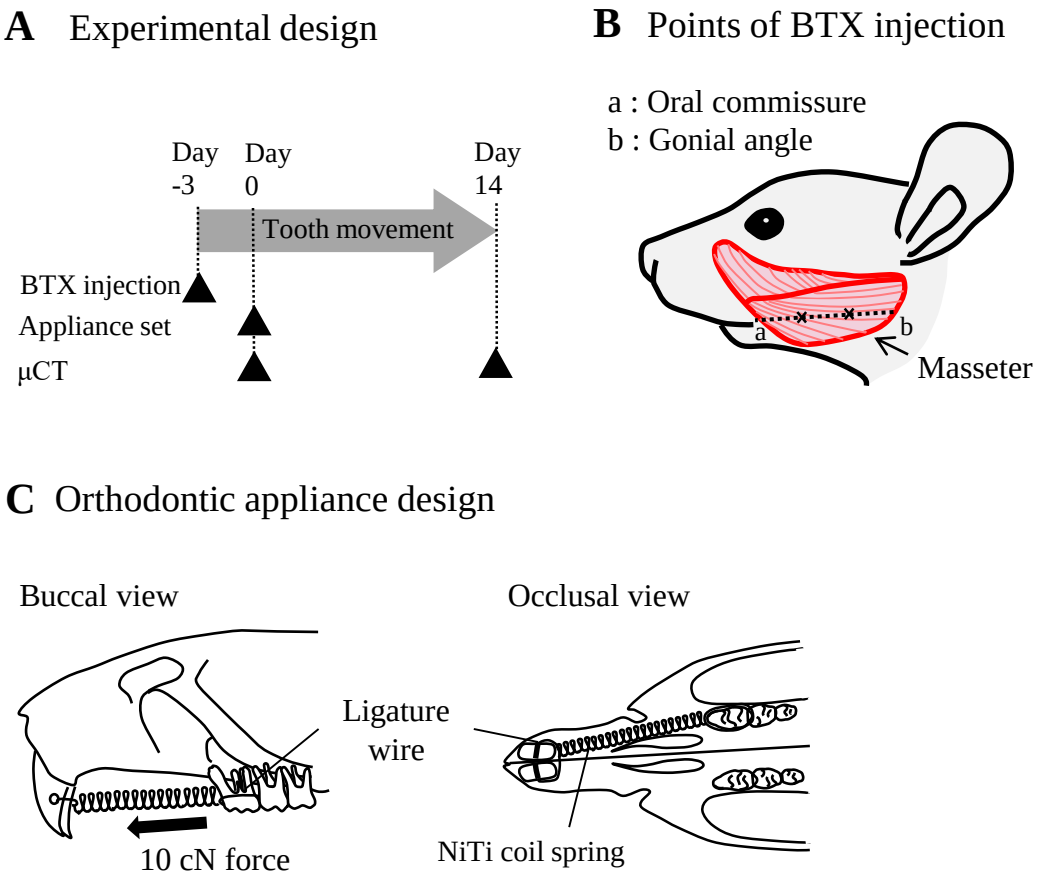
A Experimental design
Day -3
Day 0
Day 14
Tooth movement
BTX injection
Appliance set
μCT
B Points of BTX injection
a : Oral commissure
b : Gonial angle
a
b
Masseter
C Orthodontic appliance design
Buccal view
Occlusal view
Ligature wire
10 cN force
NiTi coil spring

Figure 1

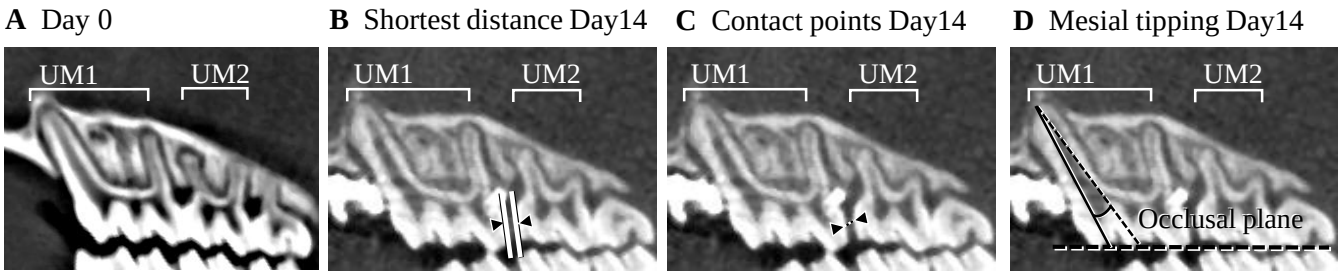
A Day 0
B Shortest distance Day14
C Contact points Day14
D Mesial tipping Day14
UM1
UM2
UM1
UM2
UM1
UM2
UM1
UM2
Occlusal plane

Figure 2

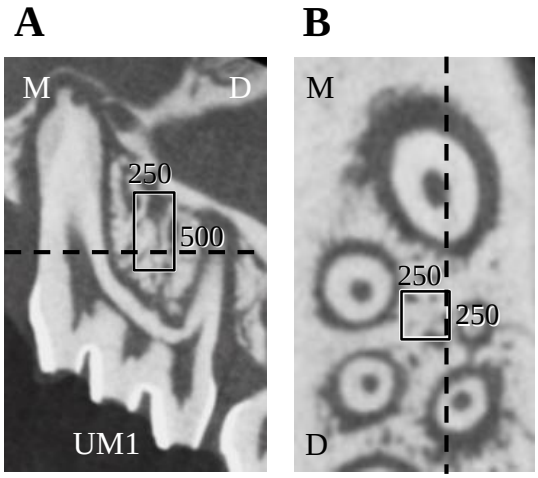

Figure 3

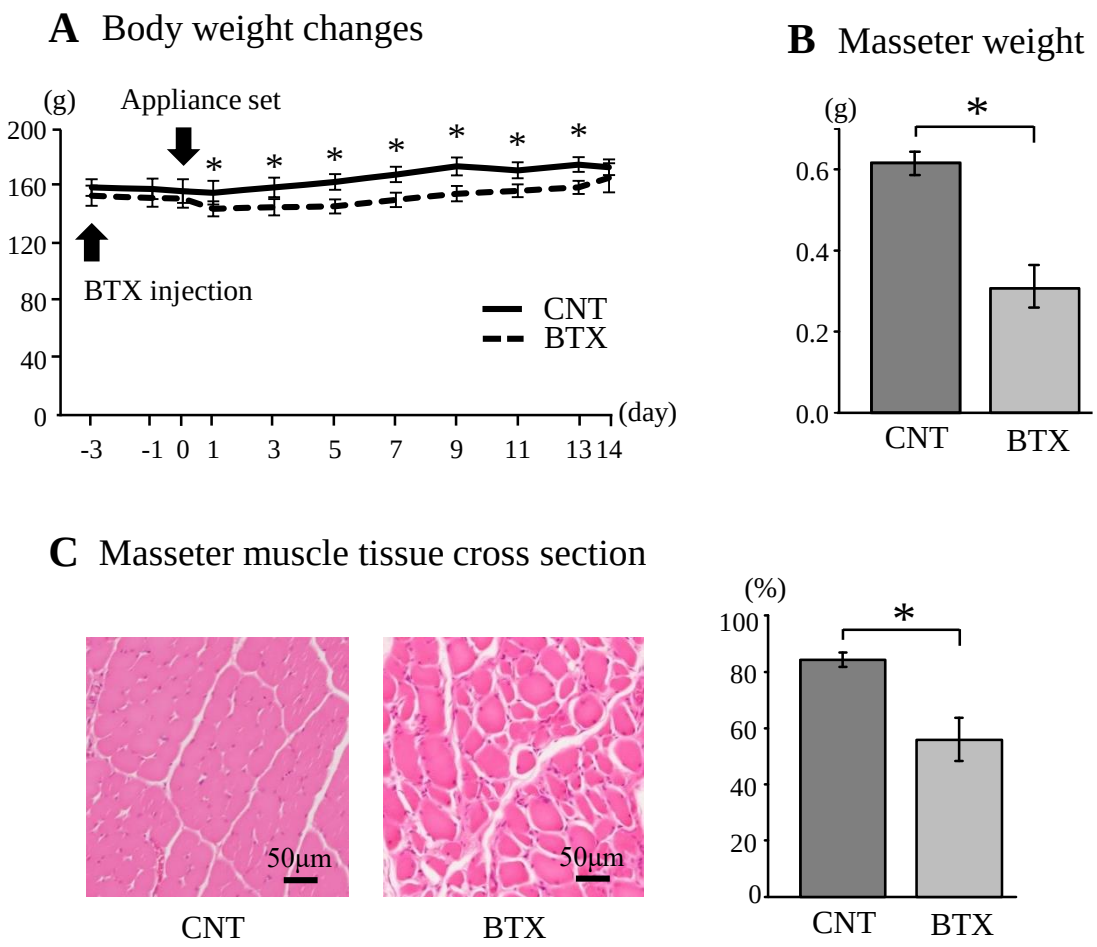
A Body weight changes
(g)
Appliance set
200
160
120
80
40
0
BTX injection
CNT
BTX
(day)
-3
-1
0
1
3
5
7
9
11
13
14
B Masseter weight
(g)
0.6
0.4
0.2
0.0
CNT
BTX
C Masseter muscle tissue cross section
50μm
50μm
CNT
BTX
(%)
100
80
60
40
20
0
CNT
BTX

Figure 4

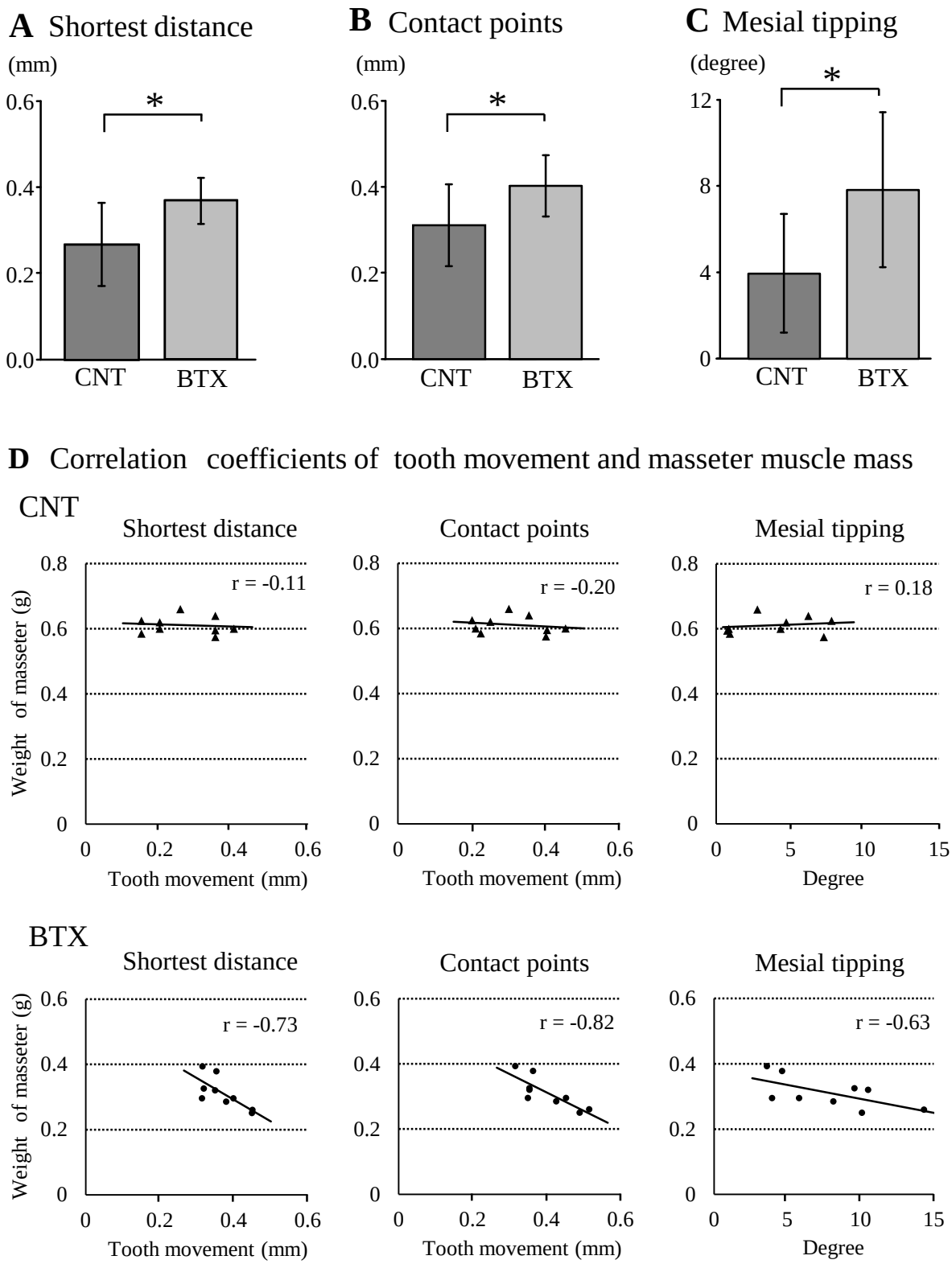
A Shortest distance
(mm)
0.6
0.4
0.2
0.0
*
CNT
BTX
B Contact points
(mm)
0.6
0.4
0.2
0.0
*
CNT
BTX
C Mesial tipping
(degree)
12
8
4
0
*
CNT
BTX
D Correlation coefficients of tooth movement and masseter muscle mass
CNT
Shortest distance
r = -0.11
Contact points
r = -0.20
Mesial tipping
r = 0.18
Weight of masseter (g)
Tooth movement (mm)
Degree
BTX
Shortest distance
r = -0.73
Contact points
r = -0.82
Mesial tipping
r = -0.63
Weight of masseter (g)
Tooth movement (mm)
Degree

Figure 5