

Kawasaki Disease Triggering an Episode of Psoriasis – a Case Report

Kawasaki-Syndrom als Auslöser einer Episode von psoriatischen Hautläsionen – ein Fallbericht



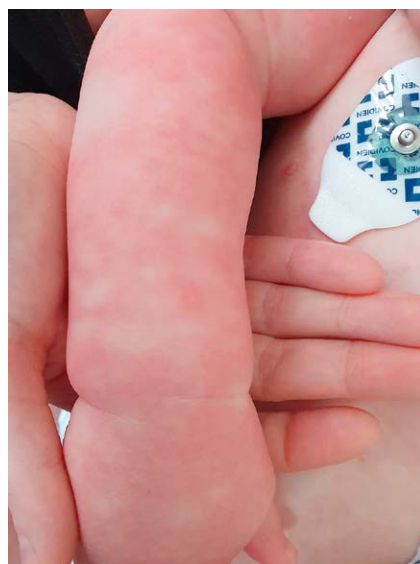Introduction

Kawasaki disease (KD) is an acute systemic inflammatory illness causing vasculitis. A diffuse polymorphous rash is one of the predominant features of patients presenting with KD. This rash can have a morbilliform, urticarial, micropustular, or further unspecific morphology. Psoriasis-like eruptions following KD were first described by Han et al. 2000 (Han M H et al., *Br J Dermatol* 2000; 142: 548–550), thereafter several case reports – describing over 30 children worldwide – have been published. It usually consists of a single episode with enduring remission, contrasting typical psoriasis. Furthermore, the eruptions can have an atypical presentation with less involvement of the anogenital area and more serous crusting (Haddock E S et al., *J Am Acad Dermatol* 2016; 75: 69–76), (Eberhard B A et al., *J Pediatr* 2000; 137, 4: 578–580). It is a well-known entity amongst dermatologists. However, acknowledgement by the paediatric community is limited. This is also

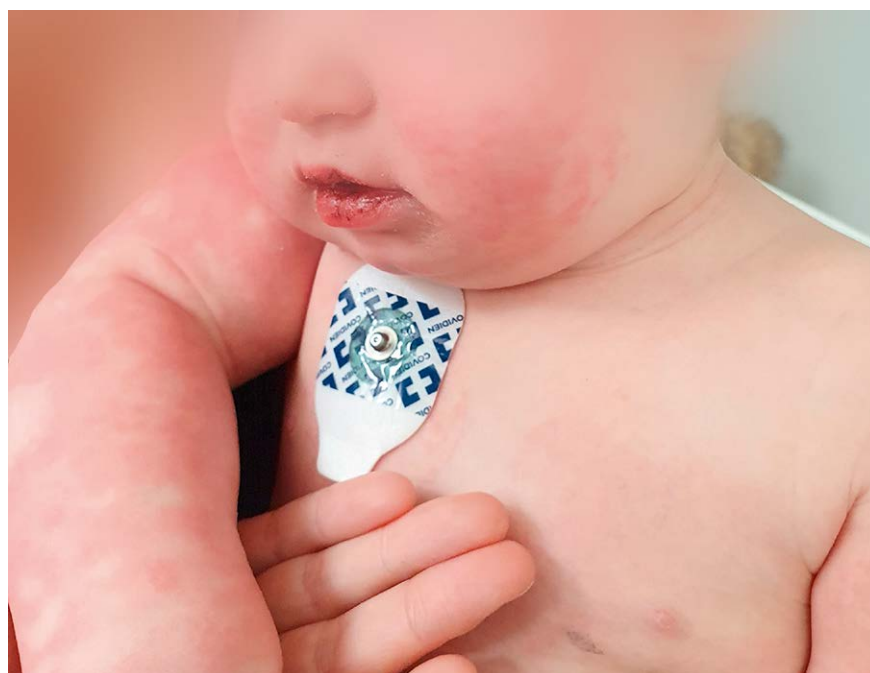reflected by the fact that 11 publications can be found in a dermatological journal versus 4 publications in a paediatric journal.

Case report

A 12-month-old boy who had been diagnosed and treated for classic KD around 2 weeks prior presented to our outpatient department on day 17 (day 1 = first day of fever) with nummular, erythematous and desquamating skin eruptions on his arms, legs and face. When he was admitted and treated for KD, he presented with pyrexia, a morbilliform rash and conjunctivitis evident since 4 days. In addition to the aforementioned symptoms, cracked lips were present (► **Fig. 1 and 2**). Biochemical and haematological parameters revealed a C-reactive protein of 112 mg/l, abnormal liver function tests (ALAT 2x upper norm), elevated NT-proBNP of 4473 pg/ml, anaemia (Hb 68 g/l) and an erythrocyte sedimentation rate (ESR) of 77 mm/1 h with normal platelets and no lymphopaenia. A nasopharyngeal aspirate PCR test was negative for respiratory viruses (including SARS-CoV-2). Serum SARS-CoV-2 IgG (anti-Nucleocapsid IgG and anti-Spike protein IgG) were negative. Echocardiography did not show any abnormalities. Fulfilling clinical criteria for complete KD, treatment with high-dose intravenous immunoglobulins (2 g/kg/dose) and high-dose oral acetyl salicylic acid (65 mg/kg/day) was initiated, and given his young age, intravenous methylprednisolone (2 mg/kg/day) was added. His clinical course was favourable and he defervesced within the first 24 hours after initiating KD treatment. On day 10 he was discharged on a weaning dose of oral prednisolone and low dose oral acetyl salicylic acid.



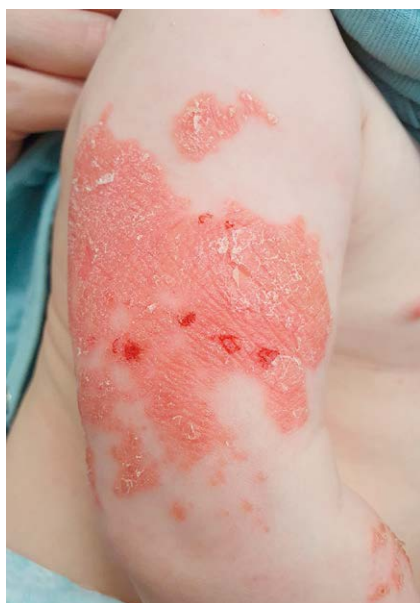► **Fig. 1** eruptions on face on day 17 after onset of symptoms (outpatient follow-up).



► **Fig. 2** rash on face when admitted, day 4 of fever.

As a side note, the fact that there was no evidence of either a relevant COVID-19 exposure or positive microbiological samples, and in the absence of lymphopaenia or other suggestive laboratory markers, we considered KD-like PIMS-TS (Paediatric Inflammatory Multisystem Syndrome – Temporally associated with COVID-19) highly unlikely.

On day 17, when he was scheduled for a planned follow-up appointment in our outpatient department, he presented with well-demarcated, erythematous scaly plaques on his face and arms (► **Fig. 3**



► **Fig. 3** eruptions on upper extremity on day 17 after onset of symptoms (outpatient follow-up).

and **4**) without any nappy area involvement. These lesions were clearly distinguishable from the previous rash, but the areas affected were similar. We classified these eruptions as diffuse plaque psoriasis. A skin biopsy was withheld. Topical treatment with tacrolimus cream 0.03% and an emollient was initiated and resulted in resolution of symptoms within 3 weeks.

Discussion

Data shows that psoriasis developing in the context of KD affects only a small subset of patients during the acute, subacute, or convalescent phases of the disease (Eberhard B A et al., *J Pediatr* 2000; 137, 4: 578–580). The prevalence of psoriasiform eruptions among children with KD may be higher than the prevalence in the general paediatric population. Haddock et al. reported 1.3% in children with KD (i. e. 11 of 870) vs prevalence estimates of 0.19% to 1.4% in the general population (Haddock E S et al., *J Am Acad Dermatol* 2016; 75: 69–76). Histologically, these eruptions are indistinguishable from true psoriasis and do not appear to be a manifestation of KD vasculitis, as skin biopsies, which have been carried out in a proportion of cases, have not shown small or medium vessel vasculitis (Haddock E S et al., *J Am Acad Dermatol* 2016; 75: 69–76). In our case, we found a strong correlation of skin areas affected by the psoriatic eruptions and those initially involved with the KD rash. We hypothesise this to be explained by the Koebner's phenomenon (Ortonne J P, *Br J Dermatol* 1996; 135: 1–5) that describes the appearance of

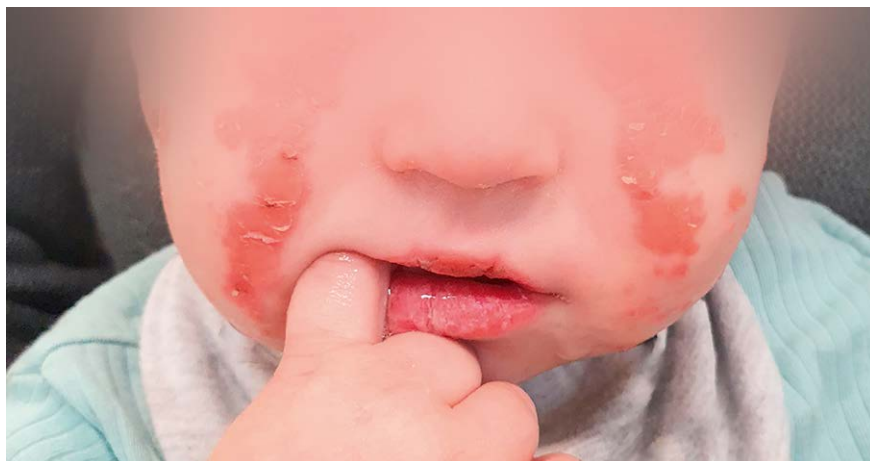psoriasis in areas of previous skin injuries and has been reported similarly in other case reports. Interestingly, this boy developed psoriatic eruptions whilst still on a moderate dose of systemic steroids, which is a very effective drug in downregulating KD induced systemic inflammation, but has indeed been reported to result in exacerbation of psoriasis in the general population even though its impact has been challenged by newer data (Gregoire A R F et al., *JAMA Dermatol* 2021; 157: 198–201).

Pathophysiologically, KD and psoriasis may share a common pathway, as proinflammatory cytokines produced during the acute phase of KD (Zvulunov A et al., *J Paediatr Child Health* 2003; 39: 229–231) result in the activation of Th17 cells and expression of IL-17/IL-22. These also play an important role in the pathogenesis of psoriasis (Marinoni B et al., *Auto-Immun Highlights* 2014; 5: 9–19). Moreover, the concept of super-antigen producing bacteria activating T-lymphocytes that have the potential to damage endothelial cells, might be an alternative or additional explanation of this correlation (Jappe U, *Acta Derm Venereol* 2000; 80: 321–328).

Finally, there is no evidence that psoriasiform eruptions would impact KD outcomes and it remains unclear whether the development of psoriatic lesions after KD entails the development of psoriasis later in life (Haddock E S et al., *J Am Acad Dermatol* 2016; 75: 69–76).

Conclusion

There is a substantial number of case reports and evidence available in the public literature, mostly published in the dermatological literature, of psoriasis triggered by KD in children and it is a well-known entity in the dermatology consortium. However, as of today it has not been broadly acknowledged by the paediatric community. With this case report, we seek to increase awareness amongst paediatricians. Parents may be reassured by the excellent long-term prognosis that differs from classic psoriasis.





► **Fig. 4** eruptions on face on day 17 after onset of symptoms (outpatient follow-up).

Contributor's Statement

All authors listed have made a substantial, direct and intellectual contribution to the work, and approved it for publication.

Authors

Nina Schöbi¹ , Kristin Kernland², Matthias Kopp³ , Christoph Aebi¹

Affiliations

- 1 Department of Paediatrics, Division of Paediatric Infectious Diseases, Inselspital Universitätsspital Bern Kinderklinik, Bern, Switzerland
- 2 Department of Pediatrics, Pediatric Dermatology, Kantonsspital Baden AG, Baden, Switzerland
- 3 University Clinic for Pediatrics, Inselspital Universitätsspital Bern, Bern, Switzerland

Correspondence

Dr. Nina Schöbi
Inselspital Universitätsspital Bern
Kinderklinik
Pädiatrische Infektiologie
Freiburgstrasse
3010 Bern
Switzerland
Tel.: 0041316322111
nina.schoebi@insel.ch

Bibliography

Klin Padiatr

DOI 10.1055/a-1885-3140

ISSN 0300-8630

© 2022. Thieme. All rights reserved.

This is an open access article published by Thieme under the terms of the Creative Commons Attribution-NonDerivative-NonCommercial-License, permitting copying and reproduction so long as the original work is given appropriate credit. Contents may not be used for commercial purpose, or adapted, remixed, transformed or built upon. (<https://creativecommons.org/licenses/by-nc-nd/4.0/>)

Georg Thieme Verlag, Rüdigerstraße 14,
70469 Stuttgart, Germany

