








RESEARCH ARTICLE

Mitochondrial fission factor (MFF) frameshift variant in Bullmastiffs with mitochondrial fission encephalopathy

Matthias Christen¹  | Rodrigo Gutierrez-Quintana²  | Helene Vandenberghe³  |
Adriana Kaczmarzka²  | Jacques Penderis⁴ | Roberto José-López⁵  | Angie Rupp² |
Ian R. Griffiths² | Vidhya Jagannathan¹  | Tosso Leeb¹ 

¹Institute of Genetics, Vetsuisse Faculty, University of Bern, Bern, Switzerland

²School of Veterinary Medicine, College of Medical Veterinary and Life Sciences, University of Glasgow, Glasgow, UK

³Highcroft Veterinary Referrals, Bristol, UK

⁴Vet-Extra Neurology, Stirling, UK

⁵Hamilton Specialist Referrals, IVC Evidensia, High Wycombe, UK

Correspondence

Tosso Leeb, Institute of Genetics, Vetsuisse Faculty, University of Bern, Bremgartenstrasse 109a, 3001 Bern, Switzerland.

Email: tosso.leeb@vetsuisse.unibe.ch

Abstract

Familial cerebellar ataxia with hydrocephalus in Bullmastiffs was described almost 40 years ago as a monogenic autosomal recessive trait. We investigated two young Bullmastiffs showing similar clinical signs. They developed progressive gait and behavioural abnormalities with an onset at around 6 months of age. Neurological assessment was consistent with a multifocal brain disease. Magnetic resonance imaging of the brain showed intra-axial bilateral symmetrical focal lesions localised to the cerebellar nuclei. Based on the juvenile age, nature of neurological deficits and imaging findings, an inherited disorder of the brain was suspected. We sequenced the genome of one affected Bullmastiff. The data were compared with 782 control genomes of dogs from diverse breeds. This search revealed a private homozygous frameshift variant in the *MFF* gene in the affected dog, XM_038574000.1:c.471_475delinsCGCTCT, that is predicted to truncate 55% of the wild type *MFF* open reading frame, XP_038429928.1: p.(Glu158Alafs*14). Human patients with pathogenic *MFF* variants suffer from 'encephalopathy due to defective mitochondrial and peroxisomal fission 2'. Archived samples from two additional affected Bullmastiffs related to the originally described cases were obtained. Genotypes in a cohort of four affected and 70 unaffected Bullmastiffs showed perfect segregation with the disease phenotype. The available data together with information from previous disease reports allow classification of the investigated *MFF* frameshift variant as pathogenic and probably causative defect of the observed neurological phenotype. In analogy to the human phenotype, we propose to rename this disease 'mitochondrial fission encephalopathy (MFE)'.

KEYWORDS

animal model, *Canis lupus familiaris*, dog, mitochondrion, neurology, precision medicine, veterinary medicine

This is an open access article under the terms of the [Creative Commons Attribution](https://creativecommons.org/licenses/by/4.0/) License, which permits use, distribution and reproduction in any medium, provided the original work is properly cited.

© 2022 The Authors. *Animal Genetics* published by John Wiley & Sons Ltd on behalf of Stichting International Foundation for Animal Genetics.

INTRODUCTION

Familial cerebellar ataxia with hydrocephalus in Bullmastiff dogs was initially described in 1983 (OMIA 002551-9615; Carmichael et al., 1983). Affected puppies of one litter showed ataxia, impaired vision and behavioural abnormalities consisting of hysterical behaviour, difficulty to train, backing compulsively when called and lifting a foreleg while eating. The clinical signs were macroscopically associated with symmetrical hydrocephalus and histologically with cerebellar vacuolisation, gliosis and axonal degeneration. It was hypothesised that the observed phenotype was due to a genetically determined metabolic disturbance with an autosomal recessive mode of inheritance (Carmichael et al., 1983). Four years later, the same author described a total of six closely related Bullmastiff dogs with similar clinical signs (Carmichael, 1987). Additionally, abnormally shaped mitochondria in axons of affected brain regions were found in electron micrographs, leading to the conclusion that the dogs suffered from a neuronal abiotrophy caused by an intrinsic metabolic effect (Carmichael, 1987). Magnetic resonance imaging (MRI) demonstrated changes within the deep cerebellar nuclei in additional affected dogs (Johnson et al., 2001).

The current study was prompted by reports of two cases of Bullmastiffs from different litters showing behavioural and gait abnormalities. We hypothesised that the dogs might be affected by the same disease that was first described almost 40 years ago and initiated a genetic investigation.

MATERIALS AND METHODS

Clinical examinations

An 8-month-old, female entire Bullmastiff (case no. 1) and a 6-month-old, male entire Bullmastiff (case no. 2) underwent physical and neurological examinations. Additional laboratory investigations included a complete blood cell count, serum biochemistry (including electrolyte levels) and serology for canine distemper virus (case no. 2 only), *Toxoplasma gondii* and *Neospora caninum*. Additionally, a cisternal cerebrospinal fluid sample (case no. 2) was submitted for protein levels and total and differential cell counts, and for this dog also urine was submitted to an external human testing laboratory for organic acid analysis.

Magnetic resonance imaging examination

Magnetic resonance imaging of the brain was performed on case no. 2 with a 1.5 Tesla machine (1.5T Magnetom, Siemens) and included T_2 -weighted sagittal, dorsal and transverse views, with the following transverse views: fluid attenuated inversion recovery and gradient echo T_2^* , T_1 -weighted pre- and post-contrast sequences (gadopentate dimeglumine; Magnevist, Bayer Schering Pharma AG).

Post-mortem examination

Owing to clinical progression, case no. 2 was euthanised and a post-mortem examination was performed. Representative samples of heart, lungs, liver and brain were stained with hematoxylin and eosin and examined histologically.

Genetic analyses

Animal samples

The study included samples from 74 Bullmastiffs. We used EDTA blood samples from the two contemporary clinical cases (case nos 1 and 2) and formalin-fixed paraffin-embedded (FFPE) tissue samples from two additional affected dogs seen in 1996 (case nos 3 and 4) that were reportedly siblings and closely related to the previously reported cases (Carmichael, 1987). The FFPE samples of the historical cases were kindly provided by the pathology service of the School of Veterinary Medicine of the University of Glasgow. EDTA blood samples of 70 additional Bullmastiffs that had been donated to the Vetsuisse Biobank were used as controls. They consisted of five unaffected close relatives of case no. 2 and 65 population controls without known relationships to any of the cases.

DNA extraction

Genomic DNA was isolated from EDTA blood with the Maxwell RSC Whole Blood Kit using a Maxwell RSC instrument (Promega). The same instrument was used for DNA isolation from FFPE tissue samples with the Maxwell RSC DNA FFPE kit.

Whole-genome sequencing

An Illumina TruSeq PCR-free DNA library with a ~390 bp insert size of case no. 1 was prepared. We collected 241 million 2×150 bp paired-end reads on a NovaSeq 6000 instrument ($27.5 \times$ coverage). Mapping and alignment were performed as described in Jagannathan et al. (2019). The sequence data were deposited under the study accession no. PRJEB16012 and sample accession no. SAMEA8157163 at the European Nucleotide Archive.

Variant calling and filtering

Variant calling was performed using GATK HaplotypeCaller (McKenna et al., 2010) in gVCF mode as described by Jagannathan et al. (2019). To predict the functional effects of the called variants, snpeff software (Cingolani et al., 2012) together with NCBI annotation release 106 for the UU_Cfam_GSD_1.0 genome reference

assembly was used. For variant filtering, we used 782 genetically diverse control dog genomes representing 175 different dog breeds and 21 mixed-breed dogs (Table S1).

Private variants in the case were identified by a hard filtering approach of the vcf-file using a Python script. Private variants were required to have a homozygous alternate genotype in the case (1/1) and a homozygous reference (0/0) or missing genotype (./.) in the controls. The control cohort did not contain any Bullmastiffs; therefore the probability of having a heterozygous carrier in the control group was estimated as negligible.

Variants with SnpEff-predicted 'high' or 'moderate' impact were classified as protein-changing variants. These include missense, nonsense, frameshift and splice site variants.

Gene analysis

We used the UU_Cfam_GSD_1.0 dog reference genome assembly and NCBI annotation release 106. Numbering within the canine *MFF* gene corresponds to the NCBI RefSeq accession nos XM_038574000.1 (mRNA) and XP_038429928.1 (protein).

PCR and sanger sequencing

The candidate variant *MFF*:c.471_475delinsCGCTCT was genotyped by direct Sanger sequencing of PCR amplicons. A 380 bp (or 381 bp in case of the mutant allele) PCR product was amplified from genomic DNA using AmpliTaqGold360Mastermix (Thermo Fisher Scientific) and the primers 5'-CTCCCTTTCTTTGTGCCTCA-3' and 5'-CGAGAGGATAATGCTACTGGAAA-3'. A smaller PCR product of 101 bp size (or 102 bp in case of the mutant allele) was amplified from FFPE-derived DNA with the primers 5'-TCCCTTTCTTTGTGCCTCAC-3' and 5'-CTCTGACCAGCTGTCCGTTT-3'. After treatment with exonuclease I and alkaline phosphatase, amplicons were sequenced on an ABI 3730 DNA Analyzer (Thermo Fisher Scientific). Sanger sequences were analysed using the SEQUENCHER 5.1 software (GeneCodes).

RESULTS

Clinical investigations

An 8-month-old, female entire (case no. 1) and a 6-month-old, male entire (case no. 2) Bullmastiff presented with a chronic and progressive history of uncoordinated gait and abnormal behaviour including barking at imaginary objects and no interaction with other dogs, and decreased vision. The clinical signs were noticed by the owners a couple of months before presentation and had been gradually progressing. Some of the littermates were reported to be showing similar clinical

signs. Physical examination was mainly unremarkable, apart from case no. 1 exhibiting scuffing wounds on the dorsal aspect of both pelvic limbs. Neurological examination showed abnormal mentation and a wide-base stance (Video S1). The gait was abnormal with hypermetria affecting all limbs. Menace response was absent or decreased with normal pupillary light reflexes in both cases. Additionally, spontaneous and intermittent horizontal nystagmus was observed in case no. 2. Postural reactions (mainly hopping responses) were delayed in all limbs. No pain was elicited on spinal palpation and segmental spinal reflexes were normal. The neurological examination was consistent with a disease involving the cerebral cortex, leading to an abnormal behaviour and decreased vision, and the vestibulo-cerebellum, leading to cerebellar ataxia and nystagmus.

Complete blood cell count and serum biochemistry including electrolyte levels showed a mild increase in cholesterol and creatinine kinase in case no. 2. Serologies for canine distemper virus, *Toxoplasma gondii* and *Neospora caninum* were negative. Cerebrospinal fluid and urine organic acids analyses for case no. 2 were within normal range. MRI of the brain showed intra-axial bilateral symmetrical focal T_2 -weighted hyperintense, T_1 -weighted isointense and no contrast-enhancing lesions localised to the cerebellar nuclei. Additionally, the sulci of the cerebral cortex appeared widened with an increased amount of cerebrospinal fluid and the lateral ventricles were bilaterally enlarged (Figure 1).

Case no. 1 died owing to progression of clinical signs. No further information regarding the age of the dog and circumstances of death are available. Case no. 2 was euthanised at 10 months of age owing to progression of the clinical signs. Post-mortem examination confirmed spongy vacuolar changes in the cerebellar nuclei as previously reported (Carmichael et al., 1983). Mild to moderate dilation of the left cardiac ventricle, less so the right ventricle, compatible with a dilated cardiomyopathy, was observed, in turn considered the cause for the mild hydrothorax, ascites and hydropericardium present, as well as pulmonary congestion, hepatic centrilobular fibrosis and mild tunica media hyperplasia of the small arteries in the septal myocardium.

Genetic analysis

At the beginning of the genetic analysis, we only had access to a single affected dog (case no. 1). As the clinical and neurological findings of this case resembled previously described cases in Bullmastiffs, we hypothesised that the phenotype in the affected dog was due to a genetic defect with a monogenic autosomal recessive mode of inheritance. We sequenced the genome of case no. 1 and identified private homozygous variants that were not present in the genome sequences of 782 control dogs of diverse breeds (Table 1 and Tables S1 and S2).

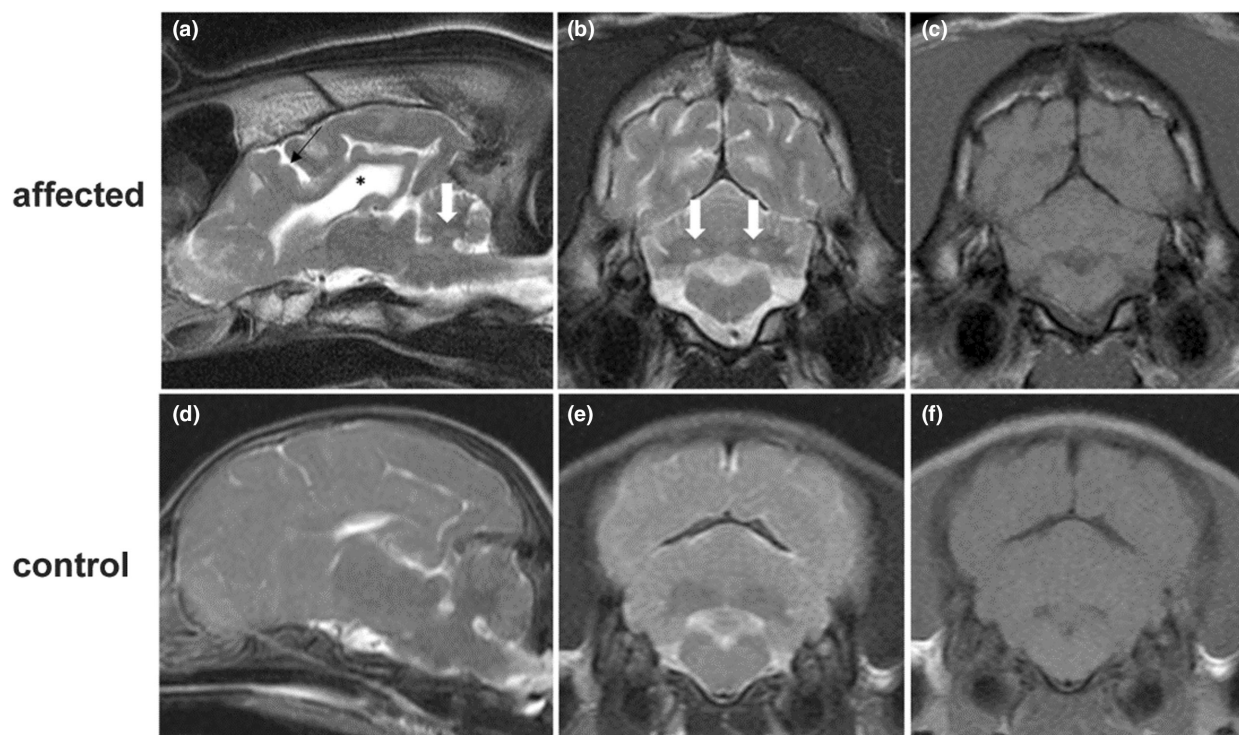


FIGURE 1 Magnetic resonance imaging of case no. 2 and an age-matched control. (a) T_2 -weighted parasagittal image of the brain showing widening of the cerebral sulci (black arrow), lateral ventricle enlargement (black asterisk) and hyperintensity of the cerebellar nuclei (white arrow). Transverse T_2 -weighted image (T2WI) (b) and T_1 -weighted image (T1WI) (c) at the level of the cerebellum showing bilateral and symmetric T2WI intra-axial hyperintensities at the level of the cerebellar nuclei (white arrows); these lesions are isointense on T1WI (c). (d) T_2 -weighted parasagittal of an age-matched control with no widening of the cerebral sulci or enlargement of the lateral ventricle for comparison. Transverse T2WI (e) and T1WI (f) at the level of the cerebellum of an age-matched control with no lesions.

TABLE 1 Homozygous variants in case no. 1, filtered against 782 control genomes

Filtering step	Variants
All variants in the affected dog	2859 546
Private variants	591
Protein-changing private variants	8

The resulting variants were prioritised according to functional knowledge of the affected genes. The automated bioinformatic analysis identified two independent homozygous private protein-changing variants at neighbouring nucleotides in the functional candidate gene *MFF* encoding the mitochondrial fission factor. Visual inspection of the short read alignments in the affected region revealed that the two initially separately called variants actually represented just one single insertion–deletion variant. This variant, XM_038574000.1:c.471_475delinsCGCTCT, leads to a frameshift and is predicted to truncate 209 codons or roughly 55% of the wild type MFF open reading frame, XP_038429928.1:p.(Glu158Alafs*14). On the genomic level, the variant can be described as Chr-25:40,322,999_40,323,003delinsCGCTCT (UU_Cfam_GS-D_1.0 assembly). The other six private protein-changing variants were not located in genes known to cause similar phenotypes in humans, mice or domestic animals.

We confirmed the presence of the *MFF* variant in a homozygous state in case no. 1 by Sanger sequencing (Figure 2a). At this point of the genetic analysis, we became aware of the second case with a very similar phenotype to the index case. We also genotyped the second case and five of its unaffected close relatives (Figure 2b).

Furthermore, we identified FFPE archived samples from two additional young Bullmastiff siblings seen in 1996 (cases no. 3 and 4) with similar clinical presentation and closely related to previously reported cases (Carmichael, 1987). We genotyped the *MFF* variant in the additional cases and a cohort of unrelated control Bullmastiffs (Table 2). These analyses confirmed a perfect genotype–phenotype association. All four available cases were homozygous mutant, one obligate carrier was heterozygous and none of the 70 unaffected dogs were homozygous for the mutant allele. The carrier frequency in the unrelated control cohort was 12/65 (18%).

DISCUSSION

We describe two contemporary cases of Bullmastiffs with progressive behavioural and gait abnormalities exhibiting a similar clinical phenotype to dogs reported almost 40 years ago (Carmichael, 1987; Carmichael et al., 1983).

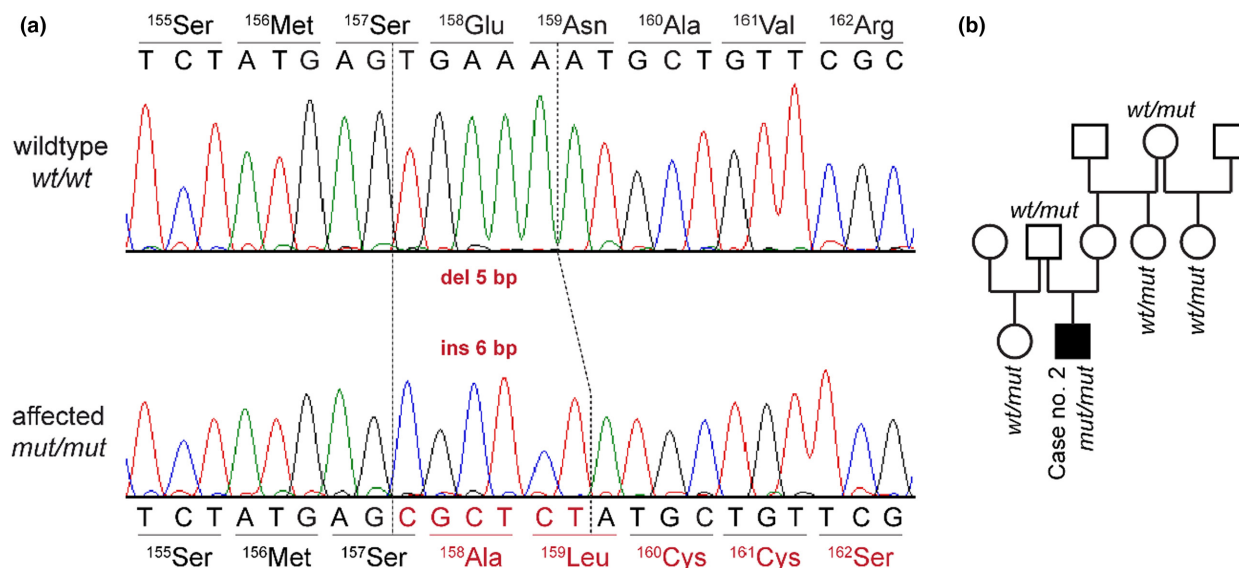


FIGURE 2 Details of the *MFF*:C.471_475delinsCGCTCT variant. (a) Representative electropherograms of a control and an affected dog are shown. The amino acid translations of the wild type and mutant alleles are indicated. (b) Pedigree of case no. 2. The genotypes at the *MFF*:C.471_475delinsCGCTCT variant are indicated for sampled dogs. The sire of case no. 2 was confirmed to be heterozygous as expected for an obligate carrier of a monogenic autosomal recessive trait.

Phenotype	Wt/Wt	Wt/Mut	Mut/Mut
Affected Bullmastiffs ($n = 4$)	–	–	4
Non-affected relatives of case no. 2 ($n = 5$)	–	5	–
Unrelated control Bullmastiffs ($n = 65$)	53	12	–

TABLE 2 Association of the genotypes at the *MFF*:C.471_475delinsCGCTCT variant with ataxia and hydrocephalus in 74 bullmastiffs

In this study, we provide a plausible candidate disease causing variant, *MFF*:c.471_475delinsCGCTCT. The *MFF* gene encodes the mitochondrial fission factor (Gandre-Babbe & van der Bliek, 2008). Mitochondria are subject to a constant series of fusion and fission in order to regulate subcellular processes and their own homeostasis. Thus, mitochondrial morphology is dynamically regulated at all times (Meyer et al., 2017).

Loss of function variants in the *MFF* gene result in a cellular phenotype with elongated tubular mitochondria because the organelles can still fuse while fission is blocked (Gandre-Babbe & van der Bliek, 2008; Otera et al., 2010). The resulting hyperfused mitochondria may be resistant to autophagosomal degradation leading to the accumulation of damaged and abnormally functioning mitochondria as well as reactive oxygen species (Meyer & Bess, 2012; Twig et al., 2008).

These mitochondrial defects result in a specific clinical phenotype in human patients with *MFF* variants, which is termed ‘encephalopathy due to defective mitochondrial and peroxisomal fission 2’ (OMIM# 617086, Shamseldin et al., 2012; Koch et al., 2016; Nasca et al., 2018; Panda et al., 2020). Changes to mitochondrial morphology with those exhibiting elongated tubular shapes have been observed both in human patients (Koch et al., 2016) and in affected dogs (Carmichael, 1987). Furthermore, bilateral symmetrical MRI changes affecting the basal and

cerebellar nuclei have been reported in humans with *MFF* variants (Nasca et al., 2018) sharing some similarities with the MRI changes reported in the present and previously reported dogs (Johnson et al., 2001). Further studies will be necessary to understand the predilection for specific nuclei which appears to vary between species and/or variants.

Mff^{−/−} knockout mice die prematurely with a mean life span of 13 weeks. The murine phenotype is characterised by a severe dilated cardiomyopathy in combination with prominent neuromuscular defects (Chen et al., 2015). Interestingly, the post-mortem examination of one of the affected dogs showed mild to moderate dilated cardiomyopathy. Further studies will be needed to determine the degree and significance of the cardiac changes observed in dogs with this *MFF* variant.

The canine *MFF*:c.471_475delinsCGCTCT variant is predicted to truncate 55% of the open reading frame of the wild type *MFF* transcript, XP_038429928.1:p. (Glu158Alafs*14). We assume that the premature stop codon results in a complete loss of function. The mutant allele was absent in whole genome sequence data of 782 control dogs from genetically diverse breeds. Three additional affected Bullmastiffs with strikingly similar phenotypes carried the same homozygous mutant genotype, while 70 non-affected Bullmastiff dogs were found to be free of the homozygous mutant genotype. The pedigrees

of the affected dogs strongly suggested monogenic autosomal recessive inheritance (Carmichael, 1987). The phenotype with documented changes in mitochondrial morphology (Carmichael, 1987) is highly specific. Extrapolating the established guidelines for the interpretation of sequence variants in human medicine (Richards et al., 2015) to dogs, these arguments allow the *MFF:c.471_475delinsCGCTCT* variant to be classified as pathogenic.

The clinical and pathological features of this disease that closely resemble the human phenotype, together with the genetic findings, suggest *MFF:c.471_475delinsCGCTCT* as compelling causative variant. To the best of our knowledge, the affected dogs represent the first domestic animals described with an *MFF*-related disease. In analogy to the human phenotype, we tentatively propose to rename the phenotype seen in Bullmastiffs 'mitochondrial fission encephalopathy (MFE)'. Our results enable genetic testing, which can be used to avoid the unintentional breeding of further MFE-affected dogs. In addition, the studied dogs might serve as a spontaneous large animal model to further the understanding of mitochondrial fission dysfunction in human patients.

ACKNOWLEDGMENTS

The authors are grateful to the dog owners who donated samples and participated in the study. We thank the Next Generation Sequencing Platform of the University of Bern for performing the high-throughput sequencing experiments and the Interfaculty Bioinformatics Unit of the University of Bern for providing high-performance computing infrastructure. We acknowledge the Dog10K genomes project and all researchers who have deposited dog or wolf whole genome sequencing data into public databases. We thank Dr Mark MacLaughlin, Jennifer Barrie and Lynn Stevenson for helping locate the FFPE samples from the historical cases. Open access funding provided by Universitat Bern.

FUNDING INFORMATION

This research did not receive any specific grant from funding agencies in the public, commercial, or not-for-profit sectors.

CONFLICT OF INTEREST

The authors declare no conflict of interest.

DATA AVAILABILITY STATEMENT

The accession nos for the sequence data reported in this study are listed in Table S1.


ETHICAL APPROVAL


All animal experiments were performed according to local regulations. The dogs in this study are privately owned and were examined with the consent of the owners. The Cantonal Committee for Animal Experiments

approved the collection of blood samples from control dogs that were used in this study (Canton of Bern; permit BE 71/19).

ORCID


Matthias Christen  <https://orcid.org/0000-0003-3275-5929>

Rodrigo Gutierrez-Quintana  <https://orcid.org/0000-0002-3570-2542>

Helene Vandenberghe  <https://orcid.org/0000-0001-8738-7006>

Adriana Kaczmarek  <https://orcid.org/0000-0002-7088-8207>

Roberto José-López  <https://orcid.org/0000-0002-0661-5562>

Vidhya Jagannathan  <https://orcid.org/0000-0002-8155-0041>

Tosso Leeb  <https://orcid.org/0000-0003-0553-4880>

REFERENCES

- Carmichael, S., Griffiths, I. & Harvey, M. (1983) Familial cerebellar ataxia with hydrocephalus in bull mastiffs. *Veterinary Record*, 112, 354–358. Available from: <https://doi.org/10.1136/vr.112.15.354>
- Carmichael, S. (1987) *Familial cerebellar ataxia in the Bull Mastiff*. Master Thesis. Glasgow: University of Glasgow Veterinary School. Available from: <https://theses.gla.ac.uk/77525/1/10995573.pdf>. [Accessed 06th September 2022].
- Chen, H., Ren, S., Clish, C., Jain, M., Mootha, V., McCaffery, J.M. et al. (2015) Titration of mitochondrial fusion rescues Mff-deficient cardiomyopathy. *Journal of Cell Biology*, 211, 795–805. Available from: <https://doi.org/10.1083/jcb.201507035>
- Cingolani, P., Platts, A., Wang, L.L., Coon, M., Nguyen, T., Wang, L. et al. (2012) A program for annotating and predicting the effects of single nucleotide polymorphisms, SnpEff. *Fly (Austin)*, 6, 80–92. Available from: <https://doi.org/10.4161/fly.19695>
- Gandre-Babbe, S. & van der Blik, A.M. (2008) The novel tail-anchored membrane protein Mff controls mitochondrial and peroxisomal fission in mammalian cells. *Molecular Biology of the Cell*, 19, 2402–2412. Available from: <https://doi.org/10.1091/mbc.e07-12-1287>
- Jagannathan, V., Drögemüller, C., Leeb, T. & Dog Biomedical Variant Database Consortium (DBVDC). (2019) A comprehensive biomedical variant catalogue based on whole genome sequences of 582 dogs and eight wolves. *Animal Genetics*, 50, 695–704. Available from: <https://doi.org/10.1111/age.12834>
- Johnson, R.P., Neer, T.M., Partington, B.P., Cho, D.Y. & Partington, C.R. (2001) Familial cerebellar ataxia with hydrocephalus in bull mastiffs. *Veterinary Radiology & Ultrasound*, 42, 246–249. Available from: <https://doi.org/10.1111/j.1740-8261.2001.tb00934.x>
- Koch, J., Feichtinger, R.G., Freisinger, P., Pies, M., Schrödl, F., Iuso, A. et al. (2016) Disturbed mitochondrial and peroxisomal dynamics due to loss of MFF causes Leigh-like encephalopathy, optic atrophy and peripheral neuropathy. *Journal of Medical Genetics*, 53, 270–278. Available from: <https://doi.org/10.1136/jmedgenet-2015-103500>
- McKenna, A., Hanna, M., Banks, E., Sivachenko, A., Cibulskis, K., Kernysky, A. et al. (2010) The Genome Analysis Toolkit: a MapReduce framework for analyzing next-generation DNA sequencing data. *Genome Research*, 20, 1297–1303. Available from: <https://doi.org/10.1101/gr.107524.110>
- Meyer, J.N., Leuthner, T.C. & Luz, A.L. (2017) Mitochondrial fusion, fission, and mitochondrial toxicity. *Toxicology*, 391, 42–53. Available from: <https://doi.org/10.1016/j.tox.2017.07.019>

- Meyer, J.N. & Bess, A.S. (2012) Involvement of autophagy and mitochondrial dynamics in determining the fate and effects of irreparable mitochondrial DNA damage. *Autophagy*, 8, 1822–1823. Available from: <https://doi.org/10.4161/auto.21741>
- Nasca, A., Nardecchia, F., Commone, A., Semeraro, M., Legati, A., Garavaglia, B. et al. (2018) Clinical and biochemical features in a patient with mitochondrial fission factor gene alteration. *Frontiers in Genetics*, 9, 1–8. Available from: <https://doi.org/10.3389/fgene.2018.00625>
- Otera, H., Wang, C., Cleland, M.M., Setoguchi, K., Yokota, S., Youle, R.J. et al. (2010) Mff is an essential factor for mitochondrial recruitment of Drp1 during mitochondrial fission in mammalian cells. *Journal of Cell Biology*, 191, 1141–1158. Available from: <https://doi.org/10.1083/jcb.201007152>
- Panda, I., Ahmad, I., Sagar, S., Zahra, S., Shamim, U., Sharma, S. et al. (2020) Encephalopathy due to defective mitochondrial and peroxisomal fission 2 caused by a novel *MFF* gene mutation in a young child. *Clinical Genetics*, 97, 933–937. Available from: <https://doi.org/10.1111/cge.13740>
- Richards, S., Aziz, N., Bale, S., Bick, D., Das, S., Gastier-Foster, J. et al. (2015) Standards and guidelines for the interpretation of sequence variants: a joint consensus recommendation of the American College of Medical Genetics and Genomics and the Association for Molecular Pathology. *Genetics in Medicine*, 17, 405–424. Available from: <https://doi.org/10.1038/gim.2015.30>
- Shamseldin, H.E., Alshammari, M., Al-Sheddi, T., Salih, M.A., Alkhalidi, H., Kentab, A. et al. (2012) Genomic analysis of mitochondrial diseases in a consanguineous population reveals novel candidate disease genes. *Journal of Medical Genetics*, 49, 234–241. Available from: <https://doi.org/10.1136/jmedgenet-2012-100836>
- Twig, G., Hyde, B. & Shirihai, O.S. (2008) Mitochondrial fusion, fission and autophagy as a quality control axis: the bioenergetic view. *Biochimica et Biophysica Acta – Bioenergetics*, 1777, 1092–1097. Available from: <https://doi.org/10.1016/j.bbabi.2008.05.001>

SUPPORTING INFORMATION

Additional supporting information can be found online in the Supporting Information section at the end of this article.

How to cite this article: Christen, M., Gutierrez-Quintana, R., Vandenberghe, H., Kaczmarek, A., Penderis, J., José-López, R. et al. (2022) Mitochondrial fission factor (MFF) frameshift variant in Bullmastiffs with mitochondrial fission encephalopathy. *Animal Genetics*, 53, 814–820. Available from: <https://doi.org/10.1111/age.13263>