HHS Public Access
Author manuscript
Oncogene. Author manuscript; available in PMC 2022 September 08.

Published in final edited form as:
Oncogene. 2022 June ; 41(26): 3455–3460. doi:10.1038/s41388-022-02350-6.

Molecular profiling of signet-ring-cell carcinoma (SRCC) from the stomach and colon reveals potential new therapeutic targets

Alberto Puccini[1,2], **Kelsey Poorman**[3], **Fabio Catalano**[2], **Andreas Seeber**[4], **Richard M. Goldberg**[5], **Mohamed E. Salem**[6], **Anthony F. Shields**[7], **Martin D. Berger**[1], **Francesca Battaglin**[1], **Ryuma Tokunaga**[1], **Madiha Naseem**[1], **Wu Zhang**[1], **Philip A. Philip**[7], **John L. Marshall**[8], **W. Michael Korn**[3], **Heinz-Josef Lenz**[1,✉]

[1]Norris Comprehensive Cancer Center, Keck School of Medicine, University of Southern California, Los Angeles, CA, USA.

[2]University of Genoa, Ospedale Policlinico San Martino—IRCCS, Genova, Italy.

[3]Caris Life Sciences, Phoenix, AZ, USA.

[4]Department of Hematology and Oncology, Comprehensive Cancer Center Innsbruck, Innsbruck Medical University, Innsbruck, Austria.

[5]West Virginia University Cancer Institute, Morgantown, WV, USA.

[6]Levine Cancer Institute, Charlotte, NC, USA.

[7]Department of Oncology, Karmanos Cancer Institute, Wayne State University, Detroit, MI, USA.

[8]Ruesch Center for The Cure of Gastrointestinal Cancers, Lombardi Comprehensive Cancer Center, Georgetown University Medical Center, Washington, DC, USA.

Abstract

Signet ring cell carcinoma (SRCC) is rare: about 10% of gastric cancer (GC) and 1% of colorectal cancer (CRC). SRCC is associated with poor prognosis, however the underlying molecular characteristics are unknown. SRCCs were analyzed using NGS, immunohistochemistry, and in situ hybridization. Tumor mutational burden (TMB) was calculated based on somatic nonsynonymous missense mutations, and microsatellite instability (MSI) was evaluated by NGS of known MSI loci. A total of 8500 CRC and 1100 GC were screened. Seventy-six SRCC were identified from the CRC cohort (<1) and 98 from the GC cohort (9%). The most frequently mutated genes in

✉**Correspondence** and requests for materials should be addressed to Heinz-Josef Lenz. lenz@med.usc.edu.

AUTHOR CONTRIBUTIONS
Conception of the work; acquisition, analysis, and interpretation of data: AP, KP, HJL. Revision and approval of the submitted version: All authors

COMPETING INTERESTS
KP and WMK are employed by Caris Life Sciences. JLM and AS are consultants for Caris Life Sciences. AFS and RMG received research and travel support from Caris Life Sciences. MES and H-JL received travel support from Caris Life Sciences. AP, FC, FB, MDB, RT, MN, WZ, and PAP declare that there are no competing interests.

ETHICS APPROVAL
All human subjects' data were de-identified prior to analysis. Thus, this research was determined to be exempt from the requirement for informed consent per the Western Institutional Review Board (WIRB).

ADDITIONAL INFORMATION
Reprints and permission information is available at http://www.nature.com/reprints

CRC-SRCC were *TP53* (47%), *ARID1A* (26%), *APC* (25%); in GC-SRCC were *TP53* (42%), *ARID1A* (27%), *CDH1* (11%). When compared to non-SRCC histology ($N = 3522$), CRC-SRCC ($N = 37$) more frequently had mutations in *BRCA1* (11% vs 1%, $P < 0.001$) and less frequently mutations in *APC* (19% vs 78%, $P < 0.001$ *KRAS* (22% vs 51%, $P = 0.001$) and *TP53* (47% vs 73%, $P = 0.001$). Among the GC cohort, SRCC ($N = 54$) had a higher frequency of mutations in *CDH1*, *BAP1*, and *ERBB2*, compared to non-SRCC ($N = 540$). Our data suggest that SRCCs harbor a similar molecular profile, regardless of the tumor location. Tailored therapy may become available for these patients.

INTRODUCTION

Signet-ring cell carcinoma (SRCC) is defined according to the World Health Organization (WHO) classification as a poorly cohesive carcinoma composed predominantly of tumor cells with prominent cytoplasmic mucin and a crescent-shaped nucleus eccentrically placed [1].

Besides gastric cancer, SRCC histology may be found in several other solid cancers, including colorectal cancer (CRC) [2], esophagus [3], breast [4], prostate [5], among others, although the prevalence of SRCC in these tumor types is very low [6]. However, the molecular characteristics underlying the biology of these tumors have not been elucidated yet.

Formally, a cancer is labeled a SRCC if greater than 50% of tumor cells show prominent intracytoplasmic mucin and an eccentrically placed crescent-shaped nucleus, whereas adenocarcinomas with less than 50% signet ring cells are classified as “adenocarcinomas” with a signet ring cell component [7, 8].

Regarding gastric cancer, despite a decrease in the overall incidence of gastric cancer in recent decades, the incidence of signet-ring cell carcinoma (SRCC) is constantly increasing globally, accounting for 35–45% of gastric adenocarcinoma cases in recent studies [9, 10]. Indeed, its incidence increased tenfold between 1970 and 2000 [11]. This increase in prevalence can be partially explained by changes in the pathological classifications used to characterize these cancers. It is important to understand that signet-ring cell adenocarcinomas are always classified, by definition, as “undifferentiated type” by Nakamura and as “diffuse type” by Lauren. But, conversely, not all gastric cancers classified as “undifferentiated” or “diffuse” are signetring cell cancers. Demographically, SRCC is more frequent in women and in younger patients than non-SRCC [12]. The prognosis of signet-ring cell adenocarcinoma is still debated and appears to depend on the stage of the cancer at the time of diagnosis [13]. In fact, in early gastric cancer, patients with SRCC demonstrated more favorable prognoses than those with adenocarcinomas, while SRCC patients with advanced gastric cancer had a worse prognosis [14]. Recently, Kong et al. [15] showed that SRCC histology was correlated with a poor prognosis in terms of recurrence in node-negative gastric cancer patients and that SRCC histologic analysis combined with AJCC staging may be an effective method for prediction of the recurrence rate.

Regarding CRC, many studies have reported a younger median age of onset for SRCC compared to CRC adenocarcinomas [16–19]. The incidence of colorectal cancer in younger patients is rising, posing a global health issue. The cause of this trend remains unknown, although lack of screening, obesity, physical inactivity, and Western diets may play a crucial role in early-onset CRC [20]. Due to the rarity of the histology, specific SRCC risk factors are not known. Since shared risk factors might exist, further investigations into causality are necessary to develop potential preventive strategies. Few studies clearly showed higher rates among women as is seen in gastric SRCC, while others have found no difference between men and women [21]. Inamura and colleagues [22] showed that even when the signet-ring cell component was less than 50% the finding was associated with higher mortality, independent of other clinicopathologic and molecular features (microsatellite instability - MSI, CpG island methylator phenotype, LINE-1 methylation, and *KRAS*, *BRAF*, and *PIK3CA* mutations) in CRC patients. In CRC, SRCC is generally considered to be associated with MSI-high and molecular features common to other MSI-high and mismatch repair deficient (dMMR) CRCs. Although MSI-high is a well-established prognostic biomarker for better survival in patients with localized disease stages, signet-ring cell carcinoma is associated with shorter survival in CRC patients [23]. More recently, a huge effort by authors from The University of Texas MD Anderson Cancer Center, demonstrated that SRCCs are more commonly found in patients with right-sided tumors, poorly differentiated tumors or peritoneal metastasis. SRCC were commonly found with *KRAS* wild-type (WT), *APC* WT and *PIK3CA* WT, while no significant association was observed between SRCC and MSI, *NRAS*, *BRAF*, *SMAD4*, *TP53* or *FBXW7* status. Finally, patients with SRCC tumors had significantly worse overall survival (OS) than patients with adenocarcinomas [16].

Therefore, further studies are warranted to elucidate molecular mechanisms accounting for the aggressive behavior.

To our knowledge, our research is one of the largest to comprehensively characterize the molecular features of SRCC, focusing on gastric cancers and CRCs. We investigate whether SRCCs harbor different molecular characteristics compared with non-SRCC counterparts. In addition, we compare SRCCs tumors arising from different locations (e.g., gastric SRCC vs CRC SRCC) to evaluate whether SRCC histology harbor molecular similarities, regardless of tumor location.

RESULTS

A total of 11,768 patients (10,459 with CRC and 1309 with GC) were included in this study and were screened for any SRCC histology. Seventy-six SRCC were identified from the CRC cohort (<1%) and 98 from the GC cohort (9%), of which 54 and 45 were profiled with 592-gene panels, respectively and the rest with the 44-gene panel (Fig. 1).

The most frequently mutated genes among the CRC-SRCC are *TP53* (47%), *ARID1A* (26%), *APC* (25%), *KRAS* (22%), *RNF43* (16%), *KMT2D* (12%), *KMT2C* (11%), *SMAD4* (10%), BRAF (10%) and *BRCA1* (7%): for this analysis we combined both the 592-gene and 44-gene DNA data into a single cohort. Twenty percent of CRC-SRCC were NGS-MSI

and 17% showed TMB-high (Fig. 2). From 592-gene cohort only, which was used for the comparison to the traditional CRC, when compared to non-SRCC histology ($N = 3522$), CRC-SRCC more frequently had mutations in *BRCA1* (9.1% vs 1%, $P = 0.002$) and less mutations in *APC* (22% vs 78%, $P < 0.001$), *KRAS* (20% vs 51%, $P = 0.001$) and *TP53* (48% vs 73%, $P = 0.001$) (Fig. 3).

The most frequently mutated genes in GC-SRCC were *TP53* (42%), *ARID1A* (27%), *CDH1* (11%), *BAP1* (7%), *PIK3CA* (7%), *ERBB2* (5%). PD-L1 overexpression was 45%, NGS-MSI was seen in 3.5% of GC-SRCC; only 1.8% showed TMB-high (Fig. 4).

Among the GC cohort, SRCC ($N = 54$) had a higher frequency of mutations in *CDH1* (20% vs 8%, $P = 0.005$), *BAP1* (7.4% vs 2%, $P = 0.039$), and *ERBB2* (9.3% vs 3.9%, $P = 0.072$), and a higher rate of amplification in MYB (4.1% vs 0%, $P = 0.005$) compared to nonSRCC ($N = 540$), although none reached statistical significance after correction for multiple comparisons (Fig. 5).

When we compared GC-SRCC vs. CRC-SRCC, only the mutation rate in *APC* (0% vs 25%) and *KRAS* (2% vs 22%) genes were significantly different ($P < 0.001$). Furthermore, increased rates of MSI (20% vs 3.5%, $P = 0.008$) and high TMB (17.8 vs 1.8, $P = 0.013$) were seen in CRC-SRCC compared to GC-SRCC (Fig. 6).

DISCUSSION

Signet ring cells are characterized by the presence of a large central optically clear droplet of cytoplasmic mucin that displaces the nucleus to the cell periphery [24].

The World Health Organization (WHO) classified SRCCs as a group of rare tumors defined by the content of signet ring celltype cells greater than 50%. However, there is a need for a better classification supported by conflicting data about the frequency and prognostic relevance of SRC histology [25]. Therefore, some authors suggested a different classification to standardize the definition of GC-SRCC: they proposed that only WHO “poorly cohesive” GC with more than 90% signet ring cell morphology should be classified as SRCC [26]. In CRC-SRCC other authors reported that even less than 50% of signet ring cell component is associated with a worse prognosis [12]. Due to the worse prognosis and the differences in response rate to the common therapeutic schedules, better classification of this rare histological subtype is needed.

It seems that colorectal cancers with SRC histology do not develop through the usual sequence of colorectal carcinogenesis, arising *de novo* without passing through the adenoma-carcinoma transformation [27]. The most frequent mutations involved in the adenoma-carcinoma tumorigenic progression are *APC*, *KRAS*, and *PIK3CA* [28]. A prospective targeted sequencing of 1134 CRCs identified in the subgroup of microsatellite stable (MSS) patients ($N = 1027$, only 5 patients with SRC histology) the most frequently mutated genes are as follows: 79% harbored *APC* mutation, 44% *KRAS* mutation, and 18% *PIK3CA* mutation [29]. According to the Tumor Cancer Genome Atlas, the rate of gene mutations in CRC was: *APC* 51% in hypermutated samples vs. 81% in non-hypermutated,

KRAS 43%, and *PIK3CA* 18% in non-hypermutated patients [30]. Our analysis confirmed a lower rate of these mutations in CRC-SRCC (*APC*: 25% and *KRAS*: 22%).

To date, therapy recommended for patients with CRC-SRCC is identical to that recommended for adenocarcinomas. As SRCCs are frequently diagnosed in an advanced tumor stage, typically only palliative chemotherapy is recommended [31]. It was reported that CRC-SRCC, in all stages, is usually insensitive to irinotecan, oxaliplatin, and 5-fluorouracil [32]. Despite that, in a SEER population analysis (1675 patients) an improvement in survival was reported in 936 stage II-III patients treated with undefined (single agent or doublet) postoperative adjuvant chemotherapy [33]. The actual clinical benefit gain from adjuvant chemotherapy in early-stage CRC-SRCC remains unclear, as randomized studies in this rare subgroup are lacking. For advanced disease, systemic treatment remains the primary treatment option, however, SRCC seems to be less sensitive to commonly used chemotherapy drugs, possibly due to the lower proliferation activity of these cells [31, 32]. A comprehensive characterization of molecular features of CRC-SRCC may help to find new histology-specific tailored therapies.

A personalized approach has not been proposed for gastric cancer with signet ring cell histology. Mengardo et al. suggested that multimodal therapy may be the best option for these patients [34]. Supporting this, a SEER population analysis highlighted the effect of preoperative radiotherapy (RT) in improving survival for patients with GC-SRCC [35]. The chemosensitivity of GC-SRCC remains undefined, as conflicting data has been reported on the use of 5-fluorouracil, platinum derivates, and taxane-based chemotherapy in a perioperative setting [13]. Therefore, some authors suggested performing front-line surgery without neoadjuvant treatment when possible [36]. In the metastatic setting, the use of docetaxel, 5-fluorouracil, and oxaliplatin may give an acceptable response rate, at least similar in magnitude to that benefit in patients with non-SRCC histology [13].

NGS-based therapeutic approaches have yet to be fully explored, for both gastric and colon SRCC. Our analysis showed that 20% of CRC-SRCC were MSI-High, allowing for the consideration of pembrolizumab as first-line therapy, a new standard treatment in metastatic MSI-high CRC [37]. A similar approach may be useful in GC-SRCC (MSI-High was found in 3.5% of GC-SRCC). Results from the phase II Keynote-158 study demonstrated a clinical benefit of pembrolizumab, after first-line treatment, among MSI-high non-CRC solid tumors [38]. However, no robust data are available on the efficacy of Pembrolizumab in SRCC subpopulation of patients as well as on SRCC histology as positive or negative predictive biomarkers for immunotherapy in gastric and/or CRC cancer patients [39]. Thus, further research into biomarkers of SRCC immune microenvironment may highlight targets for immunotherapy [40].

Additionally, targeting mutated DNA damage repair genes in gastrointestinal tumors is still at an early stage of development, but could be a valid option in those SRCC who harbor a *BRCA1* mutation [41]. Our study showed that 7% of CRC-SRCC harbored a *BRCA1* mutation, making this a viable therapeutic target. Clinical trials are ongoing to investigate the potential role of Poly (ADP-ribose) polymerase (PARP) inhibitors (PARPi) in both gastric [42] and CRC patients [43].

Furthermore, our analysis revealed that further targetable gene alterations were detectable in SRCCs: *RNF43*, *PIK3CA*, *ERBB2* as well as *BRAF*. Further study to identify activation pathways and potential therapeutic targets are needed [16].

We acknowledge that there are some limitations to our study including the retrospective nature of the analysis, the lack of clinical treatment and outcomes data to correlate with mutational analysis, as well as the heterogeneity of the study population unselected for tumor stage and site of tumors (primary vs metastatic sites). In addition, some further limitations exist in this study as well. The small number of included samples due to the rarity of SRCC may have given our study insufficient statistical power to identify all significant associations and differences such as molecular differences between MSI-high and microsatellite stable (MSS) tumors within SRCC cohort. Finally, in our dataset not enough data about tumor location (right vs left CRC) were available to establish a correlation between SRCC and primary site location.

CONCLUSION

Our research is one of the largest to molecularly characterize features of SRCC from gastric and colorectal tumors. Our data suggest that SRCCs harbor similar molecular profiles, regardless of the primary site of tumor origin. On the other hand, significant differences were observed between SRCCs and non-SRCC both within GC and CRC. Further studies are warranted to elucidate molecular mechanisms accounting for the aggressive behavior of SRCCs, as well as to identify activation pathways and potential therapeutic targets.

METHODS

Tumors submitted to Caris Life Sciences (Phoenix, AZ) for routine molecular profiling between January 2013 and January 2018 were reviewed from a de-identified database. Cases were reviewed from the Caris database based on available pathological notation using the search terms “signet ring cell”. Identified cases were reviewed and designated as primary signet ring cell, mixed signet ring cell, or rare signet ring cell based on the histological description provided with each specimen. Cases with histologic descriptions other than signet ring carcinoma were denoted separately.

Immunohistochemistry (IHC)

IHC was performed on FFPE sections. Protein staining was scored for intensity (0 = no staining; 1 += weak staining; 2 += moderate staining; 3 += strong staining) and staining percentage (0–100%) by pathologists. PD-L1 testing was performed using the SP142 anti-PD-L1 clone (Ventana, Tucson, AZ) and staining was measured on tumor cells alone. (2+ and/or 5% were considered positive for staining).

Next-generation sequencing (NGS)

NGS was performed in a CAP/CLIA/ISO-certified commercial laboratory on genomic DNA isolated from FFPE tumor samples using the NextSeq platform (Illumina, Inc., San Diego, CA.). A custom-designed SureSelect XT assay was used to enrich 592 whole-gene targets or 44-gene oncogenic hot-spot targets (Agilent Technologies). All variants were

detected with >99% confidence based on allele frequency and amplicon coverage, with an average sequencing depth of coverage of 750 and an analytic sensitivity of 5%. Prior to molecular testing, tumor enrichment was achieved by harvesting targeted tissue using manual microdissection techniques. Genetic variants identified were interpreted by board-certified molecular geneticists and categorized as “pathogenic,” “presumed pathogenic,” “variant of unknown significance,” “presumed benign,” or “benign,” according to the American College of Medical Genetics and Genomics (ACMG) standards. When assessing mutation frequencies of individual genes, “pathogenic,” and “presumed pathogenic” were counted as mutations, whereas “benign”, “presumed benign” variants, and “variants of unknown significance” were excluded.

Microsatellite instability (MSI)

MSI was examined by counting the number of microsatellite loci that were altered by somatic insertion or deletion for each sample. The threshold to determine MSI by NGS was determined to be 46 or more loci with insertions or deletions to generate a sensitivity of >95% and specificity of >99%.

Tumor mutational burden (TMB)

TMB was measured by counting all nonsynonymous missense mutations found per tumor that had not been described previously as germline alterations [592 genes and 1.4 megabases (MB) sequenced/tumor]. Potential germline mutations are excluded by comparing data against dbSNP 137 full and 1000 Genomes Phase 3. The threshold to define TMB-high (TMB-H) was greater than or equal to 17 mutations/MB and was established by comparing TMB with MSI by fragment analysis in colorectal cancer cases, based on reports of TMB having high concordance with MSI-H in colorectal cancer. Differences in mean TMB was assessed using Student’s *t* test.

Statistical analysis

Chi-square test was performed for comparative analysis using SPSS v23 (IBM SPSS Statistics), and a statistical significance was defined as p value < 0.05.

DATA AVAILABILITY

The datasets generated during and/or analysed during the current study are available from the corresponding author on reasonable request.

ACKNOWLEDGEMENTS

This work was partly supported by National Cancer Institute (grant number P30CA014089), Gloria Borges WunderGlo Foundation, Dhont Family Foundation, Gene Gregg Pancreas Research Fund, San Pedro Peninsula Cancer Guild, Daniel Butler Research Fund, Victoria and Philip Wilson Research Fund, Fong research project and Ming Hsieh research fund. The content is solely the responsibility of the authors and does not necessarily represent the official views of the National Cancer Institute of the National Institutes of Health.

REFERENCES

1. Lauwers G, Carneiro F, Graham D, Curado M, Franceschi S. Classification of tumours of the digestive system. 4th ed. Lyon: IARC Press; 2010. pp. 48–58.

2. Hugen N, Verhoeven RH, Lemmens VE, van Aart CJ, Elferink MA, Radema SA, et al. Colorectal signet-ring cell carcinoma: benefit from adjuvant chemotherapy but a poor prognostic factor. Int J Cancer. 2015;136:333–9. [PubMed: 24841868]
3. Chen L, Liu X, Gao L, Wang R, Gao D, Bai D. The clinicopathological features and prognosis of signet ring cell carcinoma of the esophagus: a 10-year retrospective study in China. PLoS One. 2017;12:e0176637. [PubMed: 28486494]
4. Wu X, Zhang Z, Li X, Lin Q, Chen G, Lu J, et al. Poorer prognosis of primary signetring cell carcinoma of the breast compared with mucinous carcinoma. PLoS One. 2016;11:e0162088. [PubMed: 27583684]
5. Warner JN, Nakamura LY, Pacelli A, Humphreys MR, Castle EP. Primary signet ring cell carcinoma of the prostate. Mayo Clin Proc. 2010;85:1130–6. [PubMed: 21123640]
6. Benesch MGK, Mathieson A. Epidemiology of signet ring cell adenocarcinomas. Cancers. 2020;12:1544.
7. Bosman FT, Carneiro F, Hruban RH, Theise ND WHO Classification of Tumours of the Digestive System. World Health Organization; Geneva, Switzerland: 2010.
8. WHO Digestive System Tumours, WHO Classification of Tumours Series. 5th ed. International Agency for Research on Cancer; Lyon, France: 2019.
9. Bamboat ZM, Tang LH, Vinuela E, Kuk D, Gonen M, Shah MA, et al. Stage-stratified prognosis of signet ring cell histology in patients undergoing curative resection for gastric adenocarcinoma. Ann Surg Oncol. 2014;21:1678–85. [PubMed: 24394986]
10. Taghavi S, Jayarajan SN, Davey A, Willis AI. Prognostic significance of signet ring gastric cancer. J Clin Oncol. 2012;30:3493–8. [PubMed: 22927530]
11. Henson DE, Dittus C, Younes M, Nguyen H, Albores-Saavedra J. Differential trends in the intestinal and diffuse types of gastric carcinoma in the United States, 1973–2000: increase in the signet ring cell type. Arch Pathol Lab Med. 2004;128:765–70. [PubMed: 15214826]
12. Kwon KJ, Shim KN, Song EM, Choi JY, Kim SE, Jung HK, et al. Clinicopathological characteristics and prognosis of signet ring cell carcinoma of the stomach. Gastric Cancer. 2014;17:43–53. [PubMed: 23389081]
13. Pernot S, Voron T, Perkins G, Lagorce-Pages C, Berger A, Taieb J. Signet-ring cell carcinoma of the stomach: Impact on prognosis and specific therapeutic challenge. World J Gastroenterol. 2015;21:11428–38. [PubMed: 26523107]
14. Chon HJ, Hyung WJ, Kim C, Park S, Kim JH, Park CH, et al. Differential prognostic implications of gastric signet ring cell carcinoma: stage adjusted analysis from a single high-volume center in Asia. Ann Surg. 2017;265:946–53. [PubMed: 27232252]
15. Kong P, Wu R, Yang C, Geng Q, Liu J, Chen S, et al. Prognostic impact of the signet ring cell type in node-negative gastric cancer. Sci Rep. 2016;6:26313. [PubMed: 27381549]
16. Korphaisarn K, Morris V, Davis JS, Overman MJ, Fogelman DR, Kee BK, et al. Signet ring cell colorectal cancer: genomic insights into a rare subpopulation of colorectal adenocarcinoma. Br J Cancer. 2019;121:505–10. [PubMed: 31406299]
17. Hyngstrom JR, Hu CY, Xing Y, You YN, Feig BW, Skibber JM, et al. Clinicopathology and outcomes for mucinous and signet ring colorectal adenocarcinoma: analysis from the national cancer data base. Ann Surg Oncol. 2012;19:2814–21. [PubMed: 22476818]
18. Tung SY, Wu CS, Chen PC. Primary signet ring cell carcinoma of colorectum: an age- and sex-matched controlled study. Am J Gastroenterol. 1996;91:2195–9. [PubMed: 8855747]
19. Nitsche U, Friess H, Agha A, Angele M, Eckel R, Heitland W, et al. Prognosis of mucinous and signet-ring cell colorectal cancer in a population-based cohort. J Cancer Res Clin Oncol. 2016;142:2357–66. [PubMed: 27573386]
20. Puccini A, Lenz HJ, Marshall JL, Arguello D, Raghavan D, Korn WM, et al. Impact of patient age on molecular alterations of left-sided colorectal tumors. Oncologist. 2019;24:319–26. [PubMed: 30018131]
21. Tajiri K, Sudou T, Fujita F, Hisaka T, Kinugasa T, Akagi Y. Clinicopathological and corresponding genetic features of colorectal signet ring cell carcinoma. Anticancer Res. 2017;37:3817–23. [PubMed: 28668881]

22. Inamura K, Yamauchi M, Nishihara R, Kim SA, Mima K, Sukawa Y, et al. Prognostic significance and molecular features of signet-ring cell and mucinous components in colorectal carcinoma. Ann Surg Oncol. 2015;22:1226–35. [PubMed: 25326395]
23. Nitsche U, Zimmermann A, Spath C, Muller T, Maak M, Schuster T, et al. Mucinous and signet-ring cell colorectal cancers differ from classical adenocarcinomas in tumor biology and prognosis. Ann Surg. 2013;258:775–82. discussion 782–773 [PubMed: 23989057]
24. Nagtegaal ID, Odze RD, Klimstra D, Paradis V, Rugge M, Schirmacher P, et al. The 2019 WHO classification of tumours of the digestive system. Histopathology. 2020;76:182–8. [PubMed: 31433515]
25. Piessen G, Messager M, Leteurtre E, Jean-Pierre T, Mariette C. Signet ring cell histology is an independent predictor of poor prognosis in gastric adenocarcinoma regardless of tumoral clinical presentation. Ann Surg. 2009;250:878–87. [PubMed: 19855261]
26. Mariette C, Carneiro F, Grabsch HI, van der Post RS, Allum W, de Manzoni G, et al. Consensus on the pathological definition and classification of poorly cohesive gastric carcinoma. Gastric Cancer. 2019;22:1–9. [PubMed: 30167905]
27. Alvi MA, Loughrey MB, Dunne P, McQuaid S, Turkington R, Fuchs MA, et al. Molecular profiling of signet ring cell colorectal cancer provides a strong rationale for genomic targeted and immune checkpoint inhibitor therapies. Br J Cancer. 2017;117:203–9. [PubMed: 28595259]
28. Barresi V, Pedrazzani C. Colorectal signet ring cell carcinoma: advancing research in a rare cancer. Future Oncol. 2020;16:1161–3. [PubMed: 32351144]
29. Yaeger R, Chatila WK, Lipsyc MD, Hechtman JF, Cercek A, Sanchez-Vega F, et al. Clinical sequencing defines the genomic landscape of metastatic colorectal cancer. Cancer Cell. 2018;33:125–36 e123. [PubMed: 29316426]
30. Atlas N Comprehensive molecular characterization of human colon and rectal cancer. Nature. 2012;487:330–7. Cancer Genome [PubMed: 22810696]
31. Lee WS, Chun HK, Lee WY, Yun SH, Cho YB, Yun HR, et al. Treatment outcomes in patients with signet ring cell carcinoma of the colorectum. Am J Surg. 2007;194:294–8. [PubMed: 17693269]
32. Pande R, Sunga A, Levea C, Wilding GE, Bshara W, Reid M, et al. Significance of signet-ring cells in patients with colorectal cancer. Dis Colon Rectum. 2008;51:50–55. [PubMed: 18030531]
33. Zhao Z, Yan N, Pan S, Wang DW, Li ZW. The value of adjuvant chemotherapy in stage II/III colorectal signet ring cell carcinoma. Sci Rep. 2020;10:14126. [PubMed: 32839528]
34. Mengardo V, Treppiedi E, Bencivenga M, Dal Cero M, Giacopuzzi S. Tailored treatment for signet ring cell gastric cancer. Updates Surg. 2018;70:167–71. [PubMed: 29948660]
35. Gong H, Chu Y, Hu Q, Song Q. Preoperative radiotherapy is associated with significant survival benefits for patients with gastric signet ring cell carcinoma: a SEER-based approach. Technol Cancer Res Treat. 2020;19:1533033820960746.
36. Kim S, Fiteni F, Paget-Bailly S, Ghiringhelli F, Lakkis Z, Jary M, et al. The impact of taxane-based preoperative chemotherapy in gastroesophageal signet ring cell adenocarcinomas. J Hematol Oncol. 2015;8:52. [PubMed: 25976888]
37. Andre T, Shiu KK, Kim TW, Jensen BV, Jensen LH, Punt C, et al. Pembrolizumab in microsatellite-instability-high advanced colorectal cancer. N Engl J Med. 2020;383:2207–18. [PubMed: 33264544]
38. Marabelle A, Le DT, Ascierto PA, Di Giacomo AM, De Jesus-Acosta A, Delord JP, et al. Efficacy of pembrolizumab in patients with noncolorectal high microsatellite instability/mismatch repair-deficient cancer: results from the phase II KEYNOTE-158 study. J Clin Oncol. 2020;38:1–10. [PubMed: 31682550]
39. Noh MG, Yoon Y, Kim G, Kim H, Lee E, Kim Y, et al. Practical prediction model of the clinical response to programmed death-ligand 1 inhibitors in advanced gastric cancer. Exp Mol Med. 2021;53:223–34. [PubMed: 33547412]
40. Jin S, Xu B, Yu L, Fu Y, Wu H, Fan X, et al. The PD-1, PD-L1 expression and CD3+ T cell infiltration in relation to outcome in advanced gastric signet-ring cell carcinoma, representing a potential biomarker for immunotherapy. Oncotarget. 2017;8:38850–62. [PubMed: 28418918]

41. Mauri G, Arena S, Siena S, Bardelli A, Sartore-Bianchi A. The DNA damage response pathway as a land of therapeutic opportunities for colorectal cancer. Ann Oncol. 2020;31:1135–47. [PubMed: 32512040]

42. Zimmer K, Kocher F, Puccini A, Seeber A. Targeting BRCA and DNA damage repair genes in GI cancers: pathophysiology and clinical perspectives. Front Oncol. 2021;11:662055. [PubMed: 34707985]

43. Catalano F, Borea R, Puglisi S, Boutros A, Gandini A, Cremante M, et al. Targeting the DNA damage response pathway as a novel therapeutic strategy in colorectal cancer. Cancers. 2022;14:1388. [PubMed: 35326540]

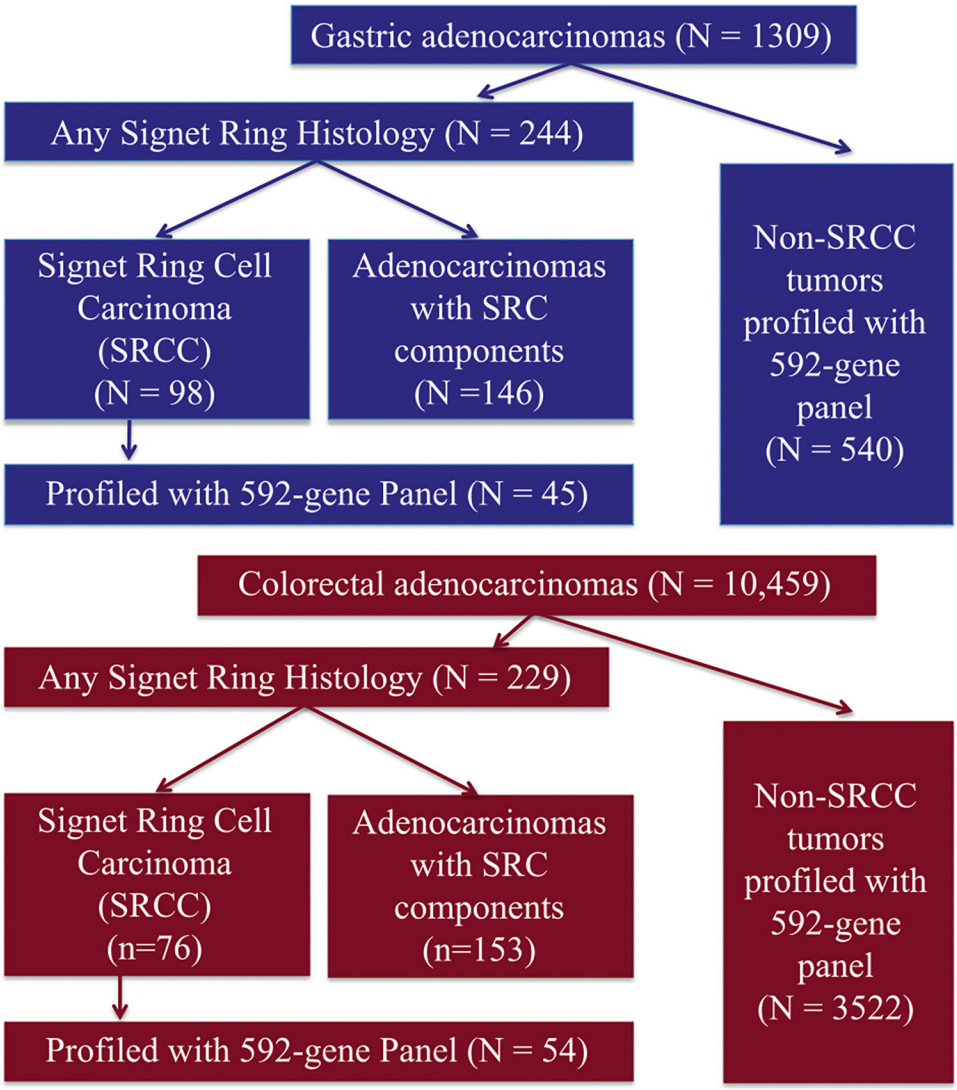

Fig. 1. Patient demographics.
Consort diagram.

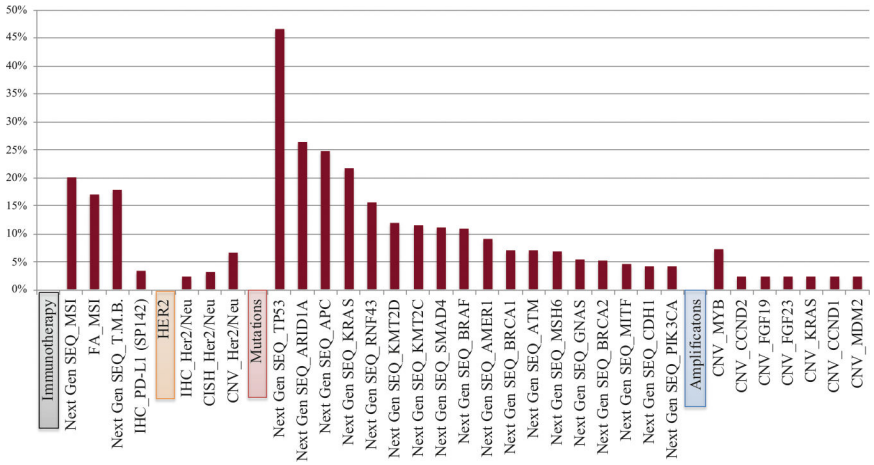

Fig. 2.
Summary genomic findings of CRC-SRCC.

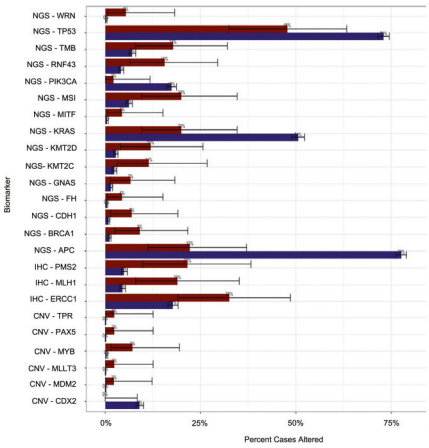

Biomarker	CRC-SRCC % Altered	CRC % Altered	p-value	q-value
Next Gen SEQ_APC	22.20%	77.60%	0.00000	0.00000
Next Gen SEQ_KRAS	20%	50.60%	0.00009	0.04852
Next Gen SEQ_TP53	47.70%	73%	0.00036	0.12713
IHC_PMS2	78.40%	95%	0.00045	0.12713
CNV_MYB	7.10%	0.40%	0.00085	0.19020
IHC_MLH1	81.10%	95.50%	0.00134	0.25105
Next Gen SEQ_BRCA1	9.10%	1.10%	0.00183	0.25900
Next Gen SEQ_MSI	20%	6.30%	0.00185	0.25900
Next Gen SEQ_RNF43	15.60%	4.20%	0.00270	0.33641
Next Gen SEQ_WRN	5.40%	0.20%	0.00462	0.51695
Next Gen SEQ_KMT2D	11.90%	2.80%	0.00637	0.60016
Next Gen SEQ_CDH1	7%	0.80%	0.00643	0.60016
Next Gen SEQ_KMT2C	11.40%	2.40%	0.01016	0.87489
Next Gen SEQ_PIK3CA	2.20%	17.40%	0.01312	1.00000
Next Gen SEQ_TMB	17.80%	7.10%	0.01373	1.00000
FA_MSI	16.70%	6.60%	0.07192	1.00000
Next Gen SEQ_FBXW7	2.40%	10.70%	0.12019	1.00000
Next Gen SEQ_PMS2	3.80%	0.50%	0.13611	1.00000
Next Gen SEQ_PRKDC	2.20%	0.30%	0.14152	1.00000
Next Gen SEQ_BAP1	2.20%	0.30%	0.14159	1.00000
Next Gen SEQ_NRAS	0%	4.30%	0.26157	1.00000
Next Gen SEQ_BRAF	13.30%	8.60%	0.27721	1.00000

Fig. 3. Signet ring cell histology vs non-SRCC from colorectal primary sites.

When compared to non-SRCC histology (N= 3522), CRC-SRCC showed more frequently mutation in *BRCA1* (9.1% vs 1%, P= 0.002) and less mutation in *APC* (22% vs 78%, P < 0.001), *KRAS* (20% vs 51%, P= 0.001) and TP53 (48% vs 73%, P= 0.001).

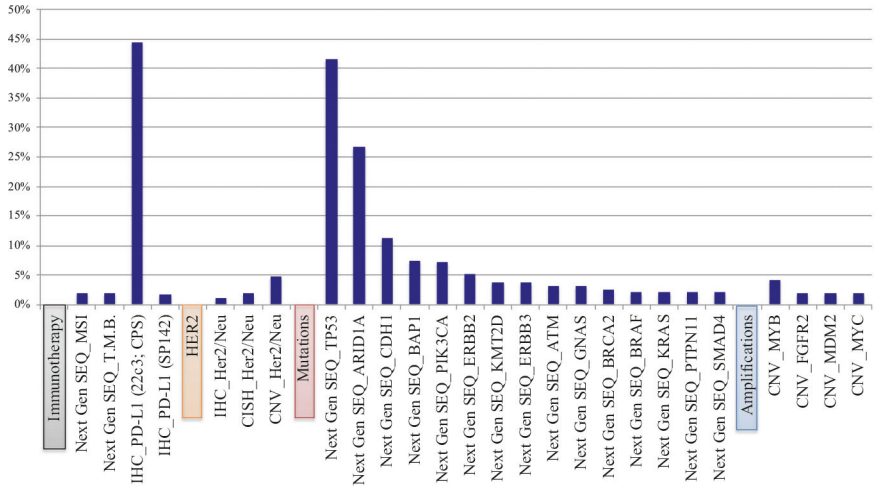

Fig. 4.
Summary genomic findings of Gastric-SRCC.

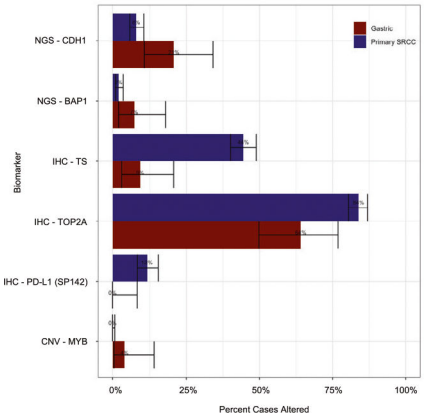

Biomarker	GC-SRCC % Altered	GC % Altered	p-value	q-value
IHC_TS	9.40%	44.50%	0.00000	0.00186
IHC_TOP2A	64.20%	83.90%	0.00074	0.41139
Next Gen SEQ_CDH1	20.80%	8%	0.00530	1.00000
CNV_MYB	4.10%	0%	0.00805	1.00000
Next Gen SEQ_BAP1	7.40%	2%	0.03977	1.00000
Next Gen SEQ_TP53	42.60%	56.40%	0.07155	1.00000
Next Gen SEQ_ERBB2	9.30%	3.90%	0.07850	1.00000
Next Gen SEQ_AKT1	1.90%	0%	0.08998	1.00000
CNV_KRAS	0%	5.90%	0.09708	1.00000
Next Gen SEQ_APC	0%	5.60%	0.09890	1.00000
Next Gen SEQ_KRAS	1.90%	8.80%	0.11123	1.00000
Next Gen SEQ_RNF43	1.90%	6.30%	0.35642	1.00000
IHC_HER2/Neu	1.90%	5.30%	0.50117	1.00000
CISH_HER2/Neu	7.10%	9.70%	1.00000	1.00000
CNV_HER2/Neu	2%	6.30%	0.34769	1.00000
Next Gen SEQ_TMB	1.90%	9.10%	0.07249	1.00000
Next Gen SEQ_MSI	1.90%	9.30%	0.07224	1.00000
IHC_PD-L1 (22c3)	44.40%	69.70%	0.14330	1.00000
IHC_PD-L1 (SP142)	0%	11.60%	0.01376	1.00000

Fig. 5. Signet ring cell histology vs non-SRCC from gastric primary sites.

Among GC cohort, SRCC had a higher frequency of mutations in *CDH1* (20% vs 8%, $P = 0.005$), *BAP1* (7.4% vs 2%, $P = 0.039$), and *ERBB2* (9.3% vs 3.9%, $P = 0.072$), and higher rate of amplification *MYB* (4.1% vs 0%, $P = 0.005$) compared to nonSRCC ($N = 540$), although none reached statistical significance after multiple test correction.

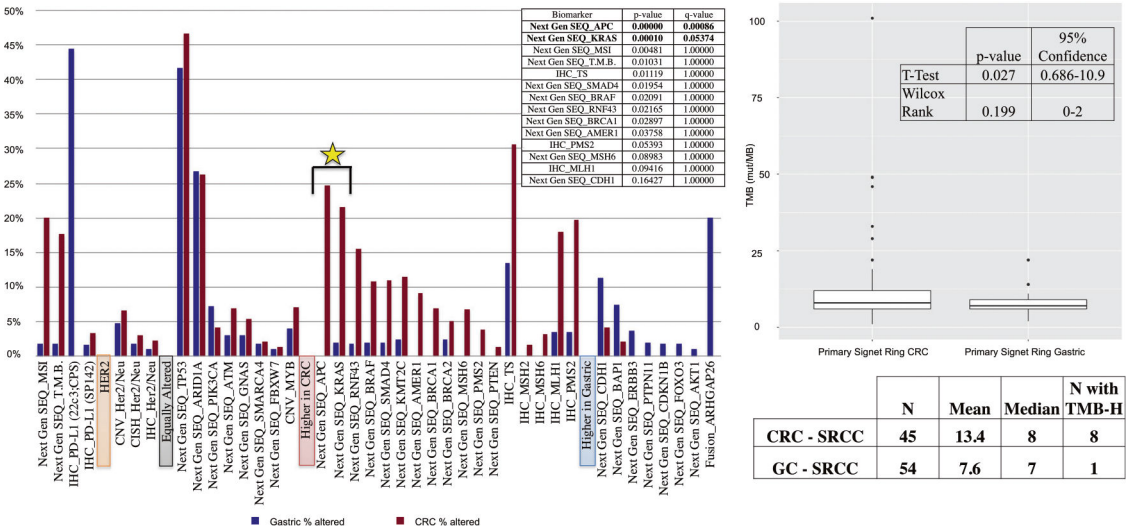

Fig. 6. Comparison of signet ring cell carcinomas between gastric and colorectal primaries.

When we compared GC-SRCC vs. CRC-SRCC, only the mutation rate in APC (0% vs 25%) and KRAS (2% vs 22%) genes were significantly different ($P < 0.0001$). Increased rates of MSI (20% vs 3.5%, $P = 0.008$) and high TMB (17.8% vs 1.8%, $P = 0.013$) were seen in CRC-SRCC compared to GC-SRCC.