



# Safety and efficacy of stand-alone anterior lumbar interbody fusion in low-grade L5-S1 isthmic spondylolisthesis



C. Marvin Jesse<sup>a,\*</sup>, Othmar Schwarzenbach<sup>b</sup>, Christian T. Ulrich<sup>a</sup>, Levin Häni<sup>a</sup>, Andreas Raabe<sup>a</sup>,  
Ralph T. Schär<sup>a</sup>

<sup>a</sup> Department of Neurosurgery, Inselspital, Bern University Hospital, University of Bern, Bern, Switzerland

<sup>b</sup> dasRueckenzentrum AG, Thun, Switzerland

## ARTICLE INFO

### Keywords:

ALIF  
Stand-alone ALIF  
Isthmic spondylolisthesis  
Anterior lumbar interbody fusion  
Lumbar fusion

## ABSTRACT

**Introduction:** Surgical management of isthmic spondylolisthesis is controversial and reports on anterior approaches in the literature are scarce.

**Research question:** To evaluate the safety and efficacy of stand-alone anterior lumbar interbody fusion (ALIF) in patients with symptomatic low-grade L5-S1 isthmic spondylolisthesis.

**Material and methods:** All adult patients with isthmic spondylolisthesis of the lumbosacral junction treated in a single institution between 2008 and 2019 with stand-alone ALIF were screened. A titan cage was inserted at L5-S1 with vertebral anchoring screws. Prospectively collected surgical, clinical and radiographic data were analyzed retrospectively.

**Results:** 34 patients (19 men, 15 women, mean age  $52.5 \pm 11.5$  years) with a mean follow-up of  $3.2 (\pm 2.5)$  years were analyzed. 91.2% ( $n = 31$ ) of patients had a low-grade spondylolisthesis and 8.8% ( $n = 3$ ) grade III according to Meyerding classification. Mean COMI and ODI scores improved significantly from  $6.9 (\pm 1.5)$  and  $35.5 (\pm 13.0)$  to  $2.0 (\pm 2.5)$  and  $10.2 (\pm 13.0)$ , respectively after one year, and to  $1.7 (\pm 2.5)$  and  $8.2 (\pm 9.6)$ , respectively, after two years. The COMI and ODI scores improved in 86.4% and 80%, respectively, after one year and 92.9% of patients after two years by at least the minimal clinically important difference. No intraoperative complications were recorded. 8.8% ( $n = 3$ ) of patients needed a reoperation.

**Discussion and conclusion:** After stand-alone ALIF for symptomatic isthmic spondylolisthesis, the patients improved clinically important after one and two years. Stand-alone ALIF is a safe and effective surgical treatment option for low-grade isthmic spondylolisthesis.

## 1. Introduction

For patients with L5-S1 isthmic spondylolisthesis suffering from severe lumbar radicular pain refractory to multimodal conservative treatments, fusion surgery is superior to conservative care (Moller and Hedlund, 2000; Endler et al., 2017). Different approaches including anterior, posterior as well as circumferential fusion techniques have been described in the literature (Moller and Hedlund, 2000; Endler et al., 2017; Lemcke et al., 2007; Fleege et al., 2016; Viglione et al., 2017; Kim et al., 2010a, 2010b). However, the optimal surgical management for isthmic spondylolisthesis is controversial, and reports on solely anterior approaches for low-grade isthmic spondylolisthesis in the literature are scarce (Sebastian et al., 2020; Jaeger et al., 2019).

Anterior lumbar interbody fusion (ALIF) has been advocated as an

effective treatment option for lumbar spondylolisthesis (Rao et al., 2015a). Compared to other spinal fusion techniques such as transforaminal lumbar interbody fusion (TLIF), or posterior lumbar interbody fusion (PLIF), the ALIF has shown to be superior with regard to restoration of disc height and segmental lordosis (Kapustka et al., 2020). Furthermore, an indirect foraminal decompression is achieved and the integrity of the posterior tension band complex is preserved by avoiding dissection of ligaments and paraspinal muscles (Rao et al., 2015b). The disadvantages of the ALIF technique include approach related complications such as vascular or visceral injuries and retrograde ejaculation (Mobbs et al., 2015, 2016).

A recent systematic review included nine publications reporting the safety and efficacy of stand-alone ALIF in isthmic spondylolisthesis of the lumbosacral junction (Viglione et al., 2017). The authors concluded that there was insufficient evidence to support the use of stand-alone ALIF in

\*Corresponding author. University of Bern, Department of Neurosurgery, Freiburgstrasse 10, 3010 Bern, Switzerland.

E-mail address: [christophermarvin.jesse@insel.ch](mailto:christophermarvin.jesse@insel.ch) (C.M. Jesse).

<https://doi.org/10.1016/j.bas.2022.100861>

Received 25 October 2021; Received in revised form 26 November 2021; Accepted 10 January 2022

Available online 12 January 2022

2772-5294/© 2022 The Author(s). Published by Elsevier B.V. on behalf of EUROSPINE, the Spine Society of Europe, EANS, the European Association of Neurosurgical

Societies. This is an open access article under the CC BY-NC-ND license (<http://creativecommons.org/licenses/by-nc-nd/4.0/>).

Abbreviations	
ASA	American Society of Anesthesiologists
ALIF	Anterior lumbar interbody fusion
COMI	Core Outcome Measures Index
CT	Computed tomography
FU	Follow-up
LL	Lumbar lordosis
MCIC	Minimal clinically important change
MRI	Magnetic resonance imaging
ODI	Oswestry disability index
PI	Pelvic incidence
PLIF	Posterior lumbar interbody fusion
PROM	Patient-reported outcome measure
TLIF	Transforaminal lumbar interbody fusion
VAS	Visual analog scale

treating this specific pathology. Evidently, more reports are needed to support the use of this technique for isthmic spondylolisthesis.

In the present study, we present a series of patients with symptomatic L5-S1 isthmic spondylolisthesis treated by stand-alone ALIF. To the best of our knowledge, this is the largest case series of stand-alone ALIF for isthmic spondylolisthesis in the literature to date.

## 2. Material and methods

### 2.1. Study design and patient selection

We performed a retrospective single-center analysis of prospectively collected data. Consecutive patients with symptomatic L5-S1 isthmic spondylolisthesis treated with a stand-alone ALIF from 2008 to 2019 were screened for study eligibility (Fig. 1). Patients with no postoperative data and patients with prior surgery at the lumbosacral junction were excluded. The study was approved by the local ethics committee (Kantonale Ethikkommission Bern, Switzerland, 2020–02659). All methods were carried out in accordance with relevant guidelines and regulations. Informed consent was obtained from all subjects.

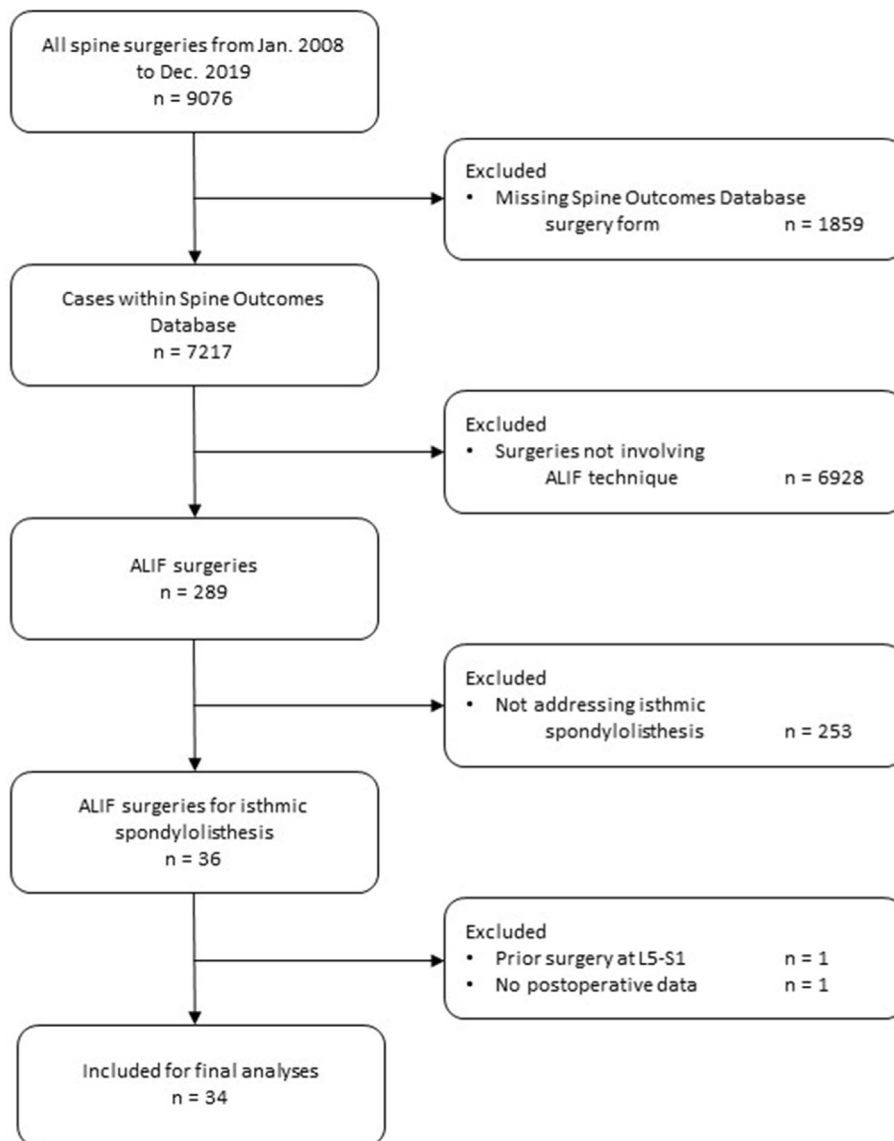


Fig. 1. Flow diagram of patients included.

## 2.2. Imaging studies

Standing lateral and anteroposterior radiographs of the lumbar spine were routinely obtained preoperatively, postoperatively and for each follow-up (FU) visit. Flexion- and extension radiographs were performed before and one year after surgery and beyond. Additionally, magnetic resonance imaging (MRI) was obtained preoperatively. CT-imaging was ordered if felt necessary to confirm the diagnosis of isthmic spondylolisthesis.

Meyerding grades 1 and 2 were classified as low-grade and grades 3 and 4 as high-grade spondylolisthesis. Spondylolisthesis grade and spinopelvic parameters were determined using upright radiographs of the lumbar spine. Fusion was defined as evidence of bridging bone formations between the L5-S1 interspace as seen on a postoperative CT scan (Burkus et al., 2001). If no postoperative CT scan was available, criteria for fusion on dynamic radiographs where: i) angular motion of less than 3° and ii) reduction in sagittal- or frontal plane translation of less than 5 mm (Burkus et al., 2001). All radiographic assessments were made by an independent observer, not involved in the surgery.

## 2.3. Radiologic follow-up

Patients were followed-up 6 weeks, 3 months, 6 months, 1 year, 2 years and 5 years postoperatively. At every FU, standing lateral and anteroposterior radiographs were obtained. One year after surgery and beyond, flexion and extension radiographs were additionally performed. CT or MR imaging was ordered based on the surgeon's judgment, e.g. for suspicion of pseudoarthrosis on radiographs.

## 2.4. Surgical technique

Surgery was performed under general anesthesia with the patient in supine position. An experienced spine surgeon (OS) carried out all surgeries without the support of an access surgeon. The skin incision was made subumbilically in the midline after fluoroscopic confirmation of the surgical trajectory. The fascia was sharply dissected followed by a blunt muscle-splitting and retroperitoneal approach to the promontory of sacrum. The middle sacral vessels were ligated and transected. After careful blunt dissection and mobilization of the iliac vessels and exposure of the L5-S1 disc, a self-retaining retraction system was inserted (Synframe, DePuySynthes, Raynham, Massachusetts, United States). The correct disc level was verified by lateral fluoroscopy followed by a thorough discectomy and careful preparation of the endplates. The stand-alone cage (Cobra Cage, Biedermann Motech, Villingen-Schwenningen, Germany; or Synfix Evloution System, DePuySynthes, Raynham, MA, U.S. in two cases) was filled with cancellous bone harvested from the iliac crest with an additional small incision and implanted under fluoroscopic guidance. For fixation of the cage one screw was inserted in L5 and two diverging screws in S1. After meticulous hemostasis the wound was closed in a standard layered fashion.

## 2.5. Data acquisition and patient reported outcome measures

All clinical, surgical and radiological data was prospectively collected using an in-house database linked to the EUROSPINE Spine Tango registry system (Roder et al., 2005). All patients were asked to complete a questionnaire before surgery and at every FU. The questionnaire included the Oswestry disability index (ODI) and Core Outcome Measures Index (COMI). The ODI incorporates 10 questions concerning the intensity of pain and the limitations in different daily activities (each on a 0 to 5-point scale). All qualities are summed up to a score, which is multiplied by 2 to receive the final score (0–100; 0 = no disability at all, and 100 = maximum disability) (Fairbank and Pynsent, 2000). The COMI comprises several questions covering the domains of pain [back and leg/buttock pain intensity, each measured separately on a 0–10 visual analog scale (VAS)], and function, symptom specific well-being,

general quality of life, social disability, and work disability (each on a 5-point scale) (Mannion et al., 2009).

The surgeon completed the spine tango surgical and FU forms after surgery and at each FU visit. These forms included surgical aspects, spine pathology, reoperations and intra- and postoperative operations. We extracted the relevant data from the database and verified or completed it with data from our electronic hospital information system.

## 2.6. Statistical analyses

Descriptive data included the calculation of the mean and standard deviation (SD). Normal distribution was determined using the Kolmogorov-Smirnov-Test. The significance of differences for the COMI, ODI, back and leg pain were calculated using the T-Test in normally distributed data, otherwise Wilcoxon signed-rank test was performed. The minimal clinically important change (MCIC) has been defined as 2.2 points in the COMI (Mannion et al., 2009) and 12.9 points improvement in the ODI (Copay et al., 2008). Statistical significance was defined as a p-value less than 0.05. Statistical analysis was performed using the statistical software SPSS (IBM, version 21). We addressed missing values first by reanalyzing the source data, and if no value was retrievable by pairwise deletion.

## 3. Results

### 3.1. Patient population

In total, 34 patients (15 women, 19 men, mean age 52.5 ± 11.5 years) were included for final analysis (Fig. 1). Mean follow-up (FU) was 3.2 (±2.5) years (3 months–10 years), the mean ASA risk classification was 2.0 (±0.6) (Table 1).

### 3.2. Radiologic findings

The mean pelvic incidence (PI) was 65 (±9)°. 47.1% (n = 16) of patients had a spondylolisthesis grade I, 44.1% (n = 15) grade II and 8.8% (n = 3) grade III. Mean lumbar lordosis (LL) was 59 (±9)° before and 65 (±9)° after surgery. The difference between pelvic incidence and lumbar lordosis (PI - LL) was 6 (±9)° preoperatively, and <1 (±6)° postoperatively. The mean preoperative slip measured 33 ± 11%, the postoperative slip 28 ± 13% with a mean absolute slip reduction of 5 ± 6%. The overall fusion rate was 84.0% after one year (10 out of 11 patients with postoperative CT-scan and 11 out of 14 patients with only postoperative dynamic radiographs). Of a total of 11 patients with postoperative CTs, 10 patients showed evidence of solid bony fusion at the L5-S1 level (Table 2) (Fig. 2)

### 3.3. Patient reported outcome

Mean COMI and ODI scores improved from 6.9 ± 1.5 and 35.5 ± 13.0 to 2.0 ± 2.5 and 10.2 ± 13.0, respectively after one year (22/34), and to 1.7 ± 2.5 and 8.2 ± 9.6, respectively after two years (14/34). The COMI score improved in 86.4% of patients after one year, and in 92.9% of patients after two years by at least the MCIC score of 2.2 points (Mannion et al., 2009). The ODI improved in 80% of patients after one year, and in 92.9% after two years by at least the MCIC score of 12.9 points (Copay

**Table 1**  
Data of included patients.

Parameter	n/Value (±SD)
Included patients	34
Sex (m/f)	19/15
Age	52.5 (±11.5) years
Follow-Up (FU)	2.7 (±2.4) years
ASA risk classification	2.0 (±0.6)

**Table 2**

Radiographic findings pre- and postoperative. <sup>+</sup>One patient had no longer a slip after the ALIF; for one patient neither the radiographs were traceable nor there was a documentation.

Parameter	Preoperative (mean ± SD)	Postoperative (mean ± SD)
Pelvic incidence (PI)	65 (±9)°	
Meyerding classification:		
- Grade 1	16	22
- Grade 2	15	10
- Grade 3	3	0 <sup>+</sup>
- Grade 4	0	0
Slip	33 (±11)%	28 (±13)%
Lumbar lordosis (LL)	59 (±9)°	65 (±9)°
PI - LL	6 (±9)°	0.4 (±6)°

et al., 2008). Preoperatively, mean VAS values for back and leg pain measured  $5.3 \pm 2.5$  and  $6.8 \pm 2.3$ , respectively, and improved to  $1.9 \pm 1.8$  and  $1.7 \pm 2.5$ , respectively at one year FU (22/34 patients), and to  $1.6 \pm 2.3$  and  $1.2 \pm 1.5$ , respectively at two years FU (14/34 patients). The improvement of all parameters from pre-to postoperative was significant (Table 3) (Fig. 3)

### 3.4. Intraoperative data, surgical complications and reoperations

The mean operation time was  $136 \pm 21$  min. The mean estimated blood loss was  $171 \pm 75$  ml.

There were no intraoperative vascular or other major complications. One patient with an estimated blood loss of 400 ml and postoperative anemia was treated with transfusion of one unit of packed red blood cells. The reoperation rate was 8.8% (3 patients) for the index segment and 0% for the adjacent segment, in the observation period. In one patient, the S1 anchoring screws could not be inserted due to severely sclerotic bone and posterior instrumentation was therefore added. Two other patients received an additional posterior instrumentation. In one case due to pseudoarthrosis diagnosed by CT after 6 months causing severe back pain, and in the other case additional posterior decompression was required for persisting sciatica after 3 months.

One patient had adjacent segment disease with a disc herniation, which was successfully treated conservatively. None of the male patients experienced retrograde ejaculation after surgery. There was no donor site morbidity at the iliac crest (Table 4).

## 4. Discussion

In our series, stand-alone ALIF proved to be a safe and effective technique to treat symptomatic lumbosacral isthmic spondylolisthesis. Improvement of radicular pain points to the effectiveness of indirect decompression within the neuroforamen and the spinal canal by restoring the disc height with high and lordotic cages (Rao et al., 2015b).

Lemcke et al. (2007) compared the outcome of 115 patients with isthmic spondylolisthesis treated by ALIF or PLIF. They found a significant improvement after surgery in both groups. However, contrary to our series, a posterior instrumentation was routinely added in the ALIF group in their study.

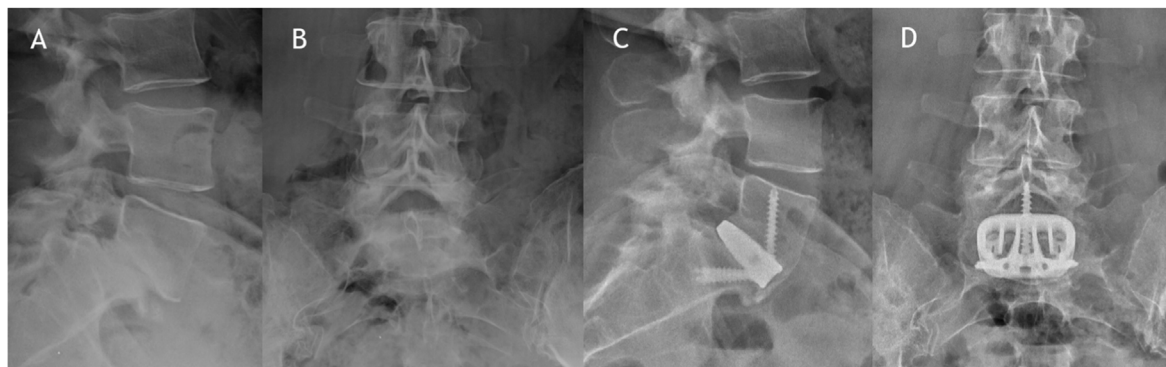
Fleege et al. (2016) found significant improvement in the VAS in 72 patients with low-grade isthmic spondylolisthesis managed by ALIF with posterior instrumentation or PLIF with no significant differences in the ODI scores between the two groups. However, the revision rate for non-union and wound healing disturbances were higher in the PLIF group. On the other hand, there was a higher rate of adjacent level disease (20%), longer mean hospital stay, and operation time in the ALIF group. In the present study, we demonstrate that a stand-alone ALIF with vertebral anchoring screws is sufficient in most cases for improved sagittal balance, lumbar fusion and clinically important improvement of back and leg pain with a low rate of adjacent level disease (3%). This is in accordance with one other study that also demonstrated a lower rate of adjacent level disease for stand-alone ALIF than for PLIF (Min et al., 2007).

Kim et al. (2010b) compared the clinical and radiographic outcomes of TLIF and instrumented ALIF retrospectively in 128 patients with unstable low-grade isthmic spondylolisthesis at the L4-5 and L5-S1 level. At the L4-5 level, the TLIF group fared better than the ALIF group with regard to postoperative ODI score improvement. However, at the L5-S1 level, radiographic results indicated that ALIF was significantly superior to TLIF in its ability to restore disc height and improve sagittal balance parameters. The authors concluded that TLIF is preferable at the L4-5 segment, whereas ALIF might be preferable at L5-S1 for the mentioned reasons. In our opinion, stand-alone ALIF with vertebral anchoring screws has the important advantage of abolishing the necessity of an additional posterior instrumentation to achieve sufficient segmental stability. Thus, iatrogenic muscle trauma is avoided and duration of surgery is reduced. This line of argumentation is also

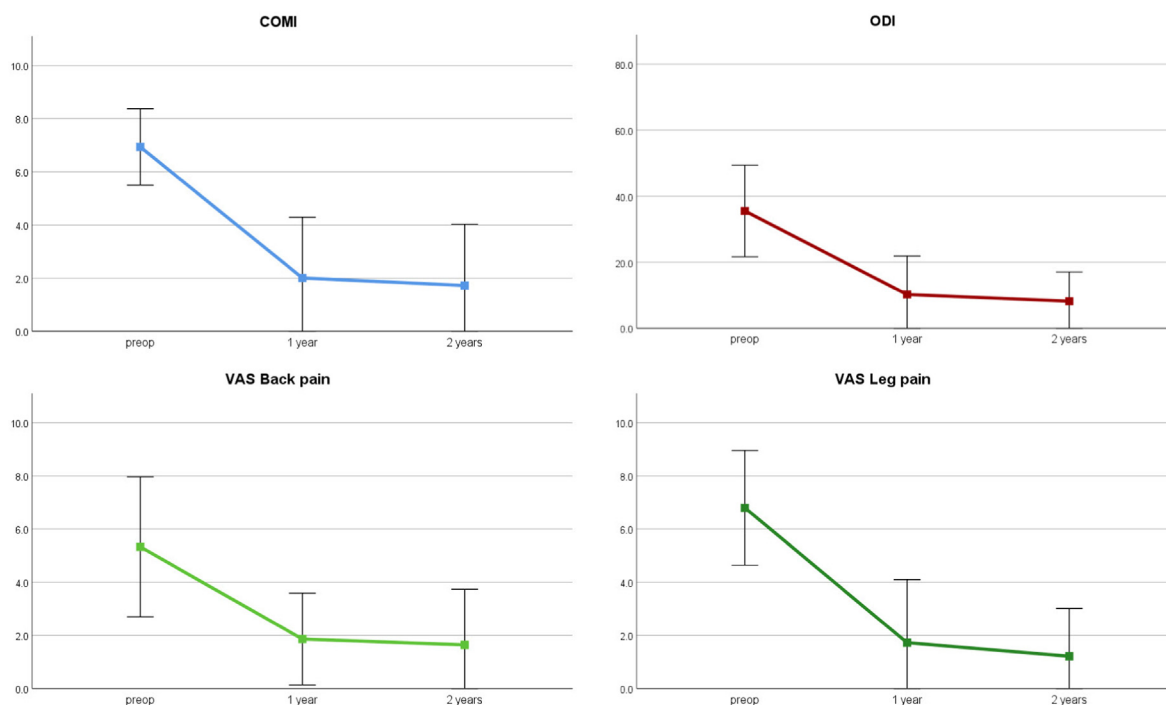
**Table 3**

Comparison of pre- and postoperative PROMS. \*p-value for comparison between preoperative and 1 year postoperative and preoperative and 2 years postoperative, respectively.

Parameter	Preoperative (mean ± SD)	1 year Postoperative (mean ± SD)	2 years Postoperative (mean ± SD)	p-value*
COMI	6.9 (1.4)	2.0 (2.3)	1.7 (2.3)	<0.001/ <0.01
ODI	35.5 (13.8)	10.2 (11.7)	8.2 (8.9)	<0.001/ <0.01
VAS back pain	5.3 (2.6)	1.9 (1.7)	1.6 (2.1)	<0.001/ <0.02
VAS leg pain	6.8 (2.2)	1.7 (2.4)	1.2 (1.8)	<0.001/ <0.01



**Fig. 2.** A, B: Lateral and a.p. radiographs of a patient with symptomatic isthmic spondylolisthesis L5-S1 Meyerding grade 2. C, D: Postoperative images one year after surgery with a bridging fusion and slip correction.



**Fig. 3.** Comparison of patient-rated outcomes before and after surgery. COMI, ODI and VAS scores shown as mean values  $\pm$  standard deviation. A significant improvement in all parameters was observed ( $p < 0.02$ ) in the follow-up period.

**Table 4**

Intra- and postoperative complications and reoperations.

Complications	n (%)
Postoperative anemia	1 (2.9%)
Anchoring screws not implantable	1 (2.9%)
Vascular injury	0 (0%)
Symptomatic pseudoarthrosis	1 (2.9%)
Persisting sciatica	1 (2.9%)
Adjacent segment disease (treated conservatively)	1 (2.9%)
Retrograde ejaculation	0 (0%)
Thrombosis	0 (0%)
Donor site morbidity	0 (0%)
Reoperations	3 (8.8%)

supported by other authors (Strube et al., 2012).

Anobile et al. (Aunoble et al., 2006) also described a case series of 20 patients with low-grade L5-S1 isthmic spondylolisthesis treated with video-assisted ALIF and anterior plate fixation. They had similar reoperations rates (10% compared to 8.8% in our group) and improvement of both radiologic and patient reported outcome measures. Some authors consider isthmic and high-grade spondylolisthesis to be a contraindication for a stand-alone ALIF (Jaeger et al., 2019; Mobbs et al., 2015). However, our data and other published studies suggest that stand-alone ALIF is in fact a safe and effective surgical technique to treat low-grade isthmic spondylolisthesis (Viglione et al., 2017; Muschik et al., 1997). We agree that an anterior approach would be challenging or simply unfeasible in many high-grade spondylolisthesis cases, due to anatomical considerations. Also, the high rate of reported postoperative L5 radiculopathies in high-grade spondylolisthesis cases might be an argument for a posterior approach with direct foraminal decompression prior to reduction (Schar et al., 2017). Of the three high-grade spondylolisthesis patients in our cohort, none had a slip of more than 55%. In these cases, being high-grade spondylolisthesis cases by definition, a circumferential approach would certainly also have been feasible.

A high PI and steep sacral slope are generally known as risk factors for pseudoarthrosis in isthmic spondylolisthesis (Jaeger et al., 2019). Additionally, a steep sacral slope may be a contraindication for an ALIF

because of the difficulties of the steep working trajectory and cage insertion (Kim et al., 2008).

Our data suggest an acceptable overall fusion rate of 84.0%. In this group there was only one pseudoarthrosis corresponding to a CT-based fusion rate of 90.9%. For the remaining cases, fusion was defined by above-mentioned criteria on dynamic radiographs. Only one patient had to undergo an additional posterior fusion due to a symptomatic pseudoarthrosis with non-union. Our findings are in line with a recent systematic review, which reported overall fusion rates for stand-alone ALIF of 88.6% (range: 57.5%–99.0%) (Manzur et al., 2019).

In our series, three patients required reoperation (8.8%) for the reasons mentioned earlier. Yet, in this regard our data is in line with previous reports on reoperation. Viglione et al. (2017) reported an overall reoperation rate of 11% in their systematic review of stand-alone ALIF in isthmic spondylolisthesis. The rate of adjacent segment disease in our series was quite low with only one patient, who developed a L4-5 disc herniation years after the initial surgery. However, one might argue that this was merely the natural course of the L4-5 disc degeneration, rather than a consequence of a previous L5-S1 fusion. In accordance with our results, other authors have suggested that stand-alone ALIF might be more advantageous in preventing adjacent segment disease than posterior approaches (Min et al., 2007).

Retrograde ejaculation is a rare but feared and dramatic complication potentially leading to a far-reaching loss in quality of life in men. Although there are surgical tricks, such as not using any electrocauterization in the vicinity of the superior hypogastric plexus, to prevent this complication (Mobbs et al., 2016; Lindley et al., 2012), careful decision making as well as patient counselling is crucial before committing to an ALIF procedure in young men. In our series of 19 male patients, none suffered from retrograde ejaculation after the ALIF.

## 5. Limitations

Our study has several limitations. First, although the data are prospectively collected, this is a retrospective study with a limited number of patients. However, this is a highly selective population, and we believe reporting of this outcome data is justified. Second, the generalizability of



our study is somewhat compromised by missing follow-up data. Also, not all patients received a postoperative CT scan or flexion-extension radiographs to assess spinal fusion. Third, one could argue that there is a patient selection bias in our study. However, in our series ALIF was the institution's standard approach for symptomatic patients with low-grade isthmic spondylolisthesis of the lumbosacral junction. Lastly, no comparison group was defined to further highlight the advantages of stand-alone ALIF.

## 6. Conclusion

Patient reported outcomes after stand-alone ALIF for symptomatic isthmic spondylolisthesis showed clinically important improvements after one and two years. There were no vascular or other major complications in our series. To achieve bony fusion the use of an auto- or allograft is crucial. These results suggest that with careful patient selection, stand-alone ALIF is an effective and safe surgical treatment option for symptomatic low-grade isthmic spondylolisthesis.

## Declarations

### Funding information

This research did not receive any specific grant from funding agencies in the public, commercial, or not-for-profit sectors.

### Conflict of interest

OS: Designing surgeon for Biedermann Motech GmbH & Co. KG, Villingen-Schwenningen, Germany. All other authors declare that they have no conflict of interest.

### Availability of data and material

The datasets generated during and/or analyzed during the current study are available from the corresponding author on reasonable request.

### Ethics approval

Approval from the local ethics committee of the canton of Bern, Switzerland, for this study (2020–02659) was obtained.

### Consent for publication

All authors revised the manuscript and approved the version to be published.

## Declaration of competing interest

The authors declare that they have no known competing financial interests or personal relationships that could have appeared to influence the work reported in this paper.

## References

- Aunoble, S., Hoste, D., Donkersloot, P., Liqueois, F., Basso, Y., Le Huec, J.C., 2006. Video-assisted ALIF with cage and anterior plate fixation for L5-S1 spondylolisthesis. *J. Spinal Disord. Tech.* 19, 471–476. <https://doi.org/10.1097/01.bsd.0000211249.82823.d9>.
- Burkus, J.K., Foley, K., Haid, R.W., LeHuec, J.C., 2001. Surgical Interbody Research Group—radiographic assessment of interbody fusion devices: fusion criteria for anterior lumbar interbody surgery. *Neurosurg. Focus* 10, E11. <https://doi.org/10.3171/foc.2001.10.4.12>.
- Copay, A.G., Glassman, S.D., Subach, B.R., Berven, S., Schuler, T.C., Carreon, L.Y., 2008. Minimum clinically important difference in lumbar spine surgery patients: a choice of methods using the Oswestry Disability Index, Medical Outcomes Study questionnaire

- Short Form 36, and pain scales. *Spine J. : Off. J. North Am. Spine Soc.* 8, 968–974. <https://doi.org/10.1016/j.spinee.2007.11.006>.
- Endler, P., Ekman, P., Moller, H., Gerdhem, P., 2017. Outcomes of posterolateral fusion with and without instrumentation and of interbody fusion for isthmic spondylolisthesis: a prospective study. *J. Bone Joint Surg. Am.* 99, 743–752. <https://doi.org/10.2106/JBJS.16.00679>.
- Fairbank, J.C., Pynsent, P.B., 2000. The Oswestry disability index. *Spine* 25, 2940–2952. <https://doi.org/10.1097/00007632-20001150-00017> discussion 2952.
- Fleege, C., Arabmottlagh, M., Rother, W., Rauschmann, M., Rickert, M., 2016. [ALIF and PLIF interposition in low-grade isthmic spondylolisthesis L5/S1 : longterm-Comparison of interbody fusion techniques (ALIF - PLIF)]. *Orthopä* 45, 760–769. <https://doi.org/10.1007/s00132-016-3311-4>.
- Jaeger, A., Giber, D., Bastard, C., Thiebaut, B., Roubineau, F., Flouzat Lachaniette, C.H., Dubory, A., 2019. Risk factors of instrumentation failure and pseudarthrosis after stand-alone L5-S1 anterior lumbar interbody fusion: a retrospective cohort study. *J. Neurosurg. Spine* 31, 338–346. <https://doi.org/10.3171/2019.3.SPINE181476>.
- Kapustka, B., Kiwic, G., Chodakowski, P., Miodonski, J.P., Wysokinski, T., Laczynski, M., Paruzel, K., Kotas, A., Marcol, W., 2020. Anterior lumbar interbody fusion (ALIF): biomechanical results and own experiences. *Neurosurg. Rev.* 43, 687–693. <https://doi.org/10.1007/s10143-019-01108-1>.
- Kim, S.Y., Maeng, D.H., Lee, S.H., Jang, J.S., 2008. Anterior lumbar interbody fusion for lumbosacral junction in steep sacral slope. *J. Spinal Disord. Tech.* 21, 33–38. <https://doi.org/10.1097/BSD.0b013e3180577223>.
- Kim, J.S., Choi, W.G., Lee, S.H., 2010a. Minimally invasive anterior lumbar interbody fusion followed by percutaneous pedicle screw fixation for isthmic spondylolisthesis: minimum 5-year follow-up. *Spine J. : Off. J. North Am. Spine Soc.* 10, 404–409. <https://doi.org/10.1016/j.spinee.2010.02.022>.
- Kim, J.S., Lee, K.Y., Lee, S.H., Lee, H.Y., 2010b. Which lumbar interbody fusion technique is better in terms of level for the treatment of unstable isthmic spondylolisthesis? *J. Neurosurg. Spine* 12, 171–177. <https://doi.org/10.3171/2009.9.SPINE09272>.
- Lemcke, J., Klotzer, S., Klotzer, R., Meier, U., 2007. [PLIF and ALIF for the degenerative spondylolisthesis of the lumbar spine]. *Zeitschrift für Orthopädie und ihre Grenzgebiete* 145, 48–54. <https://doi.org/10.1055/s-2007-960512>.
- Lindley, E.M., McBeth, Z.L., Henry, S.E., Cooley, R., Burger, E.L., Cain, C.M., Patel, V.V., 2012. Retrograde ejaculation after anterior lumbar interbody surgery. *Spine* 37, 1785–1789. <https://doi.org/10.1097/BRS.0b013e31825752bc>.
- Mannion, A.F., Porchet, F., Kleinstuck, F.S., Lattig, F., Jeszenszky, D., Bartanusz, V., Dvorak, J., Grob, D., 2009. The quality of spine surgery from the patient's perspective. Part 1: the Core Outcome Measures Index in clinical practice. *Eur. Spine J. : Off. Publ. Eur. Spine Soc. Eur. Spinal Deformity Soc. Eur. Sec. Cervical Spine Res. Soc.* 18 (Suppl. 3), 367–373. <https://doi.org/10.1007/s00586-009-0942-8>.
- Manzur, M., Virk, S.S., Jivanelli, B., Vaishnav, A.S., McAnany, S.J., Albert, T.J., Iyer, S., Gang, C.H., Qureshi, S., 2019. The rate of fusion for stand-alone anterior lumbar interbody fusion: a systematic review. *Spine J. : Off. J. North Am. Spine Soc.* 19, 1294–1301. <https://doi.org/10.1016/j.spinee.2019.03.001>.
- Min, J.H., Jang, J.S., Lee, S.H., 2007. Comparison of anterior- and posterior-approach instrumented lumbar interbody fusion for spondylolisthesis. *J. Neurosurg. Spine* 7, 21–26. <https://doi.org/10.3171/SPI-07/07/021>.
- Mobbs, R.J., Phan, K., Malham, G., Seex, K., Rao, P.J., 2015. Lumbar interbody fusion: techniques, indications and comparison of interbody fusion options including PLIF, TLIF, MI-TLIF, OLIF/ATP, LLIF and ALIF. *J. spine surg.* 1, 2–18. <https://doi.org/10.3978/j.issn.2414-469X.2015.10.05>.
- Mobbs, R.J., Phan, K., Daly, D., Rao, P.J., Lennox, A., 2016. Approach-related complications of anterior lumbar interbody fusion: results of a combined spine and vascular surgical team. *Global Spine J.* 6, 147–154. <https://doi.org/10.1055/s-0035-1557141>.
- Moller, H., Hedlund, R., 2000. Surgery versus conservative management in adult isthmic spondylolisthesis—a prospective randomized study: part 1. *Spine* 25, 1711–1715. <https://doi.org/10.1097/00007632-200007010-00016>.
- Muschik, M., Zippel, H., Perka, C., 1997. Surgical management of severe spondylolisthesis in children and adolescents. Anterior fusion in situ versus anterior spondylosis with posterior transpedicular instrumentation and reduction. *Spine* 22, 2036–2042. <https://doi.org/10.1097/00007632-199709010-00020> discussion 2043.
- Rao, P.J., Loganathan, A., Yeung, V., Mobbs, R.J., 2015a. Outcomes of anterior lumbar interbody fusion surgery based on indication: a prospective study. *Neurosurgery* 76, 7–23. <https://doi.org/10.1227/NEU.0000000000000561> discussion 23-24.
- Rao, P.J., Maharaj, M.M., Phan, K., Lakshan Abeygunasekara, M., Mobbs, R.J., 2015b. Indirect foraminal decompression after anterior lumbar interbody fusion: a prospective radiographic study using a new pedicle-to-pedicle technique. *Spine J. : Off. J. North Am. Spine Soc.* 15, 817–824. <https://doi.org/10.1016/j.spinee.2014.12.019>.
- Roder, C., Chavanne, A., Mannion, A.F., Grob, D., Aebi, M., 2005. SSE Spine Tango—content, workflow, set-up. *European spine journal* 14, 920–924. <https://doi.org/10.1007/s00586-005-1023-2>. [www.eurospine.org/Spine\\_Tango](http://www.eurospine.org/Spine_Tango). official publication of the European Spine Society, the European Spinal Deformity Society, and the European Section of the Cervical Spine Research Society.
- Schar, R.T., Sutter, M., Mannion, A.F., Eggsphuhler, A., Jeszenszky, D., Fekete, T.F., Kleinstuck, F., Haschtmann, D., 2017. Outcome of L5 radiculopathy after reduction and instrumented transforaminal lumbar interbody fusion of high-grade L5-S1 isthmic spondylolisthesis and the role of intraoperative neurophysiological monitoring. *Eur. Spine J. : Off. Publ. Eur. Spine Soc. Eur. Spinal Deformity Soc. Eur. Sec. Cervical Spine Res. Soc.* 26, 679–690. <https://doi.org/10.1007/s00586-017-4964-3>.

- Sebastian, A.S., Dalton, D., Slaven, S.E., Welch-Phillips, A., Fredericks Jr., D.R., Ahern, D.P., Butler, J.S., 2020. What is the optimal surgical treatment for low-grade isthmic spondylolisthesis? ALIF or TLIF? *Clin. spine surg.* 33, 389–392. <https://doi.org/10.1097/BSD.0000000000000926>.
- Strube, P., Hoff, E., Hartwig, T., Perka, C.F., Gross, C., Putzier, M., 2012. Stand-alone anterior versus anteroposterior lumbar interbody single-level fusion after a mean follow-up of 41 months. *J. Spinal Disord. Tech.* 25, 362–369. <https://doi.org/10.1097/BSD.0b013e3182263d91>.
- Viglione, L.L., Chamoli, U., Diwan, A.D., 2017. Is stand-alone anterior lumbar interbody fusion a safe and efficacious treatment for isthmic spondylolisthesis of L5-S1? *Global Spine J.* 7, 587–595. <https://doi.org/10.1177/2192568217699210>.