




Contents lists available at ScienceDirect

Journal of the Neurological Sciences

journal homepage: www.elsevier.com/locate/jns

Magnetic resonance imaging-based scores of small vessel diseases: Associations with intracerebral haemorrhage location

Ghil Schwarz^{a,b}, Gargi Banerjee^a, Isabel Charlotte Hostettler^{a,m}, Gareth Ambler^c, David J. Seiffge^{a,d}, Tenzin S. Brookes^a, Duncan Wilson^{a,e}, Hannah Cohen^f, Tarek Yousry^g, Rustam Al-Shahi Salman^h, Gregory Y.H. Lip^{i,n}, Martin M. Brown^a, Keith W. Muir^j, Henry Houlden^k, Rolf Jäger^g, David J. Werring^a, Julie Staals^{l,*}, on behalf of the CROMIS-2 investigators

^a Stroke Research Centre, University College London, Institute of Neurology, London, UK

^b Neurologia and Stroke Unit ASST Grande Ospedale Metropolitano Niguarda, Milan, Italy

^c Department of Statistical Science, University College London, London, UK

^d Department of Neurology and Stroke Center, Inselspital, Bern, Switzerland

^e New Zealand Brain Research Institute, Christchurch, New Zealand

^f Haemostasis Research Unit, Department of Haematology, University College London, London, UK

^g Lysholm Department of Neuroradiology and the Neuroradiological Academic Unit, Department of Brain Repair and Rehabilitation, UCL Institute of Neurology, Queen Square, London, UK

^h Centre for Clinical Brain Sciences, School of Clinical Sciences, University of Edinburgh, Edinburgh, UK

ⁱ Liverpool Centre for Cardiovascular Science, University of Liverpool and Liverpool Heart & Chest Hospital, Liverpool, UK

^j Institute of Neuroscience & Psychology, University of Glasgow, Queen Elizabeth University Hospital, Glasgow, UK

^k Department of Molecular Neuroscience, UCL Institute of Neurology and the National Hospital for Neurology and Neurosurgery, Queen Square, London, UK

^l Department of Neurology and School for Cardiovascular Diseases (CARIM), Maastricht University Medical Centre, Maastricht, the Netherlands

^m Department of Neurosurgery, Cantonal Hospital St. Gallen, Switzerland

ⁿ Department of Clinical Medicine, Aalborg University, Aalborg, Denmark

ARTICLE INFO

Keywords:

Intracerebral haemorrhage

Small vessel disease

Total SVD score

MRI-based score

Cerebral amyloid angiopathy

CAA score

ABSTRACT

Introduction: Total small vessel disease (SVD) score and cerebral amyloid angiopathy (CAA) score are magnetic resonance imaging-based composite scores built to preferentially capture deep perforator arteriopathy-related and CAA-related SVD burden, respectively. Non-lobar intracerebral haemorrhage (ICH) is related to deep perforator arteriopathy, while lobar ICH can be associated with deep perforator arteriopathy or CAA; however, the associations between ICH location and these scores are not established.

Methods: In this post-hoc analysis from a prospective cohort study, we included 153 spontaneous non-cerebellar ICH patients. Wald test, univariable and multivariable logistic regression analysis were performed to investigate the association between each score (and individual score components) and ICH location.

Results: Total SVD score was associated with non-lobar ICH location (Wald test: unadjusted, $p = 0.017$; adjusted, $p = 0.003$); however, no individual component of total SVD score was significantly associated with non-lobar ICH. CAA score was not significantly associated with lobar location (Wald test: unadjusted, $p = 0.056$; adjusted, $p = 0.126$); cortical superficial siderosis (OR 8.85 [95%CI 1.23–63.65], $p = 0.030$) and ≥ 2 strictly lobar microbleeds (OR 1.63 [95%CI 1.04–2.55], $p = 0.035$) were related with lobar ICH location, while white matter hyperintensities showed an inverse relation (OR 0.53 [95%CI 0.26–1.08; $p = 0.081$]).

Conclusions: Total SVD score was associated with non-lobar ICH location. The lack of significant association between CAA score and lobar ICH may in part be due to the mixed aetiology of lobar ICH, and to the inclusion of white matter hyperintensities, a non-specific marker of SVD type, in the CAA score.

* Corresponding author at: Department of Neurology and School for Cardiovascular Diseases (CARIM), Maastricht University Medical Centre, PO Box 5800, 6202 AZ Maastricht, the Netherlands.

E-mail address: j.staals@mumc.nl (J. Staals).

<https://doi.org/10.1016/j.jns.2022.120165>

Received 8 August 2021; Received in revised form 20 December 2021; Accepted 18 January 2022

Available online 24 January 2022

0022-510X/© 2022 The Author(s). Published by Elsevier B.V. This is an open access article under the CC BY license (<http://creativecommons.org/licenses/by/4.0/>).

1. Introduction

Most spontaneous (non-traumatic) intracerebral haemorrhages (ICH) are caused by disease of the small vessels in the brain. [1,2] Deep perforator arteriopathy and cerebral amyloid angiopathy (CAA) are the two most common types of small vessel disease (SVD) underlying ICH [3]. Deep perforator arteriopathy is a strongly age- and hypertension-related pathology, predominantly of the deep perforating vessels supplying the basal ganglia, brainstem, and deep white matter. Deep perforator arteriopathy can cause either deep (non-lobar) or lobar ICH. CAA results from β -amyloid deposition within cortical and leptomeningeal small arteries and primarily causes lobar ICH [4].

Several MRI findings have been recognized as structural markers of the presence and severity of SVD. These neuroimaging features have been incorporated in two MRI-based composite 'scores' which aim to capture the overall burden of SVD in the brain: the total SVD score and CAA score. The total SVD score was developed in patients with lacunar ischaemic stroke [5] and hypertension [6] and therefore probably best captures deep perforator arteriopathy. The score incorporates lacunes, cerebral microbleeds, basal ganglia perivascular spaces and white matter hyperintensities [5]. The CAA score measures strictly lobar microbleeds, cortical superficial siderosis, centrum semiovale perivascular spaces and white matter hyperintensities with the aim of specifically capturing the burden of CAA [7].

Whether total SVD score and CAA score can capture the burden of different SVD subtypes (deep perforator arteriopathy and CAA-related) has still to be fully tested in populations of patients with a spectrum of SVDs. Non-lobar ICH can be considered a primarily deep perforator arteriopathy-related SVD event, while lobar ICH is primarily (but not exclusively) CAA-related [8]. However, the association between the two scores and ICH location is not established and both scores have not been applied to a mixed ICH population. An association between total SVD score and non-lobar ICH and between CAA score and lobar ICH could support the validity and research application of the two scores in ICH.

This study aims to evaluate whether there is an association between type of composite SVD score (total SVD score and CAA score) and ICH location (non-lobar vs lobar) in a prospective cohort of mixed spontaneous ICH patients.

2. Methods

2.1. Study design and patient cohort

This is a post-hoc analysis based on data from CROMIS-2 ICH [9] (NCT02513316), a prospective cohort study undertaken at 79 UK hospitals and one in the Netherlands, in 2011–2015. The trial enrolled 1065 patients; 1037 (97.4%) had spontaneous non-traumatic ICH confirmed on neuroimaging. From the entire cohort, we excluded 866 (81.3%) patients with non-available MRI data and/or without all sequences available for rating of SVD and CAA scores, 18 [1.7%] patients with non-available measurement of ICH volume (via semi-automated method) and 28 (2.6%) patients with missing follow-up (relevant for detecting evidence of underlying structural cause for ICH). We collected detailed data on demographics, risk factors, clinical presentation and brain imaging findings.

2.2. MRI assessment and SVD scores

MRI sequences were assessed by experienced independent raters, blinded to other clinical information. Measurement of ICH volume was performed via a semi-automated (threshold-based) approach, as previously described [10]. ICH location was assessed using the Cerebral Haemorrhage Anatomical Rating Instrument (CHARTS) [11]. Imaging markers of cerebral SVD were rated in accordance with the Standards for Reporting Vascular Changes on Neuroimaging consensus criteria [12]. Lacunes are defined as rounded or ovoid lesions (3–15 mm in diameter)

with central cerebrospinal fluid-like hypointensity and a surrounding rim of hyperintensity on fluid-attenuated inversion recovery (FLAIR) sequences. Lacunes were rated (on T2 and FLAIR sequences) in basal ganglia, internal capsule, centrum semi-ovale and brainstem [12]. Cerebral microbleeds are small (≤ 10 mm), homogeneous, round foci of low signal intensity on T2*-GRE/SWI sequences. Microbleeds were classified through Microbleed Anatomical Rating Scale (MARS) [13]. Cortical superficial siderosis was classified per consensus criteria [12,14], and was considered disseminated if more than 3 sulci were involved (otherwise considered focal). Perivascular spaces are small (≤ 2 mm) punctate or linear (depending on the plane of the scan) hyperintensities on T2 sequences [15]. Perivascular spaces were rated in the centrum semiovale and basal ganglia using a validated 4-point visual rating scale on a single predefined slice (first slice above the anterior commissure for the basal ganglia, and the first slice above the level of the lateral ventricles for the centrum semiovale) [12,15]. White matter hyperintensities were rated on T2 and FLAIR sequences using the Fazekas scale [16].

Total SVD-score and CAA-score were calculated as described in the original publications:

1. Total SVD-score [5]. One point was given for each of the following: presence of one or more lacunes; one or more microbleeds in any location; moderate/severe presence of perivascular spaces in the basal ganglia (score 2–4); Fazekas score 3 in periventricular white matter and/or Fazekas 2–3 in deep white matter. Total SVD score ranges from 0 to 4 (ordinal scale).
2. CAA-score [7]. One point was awarded if 2 to 4 strictly lobar microbleeds were present and 2 points for 5 or more lobar microbleeds. One point for focal and 2 points for disseminated cortical superficial siderosis. The presence of moderate/severe (score 3–4) perivascular spaces in centrum semiovale achieved one point. White matter hyperintensities was rated as per SVD-score. The CAA score ranges from 0 to 6 points (ordinal scale).

Examples of MRI-based biomarkers included in the two scores are presented in Fig. 1.

2.3. Statistical analyses

We described categorical variables with frequencies and percentages, and continuous variables using mean and standard deviation (SD) or median with interquartile range. To test for differences of clinical and radiological variables per ICH location (non-lobar vs lobar), we used Chi-square or Fisher exact, and Mann–Whitney tests, as appropriate.

Wald test was used to assess the overall association between scores and ICH location. The association between each level of the score with ICH location was evaluated through univariable and multivariable (adjusted for baseline clinical variables found to be associated with ICH location [$p < 0.1$]) logistic regression models. Association between single neuroimaging features included in total SVD and CAA score with ICH location was also evaluated via univariable logistic regression analysis. A secondary analysis, repeating the above described regression analyses but excluding patients on oral anticoagulant drug was also performed. Correlation between the two scores was evaluated via Spearman's rho test. The significance level was set at $p = 0.05$. Statistical analysis was performed using STATA 16 (StataCorp. 2019. *Stata Statistical Software: Release 16*. College Station, TX: StataCorp LP).

3. Results

We included 153 patients with spontaneous non-traumatic non-cerebellar ICH. Differences between included and excluded patients are reported in the Appendix table A.1). Seventy-five patients (49.0%) were classified as non-lobar, 78 (51.0%) as lobar ICH. According to the modified Boston criteria [17], 23 (29.5%) patients with lobar ICH

fulfilled the criteria for probable CAA and 43 (55.1%) for possible CAA. Clinical and radiological characteristics, and differences between non-lobar and lobar ICH location are reported in [Table 1](#).

Patients with lobar ICH were older, were less frequently hypertensive

and had larger ICH volumes. Total SVD scores were higher in patients with non-lobar vs lobar ICH location (median 1 [Q1-Q3 = 1–2] vs median 1 [Q1-Q3 = 0–1]; $p = 0.012$), while CAA scores were higher in patients with lobar vs non-lobar ICH location (median 1 [Q1-Q3 = 0–2]

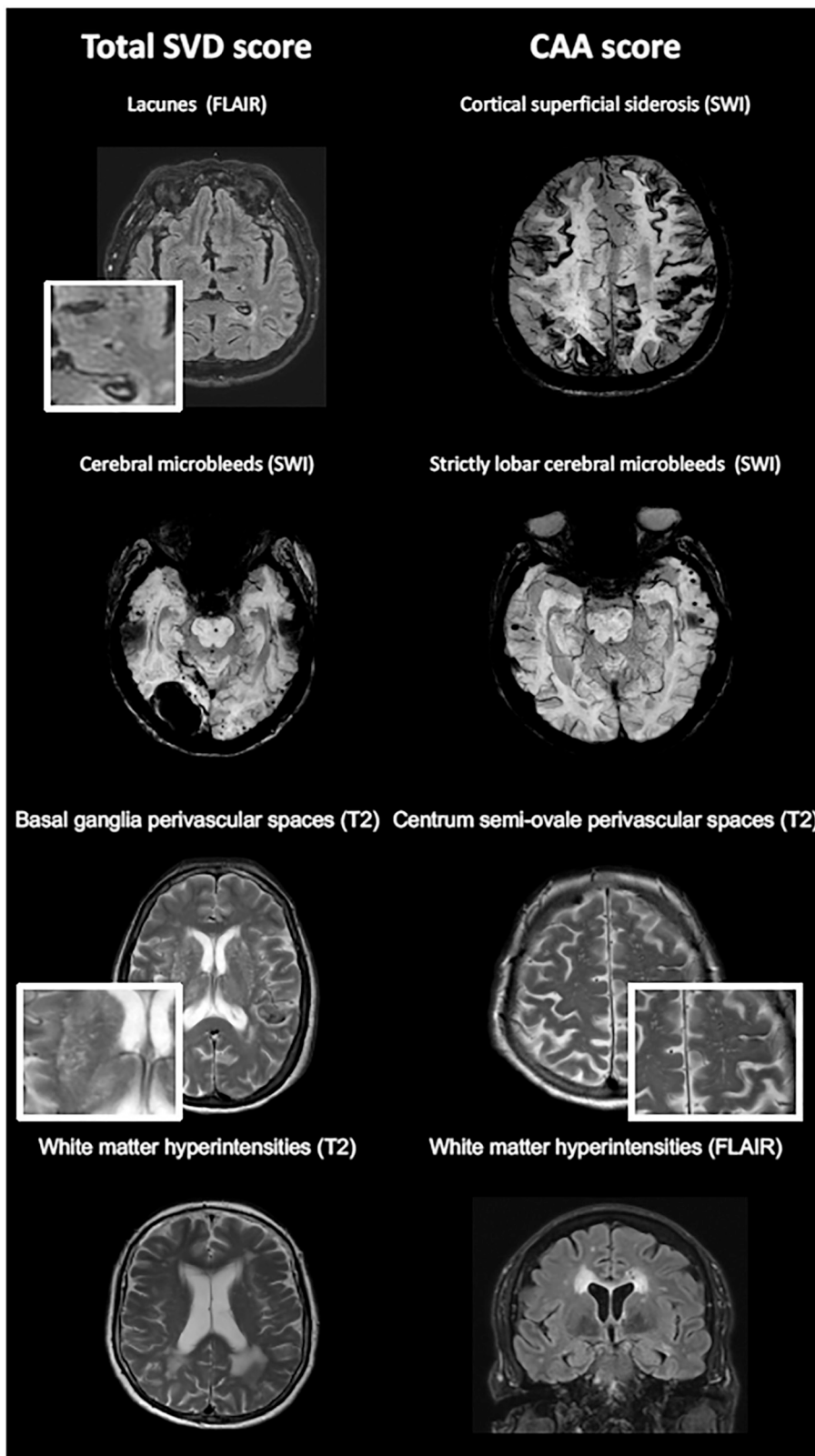


Fig. 1. MRI examples of SVD markers included in Total SVD score and CAA score. SVD, small vessel disease; CAA, cerebral amyloid angiopathy; FLAIR, fluid-attenuated inversion recovery; SWI, susceptibility weighted imaging.

Table 1

Clinical and radiological variables for the entire cohort, and differences between non-lobar and lobar ICH patients.

| Variable | Entire cohort | Non-lobar ICH | Lobar ICH | p value |
|--|------------------|------------------|------------------|------------------|
| | N (%) | N (%) | N (%) | |
| | 153 (100) | 75 (49.0) | 78 (51.0) | |
| Clinical variables | | | | |
| Age (years, median, [Q1-Q3]) | 69.0 [61.3–76.2] | 66.0 [53.2–74.1] | 72.9 [64.4–77.9] | 0.003 |
| Female | 59/153 (38.6) | 27/75 (36.0) | 32/78 (41.0) | 0.523 |
| Hypertension | 86/153 (56.2) | 49/75 (65.3) | 37/78 (47.4) | 0.026 |
| Diabetes Mellitus | 16/153 (10.5) | 8/75 (10.7) | 8/78 (10.3) | 1.0 |
| Smoking | | | | 0.154 |
| Current | 17/150 (11.3) | 11/73 (15.1) | 6/77 (7.8) | |
| Ex-smoker | 64/150 (42.7) | 26/73 (35.6) | 38/77 (49.4) | |
| Non-smoker | 69/150 (46.0) | 36/73 (49.3) | 33/77 (42.9) | |
| Previous ischemic stroke | 14/153 (9.2) | 9/75 (12.0) | 5/78 (6.4) | 0.231 |
| Previous ICH | 6/153 (3.9) | 3/75 (4.0) | 3/78 (3.9) | 0.961 |
| Oral Anticoagulant | 35/153 (22.9) | 15/75 (20.0) | 20/78 (25.6) | 0.626 |
| Drug | | | | |
| VKA | 31/153 (20.3) | 12/75 (16.0) | 19/78 (24.4) | 0.198 |
| DOAC | 4/153 (1.6) | 3/75 (4.0) | 1/78 (1.3) | 0.292 |
| Antiplatelet Drug | 30/153 (19.6) | 13/75 (17.3) | 17/78 (21.8) | 0.487 |
| Statin Drug | 60/153 (39.2) | 28/75 (37.3) | 32/78 (41.0) | 0.640 |
| NIHSS score (median, [Q1-Q3]) ^a | 8 [3–13] | 10 [4–13] | 6 [3–11] | 0.121 |
| GCS (median, [Q1-Q3]) | 15 [14–15] | 15 [14–15] | 15 [14–15] | 0.385 |
| Imaging variables | | | | |
| ICH volume (ml, median, [Q1-Q3]) | 7.3 [2.6–15.9] | 5.1 [1.6–11.4] | 11.0 [4.1–26.3] | <0.001 |
| ≥1 Lacunes | 33/153 (21.6) | 21/75 (28.0) | 12/78 (15.4) | 0.058 |
| Moderate/Severe PVS in basal ganglia | 21/153 (13.7) | 14/75 (18.7) | 7/78 (9.0) | 0.10 |
| ≥1 cerebral microbleed | 91/153 (59.5) | 48/75 (64.0) | 43/78 (55.1) | 0.264 |
| WMH periventr. 3 and/or deep 2–3 | 45/153 (29.4) | 27/75 (36.0) | 18/78 (23.1) | 0.079 |
| Cortical superficial siderosis | | | | 0.009 |
| No | 141/153 (92.2) | 74/75 (98.7) | 67/78 (85.9) | |
| Focal | 8/153 (5.2) | 1/75 (1.3) | 7/78 (9.0) | |
| Disseminated | 4/153 (2.6) | 0/75 (0.0) | 4/78 (5.1) | |
| Moderate/severe PVS in centrum semiovale | 30/153 (19.6) | 11/75 (14.7) | 19/78 (24.4) | 0.156 |
| Strictly lobar microbleeds | | | | 0.060 |
| No | 107/153 (69.9) | 57/75 (76.0) | 50/78 (64.1) | |
| 2–4 | 23/153 (15.0) | 12/75 (16.0) | 11/78 (14.1) | |
| >5 | 23/153 (15.0) | 6/75 (8.0) | 17/78 (21.8) | |
| Total SVD score (median, [Q1-Q3]) | 1 [0–2] | 1 [1–2] | 1 [0–1] | 0.012 |
| 0 | 41/153 (26.8) | 18/75 (24.0) | 23/78 (29.5) | |
| 1 | 57/153 (37.2) | 21/75 (28.0) | 36/78 (46.1) | |
| 2 | 35/153 (22.9) | 21/75 (28.0) | 14/78 (18.0) | |
| 3–4 [§] | 20/153 (13.1) | 15/75 (20.0) | 5/78 (6.4) | |
| CAA score (median, [Q1-Q3]) | 1 [0–2] | 0 [0–2] | 1 [0–2] | 0.018 |
| 0 | 63/153 (41.2) | 39/75 (52.0) | 24/78 (30.8) | |
| 1 | 46/153 (30.1) | 17/75 (22.7) | 29/78 (37.2) | |
| 2 | 25/153 (16.3) | 13/75 (17.3) | 12/78 (15.4) | |
| 3 | 14/153 (9.1) | 5/75 (6.7) | 9/78 (11.5) | |
| 4–5–6 [†] | 5/153 (3.3) | 1/75 (1.3) | 4/78 (5.1) | |

GCS, Glasgow Coma Scale; ICH, intracerebral haemorrhage; SD, standard deviation; Q1-Q3, quartile 1-quartile 3; PVS perivascular spaces; WMH, white matter hyperintensities; CAA, cerebral amyloid angiopathy; VKA, vitamin K antagonists; DOAC, direct oral anticoagulants. NIHSS National Institute Health Stroke Scale. Bold indicates P<0.05.

^a NIHSS score available for 97 out of 153 patients.

[§] SVD score 3 and 4 were merged together (only two patients with score 4).

[†] CAA score 4, 5 and 6 were merged together (only two patients with score 5, and no patients in the cohort with score 6).

vs median 0 [Q1-Q3 = 0–2]; $p = 0.018$). In patients with lobar ICH, CAA scores were higher in those with probable CAA (median 2 [Q1-Q3 = 1–3]) compared to those with possible/no CAA (median 1 [Q1-Q3 = 0–1]; $p < 0.001$). The total SVD and CAA score showed a moderate significant correlation: Spearman's rho 0.55 ($p \leq 0.001$).

3.1. Total SVD score and ICH location

The overall association between total SVD score and non-lobar ICH location was statistically significant (Wald test unadjusted, $p = 0.017$; Wald test adjusted [for age and hypertension], $p = 0.003$) (Table 2). In both univariable and multivariable (adjusted for age and hypertension) logistic regression models the odds for non-lobar ICH (vs lobar) increased with higher total SVD score (Table 2).

3.2. CAA score and ICH location

The association between CAA score and lobar ICH location was not significant (Wald test unadjusted, $p = 0.056$). In multivariable analysis CAA score also did not show a statistically significant overall association with lobar ICH location: Wald test adjusted [for age and hypertension], $p = 0.126$. (Table 2).

3.3. Individual imaging variables

The presence of individual imaging variables as included in the composite scores is presented in Table 1. The association between single imaging variables and ICH location are presented in Table 3. The components in the total SVD score all had OR > 1.0 but were not significant. Conversely, cortical superficial siderosis (OR 8.85 [95%CI 1.23–63.65], $p = 0.030$) and ≥ 2 strictly lobar microbleeds (OR 1.63 [95%CI 1.04–2.55], $p = 0.035$) were found to be significantly associated with lobar ICH location. White matter hyperintensities showed an inverse non-significant association with lobar ICH.

Table 2

Wald test and logistic regression models to test association between scores and ICH location.

| Association between total SVD score and the odds for non-lobar ICH location (vs lobar) | | | | | |
|--|------------------------|--------------|-----------------------------------|---------|--------------|
| Total SVD score | Unadjusted OR (95%CI) | P value | Adjusted OR (95% CI) [§] | P value | |
| Wald test | | 0.017 | | | 0.003 |
| 0 | 1.00 | | 1.00 | | |
| 1 | 0.75 (0.33–1.69) | | 0.79 (0.31–1.96) | | |
| 2 | 1.92 (0.77–4.79) | | 2.39 (0.86–6.64) | | |
| 3–4 [†] | 3.83 (1.17–12.54) | | 7.54 (1.93–29.48) | | |
| Association between CAA score and the odds for lobar ICH location (vs non-lobar) | | | | | |
| CAA score | Unadjusted OR (95% CI) | P value | Adjusted OR (95% CI) [§] | P value | |
| Wald test | | 0.056 | | | 0.126 |
| 0 | 1.00 | | 1.00 | | |
| 1 | 2.77 (1.26–6.08) | | 2.29 (0.99–5.27) | | |
| 2 | 1.50 (0.59–3.82) | | 0.90 (0.31–2.62) | | |
| 3 | 2.93 (0.88–9.77) | | 2.77 (0.77–9.96) | | |
| 4–5–6 [†] | 6.5 (0.69–61.64) | | 4.54 (0.45–45.99) | | |

SVD, small vessel disease; OR, odds ratio; ICH, intracranial haemorrhage; CI, confidence interval; CAA, cerebral amyloid angiopathy. Bold indicates P<0.05.

[†] SVD score 3 and 4 were merged together (only two patients with score 4).

[†] CAA score 4–5–6 were merged together (2 patients with score 5, and no patients in the cohort with score 6).

[§] Adjusted for age, hypertension.

Table 3
Association between individual MRI markers and ICH location.

| Total SVD score variables | Non-lobar ICH location | | |
|--|------------------------|-----------|---------|
| | OR | 95% CI | P value |
| ≥1 Lacunes | 2.14 | 0.97–4.74 | 0.061 |
| Moderate/Severe PVS in basal ganglia | 2.33 | 0.88–6.14 | 0.088 |
| WMH score: periventricular 3 and/or deep 2–3 | 1.88 | 0.92–3.80 | 0.081 |
| ≥1 Cerebral microbleeds | 1.45 | 0.76–2.77 | 0.265 |

| CAA score variables | Lobar ICH location | | |
|--|--------------------|------------|--------------|
| | OR | 95% CI | P value |
| Cortical superficial siderosis** | 8.85 | 1.23–63.65 | 0.030 |
| ≥2 Strictly lobar cerebral microbleeds | 1.63 | 1.04–2.55 | 0.035 |
| WMH score: periventricular 3 and/or deep 2–3 | 0.53 | 0.26–1.08 | 0.081 |
| Moderate/severe PVS in centrum semiovale | 1.87 | 0.82–4.26 | 0.135 |

BG, basal ganglia; PVS, peri-vascular spaces; WMH, white matter hyperintensities; OR, odds ratio; CI, Confidence Interval. Bold indicates $P < 0.05$.

** Only 4 patients with disseminated cSS: focal and disseminated considered together.

3.4. Secondary analysis

Results from secondary analysis, excluding patients on oral anticoagulant drug, confirmed our main findings (Appendix Tables A.2 and A.3).

4. Discussion

The total SVD score had a significant association with non-lobar ICH. The association was maintained when adjusted for potential confounding factors. These results suggest that total SVD score preferentially captures deep perforator arteriopathy-related SVD.

For the CAA score, the association with lobar ICH location was less clear. The reason may be partially related to the fact that non-lobar (deep) ICH is strictly linked to deep perforator arteriopathy and hypertension, while lobar ICH is not an exclusive CAA-related event. Lobar spontaneous ICH are known to be mixed in aetiology: hypertension-related, CAA-related or mixed [18]. In an autopsy study, 58% of lobar ICH were attributed to CAA, and of these 72% also had hypertensive related SVD (i.e. arteriosclerosis) [8]. CAA score was developed in CAA-confirmed ICH cases [7] and has never been applied in heterogeneous ICH population. In our patient group with lobar ICH, those classified as probable CAA (per modified Boston criteria [17]) had higher CAA scores compared to possible/no CAA. However, CAA score may not be able to discriminate between CAA and non-CAA related lobar ICH.

Despite a significant association of the composite total SVD score with non-lobar ICH, when considering the association of single variables included in this score, we found no single variable to be significantly associated with non-lobar ICH. This suggests that total SVD burden score can capture presence of deep perforator arteriopathy-related SVD underlying ICH better than individual variables. This finding may have clinical implications: a composite score - rather than individual SVD-related biomarker [1] - may be a better tool to help identifying patients who need digital subtraction angiography (DSA) to rule out macrovascular causes after ICH. Conversely, the single variables included in the CAA score showed mixed association with ICH location: presence of cortical superficial siderosis, strictly lobar microbleeds and perivascular spaces in centrum semiovale showed a positive relation with lobar ICH, while white matter hyperintensities showed an inverse relation. Our findings suggest that the inclusion of white matter hyperintensities, a non-specific marker of SVD type, in CAA score may partially explain the non-significant association between the score and lobar ICH. Different patterns of white matter hyperintensities demonstrated to provide insights into the dominant underlying micro-

angiopathy type [19]. The multispot pattern of white matter hyperintensities was recently included in the Boston 2.0 criteria for CAA [20]; future studies are needed to investigate whether the inclusion of specific patterns of white matter hyperintensities might improve the correlation between the scores and ICH location. In line with recent evidence, we found that cortical superficial siderosis is the radiological biomarker with the strongest association with lobar ICH, which is often related to CAA [14].

Deep perforator arteriopathy- and CAA-related pathophysiological mechanisms are distinct but related. Consequently, the imaging markers included in the two scores partially overlap and white matter hyperintensities are included in both scores. The overlap between the total SVD and CAA score was confirmed by a moderate correlation between the two. Despite the association with ICH location, given the partial overlap and the correlation between the two scores, our results suggest that total SVD score and CAA score cannot reliably and specifically discriminate between deep perforator arteriopathy and CAA-related SVD.

Our study has strengths. Expert raters applied previously established and accepted MRI-based small vessel disease scores in a population of mixed (non-lobar and lobar) ICH patients. Given our multicenter design, we expect that our results have good generalizability among Western population.

Our study also has limitations. Although SVD biomarkers are diffuse and can be easily scored in the non-hemorrhagic hemisphere, large hematomas could have masked some of them; this could have affected our scoring. Despite a conspicuous sample size, the analysis of individual imaging variables resulted in large odds ratios and p values close to 0.05; these two aspects, combined, suggest a lack of power. The requirement of informed consent, and an MRI scan, could have created a selection bias towards non-severe, clinically stable ICH patients, which in turn may affect our results. This is the first attempt to apply Total SVD- and CAA-scores in a mixed cohort of ICH patients, but other studies on large cohorts of unselected ICH patients are needed to confirm our findings.

5. Conclusion

In a mixed ICH cohort, total SVD score was associated with non-lobar ICH location. The lack of significant association between the CAA score and lobar ICH may in part be due to the mixed aetiology of lobar ICH, and to the non-specific inclusion of white matter hyperintensities in the CAA score.

Ethical approval

The CROMIS-2 study was approved by the local Ethics Committee (reference: 10/H0716/64).

Data availability

All data requests should be submitted to the corresponding author for consideration by the CROMIS-2 Steering Committee.

Standard protocol approvals, registrations and patient consents

Written informed consent was obtained from all participants; in case of lack of capacity written informed consent was obtained from a relative or representative.

Financial disclosures and Conflict of Interest

H.C. reports grants and other support from Bayer Healthcare and UCB outside the submitted work. T.Y. reports personal fees and other support from GlaxoSmithKline, Biogen Idec, Novartis, ESOR, Merck, Hikma and Parexel outside the submitted work. G.Y.H.L. reports consultancy and speaker fees from Bayer, Bayer/Janssen, BMS/Pfizer,

Biotronik, Medtronic, Boehringer Ingelheim, Microlife, Roche and Daiichi-Sankyo outside the submitted work; no fees are directly received personally. K.W.M. reports personal fees from Bayer, personal fees and non-financial support from Boehringer Ingelheim and personal fees from Daiichi-Sankyo outside the submitted work. DJS: Scientific advisory boards: Bayer and Pfizer. Compensation for educational efforts: Stago. DJS is supported by a fellowship from the Swiss National Science Foundation (SNF), the Bangerter-Rhyner Foundation, the Bayer Foundation 2017 “Thrombosis Research Award” and the Swiss Society of Neurology. D.J.W. reports personal fees from Bayer, Alnylam and Portola outside the submitted work. The remaining authors declare no financial or other conflicts of interest.

Acknowledgments and Sources of funding

DJW received funding from the Stroke Foundation/British Heart Foundation. This work was undertaken at UCLH/UCL which receives a proportion of funding from the Department of Health’s National Institute for Health Research (NIHR) Biomedical Research Centres funding scheme. GB holds a Stroke Association and NIHR Clinical Lectureship, and has received funding from the Rosetrees Trust. ICH and HH received funding from the Alzheimer Research UK and Dunhill Medical Trust Foundation.

Appendix A. Supplementary data

Supplementary data to this article can be found online at <https://doi.org/10.1016/j.jns.2022.120165>.

References

- [1] N.A. Hilken, C.J.J. van Asch, D.J. Werring, et al., Predicting the presence of macrovascular causes in non-traumatic intracerebral haemorrhage: the DIAGRAM prediction score, *J. Neurol. Neurosurg. Psychiatry* 89 (7) (2018) 674–679.
- [2] I.C. Hostettler, D.J. Seiffge, D.J. Werring, Intracerebral hemorrhage: an update on diagnosis and treatment, *Expert. Rev. Neurother.* 19 (7) (2019) 679–694.
- [3] L. Pantoni, Cerebral small vessel disease: from pathogenesis and clinical characteristics to therapeutic challenges, *The Lancet Neurology* 9 (7) (2010) 689–701.
- [4] A. Charidimou, Q. Gang, D.J. Werring, Sporadic cerebral amyloid angiopathy revisited: recent insights into pathophysiology and clinical spectrum, *J. Neurol. Neurosurg. Psychiatry* 83 (2) (2012) 124–137.
- [5] J. Staals, S.D. Makin, F.N. Doubal, et al., Stroke subtype, vascular risk factors, and total MRI brain small-vessel disease burden, *Neurology*. 83 (14) (2014) 1228–1234.
- [6] P. Klarenbeek, R.J. van Oostenbrugge, R.P.W. Rouhl, et al., Ambulatory blood pressure in patients with lacunar stroke, *Stroke* 44 (11) (2013) 2995–2999.
- [7] A. Charidimou, S. Martinez-Ramirez, Y.D. Reijmer, et al., Total magnetic resonance imaging burden of small vessel disease in cerebral amyloid angiopathy, *JAMA Neurology* 73 (8) (2016) 994–998.
- [8] M.A. Rodrigues, N. Samarasekera, C. Lerpiniere, et al., The Edinburgh CT and genetic diagnostic criteria for lobar intracerebral haemorrhage associated with cerebral amyloid angiopathy: model development and diagnostic test accuracy study, *The Lancet Neurology* 17 (3) (2018) 232–240.
- [9] A. Charidimou, D. Wilson, C. Shakeshaft, et al., The Clinical Relevance of Microbleeds in Stroke study (CROMIS-2): rationale, design, and methods, *Int. J. Stroke* 10 (100) (2015) 155–161.
- [10] B. Volbers, D. Staykov, I. Wagner, et al., Semi-automatic volumetric assessment of perihemorrhagic edema with computed tomography, *Eur. J. Neurol.* 18 (11) (2011) 1323–1328.
- [11] A. Charidimou, A. Schmitt, D. Wilson, et al., The Cerebral Haemorrhage Anatomical Rating Instrument (CHARTS): development and assessment of reliability, *J. Neurol. Sci.* 372 (C) (2017) 178–183.
- [12] J.M. Wardlaw, E.E. Smith, G.J. Biessels, Standards for Reporting Vascular changes on neuroimaging (STRIVE v1), et al., Neuroimaging standards for research into small vessel disease and its contribution to ageing and neurodegeneration, *The Lancet Neurology* 12 (8) (2013) 822–838.
- [13] S.M. Gregoire, U.J. Chaudhary, M.M. Brown, et al., The Microbleed Anatomical Rating Scale (MARS): reliability of a tool to map brain microbleeds, *Neurology*. 73 (21) (2009) 1759–1766.
- [14] A. Charidimou, J. Linn, M.W. Vernooij, et al., Cortical superficial siderosis: detection and clinical significance in cerebral amyloid angiopathy and related conditions, *Brain* 138 (8) (2015) 2126–2139.
- [15] F.N. Doubal, A.M.J. MacLulich, K.J. Ferguson, et al., Enlarged perivascular spaces on MRI are a feature of cerebral small vessel disease, *Stroke* 41 (3) (2010) 450–454.
- [16] F. Fazekas, J.B. Chawluk, A. Alavi, et al., MR signal abnormalities at 1.5 T in Alzheimer’s dementia and normal aging, *American Journal of Roentgenology* 149 (2) (1987) 351–356.
- [17] J. Linn, A. Halpin, P. Demaerel, et al., Prevalence of superficial siderosis in patients with cerebral amyloid angiopathy, *Neurology*. 74 (17) (2010) 1346–1350.
- [18] D. Woo, L.R. Sauerbeck, B.M. Kissela, et al., Genetic and environmental risk factors for intracerebral hemorrhage, *Stroke* 33 (5) (2002) 1190–1196.
- [19] A. Charidimou, G. Boulouis, K. Haley, E. Auriel, E.S. van Etten, P. Fotiadis, Y. Reijmer, A. Ayres, A. Vashkevich, Z.Y. Dipucchio, K.M. Schwab, S. Martinez-Ramirez, J. Rosand, A. Viswanathan, S.M. Greenberg, M.E. Gurol, White matter hyperintensity patterns in cerebral amyloid angiopathy and hypertensive arteriopathy, *Neurology*. 86 (6) (2016) 505–511.
- [20] A. Charidimou, G. Boulouis, M. Frosch, et al., The Boston criteria V2.0 for cerebral amyloid angiopathy: updated criteria and multicenter MRI-neuropathology validation. International stroke conference march 2021, Oral Abstract (2021), <https://doi.org/10.1161/str.52.suppl.1.36>.