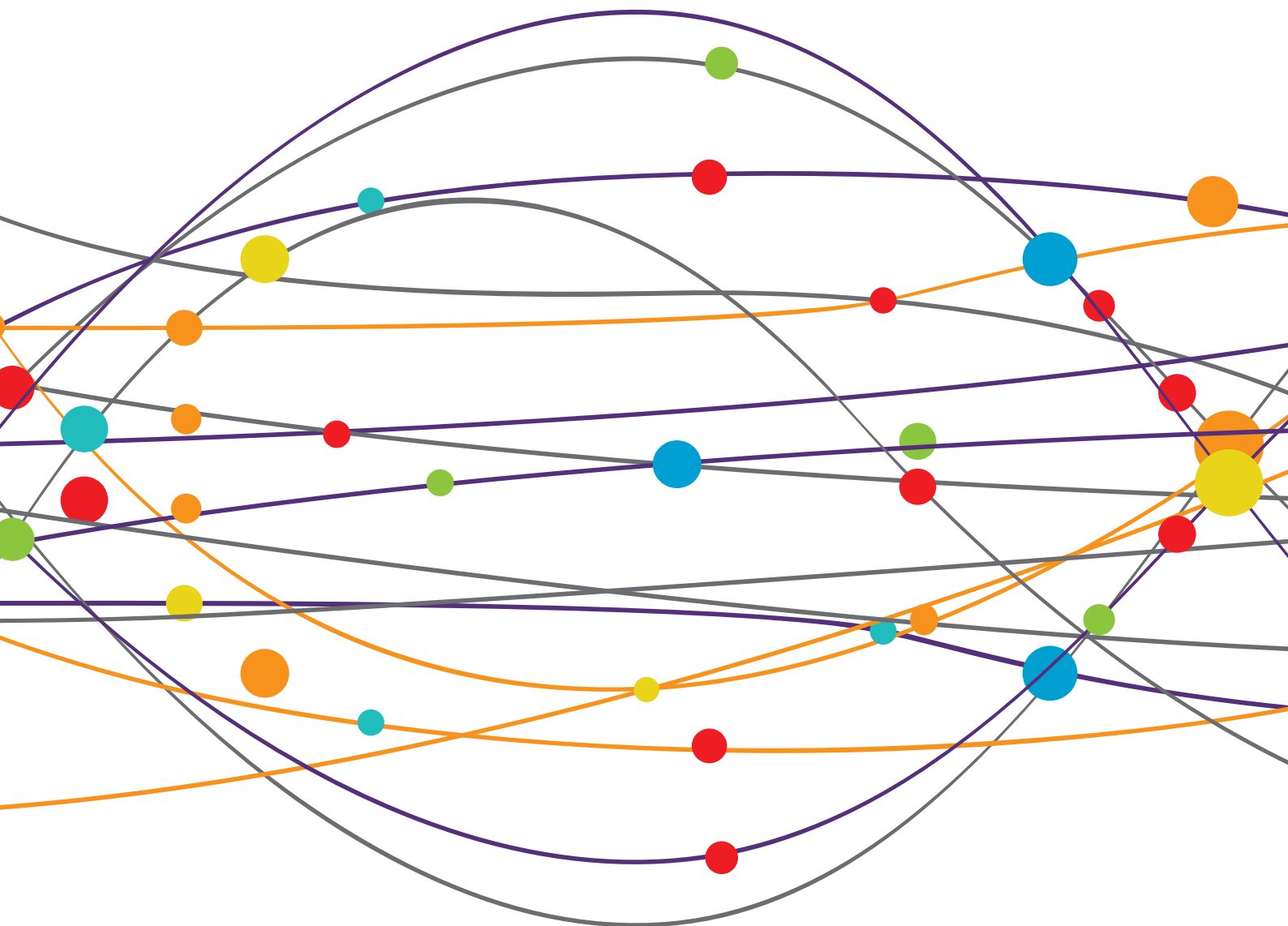


# VISUAL SNOW: OLD PROBLEM, NEW UNDERSTANDING

EDITED BY: Owen B. White, Joanne Fielding, Victoria Susan Pelak and  
Christoph Schankin  
PUBLISHED IN: Frontiers in Neurology





# frontiers

## Frontiers eBook Copyright Statement

The copyright in the text of individual articles in this eBook is the property of their respective authors or their respective institutions or funders. The copyright in graphics and images within each article may be subject to copyright of other parties. In both cases this is subject to a license granted to Frontiers.

The compilation of articles constituting this eBook is the property of Frontiers.

Each article within this eBook, and the eBook itself, are published under the most recent version of the Creative Commons CC-BY licence.

The version current at the date of publication of this eBook is CC-BY 4.0. If the CC-BY licence is updated, the licence granted by Frontiers is automatically updated to the new version.

When exercising any right under the CC-BY licence, Frontiers must be attributed as the original publisher of the article or eBook, as applicable.

Authors have the responsibility of ensuring that any graphics or other materials which are the property of others may be included in the CC-BY licence, but this should be checked before relying on the CC-BY licence to reproduce those materials. Any copyright notices relating to those materials must be complied with.

Copyright and source acknowledgement notices may not be removed and must be displayed in any copy, derivative work or partial copy which includes the elements in question.

All copyright, and all rights therein, are protected by national and international copyright laws. The above represents a summary only. For further information please read Frontiers' Conditions for Website Use and Copyright Statement, and the applicable CC-BY licence.

ISSN 1664-8714

ISBN 978-2-88976-107-4

DOI 10.3389/978-2-88976-107-4

## About Frontiers

Frontiers is more than just an open-access publisher of scholarly articles: it is a pioneering approach to the world of academia, radically improving the way scholarly research is managed. The grand vision of Frontiers is a world where all people have an equal opportunity to seek, share and generate knowledge. Frontiers provides immediate and permanent online open access to all its publications, but this alone is not enough to realize our grand goals.

## Frontiers Journal Series

The Frontiers Journal Series is a multi-tier and interdisciplinary set of open-access, online journals, promising a paradigm shift from the current review, selection and dissemination processes in academic publishing. All Frontiers journals are driven by researchers for researchers; therefore, they constitute a service to the scholarly community. At the same time, the Frontiers Journal Series operates on a revolutionary invention, the tiered publishing system, initially addressing specific communities of scholars, and gradually climbing up to broader public understanding, thus serving the interests of the lay society, too.

## Dedication to Quality

Each Frontiers article is a landmark of the highest quality, thanks to genuinely collaborative interactions between authors and review editors, who include some of the world's best academicians. Research must be certified by peers before entering a stream of knowledge that may eventually reach the public - and shape society; therefore, Frontiers only applies the most rigorous and unbiased reviews. Frontiers revolutionizes research publishing by freely delivering the most outstanding research, evaluated with no bias from both the academic and social point of view. By applying the most advanced information technologies, Frontiers is catapulting scholarly publishing into a new generation.

## What are Frontiers Research Topics?

Frontiers Research Topics are very popular trademarks of the Frontiers Journals Series: they are collections of at least ten articles, all centered on a particular subject. With their unique mix of varied contributions from Original Research to Review Articles, Frontiers Research Topics unify the most influential researchers, the latest key findings and historical advances in a hot research area! Find out more on how to host your own Frontiers Research Topic or contribute to one as an author by contacting the Frontiers Editorial Office: [frontiersin.org/about/contact](http://frontiersin.org/about/contact)

# VISUAL SNOW: OLD PROBLEM, NEW UNDERSTANDING

Topic Editors:

**Owen B. White**, Monash University, Australia

**Joanne Fielding**, Monash University, Australia

**Victoria Susan Pelak**, University of Colorado, United States

**Christoph Schankin**, Bern University Hospital, Switzerland

**Citation:** White, O. B., Fielding, J., Pelak, V. S., Schankin, C., eds. (2022).

Visual Snow: Old Problem, New Understanding. Lausanne: Frontiers Media SA.

doi: 10.3389/978-2-88976-107-4

# Table of Contents

- 04 Editorial: Visual Snow: Old Problem, New Understanding**  
Owen B. White, Joanne Fielding, Victoria Susan Pelak and Christoph J. Schankin
- 07 Magnetic Suppression of Perceptual Accuracy Is Not Reduced in Visual Snow Syndrome**  
Ozan E. Eren, Ruth Ruscheweyh, Veronika Rauschel, Thomas Eggert, Christoph J. Schankin and Andreas Straube
- 12 The Psychiatric Symptomology of Visual Snow Syndrome**  
Emma J. Solly, Meaghan Clough, Paige Foletta, Owen B. White and Joanne Fielding
- 22 Short-Wave Sensitive (“Blue”) Cone Activation Is an Aggravating Factor for Visual Snow Symptoms**  
Jenny L. Hepschke, Paul R. Martin and Clare L. Fraser
- 28 Diagnostic Evaluation of Visual Snow**  
Michael S. Vaphiades, Brendan Grondines, Kasey Cooper, Sean Gratton and Jennifer Doyle
- 33 Delayed Onset of Inhibition of Return in Visual Snow Syndrome**  
Paige J. Foletta, Meaghan Clough, Allison M. McKendrick, Emma J. Solly, Owen B. White and Joanne Fielding
- 41 Widespread White Matter Alterations in Patients With Visual Snow Syndrome**  
Lars Michels, Philipp Stämpfli, Njoud Aldusary, Marco Piccirelli, Patrick Freund, Konrad P. Weber, Fabienne C. Fierz, Spyros Kollias and Ghislaine Traber
- 50 A Study Protocol for an Open-Label Feasibility Treatment Trial of Visual Snow Syndrome With Transcranial Magnetic Stimulation**  
Marissa Grande, Lucas Lattanzio, Isabelle Buard, Allison M. McKendrick, Yu Man Chan and Victoria S. Pelak
- 58 Visual Snow Syndrome as a Network Disorder: A Systematic Review**  
Antonia Klein and Christoph J. Schankin
- 67 Distinct Patterns of P1 and C2 VEP Potentiation and Attenuation in Visual Snow: A Case Report**  
Alison M. Harris
- 76 Case Report: Transformation of Visual Snow Syndrome From Episodic to Chronic Associated With Acute Cerebellar Infarct**  
Francesca Puledda, María Dolores Villar-Martinez and Peter J. Goadsby



# Editorial: Visual Snow: Old Problem, New Understanding

Owen B. White<sup>1\*</sup>, Joanne Fielding<sup>1</sup>, Victoria Susan Pelak<sup>2</sup> and Christoph J. Schankin<sup>3</sup>

<sup>1</sup> Central Clinical School, Faculty of Medicine, Nursing and Health Sciences, Monash University, Melbourne, VIC, Australia,

<sup>2</sup> School of Medicine, University of Colorado, Aurora, CO, United States, <sup>3</sup> Department of Neurology, Inselspital, Bern University Hospital, University of Bern, Bern, Switzerland

**Keywords:** Visual snow syndrome, sensory perception, sensorimotor interaction, functional image analysis, central processing

## Editorial on the Research Topic

### Visual Snow: Old Problem, New Understanding

Visual snow syndrome (VSS) is a well known disturbance of visual perception. It has been misdiagnosed over the years as either being an untreatable form of migraine or, conversely, a manifestation of psychological disturbance. It was eventually recognized as a separate entity in 1995 (1) and was subsequently codified as a syndrome in a series of papers from 2012 to 2014 (2–5), and expanded on as part of a more widespread disturbance of sensory processing on the basis of its association with numerous other sensory disturbances (6, 7). It is described as a very rare entity (8) and yet recent studies have suggested that it may affect as much as 2.2% of the community (9).

VSS is a clinical diagnosis with the main criterion of persistent pan-field “TV-snow” or “pixilation,” extending beyond 3 months, in conjunction with two of either photophobia, enhanced entoptic phenomena (e.g., blue field phenomena, floaters), palinopsia, or nyctalopia (4, 5). Numerous other non-visual or even non-perceptual symptoms have been identified, including migraine, tinnitus, vestibular disturbance (consistent with persistent perceptual postural disorder), fibromyalgia, migratory paresthesia, and endogenous perceptual phenomena such as depersonalization and derealization (6, 7, 10).

Recent work has demonstrated both structural (11–15) and physiological/functional signatures of the disorder (16–18) (Foletta et al.; Solly et al.), confirming this as a separate disorder from migraine and, in conjunction with the above quoted studies, introduces the concept of impaired central processing as a new group of disorders deserving of study, as well as providing a means for study.

Thus, the recent interest in visual snow has enfranchised a group of patients previously mislabeled as neurotic or having untreatable migraine. It has also provided a means for evaluating potential treatment strategies, permitting trials going forward.

This Research Topic of Frontiers in Neurology, Section Neuro-Ophthalmology is focused on the current advances in the field of visual snow research. It demonstrates the progress made in clinical, paraclinical, and experimental aspects with the ultimate aim to reduce symptoms and improve quality of life in these patients.

Currently, it is still difficult to determine what drives patients to develop VSS later in life or early during childhood. In early studies, eye examinations were in general normal (1, 5) but it has remained unclear how much ophthalmic examination is necessary. The retrospective study from this Research Topic reviewed detailed ophthalmology exams in 52 patients and revealed that patients presenting with typical VSS may not need more than the standard neuro-ophthalmologic examination and automated perimetry (Vaphiades et al.). From the beginning, it has been suggested that VSS might be a migrainous phenomenon, essentially driven by the comorbidity and the

## OPEN ACCESS

### Edited and reviewed by:

Aki Kawasaki,  
Hôpital Ophtalmique  
Jules-Gonin, Switzerland

### \*Correspondence:

Owen B. White  
owen.white@monash.edu

### Specialty section:

This article was submitted to  
Neuro-Ophthalmology,  
a section of the journal  
Frontiers in Neurology

Received: 27 February 2022

Accepted: 14 March 2022

Published: 15 April 2022

### Citation:

White OB, Fielding J, Pelak VS and  
Schankin CJ (2022) Editorial: Visual  
Snow: Old Problem, New  
Understanding.  
Front. Neurol. 13:884752.  
doi: 10.3389/fneur.2022.884752

more severe presentation in patients who have both (5, 19). The pathophysiological link has been investigated by Eren et al. who, in an electrophysiological study, assessed magnetic suppression of perceptual accuracy, which is reduced in patients with migraine with aura and chronic migraine (19). In patients with VSS, this is not the case, suggesting that occipital cortex inhibition is not affected, and that the mechanisms of VSS and migraine with aura are different. In contrast, a predisposition to VSS might exist for patients with episodic visual snow as nicely shown in the case report by Puledda et al. (20). In this manuscript, a 44-year-old man had an acute stroke in the right superior cerebellar artery territory and immediately developed all the symptoms of VSS. Prior to the stroke, he had the same symptoms in an episodic manner about once per month. This means that episodic visual snow might not be so uncommon (21) and may be a risk factor for VSS. This is important for counseling patients with episodic visual snow.

Another focus of this Research Topic was brain physiology in VSS. Harris et al. analyzed double-pulse visual evoked potentials (VEPs) and found a differential pattern of VEP attenuation and potentiation in one patient suggesting that multiple mechanisms of neuronal responsiveness to visual stimulation might exist in VSS. In a psychophysical experiment, attention was investigated by Foletta et al., who assessed eye movements toward and away from target stimuli using an “inhibition of return” paradigm. This study raises the potential for a distinct saccadic behavioral profile in VSS that might serve as a biomarker for VSS for future therapeutic studies, and suggests that attention is impacted in VSS.

From a neuroimaging perspective, Michels et al. investigated the white matter in VSS. They found widespread alterations in prefrontal, temporal, and occipital areas, supporting the fact that atypical visual processing and conceptualization might be an important mechanism in this disorder. Taken together, VSS might be regarded as a particular form of network disorder as carved out in a systematic review by Klein and Schankin (7). The authors presented and combined what is known from clinical, neurophysiological, functional, and structural imaging in visual and extra-visual areas. They conclude that VSS is a network disorder with key structures in pre-cortical and attentional networks, where filtering and prioritizing might happen.

Despite all these advances in our clinical and pathophysiological understanding of VSS, therapy remains a substantial challenge. Against this background, Solly et al. profiled patients with VSS in respect of psychiatric and neuropsychological symptoms with a focus on depression, anxiety, depersonalization, sleep, fatigue, and quality of life. Although VSS is clearly not a psychiatric disorder, patients with VSS show high rates of psychiatric symptoms and a reduction of quality of life (Solly et al.). For clinical practice, this is highly important. Currently, we cannot offer evidence-based treatment for the key visual symptoms of VSS. However, the psychiatric comorbidities can be identified and addressed

specifically with the aim of increasing overall quality of life in our patients. Another important therapeutic option is non-pharmacological. Hepschke et al. (22) applied intuitive colorimetry in a psychophysical experiment. They found that VSS discomfort exacerbates with short-wave (i.e., “blue”) cone activation, which is important for two reasons. First, the koniocellular pathway might be affected in VSS; and second, intuitive colorimetry starting in the blue filter area should be offered to patients with the aim of reducing visual discomfort. Although symptomatic therapy and consideration of psychiatric comorbidity is important, etiological treatment will be the ultimate goal in VSS research. Also in this Research Topic, Grande et al. published a promising protocol for an open-label pilot trial for a 10-day treatment protocol for VSS with transcranial magnetic stimulation. The authors report some of the burdens associated with TMS treatment protocols, including the need for multiple consecutive treatment days and the current COVID-19 pandemic. Outcome measures being used include psychophysical perceptual measures, previously investigated in VSS by McKendrick et al. (23), that include assessment of center-surround contrast suppression and luminance increment thresholds in noise. Results of the TMS protocol are expected in the next year.

In the last decade, the establishment of clinical criteria for VSS has taken the disorder out of the area of psychiatric or psychological disease, as shown in this Research Topic, and set the stage for a rapid growth in research in many domains of neurology and neurosciences that might 1 day lead to a better understanding of and treatment for VSS and other disorders with similar underlying “network” mechanisms. Our previous nodal concept of cerebral function is inadequate to explain the brain’s function. We need to move away from the Charcot-based evaluation of cerebral function, recognizing that it represents no more than 10% of cerebral circuits, and look at more in-depth studies. We must reorientate toward a concept of interactive networks which are neither sensory nor motor but are in fact sensorimotor. There are afferent components, efferent components, and central processing, about which we have much to learn but for which we have sufficient tools to make a start. Visual snow syndrome is a condition where we can start to gain these insights, and it will be exciting to go along with the development of this field in the coming years.

## AUTHOR CONTRIBUTIONS

OW was responsible for setting up the introduction to the editorial and subsequent combination of all author contributions. JF and VP reviewed articles for the Research Topics and reviewed the manuscript. CS reviewed articles for the Research Topics, reviewed the manuscript, and substantially modified the initial concept of the editorial. All authors contributed to the article and approved the submitted version.

## REFERENCES

- Liu GT, Schatz NJ, Galetta SL, Volpe NJ, Skobieranda F, Kosmorsky GS, et al. Persistent positive visual phenomena in migraine. *Neurology*. (1995) 45:664–8. doi: 10.1212/WNL.45.4.664
- Schankin CJ, Goadsby PJ. Visual snow—persistent positive visual phenomenon distinct from migraine aura. *Curr Pain Headache R*. (2015) 19:23. doi: 10.1007/s11916-015-0497-9
- Schankin C, Maniyar F, Hoffmann J, Chou D, Goadsby P. Visual snow: a new disease entity distinct from migraine aura. *Neurology*. (2012) 78:S36.006. doi: 10.1212/WNL.78.1\_MeetingAbstracts.S36.006
- Schankin CJ, Maniyar FH, Goadsby PJ. Field-testing the criteria for visual snow (positive persistent visual disturbance). *Headache*. (2012) 14:1. doi: 10.1186/1129-2377-14-S1-P132
- Schankin CJ, Maniyar FH, Digre KB, Goadsby PJ. ‘Visual snow’—a disorder distinct from persistent migraine aura. *Brain*. (2014) 137:1419–28. doi: 10.1093/brain/awu050
- White OB, Clough M, McKendrick AM, Fielding J. Visual snow: visual misperception. *J Neuroophthalmol*. 38:1–521. doi: 10.1097/WNO.0000000000000702
- Klein A, Schankin CJ. Visual snow syndrome, the spectrum of perceptual disorders, and migraine as a common risk factor: a narrative review. *Headache J Head Face Pain*. (2021) 61:1306–13. doi: 10.1111/head.14213
- IHS. The International Classification of Headache Disorders, 3rd edition (beta version). *Cephalalgia*. (2013) 33:629–808. doi: 10.1177/0333102413485658
- Kondziella D, Olsen MH, Dreier JP. Prevalence of visual snow syndrome in the UK. *Eur J Neurol*. (2020) 27:764–72. doi: 10.1111/ene.14150
- Lauschke JL, Plant GT, Fraser CL. Visual snow: a thalamocortical dysrhythmia of the visual pathway? *J Clin Neurosci*. (2016) 28:123–7. doi: 10.1016/j.jocn.2015.12.001
- Aldusary N, Traber GL, Freund P, Fierz FC, Weber KP, Baeshen A, et al. Abnormal connectivity and brain structure in patients with visual snow. *Front Hum Neurosci*. (2020) 14:582031. doi: 10.3389/fnhum.2020.582031
- Chen WT, Lin YY, Fuh JL, Hämäläinen MS, Ko YC, Wang SJ. Sustained visual cortex hyperexcitability in migraine with persistent visual aura. *Brain*. (2011) 134:2387–95. doi: 10.1093/brain/awr157
- Jäger HR, Giffin NJ, Goadsby PJ. Diffusion- and perfusion-weighted MR imaging in persistent migrainous visual disturbances. *Cephalalgia*. (2005) 25:323–32. doi: 10.1111/j.1468-2982.2004.00858.x
- Latini F, Fahlström M, Marklund N, Feresiadou A. White matter abnormalities in a patient with visual snow syndrome: new evidence from a diffusion tensor imaging study. *Eur J Neurol*. (2021) 28:2789–93. doi: 10.1111/ene.14903
- Puledda F, O’Daly O, Schankin C, Ffytche D, Williams SC, Goadsby PJ. Disrupted connectivity within visual, attentional and salience networks in the visual snow syndrome. *Hum Brain Mapp*. (2021) 2021:1–13. doi: 10.1002/hbm.25343
- Solly EJ, Clough M, McKendrick AM, Foletta P, White OB, Fielding J. Ocular motor measures of visual processing changes in visual snow syndrome. *Neurology*. (2020) 95:e1784–91. doi: 10.1212/WNL.00000000000010372
- Solly EJ, Clough M, McKendrick AM, Foletta P, White OB, Fielding J. Eye movement characteristics provide an objective measure of visual processing changes in patients with visual snow syndrome. *Sci Rep-UK*. (2021) 11:9607. doi: 10.1038/s41598-021-88788-2
- McKendrick AM, Badcock DR. Contrast-processing dysfunction in both magnocellular and parvocellular pathways in migraineurs with or without aura. *Invest Ophthalmol Vis Sci*. (2003) 44:442–8. doi: 10.1167/iovs.02-0630
- Schankin CJ, Maniyar FH, Sprenger T, Chou DE, Eller M, Goadsby PJ. The relation between migraine, typical migraine aura and “visual snow”. *Headache*. (2014) 54:957–66. doi: 10.1111/head.12378
- Puledda F, Schankin C, Goadsby PJ. Visual snow syndrome: a clinical and phenotypical description of 1,100 cases. *Neurology*. (2020) 94:e564–74. doi: 10.1212/WNL.00000000000008909
- Hodak J, Fischer U, Bassetti CLA, Schankin CJ. Episodic visual snow associated with migraine attacks. *JAMA Neurol*. (2020) 77:392–3. doi: 10.1001/jamaneurol.2019.4050
- Hepschke JL, Seymour RA, He W, Etschell A, Sowman PF, Fraser CL. Cortical oscillatory dysrhythmias in visual snow syndrome: a magnetoencephalography study. *Brain Commun*. (2021) 4:fcab296. doi: 10.1101/2021.05.17.444460
- McKendrick AM, Chan YM, Tien M, Millist L, Clough M, Mack H, et al. Behavioral measures of cortical hyperexcitability assessed in people who experience visual snow. *Neurology*. (2017) 88:1243–9. doi: 10.1212/WNL.0000000000003784

**Conflict of Interest:** The authors declare that the research was conducted in the absence of any commercial or financial relationships that could be construed as a potential conflict of interest.

**Publisher’s Note:** All claims expressed in this article are solely those of the authors and do not necessarily represent those of their affiliated organizations, or those of the publisher, the editors and the reviewers. Any product that may be evaluated in this article, or claim that may be made by its manufacturer, is not guaranteed or endorsed by the publisher.

Copyright © 2022 White, Fielding, Pelak and Schankin. This is an open-access article distributed under the terms of the Creative Commons Attribution License (CC BY). The use, distribution or reproduction in other forums is permitted, provided the original author(s) and the copyright owner(s) are credited and that the original publication in this journal is cited, in accordance with accepted academic practice. No use, distribution or reproduction is permitted which does not comply with these terms.



# Magnetic Suppression of Perceptual Accuracy Is Not Reduced in Visual Snow Syndrome

Ozan E. Eren<sup>1\*</sup>, Ruth Ruscheweyh<sup>1</sup>, Veronika Rauschel<sup>1</sup>, Thomas Eggert<sup>1</sup>,  
Christoph J. Schankin<sup>1,2†</sup> and Andreas Straube<sup>1†</sup>

<sup>1</sup> Department of Neurology, Ludwig Maximilians University of Munich, University Hospital - Großhadern, Munich, Germany,

<sup>2</sup> Department of Neurology, Inselspital, Bern University Hospital, University of Bern, Bern, Switzerland

## OPEN ACCESS

### Edited by:

Valerie Purvin,  
Midwest Eye Institute, United States

### Reviewed by:

Gianluca Coppola,  
Sapienza University of Rome, Italy  
Simona Maccora,  
University of Palermo, Italy

### \*Correspondence:

Ozan E. Eren  
ozan.eren@med.uni-muenchen.de

<sup>†</sup>These authors have contributed  
equally to this work

### Specialty section:

This article was submitted to  
Neuro-Ophthalmology,  
a section of the journal  
Frontiers in Neurology

**Received:** 26 January 2021

**Accepted:** 15 March 2021

**Published:** 04 May 2021

### Citation:

Eren OE, Ruscheweyh R, Rauschel V,  
Eggert T, Schankin CJ and Straube A  
(2021) Magnetic Suppression of  
Perceptual Accuracy Is Not Reduced  
in Visual Snow Syndrome.  
*Front. Neurol.* 12:658857.  
doi: 10.3389/fneur.2021.658857

**Objective:** Patients with visual snow syndrome (VSS) suffer from continuous (“TV snow-like”) visual disturbance of unknown pathoetiology. In VSS, changes in cortical excitability in the primary visual cortex and the visual association cortex are discussed, with recent imaging studies tending to point to higher-order visual areas. Migraine, especially migraine with aura, is a common comorbidity. In chronic migraine and episodic migraine with aura but not in episodic migraine without aura, a reduced magnetic suppression of perceptual accuracy (MSPA) reflects a probably reduced inhibition of the primary visual cortex. Here we investigated the inhibition of the primary visual cortex using MSPA in patients with VSS, comparing that with MSPA in controls matched for episodic migraine.

**Methods:** Seventeen patients with VSS were compared to 17 age- and migraine-matched controls. Visual accuracy was assessed by letter recognition and modulated by transcranial magnetic stimulation delivered to the occipital cortex at different intervals with respect to the letter presentation (40, 100, and 190 ms).

**Results:** Suppression of visual accuracy at the 100-ms interval was present without significant differences between VSS patients and age- and migraine-matched controls (percentage of correctly recognized trigrams, control:  $46.4 \pm 34.3$ ; VSS:  $52.5 \pm 25.4$ ,  $p = 0.56$ ).

**Conclusions:** In contrast to migraine with aura, occipital cortex inhibition, as assessed with MSPA, may not be affected in VSS.

**Keywords:** visual snow syndrome, cortical hyperexcitability, magnetic suppression of perceptual accuracy, migraine, pathophysiology

## INTRODUCTION

Patients with visual snow (VS) describe continuous, mostly black and white tiny flickering dots in their entire visual field, comparable to the old TV-static noise when missing the analog signal. When accompanied by other visual symptoms such as afterimages (palinopsia), impaired night vision (nyctalopia), or increased light sensitivity (photophobia), it is called visual snow syndrome (VSS) (1–3). Its pathophysiology is still under discussion, and although it is highly associated with migraine with and without aura and may partially overlap with these, recent research strongly suggests that VS is a distinct disorder (2–5). The visual disturbance sums up to a clinical picture that



is best explained by dysfunction of the higher-order visual cortex. Consistently, fluorodeoxyglucose-positron emission tomography (PET) investigations showed hypermetabolism in the lingual gyrus, an area of the higher visual association cortex (3, 6). Importantly, these findings from functional neuroimaging were confirmed by voxel-based morphometry by two independent groups which demonstrated increased gray matter volume in the same cortical area (6, 7). A possible neurophysiological correlate of the involvement of higher visual areas could be the significantly prolonged latency of the late N145 potentials with normal P100 potentials in visual evoked potentials (4). However, the picture is likely more complex with studies pointing to a dysfunction of the primary visual cortex, considering thalamocortical dysrhythmia as the origin of VSS (8, 9) and demonstrating alterations also in non-visual, acoustic, and limbic areas (6).

Here we used magnetic suppression of perceptual accuracy (MSPA) to further elucidate the role of the primary visual cortex or at least its inhibition in VSS. Reduced MSPA reflects reduced inhibition of the primary visual cortex, which is seen in chronic migraine and episodic migraine with aura, but not in episodic migraine without aura (10). Reduced MSPA in VSS would therefore argue for a decreased local inhibition of the primary visual cortex similar to episodic migraine with aura.

## MATERIALS AND METHODS

The study was conducted in accordance with the Declaration of Helsinki and approved by the local ethics committee (227-15). All patients gave written informed consent. The results of the study were presented in preliminary format at the International Headache Conference 2017 (11).

### Subjects

For recruitment, the study was advertised in social media with support from the self-help group on VS, “Eye on Vision Foundation” (<http://www.eyeonvision.org/>). We first assessed the eligibility of interested patients during telephone interviews conducted by a headache specialist familiar with VSS. The interview was cross-checked by a second headache specialist. Inclusion criteria were age  $\geq 18$  years and presence of VSS (subtype black and white dots) in accordance with the criteria published previously (2). Exclusion criterion was intake of any illicit drugs currently or within 2 weeks prior to the onset of VSS. Brain MRI was normal in all subjects. Later, the VSS patients were examined at presentation by one of the two mentioned specialists. Of medications known to possibly affect cortical excitability, only one patient was on lamotrigine and three patients were on mirtazapine. Travel expenses were reimbursed, and no further payment was made for study participation. Patients with VSS were compared to age- and migraine-matched subjects.

### Measurement of MSPA

MSPA was measured according to our previous work (10). To summarize, three-letter sequences (so-called trigrams) were presented for 30 ms on a monitor in front of the subjects. They

were instructed to read the letters aloud from left to right. In a first step, training runs were performed to adjust contrast in a manner that  $\sim 80\%$  of the letters could be recognized correctly by the subject without transcranial magnetic stimulation (TMS) intervention. In a second step, the experiment was started by presenting a series of 54 trigrams, followed each by a TMS pulse (output of at least 70% of the possible maximum output, Magstim 200, The MagStim Company Ltd, Whitland, UK) via a 90-mm circular coil to the occipital cortex in randomized intervals of 40, 100, or 190 ms in regard to the trigram presentation. The time between the start of trigram presentation and TMS pulse delivery is called stimulus onset asynchrony (SOA). Later, the percentage of correctly recognized trigrams was calculated for each SOA interval. All subjects were measured interictally; as corroborated by telephone contact, no subject reported a migraine attack or aura within 2 days after the experiment.

### Statistical Analysis

Statistical analysis was done using SPSS 25 (IBM Corp. Released 2017. IBM SPSS Statistics for Windows, version 25.0.0.1, 32-bit-version, Armonk, NY: IBM Corp.). Statistical significance was assumed at  $p \leq 0.05$ . The demographics of the groups were compared using chi-square test.

ANOVA was used for MSPA comparison (within-subject factor: SOA, between-subject factor: group). Where ANOVA was significant ( $p \leq 0.05$ ), *t*-test with Bonferroni correction was used for *post hoc* analysis.

### Data Availability Statement

Anonymized data will be shared at request from any qualified investigator.

## RESULTS

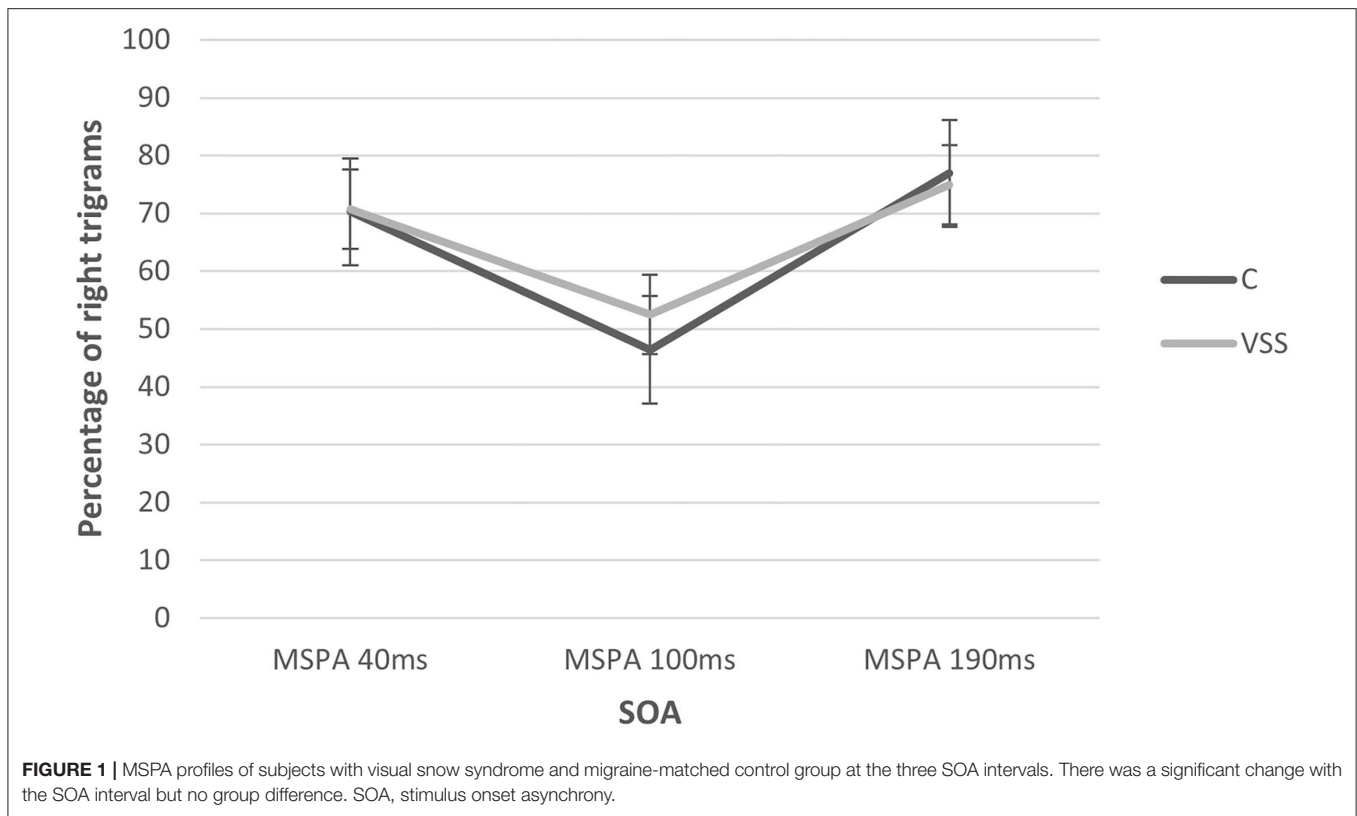
### Subjects

Seventeen patients with visual snow syndrome (six females and 11 males; mean age,  $30.0 \pm 10.8$  years; 12 with comorbid migraine, seven of them also with typical migraine aura) were compared to 17 control subjects (C) (14 females and three males; mean age,  $28.3 \pm 8.2$  years; 12 with comorbid migraine, none of them with typical migraine aura). The groups did differ in gender ( $\chi = 7.77$   $p = 0.005$ ) and aura ( $\chi = 8.82$   $p = 0.003$ ), but not in migraine ( $\chi = 0$ ,  $p = 1$ ) and age  $\chi = 16.87$ ,  $p = 0.66$ . For more information on study population, see the **Supplementary Table 1**. If not stated otherwise, the term “controls” describes the group of age- and migraine-matched subjects.

### MSPA

The MSPA profiles of patients with VSS and migraine-matched controls can be seen in **Figure 1** and **Table 1**.

There was a significant main effect of SOA interval (rmANOVA: Greenhouse–Geisser  $F 31.75$ ,  $p \leq 0.01$ ) with a significant suppression of visual accuracy at 100 ms compared to 40 and 190 ms. There was no significant main effect of group (rmANOVA:  $F 0.70$ ,  $p = 0.47$ ). Additionally, we



**TABLE 1** | Mean percentage of correctly detected trigrams at the three different stimulus onset asynchrony (SOA) intervals (40, 100 and 190 ms).

SOA	Average percentage correct (mean ± SD)	
	Visual snow syndrome	Control
40 ms	70.70 ± 14.88	70.26 ± 26.53
100 ms	52.51 ± 25.41	46.40 ± 34.26
190 ms	74.95 ± 10.08	76.91 ± 22.62

performed an explorative subgroup analysis beginning with comparing the same control group only with VSS patients without migraine aura, showing almost identical percentages of correctly recognized trigrams at 100 ms (C:  $46.40 \pm 34.26$  vs. VSS:  $46.67 \pm 27.99$ ), again without significant group differences (rmANOVA:  $F 0.261, p = 0.77$ ).

Afterwards, to understand the effect of aura in our VSS group itself, we compared VSS patients with migraine with aura (VSSMwA;  $n = 7$ ) and VSS patients with migraine without aura (VSSMwoA;  $n = 5$ ). There was again a significant main effect of SOA interval (rmANOVA: Greenhouse–Geisser  $F 6.31, p \leq 0.05$ ) with a significant suppression of visual accuracy at 100 ms (VSSMwoA:  $48.2 \pm 31.89$  vs. VSSMwA:  $60.85 \pm 20.21$ ) compared to 40 and 190 ms, but also no significant main effect of group (rmANOVA:  $F 0.40, p = 0.57$ ).

## DISCUSSION

The main result of this study is that magnetic suppression of perceptual accuracy is not reduced in visual snow syndrome when compared to controls matched for migraine. In this respect, VSS differs from migraine with aura (12). The significant suppression at 100 ms is comparable instead to that of patients with migraine without aura and controls without migraine (10). Previous work of Aurora and Mulleners showed that healthy controls exhibited the largest suppression at 100 ms SOA, followed by migraine patients without aura, while chronic migraine patients and episodic migraineurs with aura showed the least suppression (12, 13). Consistently, within the VSS group, subjects with migraine with aura showed a smaller MSPA compared to those without aura. However, the difference was not significant, maybe due to the small sample sizes in the subgroups.

It has been discussed that a reduced MSPA reflects a higher cortical excitability due to a deficiency of intracortical inhibition of the primary visual cortex (12). This would facilitate the initiation of cortical spreading depression, resulting in an attack of migraine with visual aura, but apparently playing a minor role in migraineurs without aura (10, 14).

Visual snow syndrome is thought to involve cortical hyperexcitability or a lack of inhibition. The present results suggest that, at least for our collective, such hyperexcitability does not seem to arise from the primary visual cortex. From the clinical description, the typical visual phenomena seem to be best explained by a dysfunction of higher-order visual cortex.

This is supported by overlapping morphological and functional correlates in the visual association cortex in PET and MRI (3, 6) as well as alterations in the late visual evoked potentials (4).

## LIMITATIONS

One limitation of the study is the lack of matching for gender, but to the best of our knowledge, there is no evidence of sex differences in MSPA. Nevertheless, an influence cannot be excluded. Another limitation is the lack of matching for aura, but based on our explorative subgroup analysis irrespective of inclusion or exclusion of the aura patients in the VSS group, the results remained unchanged. Additionally, it should be mentioned that, in the VSS group, the disability caused by headache measured by Migraine Disability Assessment was lower compared to the migraine-matched controls, as we matched for comorbidity and not severity. Lastly, we could have added a healthy control group without comorbid migraine and give more details on clinical data.

## CONCLUSION

This study demonstrates that magnetic suppression of perceptual accuracy, in contrast to the situation in migraine with aura, is not reduced in VSS compared to migraine-matched controls. Therefore, although hyperexcitability apparently occurs in both VSS and migraine aura, the locations seem to be different. The primary visual cortex might not be the main location in VSS.

## DATA AVAILABILITY STATEMENT

The raw data supporting the conclusions of this article will be made available by the authors, without undue reservation.

## REFERENCES

- Bessero AC, Plant GT. Should “visual snow” and persistence of after-images be recognised as a new visual syndrome? *J Neurol Neurosurg Psychiatry*. (2014) 85:1057–8. doi: 10.1136/jnnp-2013-306827
- Schankin C, Maniyar FH, Digre KB, Goadsby PJ. “Visual snow” - a disorder distinct from persistent migraine aura. *Brain*. (2014) 137:1419–28. doi: 10.1093/brain/awu050
- Schankin C, Maniyar F, Sprenger T, Chou DE, Eller M, Goadsby PJ. The relation between migraine, typical migraine aura and visual snow (TM). *Headache*. (2014) 54:8. doi: 10.1111/head.12378
- Eren O, Rauschel V, Ruscheweyh R, Straube A, Schankin CJ. Evidence of dysfunction in the visual association cortex in visual snow syndrome. *Ann Neurol*. (2018) 84:946–9. doi: 10.1002/ana.25372
- Puledda F, Schankin C, Digre K, Goadsby P. Visual snow syndrome: what we know so far. *Curr Opin Neurol*. (2018) 31:52–8. doi: 10.1097/WCO.0000000000000523
- Schankin CJ, Maniyar FH, Chou DE, Eller M, Sprenger T, Goadsby PJ. Structural and functional footprint of visual snow syndrome. *Brain*. (2020) 143:1106–13. doi: 10.1093/brain/awaa053
- Aldusary N, Traber GL, Freund P, Fierz FC, Weber KP, Baeshen A, et al. Abnormal connectivity and brain structure in patients with visual snow. *Front Hum Neurosci*. (2020) 14:31. doi: 10.3389/fnhum.2020.582031
- Lauschke JL, Plant GT, Fraser CL. Visual snow: a thalamocortical dysrhythmia of the visual pathway? *J Clin Neurosci*. (2016) 28:123–7. doi: 10.1016/j.jocn.2015.12.001
- Unal-Cevik I, Yildiz FG. Visual snow in migraine with aura: further characterization by brain imaging, electrophysiology, and treatment – case report. *Headache*. (2015) 55:1436–41. doi: 10.1111/head.12628
- Rauschel V, Ruscheweyh R, Eggert T, Straube A. Magnetic suppression of perceptual accuracy is not reduced in episodic migraine without aura. *J Headache Pain*. (2014) 15:83. doi: 10.1186/1129-2377-15-83
- Eren O, Rauschel V, Ruscheweyh R, Straube A, Schankin C. Visual snow syndrome is associated with reduced amplitudes and lack of habituation of visual evoked potentials independent from comorbid migraine. *Cephalalgia*. (2017) 225–6. doi: 10.1177/0333102417719590
- Mulleners WM, Chronicle EP, Palmer JE, Koehler PJ, Vredeveld JW. Suppression of perception in migraine: evidence for reduced inhibition in the visual cortex. *Neurology*. (2001) 56:178–83. doi: 10.1212/WNL.56.2.178
- Aurora SK, Barrodale P, Chronicle EP, Mulleners WM. Cortical inhibition is reduced in chronic and episodic migraine and demonstrates a spectrum of illness. *Headache*. (2005) 45:546–52. doi: 10.1111/j.1526-4610.2005.05108.x
- Charles AC, Baca SM. Cortical spreading depression and migraine. *Nat Rev Neurol*. (2013) 9:637–44. doi: 10.1038/nrneurol.2013.192

## ETHICS STATEMENT

The studies involving human participants were reviewed and approved by Ludwig Maximilians University Munich (227-15). The patients/participants provided their written informed consent to participate in this study.

## AUTHOR CONTRIBUTIONS

AS, CS, OE, RR, TE, and VR contributed to the conception and design of the study. CS, OE, RR, and VR contributed to the acquisition and analysis of data. AS, CS, and OE contributed to the drafting of a significant portion of the manuscript. All authors contributed to the article and approved the submitted version.

## FUNDING

This study received funding from Deutsche Migräne- und Kopfschmerzgesellschaft ([www.dmkg.de](http://www.dmkg.de)), Eye on Vision Foundation ([www.eyevision.org](http://www.eyevision.org)), Baasch Medicus Foundation, and Friedrich-Baur Foundation. This study was supported by the self-help group for visual snow (Eye On Vision Foundation) by communicating the study to the patients.

## ACKNOWLEDGMENTS

We thank all the patients who have taken part in the study.

## SUPPLEMENTARY MATERIAL

The Supplementary Material for this article can be found online at: <https://www.frontiersin.org/articles/10.3389/fneur.2021.658857/full#supplementary-material>

**Conflict of Interest:** OE reports grants from Friedrich-Baur Foundation, Deutsche Migräne- und Kopfschmerzgesellschaft during the conduct of the study and

Novartis outside the submitted work. RR reports personal fees and/or other from Allergan, Novartis, Teva Pharmaceuticals, Hormosan outside the submitted work. CS reports grants from Deutsche Migräne- und Kopfschmerzgesellschaft, Eye on Vision Foundation, and Baasch Medicus Foundation during the conduct of the study, personal fees from Novartis, Eli Lilly, Allergan, Almirall, Amgen, MindMed, and Grünenthal, and personal fees and other from Teva Pharmaceuticals outside the submitted work. AS reports personal fees from Allergan, Bayer, Sanofi, Desitin, Electrocore, Eli Lilly, and Teva Pharmaceuticals and grants from the German Research Council, Kröner-Fresenius Foundation, Ludwig-Maximilian University, and Friedrich-Baur Foundation outside the submitted work.

The remaining authors declare that the research was conducted in the absence of any commercial or financial relationships that could be construed as a potential conflict of interest.

*Copyright © 2021 Eren, Ruscheweyh, Rauschel, Eggert, Schankin and Straube. This is an open-access article distributed under the terms of the Creative Commons Attribution License (CC BY). The use, distribution or reproduction in other forums is permitted, provided the original author(s) and the copyright owner(s) are credited and that the original publication in this journal is cited, in accordance with accepted academic practice. No use, distribution or reproduction is permitted which does not comply with these terms.*



# The Psychiatric Symptomology of Visual Snow Syndrome

Emma J. Solly<sup>1†</sup>, Meaghan Clough<sup>1†</sup>, Paige Foletta<sup>1†</sup>, Owen B. White<sup>1,2†</sup> and Joanne Fielding<sup>1,2\*†</sup>

<sup>1</sup> Department of Neuroscience, Central Clinical School, Monash University, Melbourne, VIC, Australia, <sup>2</sup> Department of Neurology, Alfred Health, Melbourne, VIC, Australia

## OPEN ACCESS

### Edited by:

Heather E. Moss,  
Stanford University, United States

### Reviewed by:

Michael S. Vaphiades,  
University of Alabama at Birmingham,  
United States  
Silvia Colnaghi,  
University of Pavia, Italy

### \*Correspondence:

Joanne Fielding  
joanne.fielding@monash.edu

### †ORCID:

Emma J. Solly  
[orcid.org/0000-0002-5241-6572](https://orcid.org/0000-0002-5241-6572)  
Meaghan Clough  
[orcid.org/0000-0001-5962-3681](https://orcid.org/0000-0001-5962-3681)  
Paige Foletta  
[orcid.org/0000-0003-2093-2801](https://orcid.org/0000-0003-2093-2801)  
Owen B. White  
[orcid.org/0000-0002-2836-7344](https://orcid.org/0000-0002-2836-7344)  
Joanne Fielding  
[orcid.org/0000-0002-1131-0587](https://orcid.org/0000-0002-1131-0587)

### Specialty section:

This article was submitted to  
Neuro-Ophthalmology,  
a section of the journal  
Frontiers in Neurology

**Received:** 30 April 2021

**Accepted:** 28 June 2021

**Published:** 30 July 2021

### Citation:

Solly EJ, Clough M, Foletta P,  
White OB and Fielding J (2021) The  
Psychiatric Symptomology of Visual  
Snow Syndrome.  
*Front. Neurol.* 12:703006.  
doi: 10.3389/fneur.2021.703006

**Objective:** To characterise the psychiatric symptoms of visual snow syndrome (VSS), and determine their relationship to quality of life and severity of visual symptoms.

**Methods:** One hundred twenty-five patients with VSS completed a battery of questionnaires assessing depression/anxiety, dissociative experiences (depersonalisation), sleep quality, fatigue, and quality of life, as well as a structured clinical interview about their visual and sensory symptoms.

**Results:** VSS patients showed high rates of anxiety and depression, depersonalisation, fatigue, and poor sleep, which significantly impacted quality of life. Further, psychiatric symptoms, particularly depersonalisation, were related to increased severity of visual symptoms. The severity/frequency of psychiatric symptoms did not differ significantly due to the presence of migraine, patient sex, or timing of VSS onset (lifelong vs. later onset).

**Conclusion:** Psychiatric symptoms are highly prevalent in patients with VSS and are associated with increased visual symptom severity and reduced quality of life. Importantly, patients with lifelong VSS reported lower levels of distress and milder self-ratings of visual symptoms compared to patients with a later onset, while being equally likely to experience psychiatric symptoms. This suggests that the psychiatric symptoms of VSS are not solely due to distress caused by visual symptoms. While no consistently effective treatments are available for the visual symptomology of VSS, psychiatric symptoms offer an avenue of treatment that is likely to significantly improve patient quality of life and ability to cope with visual symptoms.

**Keywords:** visual snow syndrome, visual snow, depersonalisation, visual processing, sensory processing

## INTRODUCTION

Visual snow syndrome (VSS) is a neurological disorder characterised by a range of persistent visual disturbances. Its defining symptom is visual snow (VS), described as constant, flickering static across the entire visual field. Diagnosis of VSS requires the presence of VS for >3 months, alongside at least two of the following visual symptoms: palinopsia, enhanced entoptic phenomena, photophobia, and impaired night vision (nyctalopia) (1). For ~40% of patients, the visual disturbances associated with VSS have been present from their earliest memories; the remainder of patients experience a sudden or stepwise onset of symptoms, generally in the second or third decade of life. Symptom onset may be related to a migraine attack, but typically cannot be linked to a clear trigger (2, 3).

VSS often presents with a number of comorbidities, most commonly migraine and tinnitus (2, 4), but also other sensory symptoms, including paraesthesia and dizziness (5, 6). Notably, a range of psychiatric symptoms are consistently reported in VSS patients; these include depression and anxiety, (2, 3, 5), as well as fatigue, sleep disturbances (7, 8), and depersonalisation, a dissociative experience involving a sense of estrangement from the body (9). Irritability and difficulty concentrating are also frequent complaints (3). It is currently unclear how these psychiatric symptoms relate to each other or to the visual symptoms of the disorder, and ultimately how they impact quality of life. Since there is no cure or effective treatments available for the visual symptoms of VSS (10), management of psychiatric symptoms offers a viable means to alleviate the burden of VSS and improve patient quality of life.

Here, we comprehensively characterised the psychiatric symptomatology of VSS in a large cohort of patients, using a combination of validated questionnaires and a structured interview. Specifically, we investigated the frequency of psychiatric symptoms and assessed their relationships to each other as well as to visual symptoms. In addition, we evaluated whether psychiatric symptom severity differed as a function of migraine status, onset of visual snow, and sex. Finally, we explored the impact of psychiatric symptoms on the frequency and severity of visual symptoms and their relative contribution to quality of life. The results of this research will provide important information for health professionals who encounter patients with VSS, and help identify treatment options allowing more effective management of the disorder.

## METHODS

### Participant Recruitment

Participants with VSS were recruited primarily through online, radio, and television advertising, with a number of patients also referred by neurologists. Patients who had not been diagnosed with VSS by a neurologist were screened using an online questionnaire to confirm that they met the diagnostic criteria for VSS as specified by the International Classification of Headache Disorders (ICHD) (1). The questionnaire enquired about the onset and characteristics of the participant's VS, other visual symptoms the participant experienced, and whether they had ever undergone ophthalmological or imaging examinations regarding their VS.

Participants also were asked if they had been diagnosed with other ophthalmological, neurological, or psychiatric conditions, to exclude those with potentially confounding disorders. To exclude patients with Hallucinogen Persisting Perception Disorder (HPPD), which can present very similarly to VSS (11), participants were asked about illicit drug use. Those who reported illicit drug use in the 12 months preceding VSS symptom onset were considered possible HPPD patients and were not included in the study.

Forty-one healthy controls were recruited from the community through researcher social circles. Control data were used to determine normative ranges for the Short-Form 36 Health Survey global score and subscales, as clinical cut-off

scores were not available. Exclusion criteria were a diagnosis of a confounding psychiatric, neurological, or ophthalmological condition. The mean age of controls was 27.2 (SD = 8.7): 15 (36.6%) male, and 26 (63.4%) female.

### Standard Protocol Approvals, Registrations, and Patient Consents

Ethics approval was granted by the Monash University Human Research Ethics Committee. All participants provided written informed consent prior to participation in the study in accordance with the declaration of Helsinki.

### Measures

Participants completed a battery of online questionnaires relating to psychiatric symptomatology and health-related quality of life. Standard methods for calculating scores and cut-offs for questionnaires were used unless otherwise indicated. In addition, VSS patients provided clinical information regarding age of VSS onset, VS symptom severity, presence of other symptoms (both visual and non-visual), and other relevant health information.

### VSS Clinical Information

VS symptom severity was determined using a figure displaying varying intensities of "static." Based on this figure, patients rated their VS intensity on a scale of 1–6, with 1 referring to the lowest intensity image and 6 to the highest intensity image. Patients also rated how disruptive they considered their VS to be on a scale from 1 ("Not at all disruptive") to 7 ("Severely disruptive"), and how much they felt that VS has impacted their life on a scale from 1 ("No impact") to 7 ("Severely reduced quality of life"). Further, they were given the option to list factors that improved or worsened their VS, and any life activities that were directly impacted by their visual symptoms.

A checklist of visual and non-visual symptoms commonly reported with VSS was provided to patients who were asked to nominate which symptoms, if any, they experienced. For symptoms patients may not be familiar with, such as depersonalisation and derealization, definitions were provided. Depersonalisation was defined as "feelings of being detached or disconnected from your body," and derealization as "feelings that your surroundings or the people around you are not real." Finally, patients reported whether they had ever been diagnosed with an anxiety or depressive disorder. Demographic and symptom information for VSS patients is presented in **Table 1**.

### Depression Anxiety Stress Scale

The Depression Anxiety Stress Scale (DASS) is a commonly used measure of anxiety and depression (12) assessing self-reported negative emotions over the immediately preceding week. It consists of three scales: depression, anxiety, and stress, with higher scores reflecting higher levels of each symptom. Standard score ranges were used, as recommended by the DASS manual. Depression: Normal (0–9), Mild (10–13), Moderate (14–20), Severe (21–27), Extremely severe (28+). Anxiety: Normal (0–7), Mild (8–9), Moderate (10–14), Severe (15–19), Extremely severe

**TABLE 1** | Demographic information and symptom prevalence.

	VSS patients (n = 125)	
	Number	Percentage
Age (mean, SD)	31.3, 10.4	–
Female (male)	63 (62)	50.4% (49.6%)
Lifelong VSS	45	36%
Later onset VSS:	80	64%
Age of onset (mean, SD)	22.4, 9.8	–
VSS duration (mean, SD)	9.7, 9.9	–
VSS intensity (mean, SD)	3.7, 1.3	–
VSS disruptiveness (mean, SD)	3.6, 1.6	–
VSS impact on quality of life (mean, SD)	3.7, 1.7	–
Migraine	61	48.8%
Family history of migraine	66	52.8%
Relative with VSS	5	4%
<b>Visual symptoms</b>		
Palinopsia: afterimages	108	86.4%
Palinopsia: trailing	66	52.8%
Nyctalopia	88	70.4%
Photophobia	58	46.4%
Floaters	113	90.4%
Blue field entoptic phenomena	91	72.8%
Halos	83	66.4%
Number of visual symptoms (mean, SD)	5.4, 1.8	–
<b>Non-visual sensory symptoms</b>		
Tinnitus	97	77.6%
Tremor	43	34.4%
Paraesthesia	59	47.2%
Dizziness	44	35.2%
<b>Other symptoms</b>		
Neck pain	63	50.4%
Irritability	70	56%
Concentration problems	99	79.2%
Depersonalisation	45	44.1%
Derealization	31	30.4%
Previous or current anxiety disorder	56	44.8%
Previous or current depressive disorder	48	38.4%

(20+). Stress: Normal (0–14), Mild (15–18), Moderate (19–25), Severe (26–33), Extremely severe (34+).

### Cambridge Depersonalisation Scale

The CDS measures self-reported experiences of depersonalisation over the previous 6 months (13). Higher scores indicate more frequent and severe depersonalisation, scores above 70 indicating clinical levels of depersonalisation (13).

### The Pittsburgh Sleep Quality Index

The PSQI is a questionnaire assessing sleep quality over the past month (14). It consists of 7 subscales, each with a score range of 0–3: sleep quality, sleep latency, sleep duration, habitual sleep efficacy, sleep disturbances, use of sleeping medication, and daytime dysfunction. A global score ranging from 0 to 21 is

also generated, with higher scores indicating poorer sleep. In the general population a global cut-off score of >5 is normally used, however in this study a more conservative cut-off score of >8 was chosen, as this has been suggested to be more appropriate in clinical populations (15).

### The Fatigue Severity Scale

The FSS assesses the impact of fatigue on day to day functioning (16). It is a nine item self-report questionnaire requiring participants to respond on a scale of 1–7, with higher scores indicating higher levels of fatigue. Scores from each item were summed to form a total score ranging from 7 to 63. A cut-off score of >36 was used, equivalent to the cut-off score recommended by the original authors (16).

### The Short-Form 36 Health Survey Version 2

The SF-36 is a commonly used measure of health-related quality of life comprising 8 subscales: physical functioning, role limitations due to physical problems, social functioning, bodily pain, mental health, role limitations due to emotional problems, vitality, and general health perceptions (17). Subscale scores are transformed to a scale from 0 to 100, with 0 representing the lowest possible score and 100 representing the maximum possible score. Higher scores indicate better health. A global score for the SF-36 was calculated to provide an overall indication of health-related quality of life, by summing the 8 raw subscale scores and similarly transforming to a 0–100 scale.

### Data Analysis

Data were analysed using SPSS statistics 27. Group means, standard deviations (SD), and the percentage of patients with scores falling above/below cut-offs were calculated for all questionnaires. Where published cut off scores were not available (SF-36 subscales and global score) control data were used by converting scores to z-scores based on the formula; (patient raw score – control population mean)/control population SD. For the SF-36, a z-score of –1.96 or below was considered indicative of significantly ( $p < 0.05$ ) poor health relative to normative population scores. Z-scores were not calculated for the Pittsburgh Sleep Quality Index subscales due to the limited range of values for each subscale (0–3).

Where >25% of VSS patients scored outside defined normative cut-offs, analyses used independent samples *t*-test to determine whether psychiatric symptom severity differed due to the presence of migraine, patient sex, onset of symptoms (lifelong vs. later onset), or presence of depersonalisation. Chi square analyses were used to assess the likelihood of visual and non-visual symptoms occurring in each group. Relationships among questionnaire scores, number of visual symptoms, and VS self-ratings were examined using Pearson correlations, or Spearman correlations where appropriate. A backwards stepwise linear regression was run to assess the contributions of questionnaire scores to health-related quality of life (overall SF-36 score), and

**TABLE 2** | Questionnaire results.

	Mean (SD)	Scores above cut-off (%)
<b>Depression Anxiety Stress scale</b>		
Depression	13.1 (10.9)	–
Anxiety	9.5 (8.4)	–
Stress	14 (9.6)	–
<b>Cambridge Depersonalisation Scale</b>	47.9 (41.1)	34 (27.2%)
<b>The Pittsburgh Sleep Quality Index</b>		
Global score	8.6 (3.7)	56 (44.8%)
Subjective sleep quality	1.3 (0.7)	–
Sleep latency	2 (1)	–
Sleep duration	0.8 (0.9)	–
Sleep efficiency	1.7 (1.4)	–
Sleep disturbances	1.4 (0.6)	–
Sleep medication	0.7 (1.1)	–
Daytime dysfunction	0.8 (0.9)	–
<b>Fatigue Severity Scale</b>	35.3 (15.1)	62 (49.6%)

**TABLE 3** | Short-Form 36 health survey results.

Subscale	Mean (SD)	Significantly low scores (%)
Global score	58.8 (16.1)	52 (41.6%)
Physical functioning	83 (21.9)	16 (12.8%)
Role: physical	67.9 (32.9)	47 (37.6%)
Role: emotional	48.4 (24.5)	41 (32.8%)
Bodily pain	48.2 (8.3)	3 (2.4%)
General health	52.9 (22)	31 (24.8%)
Vitality	36.2 (20.2)	31 (24.8%)
Social functioning	59.3 (29.2)	36 (28.8%)
Mental health	55.4 (20.2)	52 (41.6%)

to VS intensity and the number of visual symptoms. An alpha-level of  $p < 0.05$  was used to determine significance. Adjustments were not made for multiple comparisons.

## RESULTS

Demographic information and prevalence of visual and non-visual symptoms in VSS patients are presented in **Table 1**.

Questionnaire results (mean scores, SDs, number and percentage of patient scores falling above specified cut-offs) are presented in **Table 2**, with SF-36 results presented separately in **Table 3**. The number and percentage of patients in each DASS score range are displayed in **Figure 1**.

### Sub-group Comparisons Migraine

Psychiatric questionnaire scores did not differ between patients with and without migraine.

A higher number of visual symptoms was reported by patients with migraine (Mean = 5.9, SD = 1.7), relative to those without

(Mean = 4.8, SD = 1.7),  $t_{(123)} = -3.6$ ,  $p < 0.001$ ,  $d = 0.1$ , 95% CI (-1.68, -0.49).

Patients with migraine were more likely to report photophobia [ $X^2_{(1,N=125)} = 7.63$ ,  $p = 0.006$ ], and palinopsia (visual trailing) [ $X^2_{(1,N=125)} = 5.93$ ,  $p = 0.015$ ]. The prevalence of other visual and non-visual symptoms did not differ.

### Sex

Women exhibited higher levels of fatigue (FSS scores) than men (Mean = 39, SD = 14.2; Mean = 31.6, SD = 15.4),  $t_{(123)} = -2.8$ ,  $p = 0.006$ ,  $d = 0.5$ , 95% CI (-12.59, -2.12).

Women also rated the intensity of their VS as more severe (Mean = 3.94, SD = 1.13) than men (Mean = 3.42, SD = 1.35),  $t_{(123)} = -2.3$ ,  $p = 0.022$ ,  $d = 0.4$ , 95% CI (-0.96, 0.07). The prevalence of visual and non-visual symptoms did not differ.

### VSS Onset

Psychiatric questionnaire scores did not differ between lifelong and later onset VSS patients.

Later onset VSS patients rated their VS as being more disruptive than lifelong VSS patients (Mean = 3.9, SD = 1.5; Mean = 3, SD = 1.5),  $t_{(123)} = 3.18$ ,  $p = 0.002$ ,  $d = 0.6$ , 95% CI (0.34, 1.44), with a greater impact on their quality of life (Mean = 4.13, SD = 1.69) than lifelong VSS patients (Mean = 2.82, SD = 1.53),  $t_{(123)} = 4.27$ ,  $p < 0.001$ ,  $d = 0.8$ , 95% CI (0.69, 1.91).

Lifelong VSS patients were less likely to report palinopsia (visual trailing),  $X^2_{(1,N=125)} = 4.62$ ,  $p = 0.032$ . The prevalence of other visual and non-visual symptoms did not differ.

### Tinnitus

Psychiatric questionnaire scores did not differ between patients with and without migraine.

Patients with tinnitus reported a higher number of visual symptoms (Mean = 5.7, SD = 1.6), than those without tinnitus (Mean = 4.3, SD = 1.8),  $t_{(123)} = 0.33$ ,  $p < 0.001$ ,  $d = 0.8$ , 95% CI (-2.15, -0.75), and rated their VS as being more disruptive (Mean = 3.8, SD = 1.6), than those without (Mean = 2.9, SD = 1.3),  $t_{(123)} = -2.62$ ,  $p \leq 0.010$ ,  $d = 0.6$ , 95% CI (-1.5, -0.21).

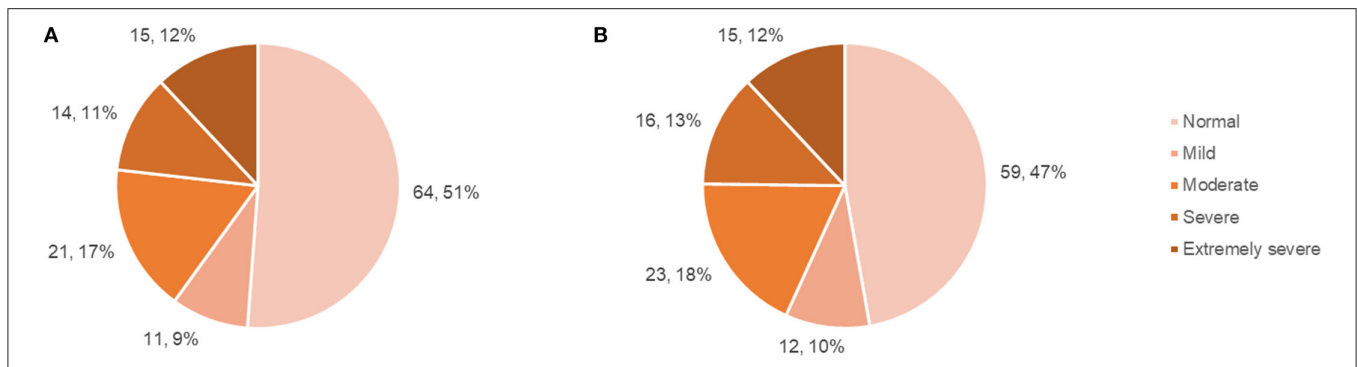
VSS patients with tinnitus were more likely to experience palinopsia (afterimages) [ $X^2_{(1,N=125)} = 10.56$ ,  $p = 0.001$ ], floaters [ $X^2_{(1,N=125)} = 14.96$ ,  $p < 0.001$ ], and Blue Field Entoptic Phenomena (BFEP) [ $X^2_{(1,N=125)} = 9.47$ ,  $p = 0.002$ ]. They also reported paraesthesia [ $X^2_{(1,N=125)} = 23.23$ ,  $p < 0.001$ ], tremor [ $X^2_{(1,N=125)} = 6.47$ ,  $p = 0.011$ ], concentration problems [ $X^2_{(1,N=125)} = 4.87$ ,  $p = 0.027$ ], and neck pain [ $X^2_{(1,N=125)} = 6.89$ ,  $p = 0.009$ ], more often than patients without tinnitus.

Correlations between questionnaire scores, the number of visual symptoms, and self-ratings of VSS severity are presented in **Table 4**.

### Relationship Between Psychiatric and Visual Symptoms

To estimate the proportion of variance in health-related quality of life (as estimated by the SF-36) that can be accounted for by fatigue (FSS), sleep (PSQI), depression (DASS: Depression), anxiety (DASS: Anxiety), and depersonalisation (CDS), we





**FIGURE 1 |** Patient DASS anxiety and depression subscale scores. **(A)** Number and percentage of patients falling within each DASS: anxiety score range. **(B)** Number and percentage of patients falling within each DASS: depression score range.

**TABLE 4 |** Correlations between variables.

	SF-36: Global	FSS	PSQI: Global	DASS: Depression	DASS: Anxiety	CDS	No. visual symptoms	VS Intensity	VS disruptiveness	VS impact on QoL
SF-36: Global	–	–0.484 (<0.001)	–0.373 (<0.001)	–0.619 (<0.001)	–0.653 (<0.001)	–0.559 (<0.001)	–0.117 (0.194)	–0.151 (0.092)	–0.204 (0.023)	–0.304 (<0.001)
FSS	–0.484 (<0.001)	–	0.164 (0.067)	0.276 (0.002)	0.299 (<0.001)	0.371 (<0.001)	0.270 (0.002)	0.125 (0.165)	0.186 (0.038)	0.217 (0.015)
PSQI: Global	–0.373 (<0.001)	0.164 (0.067)	–	0.265 (0.003)	0.446 (<0.001)	0.290 (<0.001)	0.130 (0.148)	–0.014 (0.874)	0.008 (0.932)	0.017 (0.852)
DASS: depression	–0.619 (<0.001)	0.276 (0.002)	0.265 (0.003)	–	0.596 (<0.001)	0.488 (<0.001)	–0.021 (0.815)	0.005 (0.957)	0.068 (0.450)	0.187 (0.036)
DASS: Anxiety	–0.653 (<0.001)	0.299 (<0.001)	0.446 (<0.001)	0.596 (<0.001)	–	0.473 (<0.001)	0.177 (0.048)	0.069 (0.442)	0.190 (0.034)	0.305 (<0.001)
CDS	–0.559 (<0.001)	0.371 (<0.001)	0.290 (<0.001)	0.488 (<0.001)	0.473 (<0.001)	–	0.256 (0.004)	0.288 (<0.001)	0.222 (0.013)	0.284 (0.001)
No. visual symptoms	–0.117 (0.194)	0.270 (0.002)	0.130 (0.148)	–0.021 (0.815)	0.177 (0.048)	0.256 (0.004)	–	0.209 (0.019)	0.455 (<0.001)	0.343 (<0.001)
VS Intensity	–0.151 (0.092)	0.125 (0.165)	–0.014 (0.874)	0.005 (0.957)	0.069 (0.442)	0.288 (<0.001)	0.209 (0.019)	–	0.496 (<0.001)	0.283 (0.001)
VS disruptiveness	–0.204 (0.023)	0.186 (0.038)	0.008 (0.932)	0.068 (0.450)	0.190 (0.034)	0.222 (0.013)	0.455 (<0.001)	0.496 (<0.001)	–	0.725 (0.001)
VS impact on QoL	–0.304 (<0.001)	0.217 (0.015)	0.017 (0.852)	0.187 (0.036)	0.305 (<0.001)	0.284 (0.001)	0.343 (<0.001)	0.283 (0.001)	0.725 (0.001)	–

Correlation coefficient (p-value). Bold, significant.

SF-36, Short Form 36 Health Survey; FSS, Fatigue Severity Scale; PSQI, Pittsburgh Sleep Quality Index; DASS, Depression Anxiety Stress Scale; CDS, Cambridge Depersonalisation Scale; VS, Visual snow; QoL, quality of life.

performed a multiple regression analysis using the stepwise backward elimination method. In combination, these variables accounted for a significant 60% of the variability in overall health-related quality of life (SF-36),  $R^2 = 0.6$ , adjusted  $R^2 = 0.59$ ,  $F_{(5,120)} = 45.49$ ,  $p < 0.001$ . Unstandardised ( $B$ ) and standardised ( $\beta$ ) regression coefficients for each predictor in the regression model are reported in **Table 5**.

Further multiple regression analyses using the stepwise backward elimination method were performed to determine the proportion of variance in the number of visual symptoms, and self-reported VS intensity, that can be accounted for by the same variables. In combination, these variables, excluding the PSQI which was again non-significant, accounted for 18% of the variability in the number of visual symptoms,  $R^2 = 0.18$ ,

adjusted  $R^2 = 1.5$ ,  $F_{(5,119)} = 6.42$ ,  $p < 0.001$ . Unstandardised ( $B$ ) and standardised ( $\beta$ ) regression coefficients for each predictor in the regression model are reported in **Table 6**. Depression and depersonalisation accounted for 12% of the variability in VS intensity,  $R^2 = 0.12$ , adjusted  $R^2 = 0.12$ ,  $F_{(5,119)} = 8.58$ ,  $p < 0.001$ , with the remaining variables non-significant. Unstandardised ( $B$ ) and standardised ( $\beta$ ) regression coefficients for each predictor in the regression model are reported in **Table 6**.

### Patient Experiences of Visual Snow Factors That Worsened Visual Snow

Patients identified environmental and individual factors that worsened their VS. The most common environmental factors were dim or low-light conditions, harsh artificial light, bright

**TABLE 5** | Quality of life regression analysis summary.

Variable	B (95% CI)	$\beta$	t	p
FSS	-0.26 (-0.39, -0.13)	-0.24	-3.87	<0.001
PSQI: Global	-	-	-	-
DASS: Depression	-0.39 (-0.61, -0.17)	-0.27	-3.49	<0.001
DASS: Anxiety	-0.65 (-0.94, -0.37)	-0.34	-4.55	<0.001
CDS	0.07 (-0.13, 0.02)	-0.18	-2.57	0.011

FSS, Fatigue severity scale; PSQI, Pittsburgh Sleep Quality Inventory; DASS, Depression Anxiety Stress Scale; CDS, Cambridge Depersonalisation Scale.

**TABLE 6** | Visual symptoms regression analysis summaries.

Variable	B (95% CI)	$\beta$	t	p
<b>Number of visual symptoms</b>				
FSS	0.24 (0, 0.05)	0.21	2.35	0.021
PSQI: Global	-	-	-	-
DASS: Depression	-0.53 (-0.08, -0.02)	-0.33	-3.07	0.003
DASS: Anxiety	0.06 (0.13, 0.1)	0.27	2.54	0.012
CDS	0.01 (0, 0.02)	0.2	1.99	0.049
<b>VS intensity</b>				
FSS	-	-	-	-
PSQI: Global	-	-	-	-
DASS: Depression	-0.02 (-0.05, 0)	-0.21	-2.15	0.034
DASS: Anxiety	-	-	-	-
CDS	0.01 (0.01, 0.02)	0.4	4.14	<0.001

FSS, Fatigue Severity Scale; PSQI, Pittsburgh Sleep Quality Inventory; DASS, Depression Anxiety Stress Scale; CDS, Cambridge Depersonalisation Scale.

sunlight, and darkness. The most common individual factors were tiredness/fatigue, stress/anxiety, alcohol consumption, inadequate sleep, exercise, caffeine, and screen use. Other factors mentioned less commonly included migraine, poor diet, dehydration, illness, menstruation, and illicit drug use (historically).

### Factors That Improved Visual Snow

Most of the factors listed as improving VS were individual, with the most common, improving sleep, followed by “accepting” or learning to ignore symptoms (“looking through them rather than at them”), and improving diet. Other factors mentioned less commonly included altering ambient lighting, practising meditation or mindfulness, improving general mood, reducing stress/anxiety, and regular exercise. The patients who listed exercise as helpful clarified that exercise may intensify VS during physical activity, but led to improved perception of symptoms in the longer term. Patients frequently reported wearing sunglasses to reduce light sensitivity. Two patients reported wearing coloured lenses to reduce the perception of visual symptoms (5), and 2 reported that focusing on videos of static found online for 2–3 min decreased their VS significantly for ~30 s, although it did not provide long-lasting benefits.

### Activities Impacted by Visual Snow

The most common activity impacted by VS was driving, with patients often specifying that driving at night/in the dark was

difficult or impossible. Some patients elaborated on this, citing difficulty reading road signs, oncoming headlights being “too bright,” and afterimages of car lights and streetlights interfering with vision.

Patients also reported difficulty reading, with many adding that they avoided reading unless necessary. Issues using screens were also common, with one patient responding that he quit his career due to being unable to work on computers all day as required.

Other activities mentioned as impacted included social activities or sports which take place in bright daylight, going out at night, physical activity due to the temporary exacerbation of symptoms, and being able to enjoy natural scenery or stargazing. A number of patients simply replied broadly that their work, study, or social life were affected.

## DISCUSSION

VSS remains a poorly understood disorder, with even less known about the frequently co-occurring psychiatric symptomatology. Given the difficulty in treating the visual symptomatology of VSS (10), understanding how psychiatric symptoms manifest and relate to the visual symptoms of the disorder offers avenues of treatment that may significantly improve quality of life for patients. Here we characterise the psychiatric symptoms most commonly reported by VSS patients, and their relationship with

visual symptoms and quality of life (QoL). Our results show that patients with VSS more frequently exhibit clinically significant levels of depression, anxiety, depersonalisation, fatigue, and higher incidences of poor sleep, which significantly impact their QoL. Further, these psychiatric symptoms are related to more severe visual symptomology, with depersonalisation in particular consistently associated with more severe self-ratings of VS. Interestingly, the timing of VSS onset (lifelong vs. later onset), presence of migraine, and patient sex were not found to significantly impact the severity of psychiatric symptoms.

## Depression and Anxiety

Consistent with previous reports (3, 5, 8), a significant proportion of patients exhibited high levels of anxiety and depression, and poor overall mental health (SF-36: mental health subscale). DASS results indicated that 25% of patients exhibited either severe or extremely severe levels of depression, with a similar number exhibiting severe or extremely severe anxiety. Anxiety and depression scores were found to relate significantly to perceived VS severity. As with other neurological disorders, these symptoms might be assumed to reflect distress relating to the symptoms themselves, or may be linked to neurobiological changes underlying the specific disorder (18, 19). The impact of VSS visual symptomology on patient QoL can be profound, and is likely to contribute to higher levels of anxiety and depression. Key life activities including driving, reading, and screen use may be impacted, which frequently lead to difficulties with work and study; some patients stated that they changed employment or elected not to pursue further education as a result of their VSS. Social functioning also appears to be affected, with almost 30% of patients reporting significantly low scores on the SF-36 social functioning subscale. Social and recreational activities may be impacted by VSS in a number of ways: exercise, alcohol consumption, and bright or low-light conditions may temporarily exacerbate symptoms, resulting in avoidance of activities involving those factors. Some patients also reported that anxiety associated with visual symptoms affected their ability to leave their home.

In addition to the distressing nature and impact of their visual symptoms, there are many other factors influencing mental health. As VSS is still not widely recognised or understood, many patients struggle to find a diagnosis or explanation for their symptoms. Patients are often told that their symptoms are psychogenic, or presumed to be malingering (5, 20). Some patients involved in this study relayed having fears pre-diagnosis that they might have unidentified brain cancer, or that their visual symptoms would continue to progressively worsen until they became blind. Even following a diagnosis of VSS, most patients experience little if any relief from the few currently available treatments (10). These factors likely contribute to the prevalence of anxiety and depression in VSS patients.

However, our results indicate that anxiety and depression in VSS patients are not necessarily secondary to their disabling sensory symptoms, but may be, at least partially, inherent to the disorder. We anticipated that patients with lifelong VSS would report lower levels of anxiety and depression than patients with an onset later in life, given that for them, VS is “normal”;

indeed, many lifelong patients report not realising their vision was abnormal until adulthood. In support of this, lifelong VSS patients rated their VS as being less disruptive and impacting their quality of life significantly less than patients with a later onset of symptoms. Yet despite being subjectively less concerned by their symptoms, lifelong VSS patients reported equal levels of depression and anxiety with later onset patients. The two groups also did not differ in sleep quality, level of fatigue, experiences of depersonalisation, or overall health-related quality of life. This suggests that the negative impact of VSS on mental health, sleep, and energy level is not solely attributable to distress caused by its symptoms.

## Sleep and Fatigue

Sleep difficulties have not been previously reported in VSS, however they were a frequent complaint among our cohort, and over 40% of patients exhibited sleep scale (PSQI) scores indicative of sleep dysfunction. Anecdotally, our VSS patients often reported difficulty sleeping due to the distracting and prominent nature of their visual symptoms in the dark, which are present with the eyes open or closed. We found that sleep difficulties were not limited to increased time to fall asleep (sleep latency), but also included high rates of sleep disturbances, poor sleep quality, and low sleep efficiency. As sleep reliably shows a bidirectional relationship with anxiety and depression (21), poor sleep may both contribute to and be influenced by poor mental health. Indeed, poor sleep was linked with higher rates of depression and anxiety. Given that many patients cited poor sleep as an aggravating factor for VS, addressing sleep difficulties in patients may lead to improvement in both mental health and the tolerability of visual symptoms.

Fatigue and lethargy have been previously reported in multiple VSS cohorts (3, 7). Interestingly, we did not find a significant relationship between sleep quality (PSQI) and level of fatigue (FSS), suggesting that the high levels of fatigue reported by VSS patients were not solely a consequence of poor sleep. Fatigue is highly prevalent in other neurological disorders, including migraine (22, 23), where it has been linked with more severe migraine symptomology and a greater level of impairment (22). Our results suggest a similar association in VSS, with increased levels of fatigue associated with a higher number of visual symptoms, and poorer self-ratings of VS severity. However, it remains unclear whether fatigue occurs as a consequence of coping with constant sensory dysfunction, whether patients with higher levels of fatigue are less able to ignore their visual symptoms and thus perceive them as worse, or whether fatigue is linked directly to the pathophysiology of VSS.

## Depersonalisation

Depersonalisation (CDS) scores showed the most consistent relationship with the number of visual symptoms and patient ratings of VS severity. CDS scores were also found to contribute significantly to VS intensity and the number of symptoms experienced. Depersonalisation refers to subjective feelings of detachment from the physical body and mental processes, and may involve a diminished sense of agency or feelings of being “robotic” (24). Temporary experiences of depersonalisation

are common in the general population, but when they are recurrent and distressing a diagnosis of depersonalisation-derealization disorder may be considered (9). Nearly 45% of VSS patients in this study reported having experienced depersonalisation, and over 25% showed scores above the scale cut-off indicating a possible depersonalisation disorder. This suggests that depersonalisation is not only common in VSS, but is severe in a significant number of patients. Derealization, a dissociative experience characterised by a sense that the surrounding world is unreal or artificial (24), was also reported by ~30% patients. Derealization frequently co-occurs with depersonalisation; it is unclear whether they are truly distinct dissociative experiences, or whether derealization may represent a subtype of depersonalisation (25).

High rates of depersonalisation have been reported previously in patients with vestibular dysfunction (26, 27), retinal disease (28), and chronic dizziness (29). Here it has been theorised that feelings of depersonalisation may be evoked by a discrepancy between expected sensory input (provided by the frame of experience) and actual (aberrant) sensory experience (28); or, alternatively, by a discrepancy between signals from different sensory systems due to one or more being disrupted (30). A coherent perception of the body and surrounding space requires the seamless integration of inputs from different sensory modalities; conceivably, disturbance of this integration may lead to a disrupted awareness of the self (30). As depersonalisation and derealization are not well-known as symptoms, or as a disorder, patients may lack the language to describe their experiences, or may not realise what they are experiencing is a defined psychological symptom. Health professionals may therefore need to describe these experiences to a patient to ascertain whether they have experienced them.

## Pathophysiology of VSS

Although it is unclear whether poorer mental health and difficulties with sleep and fatigue are primary VSS symptoms, or secondary to sensory dysfunction, a shared underlying cause is plausible. The pathophysiology of VSS remains unknown, but is theorised to involve a central disturbance in the processing of sensory information (3, 5, 20). In our previous studies investigating ocular motor performance in VSS patients (6), we identified attentional changes hypothesised to be consistent with disrupted thalamocortical (TC) communication, potentially a thalamocortical dysrhythmia (3, 5). With the exception of the olfactory system, all sensory input passes through the thalamus, which regulates the incoming flow of sensory information to the cortex (31, 32). The thalamus and cortex are highly interconnected through recurring feedback loops. TC circuits are characterised by state-dependent resonant oscillatory activity, which modulates thalamic and cortical functioning (33). The oscillatory activity of TC networks is crucial not only for the processing and integration of sensory information, but also for attention, cognition, and arousal level (34, 35). As such, alteration in the oscillatory activity of TC networks may conceivably underlie the range of sensory and non-sensory symptoms reported by VSS patients, including disrupted sleep and fatigue.

Evidence also exists that dissociative experiences may involve abnormal TC network activity (36).

Thalamocortical dysrhythmia (TCD) is a form of aberrant TC oscillatory activity proposed to underlie a number of neurological and psychiatric disorders including migraine, tinnitus, and depression (37–40). In TC networks, different behavioural states are characterised by specific forms of oscillatory activity (34). TCD involves a pathological increase in low-frequency theta waves during states of wakefulness, coupled with surrounding high-frequency gamma waves (37, 40). These oscillatory changes result in disruption to normal state-dependent communication between the thalamus and cortex, which may manifest as a diverse range of affective, cognitive, and sensory symptoms, depending on which TC networks and associated cortical areas are implicated (40, 41). TCD occurs due to increased inhibitory or decreased excitatory input at the thalamic level, which may be triggered by bottom-up or top-down processes (37). It has been theorised that TCD in VSS may be secondary to cortical excitability (5).

Potential limitations of this study include recruitment bias, and a lack of objective measures of VSS severity. Patients who are more impacted by their symptoms may be more motivated to seek out and engage in research, biasing studies toward reporting more severe cases. Self-ratings of VS are also unlikely to be purely objective, reflecting distress relating to symptoms as well as symptom severity. Correlations between self-ratings of VS and questionnaire scores should therefore be interpreted with the awareness that they may reflect both the impact of VS on quality of life, and the influence of psychiatric symptomology on the perception of symptoms. Indeed, many patients reported that changes in psychiatric symptomology (e.g., in anxiety level or sleep quality) worsened or improved their perception of visual symptoms.

## Treatments

Treating the psychiatric symptomology associated with VSS is likely to significantly improve patient QoL, with or without accompanying improvement in visual symptoms. Sleep dysfunction is highly treatable through a number of approaches including lifestyle changes, behavioural therapies, and pharmacological agents (42). Addressing sleep dysfunction may also lead to improvements in depression and anxiety due to the bidirectional relationship between sleep and mental health (21). Identifying and treating patients at risk of severe mental health problems, and possibly suicidality, is also highly important given the rates of severe depression and anxiety associated with VSS. As with sleep dysfunction, a number of treatment avenues are available for anxiety and depression, both pharmacological and psychological (43, 44). While little research has been conducted into treatments for depersonalisation, there is some evidence that lamotrigine, currently the medication considered most efficacious in VSS (10), may be helpful in treating this symptom (45). Psychological therapies commonly used to treat depression and anxiety, such as cognitive behavioural therapy (CBT) may also help patients cope with their visual symptoms.

No study to date has investigated psychological approaches to treating VSS; however, a wealth of research exists on CBT based

treatments for tinnitus. Tinnitus is reported by the majority of VSS patients, and has been theorised to represent an auditory analogue of VS; i.e., the constant perception of low level “noise” in each sensory system (3). Given the similarities between tinnitus and VS, and overlap of patients, treatments shown to be effective for tinnitus may also be helpful in VSS. CBT encompasses a wide variety of cognitive and behavioural therapeutic techniques, but simplistically, typically aims to identify and modify negatively biased or irrational reactions to events and experiences, such as the perception of tinnitus (or VS) (46). CBT has been shown to significantly improve depression, anxiety, insomnia, and overall health-related QoL in tinnitus patients (47). Forms of CBT developed to treat tinnitus may be efficacious if adapted for use in VSS.

## CONCLUSION

Our results show that VSS significantly impacts a patient's QoL, affecting various aspects of physical and mental health. Anxiety and depression, depersonalisation, disrupted sleep, fatigue, and impaired social functioning were highly prevalent among patients, with poorer scores on these variables typically relating to worse self-ratings of visual symptoms. Although the equivalent QoL scores of lifelong and later onset patients indicate that mental health, fatigue, and sleep difficulties may be partially inherent to the disorder, they are doubtless exacerbated by the emotional impact of sensory symptoms. Patients reported that poor sleep, tiredness, and anxiety worsened their VS, whereas improving sleep and reducing stress and anxiety were said to improve perception of symptoms. Given the sparsity of effective treatments available for VSS, treating associated mental and

physical health symptoms may in some cases be the only and most effective method of assisting patients. Managing the mental health and sleep of patients is likely to improve their overall quality of life and lead to improvement in the perception of visual symptoms.

## DATA AVAILABILITY STATEMENT

The raw data supporting the conclusions of this article will be made available by the authors, without undue reservation.

## ETHICS STATEMENT

The studies involving human participants were reviewed and approved by Monash University Human Research Ethics Committee. Written informed consent to participate in this study was provided by the participants.

## AUTHOR CONTRIBUTIONS

JF, MC, OW, ES, and PF contributed to the conception and design of the study. Acquisition of data was handled by ES and PF. ES wrote the first draft of the manuscript. JF, MC, and OW supervised the project and were involved in critical revision of the manuscript. All authors contributed to the article and approved the submitted version.

## FUNDING

This study was funded in part a donation from the Visual Snow Initiative.

## REFERENCES

1. The International Classification of Headache Disorders, 3rd edition. *Cephalalgia*. (2013) 33:629–808. doi: 10.1177/0333102413485658
2. Puledra F, Schankin C, Goadsby PJ. Visual snow syndrome: a clinical and phenotypical description of 1,100 cases. *Neurology*. (2020) 94:e564–74. doi: 10.1212/WNL.0000000000008909
3. Schankin CJ, Maniyar FH, Digre KB, Goadsby PJ. 'Visual snow' - a disorder distinct from persistent migraine aura. *Brain*. (2014) 137 (Pt 5):1419–28. doi: 10.1093/brain/awu050
4. Schankin CJ, Maniyar FH, Sprenger T, Chou DE, Eller M, Goadsby PJ. The relation between migraine, typical migraine aura and “visual snow”. *Headache*. (2014) 54:957–66. doi: 10.1111/head.12378
5. Lauschke JL, Plant GT, Fraser CL. Visual snow: a thalamocortical dysrhythmia of the visual pathway? *J Clin Neurosci*. (2016) 28:123–7. doi: 10.1016/j.jocn.2015.12.001
6. Solly EJ, Clough M, McKendrick AM, Foletta P, White OB, Fielding J. Ocular motor measures of visual processing changes in visual snow syndrome. *Neurology*. (2020) 95:e1784–91. doi: 10.1212/WNL.00000000000010372
7. Metzler AI, Robertson CE. Visual snow syndrome: proposed criteria, clinical implications, and pathophysiology. *Curr Neurol Neurosci Rep*. (2018) 18:52. doi: 10.1007/s11910-018-0854-2
8. Yildiz FG, Turkyilmaz U, Unal-Cevik I. The clinical characteristics and neurophysiological assessments of the occipital cortex in visual snow syndrome with or without migraine. *Headache*. (2019) 52: 58–63. doi: 10.1111/head.13494
9. Michal M, Adler J, Wiltink J, Reiner I, Tschan R, Wolfing K, et al. A case series of 223 patients with depersonalization-derealization syndrome. *BMC Psychiatry*. (2016) 16:203. doi: 10.1186/s12888-016-0908-4
10. van Dongen RM, Waaijer LC, Onderwater GLJ, Ferrari MD, Terwindt GM. Treatment effects and comorbid diseases in 58 patients with visual snow. *Neurology*. (2019) 93:e398–403. doi: 10.1212/WNL.0000000000007825
11. Abraham HD. Visual phenomenology of the LSD flashback. *Arch Gen Psychiatry*. (1983) 40:884–9. doi: 10.1001/archpsyc.1983.01790070074009
12. Lovibond SH, Lovibond PF. *Manual for the Depression Anxiety & Stress Scales*. 2nd ed. Sydney, NSW: Psychology Foundation (1995).
13. Sierra M, Berrios GE. The Cambridge Depersonalization Scale: a new instrument for the measurement of depersonalization. *Psychiatry Res*. (2000) 93:153–64. doi: 10.1016/S0165-1781(00)00100-1
14. Buysse DJ, Reynolds CF, 3rd, Monk TH, Berman SR, Kupfer DJ. The Pittsburgh Sleep Quality Index: a new instrument for psychiatric practice and research. *Psychiatry Res*. (1989) 28:193–213. doi: 10.1016/0165-1781(89)90047-4
15. Carpenter JS, Andrykowski MA. Psychometric evaluation of the Pittsburgh sleep quality index. *J Psychosom Res*. (1998) 45:5–13. doi: 10.1016/S0022-3999(97)00298-5
16. Krupp LB, LaRocca NG, Muir-Nash J, Steinberg AD. The fatigue severity scale. Application to patients with multiple sclerosis and systemic lupus erythematosus. *Arch Neurol*. (1989) 46:1121–3. doi: 10.1001/archneur.1989.00520460115022
17. Ware JE Jr. SF-36 health survey update. *Spine*. (2000) 25:3130–9. doi: 10.1097/00007632-200012150-00008

18. Prisdie JC, Sajobi TT, Wang M, Patten SB, Fiest KM, Bulloch AGM, et al. Effects of depression and anxiety on quality of life in five common neurological disorders. *Gen Hosp Psychiatry*. (2018) 52:58–63. doi: 10.1016/j.genhosppsych.2018.03.009
19. Hesdorffer DC. Comorbidity between neurological illness and psychiatric disorders. *CNS Spectr*. (2016) 21:230–8. doi: 10.1017/S1092852915000929
20. White OB, Clough M, McKendrick AM, Fielding J. Visual snow: visual misperception. *J Neuroophthalmol*. (2018) 38:514–21. doi: 10.1097/WNO.0000000000000702
21. Alvaro PK, Roberts RM, Harris JK. A systematic review assessing bidirectionality between sleep disturbances, anxiety, and depression. *Sleep*. (2013) 36:1059–68. doi: 10.5665/sleep.2810
22. Maestri M, Romigi A, Schirru A, Fabbri M, Gori S, Bonuccelli U, et al. Excessive daytime sleepiness and fatigue in neurological disorders. *Sleep Breathing*. (2020) 24:413–24. doi: 10.1007/s11325-019-01921-4
23. Chaudhuri A, Behan PO. Fatigue in neurological disorders. *Lancet*. (2004) 363:978–88. doi: 10.1016/S0140-6736(04)15794-2
24. Simeon D, Kozin DS, Segal K, Lerch B, Dujour R, Giesbrecht T. Deconstructing depersonalization: further evidence for symptom clusters. *Psychiatry Res*. (2008) 157:303–6. doi: 10.1016/j.psychres.2007.07.007
25. Baker D, Hunter E, Lawrence E, Medford N, Patel M, Senior C, et al. Depersonalisation disorder: clinical features of 204 cases. *Br J Psychiatry*. (2003) 182:428–33. doi: 10.1192/bjp.182.5.428
26. Yen Pik San F, Jauregui-Renaud K, Green DA, Bronstein AM, Gresty MA. Depersonalisation/derealisation symptoms in vestibular disease. *J Neurol Neurosurg Psychiatry*. (2006) 77:760–6. doi: 10.1136/jnnp.2005.075473
27. Jauregui Renaud K. Vestibular function and depersonalization/derealization symptoms. *Multisens Res*. (2015) 28:637–51. doi: 10.1163/22134808-00002480
28. Jauregui-Renaud K, Ramos-Toledo V, Aguilar-Bolanos M, Montano-Velazquez B, Pliego-Maldonado A. Symptoms of detachment from the self or from the environment in patients with an acquired deficiency of the special senses. *J Vestib Res*. (2008) 18:129–37. <https://pubmed.ncbi.nlm.nih.gov/19126983/>
29. Toupet M, Van Nechel C, Hautefort C, Heuschen S, Duquesne U, Cassoulet A, et al. Influence of visual and vestibular hypersensitivity on derealization and depersonalization in chronic dizziness. *Front Neurol*. (2019) 10:69. doi: 10.3389/fneur.2019.00069
30. Lopez C. A neuroscientific account of how vestibular disorders impair bodily self-consciousness. *Front Integr Neurosci*. (2013) 7:91. doi: 10.3389/fnint.2013.00091
31. Kremkow J, Alonso JM. Thalamocortical circuits and functional architecture. *Annu Rev Vis Sci*. (2018) 4:263–85. doi: 10.1146/annurev-vision-091517-034122
32. Ward LM. The thalamus: gateway to the mind. *Wiley Interdiscip Rev Cogn Sci*. (2013) 4:609–22. doi: 10.1002/wcs.1256
33. Llinas R, Ribary U, Contreras D, Pedroarena C. The neuronal basis for consciousness. *Philos Trans R Soc Lond B Biol Sci*. (1998) 353:1841–9. doi: 10.1098/rstb.1998.0336
34. Zobeiri M, van Luijtelaar G, Budde T, Sysoev IV. The brain network in a model of thalamocortical dysrhythmia. *Brain Connect*. (2019) 9:273–84. doi: 10.1089/brain.2018.0621
35. Timofeev I, Bazhenov M. Mechanisms and biological role of thalamocortical oscillations. *Trends Chronobiol Res*. (2005) 1–47. doi: 10.4249/scholarpedia.1319
36. Vesuna S, Kauvar IV, Richman E, Gore F, Oskotsky T, Sava-Segal C, et al. Deep posteromedial cortical rhythm in dissociation. *Nature*. (2020) 586:87–94. doi: 10.1038/s41586-020-2731-9
37. Llinas RR, Ribary U, Jeanmonod D, Kronberg E, Mitra PP. Thalamocortical dysrhythmia: a neurological and neuropsychiatric syndrome characterized by magnetoencephalography. *Proc Natl Acad Sci USA*. (1999) 96:15222–7. doi: 10.1073/pnas.96.26.15222
38. De Ridder D, Vanneste S, Langguth B, Llinas R. Thalamocortical dysrhythmia: a theoretical update in tinnitus. *Front Neurol*. (2015) 6:124. doi: 10.3389/fneur.2015.00124
39. Hodkinson DJ, Wilcox SL, Veggeberg R, Nosedá R, Burstein R, Borsook D, et al. Increased amplitude of thalamocortical low-frequency oscillations in patients with migraine. *J Neurosci*. (2016) 36:8026–36. doi: 10.1523/JNEUROSCI.1038-16.2016
40. Vanneste S, Song JJ, De Ridder D. Thalamocortical dysrhythmia detected by machine learning. *Nat Commun*. (2018) 9:1103. doi: 10.1038/s41467-018-02820-0
41. Malekmohammadi M, Elias WJ, Pouratian N. Human thalamus regulates cortical activity via spatially specific and structurally constrained phase-amplitude coupling. *Cereb Cortex*. (2015) 25:1618–28. doi: 10.1093/cercor/bht358
42. Becker PM, Sattar M. Treatment of sleep dysfunction and psychiatric disorders. *Curr Treat Opt Neurol*. (2009) 11:349–57. doi: 10.1007/s11940-009-0039-z
43. Malhi GS, Bell E, Bassett D, Boyce P, Bryant R, Hazell P, et al. The 2020 Royal Australian and New Zealand College of Psychiatrists clinical practice guidelines for mood disorders. *Aust N Z J Psychiatry*. (2021) 55:7–117. doi: 10.1177/0004867420979353
44. Andrews G, Bell C, Boyce P, Gale C, Lampe L, Marwat O, et al. Royal Australian and New Zealand College of Psychiatrists clinical practice guidelines for the treatment of panic disorder, social anxiety disorder and generalised anxiety disorder. *Aust N Z J Psychiatry*. (2018) 52:1109–72. doi: 10.1177/0004867418799453
45. Naguy A, Al-Enezi N. Lamotrigine uses in psychiatric practice. *Am J Ther*. (2019) 26:e96–102. doi: 10.1097/MJT.0000000000000535
46. Andersson G. Psychological aspects of tinnitus and the application of cognitive-behavioral therapy. *Clin Psychol Rev*. (2002) 22:977–90. doi: 10.1016/S0272-7358(01)00124-6
47. Landry EC, Sandoval XCR, Simeone CN, Tidball G, Lea J, Westerberg BD. Systematic review and network meta-analysis of cognitive and/or behavioral therapies (CBT) for tinnitus. *Otol Neurotol*. (2020) 41:153–66. doi: 10.1097/MAO.00000000000002472

**Conflict of Interest:** OW receives discretionary research funding from Merck, and is an Associate Editor for Frontiers in Neuro-ophthalmology. JF receives funding for other research from Biogen and Genzyme and VSI.

The remaining authors declare that the research was conducted in the absence of any commercial or financial relationships that could be construed as a potential conflict of interest.

**Publisher's Note:** All claims expressed in this article are solely those of the authors and do not necessarily represent those of their affiliated organizations, or those of the publisher, the editors and the reviewers. Any product that may be evaluated in this article, or claim that may be made by its manufacturer, is not guaranteed or endorsed by the publisher.

Copyright © 2021 Solly, Clough, Foletta, White and Fielding. This is an open-access article distributed under the terms of the Creative Commons Attribution License (CC BY). The use, distribution or reproduction in other forums is permitted, provided the original author(s) and the copyright owner(s) are credited and that the original publication in this journal is cited, in accordance with accepted academic practice. No use, distribution or reproduction is permitted which does not comply with these terms.



# Short-Wave Sensitive (“Blue”) Cone Activation Is an Aggravating Factor for Visual Snow Symptoms

Jenny L. Hepschke, Paul R. Martin and Clare L. Fraser\*

Faculty of Health and Medicine, Save Sight Institute, The University of Sydney, Sydney, NSW, Australia

**Background and Purpose:** Visual Snow (VS) is a disorder characterised by the subjective perception of black-and-white visual static. The aetiology of this condition is not known. In our previous work we suggested that there is a link between short-wave (S or “blue” cone) signals and severity of visual snow symptoms. Therefore we aimed to further characterise this potential link.

**Methods:** Patients ( $n = 22$ ) with classic VS based on the diagnostic criteria and healthy controls ( $n = 12$ ), underwent Intuitive Colorimetry (IC) testing (Cerium Visual Technologies). Twelve hue directions (expressed as angle in CIE 1976 LUV space relative to D65) were rated on a five-point scale from preferred (relieving, positive score) to non-preferred (exacerbating, negative score), and overall preferred and non-preferred angles were chosen.

**Results:** A non-preferred violet region near the tritanopic confusion line / S-cone axis (267 deg.) was strongly associated with exacerbation of VS symptoms (range 250–310 deg, mean  $276 \pm 16$ ,  $n = 20$ , Rayleigh  $p < 0.001$ ). Two subjects with non-preferred region  $> 90$  deg from mean were considered as outliers. Median rank at angle 270 deg was significantly lower than at angle 90 ( $-1.5$  vs.  $0.0$ ,  $p < 0.001$ , Wilcoxon non-parametric rank-sum test). Patients showed preference for one of two spectral regions which relieved VS symptoms: orange-yellow (range 50–110 deg., mean  $79 \pm 24$ ,  $n = 14$ ) and turquoise-blue (range (210–250 deg., mean  $234 \pm 27$ ,  $n = 8$ ).

**Conclusion:** Our results show that visual snow symptoms are exacerbated by colour modulation that selectively increased levels of S-cone excitation. Because S-cone signals travel on primordial brain pathways that regulate cortical rhythms (koniocellular pathways) we hypothesise that these pathways contribute to the pathogenesis of this disorder.

**Keywords:** visual snow, palinopsia, migraine, positive persistent visual disturbance, thalamocortical dysrhythmia, colour filter

## INTRODUCTION

Visual Snow (VS) refers to the persistent visual experience of static in the whole visual field of both eyes likened to “static analogue television noise” (1) and was originally reported as a positive visual phenomena experienced by patients with migraine (2). The visual snow syndrome (VSS) is classified based on a set of diagnostic criteria which capture the spectrum of pathology of this condition (3, 4). Specifically it is defined as flickering fine achromatic dots with at least one

## OPEN ACCESS

### Edited by:

Christoph Schankin,  
Bern University Hospital, Switzerland

### Reviewed by:

Michael S. Vaphiades,  
University of Alabama at Birmingham,  
United States

Ozan Emre Eren,  
LMU Munich University  
Hospital, Germany

### \*Correspondence:

Clare L. Fraser  
clare.fraser@sydney.edu.au

### Specialty section:

This article was submitted to  
Neuro-Ophthalmology,  
a section of the journal  
Frontiers in Neurology

Received: 20 April 2021

Accepted: 29 June 2021

Published: 19 August 2021

### Citation:

Hepschke JL, Martin PR and  
Fraser CL (2021) Short-Wave  
Sensitive (“Blue”) Cone Activation Is  
an Aggravating Factor for Visual Snow  
Symptoms. *Front. Neurol.* 12:697923.  
doi: 10.3389/fneur.2021.697923

associated visual symptom of palinopsia, photopsia, nyctalopia, and entoptic phenomena as well as non-visual symptoms such as tinnitus and migraine (3, 5).

Puledda et al. (5) provided a detailed phenotypical and epidemiological description of over one thousand patients with VS and VSS. Their study confirmed several aspects of VSS that had previously been characterised in smaller cohorts including the lack of gender prevalence, onset early in life and absence of relationship to prior psychotropic substance use (6–8). It is clear from all these studies that VS and VSS exists as a continuum and the frequency of associated non-visual symptoms often carries a higher symptom severity and burden of disease (5, 9, 10).

The pathophysiology underlying VS remains elusive, but several hypotheses exist. Cortical hyperexcitability in the visual system has been suggested as a mechanism based on detection of cortical hypermetabolism (11, 12), increased lactate presence (13) and behavioural imbalance between inhibition and excitation (9, 14). Other reports have considered mechanisms of impaired sensory processing as evidenced by hypoperfusion on SPECT (15), hyperexcitability on EEG (16), as well as evidence of reduced habituation on electrophysiological assessment (17, 18). Most recently differences in grey matter volume and resting state functional connectivity in VS patients were identified using MRI (12, 13, 19).

We have previously hypothesised that VS results from a thalamocortical dysrhythmia (TCD) of the visual system, whereby normal thalamo-cortical oscillations are disrupted by changes in the oscillatory properties of the constituent neural circuits (20). Specifically we proposed that VS is associated with abnormalities to the koniocellular (KC) pathways, which include cells that transmit short-wave (S-cone) signals serving blue-yellow colour vision. This hypothesis was based on previous observations of yellow-blue colour preferences in VS patients (8), and is broadly in line with the thalamocortical synchrony (TCS) hypothesis (21). The TCS proposes that KC activity entrains or gates cortical circuits fed by magno- and parvocellular afferent pathways, thereby rendering otherwise sub-threshold activity in these visual pathways as visual snow (22, 23).

The present study characterises the colour preferences of VS patients in more detail, with emphasis on the tritan (blue-yellow) and protan (red-green) colour axes. Our specific hypothesis is that S-cone activation, and resultant central koniocellular pathway modulation, plays a crucial role in the pathogenesis of visual snow syndrome.

## MATERIALS AND METHODS

### Participants

Data were collected from 22 VS patients and 12 controls. Patients underwent a standardised series of questions about their associated visual and non-visual symptoms. The associated medical and psychiatric co-morbidities were reviewed or noted from past medical records. The VS participants were included only if they had a clinical diagnosis by a Neuro-ophthalmologist of typical VS according to the diagnostic criteria by Schankin et al. (3). Participants were excluded if they were taking psychiatric medication, reported epileptic symptoms

or had a diagnosis of Hallucinogen-persistence perceptual Disorder (HPPD).

### Intuitive Colorimetry

All participants were tested by Intuitive Colorimetry (IC) as previously described by Wilkins et al. (24) (Figure 3). Participants were seated in front of an Intuitive Colorimeter Device (Cerium Visual Technologies) which illuminated a page of crowded text. The participants were asked to judge whether a change in the illumination colour had any effect on their visual snow symptoms (their “visual comfort”). Saturation in the 12 different hue directions (expressed as angle in CIE 1976 LUV space relative to D65) was slowly increased from a neutral setting, which was a white similar to daylight (CIE 1976  $u' = 0.21$ ;  $v' = 0.75$ ) to one with a moderate strength of colour or saturation. The hue directions were rated on a five-point scale from preferred (relieving, positive score), neutral to non-preferred (exacerbating, negative score). For those hues that elicited clear exacerbation or relief of visual snow symptoms the saturation was optimised, usually by asking the patient to adjust the saturation using a manual dial. The preferred and least-preferred hues were then compared, typically by forced choice between two previously selected choices successively presented by the examiner until a chromaticity had been selected by the participant.

### Analysis

Statistical comparisons of area of preferred and least preferred spectral regions were made using non-parametric tests with Matlab. The research procedures complied with the Declaration of Helsinki and were approved by the Macquarie University ethics committee (HREC 5201800350). Participants gave written informed consent.

## RESULTS

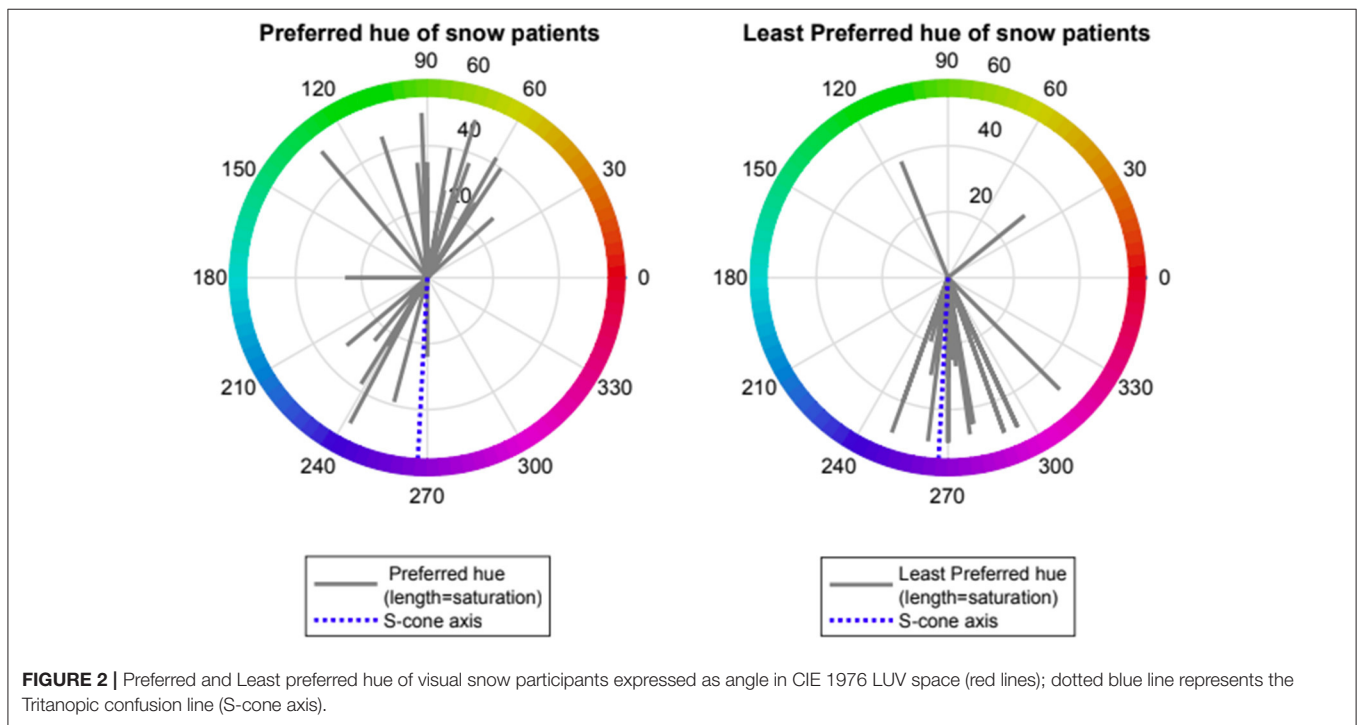
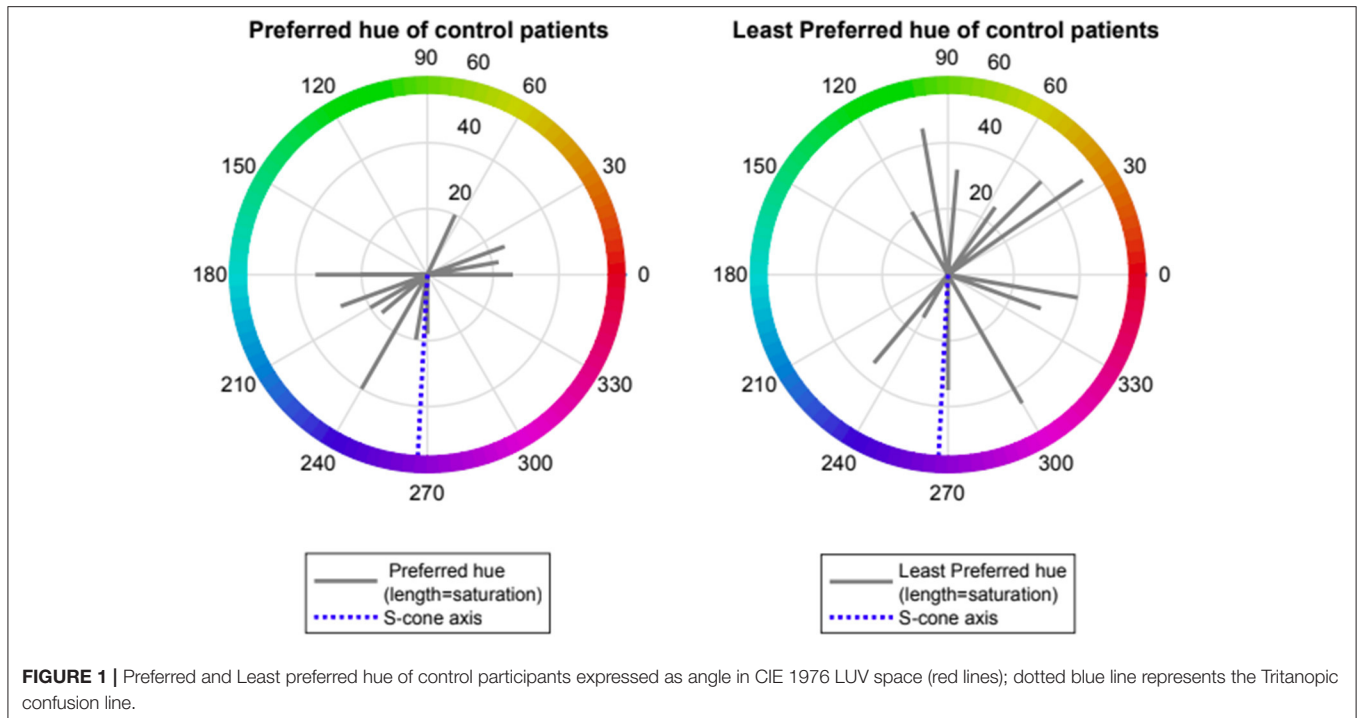
### Epidemiology

The VS cohort consisted of 9 female and 13 male patients with a mean age of  $31.8 \pm 11.3$  years (range 22–61 y). The average VS symptom duration was  $6.8 \pm 2.5$  years (range 2–40 years)

**TABLE 1** | Frequency of visual and non-visual symptoms of visual snow participants in line with diagnostic criteria.

Visual snow criteria	
<b>Visual symptoms</b>	
Visual snow	100%
Palinopsias	95%
Enhanced entoptic phenomena	91%
Photophobia	64%
Nyctalopia	64%
<b>Non-visual symptoms</b>	
Tinnitus	86%
Migraine	59%
Tremor	46%



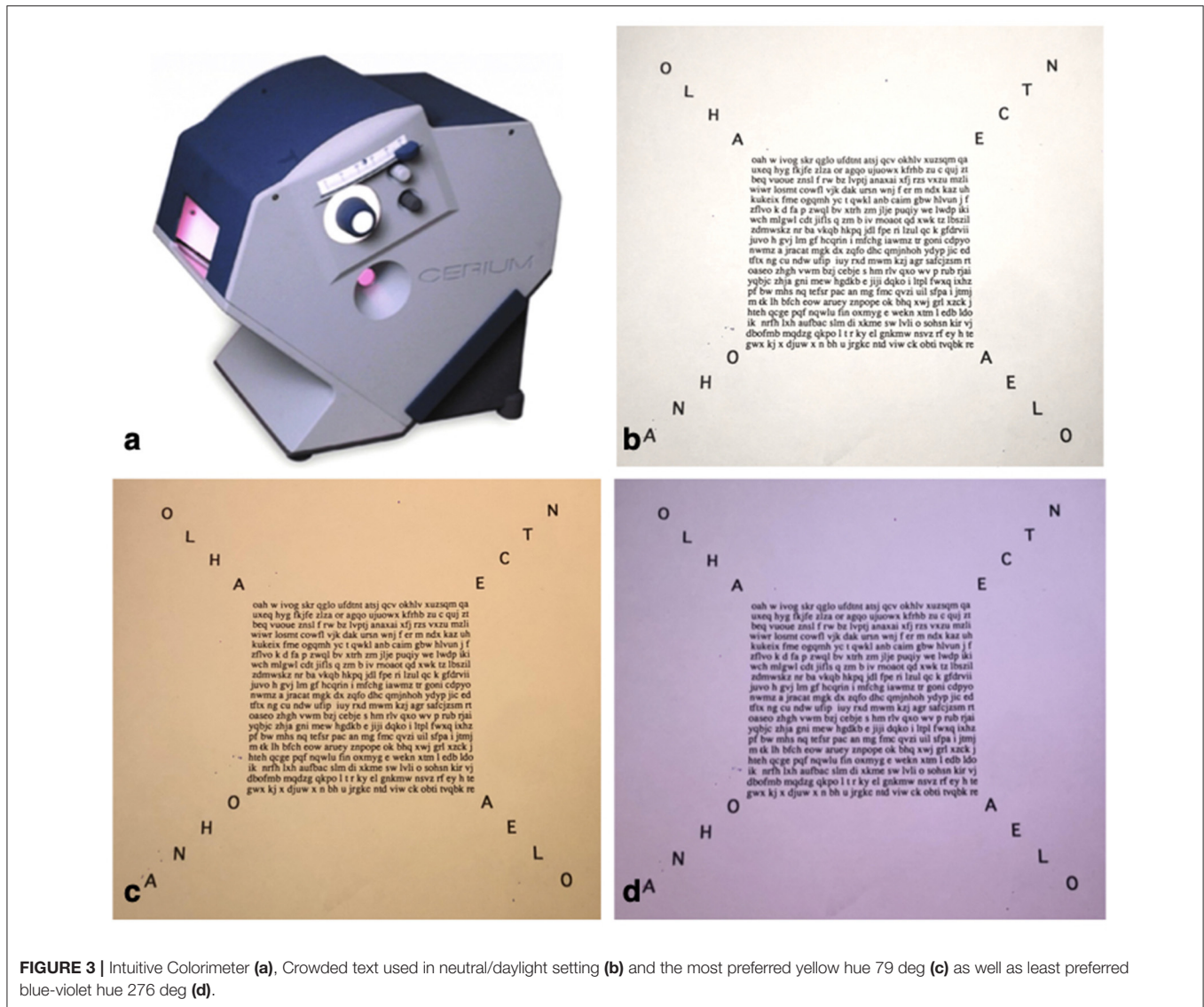


with four patients reporting symptoms since early childhood. Associated visual and non-visual symptoms are summarised in **Table 1**.

All of the VS cohort fulfilled the diagnostic criteria of classic achromatic visual snow (3). Associated visual symptoms were reported with the following frequency; 95% palinopsias, 91%

entoptic phenomena and 64% photophobia and nyctalopia. Associated non-visual symptoms included 86% tinnitus, 59% migraine, and 46% tremor.

Healthy controls were eight female and four male volunteers with a mean age of  $38.4 \pm 16.2$  years (range 22–74 y). In our control cohort none of the patients experienced VS nor any



**FIGURE 3 |** Intuitive Colorimeter (a), Crowded text used in neutral/daylight setting (b) and the most preferred yellow hue 79 deg (c) as well as least preferred blue-violet hue 276 deg (d).

associated visual symptoms. Five (42%) of the healthy controls had migraines and none had tinnitus or tremor.

### Intuitive Colorimetry Preference

Control volunteers showed a slight preference for one of two spectral regions which provided “visual comfort” namely red-orange (range 0–70 deg., mean  $12 \pm 1$ ,  $n = 4$ ) and turquoise-blue (range (180–270 deg., mean  $220 \pm 35$ ,  $n = 8$ ). Control volunteers had no non-preferred region for “visual discomfort” (see Figure 1).

Patients with VS showed preference for one of two spectral regions which relieved VS symptoms namely orange- yellow (range 50–110 deg., mean  $79 \pm 24$ ,  $n = 14$ ) and turquoise-blue (range (210–250 deg., mean  $234 \pm 27$ ,  $n = 8$ ). Patients with VS also showed a strong negative preference for a spectral blue-violet region which exacerbated VS symptoms (range 250–310 deg, mean  $276 \pm 16$ ,  $n = 20$ , Rayleigh  $p < 0.001$ ). Two

subjects with non-preferred region  $> 90$  deg from mean were considered as outliers. Median rank at hue angle 270 deg was significantly lower than at angle 90 ( $-1.5$  vs.  $0.0$ ,  $p < 0.001$ , Wilcoxon non-parametric rank-sum test) (see Figures 2, 3).

### DISCUSSION

We previously reported subjective relief of VS symptoms with yellow-blue colour filters (8). In this paper we formally classify colour preferences in VS patients compared to controls. We confirm a yellow-blue colour preferences for VS participants compared to controls, with the colour filter acting to relieve the symptoms. Most striking however was the strong negative preference or dislike for a blue-violet region (mean  $276 \pm 16$  deg), in a direction close to the tritanopic confusion line. The tritanopic confusion line is of interest as points along this line specifically cause different levels of S-cone excitation.

The S-cones participate in the construction of a blue-yellow colour opponent channel in the retina, whereby small and large bistratified cells get ON-sign input from S-cones (via ON-type S-cone contacting bipolar cells) and OFF-sign input from medium- and long-wave sensitive cones (via OFF-type diffuse bipolar cells) (25). These ganglion cells project predominantly through the koniocellular (KC) layers of the lateral geniculate nucleus (LGN) to reach supragranular layers of primary visual cortex (V1). The KC pathways are part of an evolutionarily ancient group of thalamocortical pathways that include the paralemniscal somatosensory and tegmental auditory pathways, and for this reason has been characterised as a primitive visual system (21, 26–28). In contrast to KC layers, the main parvocellular (PC) and magnocellular (MC) layers of the LGN evolved relatively recently, form tightly topographically organised inputs to layer 4 in V1, and have been linked to high frequency cortical oscillations (26) and high-resolution analysis of visual inputs (21). Overall S-cones and the KC pathway are unique due to the sparse distribution of s-cones in the retina, their distinct neurotransmitter profiles and their complex and varied interconnections within the thalamus giving rise to a range of visual and non-visual pathways (25). It is important to note that S-cones also contribute to “blue-off” type responses in intrinsically photosensitive melanopsin-expressing cells (29). This cell population represents a possible alternative route by which the effects we observe could be mediated.

The thalamocortical system is comprised of extensive corticothalamic connections that are arranged into networks with spatial and temporal organisation through synchronisation of oscillations thereby creating the complex pathways required for sensory perception and conscious awareness (20, 30). When the neuronal integration and synchronisation at the level of the thalamus is disrupted due to changes in specific neurons or pathways, either top-down or bottom-up, then thalamocortical dysrhythmia (TCD) may arise. The model of thalamocortical dysrhythmia (TCD) was first proposed by Llinás et al. (20) to explain common pathological patterns such as abnormal low-frequency theta oscillations, persistent gamma activity, and reduced resting-state alpha activity. Today, TCD is thought to contribute to diverse neuropathies depending on the localisation of the dysfunction in the thalamocortical network including migraine, neuropathic pain and tinnitus (31, 32), Parkinson’s disease and depression (33, 34).

Components of the VSS have been traced to various areas in the visual system such as illusionary hallucinations can be traced to the V1 to V3 visual cortex, palinopsias can be traced to the parietal lobe coordination system and trailing as well as after-images can be located in the parietal association cortex (35). Symptoms affecting different aspect of the visual system that were traditionally held as distinct, may in fact be closely related, when considered from the perspective of

TCD as a potential underlying mechanism. In addition the TCD hypothesis highlights that many non-visual symptoms affecting VS patients in other sensory domains such as migraine, tinnitus and tremor, may be explained by a single underlying pathophysiology (1, 31).

Some form of anatomical or functional disconnect between thalamus and cortex is thought to be a pre-requisite for the occurrence of TCD such as lack of afferent input in phantom pain and functional de-afferentiation in tinnitus (31, 36). Hyperexcitability of individual neurons may be a significant enough disruption to lead to TCD (37) and abnormal KC pathway input may be sufficient to drive the TCD in VSS.

In the above contexts, the clear dislike of blue light on the tritanopic confusion line we observed in the VS patients implicates S-cone activity, carried on KC pathways, enabling perception of visual snow. Our specific conjecture here is that activity in PC and MC pathways is increased by activity in KC cells, resulting in conscious awareness of sub-threshold visual stimuli. Defining a neurophysiological substrate for the pathology of VS gives further insights into this condition, helping patients and physicians work towards better treatment options. We have previously reported subjective benefit of blue-yellow coloured lenses causing improvement in VS symptoms (8). Our results have further defined the specific wavelengths implicated in VS and thus might help developing further treatment modalities that may suppress S-cone and KC activation.

## DATA AVAILABILITY STATEMENT

The raw data supporting the conclusions of this article will be made available by the authors, without undue reservation.

## ETHICS STATEMENT

The studies involving human participants were reviewed and approved by Macquarie University Ethics. The patients/participants provided their written informed consent to participate in this study.

## AUTHOR CONTRIBUTIONS

All authors listed have made a substantial, direct and intellectual contribution to the work, and approved it for publication.

## ACKNOWLEDGMENTS

We would like to thank The Eye Practice Sydney for generously allowing us to access their Intuitive Colorimeter and acknowledge the North American Neuro-Ophthalmology Society Pilot grant.

## REFERENCES

- Gersztenkorn D, Lee AG. Palinopsia revamped: a systematic review of the literature. *Surv Ophthalmol.* (2015) 60:1–35. doi: 10.1016/j.survophthal.2014.06.003
- Liu GT, Schatz NJ, Galetta SL, Volpe NJ, Skobieranda F, Kosmorsky GS. Persistent positive visual phenomena in migraine. *Neurology.* (1995) 45:664–8. doi: 10.1212/WNL.45.4.664
- Schankin CJ, Maniyar FH, Digre KB, Goadsby PJ. 'Visual snow'—a disorder distinct from persistent migraine aura. *Brain.* (2014) 137 (Pt 5):1419–28. doi: 10.1093/brain/awu050
- Santos-Bueso E, Sastre-Ibáñez M, Sáenz-Francés F, Porta-Etessam J, García-Sánchez J. [Visual snow. From a symptom to a syndrome?]. *Arch Soc Esp Oftalmol.* (2015) 90:51–2. doi: 10.1016/j.oftale.2015.02.019
- Puledda F, Schankin C, Goadsby PJ. Visual snow syndrome. A clinical and phenotypical description of 1,100 cases. *Neurology.* (2020) 94:e564–74. doi: 10.1212/WNL.0000000000008909
- Bessero AC, Plant GT. Should 'visual snow' and persistence of after-images be recognised as a new visual syndrome? *J Neurol Neurosurg Psychiatry.* (2014) 85:1057–8. doi: 10.1136/jnnp-2013-306827
- Schankin CJ, Goadsby PJ. Visual snow—persistent positive visual phenomenon distinct from migraine aura. *Curr Pain Headache Rep.* (2015) 19:23. doi: 10.1007/s11916-015-0497-9
- Lauschke JL, Plant GT, Fraser CL. Visual snow: A thalamocortical dysrhythmia of the visual pathway? *J Clin Neurosci.* (2016) 28:123–7. doi: 10.1016/j.jocn.2015.12.001
- White OB, Clough M, McKendrick AM, Fielding J. Visual snow: visual misperception. *J Neuroophthalmol.* (2018) 38:514–21. doi: 10.1097/WNO.0000000000000702
- Schankin CJ, Puledda F, Goadsby PJ. Visual snow syndrome: is it normal or a disorder - and what to do with patients? *Eur J Neurol.* (2020) 27:2393–5. doi: 10.1111/ene.14436
- Bou Ghannam A, Pelak VS. Visual Snow: a potential cortical hyperexcitability syndrome. *Curr Treat Options Neurol.* (2017) 19:9. doi: 10.1007/s11940-017-0448-3
- Schankin CJ, Maniyar FH, Chou DE, Eller M, Sprenger T, Goadsby PJ. Structural and functional footprint of visual snow syndrome. *Brain.* (2020) 143:1106–13. doi: 10.1093/brain/awaa053
- Puledda F, Ffytche D, Lythgoe DJ, O'Daly O, Schankin C, Williams SCR, et al. Insular and occipital changes in visual snow syndrome: a BOLD fMRI and MRS study. *Ann Clin Transl Neurol.* (2020) 7:296–306. doi: 10.1002/acn3.50986
- McKendrick AM, Chan YM, Tien M, Millist L, Clough M, Mack H, et al. Behavioral measures of cortical hyperexcitability assessed in people who experience visual snow. *Neurology.* (2017) 88:1243–9. doi: 10.1212/WNL.0000000000003784
- Shibata M, Tsutsumi K, Iwabuchi Y, Kameyama M, Takizawa T, Nakahara T, et al. [(123)I]-IMP single-photon emission computed tomography imaging in visual snow syndrome: a case series. *Cephalalgia.* (2020) 40:1671–5. doi: 10.1177/0333102420950454
- Luna S, Lai D, Harris A. Antagonistic relationship between VEP potentiation and gamma power in visual snow syndrome. *Headache.* (2018) 58:138–44. doi: 10.1111/head.13231
- Fantini J, Sartori A, Manganotti P. Can we speak of lack of habituation in visual snow? *Headache.* (2016) 56:1517–8. doi: 10.1111/head.12957
- Eren O, Rauschel V, Ruscheweyh R, Straube A, Schankin CJ. Evidence of dysfunction in the visual association cortex in visual snow syndrome. *Ann Neurol.* (2018) 84:946–9. doi: 10.1002/ana.25372
- Puledda F, Bruchhage M, O'Daly O, Ffytche D, Williams SCR, Goadsby PJ. Occipital cortex and cerebellum gray matter changes in visual snow syndrome. *Neurology.* (2020) 95:e1792–e9. doi: 10.1212/WNL.0000000000010530
- Llinás RR, Ribary U, Jeanmonod D, Kronberg E, Mitra PP. Thalamocortical dysrhythmia: a neurological and neuropsychiatric syndrome characterized by magnetoencephalography. *Proc Natl Acad Sci USA.* (1999) 96:15222–7. doi: 10.1073/pnas.96.26.15222
- Jones EG. The thalamic matrix and thalamocortical synchrony. *Trends Neurosci.* (2001) 24:595–601. doi: 10.1016/S0166-2236(00)01922-6
- Hendry SH, Reid RC. The koniocellular pathway in primate vision. *Annu Rev Neurosci.* (2000) 23:127–53. doi: 10.1146/annurev.neuro.23.1.127
- Cheong SK, Tailby C, Martin PR, Levitt JB, Solomon SG. Slow intrinsic rhythm in the koniocellular visual pathway. *Proc Natl Acad Sci USA.* (2011) 108:14659–63. doi: 10.1073/pnas.1108004108
- Wilkins AJ, Nimmo-Smith I, Jansons JE. Colorimeter for the intuitive manipulation of hue and saturation and its role in the study of perceptual distortion. *Ophthalmic Physiol Opt.* (1992) 12:381–5. doi: 10.1111/j.1475-1313.1992.tb00413.x
- Lee BB, Martin PR, Grünert U. Retinal connectivity and primate vision. *Prog Retin Eye Res.* (2010) 29:622–39. doi: 10.1016/j.preteyeres.2010.08.004
- Casagrande VA. A third parallel visual pathway to primate area V1. *Trends Neurosci.* (1994) 17:305–10. doi: 10.1016/0166-2236(94)90065-5
- Sincich LC, Park KF, Wohlgenuth MJ, Horton JC. Bypassing V1: a direct geniculate input to area MT. *Nat Neurosci.* (2004) 7:1123–8. doi: 10.1038/nm1318
- Warner C, Goldshmit Y, Bourne J. Retinal afferents synapse with relay cells targeting the middle temporal area in the pulvinar and lateral geniculate nuclei. *Front Neuroanat.* (2010) 4:8. doi: 10.3389/neuro.05.008.2010
- Dacey DM, Liao H-W, Peterson BB, Robinson FR, Smith VC, Pokorny J, et al. Melanopsin-expressing ganglion cells in primate retina signal colour and irradiance and project to the LGN. *Nature.* (2005) 433:749–54. doi: 10.1038/nature03387
- Bollimunta A, Mo J, Schroeder CE, Ding M. Neuronal mechanisms and attentional modulation of corticothalamic  $\alpha$  oscillations. *J Neurosci.* (2011) 31:4935–43. doi: 10.1523/JNEUROSCI.5580-10.2011
- De Ridder D, Vanneste S, Langguth B, Llinás R. Thalamocortical dysrhythmia: a theoretical update in tinnitus. *Front Neurol.* (2015) 6:124. doi: 10.3389/fneur.2015.00124
- Ferrari MD, Klever RR, Terwindt GM, Ayata C, van den Maagdenberg AM. Migraine pathophysiology: lessons from mouse models and human genetics. *Lancet Neurol.* (2015) 14:65–80. doi: 10.1016/S1474-4422(14)70220-0
- Schulman J, Cancro R, Lowe S, Lu F, Walton K, Llinás R. Imaging of thalamocortical dysrhythmia in neuropsychiatry. *Front Hum Neurosci.* (2011) 5:69. doi: 10.3389/fnhum.2011.00069
- Vanneste S, Song J-J, De Ridder D. Thalamocortical dysrhythmia detected by machine learning. *Nat Commun.* (2018) 9:1103. doi: 10.1038/s41467-018-02820-0
- Ffytche DH, Blom JD, Catani M. Disorders of visual perception. *J Neurol Neurosurg Psychiatry.* (2010) 81:1280–7. doi: 10.1136/jnnp.2008.171348
- Weisz N, Müller S, Schlee W, Dohrmann K, Hartmann T, Elbert T. The neural code of auditory phantom perception. *J Neurosci.* (2007) 27:1479–84. doi: 10.1523/JNEUROSCI.3711-06.2007
- Volcy M, Sheftell FD, Tepper SJ, Rapoport AM, Bigal ME. Tinnitus in migraine: an allodynic symptom secondary to abnormal cortical functioning? *Headache.* (2005) 45:1083–7. doi: 10.1111/j.1526-4610.2005.05193\_2.x

**Conflict of Interest:** The authors declare that the research was conducted in the absence of any commercial or financial relationships that could be construed as a potential conflict of interest.

**Publisher's Note:** All claims expressed in this article are solely those of the authors and do not necessarily represent those of their affiliated organizations, or those of the publisher, the editors and the reviewers. Any product that may be evaluated in this article, or claim that may be made by its manufacturer, is not guaranteed or endorsed by the publisher.

Copyright © 2021 Hepschke, Martin and Fraser. This is an open-access article distributed under the terms of the Creative Commons Attribution License (CC BY). The use, distribution or reproduction in other forums is permitted, provided the original author(s) and the copyright owner(s) are credited and that the original publication in this journal is cited, in accordance with accepted academic practice. No use, distribution or reproduction is permitted which does not comply with these terms.



# Diagnostic Evaluation of Visual Snow

Michael S. Vaphiades<sup>1\*</sup>, Brendan Grondines<sup>1</sup>, Kasey Cooper<sup>1</sup>, Sean Gratton<sup>2</sup> and Jennifer Doyle<sup>3</sup>

<sup>1</sup> Department of Ophthalmology, University of Alabama, Birmingham, AL, United States, <sup>2</sup> Department of Ophthalmology, University of Missouri-Kansas City School of Medicine, Kansas City, MO, United States, <sup>3</sup> Department of Ophthalmology, Little Rock Eye Clinic, Little Rock, AK, United States

**Introduction:** To determine which patients with visual snow (VS) and VS syndrome (VSS) require standard ophthalmologic testing including automated visual field and which patients require further testing such as macular spectral domain optical coherence tomography (SD-OCT), electrophysiology, and neuroimaging.

**Materials and Methods:** We retrospectively reviewed 52 consecutive patients at three institutions with VS and VSS including the University of Alabama, Callahan Eye Hospital, the University of Missouri-Kansas City School of Medicine, and the Little Rock Eye Clinic from the years 2015 to 2021. We collected historical information, examination findings, ophthalmic testing, electrophysiology, and neuroimaging.

**Results:** Of the 52 patients with VS and VSS, eight of the 52 cases met the clinical criteria for VSS. The ages ranged from 7 to 79 years, with a mean age of 25 years (SD = 14.0). There were 22 males and 30 females. Color vision was tested in 51 cases and was normal in 47 cases (92%). A fundusoscopic exam was performed in all 52 cases and was normal in 46 cases (88%). The macular SD-OCT was normal in all of the 19 cases that it was performed (100%). A Humphrey visual field was performed in 50 cases and was normal in 43 (86%). A visually evoked potential (VEP) was normal in 18 of the 19 cases where it was obtained (95%). The full-field electroretinography (ffERG) was obtained in 28 cases and was normal in 25 (89%). The multifocal electroretinography (mfERG) was normal in 11 of 12 cases (92%). Only four patients accounted for all of the abnormal electrophysiological tests. In the 37 cases that had an MRI, 29 were normal (78%). Only one patient revealed a lesion in the visual pathway (right optic nerve enhancement in an optic neuritis patient).

**Conclusions:** Patients with VS and VSS, if typical in presentation and with normal testing, do not require a workup beyond a thorough history, neuro-ophthalmologic examination, and automated perimetry. If this testing is abnormal, then ancillary testing is required.

**Keywords:** visual snow, visual snow syndrome, MRI, CT, OCT, electroretinography

## INTRODUCTION

Visual snow (VS) is a visual phenomenon that is akin to looking at an old analog television where the reception is poor (1). VS syndrome (VSS) is VS plus other visual and perceptual symptoms (2). VS usually manifests in early life, with black and white, transparent, or different combinations of color static effects. Floaters, afterimages, and photophobia are almost invariably also present (3).

## OPEN ACCESS

### Edited by:

Victoria Susan Pelak,  
University of Colorado, United States

### Reviewed by:

Márta Janáky,  
University of Szeged, Hungary  
Shlomo Dotan,  
Tel Aviv Sourasky Medical  
Center, Israel

### \*Correspondence:

Michael S. Vaphiades  
mvaphiades@uabmc.edu

### Specialty section:

This article was submitted to  
Neuro-Ophthalmology,  
a section of the journal  
Frontiers in Neurology

**Received:** 18 July 2021

**Accepted:** 17 August 2021

**Published:** 16 September 2021

### Citation:

Vaphiades MS, Grondines B,  
Cooper K, Gratton S and Doyle J  
(2021) Diagnostic Evaluation of Visual  
Snow. *Front. Neurol.* 12:743608.  
doi: 10.3389/fneur.2021.743608

The main question we wanted to answer from this study is if ancillary testing is required in the typical patient who experiences VS symptoms.

Secondarily, since we accumulated more VS and VSS patients than anticipated, we thought it prudent to determine common features in the history, ophthalmologic examination, electrophysiological and ophthalmologic testing, and neuroimaging.

## METHODS AND MATERIALS

We retrospectively evaluated 52 patients who experienced VS and VSS as defined by in 2014 by Schankin et al. (2) from three institutions including the University of Alabama, Callahan Eye Hospital (MV, BG, and KC), the University of Missouri-Kansas City School of Medicine (SG), and the Little Rock Eye Clinic (JD) from the years 2015 to 2021. Patients underwent a history inquiry (quality and length of the snow) and examination (visual acuity and color testing), ophthalmic imaging (automated visual fields, macular spectral domain optical coherence tomography (SD-OCT), electrophysiological testing consisting of full-field electroretinography (ffERG), multifocal electroretinography (mfERG), and visually evoked potential (VEP)), and brain neuroimaging consisting of magnetic resonance imaging (MRI) and/or computed tomography (CT) of the head. Not every patient underwent every test. Visual acuity was deemed normal if Snellen acuity was 20/25 or better, color vision was deemed normal if all the color plates are identified, and visual fields were deemed normal as reviewed by each physician's interpretation. The head MRI/CT was deemed normal per radiologic interpretation. Medical charts and referral letters were reviewed to identify a previous diagnostic history of psychiatric comorbidities, neurological examination results, and prescribed medications. We also notated race, gender, psychological conditions, migraine headaches, and other comorbidities and if any treatment was instituted. A PubMed literature review using the term "visual snow" and "visual snow syndrome" was performed. References were reviewed and articles discovered.

## RESULTS

Of the 52 patients with VS and VSS, eight of the 52 cases met the clinical criteria for VSS. The ages of the 52 patients ranged from 7 to 79 years, with a mean age of 25 years ( $SD = 14.0$ ). There were 22 males and 30 females. More than half (27) of all cases were white, four were African American, and there were one each of Hispanic, Asian, and Native Hawaiian descent. In 17 cases, no information on race was reported. Nine patients reported VS for as long as they could remember, 15 reported to have it for the majority of their life, 35 reported that the VS developed later in life, and eight cases reported no information on the duration of symptoms. There were 27 cases with migraine headaches (52%), five of whom reported visual aura, however separate from the VS. Nine patients noted palinopsia, three had nyctalopia, four had floaters, five had photophobia, and seven

had enhanced entopic phenomena. Sixteen of the 52 patients reported at least one psychiatric condition (30%). These included 11 cases of depression, eight of anxiety, two of insomnia, one of attention deficit hyperactivity disorder (ADHD), one of bipolar disorder, one of borderline personality disorder, one of post-traumatic stress disorder (PTSD), and one of both Asperger's and Tourette's syndromes.

The best-corrected Snellen visual acuity was 20/25 or 20/20 in 46 of the 52 cases (88%). Color vision was tested in 51 cases and was normal in 47 cases (92%). A funduscopy exam was performed in all 52 cases and was normal in 46 cases (88%). The macular SD-OCT was normal in all of the 19 cases that it was performed (100%).

A Humphrey visual field test was performed in 50 cases and was normal in 43 (86%). Two of the cases with an abnormal Humphrey visual field showed an enlarged blind spot in both eyes (OU), one case was initially normal but when retested 1 year later showed an enlarged blind spot in the right eye (OD) but still normal in the left eye (OS), one case showed central depression OU, one case showed mild constriction OU, and one case was normal OD but showed nasal superior depression OS.

Electrophysiological studies were generally unrevealing. A VEP was normal in 18 of the 19 cases where it was obtained (95%). Similarly, the ffERG was obtained in 28 cases and was normal in 25 (89%). The mfERG was normal in 11 of 12 cases (92%). Only four patients accounted for all of the abnormal electrophysiological tests, and they are as follows: (1) a ffERG showed abnormally depressed OS. This patient had deprivation amblyopia OS secondary to congenital hemangioma of the left upper lid. (2) A mfERG was abnormal. This patient also had pathologic high myopia ( $-14.00$  diopters OD and  $-13.00$  diopters OS), which appeared to be responsible for the abnormal mfERG. (3) A ffERG was abnormally depressed OD. This patient complained of monocular visual loss in that eye. (4) Both the VEP and mfERG showed abnormal OU. This was initially felt to be related to high myopia OU and keratoconus OU; however, the ffERG was abnormal OU as well, which prompted genetic testing revealing a MYO7A variant, which is associated with autosomal recessive Usher type 1. Thus, all four cases had other complaints and exam findings accounting for the abnormalities other than the VS complaint.

Neuroimaging was also generally unrevealing. Overall, 43 patients had cranial neuroimaging: nine had CT, 37 had MRI, and three had both. All nine of the cases that had a CT of the head were normal (100%). In the 37 cases that had an MRI, 29 were normal (78%). The abnormalities among these eight MRI patients ranged from a (1) a right cerebellar hemispheric lesion "scar", (2) fluid-attenuated inversion recovery (FLAIR) changes in the thalamic and subthalamic regions, (3) tonsillar ectopia and mild ventriculomegaly, (4) areas of periventricular white matter changes, (5) enhancement of the right optic nerve just prior to the chiasm, (6) small amount of fluid in the air cells of the right petrous pyramid, (7) right frontal deep vein abnormality, and (8) left-sided cerebellar venous angioma. Only one patient revealed a lesion in the visual pathway (right optic nerve enhancement in an optic neuritis patient).

## DISCUSSION

VS was first described by Liu et al. in 1995 as an “unusual complication of migraine” manifesting as “persistent diffuse small particles such as TV static, snow, lines of ants, dots, and rain” in the patient’s entire visual field (1). It is akin to looking at an old analog television where the reception is poor (2). It generally lasts for months to years, and no underlying etiology is identified. This syndrome was first referred to as “visual snow phenomena” in 2005 (4) and later as VSS (5) with VS as the defining characteristic of the VSS, which includes other visual and perceptual symptoms (2, 6). In 2014, Schankin et al. proposed a definition of VSS to include two of the following: (1) palinopsia, (2) enhanced entoptic phenomena (excessive floaters, excessive blue field entoptic phenomena, self-light of the eye, or spontaneous photopsia), (3) photophobia, and (4) nyctalopia (night blindness). Also, symptoms cannot be consistent with typical migraine aura, another disorder or medication effect (2). In 2018, these criteria were adopted by the International Headache Society as VSS criteria (7). Patients may experience VS without the complete VSS; and as stated in the above criteria, it is not associated with the effects of psychotropic substances on the brain or other chronic neurological or ophthalmologic disorders (3). Even though VS is not typical of migraine aura, migraine is frequently reported in approximately 70% of patients (3). Migraine headache was present in 52% of our patient population. The perception of VS has been attributed to dysfunctional central sensory processing, which overlaps with, yet is different from, migraine (8).

It is clinically advantageous to have an understanding of what a “typical” patient with VSS experiences. Naturally, the key feature of VSS is the symptom of VS itself: dynamic, continuous, tiny dots in the entire visual field. Typically, the dots are black/gray on a white background or gray/white on a black background; however, the visual phenomena can also be transparent, white flashing, or colored (9), and typically there is no auditory component. Other visual symptoms coexist with VS as part of the syndrome as mentioned to include, but are not limited to palinopsia, enhanced entoptic phenomena, photophobia, and nyctalopia (3). Yoo et al. reviewed the neuro-ophthalmic findings in 20 patients with VSS, and they detected high rates of other visual symptoms including illusionary palinopsia (61%), enhanced entoptic phenomenon (65%), disturbance of night vision (44%), and photophobia (65%) (10). Non-visual symptoms such as tinnitus (7) and even symptoms such as difficulty concentrating and irritability can occur as well (11). The VS typically appears early in life, and in approximately 40% of patients, the symptom has been present for as long as they can remember (3).

Migraine is highly comorbid with VSS (2, 3); however, unlike migraine, VSS does not display a gender prevalence (3) as in our patient population.

These patients typically have a normal neuro-ophthalmologic exam; (10) however, a subpopulation may have atypical history and exam leading to a neuro-ophthalmologic disorder originating from diseases of the eye or the brain. It has been reported in rod-cone dystrophy (10), idiopathic

intracranial hypertension (10), Creutzfeldt–Jakob disease (12), and paraneoplastic syndromes (13), among others. It is important for the clinician to distinguish between VS that originates from one of these potentially vision-threatening and dangerous pathologies and idiopathic or “isolated VS or VSS.” A detailed history inquiry is the most effective way of making this distinction. Beyond the history inquiry and exam, it is not well-established whether ancillary testing such as brain imaging or electroretinography is required in the workup of patients presenting with VS. Yoo et al. examined 20 patients with VS, and one was a 36-year-old woman had classic symptoms of VS; however, based on history, the symptoms had only occurred for 6 years, and she had binasal defects on the visual field. This prompted further workup revealing an abnormal fERG and rod-cone dystrophy (10).

In our population of 47 patients, we obtained a variety of different tests that were all not uniform, partly because there is no well-established guidelines on testing and also the retrospective nature of the study. However, our results indicated that ancillary testing yielded no etiologic pathology when patients presented with “typical” historic and exam features of idiopathic or isolated VS or VSS. We define “typical features” as originating at an early age with the appearance akin to looking at an old analog television where the reception is poor, and a completely normal neuro-ophthalmic examination including normal acuity, pupillary exam, color vision, and automated perimetry. Our “typical” VS and VSS patients were identified based on history, ophthalmologic examination, and ophthalmic ancillary testing, which highlight the importance of these practices; and this suggests that clinicians can accurately identify idiopathic VS and VSS.

A complete understanding of the pathophysiology of VSS is lacking, but it is generally understood to be a disorder of visual processing. Using conventional 1.5-T and 3-T MRI, functional MRI, positron emission tomography, and electrophysiology, several authors have offered explanations including a thalamo-cortical dysrhythmia of the visual pathway (14), hyperexcitation of primary and secondary visual cortices (6), increased saliency of normally ignored subcortical activity (15), or some combination of these mechanisms (16). Advanced neuroimaging and neurophysiological studies have uncovered structural, metabolic, and physiological differences in the brains of patients with VSS. These differences include increased gray matter volume in the left primary and secondary visual cortices, the left visual motion area V5, and the left cerebellar crus (3) and hypermetabolism of the right lingual gyrus (17). Patients with VSS have a higher regional cerebral blood flow than controls over an extensive brain network, suggesting that VSS patients have marked differences in brain processing of visual stimuli, validating its neurobiological basis (18). How these differences fit into the puzzle of VS and VSS pathophysiology is not fully understood; however, collectively, they support the notion that this is a disorder of cerebral visual processing. When understood as such, some of the important features of VS and VSS seem logical. A visual processing disorder would be expected to be present from an early age, to be constant and affecting the entirety of the visual field, and to be generally poorly responsive to

conventional pharmacologic therapies. Also, one would expect an association with other visual and perceptual symptoms, but to have normal visual function when measured with standard testing. These are all salient features of VS and VSS and can generally be elicited by careful history inquiry and examination.

Patients with VS and VSS do not generally have abnormalities on examination or ancillary testing (10) as in our patient population. However, although most cases of VS are spontaneous, potential secondary causes should be recognized including post-concussion, post-infection, hallucinogen-persisting perception disorder, idiopathic intracranial hypertension, neoplastic, and posterior cortical atrophy (19). Patients who develop VS after an inciting event or related to an underlying comorbidity may have a better prognosis than those in whom it develops spontaneously (19).

The treatments of VSS were reviewed by Eren et al. on data of 153 patients who were treated with 44 different medications. Only eight of the medications were effective at least once. Of all the medications prescribed, lamotrigine and topiramate had the best results, though they were effective in only 22.2 and 15.4% of patients, respectively (20). Other medications that have been studied include amitriptyline (which may worsen VS), benzodiazepines, acetazolamide, valproate, propranolol, naproxen, and sertraline (19, 20). There is no widely accepted standard treatment for VSS.

Limitations of our study include its retrospective nature. The cases were collected from multiple different providers and centers and therefore not standardized. All of our patients had VS, and eight of the 52 patients met the diagnostic criteria for VSS. We suspect that more of our patients would have met the criteria for VSS if not for the lack of a standardized questionnaire and retrospective nature of the study. The other limiting factor is that our various providers evaluated patients in different ways, and as we learned more about VS, the testing seemed to become more uniform.

To answer the question if non-ophthalmic ancillary testing is required in the typical patient who experiences classic VS and VSS symptoms, it appears as if VS is akin to conditions like acephalgic migraine or even much more remotely like blepharospasm, in that clinicians used to work these patients up until the literature proved no benefit to ancillary studies outside thorough history, examination, and neuro-ophthalmic testing (including pupillary exam, ocular motility, and automated visual field examinations), which should be performed on all VS patients. If etiologies other than typical VS are suspected, one should obtain ancillary testing including OCT, electrophysiology, and cranial neuroimaging.

## REFERENCES

1. Liu GT, Schatz NJ, Galetta SL, Volpe NJ, Skobieranda F, Kosmorsky GS. Persistent positive visual phenomena in migraine. *Neurology*. (1995) 45:664–8. doi: 10.1212/WNL.45.4.664
2. Schankin CJ, Maniyar FH, Digre KB, Goadsby PJ. “Visual snow”—a disorder distinct from persistent migraine aura. *Brain*. (2014) 137:1419–28. doi: 10.1093/brain/awu050

The key historical features of idiopathic VS and VSS are a non-progressive course and constant snowy visual phenomena that involve the entire visual field OU with onset at an early age. In addition, the presence of other features of VS and VSS including comorbid migraine and photophobia in this setting can help reassure the clinician that there is not a worrisome underlying pathology given a normal thorough neuro-ophthalmic examination including automated perimetry, which is essential in ruling out other eye and brain pathologies.

The diagnostic evaluation of VS and VSS patients should be made on a case-by-case basis; however, we propose that if VS originated at an early age, is non-progressive, and is typical in historical presentation and the patient has a normal neuro-ophthalmologic examination including automated perimetry, then ancillary testing is generally unnecessary.

## DATA AVAILABILITY STATEMENT

The raw data supporting the conclusions of this article will be made available by the authors, without undue reservation.

## ETHICS STATEMENT

The studies involving human participants were reviewed and approved by UAB Institutional Review Board for Human Use (IRB). Written informed consent from the participants' legal guardian/next of kin was not required to participate in this study in accordance with the national legislation and the institutional requirements.

## AUTHOR CONTRIBUTIONS

MV: conceptualization, methodology, data curation, writing—original draft preparation, visualization, investigation, supervision, and writing—reviewing and editing. BG: methodology, data curation, writing—original draft preparation, visualization, investigation, and writing—reviewing and editing. KC: data curation and preparation. SG: data curation, visualization, and investigation. JD: data curation. All authors contributed to the article and approved the submitted version.

## FUNDING

This work was supported in part by an unrestricted grant from the Research to Prevent Blindness, Inc., New York, NY.

3. Puledda F, Schankin C, Goadsby PJ. Visual snow syndrome: a clinical and phenotypical description of 1,100 cases. *Neurology*. (2020) 94:e564–74. doi: 10.1212/WNL.00000000000008909
4. Jäger HR, Giffin NJ, Goadsby PJ. Diffusion- and perfusion-weighted MR imaging in persistent migrainous visual disturbances. *Cephalalgia*. (2005) 25:323–32. doi: 10.1111/j.1468-2982.2004.00858.x



5. Traber GL, Piccirelli M, Michels L. Visual snow syndrome: a review on diagnosis, pathophysiology, and treatment. *Curr Opin Neurol.* (2020) 33:74–8. doi: 10.1097/WCO.0000000000000768
6. Eren O, Rauschel V, Ruscheweyh R, Straube A, Schankin CJ. Evidence of dysfunction in the visual association cortex in visual snow syndrome. *Ann Neurol.* (2018) 84:946–9. doi: 10.1002/ana.25372
7. Headache Classification Committee of the International Headache Society (IHS). The International Classification of Headache Disorders, 3rd edition. *Cephalalgia.* (2018) 38:1–211. doi: 10.1177/0333102417738202
8. White OB, Clough M, McKendrick AM, Fielding J. Visual snow: visual misperception. *J Neuroophthalmol.* (2018) 38:514–21. doi: 10.1097/WNO.0000000000000702
9. Puledda F, Schankin C, Digre K, Goadsby PJ. Visual snow syndrome: what we know so far. *Curr Opin Neurol.* (2018) 31:52–8. doi: 10.1097/WCO.0000000000000523
10. Yoo YJ, Yang HK, Choi JY, Kim JS, Hwang JM. Neuro-ophthalmologic findings in visual snow syndrome. *J Clin Neurol.* (2020) 16:646–52. doi: 10.3988/jcn.2020.16.4.646
11. Schankin CJ, Maniyar FH, Chou DE, Eller M, Sprenger T, Goadsby PJ. Structural and functional footprint of visual snow syndrome. *Brain.* (2020) 143:1106–13. doi: 10.1093/brain/awaa053
12. Chen BS, Lance S, Lallu B, Anderson NE. Visual snow: not so benign. *J Clin Neurosci.* (2019) 64:37–9. doi: 10.1016/j.jocn.2019.03.023
13. Piquet AL, Khan M, Warner JEA, Wicklund MP, Bennett JL, Leehey MA, et al. Novel clinical features of glycine receptor antibody syndrome. *Neurol Neuroimmunol Neuroinflamm.* (2019) 6:e592. doi: 10.1212/NXI.0000000000000592
14. Lauschke JL, Plant GT, Fraser CL. Visual snow: a thalamocortical dysrhythmia of the visual pathway? *J Clin Neurosci.* (2016) 28:123–7. doi: 10.1016/j.jocn.2015.12.001
15. Puledda F, Ffytche D, O'Daly O, Goadsby PJ. Imaging the visual network in the migraine spectrum. *Front Neurol.* (2019) 19:1325. doi: 10.3389/fneur.2019.01325
16. Puledda F, Ffytche D, Lythgoe DJ, O'Daly O, Schankin C, Williams SCR, et al. Insular and occipital changes in visual snow syndrome: a BOLD fMRI and MRS study. *Ann Clin Transl Neurol.* (2020) 7:296–306. doi: 10.1002/acn3.50986
17. Schankin CJ, Maniyar FH, Sprenger T, Chou DE, Eller M, Goadsby PJ. The relation between migraine, typical migraine aura and “visual snow”. *Headache.* (2014) 54:957–66. doi: 10.1111/head.12378
18. Puledda F, Schankin CJ, O'Daly O, Ffytche D, Eren O, Karsan N, et al. Localised increase in regional cerebral perfusion in patients with visual snow syndrome: a pseudo-continuous arterial spin labelling study. *J Neurol Neurosurg Psychiatry.* (2021) 92:918–26. doi: 10.1136/jnnp-2020-325881
19. Mehta DG, Garza I, Robertson CE. Two hundred and forty-eight cases of visual snow: A review of potential inciting events and contributing comorbidities. *Cephalalgia.* (2021) 41:1015–26. doi: 10.1177/03331024211996355
20. Eren O, Schankin CJ. Insights into pathophysiology and treatment of visual snow syndrome: a systematic review. *Prog Brain Res.* (2020) 255:311–26. doi: 10.1016/bs.pbr.2020.05.020

**Conflict of Interest:** The authors declare that the research was conducted in the absence of any commercial or financial relationships that could be construed as a potential conflict of interest.

**Publisher's Note:** All claims expressed in this article are solely those of the authors and do not necessarily represent those of their affiliated organizations, or those of the publisher, the editors and the reviewers. Any product that may be evaluated in this article, or claim that may be made by its manufacturer, is not guaranteed or endorsed by the publisher.

Copyright © 2021 Vaphiades, Grondines, Cooper, Gratton and Doyle. This is an open-access article distributed under the terms of the Creative Commons Attribution License (CC BY). The use, distribution or reproduction in other forums is permitted, provided the original author(s) and the copyright owner(s) are credited and that the original publication in this journal is cited, in accordance with accepted academic practice. No use, distribution or reproduction is permitted which does not comply with these terms.



# Delayed Onset of Inhibition of Return in Visual Snow Syndrome

Paige J. Foletta<sup>1</sup>, Meaghan Clough<sup>1</sup>, Allison M. McKendrick<sup>2</sup>, Emma J. Solly<sup>1</sup>, Owen B. White<sup>1</sup> and Joanne Fielding<sup>1\*</sup>

<sup>1</sup> Department of Neuroscience, Central Clinical School, Monash University, Melbourne, VIC, Australia, <sup>2</sup> Department of Optometry and Vision Sciences, The University of Melbourne, Melbourne, VIC, Australia

## OPEN ACCESS

### Edited by:

Heather E. Moss,  
Stanford University, United States

### Reviewed by:

Prem Subramanian,  
University of Colorado, United States  
Michael S. Vaphiades,  
University of Alabama at Birmingham,  
United States

### \*Correspondence:

Joanne Fielding  
joanne.fielding@monash.edu

### Specialty section:

This article was submitted to  
Neuro-Ophthalmology,  
a section of the journal  
Frontiers in Neurology

**Received:** 09 July 2021

**Accepted:** 11 August 2021

**Published:** 17 September 2021

### Citation:

Foletta PJ, Clough M,  
McKendrick AM, Solly EJ, White OB  
and Fielding J (2021) Delayed Onset  
of Inhibition of Return in Visual Snow  
Syndrome. *Front. Neurol.* 12:738599.  
doi: 10.3389/fneur.2021.738599

Visual snow syndrome (VSS) is a complex, sensory processing disorder. We have previously shown that visual processing changes manifest in significantly faster eye movements toward a suddenly appearing visual stimulus and difficulty inhibiting an eye movement toward a non-target visual stimulus. We propose that these changes reflect poor attentional control and occur whether attention is directed exogenously by a suddenly appearing event, or endogenously as a function of manipulating expectation surrounding an upcoming event. Irrespective of how attention is captured, competing facilitatory and inhibitory processes prioritise sensory information that is important to us, filtering out that which is irrelevant. A well-known feature of this conflict is the alteration to behaviour that accompanies variation in the temporal relationship between competing sensory events that manipulate facilitatory and inhibitory processes. A classic example of this is the “Inhibition of Return” (IOR) phenomenon that describes the relative slowing of a response to a validly cued location compared to invalidly cued location with longer cue/target intervals. This study explored temporal changes in the allocation of attention using an ocular motor version of Posner’s IOR paradigm, manipulating attention exogenously by varying the temporal relationship between a non-predictive visual cue and target stimulus. Forty participants with VSS (20 with migraine) and 20 controls participated. Saccades were generated to both validly cued and invalidly cued targets with 67, 150, 300, and 500 ms cue/target intervals. VSS participants demonstrated delayed onset of IOR. Unlike controls, who exhibited IOR with 300 and 500 ms cue/target intervals, VSS participants only exhibited IOR with 500 ms cue/target intervals. These findings provide further evidence that attention is impacted in VSS, manifesting in a distinct saccadic behavioural profile, and delayed onset of IOR. Whether IOR is perceived as the build-up of an inhibitory bias against returning attention to an already inspected location or a consequence of a stronger attentional orienting response elicited by the cue, our results are consistent with the proposal that in VSS, a shift of attention elicits a stronger increase in saccade-related activity than healthy controls. This work provides a more refined saccadic behavioural profile of VSS that can be interrogated further using sophisticated neuroimaging techniques and may, in combination with other saccadic markers, be used to monitor the efficacy of any future treatments.

**Keywords:** visual snow, visual snow syndrome, visual processing, attention, inhibition of return, ocular motor

## INTRODUCTION

Visual Snow Syndrome (VSS) is a complex sensory disorder that diagnostically manifests in a range of debilitating visual symptoms, at its core, a persistent positive visual disturbance known as visual snow (1). While not included among the syndrome's diagnostic criteria, VSS participants often also experience other non-visual sensory changes, like tinnitus, migraine, paraesthesia, and depersonalisation. Unfortunately, there are no effective treatments for VSS, largely a consequence of an unknown aetiology. Current theories propose either widespread dysfunction of higher order visual processing areas (2–6), or direct thalamic dysfunction (7), although, as yet, the body of research conducted is small and inconclusive.

With the aim to provide objective evidence of neuropathological changes in VSS, our previous studies have investigated visual processing performance in VSS individuals using highly sensitive ocular motor (OM) tasks (8, 9). The first of these studies (8) demonstrated that participants with VSS generated faster eye movements toward suddenly appearing visual stimuli and failed more often to inhibit erroneous eye movements to stimuli not consistent with task demands. We also showed that this occurred irrespective of the complexity of the task presented. While we attributed this pattern of response to alterations in the early processing of visual stimuli within the visual regions of the cortex, we subsequently proposed that these results might also be interpreted as a more rapid shift of attention.

Our second study (9) sought to determine whether volitional shifts of attention elicited by a cue (endogenous driven shifts of attention), were similarly impaired, and revealed that VSS participants again failed more often to inhibit erroneous eye movements toward non-target locations. This demonstrated that attentional changes are evident in VSS irrespective of whether attention is directed exogenously by a suddenly appearing stimulus, or endogenously by manipulating expectation surrounding an upcoming event. We concluded that both exogenous and endogenous shifts of attention more strongly increase saccade-related activity in VSS, affecting the fine balance between saccade facilitation and inhibition, and manifesting as increased erroneous release of saccades to task irrelevant locations (increased errors) and altered saccade latency profiles.

Importantly, recent evidence has provided support for our supposition, with disruption reported in several cortical regions involved in the control of attention. For example, neuroimaging studies in VSS have found changes in grey matter volumes and reduced Blood Oxygenation Level-Dependent (BOLD) responses to visual stimulation similar to VS in several brain regions involved in attentional orienting, including the supramarginal gyrus and frontal eye fields (10). Widespread disruption has also been revealed in the functional connectivity of several brain systems, including attentional networks (5, 11). White matter abnormalities have been reported in the temporo-parieto-occipital junction in pathways related to vision (12). However, it is still unclear whether the attentional changes within the visual system indeed affect the balance between saccade facilitation and inhibition, in turn affecting the timing of saccade latencies.

Here we explored temporal changes in the allocation of attention in participants with VSS using a classic Posner style spatial cueing paradigm (13). This paradigm manipulates attention exogenously by varying the temporal relationship between a non-predictive visual cue and a target stimulus. Specifically, a cue, such as a peripheral flash or change in luminance is presented prior to the presentation of a peripheral target, either in the same location as the target (valid cue) or in a different location to the target (invalid cue). Thus, the peripheral cue orientates attention to the cued location prior to the onset of a target. However, the effect of the cue varies as a function of the temporal relationship between the cue and target, or the stimulus onset asynchrony (SOA). Where there is a short delay between cue and target, the cue facilitates a subsequent response toward that location and delays a subsequent response away from that location. However, where there is a longer delay between cue and target, this relationship is reversed with a slower response to a target presented in the same location as the previously presented cue relative to a target presented elsewhere. The relative slowing of a response to a validly cued location is known as inhibition of return (IOR) and is attributed to the build-up of an inhibitory bias against returning attention to an already inspected location (14).

Disruption to neural function has been shown to alter the timepoint at which IOR occurs (i.e., transition from facilitation to inhibition for a validly cued trial). For example, using a modified ocular motor version of Posner's spatial cueing paradigm, Larrison-Faucher et al. (15) found a delay in the onset of IOR for patients diagnosed with schizophrenia. The authors attributed this to a delay in the build-up of inhibition toward the cued location. Conversely, Fielding et al. (16) reported accelerated onset of IOR in a group of patients with Huntington's disease. This was attributed to the altered inhibitory output of the basal ganglia and the premature disengagement (or removal of facilitatory activity) from a cued location.

We presented VSS participants with an ocular motor version of the spatial cueing paradigm to assess the time-course of IOR. Given that we have previously demonstrated stronger attentional capture by suddenly appearing stimuli in VSS participants, we anticipated that the transition to IOR might be delayed, a consequence of a stronger facilitatory effect of the cue, and that VSS participants would generate more erroneous saccades to cue stimuli. We propose that clarifying changes in the exogenous orienting of attention in VSS participants will enable us to develop a more refined objective behavioural marker of VSS that may be used to guide future research into mechanisms of dysfunction or as an objective outcome measure in treatment trials.

## METHOD

### Participants

Forty participants meeting the criteria for VSS as specified by the International Classification of Headache Disorders (ICHD: see **Table 1**) were recruited through a combination of online, radio and television advertising. Equivalent numbers of VSS participants with and without a history of migraine enabled us

**TABLE 1** | International classification of headache disorders (ICHD-3) criteria for a diagnosis of visual snow syndrome.

A	Visual snow: dynamic, continuous, tiny dots across the entire visual field persisting for > 3 months
B	Additional visual symptoms of at least two of the following four types: <ol style="list-style-type: none"> <li>i. Palinopsia.</li> <li>ii. Enhanced entoptic phenomena.</li> <li>iii. Photophobia</li> <li>iv. Nyctalopia (impaired night vision)</li> </ol>
C	Symptoms are not consistent with typical migraine visual aura
D	Symptoms are not better accounted for by another disorder

to determine whether any behavioural changes revealed in VSS participants were attributable to the presence of migraine. Of those with a history of migraine, none reported experiencing a migraine and/or migraine aura in the 3 days prior to or following testing. However, a series of analyses of variance (ANOVAs) between VSS participants with and without migraine revealed no significant differences between groups for any experimental variable (**Table 2**); consequently, data for all VSS participants were combined into a single group.

All VSS participants underwent a full ophthalmological examination to exclude any visual processing deficit. This involved an assessment of visual acuity, colour vision and retinal anatomy and function. Twenty neurologically healthy controls were recruited from the community. None reported a history of migraine. Exclusion criteria for all participants was the presence of a confounding neurological condition or the use of medication likely to affect vision or cognitive function.

All participants were asked to complete an online battery of questionnaires; 4 participants with VSS failed to fully complete the battery (two with migraine and two without) as did three healthy controls. The Alcohol Use Disorders Identification Test [AUDIT; (17)] and the Drug Use Disorders Identification test [DUDIT; (18)] were used to identify any substance abuse problems; scores on these measures did not differ significantly between controls and VSS participants. The National Adult Reading Test [NART; (19)] provided an estimate of intelligence. Again, no differences were revealed between groups. However, VSS participants scored higher on the Fatigue Severity Scale [FSS; (20)] [ $F_{(1,51)} = 7.01, p = 0.010$ ], and the Depression Anxiety Stress Scale [DASS; (21)] over the past week; levels of depressive symptomatology [ $F_{(1,51)} = 5.84, p = 0.019$ ] and stress [ $F_{(1,51)} = 5.05, p = 0.029$ ].

**Table 2** provides a summary of demographic information for all participants, including a prevalence of commonly co-occurring visual symptoms associated with VSS.

## Procedure

All testing was conducted at the Central Clinical School in the Alfred Centre, Monash University, Australia. Ethical approval was granted by Monash University Human Research Ethics Committee. All participants provided informed consent prior to inclusion in the study in accordance with the Declaration of Helsinki.

## Ocular Motor Spatial Cueing Task

Participants were seated in a darkened, quiet room, on a height adjustable chair in front of a monitor at a distance of 950 mm. A head and chin rest maximised head stability during recording. Displacement of the eye was recorded using an Eyelink 1,000+ dark pupil video-oculography system, which features high resolution (noise limited at  $<0.01^\circ$ ), and a high acquisition rate (1,000 Hz). Task stimuli comprised a white centrally located fixation cross ( $17 \times 17$  mm) on a black background with two white boxes ( $34 \times 34$  mm) situated eight degrees left and right of fixation. Green target crosses ( $25.5 \times 25.5$  mm) were presented in the centre of one of the two white boxes.

The task used was a modified version of Posner and Cohen's (22) IOR paradigm. In total, the task comprised 246 randomly presented trials with breaks to mitigate fatigue. Participants were required to fixate on a central cross. Following 850 ms, one of the two peripheral boxes was illuminated for 50 ms. Participants were instructed to ignore this event and to maintain their gaze on the central cross. Following a variable delay of 17, 100, 250, or 450 ms, the central cross disappeared, and a green target cross appeared in either of the two peripheral boxes. This resulted in four stimulus onset asynchronies (SOAs); 67, 150, 250, and 500 ms, as used previously in saccadic IOR tasks (23). Participants were instructed to make an eye movement toward the target cross as soon as it appeared. Following 1,500 ms, gaze was reoriented back to centre by the presentation a small white square in preparation for the next trial.

Three trial types were included, determined by the relative location of the cue and target.

- Valid trial—cue and target presented in the same hemifield
- Invalid trial—cue presented in the hemifield opposite to the target
- Catch trial—cue presented but with no subsequent target; to reduce the likelihood of anticipatory responses.

The illumination of the box was not predictive of an upcoming target; on 50% of trials the green cross subsequently appeared in the illuminated box (valid trials), and on 50% of trials, the green cross appeared in the opposite box (invalid trials). A schematic diagram of a Valid trial is provided in **Figure 1**.

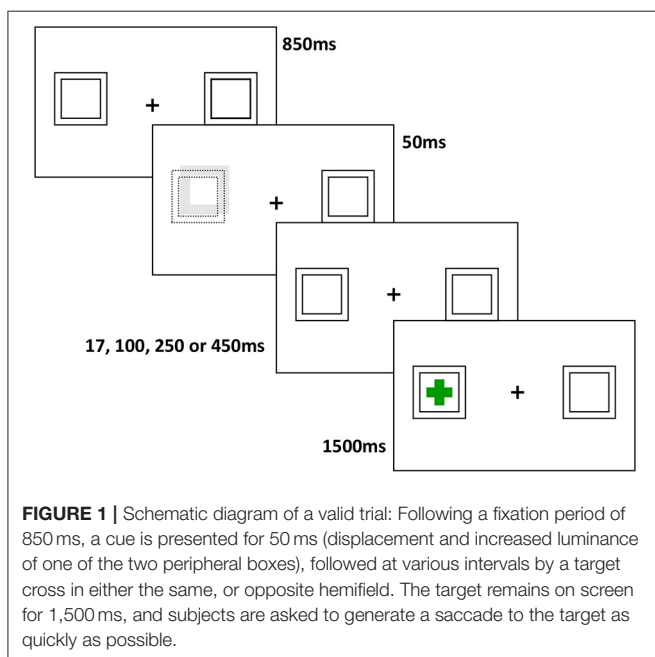
## Data Analysis

Output from the video-oculographic system was analysed using customised software written in MATLAB. Variables of interest were error rate and saccade latency (ms). An error was defined as an eye movement exceeding 1.5 degrees in the direction of the illuminated box prior to or within 100 ms of the presentation of the target cross and calculated as proportion of total trials. Saccade latency reflected the onset of a saccade minus target presentation time. Saccade onset was determined as displacement of the eyes from central fixation, corresponding with a change in the velocity profile of the saccade trace ( $>30$  degrees per second). Trials were removed from analysis of latency if an error was performed, fixation was not maintained within 2 degrees of the central cross or a blink occurred at target or saccade onset or no response was made.

**TABLE 2** | Demographic information for all participants.

	VSS Mean (SD) n = 20	VSS + Migraine Mean (SD) n = 20	Controls Mean (SD) n = 20
Female/male	9/11	15/5	13/7
Age/distribution	25.35/16–54	28.05/20–50	25.60/15–51
Visual snow			
Duration (years)	16.69 (13.34)	14.90 (12.29)	
Participants with lifelong duration (%)	55	45	
Afterimages (%)	83.3	88.9	
Photophobia (%)	88.9	83.3	
Nyctalopia (%)	77.8	61.1	
Floaters (%)	72.2	88.9	
Blue field entoptic phenomenon (%)	55.6	72.2	
Tinnitus (%)	55.6	66.7	
Paraesthesia (%)	33.3	33.3	
Family history of migraine	44.4	55.6	
Relative with VS (%)	0	5.6	
DASS	8.78 (9.84)	8.28 (8.02)	3.06 (4.15)
Depression			
Anxiety	5.72 (5.29)	6.50 (5.60)	3.65 (3.97)
Stress	13.17 (9.56)	11.61 (9.11)	6.82 (6.28)
AUDIT	5.06 (5.18)	4.72 (4.57)	3.00 (2.35)
DUDIT	0.5 (1.25)	1.89 (4.51)	0.42 (1.28)
FSS	36.5 (12.20)	39.72 (12.21)	29.06 (10.22)
NART	115.17 (5.26)	114.26 (5.07)	115.75 (7.22)

DASS, Depression Anxiety Stress Scale; AUDIT, Alcohol Use Disorders Identification Test; DUDIT, Drug Use Disorders Identification test; FSS, Fatigue Severity Scale; NART, National Adult Reading Test.



A two-way ANOVA was conducted to compare error rates between groups, with between-subjects factor of Group (VSS vs. Controls) and within-subjects factor of SOA (67, 150, 300, and 500 ms). Eligible latency trials were submitted to a 3-way ANOVA with between-subjects factor of Group (VSS vs. Controls) and within-subjects factor of SOA (67, 150, 300, and 500 ms) and Trial Type (Valid vs. Invalid). *Post-hoc* analyses were conducted using ANOVA. Where DASS depression, stress or FSS scores significantly correlated with any experimental variable, these scores were used as a covariate.

To assess whether the onset of IOR differed between groups, planned comparisons were conducted at each SOA, with valid and invalid trial latencies compared for each Group.

Correlational analyses were conducted using either Pearson's *r* or Spearman's rho between OM and clinical variables.

## RESULTS

Mean latencies and error rates for controls and VSS participants can be found in **Table 3**.

**TABLE 3** | Means and standard deviations for ocular motor task variables.

	Controls Mean (SD) <i>n</i> = 20	VSS Mean (SD) <i>n</i> = 40
<b>Latencies (ms)</b>		
Invalid SOA 67	342.93 (34.10)	361.67 (43.30)
Invalid SOA 150	330.06 (30.73)	341.75 (46.91)
Invalid SOA 300	315.37 (34.96)	322.92 (45.92)
Invalid SOA 500	290.64 (36.97)	312.77 (45.64)
Valid SOA 67	323.07 (40.73)	326.66 (37.72)
Valid SOA 150	325.52 (32.39)	326.06 (43.96)
Valid SOA 300	325.34 (36.27)	326.52 (38.40)
Valid SOA 500	314.83 (35.57)	331.85 (43.41)
<b>Error rate (%)</b>		
SOA 67	1.25 (3.27)	2.97 (5.83)
SOA 150	4.27 (6.53)	4.69 (6.44)
SOA 300	15.73 (10.06)	15.57 (12.08)
SOA 500	17.60 (13.69)	18.33 (14.50)

SOA, Stimulus Onset Asynchrony.

## Latency

A significant main effect of SOA was found [ $F_{(2.70,156.51)} = 22.28$ ,  $p < 0.001$ ,  $\eta_p = 0.28$ ], demonstrating that, overall, latencies decreased with increasing SOA. As anticipated a significant trial  $\times$  SOA interaction was found [ $F_{(2.58,149.67)} = 25.38$ ,  $p < 0.001$ ,  $\eta_p = 0.304$ ]. This was due to the well-known effect of the cue in the IOR task; faster latencies were found for valid trials at shorter SOAs and faster latencies for invalid trials at longer SOAs. A significant group and Trial type interaction [ $F_{(1,58)} = 4.11$ ,  $p = 0.047$ ,  $\eta_p = 0.066$ ] demonstrated significantly longer invalid trial latencies than valid trial latencies, overall, for VSS participants only (MD = 7.00,  $p = 0.012$ ). No other effects or interactions were found.

A series of planned comparisons revealed that with 67 ms SOAs, invalid trial latencies were significantly longer than valid trial latencies for both controls ( $p < 0.001$ ) and VSS participants ( $p < 0.001$ ), demonstrating the facilitatory effect of the cue at this SOA. With 500 ms SOAs, valid trials latencies were significantly longer than invalid trial latencies for controls ( $p < 0.001$ ) and VSS participants ( $p < 0.001$ ), reflecting the IOR effect at this SOA for both groups.

However, for controls only, there were no significant differences between trial types with 150 ms SOAs ( $p = 0.48$ ), indicating onset of IOR at around 150 ms; for VSS participants, invalid trial latencies were still significantly longer than valid trial latencies ( $p = 0.02$ ). IOR emerged later for VSS participants, for 300 ms SOAs, where there were no significant differences in latency between trial types ( $p = 0.48$ ). For controls, latencies for valid trials were longer than latencies for invalid trials at this SOA ( $p = 0.03$ ). The differences between valid and invalid trials latencies are represented in **Figure 2**.

## Error Rate

A significant main effect of SOA was found [ $F_{(2.48,143.64)} = 44.00$ ,  $p < 0.001$ ,  $\eta_p = 0.43$ ], demonstrating that error rate increased as SOA increased. No group effect or interaction was revealed.

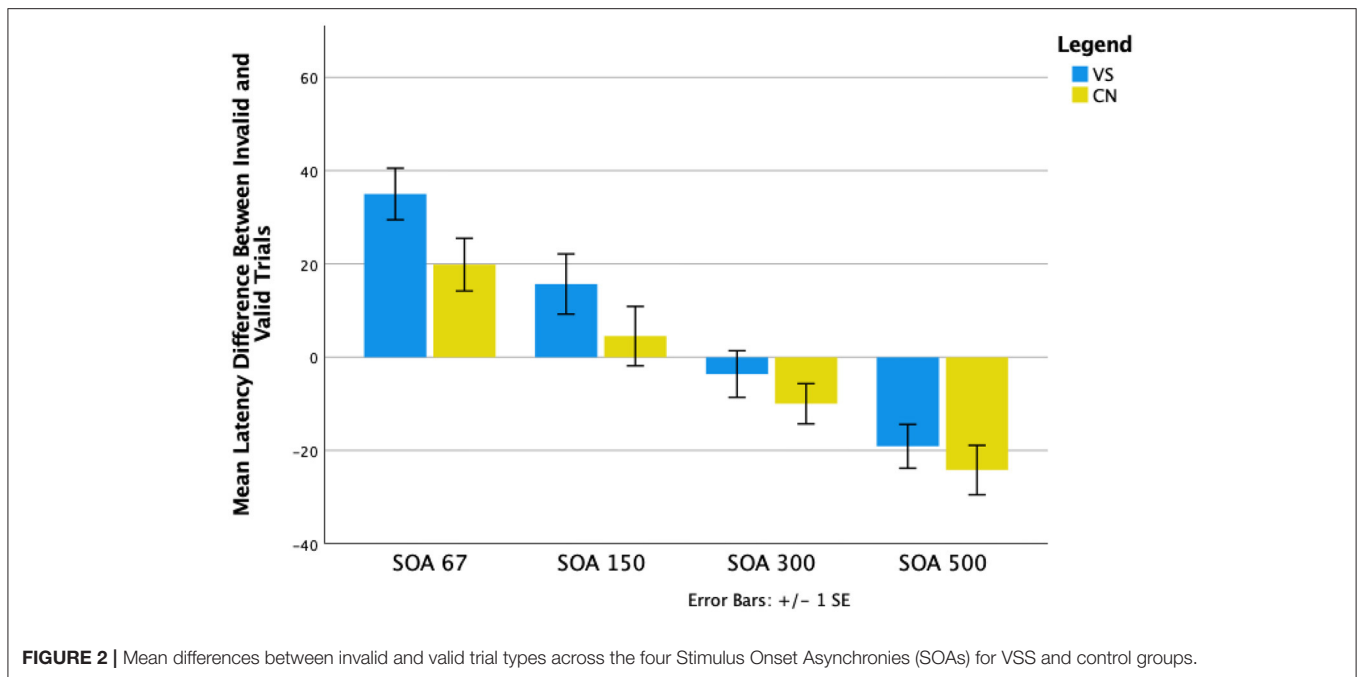
## Correlations

There were no significant correlations between any OM and clinical variable after Bonferroni adjustments for multiple comparisons were applied.

## DISCUSSION

We have previously demonstrated VSS-specific alterations to visual processing that are consistent with stronger attentional capture (8, 9). We propose that the corresponding imbalance between saccade facilitation and inhibition results in an increased number of erroneous saccades and shorter saccade latencies. Here we explicitly explored this proposal by manipulating the time course and strength of exogenous attentional capture using a classic ocular motor Posner spatial cueing paradigm, which is known to affect the temporal profile of saccade latencies. Specifically, we manipulated the time between presentation of a non-informative visual cue and a subsequent target. As expected, when the time interval between cue and target was short, saccade latencies to correctly cued locations (valid trials) were shorter than incorrectly cued locations (invalid trials) for both VSS participants and controls. Further, when the time interval between cue and target increased (to 500 ms), the cue-target relationship was inverted for both groups manifesting in IOR with saccades to invalidly cued targets generated more quickly than saccades to validly cued targets. However, the time point at which IOR occurred, differed significantly between groups. While the onset of IOR occurred at around 150ms for controls, IOR was delayed for VSS participants and was only evident at around 300 ms. This suggests a relative imbalance between facilitatory and inhibitory saccade activity in VSS participants, altering the relationship between cue and target activity. Unexpectedly, VSS participants did not generate more erroneous saccades to cue stimuli than controls.

A number of cortical and subcortical regions have been identified as important for the generation of IOR. These include the frontal and supplementary eye fields, the supramarginal gyrus, ventrolateral nucleus of the thalamus, inferior parietal lobule and the anterior cingulate cortex (24, 25), as well as networks connecting frontal and parietal regions (26, 27). These regions and tracts generate and transmit facilitatory and/or inhibitory signals regarding saccade generation, which converge and are balanced topographically within the superior colliculus (SC). The outcome is either the execution or inhibition of a saccade (28). However, when a cue is presented at the target location shortly before the visual target, there is an overlap of cue/target activity arriving at and generated within the SC that increases saccade-related activity. As activity is brought closer to threshold for release, saccade latency is also reduced (29). When a target and cue are presented in different locations, i.e., an invalid trial, there is no overlap between cue and target activity; activity decreases as the result of local inhibition within the SC (30). As a result, baseline activity is reduced when the cue appears rather than increased as seen when cue and target are in the same location, and saccades are initiated with relatively longer latencies. However, as the time between cue and target increases,



the relationship between cue and target activity alters. At longer SOAs, there is no longer overlap between target and cue activity; target-aligned activity appears to be inhibited within the SC. As a result of this reduction in activity, threshold for release of a saccade for a validly cued target is delayed relative to an invalidly cued target (31).

For VSS participants, this shift from facilitation to inhibition of a saccade toward a validly cued target was delayed compared to controls, suggesting that the overlap between cue and target activity for these trials was relatively increased, resulting in greater target-aligned activity. This increase in target-aligned activity might persist longer and require less saccade-related activity to generate a response. This alteration in SC activity is likely a consequence of disruption to signals arising from other regions of the brain (28). Indeed, similar patterns of activation to that seen in the SC has been observed in the visual cortex in both human and primate studies (31, 32). In VSS, recent studies have demonstrated functional and structural alterations within the primary visual cortex (V1) (33) and ventral visual regions (34). Hypermetabolism and cortical volume increases have been reported at the intersection of the right lingual and fusiform gyri (35), and resting-state functional MRI data revealed hyperconnectivity between extrastriate and inferior temporal brain regions as well as prefrontal and parietal regions (11). While it is not possible to determine the source (cortical/subcortical location) or mechanism (increased facilitation and/or reduced inhibition) of the proposed increase in activity, we do not believe that it is being driven by frontally mediated changes altering inhibitory activity. As indicated earlier, delayed IOR onset has been reported in patients with schizophrenia (15, 36, 37). However, these individuals also tend to make more errors than healthy controls, unlike our VSS group.

Researchers have attributed this to the pathological changes observed in the frontal cortex of participants with schizophrenia (38, 39), which disrupts the inhibition of irrelevant responses (40, 41). Given our prior findings of a speeded visually guided response and lack of deficit with respect to frontally mediated task-switching, cueing and Simon effects (8, 9), we suggest that this is not the case with VSS participants. Instead, we propose that the differences found here with respect to the time-course of IOR are likely due to enhanced early facilitation of saccade-related activity as a consequence of altered activation within early visual processing regions of the brain and/or disruption to thalamocortical networks.

While the pathophysiology underlying VSS is unclear, a commonly described consequence appears to be that of cortical hyperexcitability within, and beyond, the brain's visual processing regions (4, 35, 42, 43). While the SC is not directly implicated in VSS pathology, it receives input from areas previously described, including the visual cortex, frontal eye fields, and parietal cortex (44, 45). Consistent with our results here and in previous research, increased excitability within the visual cortex might increase SC activity to both the cue and target via these projections; resulting in greater and longer overlap in cue and target-aligned activity within the SC. Persistence, a consequence of this overlap, would present behaviourally as a stronger capture of attention and interruption to the onset of IOR, as was seen in our participants with VSS.

With respect to the unexpected finding in VSS that these individuals did not generate more erroneous saccades to cue stimuli than controls, it is conceivable that this reflects the relevance of the cue stimulus. Unlike our previous studies (8, 9), the visual cue used here bears no relationship with the required

response. It does not *predict* the location of the up-coming target, as does the cue in the endogenously cued saccade paradigm (9), and it does not provide information about where a person *should* look as in the visually guided saccade paradigm or directive stimuli used in the antisaccade (8) or Simon effect paradigms (9). In short, it is likely to engender less attentional capture than these previously used visual stimuli. While we demonstrate here what is likely to be enhanced facilitation by the cue, the increased level of activation of saccade-related neurons does not appear to exceed threshold for release, hence no more errors to cue stimuli than controls.

These findings, demonstrating differences in VSS in the temporal relationship between competing sensory events that manipulate facilitatory and inhibitory processes are consistent with our proposal that shifts of attention more strongly increase saccade-related activity in VSS. These changes conceivably reflect changes within thalamo-cortical processing networks, in particular attentional networks. This is the first study to assess temporal changes in allocation of visuospatial attention in VSS and provides a more refined saccadic behavioural profile of VSS that can be interrogated using sophisticated neuroimaging

techniques and may, in combination with other saccadic markers, be used to monitor the efficacy of any future treatments.

## DATA AVAILABILITY STATEMENT

The raw data supporting the conclusions of this article will be made available by the authors, without undue reservation.

## ETHICS STATEMENT

Ethical approval was granted by the Monash University Human Research Ethics Committee. All participants provided written informed consent prior to participation in the study in accordance with the declaration of Helsinki.

## AUTHOR CONTRIBUTIONS

Acquisition of data was handled by PF and ES. PF wrote the first draught of the manuscript. JF, MC, and OW supervised the project. All authors critically revised the manuscript and approved the submitted version.

## REFERENCES

- Schankin CJ, Maniyar FH, Digre KB, Goadsby PJ. 'Visual snow' - a disorder distinct from persistent migraine aura. *Brain*. (2014) 137 (Pt. 5):1419–28. doi: 10.1093/brain/awu050
- Eren O, Rauschel V, Ruscheweyh R, Straube A, Schankin CJ. Evidence of dysfunction in the visual association cortex in visual snow syndrome. *Ann Neurol*. (2018) 84:946–9. doi: 10.1002/ana.25372
- Luna S, Lai D, Harris A. Antagonistic relationship between vep potentiation and gamma power in visual snow syndrome. *Headache*. (2018) 58:138–44. doi: 10.1111/head.13231
- McKendrick AM, Chan YM, Tien M, Millist L, Clough M, Mack H, et al. Behavioral measures of cortical hyperexcitability assessed in people who experience visual snow. *Neurology*. (2017) 88:1243–9. doi: 10.1212/WNL.0000000000003784
- Puledda F, O'Daly O, Schankin C, Ffytche D, Williams SC, Goadsby PJ. Disrupted connectivity within visual, attentional and salience networks in the visual snow syndrome. *Hum Brain Mapp*. (2021) 42:2032–44. doi: 10.1002/hbm.25343
- Schankin C, Maniyar F, Sprenger T, Chou DE, Eller M, Goadsby PJ. The relation between migraine, typical migraine aura and visual snow (TM). *Headache*. (2014) 54:957–66. doi: 10.1111/head.12378
- Lauschke JL, Plant GT, Fraser CL. Visual snow: a thalamocortical dysrhythmia of the visual pathway? *J Clin Neurosci*. (2016) 28:123–7. doi: 10.1016/j.jocn.2015.12.001
- Solly E, Clough M, McKendrick A, Foletta MP, White O, Fielding J. Ocular motor measures of visual processing changes in visual snow syndrome. *Neurology*. (2020) 95:e1784–91. doi: 10.1212/WNL.00000000000010372
- Solly E, Clough M, McKendrick A, Foletta P, White O, Fielding J. Eye movement characteristics provide an objective measure of visual processing changes in patients with visual snow syndrome. *Sci Rep*. (2021) 11:9607. doi: 10.1038/s41598-021-88788-2
- Puledda F, Bruchhage M, O'Daly O, Ffytche D, Williams SCR, Goadsby PJ. Occipital cortex and cerebellum grey matter changes in visual snow syndrome. *Neurology*. (2020) 95:e1792–9. doi: 10.1212/WNL.00000000000010530
- Aldusary N, Traber GL, Freund P, Fierz FC, Weber KP, Baeshen A, et al. Abnormal connectivity and brain structure in patients with visual snow. *Front Hum Neurosci*. (2020) 14:582031. doi: 10.3389/fnhum.2020.582031
- Latini F, Fahlstrom M, Marklund N, Feresiadou A. White matter abnormalities in a patient with visual snow syndrome: new evidence from a diffusion tensor imaging study. *Eur J Neurol*. (2021) 28:2789–93. doi: 10.1111/ene.14903
- Posner MI. Orienting of attention. *Q J Exp Psychol*. (1980) 32:3–25. doi: 10.1080/0033558008248231
- Posner MI, Rafal RD, Choate LS, Vaughan J. Inhibition of return: neural basis and function. *Cogn Neuropsychol*. (1985) 2:211–28. doi: 10.1080/02643298508252866
- Larrison-Faucher A, Briand KA, Sereno AB. Delayed onset of inhibition of return in schizophrenia. *Prog Neuro Psychopharmacol Biol Psychiatry*. (2002) 26:505–12. doi: 10.1016/S0278-5846(01)00298-6
- Fielding J, Georgiou-Karistianis N, White O. The role of the basal ganglia in the control of automatic visuospatial attention. *J Int Neuropsychol Soc*. (2006) 12:657–67. doi: 10.1017/S1355617706060784
- Saunders JB, Aasland OG, Babor TF, de la Fuente JR, Grant M. Development of the alcohol use disorders identification test (AUDIT): WHO collaborative project on early detection of persons with harmful alcohol consumption—II. *Addiction*. (1993) 88:791–804. doi: 10.1111/j.1360-0443.1993.tb02093.x
- Berman AH, Bergman H, Palmstierna T, Schlyter F. Evaluation of the drug use disorders identification test (DUDIT) in criminal justice and detoxification settings and in a Swedish population sample. *Eur Addict Res*. (2005) 11:22–31. doi: 10.1159/000081413
- Nelson HE. *The National Adult Reading Test (NART): Test Manual*. Windsor: NFER-Nelson (1982).
- Krupp LB, LaRocca NG, Muir-Nash J, Steinberg AD. The fatigue severity scale. Application to patients with multiple sclerosis and systemic lupus erythematosus. *Arch Neurol*. (1989) 46:1121–3. doi: 10.1001/archneur.1989.00520460115022
- Lovibond SH, Lovibond PF. *Manual for the Depression Anxiety & Stress Scales*. Sydney, NSW: Psychology Foundation (1995). doi: 10.1037/t01004-000
- Posner MI, Cohen Y. *Components of Visual Orienting, in Attention and Performance*, Bouma H, Bouwhuis DG, editors. Hillsdale, NJ: Erlbaum (1984)



23. Fielding J, Georgiou-Karistianis N, Bradshaw J, Millist L, Churchyard A, White O. Accelerated time-course of inhibition of return in Huntington's disease. *Behav Brain Res.* (2006) 166:211–9. doi: 10.1016/j.bbr.2005.08.004
24. Lepsien J, Pollmann S. Covert reorienting and inhibition of return: an event-related fMRI study. *J Cogn Neurosci.* (2002) 14:127–44. doi: 10.1162/089892902317236795
25. Mayer AR, Seidenberg M, Dorflinger JM, Rao SC. Event-related fMRI study of exogenous orienting: supporting evidence for the cortical basis of inhibition of return. *J Cogn Neurosci.* (2004) 16:1262–71. doi: 10.1162/0898929041920531
26. Ro T, Farne A, Chang E. Inhibition of return and the human frontal eye fields. *Exp Brain Res.* (2003) 150:290–6. doi: 10.1007/s00221-003-1470-0
27. Chica AB, Bartolomeo P, Valero-Cabre A. Dorsal and ventral parietal contributions to spatial orienting in the human brain. *J Neurosci.* (2011) 31:8143–9. doi: 10.1523/JNEUROSCI.5463-10.2010
28. Dorris MC, Klein C, Everling S, Munoz DP. Contribution of the primate superior colliculus to inhibition of return. *J Cogn Neurosci.* (2002) 14:1256–63. doi: 10.1162/089892902760807249
29. Bell AH, Fecteau JH, Munoz DP. Using auditory and visual stimuli to investigate the behavioral and neuronal consequences of reflexive covert orienting. *J Neurophysiol.* (2004) 91:2172–84. doi: 10.1152/jn.01080.2003
30. Munoz DP, Istvan PJ. Lateral inhibitory interactions in the intermediate layers of the monkey superior colliculus. *J Neurophysiol.* (1998) 79:1193–209. doi: 10.1152/jn.1998.79.3.1193
31. Anderson EJ, Rees G. Neural correlates of spatial orienting in the human superior colliculus. *J Neurophysiol.* (2011) 106:2273–84. doi: 10.1152/jn.00286.2011
32. Muller NG, Kleinschmidt A. Temporal dynamics of the attentional spotlight: neuronal correlates of attentional capture and inhibition of return in early visual cortex. *J Cogn Neurosci.* (2007) 19:587–93. doi: 10.1162/jocn.2007.19.4.587
33. Puledda F, Ffytche D, Lythgoe DJ, O'Daly O, Schankin C, Williams SCR, et al. Insular and occipital changes in visual snow syndrome: a BOLD fMRI and MRS study. *Ann Clin Transl Neurol.* (2020) 7:296–306. doi: 10.1002/acn3.50986
34. Shibata M, Tsutsumi K, Iwabuchi Y, Kameyama M, Takizawa T, Nakahara T, et al. [(123)I]-IMP single-photon emission computed tomography imaging in visual snow syndrome: a case series. *Cephalalgia.* (2020) 40:1671–5. doi: 10.1177/0333102420950454
35. Schankin CJ, Maniyar FH, Chou DE, Eller M, Sprenger T, Goadsby PJ. Structural and functional footprint of visual snow syndrome. *Brain.* (2020) 143:1106–13. doi: 10.1093/brain/awaa053
36. Huey ED, Wexler BE. Abnormalities in rapid, automatic aspects of attention in schizophrenia: blunted inhibition of return. *Schizophr Res.* (1994) 14:57–63. doi: 10.1016/0920-9964(94)90009-4
37. Sapir A, Henik A, Dobrusin M, Hochman EY. Attentional asymmetry in schizophrenia: disengagement and inhibition of return deficits. *Neuropsychology.* (2001) 15:361–70. doi: 10.1037/0894-4105.15.3.361
38. Rimol LM, Nesvag R, Hagler DJ Jr, Bergmann O, Fennema-Notestine C, Hartberg CB, et al. Cortical volume, surface area, and thickness in schizophrenia and bipolar disorder. *Biol Psychiatry.* (2012) 71:552–60. doi: 10.1016/j.biopsych.2011.11.026
39. Honea R, Crow TJ, Passingham D, Mackay CE. Regional deficits in brain volume in schizophrenia: a meta-analysis of voxel-based morphometry studies. *Am J Psychiatry.* (2005) 162:2233–45. doi: 10.1176/appi.ajp.162.12.2233
40. Picton TW, Stuss DT, Alexander MP, Shallice T, Binns MA, Gillingham S. Effects of focal frontal lesions on response inhibition. *Cereb Cortex.* (2007) 17:826–38. doi: 10.1093/cercor/bhk031
41. Sharp DJ, Bonnelle V, De Boissezon X, Beckmann CF, James SG, Patel MC, et al. Distinct frontal systems for response inhibition, attentional capture, error processing. *Proc Natl Acad Sci USA.* (2010) 107:6106–11. doi: 10.1073/pnas.1000175107
42. Schankin CJ, Goadsby PJ. Visual snow-persistent positive visual phenomenon distinct from migraine aura. *Curr Pain Headache Rep.* (2015) 19:23. doi: 10.1007/s11916-015-0497-9
43. Yildiz FG, Turkyilmaz U, Unal-Cevik I. The clinical characteristics and neurophysiological assessments of the occipital cortex in visual snow syndrome with or without migraine. *Headache.* (2019) 59:484–94. doi: 10.1111/head.13494
44. Fries W. Cortical projections to the superior colliculus in the macaque monkey: a retrograde study using horseradish peroxidase. *J Comp Neurol.* (1984) 230:55–76. doi: 10.1002/cne.902300106
45. Field CB, Johnston K, Gati JS, Menon RS, Everling S. Connectivity of the primate superior colliculus mapped by concurrent microstimulation and event-related fMRI. *PLoS ONE.* (2008) 3:e3928. doi: 10.1371/journal.pone.0003928

**Conflict of Interest:** The authors declare that the research was conducted in the absence of any commercial or financial relationships that could be construed as a potential conflict of interest.

**Publisher's Note:** All claims expressed in this article are solely those of the authors and do not necessarily represent those of their affiliated organizations, or those of the publisher, the editors and the reviewers. Any product that may be evaluated in this article, or claim that may be made by its manufacturer, is not guaranteed or endorsed by the publisher.

Copyright © 2021 Foletta, Clough, McKendrick, Solly, White and Fielding. This is an open-access article distributed under the terms of the Creative Commons Attribution License (CC BY). The use, distribution or reproduction in other forums is permitted, provided the original author(s) and the copyright owner(s) are credited and that the original publication in this journal is cited, in accordance with accepted academic practice. No use, distribution or reproduction is permitted which does not comply with these terms.



# Widespread White Matter Alterations in Patients With Visual Snow Syndrome

Lars Michels<sup>1\*</sup>, Philipp Stämpfli<sup>2</sup>, Njoud Aldusary<sup>1,3</sup>, Marco Piccirelli<sup>1</sup>, Patrick Freund<sup>4</sup>, Konrad P. Weber<sup>5</sup>, Fabienne C. Fierz<sup>6</sup>, Spyros Kollias<sup>1</sup> and Ghislaine Traber<sup>7,8</sup>

<sup>1</sup> Department of Neuroradiology, Clinical Neuroscience Center, University Hospital Zurich and University of Zurich, Zurich, Switzerland, <sup>2</sup> Department of Psychiatry, Psychotherapy and Psychosomatics, Psychiatric Hospital, University of Zurich, Zurich, Switzerland, <sup>3</sup> Department of Diagnostic Radiology, Faculty of Applied Medical Sciences, King Abdulaziz University, Jeddah, Saudi Arabia, <sup>4</sup> Balgrist University Hospital, Zurich, Switzerland, <sup>5</sup> Department of Neurology, University Hospital Zurich and University of Zurich, Zurich, Switzerland, <sup>6</sup> Department of Ophthalmology, University Hospital Zurich and University of Zurich, Zurich, Switzerland, <sup>7</sup> Institute of Molecular and Clinical Ophthalmology Basel (IOB), Basel, Switzerland, <sup>8</sup> Department of Ophthalmology, University of Basel, Basel, Switzerland

## OPEN ACCESS

### Edited by:

Christoph Schankin,  
Bern University Hospital, Switzerland

### Reviewed by:

Francesca Puledda,  
King's College London,  
United Kingdom  
Michael S. Vaphiades,  
University of Alabama at Birmingham,  
United States

### \*Correspondence:

Lars Michels  
lars.michels@usz.ch

### Specialty section:

This article was submitted to  
Neuro-Ophthalmology,  
a section of the journal  
Frontiers in Neurology

Received: 11 June 2021

Accepted: 04 August 2021

Published: 21 September 2021

### Citation:

Michels L, Stämpfli P, Aldusary N,  
Piccirelli M, Freund P, Weber KP,  
Fierz FC, Kollias S and Traber G (2021)  
Widespread White Matter Alterations  
in Patients With Visual Snow  
Syndrome. *Front. Neurol.* 12:723805.  
doi: 10.3389/fneur.2021.723805

**Background:** Visual snow is considered a disorder of central visual processing resulting in a perturbed perception of constant binocular flickering or pixilation of the whole visual field. The underlying neurophysiological and structural alterations remain elusive.

**Methods:** In this study, we included patients (final  $n = 14$ , five dropouts; five females, mean age: 32 years) with visual snow syndrome (VSS) and age- and sex-matched controls (final  $n = 20$ , 6 dropouts, 13 females, mean age: 28.2 years). We applied diffusion tensor imaging to examine possible white matter (WM) alterations in patients with VSS.

**Results:** The patient group demonstrated higher ( $p$ -corrected  $< 0.05$ , adjusted for age and sex) fractional anisotropy (FA) and lower mean diffusivity (MD) and radial diffusivity (RD) compared to controls. These changes were seen in the prefrontal WM (including the inferior fronto-occipital fascicle), temporal and occipital WM, superior and middle longitudinal fascicle, and sagittal stratum. When additionally corrected for migraine or tinnitus—dominant comorbidities in VSS—similar group differences were seen for FA and RD, but less pronounced.

**Conclusions:** Our results indicate that patients with VSS present WM alterations in parts of the visual cortex and outside the visual cortex. As parts of the inferior fronto-occipital fascicle and sagittal stratum are associated with visual processing and visual conceptualisation, our results suggest that the WM alterations in these regions may indicate atypical visual processing in patients with VSS. Yet, the frequent presence of migraine and other comorbidities such as tinnitus in VSS makes it difficult to attribute WM disruptions solely to VSS.

**Keywords:** diffusion-weighted imaging, visual snow, white matter, neuro-ophthalmology, inferior fronto-occipital fascicle

## INTRODUCTION

Visual snow is a neurological state, defined by the presence of a continuous and chronic visual disturbance in the form of innumerable small dots covering the whole visual field (1). Patients with visual snow syndrome (VSS) experience a multi-layered array of visual symptoms in addition to the static itself, such as palinopsia, entoptic phenomena, nyctalopia and photophobia (2, 3). Visual

snow denotes a spectrum type disorder that at its worse manifests with most of these additional symptoms, as well as with comorbidities such as migraine and tinnitus (4). In such instances, the condition is perceived as highly disabling (5). Though the pathophysiology of VSS remains largely indefinite (6) recent studies have provided some insight on the possible biological mechanisms underlying the condition. Behavioural (7) and neurophysiological studies (8, 9) have demonstrated patterns of changes indicating to increased cortical excitability and visual cortex dysfunction.

Through neuroimaging, it has been possible to reveal that VSS is characterised by altered metabolism of the extrastriate visual cortex (10–13). Recently, it has been shown by resting-state functional magnetic resonance imaging (fMRI) that VSS show hyperconnectivity (compared to healthy controls) between regions of the visual cortex but also in frontal, parietal and temporal brain regions (10, 12). In addition, task-based fMRI, electroencephalography as well as MR spectroscopy pointed towards an alteration in the visual and prefrontal (insular) cortex (8, 11).

Furthermore, it is known that VSS demonstrate structural, i.e., grey matter volumes, changes involving the visual system, and further expanding beyond it (13, 14). A consistent finding is that patients with VSS show increased grey matter volume of the lingual gyrus (10, 14).

Diffusion tensor imaging (DTI) is one method to assess white matter (WM) alterations on the microstructural level. In patients with migraine—a frequent comorbidity in VSS—alterations have been reported in fractional anisotropy (FA), mean diffusivity (MD), radial diffusivity (RD), and axial diffusivity (AD). For example, FA—an indirect surrogate of neuronal integrity—is lower compared to controls in migraineurs in multiple WM regions (15–18). So far, no study has yet examined if patients with VSS display WM abnormalities. Based on the previous (and above-described) studies on structural MRI, we hypothesise to see altered WM integrity in patients with VSS.

## METHODS

### Sample

Inclusion criteria: 15 patients over 18 years of age and meeting the diagnostic criteria for VSS (1, 19) were recruited consecutively at the Department of Ophthalmology, University Hospital Zurich, Switzerland.

Exclusion criteria for all participants were pregnancy, presence of a neurodegenerative disorder, and contraindication against an MRI examination. The patients were all examined by senior neuro-ophthalmologists and neurologists. Patients were age and sex matched to 20 healthy controls (HCs). In both patients and HCs, the history was completed with regard to symptoms and conditions associated with VS syndrome as shown in **Table 1**.

The following clinical measures were included: duration of VS symptoms, history of migraine, tinnitus, anxiety, depression, tremor or imbalance, and perception of palinopsia, blue field entoptic phenomena, other entoptic phenomena, photophobia, glare, nyctalopia, symptoms in darkness, symptom presence with

eyes closed, and overall perceived symptom severity on a scale of 0–10. Migraine occurrence was assessed with the Diagnostic Algorithm of the Hardship Questionnaire (20). Participants were asked whether they had been diagnosed with, or feeling they were suffering from, an anxiety disorder or depression but no patients indicated the presence of anxiety or depression. None of the VS patients showed any signs of an underlying ophthalmic pathology based on the history and the clinical examination including best corrected visual acuity, static perimetry (Octopus 900, Haag-Streit, Bern, Switzerland), fundoscopy, and optical coherence tomography of the macula and the peripapillary retinal nerve fibre layer (Heidelberg Spectralis, Heidelberg Engineering, Heidelberg, Germany). All subjects provided informed written consent to participate in this study, which was approved by the ethics committee (Canton Zurich, Switzerland, BASEC-NR: 2016-00225).

### MRI Data Acquisition

MRI data acquisition was performed on a 3T whole-body MR scanner (Ingenia, Philips Healthcare, Best, the Netherlands), equipped with 80 mT/m gradients and a 32-channel receive head coil. Diffusion data were acquired using a diffusion-weighted single-shot spin-echo echo-planar-imaging sequence with the following parameters: repetition time (TR): 9,837 ms, echo time (TE): 94 ms, field of view (FOV): 224 × 224 mm<sup>2</sup>, 55 contiguous transversal slices, slice thickness: 1.7 mm, acquisition matrix: 132 × 130, SENSE factor: 2, partial Fourier encoding 68%. The bounding box was planned with having the inferior slice positioned at the inferior border of the cerebellum, defined on a T1-weighted midline sagittal survey image. Due to the small slice thickness, we did not cover the whole-brain but only included regions inferior to the body of the corpus callosum (covering the corpus callosum as well).

Diffusion acquisition was performed along 128 directions with a b-value of 1,000 s/mm<sup>2</sup> and two signal averages. Additionally, one non-diffusion-weighted b = 0 s/mm<sup>2</sup> scans were acquired resulting in a scan time of 21 min 40 s. For structural reference and anatomical priors for the tracking algorithm, T1-weighted images were recorded using a three-dimensional magnetisation prepared rapid gradient-echo (MP-RAGE) sequence with 1 mm isotropic resolution.

### Diffusion Data Pre-processing

Before any pre-processing steps, quality control of all acquired diffusion data was assessed based on several criteria: First, diffusion tensor residuals were calculated for every acquired diffusion direction and the nine slices in the whole diffusion dataset with the highest residuals were identified for visual inspection. Plots were generated depicting the 12 slices (four sagittal, four axial, and four coronal directions) with the highest noise level. Second, mean signal intensity plots for every diffusion direction and the non-diffusion-weighted image were derived and plotted slice by slice in sagittal, axial, and coronal directions. Artefacts, such as signal dropouts due to head motion, can easily be spotted on these plots. A trained MR physicist inspected the data for artefacts and rated the signal courses and fitting residuals of every subject on a Likert-type scale.

**TABLE 1** | Summary of demographic and clinical values for patients with VSS.

Patients	Age (years)	Sex	Non-visual symptoms							Visual symptoms					
			Migraine	With aura	Tinnitus	Depression	Anxiety	Duration of VS (years)	Imbalance	Palinopsia	Blue field entoptic phenomenon	Other entoptic phenomena	Photophobia	Glare	Nyctalopia
P1	44	0	1	0	1	0	0	9.0	1	0	0	1	0	0	1
P2	47	1	1	1	1	1	0	17.0	1	0	1	0	0	1	1
P3	23	1	0	0	0	1	0	5.5	0	0	1	0	0	0	1
P4	33	1	0	0	1	0	1	4.2	0	0	0	1	1	1	0
P5	18	1	0	0	1	1	1	1.0	1	1	1	0	1	0	1
P6	19	1	0	0	1	0	0	19.3	0	0	0	1	0	0	0
P7	44	0	1	1	0	1	1	4.1	0	1	0	0	1	1	1
P8	30	0	1	1	1	0	0	4.9	0	1	0	0	1	0	0
P9	39	0	1	1	1	0	1	0.8	0	0	1	0	1	1	1
P10	33	1	0	0	0	0	0	2.0	1	0	1	1	1	0	0
P11	21	1	1	1	1	0	0	1.2	1	1	0	1	0	1	0
P12	54	0	1	1	1	1	0	0.6	0	1	1	1	1	0	0
P13	22	1	0	0	1	0	0	6.0	0	0	0	0	0	1	1
P14	30	1	0	0	0	0	0	5.0	0	0	1	1	0	0	1

For sex, 1 = male, 0 = female. For all other variables, 1 = present, 0 = absent. Six of seven patients with migraine demonstrated visual aura.

Pre-processing diffusion data followed a similar procedure previously described in our recent publication (21). After denoising the raw data using the “dwidenoise function” from the MRtrix3 software package (<https://www.mrtrix.org/>), diffusion weighted data were first corrected for eddy-current and motion induced distortions by registration the diffusion weighted images to the b0 image using the dwipreproc routine from MRtrix3 software package. This function makes use of the eddy tool implemented in FSL (FMRIB, Oxford, UK version 6.0.0) (22). The brain extraction tool (BET) from FSL was then applied to remove non-brain tissue and estimate the inner- and outer skull surfaces. Next, the diffusion data were corrected for susceptibility-induced distortions using the “bdp correction algorithm” implemented in the BrainSuite software package (<http://brainsuite.org>) (23). Diffusion maps derived from the diffusion tensor, i.e., FA, MD, RD, and AD were then calculated using the DTIFIT tool implemented in the FSL software package (<https://fsl.fmrib.ox.ac.uk/fsl/fslwiki>).

## Statistical Analysis

To evaluate differences between the groups, voxel-wise (whole-brain) Tract-Based Spatial Statistics (TBSS, <https://fsl.fmrib.ox.ac.uk/fsl/fslwiki/TBSS>) analysis based on a general linear model was performed using FSLs randomise tool (24) with

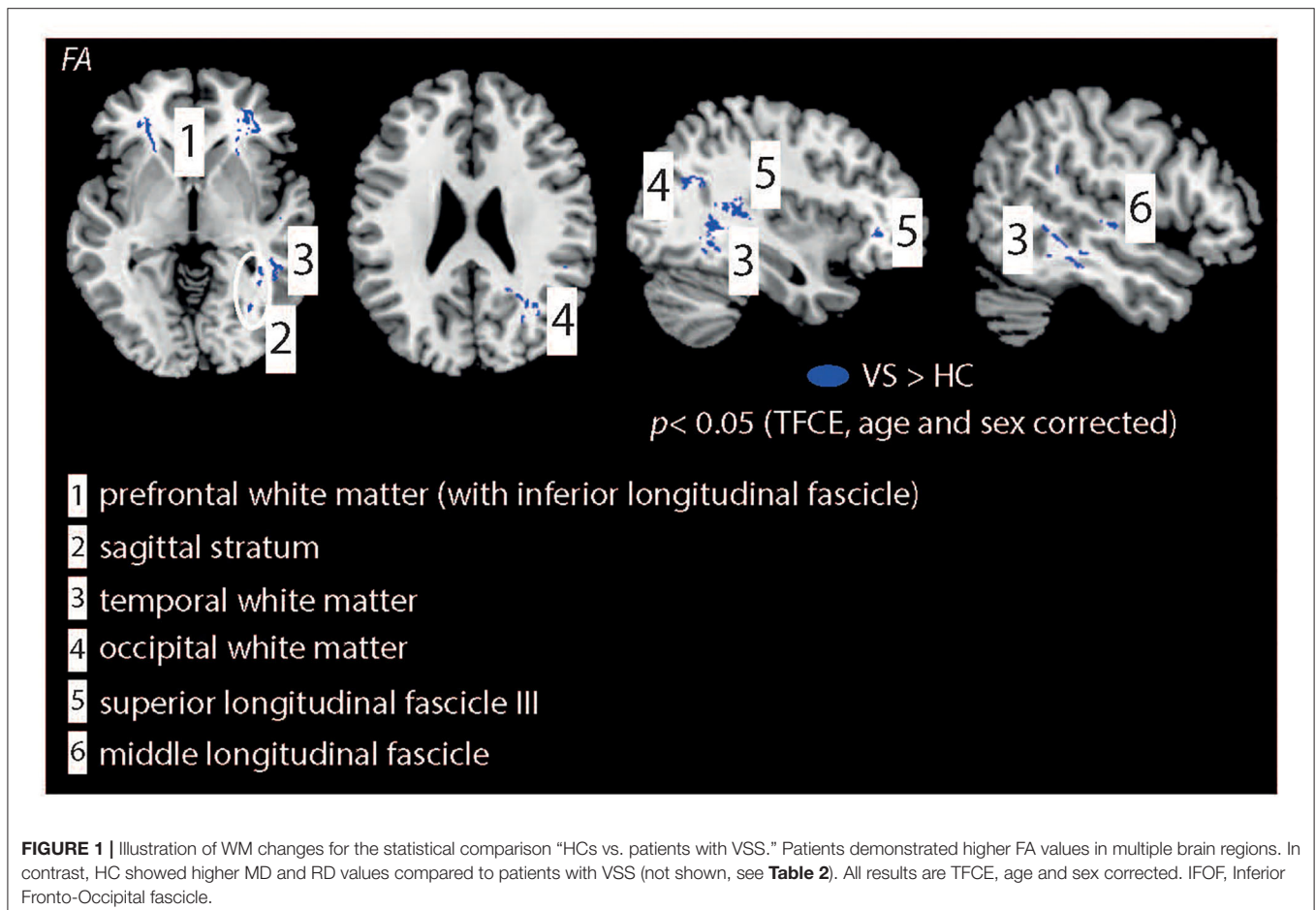
5,000 permutations to correct for multiple comparisons ( $p < 0.05$ , corrected). All results included threshold-free cluster enhancement (TFCE) (25). Three statistical contrasts were computed, testing for positive and negative differences of the DTI parameters between the patients with VSS and HCs:

- General linear model, with correction for age and sex (i.e., age and sex were used as nuisance variables in the model).
- General linear model, with correction for age, sex, and migraine occurrence
- General linear model, with correction for age, sex, and tinnitus occurrence.

## RESULTS

### Demography and Clinical Data

Seven patients showed episodic migraine; six of them demonstrated visual aura (**Table 1** provides a summary of demographic and clinical data for the VSS group). Based on the HARDSHIP questionnaire, three HCs showed migraine, and were thus excluded. Groups did not differ in sex ( $p = 0.14$ , Chi-Square test) or age ( $p = 0.13$ , unpaired  $t$ -test; mean age VSS group:  $32.6 \pm 11.1$  years, mean age HCs:  $28.2 \pm 5.5$  years).



## Image Quality

Five patients and three HCs had to be excluded because of poor DTI data quality (strong head motion resulting in artefacts on the FA map). Hence, the reported results are based on 14 patients with VSS and 20 HCs.

## DTI Findings

The VSS patient group demonstrated higher ( $p$ -corrected  $< 0.05$ , adjusted for age and sex, **Figure 1**) FA, lower MD and RD values compared to HCs. FA changes were seen in the prefrontal WM [with extension into the inferior fronto-occipital fascicle (IFOF)], sagittal stratum, temporal and occipital WM, superior longitudinal fascicle (SLF3), and middle longitudinal fascicle. For MD changes were additionally seen in the corpus callosum (genu) but not in the sagittal stratum, middle longitudinal fascicle and occipital WM. No significant group differences were seen for AD.

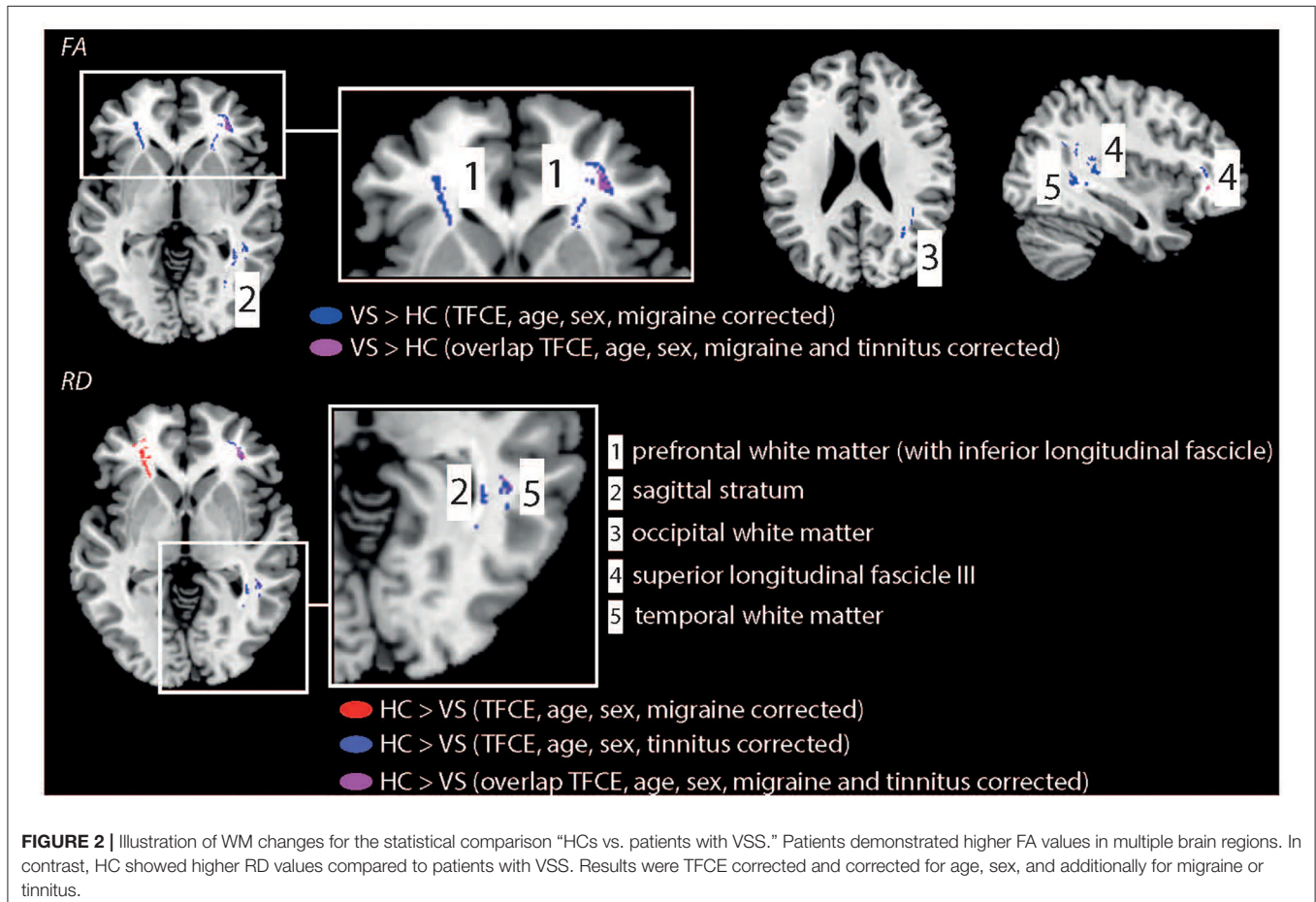
When additionally corrected for interictal migraine occurrence (**Figure 2**), FA changes were seen in the same WM areas as well except of the middle longitudinal fascicle. RD changes were seen in the prefrontal WM (with extension into the IFOF), right SLF3, and temporal WM. Yet, no significant group differences were observed for MD and AD. When additionally corrected for tinnitus occurrence FA were only seen in the right prefrontal WM, SLF3, and sagittal stratum. For RD changes were

observed in the right prefrontal WM (with extension into the IFOF), SLF3, temporal and occipital WM, and sagittal stratum. **Table 2** shows the full summary of WM group differences.

## DISCUSSION

Our study demonstrated widespread WM alterations in patients with VSS. We thus add to the growing body of literature reporting structural, i.e., grey matter volume, abnormalities in the visual cortex and visual association cortex. A novel finding is that structural WM alterations are evident in the visual cortex but also in the frontal and temporal cortex. Group differences were similar but less strong compared to the analysis without correcting for migraine or tinnitus. Consistent changes for both analyses were seen in the IFOF, sagittal stratum and right SLF. We suggest that these abnormalities could thus be associated to the manifestation of VS rather than by the presence of migraine.

Parts of the IFOF are associated with visual processing (26) by visual conceptualisation (27) and visual hallucinations (28, 29). Our results suggest that the WM alterations in these regions might indicate atypical visual processing in patients with VSS. Similarly, Aldhafeeri et al. found a disruption of WM integrity in the IFOF in patients suffering from tinnitus, a frequent comorbidity in individuals affected by VSS (30). Yet, even after



**TABLE 2** | Summary of DTI group differences.

Measure	Direction	Region	Hemisphere
<b>A)</b>			
<b>DTI</b>			
FA	VSS > HC	Prefrontal WM (with inferior fronto-occipital fascicle) Superior longitudinal fascicle III Occipital WM Temporal WM Middle longitudinal WM Sagittal stratum	Bilateral Right Right Right Right Right
MD	HC > VSS	Prefrontal WM (with inferior fronto-occipital fascicle) Superior longitudinal fascicle III Corpus callosum Temporal WM	Bilateral Right n.a. Right
RD	HC > VSS	Prefrontal WM (with inferior fronto-occipital fascicle) Superior longitudinal fascicle III Occipital WM Temporal WM Middle longitudinal WM Sagittal stratum	Bilateral Right Right Right Right Right
<b>B)</b>			
<b>DTI</b>			
FA	VSS > HC	Prefrontal WM (with inferior fronto-occipital fascicle) Superior longitudinal fascicle III Occipital WM Temporal WM Sagittal stratum	Bilateral Right Right Right Right
RD	HC > VSS	Prefrontal WM (with inferior fronto-occipital fascicle) Superior longitudinal fascicle III Temporal WM	Bilateral Right Right
<b>C)</b>			
<b>DTI</b>			
FA	VSS > HC	Prefrontal WM (with inferior fronto-occipital fascicle) Superior longitudinal fascicle III Sagittal stratum	Right Right Right
RD	HC > VSS	Prefrontal WM (with inferior fronto-occipital fascicle) Superior longitudinal fascicle III Occipital WM Temporal WM Sagittal stratum	Right Right Right Right Right

HC, healthy controls; VSS, patients with visual snow syndrome; n.a., not applicable. A) Results are TFCE, age, and sex corrected. B) Results are TFCE, age, and sex as well as for migraine. C) Results are TFCE, age, and sex corrected as well as for tinnitus.

correction of tinnitus presence, alterations were seen in the right prefrontal WM (IFOF). This suggests that this region might therefore be directly involved in the underlying biology of the condition.

The SLF is involved in speech processing (31, 32), musical processing (33), spatial attention (34) and memory (35), decision making (36), visual perception (37), and perceptual organisation

(38). For example, right-hemisphere brain damage e.g., induced by stroke often results in visual-spatial deficits, such as a neglect (37). McKendrick et al. (7) demonstrated that patients with visual snow demonstrated reduced centre-surround contrast suppression and elevated luminance increment thresholds in noise but did not differ on a global form or global motion task. Our study suggests that patients with visual snow may show

not only deficits in visual perceptual measures involving the suprathreshold processing of contrast and luminance but also in tasks involving high-order visual brain regions. Yet, this needs to be verified by psychophysical testing combined with structural neuroimaging (such as DTI).

Alterations in patients with VSS were also seen in the sagittal stratum, which contains the IFOF, inferior longitudinal fasciculus, and posterior thalamic radiation (39–41). Specifically, the sagittal stratum is a major cortico-subcortical WM bundle that conveys fibres from the parietal, occipital, cingulate, and temporal regions to subcortical destinations in the thalamus, pontine nuclei, and other brainstem structures (42). It additionally has afferents from the thalamus to the cortex, thus, it is a major subcortical fibre system and not exclusively a fibre tract linking the lateral geniculate nucleus with the calcarine cortex. Recently, electrical stimulation in patients undergoing wide-awake surgery for a cerebral glioma was applied combined with behavioural tasks (including visual and somesthetic processes, semantics as well as language, spatial and social cognition) to monitor online the patients' functions during stimulation (43). Stimulation of the right sagittal stratum lead to visual disturbances, visual hemi-agnosia, semantic paraphasia, left spatial neglect, confusion and comprehension difficulties, anomia, and mentalizing disturbances. We suggest that the observed DTI alterations in this region could be associated with some of the known visual disturbances generally observed in patients with VSS.

The alterations in temporal WM regions parallel findings of our recent resting-state fMRI connectivity study, performed in a similar sample of patients and controls (10). The middle and superior temporal cortex are involved in object, motion and form processing (44, 45) and abnormal WM could point towards a disturbed information processing in patients with VSS in these regions.

In general, we found stronger FA values for patients. Therefore, our data could indicate that patients demonstrate elevated excitability of parts of the visual cortex as well as other brain regions. Yet, further research is required to provide a more direct evidence for this proposed mechanism. We observed that WM impairments showed a right-hemispheric lateralisation (e.g., right IFOF), when results were corrected for the presence of tinnitus. This extends previous functional PET studies, who reported metabolic alterations in the right visual (lingual) gyrus (13, 19). However, the origin of the tentative anatomical lateralisation has not been examined in detail and further studies are needed to replicate this observation, especially examining larger cohorts of patients with VSS with and without tinnitus. In contrast to structural (VBM or DTI) studies, resting state fMRI studies reported abnormal functional connectivity in visual snow patients in both hemispheres (10, 12).

The ability to measure perceptual parameters in visual snow reveals promise for the development of novel ancillary tests. They may help to assist in visual snow diagnosis and possibly as a method for quantitatively assaying any benefits of treatment.

## LIMITATIONS

The lack of whole-brain coverage is a strong limitation of our study. Hence, we could not examine if WM alterations might be present e.g., in regions superior of the corpus callosum, e.g., in the parietal cortex, superior frontal regions, somatosensory, or (pre-)motor cortex. Future studies should be performed to examine this question in full detail. New DTI measures with clinical relevance, such as fibre density (46), could be additionally explored in upcoming studies. Regarding migraine presence in HCs, we excluded (based on the Hardship questionnaire) all subjects with migraine. In addition, there is no validated genetic marker (in contrast to e.g., Alzheimer's disease) for migraine. For patients, we did not assess—e.g., by headache diaries—the presence of a migraine attack the day before or the days after scanning. Thus, it might be that patients (with migraine) were scanned in an acute pre- or postictal phase.

## DATA AVAILABILITY STATEMENT

The raw data supporting the conclusions of this article will be made available by the authors, without undue reservation.

## ETHICS STATEMENT

The studies involving human participants were reviewed and approved by Ethics Committee Canton Zurich (Switzerland), BASEC-NR: 2016-00225. The patients/participants provided their written informed consent to participate in this study.

## AUTHOR CONTRIBUTIONS

LM did the statistical analysis and wrote the first manuscript draft. PS helped with data post-processing. LM, GT, MP, and SK were involved in the study design. NA did the data recording and helped with data analysis. FF, GT, and KW helped with patient recruitment, clinical interviews, and paper writing. MP set up the MRI sequences and helped with DTI scanning. All authors helped with paper writing.

## FUNDING

NA received financial support from the Saudi Arabian Cultural Mission (Paris, France). PF was funded by an SNF Eccellenza Professorial Fellowship grant (PCEFP3\_181362/1). GT (2016–2018) and FF (2020–2021) received a grant from the career development program Filling the Gap, Faculty of Medicine, University of Zurich.

## ACKNOWLEDGMENTS

The authors thank all volunteers for their willingness to participate in this study.



## REFERENCES

- Schankin CJ, Maniyar FH, Digre KB, Goadsby PJ. 'Visual snow' - a disorder distinct from persistent migraine aura. *Brain*. (2014) 137:1419–28. doi: 10.1093/brain/awu050
- Puledda F, Schankin C, Digre K, Goadsby PJ. Visual snow syndrome: what we know so far. *Curr Opin Neurol*. (2018) 31:52–8. doi: 10.1097/WCO.0000000000000523
- Traber GL, Piccirelli M, Michels L. Visual snow syndrome: a review on diagnosis, pathophysiology, and treatment. *Curr Opin Neurol*. (2020) 33:74–8. doi: 10.1097/WCO.0000000000000768
- Puledda F, Schankin C, Goadsby PJ. Visual snow syndrome: a clinical and phenotypical description of 1,100 cases. *Neurology*. (2020) 94:e564–74. doi: 10.1212/WNL.00000000000008909
- Schankin CJ, Puledda F, Goadsby PJ. Visual snow syndrome: is it normal or a disorder - and what to do with patients? *Eur J Neurol*. (2020) 27:2393–5. doi: 10.1111/ene.14436
- Puledda F, Ffytche D, O'Daly O, Goadsby PJ. Imaging the visual network in the migraine spectrum. *Front Neurol*. (2019) 10:1325. doi: 10.3389/fneur.2019.01325
- McKendrick AM, Chan YM, Tien M, Millist L, Clough M, Mack H, et al. Behavioral measures of cortical hyperexcitability assessed in people who experience visual snow. *Neurology*. (2017) 88:1243–9. doi: 10.1212/WNL.0000000000003784
- Eren O, Rauschel V, Ruscheweyh R, Straube A, Schankin CJ. Evidence of dysfunction in the visual association cortex in visual snow syndrome. *Ann Neurol*. (2018) 84:946–9. doi: 10.1002/ana.25372
- Yildiz FG, Turkyilmaz U, Unal-Cevik I. The clinical characteristics and neurophysiological assessments of the occipital cortex in visual snow syndrome with or without migraine. *Headache*. (2019) 59:484–94. doi: 10.1111/head.13494
- Aldusary N, Traber GL, Freund P, Fierz FC, Weber KP, Baeshen A, et al. Abnormal connectivity and brain structure in patients with visual snow. *Front Hum Neurosci*. (2020) 14:582031. doi: 10.3389/fnhum.2020.582031
- Puledda F, Ffytche D, Lythgoe DJ, O'Daly O, Schankin C, Williams SCR, et al. Insular and occipital changes in visual snow syndrome: a BOLD fMRI and MRS study. *Ann Clin Transl Neurol*. (2020) 7:296–306. doi: 10.1002/acn3.50986
- Puledda F, O'Daly O, Schankin C, Ffytche D, Williams SC, Goadsby PJ. Disrupted connectivity within visual, attentional and salience networks in the visual snow syndrome. *Hum Brain Mapp*. (2021) 42:2032–44. doi: 10.1002/hbm.25343
- Schankin CJ, Maniyar FH, Chou DE, Eller M, Sprenger T, Goadsby PJ. Structural and functional footprint of visual snow syndrome. *Brain*. (2020) 143:1106–13. doi: 10.1093/brain/awaa053
- Puledda F, Bruchhage M, O'Daly O, Ffytche D, Williams SCR, Goadsby PJ. Occipital cortex and cerebellum gray matter changes in visual snow syndrome. *Neurology*. (2020) 95:e1792–9. doi: 10.1212/WNL.0000000000010530
- Chong CD, Schwedt TJ. Migraine affects white-matter tract integrity: a diffusion-tensor imaging study. *Cephalalgia*. (2015) 35:1162–71. doi: 10.1177/0333102415573513
- Planchuelo-Gomez A, Garcia-Azorin D, Guerrero AL, Aja-Fernandez S, Rodriguez M, de Luis-Garcia R. White matter changes in chronic and episodic migraine: a diffusion tensor imaging study. *J Headache Pain*. (2020) 21:1. doi: 10.1186/s10194-019-1071-3
- Yu D, Yuan K, Qin W, Zhao L, Dong M, Liu P, et al. Axonal loss of white matter in migraine without aura: a tract-based spatial statistics study. *Cephalalgia*. (2013) 33:34–42. doi: 10.1177/0333102412466964
- Yuan K, Qin W, Liu P, Zhao L, Yu D, Zhao L, et al. Reduced fractional anisotropy of corpus callosum modulates inter-hemispheric resting state functional connectivity in migraine patients without aura. *PLoS ONE*. (2012) 7:e45476. doi: 10.1371/journal.pone.0045476
- Schankin CJ, Maniyar FH, Sprenger T, Chou DE, Eller M, Goadsby PJ. The relation between migraine, typical migraine aura and "visual snow". *Headache*. (2014) 54:957–66. doi: 10.1111/head.12378
- Steiner TJ, Gururaj G, Andree C, Katsarava Z, Ayzenberg I, Yu SY, et al. Diagnosis, prevalence estimation and burden measurement in population surveys of headache: presenting the HARSHIP questionnaire. *J Headache Pain*. (2014) 15:3. doi: 10.1186/1129-2377-15-3
- Stampfli P, Sommer S, Manoliu A, Burrer A, Schmidt A, Herdener M, et al. Subtle white matter alterations in schizophrenia identified with a new measure of fiber density. *Sci Rep-Uk*. (2019) 9. doi: 10.1038/s41598-019-40070-2
- Jenkinson M, Beckmann CF, Behrens TE, Woolrich MW, Smith SM. Fsl. *Neuroimage*. (2012) 62:782–90. doi: 10.1016/j.neuroimage.2011.09.015
- Shattuck DW, Leahy RM. BrainSuite: an automated cortical surface identification tool. *Med Image Anal*. (2002) 6:129–42. doi: 10.1016/S1361-8415(02)00054-3
- Winkler AM, Ridgway GR, Webster MA, Smith SM, Nichols TE. Permutation inference for the general linear model. *Neuroimage*. (2014) 92:381–97. doi: 10.1016/j.neuroimage.2014.01.060
- Smith SM, Nichols TE. Threshold-free cluster enhancement: addressing problems of smoothing, threshold dependence and localisation in cluster inference. *Neuroimage*. (2009) 44:83–98. doi: 10.1016/j.neuroimage.2008.03.061
- Catani M, Thiebaut de Schotten M. A diffusion tensor imaging tractography atlas for virtual *in vivo* dissections. *Cortex*. (2008) 44:1105–32. doi: 10.1016/j.cortex.2008.05.004
- Sarubbo S, De Benedictis A, Maldonado IL, Basso G, Duffau H. Frontal terminations for the inferior fronto-occipital fascicle: anatomical dissection, DTI study and functional considerations on a multi-component bundle. *Brain Struct Funct*. (2013) 218:21–37. doi: 10.1007/s00429-011-0372-3
- Andelman-Gur MM, Gazit T, Strauss I, Fried I, Fahoum F. Stimulating the inferior fronto-occipital fasciculus elicits complex visual hallucinations. *Brain Stimul*. (2020) 13:1577–9. doi: 10.1016/j.brs.2020.09.003
- Yuki N, Yoshioka A, Mizuhara R, Kimura T. Visual hallucinations and inferior longitudinal fasciculus in Parkinson's disease. *Brain Behav*. (2020) 10:e01883. doi: 10.1002/brb3.1883
- Aldhafeeri FM, Mackenzie I, Kay T, Alghamdi J, Sluming V. Neuroanatomical correlates of tinnitus revealed by cortical thickness analysis and diffusion tensor imaging. *Neuroradiology*. (2012) 54:883–92. doi: 10.1007/s00234-012-1044-6
- Davtian M, Ulmer JL, Mueller WM, Gaggli W, Mulane MP, Krouwer HG. The superior longitudinal fasciculus and speech arrest. *J Comput Assist Tomogr*. (2008) 32:410–4. doi: 10.1097/RCT.0b013e318157c5ff
- Maldonado IL, Moritz-Gasser S, Duffau H. Does the left superior longitudinal fascicle subserve language semantics? A brain electrostimulation study. *Brain Struct Funct*. (2011) 216:263–74. doi: 10.1007/s00429-011-0309-x
- Oechslin MS, Imfeld A, Loenneker T, Meyer M, Jancke L. The plasticity of the superior longitudinal fasciculus as a function of musical expertise: a diffusion tensor imaging study. *Front Hum Neurosci*. (2009) 3:76. doi: 10.3389/neuro.09.076.2009
- Shinoura N, Suzuki Y, Yamada R, Tabei Y, Saito K, Yagi K. Damage to the right superior longitudinal fasciculus in the inferior parietal lobe plays a role in spatial neglect. *Neuropsychologia*. (2009) 47:2600–3. doi: 10.1016/j.neuropsychologia.2009.05.010
- Kinoshita M, Nakajima R, Shinohara H, Miyashita K, Tanaka S, Okita H, et al. Chronic spatial working memory deficit associated with the superior longitudinal fasciculus: a study using voxel-based lesion-symptom mapping and intraoperative direct stimulation in right prefrontal glioma surgery. *J Neurosurg*. (2016) 125:1024–32. doi: 10.3171/2015.10.JNS.1591
- Gao S, Liu P, Guo J, Zhu Y, Liu P, Sun J, et al. White matter microstructure within the superior longitudinal fasciculus modulates the degree of response conflict indexed by N2 in healthy adults. *Brain Res*. (2017) 1676:1–8. doi: 10.1016/j.brainres.2017.09.008
- Kim SH, Jeon HE, Park CH. Relationship between visual perception and microstructural change of the superior longitudinal fasciculus in patients with brain injury in the right hemisphere: a preliminary diffusion tensor tractography study. *Diagnostics*. (2020) 10:641. doi: 10.3390/diagnostics10090641
- Koshiyama D, Fukunaga M, Okada N, Morita K, Nemoto K, Yamashita E, et al. Association between the superior longitudinal fasciculus and perceptual organization and working memory: a diffusion tensor imaging study. *Neurosci Lett*. (2020) 738:135349. doi: 10.1016/j.neulet.2020.135349

39. Catani M, Jones DK, Donato R, Ffytche DH. Occipito-temporal connections in the human brain. *Brain*. (2003) 126:2093–107. doi: 10.1093/brain/awg203
40. Klingler J, Ludwig E. *Atlas cerebri humani (Der innere Bau des Gehirns, dargestellt auf Grund makroskopischer Präparate / The Inner Structure of the Brain Demonstrated on the Basis of Macroscopical Preparations)*. Basel: Karger Publishers (1956). 136 p. doi: 10.1159/isbn.978-3-318-05323-4
41. Mori S, Oishi K, Jiang H, Jiang L, Li X, Akhter K, et al. Stereotaxic white matter atlas based on diffusion tensor imaging in an ICBM template. *Neuroimage*. (2008) 40:570–82. doi: 10.1016/j.neuroimage.2007.12.035
42. Di Carlo DT, Benedetto N, Duffau H, Cagnazzo F, Weiss A, Castagna M, et al. Microsurgical anatomy of the sagittal stratum. *Acta Neurochir*. (2019) 161:2319–27. doi: 10.1007/s00701-019-04019-8
43. Berro DH, Herbet G, Duffau H. New insights into the anatomo-functional architecture of the right sagittal stratum and its surrounding pathways: an axonal electrostimulation mapping study. *Brain Struct Funct*. (2021) 226:425–41. doi: 10.1007/s00429-020-02186-4
44. Macaudo G, Moisa M, Mast FW, Ruff CC, Michels L, Lenggenhager B. Shared neural mechanisms between imagined and perceived egocentric motion - a combined GVS and fMRI study. *Cortex*. (2019) 119:20–32. doi: 10.1016/j.cortex.2019.04.004
45. Michels L, Kleiser R, de Lussanet MH, Seitz RJ, Lappe M. Brain activity for peripheral biological motion in the posterior superior temporal gyrus and the fusiform gyrus: dependence on visual hemifield and view orientation. *Neuroimage*. (2009) 45:151–9. doi: 10.1016/j.neuroimage.2008.10.063
46. Huynh V, Staempfli P, Luetolf R, Luechinger R, Curt A, Kollias S, et al. Investigation of cerebral white matter changes after spinal cord injury with a measure of fiber density. *Front Neurol*. (2021) 12:598336. doi: 10.3389/fneur.2021.598336

**Conflict of Interest:** The authors declare that the research was conducted in the absence of any commercial or financial relationships that could be construed as a potential conflict of interest.

**Publisher's Note:** All claims expressed in this article are solely those of the authors and do not necessarily represent those of their affiliated organizations, or those of the publisher, the editors and the reviewers. Any product that may be evaluated in this article, or claim that may be made by its manufacturer, is not guaranteed or endorsed by the publisher.

Copyright © 2021 Michels, Stämpfli, Aldusary, Piccirelli, Freund, Weber, Fierz, Kollias and Traber. This is an open-access article distributed under the terms of the Creative Commons Attribution License (CC BY). The use, distribution or reproduction in other forums is permitted, provided the original author(s) and the copyright owner(s) are credited and that the original publication in this journal is cited, in accordance with accepted academic practice. No use, distribution or reproduction is permitted which does not comply with these terms.



# A Study Protocol for an Open-Label Feasibility Treatment Trial of Visual Snow Syndrome With Transcranial Magnetic Stimulation

Marissa Grande<sup>1</sup>, Lucas Lattanzio<sup>1</sup>, Isabelle Buard<sup>1</sup>, Allison M. McKendrick<sup>2</sup>, Yu Man Chan<sup>2</sup> and Victoria S. Pelak<sup>1,3\*</sup>

<sup>1</sup> Department of Neurology, University of Colorado, Aurora, CO, United States, <sup>2</sup> Department of Optometry and Vision Sciences, University of Melbourne, Melbourne, VIC, Australia, <sup>3</sup> Department of Ophthalmology, University of Colorado, Aurora, CO, United States

## OPEN ACCESS

### Edited by:

Valerie Purvin,  
Midwest Eye Institute, United States

### Reviewed by:

Shlomo Dotan,  
Tel Aviv Sourasky Medical  
Center, Israel  
Márta Janáky,  
University of Szeged, Hungary

### \*Correspondence:

Victoria S. Pelak  
victoria.pelak@CUAnschutz.edu

### Specialty section:

This article was submitted to  
Neuro-Ophthalmology,  
a section of the journal  
Frontiers in Neurology

**Received:** 11 June 2021

**Accepted:** 18 August 2021

**Published:** 24 September 2021

### Citation:

Grande M, Lattanzio L, Buard I, McKendrick AM, Chan YM and Pelak VS (2021) A Study Protocol for an Open-Label Feasibility Treatment Trial of Visual Snow Syndrome With Transcranial Magnetic Stimulation. *Front. Neurol.* 12:724081. doi: 10.3389/fneur.2021.724081

**Background:** Visual Snow (VS) syndrome is believed to be due to aberrant central visual processing. Positron Emission Tomography (PET) brain imaging and visual evoked potential studies provide evidence for excessive neuronal activity in the medial temporal lobe, specifically the lingual gyrus, and suggest the VS syndrome is a hyperexcitability syndrome. These data provide the basis for consideration of repetitive transcranial magnetic stimulation (rTMS) as a potential treatment for the VS syndrome.

**Objective:** To publish the study protocol for a pilot study underway at the University of Colorado School of Medicine to investigate the use of rTMS intervention to improve symptoms and visual dysfunction associated with VS. The study aims to determine the adverse events and drop-out rate, evaluate performance of outcome measures, including a novel VS symptom scale, and describe changes in outcomes associated with treatment.

**Methods and Design:** Up to 10 participants meeting criteria for VS syndrome, age 19–65 years, will undergo an open-label intervention consisting of 10 rTMS sessions, occurring 5 days a week over a 2-week period. Participants will complete pre-treatment and post-treatment assessments that include: the Colorado Visual Snow Scale (CVSS), the National Eye Institute Visual Functional Questionnaire—25 (VFQ-25), the General Anxiety Disorder—7 scale (GAD-7), and three psychophysical visual processing tasks.

**Discussion:** Knowledge gained from this pilot study will inform future study planning and provide valuable lessons for future investigation of rTMS for the VS syndrome. An overview of study proceedings thus far demonstrates recruitment challenges associated with the COVID-19 pandemic, and additional challenges that are unique to the VS syndrome and to treatment schedules associated with TMS.

**Registration:** This study has been approved by the Colorado Multiple Institutional Review Board. ClinicalTrials.gov Identifier: NCT04925232.

**Keywords:** visual snow, transcranial magnetic stimulation, open-label treatment trial, visual psychophysics, migraine

## INTRODUCTION

People with Visual Snow (VS) syndrome perceive small, moving dots, which resemble the TV static of a poorly tuned analog television, in a constant manner throughout their visual field. Other symptoms include palinopsia or visual trails, light sensitivity, excessive awareness of flashes of lights and floaters, tinnitus, and balance problems. VS most often affects young people in the third decade of life, but it can strike anyone at any age, including children and older adults (1, 2). Comorbidity includes migraine headaches, which are present in 60–80% of people with VS (2). There is no effective treatment, and the cause is unknown. Many patients with VS have difficulty with visual functions and can struggle to continue working because of the visual symptoms associated with the syndrome (2). The International Headache Society (IHS) published criteria (3) for the VS syndrome and these criteria are summarized in **Table 1**.

The objective of this manuscript is to describe the research protocol for an ongoing, open-label treatment study of repetitive transcranial magnetic stimulation (rTMS) for VS syndrome at the University of Colorado School of Medicine. The aim of this pilot study is to investigate the feasibility of a future randomized controlled trial of rTMS to improve visual function and symptoms associated with VS. Specifically, this study aims to determine: (1) adverse events and drop-out rate, (2) the standard deviation and test-retest reliability of a novel scale (Colorado Visual Snow Scale or CVSS) and performance of three psychophysical visual processing tasks previously investigated by McKendrick et al., and (3) describe changes in outcome measures (described below) following treatment with rTMS.

VS syndrome is believed to be due to aberrant central visual processing that results in excessive neuronal activity in regions of the brain that perform higher order visual processing (4). Given all findings and symptoms, some authors have posited that VS syndrome is due to thalamocortical dysrhythmia (1). Data from Positron Emission Tomography (PET) brain imaging studies and visual evoked potential studies indicate that the excessive neuronal activity occurs in the medial temporal lobes, specifically the right lingual gyrus (5). Although this evidence suggests that the lingual gyrus plays a role in VS, it is not clear whether increased metabolic activity in this region occurs as a

result of upstream neuronal dysfunction or is the primary cause of VS syndrome. In either case, similar syndromes with evidence for central nervous system hyperexcitability have the potential to be treated using rTMS, such as cerebellar hyperexcitability (6), central pain syndrome (7), and certain migraine syndromes (8), with each showing modest treatment responses to rTMS. In 2018, the United States Food and Drug Administration (FDA) approved marketing of TMS for the treatment of major depressive disorder, and in 2013, the FDA did the same for certain migraine headache types (9).

Pharmaceutical interventions with anti-epileptics, migraine therapies, and acetazolamide have historically been used to treat VS, and anecdotal evidence and/or limited treatment trials have shown very limited to no efficacy with side effects that often outweigh the benefits [for review of recent treatment data, see (4)]. Consequently, people with VS syndrome can suffer from decreased ability to read, to use a computer, or to drive, and they frequently report poor quality of life due to VS symptoms and anxiety associated with the syndrome (4). Transcranial magnetic stimulation (TMS) utilizes a non-invasive magnetic field to induce electrical currents that are directed at the cerebral cortex discretely, in order to alter neuronal firing. The rTMS method involves the use of continuous “trains” of stimulation for a specified duration of time, in order to produce lasting effects on brain function by either selectively increasing or decreasing neuronal firing. Repetitive TMS has improved outcomes in several neurologic and psychiatric disorders, including chronic tinnitus syndromes without hearing loss (10), which can, on some level, be considered analogous to the disorder of VS. Furthermore, many patients with VS suffer from chronic tinnitus (1, 2).

The goal of rTMS using low frequency (i.e., 1 Hz) stimulation is to decrease neuronal firing, and the inhibitory modulation likely occurs at the level of the synapse, although additional understanding is needed (11). A single pulse of TMS can alter neuronal firing at the moment the pulse is delivered. However, for longer-lasting effects that go beyond the moment of stimulation, repetitive stimulation with 5–20 daily sessions are typically necessary for longer-lasting effects, and 10 sessions have been found to be effective in a variety of disorders [see **Table 2** and (12)].

The mechanism causing more persistent change in neuronal activity is thought to be due to “weakening” of synaptic connections and synaptic plasticity that follows multiple sessions, but the mechanism is not fully understood (11). One theory posits persistent post-synaptic change (i.e., remodeling of the post-synaptic receptor) takes place only after multiple rTMS sessions with many stimulations given per session. These changes at the synaptic level appear to be akin to a physiologic process called long-term depression, or LTD, which can reduce cortical excitability and contribute to cortical plasticity and to learning and memory (13).

Evidence-based guidelines and therapeutic approaches for the use of rTMS in various conditions have been published and recently updated by Lefaucheur et al. in February 10 (12). Those reviewed in detail by Lefaucheur et al. are summarized in **Table 2**.

**TABLE 1** | Summary of international headache society criteria for visual snow (3).

### Criteria A through D must be met

- A. Dynamic, continuous tiny dots in the entire visual field >3 months
- B. At least two of four additional symptoms
  1. Palinopsia (visual after-images, trailing of moving objects, or both)
  2. Enhanced entoptic phenomena with at least one of the following: excessive floaters in both eyes, excessive blue field entoptic phenomenon, self-lighting perceived with eyes closed, or spontaneous photopsia.
  3. Photophobia
  4. Nyctalopia
- C. Symptoms not consistent with typical migraine visual aura per International Headache Society criteria.
- D. Symptoms are not better explained by another disorder (including normal ophthalmic tests and no intake of psychotropic drugs).

**TABLE 2** | Summary of data reviewed by Lefaucheur et al. (12).

Summary of the tables within Lefaucheur et al. (12)	Range of pulses per session	Range of sessions (one session per 24 h unless noted)	Level of evidence (level 1: randomized sham trial through level 4: case series or uncontrolled)
Table 1. HF-rTMS of M1 contralateral to pain region in neuropathic pain.	1,500–3,000	3–10	2
Table 2. HF-rTMS of bilateral M1 regions in Parkinson's disease (motor symptoms).	600–1,000	5–10	2
Table 3. LF-rTMS of contralesional M1 in motor stroke at the postacute stage.	900–1,800	5–15	2–3
Table 4. HF-rTMS of ipsilesional M1 in motor stroke at the postacute stage.	500–1,350	5–10	2
Table 5. iTBS of ipsilesional M1 in motor stroke at the chronic stage.	600–1,200	10	2, 3
Table 6. HF-rTMS of ipsilesional M1 in post-stroke dysphagia.	500–3,000	5–10	2, 3
Table 7. LF-rTMS of right IFG in post-stroke non-fluent aphasia at chronic stage.	600–1,200	10–20	2, 3
Table 8. rTMS (cTBS) studies in hemispatial neglect (target: left posterior parietal cortex).	4cTBS trains of 15–45 min	2–14	2, 3
Table 9. iTBS of M1 in multiple sclerosis.	600–1,200	10	2
Table 10. LF-rTMS of the auditory cortex in chronic tinnitus.	900–2,000	10 with some mixed (e.g., 4 sessions x 1,800 and 5 sessions x 1,200 pulses)	1, 2, 3
Table 11. LF-rTMS of the auditory cortex combined with HF-rTMS of the left DLPFC in chronic tinnitus.	1,000–2,000	5–10	1, 2
Table 12. HF-rTMS of the left DLPFC in major depressive disorder.	1,600–2,100	10–20 (one study with two sessions in 1 day)	1, 2, 3
Table 13. Deep HF-rTMS of the left DLPFC in major depressive disorder.	1,980–6,012	20	1, 2
Table 14. cTBS/iTBS of the right/left DLPFC in major depressive disorder.	600–1,800	10–30	2, 3
Table 15. LF-rTMS of the left TPC in auditory hallucinations (schizophrenia).	1,000–1,200	4 (two sessions per day)	2
Table 16. HF-rTMS of the left TPJ in auditory hallucinations (schizophrenia).	2,600	4 (two sessions per day)	2
Table 17. HF-rTMS studies of the left DLPFC in negative symptoms of schizophrenia.	1,000–1,500	10–15	1, 2, 3
Table 18. LF-rTMS of the DLPFC in obsessive compulsive disorder.	1,200–2,000	10–15	2, 3
Table 19. Bilateral LF-rTMS of the pre-SMA in obsessive compulsive disorder.	1,200–1,500	18–25	2, 3

LF, Low Frequency; HF, High Frequency. cTBS, continuous patterned rTMS; iTBS, intermittent patterned rTMS brain stimulation; Note: this VS study protocol uses LF-rTMS, which depresses hyperexcitable neurons, which HF-rTMS activates neuronal activity.

To date, there is no published data regarding the use of TMS for the treatment of VS. The goals for publishing the protocol for the ongoing study are to stimulate interest and to share approaches with the scientific community, as well as review the challenges encountered thus far. The methods and the TMS protocol are reviewed, followed by discussion of recruitment during COVID-19, as well as the challenges encountered and potential solutions that could inform planning for future rTMS treatment trials for VS.

## METHODS AND ANALYSIS

The ongoing study is an open-label feasibility treatment study of VS utilizing a rTMS paradigm. In summary, participants undergo a 2-week treatment intervention for a total of 10 sessions that are ~1 h in duration per session and occur 5 days per week for two consecutive weeks. Assessments described are given at baseline (pre-treatment), post-treatment, and again at 1 and 3 months following treatment.

### Description of Population Being Enrolled

Up to 10 participants ranging in age from 19 to 65 with a diagnosis of VS that meets the International Headache Society (IHS) criteria are being recruited.

### Inclusion Criteria:

- Age 19–65 years with a diagnosis of VS that meets IHS criteria
- Able to provide informed consent
- Visual snow must be present for 3 months or more and symptoms must be persistent (i.e., continuous)
- A prior brain magnetic resonance imaging (MRI) scan with and without contrast completed in the past 3 years that does not show signs of clinically significant brain lesion(s) (e.g., no evidence of multiple sclerosis, stroke, brain tumor, cortical heterotopia or other cortical developmental abnormalities, arteriovenous malformation, etc.).

### Exclusion Criteria based on TMS safety guidelines (14–16):

- Syndrome meeting criteria for Hallucinogen-persisting perception disorder
- Prior treatment with TMS for any disorder
- Epilepsy, family history of epilepsy, or personal history of seizures
- Any medical condition or medication that increases the risk of seizures
- Pacemaker or another implantable medical device
- Metal in the skull, not including the mouth
- Unstable cardiac, pulmonary, or other systemic illness

- Pregnancy
- Bipolar disorder
- History of suicidality.

## Outcome Measures

### Questionnaires and Scales

Currently, no outcome measures or scales exist specifically for VS symptoms. For this reason, the CVSS was developed for this study, and is available as **Supplementary Material**. Additionally, two previously validated scales are being used: The National Eye Institute Visual Functioning Questionnaire—25 (VFQ-25) and the General Anxiety Disorder—7 (GAD-7) scale.

### Psychophysical Visual Processing Tasks

Recently, McKendrick et al. (17) investigated psychophysical behavioral measures in people with VS compared to controls and found that VS participants showed statistically significant reduced center-surround contrast suppression and elevated luminance increment threshold detection in noise. These findings are consistent with the theory of cortical hyperexcitability. These tasks are, therefore, being employed in this feasibility study to investigate their use as potential markers of treatment efficacy.

The tasks detect extensively studied physiological properties of the visual system that have been used to explore the “balance between inhibition and excitation” and are described elsewhere (17, 18). In brief, for the center-surround matching task, observers are asked to compare the contrast between two small striped patches that are presented side-by-side. The “reference patch” is 40% contrast and is surrounded by a larger annulus of 95% contrast. The variable contrast small “target patch” is presented alone. Using a spatial forced-choice paradigm, participants must choose which patch is perceived as higher contrast. The strength of the influence of the surround annulus on the perception of the central patch contrast is a measure of the degree of center-surround suppression for each observer. The higher contrast surround (i.e., annulus) should suppress the perceived contrast of the central patch. The magnitude of this suppression of perceived contrast has been noted to be reduced in people with VS (17). For the luminance noise task, two squares filled with luminance noise are presented side-by-side and an observer must report which of the two stimuli also contains a circular luminance increment. Both high noise and low noise squares are used, and the luminance detection threshold is determined for each observer for each noise level. As noted, those with VS have been found to have a higher luminance detection threshold for luminance increments presented on both low and higher pixelated noise backgrounds (17). Learning effects were examined by McKendrick et al. (18) and were not found. The third task measures the ability to determine the global motion direction of a briefly presented field of moving dots presented within a circular window. Within the dot motion movie, some of the dots move in a coherent direction (either left or right, selected at random on each trial), while the remaining dots move in random directions (noise dots). On each trial, the observer indicates the perceived direction of global motion, with the threshold being measured as percent coherence (the percentage of dots in the pattern moving in the signal direction to correctly

perceive the direction of motion). Full details of the thresholding methodology are presented elsewhere (18). This task did not show a difference between controls and participants with VS (17).

## Transcranial Magnetic Stimulation: Determining Phosphene Threshold

As described by Stewart and colleagues (19), the phosphene threshold is used to determine the personalized “dose” of TMS that will be used for each subject. The phosphene threshold is the “dose” of TMS that is necessary to result in the perception of phosphenes as described. For this study, this is done before the first TMS treatment and determined again at the start of week 2 (or treatment session 6) of the 10-session treatment schedule. To determine the phosphene threshold, participants wear a blindfold and a cap is worn on the head. Three points positioned over the occipital midline and 2, 3, and 4 cm above theinion are marked. The TMS coil is positioned such that the handle points upwards and is parallel to the subject's spine. Single pulse TMS is then applied over one of the marked points and the subject reports the presence or absence of a phosphene immediately after stimulation. Stimulation is initially applied at 60% of stimulator output. If the subject reliably perceives a phosphene, reporting it five or more times out of ten, intensity is reduced in steps of 5% and stimulation will be again given ten times. Stimulation intensity is reduced until the subject no longer reliably perceives a phosphene. Stimulation intensity is then increased in blocks of 5% until the minimum intensity at which the subject can perceive a phosphene five times out of 10 is established and this value is determined to be the threshold. If the participant does not initially perceive a phosphene at 60% of stimulator output, intensity is increased in blocks of 5% to a maximum level of 100% of stimulator output. If the subject fails to perceive a phosphene at the maximum level, the coil position is shifted to another of the points marked on the cap and the procedure will be repeated until the threshold is determined at one of the marked points.

## Transcranial Magnetic Stimulation: Treatment Procedure

For treatment in this pilot study, bilateral low-frequency (1 Hz) repetitive transcranial magnetic stimulation (LF-rTMS) is administered to both right and left lingual gyri using a custom-built, 120°-angulated, 80 mm double figure-of-eight coil manufactured by Magstim Ltd (Whitland, Camarthenshire, UK). Targets are selected based on visual inspection of a participant's T1-weighted MRI images of the brain, and individual target coordinates are recorded in Montreal Neurological Institute (MNI) space. The TMS coil is positioned over the specified target location based upon the participant's MRI image in MNI space facilitated by the Brainsight™ interface, and LF-rTMS is administered at 110% of the phosphene threshold using the determined target and trajectory. Treatment sessions include two 15–20 min trains (one train per side) for a total of no more than 1,800 stimulations during each treatment session. Each session includes a total of 30–40 min of LF-rTMS stimulation time with a brief break in between sides. For each session, after treatment is complete, the participant is given a side effect survey. The rTMS treatment sessions occur daily for 5 days per week for two consecutive weeks.

## Data Analysis

### Side Effects

To determine whether any participant experiences untoward effects of TMS, a side effect survey is being used, as noted, and summary reports of adverse events will be published. It should be known that the cortical location of the treatment for this trial is different from previous studies, so it is possible to encounter side-effects not previously reported.

### Drop-Out Rate Estimates

With a sample size of 10, we will be able to estimate the expected drop-out rate for larger studies in the range of 20–50% to within a 95% confidence interval of  $\pm 25\%$  to  $\pm 31\%$ . To calculate a dropout rate for future studies and shrink the confidence interval, we will use data gathered in this study and data from chronic tinnitus studies using TMS to perform a Bayesian analysis for drop-out estimation. For reference, the available studies [see (12)] for tinnitus and rTMS revealed an approximate dropout rate of 7% in rTMS group and 12% in the sham group.

### Performance of Outcome Measures

To define the performance of the CVSS and the performance of the three psychophysical visual processing tasks, the standard deviation and test-retest reliability for CVSS and each of the three psychophysical tasks will be determined. The CVSS and the three psychophysical tasks will be given pre-treatment and then repeated on the 1st day of treatment prior to rTMS, and these results will be used to conclude the test-retest reliability using the intraclass correlation coefficient (with a two-way mixed effects, absolute agreement, single rater/measurement model).

### Outcome Measure Changes With Treatment

Changes in outcome measures (i.e., changes in the CVSS, VFQ-25, and GAD-7) with treatment will be assessed. Results pre-treatment (first day of treatment prior to rTMS) and results after last day of treatment with rTMS will be compared by assessing within-subject correlations (i.e., repeated measures correlation) for the CVSS, VFQ-25, GAD-7, and the suppression index (center-surround task), detection threshold (luminance detection task), and coherence threshold (global motion task). The effect size for each measure using a linear mixed model will be determined.

## RISKS AND PROTECTION AGAINST RISKS

All of the parameters proposed for this study fall within the accepted parameters for safe rTMS administration with an estimated risk of  $<1$  in 10,000 of inducing seizures in appropriately screened subjects (14–16). Overall, low frequency-rTMS protocols, such as the one used in this pilot study, are considered to be of minimal risk for serious adverse events and have been used extensively in previous research (20). LF-rTMS has been applied to over a hundred subjects with other cortical hyperexcitability syndromes (largely tinnitus and central pain) with no reports of seizures or other serious adverse events (21–23). A slight risk of headache and neck pain is expected, but these symptoms are typically self-resolving and/or treatable with over-the-counter analgesics. Other potential side effects include scalp

discomfort at the site of stimulation, scalp or jaw or face tingling or muscle spasms, light headedness, and visual blurring.

To mitigate risks, all participants are screened prior to TMS (see exclusion criteria). Each participant is required to have a MRI scan performed within 3 years that does not show any concerning lesion. There have been reports of hearing loss with repeated TMS pulses, and thus all participants and investigators are required to wear ear plugs, consistent with what is worn during an MRI brain scan. An on-call neurologist is available at all times in the event of a seizure or other adverse study event. Study personnel involved in human subject interactions are BLS certified and specifically trained in seizure safety and what to do in the event of other medical emergencies. All adverse events are reported to the Colorado Multiple Institutional Review Board (COMIRB), and if a seizure were to occur, it would also be reported to the FDA. To monitor for adverse events, and make appropriate modifications, a side effects survey is given to each participant after each treatment session and at month one and month three after treatment is completed.

## DISCUSSION

Only one participant completed the study before the COVID-19 pandemic restricted all studies on campus. This section will focus on side effects noted, the approach to the challenges encountered due to the COVID-19 pandemic, and lessons learned thus far that will inform the remainder of the trial and future treatment trials of VS using rTMS.

### Side Effects

During the rTMS sessions, the participant who completed the study experienced symptoms consistent with twitching of the face and scalp, and the feeling of a tapping sensation on the skull, which are common during TMS procedures. In one instance, while targeting the right lingual gyrus, the contralateral upper shoulder/lower neck region would twitch in unison with each pulse. This occurred for less than a few minutes into one session and was reported as uncomfortable, but not painful, and resolved after slight adjustment of the TMS coil. It is worth noting that this participant had a phosphene threshold of 87% and, therefore, a relatively high stimulator output of 96% for dosage. After several daily sessions, the participant also reported mild light headedness, and very mild blurred vision and tingling in the hands. Based on further discussion, it is possible these side effects arose from the position the participant was placed in during the sessions, as symptoms resolved with alteration of the participant's position on one occasion. During TMS, each participant is seated, with their heads facing down on a pillow and their arms resting with hands together or side-by-side above the head. It is not possible to rule outside effects due to TMS given the nature of the symptoms, but symptoms were confirmed to be resolved before the end of each visit where the symptoms were reported.

### Implementation of Psychophysical Visual Processing Tasks

A similar experimental model to that used by McKendrick et al. in their 2017 study on behavioral measures of cortical

hyperexcitability was implemented for this pilot study and was adapted to an application downloaded onto a tablet (17, 18). Several test trials ensured that the tasks and application were working and that all anonymized data were instantly uploaded to a cloud-based server, which has made data sharing streamlined and effortless. Outside of a few minor operating system issues, implementation and completion of visual processing tasks with the participant enrolled went smoothly. For future studies, this process is desirable in order to have all data processed in a blinded fashion at one center.

## The Impact of COVID-19 Pandemic

The pilot study was halted before opening for enrollment due to the COVID-19 pandemic in March 2020. Once the campus was open for in-person and on-campus treatment trials in the late Summer of 2020, additional documentation and processes were necessary before the pilot study was approved by campus research officials for recruitment. A required COVID-19 mitigation plan was submitted and included a designated COVID-19 officer for the TMS laboratory space, a plan to follow all campus and CDC guidelines with proper cleaning procedures, use of personal protective equipment, screening questionnaires for exposure to, and symptoms of, COVID-19 for participants, and a controlled check-in location for screening and temperature checks. In addition, a high-efficiency particulate air filter was purchased for use during TMS sessions to ensure the safety of the TMS technician and participants, due to the proximity (<6 feet) required during TMS treatments. Despite these measures and modifications, all but one of the potential participants who were previously screened and deemed eligible decided not to participate throughout 2020 and into the Spring of 2021. Although many potential participants contacted for the study continue to have concerns about onsite visits and travel to the site daily for 2 weeks during the pandemic, as the risks for COVID-19 are better understood and as the pandemic is under better control with increasing vaccination rates, additional eligible participants are now in the process of scheduling sessions. An unexpected consequence of these delays due to the COVID-19 pandemic is the fact that brain MRI scans are no longer falling within the 3-year cut-off time point for potential participants who were determined to be eligible before the pandemic began.

## Other Recruitment Challenges

The initial review of the electronic medical record allowed for the identification of those diagnosed with VS syndrome. Only 34% of those identified with a diagnosis of VS were eligible based on review of records. Using data regarding the safety of rTMS in all subjects, the upper limit of age eligibility that was initially proposed was increased from 40 to 65 years and this increased the pool of potential participants by 20%. Approximately 14% of those initially identified by diagnostic codes were ineligible because their brain MRI scan had been performed >3 years prior, and that number grew after delays due to the pandemic. Approximately 62% of contact attempts via phone to those deemed eligible by record review were successful. The most common factor that determined whether the potential participant had continued interest in the study, after initial contact, was the subjective degree of impact of the VS syndrome

on their daily activities. Those who reported that daily activities were significantly impacted by VS were more likely to be willing to consider ways to participate in the future and alter their daily routines and work schedules to be available for study visits. Beyond concerns related to the COVID-19 pandemic, the most common reasons for potential participants to decline to take part in the study was disruption to work schedules and personal obligations, followed by duration of travel to and from the study site. Due to the relative rarity of the VS syndrome, many of the potential participants that were contacted live out of the immediate area or live out of state. Those with commutes over 30 min were the least likely to ask to be called back after the COVID-19 pandemic was under better control and vaccinations were more common.

## Challenges and Modifications to the TMS Schedule

Numerous published studies indicate rTMS is more likely to be effective if performed in succession over multiple days for two or more weeks. Thus, the initial schedule proposed in the protocol included consecutive sessions, 5 days a week for 2 weeks. With the first participant, unforeseen circumstances related to personal and work obligations made it apparent that in order for this pilot study to be successful, one missed session per week should be allowed. For the remainder of the study, flexibility will be maintained in this manner. Another modification that increased interest in the study and interest future contact for participation (for those not comfortable participating during the pandemic) was the ability to schedule study visits in the early morning, late afternoon, or early evening.

## Summary

Currently there are no effective treatments for the VS syndrome, which converging lines of evidence suggest may be a hyperexcitability syndrome. This open-label treatment trial of rTMS for VS syndrome is ongoing, and results will be used to inform the feasibility and utility of a future randomized, controlled trial of rTMS for VS syndrome. The greatest challenge faced in the ongoing study has been difficulty with recruitment during to the COVID-19 pandemic. However, with decreasing COVID-19 restrictions within the United States and the increase in COVID-19 vaccinations in Colorado, there is renewed interest in participation in the study by those previously screened. Given the recent progress to date, the current aim is to complete enrollment by June 2022. Following completion of the study and data analyses, feasibility for future studies will be determined. Ultimately, due to the rarity of the VS syndrome, and the potential under-diagnosis of VS, a multicenter treatment trial will most likely be needed to recruit enough participants to assess treatment efficacy.

Although the challenges faced in this pilot study to date have been, by and large, related to the COVID-19 pandemic, the lessons learned also provide insights for future treatment trials. For example, consecutive daily visits disrupt schedules to a greater degree than a similar number of visits over a greater period of time. Trials in the future should include reimbursement to participants that commensurates to the burden of the schedule, which is greater than the usual for a similar number of visits



over a greater period of time in other types of treatment trials, such as pharmaceutical interventions. The budget should also include reimbursement for travel, hotel costs, and, in some instances, airline travel. These measures would help relieve the burden of concentrated visits for TMS and help address the recruitment issues associated with a rare condition. Finally, budgeting for standard brain MRI scans for those with scans more than 3 years prior to enrollment should also improve eligibility and enrollment.

## ETHICS STATEMENT

Approval for this study was obtained through the Colorado Multiple Institutional Review Board (COMIRB) and written informed consent was obtained, and will be obtained, for all participants. Results will be published following completion of the study and data analyses.

## AUTHOR CONTRIBUTIONS

VP and IB contributed to conception and design of the study. MG and LL carried out study activities and assisted with protocol amendments. MG and VP wrote the first draft of the manuscript. LL contributed to sections of the manuscript

## REFERENCES

1. Lauschke JL, Plant GT, Fraser CL. Visual snow: a thalamocortical dysrhythmia of the visual pathway?. *J Clin Neurosci.* (2016) 28:123–7. doi: 10.1016/j.jocn.2015.12.001
2. Schankin CJ, Maniyar FH, Sprenger T, Chou DE, Eller M, Goadsby PJ. The relation between migraine, typical migraine aura and 'visual snow'. *Headache.* (2014) 54:957–66. doi: 10.1111/head.12378
3. Headache Classification Committee of the International Headache Society. The international classification of headache disorders, 3rd edition. *Cephalalgia.* (2018) 38:1–211. doi: 10.1177/0333102417738202
4. Bou Ghannam A, Pelak VS. Visual snow: a potential cortical hyperexcitability syndrome. *Curr Treat Options Neurol.* (2017) 19:448. doi: 10.1007/s11940-017-0448-3
5. Schankin CJ, Maniyar FH, Digre KB, Goadsby PJ. Visual snow' – a disorder distinct from persistent migraine aura. *Brain.* (2014) 137:1419–28. doi: 10.1093/brain/awu050
6. van Dun K, Bodranghien F, Manto M, Mariën P. Targeting the cerebellum by noninvasive neurostimulation: a review. *Cerebellum.* (2016) 16:695–741. doi: 10.1007/s12311-016-0840-7
7. Khedr EM. Longlasting antalgic effects of daily sessions of repetitive transcranial magnetic stimulation in central and peripheral neuropathic pain. *J Neurol Neurosurg Psychiatry.* (2005) 76:833–8. doi: 10.1136/jnnp.2004.055806
8. Misra UK, Kalita J, Bhoi SK. High-rate repetitive transcranial magnetic stimulation in migraine prophylaxis: a randomized, placebo-controlled study. *J Neurol.* (2013) 260:2793–801. doi: 10.1007/s00415-013-7072-2
9. Food US, and Drug Administration. *FDA Permits Marketing of Transcranial Magnetic Stimulation for Treatment of Obsessive Compulsive Disorder.* (2021). Available online at: <https://www.fda.gov/news-events/press-announcements/fda-permits-marketing-transcranial-magnetic-stimulation-treatment-obsessive-compulsive-disorder> (accessed May 31, 2021).
10. Eichhammer P, Kleinjung T, Landgrebe M, Hajak G, Langguth B. TMS for treatment of chronic tinnitus — neurobiological effects. *Tinnitus.* (2007) 169:369–75. doi: 10.1016/s0079-6123(07)66035-x
11. Klomjai W, Katz R, Lackmy-Vallée A. Basic principles of transcranial magnetic stimulation (TMS) and repetitive TMS (RTMS). *Ann*

and specifically sections on conducting TMS. All authors contributed to manuscript revision, read, and approved the submitted version.

## FUNDING

The Treatment Trial was sponsored by the Visual Snow Initiative, which is a public charity under the fiscal sponsorship of the Edward Charles Foundation, a non-profit 501(c)(3) organization, EIN# 26-4245043.

## ACKNOWLEDGMENTS

The authors wish to express their gratitude for support from Jerri Lusk, Nicole Gendelman, Haley Simpson, Sara Gardon, and Haley Steinert in providing critical administrative and regulatory guidance. The authors are indebted to the Visual Snow Initiative for their support of this trial.

## SUPPLEMENTARY MATERIAL

The Supplementary Material for this article can be found online at: <https://www.frontiersin.org/articles/10.3389/fneur.2021.724081/full#supplementary-material>

12. Lefaucheur JP, Aleman A, Baeken C, Benninger DH, Brunelin J, Lazzaro VD, et al. Evidence-based guidelines on the therapeutic use of repetitive transcranial magnetic stimulation (RTMS): an update (2014–2018). *Clin Neurophysiol.* (2020) 131:474–528. doi: 10.1016/j.clinph.2019.11.002
13. Bliss TVP, Cooke SF. Long-term potentiation and long-term depression: a clinical perspective. *Clinics.* (2011) 66:3–17. doi: 10.1590/s1807-59322011001300002
14. Chen R, Gerloff C, Classen J, Wassermann EM, Hallett M, Cohen LG. Safety of different inter-train intervals for repetitive transcranial magnetic stimulation and recommendations for safe ranges of stimulation parameters. *Electroencephalogr Clin Neurophysiol.* (1997) 105:415–21. doi: 10.1016/s0924-980x(97)00036-2
15. Rossi S, Hallett M, Rossini PM, Pascual-Leone A. Safety, ethical considerations, and application guidelines for the use of transcranial magnetic stimulation in clinical practice and research. *Clin Neurophysiol.* (2009) 120:2008–39. doi: 10.1016/j.clinph.2009.08.016
16. Wassermann EM. Risk and safety of repetitive transcranial magnetic stimulation: report and suggested guidelines from the international workshop on the safety of repetitive transcranial magnetic stimulation, June 5–7, 1996. *Electroencephalogr Clin Neurophysiol.* (1998) 108:1–16. doi: 10.1016/s0168-5597(97)00096-8
17. McKendrick AM, Chan YM, Tien M, Millist L, Clough M, Mack H, et al. Behavioral measures of cortical hyperexcitability assessed in people who experience visual snow. *Neurology.* (2017) 88:1243–9. doi: 10.1212/wnl.00000000000003784
18. McKendrick AM, Chan YM, Vingrys AJ, Turpin A, Badcock DR. Daily vision testing can expose the prodromal phase of migraine. *Cephalalgia.* (2017) 38:1575–84. doi: 10.1177/0333102417741130
19. Stewart LM, Walsh V, Rothwell JC. Motor and phosphene thresholds: A transcranial magnetic stimulation correlation study. *Neuropsychologia.* (2001) 39:415–9. doi: 10.1016/s0028-3932(00)00130-5
20. Lage C, Wiles K, Shergill SS, Tracy DK. A systematic review of the effects of low-frequency repetitive transcranial magnetic stimulation on cognition. *J Neural Transm.* (2016) 123:1479–90. doi: 10.1007/s00702-016-1592-8

21. Kleinjung T, Eichhammer P, Langguth B, Jacob P, Marienhagen J, Hajak G, et al. Long-term effects of repetitive transcranial magnetic stimulation (rtms) in patients with chronic tinnitus. *Otolaryngology*. (2005) 132:566–9. doi: 10.1016/j.otohns.2004.09.134
22. Saunders JC. The role of central nervous system plasticity in tinnitus. *J Commun Disord*. (2007) 40:313–34. doi: 10.1016/j.jcomdis.2007.03.006
23. Canavero S, Bonicalzi V. Central pain syndrome: elucidation of genesis and treatment. *Expert Rev Neurother*. (2007) 7:1485–97. doi: 10.1586/14737175.7.11.1485

**Conflict of Interest:** The authors declare that the research was conducted in the absence of any commercial or financial relationships that could be construed as a potential conflict of interest.

**Publisher's Note:** All claims expressed in this article are solely those of the authors and do not necessarily represent those of their affiliated organizations, or those of the publisher, the editors and the reviewers. Any product that may be evaluated in this article, or claim that may be made by its manufacturer, is not guaranteed or endorsed by the publisher.

Copyright © 2021 Grande, Lattanzio, Buard, McKendrick, Chan and Pelak. This is an open-access article distributed under the terms of the Creative Commons Attribution License (CC BY). The use, distribution or reproduction in other forums is permitted, provided the original author(s) and the copyright owner(s) are credited and that the original publication in this journal is cited, in accordance with accepted academic practice. No use, distribution or reproduction is permitted which does not comply with these terms.



# Visual Snow Syndrome as a Network Disorder: A Systematic Review

Antonia Klein and Christoph J. Schankin\*

Department of Neurology, Inselspital, Bern University Hospital, University of Bern, Bern, Switzerland

**Aim:** By reviewing the existing clinical studies about visual snow (VS) as a symptom or as part of visual snow syndrome (VSS), we aim at improving our understanding of VSS being a network disorder.

**Background:** Patients with VSS suffer from a continuous visual disturbance resembling the view of a badly tuned analog television (i.e., VS) and other visual, as well as non-visual symptoms. These symptoms can persist over years and often strongly impact the quality of life. The exact prevalence is still unknown, but up to 2.2% of the population could be affected. Presently, there is no established treatment, and the underlying pathophysiology is unknown. In recent years, there have been several approaches to identify the brain areas involved and their interplay to explain the complex presentation.

**Methods:** We collected the clinical and paraclinical evidence from the currently published original studies on VS and its syndrome by searching PubMed and Google Scholar for the term visual snow. We included original studies in English or German and excluded all reviews, case reports that did not add new information to the topic of this review, and articles that were not retrievable in PubMed or Google Scholar. We grouped the studies according to the methods that were used.

**Results:** Fifty-three studies were found for this review. In VSS, the clinical spectrum includes additional visual disturbances such as excessive floaters, palinopsia, nyctalopia, photophobia, and entoptic phenomena. There is also an association with other perceptual and affective disorders as well as cognitive symptoms. The studies that have been included in this review demonstrate structural, functional, and metabolic alterations in the primary and/or secondary visual areas of the brain. Beyond that, results indicate a disruption in the pre-cortical visual pathways and large-scale networks including the default mode network and the salience network.

**Discussion:** The combination of the clinical picture and widespread functional and structural alterations in visual and extra-visual areas indicates that the VSS is a network disorder. The involvement of pre-cortical visual structures and attentional networks might result in an impairment of “filtering” and prioritizing stimuli as top-down process with subsequent excessive activation of the visual cortices when exposed to irrelevant external and internal stimuli. Limitations of the existing literature are that not all authors used the ICHD-3 definition of the VSS. Some were referring to the symptom VS, and in many cases, the control groups were not matched for migraine or migraine aura.

**Keywords:** visual snow syndrome, systematic (literature) review, perceptual disorder, electrophysiology, imaging, network disorder, neuroophthalmology, visual disturbance

## OPEN ACCESS

### Edited by:

Lars Neeb,  
Charité – Universitätsmedizin  
Berlin, Germany

### Reviewed by:

Michele Viana,  
King's College London,  
United Kingdom  
Mamoru Shibata,  
Tokyo Dental College Ichikawa  
General Hospital, Japan  
Allison M. McKendrick,  
The University of Melbourne, Australia

### \*Correspondence:

Christoph J. Schankin  
christoph.schankin@insel.ch

### Specialty section:

This article was submitted to  
Headache and Neurogenic Pain,  
a section of the journal  
Frontiers in Neurology

**Received:** 11 June 2021

**Accepted:** 31 August 2021

**Published:** 04 October 2021

### Citation:

Klein A and Schankin CJ (2021) Visual  
Snow Syndrome as a Network  
Disorder: A Systematic Review.  
Front. Neurol. 12:724072.  
doi: 10.3389/fneur.2021.724072

## INTRODUCTION

The first description of the visual snow phenomenon (VS) was presented by Liu et al. in 1995 with four patients with migraine who had interictal visual disturbances (1). Initially, these symptoms were thought to be persistent migraine aura (2, 3). Through the collection of 22 patient reports, Schankin et al. (4) noticed that the symptoms are very characteristic and not as polymorphous as they can be in typical migraine aura (5, 6). This was confirmed in larger groups via an internet survey (235 persons) and an additional semi-structured telephone interview (142 persons with self-assessed VS) (4, 7). It became evident that this disorder also affects patients who have not been diagnosed with migraine (4, 8). Finally, the group concluded that the symptom VS is often associated with additional visual, non-visual, and non-perceptual symptoms forming the visual snow syndrome (VSS), which is distinct from migraine. Based on this, diagnostic criteria have been proposed (4) that have been implemented in the international classification of headache disorders, 3rd edition (ICHD-3) (4, 9). The aim of this review is to summarize what we have learned about the underlying pathophysiology of VSS from clinical presentation, secondary forms, neurobehavioral studies and imaging, as well as electrophysiological testing.

## METHODS

We performed a systematic review on PubMed (accessed May 1, 2021) and Google Scholar (accessed May 15, 2021) using the search term “visual snow.”

We included case reports and studies describing epidemiological, neurophysiological, and imaging findings about the VSS or VS. We excluded articles not written in English or German, non-original work, such as reviews, case reports not adding information to the question of this review, and papers that could not be retrieved via Google Scholar or PubMed.

The records were screened by AK and also evaluated by CJS in respect of the inclusion and exclusion criteria.

Papers released prior to the publication of the diagnostic criteria for the VSS by the International Headache Society in 2018 (9) were not excluded when the criteria could be assessed retrospectively based on the clinical information presented.

Additionally, we performed a non-systematic search for the terms “palinopsia,” “floaters,” “blue field phenomenon,” “selflight of the eye,” “photopsia,” “Nyctalopia,” “Photophobia,” “Lamotrigine” AND “migraine aura,” “thalamostriatal loop,” “thalamocortical dysrhythmia,” and “salience network” to provide definitions of these expressions used in our review.

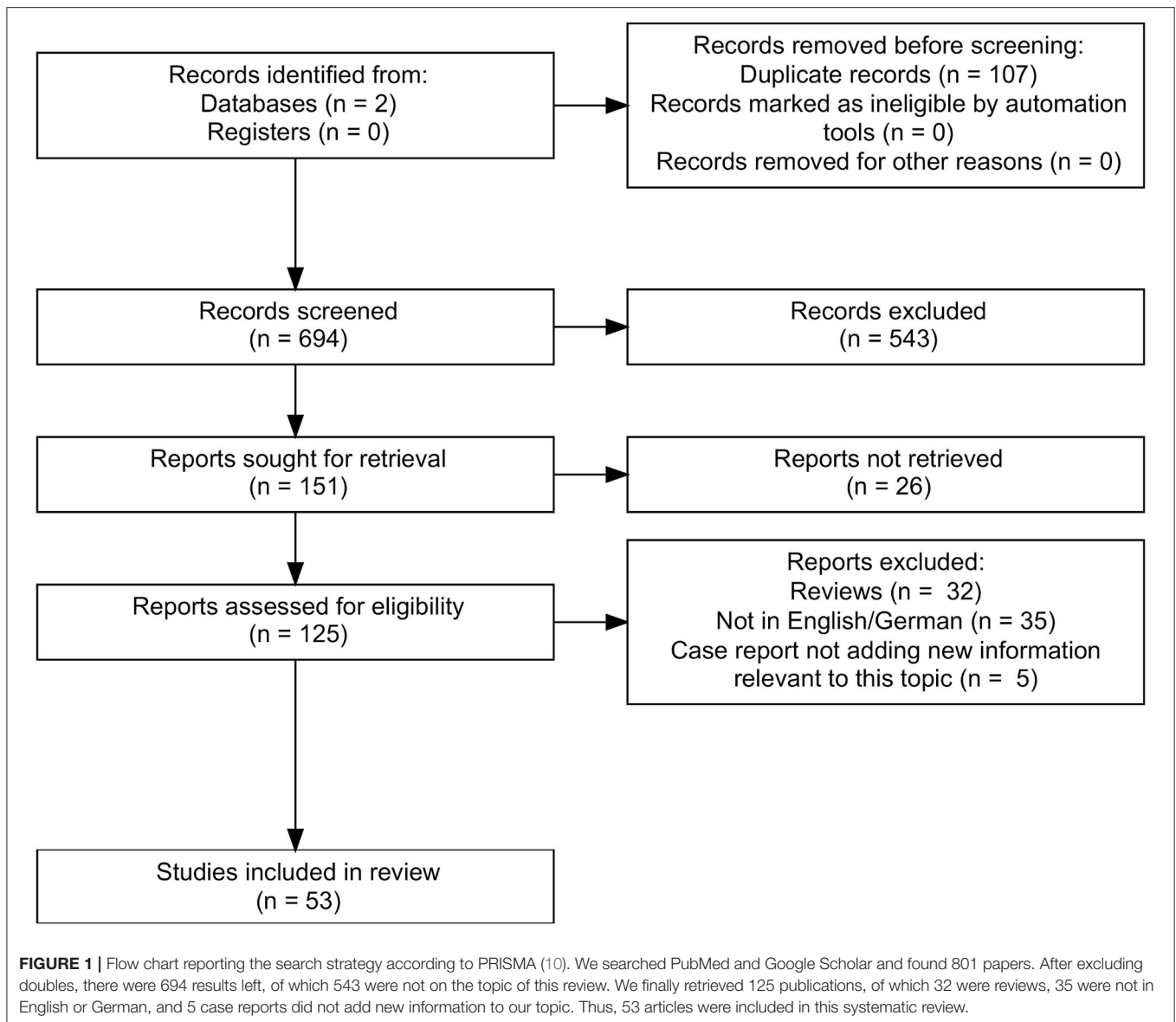
## RESULTS

In total, we found 801 papers. After excluding doubles ( $n = 107$ ) and articles that were not on the topic ( $n = 543$ ) of this review, there were 151 remaining of which 125 could be retrieved. Finally, we included 53 articles (Figure 1). We organized the articles according to the main topic and the used methodology.

## The Clinical Picture

Several studies have collected data on the prevalence of symptoms in groups of patients with VSS or VS, either in online surveys (4, 11, 12) or in interviews at headache centers or neuro-ophthalmologic departments (4, 13–17). Per definition, patients with VS experience a visual static, similar to the flickering of an old TV, with many, moving colored or black-and-white dots in the entire visual field. To fulfill the diagnostic criteria of the ICHD-3, there must be at least two additional characteristic symptoms:

1. Palinopsia is an abnormal, continued perception of an object even after it is no longer in the visual field (18, 19). This symptom is reported in 33% (14) to 86% (4) of patients with VSS. It can manifest as a steady afterimage or as “trailing,” i.e., positive afterimages persisting directly after a dynamic object (20).
2. Another group of symptoms are enhanced entoptic phenomena, which are thought to be perceptions of endogenous structures/phenomena of the eye (21):
  - Floaters can be caused by degenerative changes in the vitreous body including liquefaction (22, 23). According to the above-mentioned studies, between 61% (16) and 100% (24) of VSS patients are perceiving them in an excessive way, i.e., far more than normal vitreous floaters and far more than expected from ophthalmological findings.
  - The so-called “blue field phenomenon” is characterized by a perception of moving fragments against a bright background, such as the sky (25). It is the autovisualization of the own leukocytes in the retinal capillaries (26). It has been shown that about 42% (27) to 79% (4) of VSS patients experience this symptom, also in an excessive magnitude.
  - The “selflight of the eye” is light or colored clouds seen with closed eyes (26) and perceived by 16% (16) to 71% (11) of VSS patients. The cause of this phenomenon is unknown. Bowen et al. hypothesized that it might be linked to retinal circulation (26).
  - Photopsia, reported in 24% (15, 16) to 63% (4, 11) of VSS patients, are “flash-like” positive visual phenomena with sudden onset and brief duration (28). The origin in different diseases can be generated by almost all components of the visual path from ocular mechanical disturbances to affections of the secondary visual pathways (28).
3. Nyctalopia: Patients complain about poor vision in darker environments. In the literature, it has often been described in patients with retinal diseases (especially affecting the rod cells), but the inability to adapt to light conditions might involve almost all components of the visual pathway (29). About 28% (16) to 78% (11) of VSS patients are affected.
4. Photophobia, which is experienced by 44% (16) to 81% (11), is hypersensitivity, discomfort, or even pain caused by “normal” light (27, 30). Eren et al. (27) compared a group of 19 VSS patients to a group of 19 controls matched for age, sex, migraine, and aura using the Leiden Visual Sensitivity Scale (31). They demonstrated that VSS patients had increased



visual sensitivity at a level comparable to patients with chronic migraine during their attacks (27).

## Prevalence and Course of Disease

Graber et al. conducted the first longitudinal study in VSS. Symptoms were persistent, in some cases up to 8 years (32). In several studies, there was a fraction of patients reporting VSS for as long as they could remember (4, 11, 14). The data so far suggest that the VSS does often become a chronic disease. There are also published cases of episodic VS as part of a migraine attacks, but different from aura (33).

The first study to assess the prevalence of VSS within the population was by Kondziella et al. who used an online survey with 1,015 participants. Although this study has its limitations (34), a larger proportion of the general population, 2.2% in this study, might fulfill the criteria of VSS (35).

## Associated Symptoms and Disorders

Between 52% (13) and 72% (11) of patients with VSS also suffer from migraine. In several clinical studies, patients reported migraine attacks in association with the appearance or the aggravation of their VSS (4, 11, 14, 16, 36). Schankin et al. (4) and Puledda et al. (11) explored the relationship between migraine status and the manifestation of VSS and found that people with migraine tended to have more symptoms as a marker of a stronger affection by this disease. Another highly prevalent comorbidity affecting between 15% (14) and 75% (11) of patients is tinnitus. Puledda et al. showed that for the VSS patients in their cohort who were also affected by tinnitus, the probability of having additional visual symptoms was 2 fold increased (11). Mehta et al. reported that 7.1% of their cohort with VS had a diagnosis of fibromyalgia (16). Additionally, postural orthostatic tachycardia syndrome (16), dizziness (16), balance problems

**TABLE 1** | Summary of the imaging findings.

Modality	Study	Patients/ controls	Main findings
FDG-PET	Schankin et al. (34)	20/20	<ul style="list-style-type: none"> <li>• Hypermetabolism in the right lingual gyrus</li> <li>• Hypometabolism in the right superior temporal gyrus and the left inferior parietal lobule</li> </ul>
MRI -Volumetry	Schankin et al. (34)	17/17	<p><u>Global analysis:</u></p> <ul style="list-style-type: none"> <li>• GMV increased: junction of the right lingual and fusiform gyrus, right middle temporal gyrus, right parahippocampal gyrus, left superior temporal gyrus, right anterior cingulate cortex</li> <li>• GMV decreased: left superior temporal gyrus</li> </ul>
	Puledda et al. (11)	24/24	<p><u>Whole brain morphology, parcellated cerebellar analyses, ROI-analyses:</u></p> <ul style="list-style-type: none"> <li>• GMV increased: left V1(WB), left V1/V2 area (ROI), left V5 area (ROI), crus I/lobule VI of the left cerebellar hemisphere</li> </ul>
	Aldusary et al. (69)	19/16	<p><u>Voxel-based morphometry:</u></p> <ul style="list-style-type: none"> <li>• GMV increased: right lingual gyrus, visually: occipital bending in 7 patients</li> </ul>
fMRI	Puledda et al. (11)	24/24	<p><u>MRI block-design (visual stimulation) with MRS:</u></p> <ul style="list-style-type: none"> <li>• Reduced BOLD responses: left and right anterior insula, MRS lactate-Peak over right gyrus lingualis with anticorrelation to BOLD response</li> </ul>
	Puledda et al. (68)	24/24	<p><u>fMRI seed-based connectivity analysis:</u></p> <ul style="list-style-type: none"> <li>• Resting state (hyperconnectivity) <ul style="list-style-type: none"> <li>- right pulvinar (PV)- right postcentral, supramarginal gyrus (SMG)</li> <li>- Pre-cuneus-right pre-central gyrus/frontal eye fields</li> <li>- V1-SMG and post-central gyrus</li> </ul> </li> <li>• Resting state (hypoconnectivity): <ul style="list-style-type: none"> <li>- right V5-posterior cingulate cortex.</li> <li>- cerebellar seed- PCC and medial precuneus</li> <li>- PV- bilateral caudate nuclei</li> </ul> </li> <li>• Task (hyperconnectivity) <ul style="list-style-type: none"> <li>- right PV-right lingual gyrus</li> <li>- right V1- right V5, postcentral,precentral gyri, SMG, premotor cortex, supplementary motor cortex(SMA), FEF</li> <li>- V5-right cuneus, Brodmann 17, 18 and 19, the FEF, SMG, premotor cortex, SMA, superior parietal lobule (SPL) and intraparietal sulcus, V1</li> <li>- pMCC/PCC-bilateral medial pre-cuneus, PCC.</li> <li>- cerebellar seed-RSPL, lat pre-cuneus, post-central gyrus</li> </ul> </li> <li>• Task (hypoconnectivity) <ul style="list-style-type: none"> <li>- V5-posterior cingulate cortex, bilat medial pre-cuneus, TPJ und AG</li> </ul> </li> </ul>
	Aldusary et al. (69)	19/16	<p><u>Resting state fMRI (seed-based):</u></p> <ul style="list-style-type: none"> <li>• Hyperconnectivity: <ul style="list-style-type: none"> <li>- Left anterior inferior temporal gyrus-left posterior temporal fusiform gyrus</li> <li>- Right anterior inferior temporal gyrus-right anterior temporal fusiform gyrus</li> <li>- Left posterior superior temporal gyrus-right inferior occipito-temporal gyrus</li> <li>- Left angular gyrus-left lateral pre-frontal cortex</li> <li>- Right frontal eye field-right angular gyrus</li> <li>- Left inferior frontal gyrus-left middle frontal gyrus</li> </ul> </li> </ul>
[ <sup>123</sup> I]-IMP SPECT	Shibata et al. (74)	3 patients/no controls	<p>[<sup>123</sup>I]-IMP single-photon emission computed tomography</p> <ol style="list-style-type: none"> <li>1. Right temporooccipital hypoperfusion</li> <li>2. Mild bilateral frontal hypoperfusion</li> <li>3. No pathological findings</li> </ol>

(15), paresthesia (37), and tremor (15) have been described, but the latter without a further differentiation of the subtype.

Psychiatric comorbidities seem to be quite common in VSS, especially affective disorders such as anxiety, up to 50% (13), and depression, up to 58% (13). Patients also report cognitive complaints in the form of “brain fog” (16) and concentration problems (4). Another frequent symptom is derealization (16), which can be linked to the above-mentioned psychiatric disorders or appear independently (38).

## Secondary Forms of VS and Triggers

Ophthalmological or radiological routine findings are without pathological findings in most cases (4, 11, 16, 17, 39). There are

some case reports of patients with positive visual phenomena similar to those in VS, which turned out to be caused by ocular pathology, such as birdshot retinopathy (16, 40), but also diseases leading to an extensive visual impairment like in a patient described by Mehta et al. who had advanced macular atrophy with cystic retinal degeneration and developed Charles-Bonnet syndrome with VS in addition (16). This might indicate that sensory deafferentation could play a role in the development of VS.

Cerebral diseases, especially affecting the occipital and/or temporal brain regions, such as a pinealis cyst (with amelioration of symptoms after removal) (41), a case of Creutzfeldt-Jakob disease (42), idiopathic intracranial hypertension, posterior

cortical atrophy, multiple sclerosis (16), or glutamic acid decarboxylase antibody syndrome (43), have been described to cause secondary VS or even VSS. Catarci reported one patient who developed permanent left-sided VS in the context of an acute occlusion of the right posterior cerebral artery (44).

In some patients, systemic infections, seizures of probable temporal or occipital origin (16, 45), concussions (16, 45), hormonal changes, drugs such as steroids (16), antidepressants (46), or isotretinoin (47) were suspected triggers for VSS.

An important differential diagnosis is “hallucinogen persisting perception disorder” (HPPD): It is a chronic syndrome characterized by a spontaneous recurrence of perceptual/visual disturbances that are similar to those generated during an intoxication with a hallucinogenic drug (DSM V) (48). In the cohort of Puledda et al. (11), there were no significant differences concerning the phenotype of the VSS between a HPPD group (70 patients) and the VSS group (1,061 patients). The HPPD patients had similar comorbidities (migraine and tinnitus) (11). Van Dongen et al. did not find a difference in VSS manifestation (intensity) in a group of 24 HPPD patients and 37 VSS patients, but the VSS patients were significantly more affected by migraine (49). Drugs that were reported to cause VSS in HPPD were ecstasy, cannabis, psilocybin mushrooms, amphetamine, 4-FMP, 3-MMC, 2C-B, ketamine, and nitrous oxide (49). This is important since these recreational drugs can obviously “trigger” a VSS-like disorder in subjects who *per se* do not have increased risk due to the non-increased prevalence of migraine and migraine aura.

## Evidence for Therapeutic Effect of Medication

The current data indicate a possible effect of lamotrigine, which is an anti-seizure medication also shown to be preventive in migraine with visual aura (50). It inhibits voltage-gated sodium and calcium channels in the central nervous system, restricting the firing rate of cortical neurons and thereby lowering cortical excitability (50). Fekete et al. reported a case of VSS with complete remission under the therapy with lamotrigine (51), while other studies found only a small effect (in the sense of an amelioration) in a small number of patients (13, 52). There are single case reports of a decrease in symptom severity after the use of mydriatics (53) and a remission under amitriptyline (54). Antipsychotic drugs (55), glucocorticoids, beta-blocker, acetazolamide (17), other antidepressants (56) and antiseizure medications, benzodiazepines, migraine prophylaxis, and even ketamine were tried with a few cases of partial improvement, but mostly no benefit (16).

## Neurobehavioral Measures

Since the diagnosis of the VSS is at the moment solely based on subjective measures, there have been several attempts to find a specific neurobehavioral or electrophysiological signature. Solly et al. utilized oculomotor tasks to examine 64 VSS patients and 23 controls (one subgroup of VSS patients with migraine, one without migraine, and a healthy control group).

They demonstrated significantly quicker prosaccades in VSS patients as well as more errors in incongruencies between precue and target (37). A follow-up study with 67 patients examined interfering or conflicting saccade tasks (of which one was internally cued) again showing quicker prosaccadic movements and more errors in choosing (also internally cued) antisaccadic (contralateral) marks. This suggests that the underlying problem might go beyond the management of attention given to external stimuli, but rather include a coordination problem on the level of the saccadic control system (with hyperactivity in the prosaccade system) (57).

Three groups examined visual perception thresholds in VSS patients demonstrating decreased spatial contrast sensitivity (17), reduced center-surround contrast suppression, elevated luminance increment thresholds on a textured background (58), and significantly more difficulties recognizing image orientations specifically at a flickering frequency of 15 Hz (59).

In another study, VS patients showed normal color and rapid flicker sensitivity but a delayed dilatation after the initial constriction of the pupil after the presentation of a chromatic stimulus (60). The latter could indicate a longer afferent stimulus persistence (60) or an autonomic dysregulation (17). A limitation of this study (60) was the small number of patients and controls included.

## Electrophysiological Evidence

As an approach to study the visual pathway, several groups recorded visual evoked potentials. Eren et al. compared a group of 18 VSS patients to matched healthy controls and migraine patients. They demonstrated an increased N145 latency, which could indicate a disturbance in the secondary visual areas. There were also reduced N75-P100 amplitudes representing the afferent visual pathways between the retina and the primary visual cortex (61). Two groups investigated habituation of the P100-response after repetitive stimulation in VS patients compared to healthy controls. Yildiz et al. included a subgroup of VSS patients with migraine and a subgroup of VSS patients without migraine (24), while Luna et al. examined only one VSS patient who did not have the diagnosis of a migraine (62). In both papers, decreased habituation indicated increased cortical excitability over the afferent visual pathways, especially the primary visual cortex (V1) and possibly a disturbance of negative feedback mechanisms (24, 62).

In an occipital TMS application, the phosphene threshold was lower in the VSS group compared to healthy controls (24). These findings, too, might indicate neuronal hyperexcitability in the visual pathway (24). In contrast, Eren et al. could not find a significant effect of TMS application over the visual cortex on letter recognition (63). Grey et al. applied TMS at 10 and 10 + 1 Hz over occipital brain areas during 20 sessions in nine patients. They found an improvement of VS intensities after the 10 + 1 Hz application, but no significant difference of the comparison to Sham or 10 Hz (64).

## Brain Imaging

Another attempt to find the causes underlying the VSS is looking for functional and structural correlates in neuronal imaging studies. Schankin et al. combined [ $^{18}\text{F}$ ]-2-fluoro-2-deoxy-D-glucose positron emission tomography (FDG-PET) in 20 VSS patients (matched with 20 healthy controls) with MRI in 17 patients and controls (65). Puledda et al. performed MRI (magnetic resonance imaging) with seed-based MR spectroscopy in 24 patients and an equal number of matched controls (66–68). Aldusary et al. compared a cohort of 19 VSS patients to 16 controls using MRI (69). In all three studies, patients and controls were matched for age and sex but not migraine (**Table 1**).

In the FDG-PET analysis, focal hypermetabolism was demonstrated in the secondary visual area of the right gyrus lingualis presumably as a correlate of neuronal hyperactivity in this area (65). A matching increase in gray matter volume (in MRI volumetry) was shown in the adjacent right fusiform gyrus, and in the lingual gyrus itself in the cohort of Aldusary et al. (69). Interestingly, the symptom duration positively correlated with gray matter volume (GMV) in both lingual gyri (69). This might reflect differences caused by neuronal plasticity (70). Additionally, the seed-based MR spectroscopy by Puledda et al. showed a lactate peak in this area correlating negatively with the BOLD response as a sign of anaerobic (possibly inefficient or abnormal) metabolism (67).

There are hints that other areas of the visual system might be implicated as well. Puledda et al. found increased gray matter volume (whole brain voxel-wise volumetry) in the left primary (seed-based) and secondary visual cortex (V2 and V5) (66). Beyond that, the group showed in a seed-based functional MRI (fMRI) analysis of the regions of interest in the right hemisphere that there was increased connectivity between the thalamus and the lingual gyrus at tasks while the connection between thalamus and basal ganglia resting state was decreased. V1 and V5 showed hyperconnectivity between each other and with widespread cortical regions (somatosensory and motor areas including the supramarginal gyrus and frontal eye field) during stimulation. V5 had a decreased connectivity to the posterior cingulate cortex at rest, which is part of the default mode network (68). Aldusary et al. found seed-based fMRI resting state hyperconnectivity between extrastriate visual and other temporal brain regions (69).

Other non-visual brain areas seem to be affected as well. The response to a stimulation mimicking VS resulted in a reduced BOLD response compared to baseline over the bilateral anterior insulae (67, 71). Aldusary showed resting state hyperconnectivity between pre-frontal and parietal brain regions (69). Schankin et al. demonstrated FDG hypometabolism in the right superior temporal gyrus and the left inferior parietal lobule without associated structural alterations (65). Volumetrically, increased gray matter volume in the right middle temporal gyrus, parahippocampal gyrus, the left superior temporal gyrus and right anterior cingulate cortex (65), and cerebellum (seed-based) crus I/lobule V of the left hemisphere (66) was found.

There is one case report of a patient with VSS and another one about a patient with a prolonged migraine aura with VS demonstrating increased diffusivity in the occipital lobe, as

well as the temporal lobes including the dorsal visual stream, the ventral visual stream, and the integrative visual stream (72, 73). Shibata et al. performed [ $^{123}\text{I}$ ]-IMP single-photon emission computed tomography in one VSS patient showing right occipital and temporal hypoperfusion with and minimal bifrontal hypoperfusion in a second case (74).

## DISCUSSION

The clinical picture of VSS consists of a characteristic constellation of visual symptoms that might be attributed to different components of the visual pathway.

In patients with migraine, the involvement of the right lingual gyrus has been shown in photophobia (75). In VSS, we find imaging, metabolic, and possibly electrophysiological evidence of increased metabolism, excitability, and connectivity in and with this area. The fMRI findings by Puledda et al. (68) indicate an implication of the visual motion area V5 with increased connectivity within and beyond the visual cortices with multiple brain areas. These give further insights into the pathophysiological mechanisms underlying the VS phenomenon and could be connected to the dynamic nature of this visual misperception (68).

The perception of entoptic phenomena indicates a “filtering” problem since these partly “physiological” but irrelevant sensations are enhanced in VSS (22).

On another level, nyctalopia and the increased luminance threshold (58) and decreased contrast sensitivity (17) might be connected by a lack of inhibitory feedback mechanisms in the visual system, normally allowing to extract relevant information and suppress visual noise.

Palinopsia might also be a phenomenon of disinhibition, leading to the repetitive perception of a dysfunctional visual memory (76). In this regard, previous case reports show that palinopsia can be caused by occipital, parietal, or temporal lesions mostly of the right hemisphere (76).

The electrophysiological evidence suggests hyperexcitability of the primary visual cortex (24, 61) possibly explaining the perception of photopsia.

Puledda et al. found in their fMRI analysis a disturbance in thalamostriatal connectivity while thalamocortical connections were increased (68). The thalamostriatal loop was shown to be relevant in visual learning (77), and it was demonstrated in an animal model that a disruption of this system leads to a decrease in visual precision (68, 77). The thalamus is linked to widespread areas of the cortex including the primary and secondary visual areas of the brain (78). This is consistent with the hypothesis that VSS could be a form of thalamocortical dysrhythmia (15).

On the other hand, the decreased BOLD response over the anterior insulae (67) as well as the increased gray matter volume over the right anterior cingulate cortex (65) could indicate a disturbance in the so-called salience network. This network plays a central role in the steering of attention, coordination between large-scale networks in task-related functions (79), and the selection of relevant stimuli (80). Furthermore, the main



hubs of the salience network and the thalamus are closely interconnected (81).

There are some limitations of studies on VSS that have to be considered also in this review. Many of the earlier studies were done in smaller groups. For many imaging and most electrophysiological findings, patients have not been matched for migraine or migraine aura. This is relevant since a high comorbidity would confound the findings by also investigating migraine instead of VSS alone. In some of the case reports and neurobehavioral tests, the ICHD-3 criteria for VSS have not been applied. Similarly, patients might have been affected by the symptom VS, instead of VSS. Furthermore, intake of medication or previous drug use has not been reported in all studies. Future studies have to apply the ICHD 3 criteria for VSS and should include a reasonably sized number of patients that are matched for migraine and migraine aura. To study pharmacological and non-pharmacological treatment approaches, randomized and controlled trials are needed.

## CONCLUSION

Already from a clinical perspective, the symptoms of VSS cannot be attributed to a single brain area or a functional unit. Rather, there is evidence of a network disorder that might manifest as a disturbance in coordination or interaction between different parts of the visual system causing a loss of inhibitory modulation and thereby hyperactivity in the primary and secondary visual cortex.

VSS seems to be a spectrum disorder with different degrees of severity, e.g., defined by the number of additional symptoms (11). There is an association with tinnitus thought to be caused by cortical hyperexcitability and production of a phantom sensation (82). Several patients may suffer from comorbid fibromyalgia, the classical centralized pain disorder with hypersensitivity to external stimuli (83). There are potentially common underlying mechanisms (doi: 10.1111/head.14213).

Migraine is the most prevalent comorbidity in patients affected by VSS. Migraine can be seen as a sensory gating

disorder with a persisting hypersensitivity to internal and external stimuli even in the interictal state (84, 85). It is associated with more severe manifestations of VSS. It can be hypothesized that migraine could cause a pre-disposition to develop a persistent sensory network disorder like VSS or, based on case reports, migraine attacks could even be triggers.

Other triggers include medications, seizure, trauma, and recreational drug use, when HPPD is counted as a form of secondary VSS. Secondary VSS caused by structural lesions seem to involve different posterior areas of the brain. One potential mechanism of secondary and triggered forms might be an imbalance of this network.

Understanding the communication within this network and how its modulation might lead to VSS is crucial if treatment strategies should be developed for this currently almost untreatable condition.

## DATA AVAILABILITY STATEMENT

The original contributions presented in the study are included in the article, further inquiries can be directed to the corresponding author.

## AUTHOR CONTRIBUTIONS

AK: conceived and designed the research, collected the data, organized the papers, and wrote the paper. CJS: conceived and designed the research, organized the papers, and wrote the paper and checked the manuscript. All authors contributed to the article and approved the submitted version.

## FUNDING

This research was funded by the Visual snow Initiative: funding of the publication fee. CJS was supported by Baasch Medicus Foundation.

## REFERENCES

- Liu GT, Schatz NJ, Galetta SL, Volpe NJ, Skobieranda F, Kosmorsky GS. Persistent positive visual phenomena in migraine. *Neurology*. (1995) 45:664–8. doi: 10.1212/WNL.45.4.664
- Jäger H, Giffin N, Goadsby P. Diffusion-and perfusion-weighted MR imaging in persistent migrainous visual disturbances. *Cephalalgia*. (2005) 25:323–32. doi: 10.1111/j.1468-2982.2004.00858.x
- Simpson JC, Goadsby PJ, Prabhakar P. Positive persistent visual symptoms (visual snow) presenting as a migraine variant in a 12-year-old girl. *Pediatr Neurol*. (2013) 49:361–3. doi: 10.1016/j.pediatrneurol.2013.07.005
- Schankin CJ, Maniyar FH, Digre KB, Goadsby PJ. ‘Visual snow’ – a disorder distinct from persistent migraine aura. *Brain*. (2014) 137:1419–28. doi: 10.1093/brain/awu050
- Bartleson J. Transient and persistent neurological manifestations of migraine. *Stroke*. (1984) 15:383–6. doi: 10.1161/01.STR.15.2.383
- Viana M, Tronvik EA, Do TP, Zecca C, Hougaard A. Clinical features of visual migraine aura: a systematic review. *J Headache Pain*. (2019) 20:64. doi: 10.1186/s10194-019-1008-x
- Schankin CJ, Maniyar FH, Sprenger T, Chou DE, Eller M, Goadsby PJ. The relation between migraine, typical migraine aura and “visual snow”. *Headache*. (2014) 54:957–66. doi: 10.1111/head.12378
- Sastre-Ibáñez M, Santos-Bueso E, Porta-Etessam J, García-Feijoo J. Visual snow: report of three cases. *J Fr Ophthalmol*. (2015) 38:e157–8. doi: 10.1016/j.jfo.2014.06.030
- Olesen J. Headache Classification Committee of the International Headache Society (IHS) the international classification of headache disorders, abstracts. *Cephalalgia*. (2018) 38:1–211. doi: 10.1177/0333102417738202
- Page MJ, Moher D, Bossuyt PM, Boutron I, Hoffmann TC, Mulrow CD, et al. PRISMA 2020 explanation and elaboration: updated guidance and exemplars for reporting systematic reviews. *BMJ*. (2021) 372:osf.io/gwdhk. doi: 10.31222/osf.io/gwdhk
- Puledda F, Schankin C, Goadsby PJ. Visual snow syndrome: a clinical and phenotypical description of 1,100 cases. *Neurology*. (2020) 94:e564–74. doi: 10.1212/WNL.0000000000008909
- Viana M, Puledda F, Goadsby PJ. Visual snow syndrome: a comparison between an Italian and British population. *Eur J Neurol*. (2020) 27:2099–101. doi: 10.1111/ene.14369

13. Van Dongen RM, Waaijer LC, Onderwater GL, Ferrari MD, Terwindt GM. Treatment effects and comorbid diseases in 58 patients with visual snow. *Neurology*. (2019) 93:e398–403. doi: 10.1212/WNL.00000000000007825
14. Bessero A-C, Plant GT. Should “visual snow” and persistence of after-images be recognised as a new visual syndrome? *J Neuro Neurosurg Psychiatry*. (2014) 85:1057. doi: 10.1136/jnnp-2013-306827
15. Lauschke JL, Plant GT, Fraser CL. Visual snow: a thalamocortical dysrhythmia of the visual pathway? *J Clin Neurosci*. (2016) 28:123–7. doi: 10.1016/j.jocn.2015.12.001
16. Mehta DG, Garza I, Robertson CE. Two hundred and forty-eight cases of visual snow: a review of potential inciting events and contributing comorbidities. *Cephalalgia*. 2021:0333102421996355. doi: 10.1177/0333102421996355
17. Yoo Y-J, Yang HK, Choi J-Y, Kim J-S, Hwang J-M. Neuro-ophthalmologic findings in visual snow syndrome. *J Clin Neurol*. (2020) 16:646. doi: 10.3988/jcn.2020.16.4.646
18. Critchley M. Types of visual perseveration: “paliopsia” and “illusory visual spread”. *Brain*. (1951) 74:267–99. doi: 10.1093/brain/74.3.267
19. Abert B, Ilsen PF. Palinopsia. *Optometry*. (2010) 81:394–404. doi: 10.1016/j.optm.2009.12.010
20. Abraham HD. Visual phenomenology of the LSD flashback. *Arch Gen Psychiatry*. (1983) 40:884–9. doi: 10.1001/archpsyc.1983.01790070074009
21. Friedman B. Observations on entoptic phenomena. *Arch Ophthalmol*. (1942) 28:285–312. doi: 10.1001/archoph.1942.00880080103012
22. Cipolletta S, Beccarello A, Galan A. A psychological perspective of eye floaters. *Qual Health Res*. (2012) 22:1547–58. doi: 10.1177/1049732312456604
23. Sommerville DN. Vitrectomy for vitreous floaters: analysis of the benefits and risks. *Curr Opin Ophthalmol*. (2015) 26:173–6. doi: 10.1097/ICU.0000000000000150
24. Yildiz FG, Turkyilmaz U, Unal-Cevik I. The clinical characteristics and neurophysiological assessments of the occipital cortex in visual snow syndrome with or without migraine. *Headache*. (2019) 59:484–94. doi: 10.1111/head.13494
25. Riva CE, Petrig B. Blue field entoptic phenomenon and blood velocity in the retinal capillaries. *J Opt Soc Am*. (1980) 70:1234–8. doi: 10.1364/JOSA.70.001234
26. Bowen SF. Retinal entoptic phenomena: some diagnostic use. *Arch Ophthalmol*. (1963) 69:551–5. doi: 10.1001/archoph.1963.00960040557003
27. Eren OE, Ruscheweyh R, Straube A, Schankin CJ. Quantification of photophobia in visual snow syndrome: a case-control study. *Cephalalgia*. (2020) 40:393–8. doi: 10.1177/0333102419896780
28. Virdee J, Mollan SP. Photopsia. *Prac Neurol*. (2020) 20:415–9. doi: 10.1136/practneurol-2019-002460
29. Mehra D, Le PH. *Physiology, Night Vision* (2019).
30. Digre KB, Brennan KC. Shedding light on photophobia. *J Neuroophthalmol*. Tampa: StatPearls Publishing (2012) 32:68–81. doi: 10.1097/WNO.0b013e318247548
31. Perenboom MJ, Najafabadi AHZ, Zielman R, Carpay JA, Ferrari MD. Quantifying visual allodynia across migraine subtypes: the Leiden Visual Sensitivity Scale. *Pain*. (2018) 159:2375. doi: 10.1097/j.pain.0000000000001343
32. Graber M, Goadsby P, Scutelnic A, Schankin C. Natural course of Visual Snow Syndrome: a long-term follow-up study. *Eur J Neurol*. (2020) 27:162 (EPR1103). doi: 10.1111/ene.14307
33. Hodak J, Fischer U, Bassetti CL, Schankin CJ. Episodic visual snow associated with migraine attacks. *JAMA Neurol*. (2020) 77:392–3. doi: 10.1001/jamaneurol.2019.4050
34. Schankin CJ, Puledda F, Goadsby PJ. Visual snow syndrome: is it normal or a disorder – and what to do with patients? *Eur J Neurol*. (2020) 27:2393–5. doi: 10.1111/ene.14436
35. Kondziella D, Olsen MH, Dreier JP. Prevalence of visual snow syndrome in the UK. *Eur J Neurol*. (2020) 27:764–72. doi: 10.1111/ene.14150
36. Beyer U, Gaul C. Visual snow. *Der Nervenarzt*. (2015) 86:1561–5. doi: 10.1007/s00115-015-4401-y
37. Solly EJ, Clough M, McKendrick AM, Foletta P, White OB, Fielding J. Ocular motor measures of visual processing changes in visual snow syndrome. *Neurology*. (2020) 95:e1784–91. doi: 10.1212/WNL.00000000000010372
38. Hunter EC, Phillips ML, Chalder T, Sierra M, David AS. Depersonalisation disorder: a cognitive-behavioural conceptualisation. *Behav Res Ther*. (2003) 41:1451–67. doi: 10.1016/S0005-7967(03)00066-4
39. Tegetmeyer H. [Visual snow syndrome: symptoms and ophthalmological findings]. *Klinische Monatsblätter für Augenheilkunde*. (2017) 234:713–8. doi: 10.1055/s-0042-109701
40. Patel RC, Vitale AT, Creel DJ, Digre KB. Not all that flickers is snow. *J Neuro Ophthalmol*. (2021) 41:e97–9. doi: 10.1097/WNO.0000000000000935
41. Weiß S, Rohde V, Hautmann X, Schittkowski M. Visual-snow-syndrom – Wenn die Augen rauschen. *Der Ophthalmologe*. (2021) 118. doi: 10.1007/s00347-021-01398-1. [Epub ahead of print].
42. Chen BS, Lance S, Lallu B, Anderson NE. Visual snow: not so benign. *J Clin Neurosci*. (2019) 64:37–9. doi: 10.1016/j.jocn.2019.03.023
43. Piquet AL, Khan M, Warner JEA, Wicklund MP, Bennett JL, Leehey MA, et al. Novel clinical features of glycine receptor antibody syndrome. A series of 17 cases. *Neurol Neuroimmunol Neuroinflamm*. (2019) 6:e592. doi: 10.1212/NXI.0000000000000592
44. Catarci T. Occipital ischaemic stroke after visual snow phenomenon—a case report. *Cephalalgia*. (2021) 41:871–4. doi: 10.1177/0333102420985444
45. Polster T, Schaefer S, Panzer A. Visual snow—two adolescents with a new syndrome different from migraine or epilepsy. *Neuropediatrics*. (2019) 50:51–55. doi: 10.1055/s-0039-1698175
46. Eren OE, Schöberl F, Schankin CJ, Straube A. Visual snow syndrome after start of citalopram—novel insights into underlying pathophysiology. *Eur J Clin Pharmacol*. (2021) 77:271–2. doi: 10.1007/s00228-020-02996-9
47. Berkowitz E, River Y, Digre K, Tiosano B, Kesler A. Visual snow: a case series from Israel. *Case Rep Ophthalmol*. (2020) 11:205–11. doi: 10.1159/000508602
48. Orsolini L, Valchera A, Papanti D, Vecchiotti R, De Berardis D. The “Endless Trip”: psychopathology and psychopharmacology in the Hallucinogen Persisting Perception Disorder (HPPD). *Eur Psychiatry*. (2020) 33:S310-S. doi: 10.1016/j.eurpsy.2016.01.1060
49. van Dongen RM, Alderlieste GJ, Onderwater GLJ, Ferrari MD, Terwindt GM. Migraine prevalence in visual snow with prior illicit drug use (Hallucinogen Persisting Perception Disorder) versus without. *Eur J Neurol*. (2021) 28:2631–8. doi: 10.1111/ene.14914
50. Buch D, Chabriat H. Lamotrigine in the prevention of migraine with aura: a narrative review. *Headache*. (2019) 59:1187–97. doi: 10.1111/head.13615
51. Fekete R. Visual snow syndrome successfully treated with lamotrigine: case report. (P4.129). *Neurology*. (2018) 90(15 Suppl.):129.
52. Unal-Cevik I, Yildiz FG. visual snow in migraine with aura: further characterization by brain imaging, electrophysiology, and treatment – case report. *Headache: The J Head Face Pain*. (2015) 55:1436–41. doi: 10.1111/head.12628
53. Coleman W, Sengupta S, Boisvert CJ. A case of visual snow treated with phenylephrine. *Headache*. (2021) 61:792–3. doi: 10.1111/head.14118
54. Wentzell S, Ryan M. Visual snow syndrome: a case report and new treatment option. *Clin Med Rev Case Rep*. (2018) 5:246. doi: 10.23937/2378-3656/1410246
55. Prashar KS, Titus AM, Kinkhabwala V, Hirsch AR. 148 visual snow defeats guardians of the galaxy volume 2: unremitting pixelation despite three-dimensional stereoscopic film. *CNS Spectrums*. (2018) 23:91–2. doi: 10.1017/S1092852918000421
56. Eren O, Schankin CJ. Mirtazapine for treatment of visual snow syndrome: a case series with insights into pathophysiology and therapy. *Clin Transl Neurosci*. (2020) 4:2514183X20925695. doi: 10.1177/2514183X20925695
57. Solly EJ, Clough M, McKendrick AM, Foletta P, White OB, Fielding J. Eye movement characteristics provide an objective measure of visual processing changes in patients with visual snow syndrome. *Sci Rep*. (2021) 11:1–10. doi: 10.1038/s41598-021-88788-2
58. McKendrick AM, Chan YM, Tien M, Millist L, Clough M, Mack H, et al. Behavioral measures of cortical hyperexcitability assessed in people who experience visual snow. *Neurology*. (2017) 88:1243–9. doi: 10.1212/WNL.0000000000003784
59. Eren O, Eggert T, Ruscheweyh R, Straube A, Schankin C. Visual contrast threshold at 15 Hz is able to confirm visual snow syndrome in individual patients (S20.005). AAN Enterprises (2019).

60. Alissa R, Bi W, Bessero A, Plant G, Barbur J. Vision in subjects with hyperawareness of afterimages and “visual snow”. *Acta Ophthalmol.* (2012) 90:F066. doi: 10.1111/j.1755-3768.2012.F066.x
61. Eren O, Rauschel V, Ruscheweyh R, Straube A, Schankin CJ. Evidence of dysfunction in the visual association cortex in visual snow syndrome. *Ann Neurol.* (2018) 84:946–9. doi: 10.1002/ana.25372
62. Luna S, Lai D, Harris A. Antagonistic relationship between VEP potentiation and gamma power in visual snow syndrome. *Headache.* (2018) 58:138–44. doi: 10.1111/head.13231
63. Eren OE, Ruscheweyh R, Rauschel V, Eggert T, Schankin CJ, Straube A. Magnetic suppression of perceptual accuracy is not reduced in visual snow syndrome. *Front Neurol.* (2021) 12:498. doi: 10.3389/fneur.2021.658857
64. Grey V, Klobusiakova P, Minks E. Can repetitive transcranial magnetic stimulation of the visual cortex ameliorate the state of patients with visual snow? *Bratislavske Lekarske Listy.* (2020) 121:395–9. doi: 10.4149/BLL\_2020\_064
65. Schankin CJ, Maniyar FH, Chou DE, Eller M, Sprenger T, Goadsby PJ. Structural and functional footprint of visual snow syndrome. *Brain.* (2020) 143:1106–13. doi: 10.1093/brain/awaa053
66. Puledda F, Bruchhage M, O’Daly O, Ffytche D, Williams SC, Goadsby PJ. Occipital cortex and cerebellum gray matter changes in visual snow syndrome. *Neurology.* (2020) 95:e1792–9. doi: 10.1212/WNL.00000000000010530
67. Puledda F, Ffytche D, Lythgoe DJ, O’Daly O, Schankin C, Williams SC, et al. Insular and occipital changes in visual snow syndrome: a BOLD fMRI and MRS study. *Ann Clin Transl Neurol.* (2020) 7:296–306. doi: 10.1002/acn3.50986
68. Puledda F, O’Daly O, Schankin C, Ffytche D, Williams SC, Goadsby PJ. Disrupted connectivity within visual, attentional and salience networks in the visual snow syndrome. *Hum Brain Mapp.* (2021) 42:2032–44. doi: 10.1002/hbm.25343
69. Aldusary N, Traber GL, Freund P, Fierz FC, Weber KP, Baeshen A, et al. Abnormal connectivity and brain structure in patients with visual snow. *Front Hum Neurosci.* (2020) 14:476. doi: 10.3389/fnhum.2020.582031
70. Kutch JJ, Ichesco E, Hampson JP, Labus JS, Farmer MA, Martucci KT, et al. Brain signature and functional impact of centralized pain: a multidisciplinary approach to the study of chronic pelvic pain (MAPP) network study. *Pain.* (2017) 158:1979–91. doi: 10.1097/j.pain.0000000000001001
71. Puledda F, Lythgoe D, O’Daly O, Schankin C, Williams S, Goadsby P. Functional and metabolic changes in visual snow syndrome: a combined BOLD fMRI and MRSpectroscopy study. *Neurology.* (2020) 7(3):296–306.
72. Belvis R, Ramos R, Villa C, Segura C, Pagonabarraga J, Ormazabal I, et al. Brain apparent water diffusion coefficient magnetic resonance image during a prolonged visual aura. *Headache.* (2010) 50:1045–9. doi: 10.1111/j.1526-4610.2010.01672.x
73. Latini F, Fahlström M, Marklund N, Feresiadou A. White matter abnormalities in a patient with visual snow syndrome: New evidence from a diffusion tensor imaging study. *Eur J Neurol.* (2021) 28:2789–93. doi: 10.1111/ene.14903
74. Shibata M, Tsutsumi K, Iwabuchi Y, Kameyama M, Takizawa T, Nakahara T, et al. [123I]-IMP single-photon emission computed tomography imaging in visual snow syndrome: a case series. *Cephalalgia.* (2020) 40:1671–5. doi: 10.1177/0333102420950454
75. Denuelle M, Bouloche N, Payoux P, Fabre N, Trotter Y, Géraud G. A PET study of photophobia during spontaneous migraine attacks. *Neurology.* (2011) 76:213–8. doi: 10.1212/WNL.0b013e3182074a57
76. Gersztenkorn D, Lee AG. Palinopsia revamped: a systematic review of the literature. *Surv Ophthalmol.* (2015) 60:1–35. doi: 10.1016/j.survophthal.2014.06.003
77. Kato S, Kuramochi M, Kobayashi K, Fukabori R, Okada K, Uchigashima M, et al. Selective neural pathway targeting reveals key roles of thalamostriatal projection in the control of visual discrimination. *J Neurosci.* (2011) 31:17169–79. doi: 10.1523/JNEUROSCI.4005-11.2011
78. López-Bendito G. Development of the thalamocortical interactions: past, present and future. *Neuroscience.* (2018) 385:67–74. doi: 10.1016/j.neuroscience.2018.06.020
79. Chiong W, Wilson SM, D’Esposito M, Kayser AS, Grossman SN, Poorzand P, et al. The salience network causally influences default mode network activity during moral reasoning. *Brain.* (2013) 136:1929–41. doi: 10.1093/brain/awt066
80. Uddin LQ. Salience processing and insular cortical function and dysfunction. *Nat Rev Neurosci.* (2015) 16:55–61. doi: 10.1038/nrn3857
81. Peters SK, Dunlop K, Downar J. Cortico-striatal-thalamic loop circuits of the salience network: a central pathway in psychiatric disease and treatment. *Front Syst Neurosci.* (2016) 10:104. doi: 10.3389/fnsys.2016.00104
82. De Ridder D, Elgoyhen AB, Romo R, Langguth B. Phantom percepts: tinnitus and pain as persisting aversive memory networks. *Proc Natl Acad Sci USA.* (2011) 108:8075–80. doi: 10.1073/pnas.1018466108
83. Siracusa R, Paola RD, Cuzzocrea S, Impellizzeri D. Fibromyalgia: pathogenesis, mechanisms, diagnosis and treatment options update. *Int J Mol Sci.* (2021) 22:3891. doi: 10.3390/ijms22083891
84. Goadsby PJ, Holland PR, Martins-Oliveira M, Hoffmann J, Schankin C, Akerman S. Pathophysiology of migraine: a disorder of sensory processing. *Physiol Rev.* (2017) 97:553–622. doi: 10.1152/physrev.00034.2015
85. Peng K-P, May A. Migraine understood as a sensory threshold disease. *Pain.* (2019) 160:1494–501. doi: 10.1097/j.pain.0000000000001531

**Conflict of Interest:** CJS received scientific support, travel support and/or honoraria from Novartis, Eli Lilly, TEVA Pharmaceuticals, Lundbeck, Allergan, Almirall, Amgen, MindMed, Grünenthal. He received research grants from German Migraine and Headache Society, Eye on Vision Foundation, and Baasch Medicus Foundation. CJS is part-time employee at Zynnon.

The remaining author declares that the research was conducted in the absence of any commercial or financial relationships that could be construed as a potential conflict of interest.

**Publisher’s Note:** All claims expressed in this article are solely those of the authors and do not necessarily represent those of their affiliated organizations, or those of the publisher, the editors and the reviewers. Any product that may be evaluated in this article, or claim that may be made by its manufacturer, is not guaranteed or endorsed by the publisher.

Copyright © 2021 Klein and Schankin. This is an open-access article distributed under the terms of the Creative Commons Attribution License (CC BY). The use, distribution or reproduction in other forums is permitted, provided the original author(s) and the copyright owner(s) are credited and that the original publication in this journal is cited, in accordance with accepted academic practice. No use, distribution or reproduction is permitted which does not comply with these terms.



# Distinct Patterns of P1 and C2 VEP Potentiation and Attenuation in Visual Snow: A Case Report

Alison M. Harris\*

Department of Psychological Science, Claremont McKenna College, Claremont, CA, United States

Visual snow syndrome, characterized by persistent flickering dots throughout the visual field, has been hypothesized to arise from abnormal neuronal responsiveness in visual processing regions. Previous research has reported a lack of typical VEP habituation to repeated stimulus presentation in patients with visual snow. Yet these studies generally used pattern-reversal paradigms, which are suboptimal for measuring cortical responses to the onset of foveal stimulation. Instead, these responses are better indexed by the C2, a pattern-onset VEP peaking 100–120 ms after stimulus onset. In this case study, we analyzed the C2 and its adaptation profile in data previously collected from a single patient with visual snow using a “double-pulse” presentation paradigm. In controls, shorter intervals between stimulus pairs were associated with greater attenuation of the C2 VEP, with recovery from adaptation at longer stimulus onset asynchronies (SOAs). However, the visual snow patient showed the opposite pattern, with *reduced* C2 amplitude at longer SOAs despite distinct C2 peaks at the shortest SOAs. These results stand in contrast not only to the pattern of C2 VEP attenuation in controls, but also to a lack of adaptation previously reported for the pattern-onset P1 VEP in this patient. Exploratory source localization using equivalent current dipole fitting further suggested that P1 and C2 VEPs in the visual snow patient arose from distinct sources in extrastriate visual cortex. While preliminary, these results support differential patterns of VEP attenuation and potentiation within the same individual, potentially pointing toward multiple mechanisms of abnormal neuronal responsiveness in visual snow syndrome.

## OPEN ACCESS

### Edited by:

Christoph Schankin,  
Bern University Hospital, Switzerland

### Reviewed by:

Ozan Emre Eren,  
LMU Munich University  
Hospital, Germany  
Gianluca Coppola,  
Sapienza University of Rome, Italy

### \*Correspondence:

Alison M. Harris  
aharris@cmc.edu

### Specialty section:

This article was submitted to  
Neuro-Ophthalmology,  
a section of the journal  
Frontiers in Neurology

**Received:** 11 June 2021

**Accepted:** 25 October 2021

**Published:** 17 November 2021

### Citation:

Harris AM (2021) Distinct Patterns of P1 and C2 VEP Potentiation and Attenuation in Visual Snow: A Case Report. *Front. Neurol.* 12:723677. doi: 10.3389/fneur.2021.723677

**Keywords:** visual snow syndrome, visual evoked potentials, C2, habituation, double-pulse adaptation

## INTRODUCTION

Visual snow syndrome is a debilitating neurological condition characterized by the persistent and continuous experience of tiny flickering dots in the visual field (1). Similar to migraine aura (2), the visual disturbances in visual snow syndrome have been hypothesized to arise from changes in neuronal responsiveness to sensory stimulation (3). Habituation, the phenomenon of reduced responsiveness over repeated stimulus presentation, is commonly observed in measurements of visual evoked potentials (VEPs) for healthy individuals (4). In contrast, loss of VEP habituation has been reported both in migraine with aura (5) and visual snow syndrome (6, 7).

Yet prior measurements of VEP habituation in visual snow have largely utilized pattern-reversal paradigms, in which a patterned stimulus switches polarity repeatedly over time. While pattern-reversal stimulation produces a reliable and consistent VEP across participants, the

*pattern-reversal* P100<sup>1</sup>, this protocol is limited in terms of the cortical activity it represents. Specifically, the *pattern-reversal* P100 appears to largely reflect neural responses to the offset, rather than the onset, of the stimulus (8, 9), with contributions from both magnocellular and parvocellular pathways (10).

As a consequence, *pattern-reversal* paradigms may fail to capture cortical responses to the onset of foveal stimulation, information that is carried by parvocellular pathways of macular origin. Previous research suggests that these responses are indexed by the C2 (or CII) VEP elicited by *pattern onset* (11). Typically observed as a negative deflection peaking between 100 and 130 ms after stimulus onset (11–13), the C2 shows maximal amplitude for foveal stimuli with energy at high spatial frequencies (10). Source localization analyses suggest that this VEP arises adjacent to striate cortex (12), near the juncture of V1 and V2 (13).

Because the C2 is not visible in the *pattern-reversal* VEP (8), the effects of visual snow syndrome on this response have received little attention. However, in a recent study we recorded *pattern-onset* VEPs from a patient with visual snow (14). Our paradigm involved the central presentation of complex patterned stimuli with energy at high spatial frequencies, eliciting a strong C2 response. Additionally, we could measure the effect of repeated stimulus presentation through our use of a “double-pulse” presentation paradigm, in which two stimuli (S1 and S2) are presented with a varying stimulus onset asynchrony (SOA).

Double-pulse presentation has previously been linked to attenuation of *pattern-onset* VEPs (15–18), reflecting increased gamma oscillations in local inhibitory networks (19). This reduction is not explained by mere adaptation to low-level physical stimulus properties (18, 20), and is maximal at shorter SOAs (16, 17) when gamma power is highest (19). These properties distinguish double-pulse adaptation from *pattern-reversal* VEP habituation, which varies with stimulation parameters (e.g., reversal rate, check size, contrast) and is often strongest after successive blocks of stimulation (5, 21).

In our previous analysis, we replicated double-pulse adaptation of the *pattern-onset* P1 in normal individuals (14). In contrast, the patient with visual snow displayed a consistent pattern of P1 VEP potentiation, or enhancement, associated with decreased gamma-band inhibition, suggesting a physiological basis for VEP potentiation in visual snow (14). Although the neural mechanisms of *pattern-onset* P1 enhancement in this paradigm potentially differ from those underlying reduced VEP habituation in visual snow (6, 7), our data are nonetheless broadly consistent with increased excitability of visual cortex in this condition.

Here we performed a novel analysis quantifying the C2 response and its double-pulse adaptation profile in data previously collected from a patient with visual snow syndrome (14). Based on other research on attenuation of the C2 response,

we predicted that in normal individuals there would be C2 adaptation to the S2 stimulus at SOAs <80 ms, with recovery from adaptation for SOAs of 100 ms and above (16). We could then test whether the patient with visual snow showed a similar pattern of attenuation to controls. Finally, due to our use of a high-density EEG array, we were able to separate signals corresponding to the C2 from the previously-reported P1 response. This enabled us to directly compare the *pattern-onset* C2 and P1 components, providing further insight into how the cortical responses indexed by these two VEPs may vary.

## METHOD

### Participants

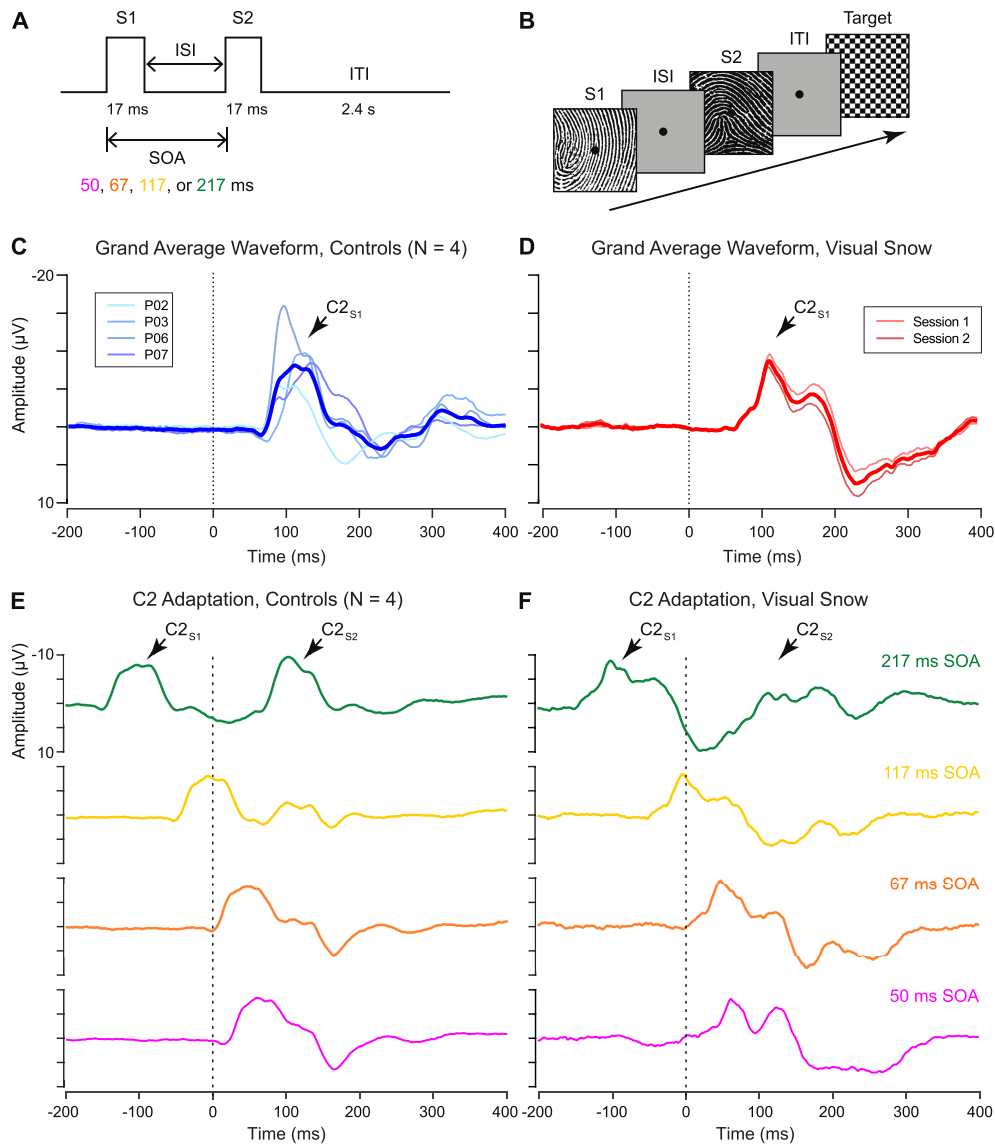
Because this is a re-analysis of an existing dataset, participants and methods are the same as previously described in the 2018 study by Luna, Lai, and Harris (14). At the time of testing, the patient was a right-handed male (age 22 years) with a 2-year history of visual snow syndrome. In line with diagnostic criteria for visual snow (1), he reported experiencing constantly flickering fine dots throughout his visual field which persisted across light conditions without remission, along with palinopsia, nyctalopia, photopsia, phosphenes, the blue field entopic phenomenon, and tinnitus. The patient had a family history of migraine with aura on the maternal side, and reported one previous episode of migrainous phenotype with symptoms of migraine aura 6 years prior to the time of testing. However, no other migraine attacks were reported, discounting episodic migraine as a factor in the patient's symptoms. Measurements of visual acuity and eye structure were normal, and neurological and neuroimaging examinations found no abnormalities.

Seven control participants with normal or corrected vision were recruited from the college community. Controls were matched to the patient on gender and age (ages 20–24, mean age = 21.1), but reported no personal or family history of migraine. Three of these participants were excluded due to problems with EEG recording ( $n = 2$ ) and failure to identify sensors displaying a C2 response within the predefined time window of interest ( $n = 1$ ). Thus, 4 control participants were included in the final analysis, a sample size in line with prior studies of the C2 component (11). Informed consent was obtained from all participants, and the study was approved by the Claremont McKenna College Institutional Review Board.

### Materials and Methods

**Figure 1A** shows the double-pulse stimulus presentation paradigm from the 2018 study by Luna, Lai, and Harris (14). On each trial, two stimuli were presented in brief succession with a variable intertrial interval ranging from 33 to 200 ms. Each stimulus was displayed for 17 ms, resulting in a stimulus onset asynchrony (SOA) of 50, 67, 117, or 217 ms. Stimuli consisted of 50 high-contrast black-and-white line (fingerprint) patterns ( $4.6^\circ \times 4.6^\circ$  of visual angle) displayed on a gray background with a central fixation point (**Figure 1B**). Each pattern served as the S2 stimulus twice per condition (100 trials per condition), with a non-identical image randomly selected on each trial to serve as S1. Participants were instructed to respond by

<sup>1</sup>Although the terms “P100” and “P1” have both been applied to positive deflections 100 ms after stimulus onset in *pattern-reversal* and *pattern-onset* stimulation, here we refer to the former as the *pattern-reversal* P100 and the latter as the *pattern-onset* P1 so our findings can be more easily related to the existing literature.



**FIGURE 1 | (A)** Schematic of “double-pulse” presentation paradigm. Two stimuli (S1 and S2) are presented with a variable interstimulus interval (ISI), resulting in a stimulus onset asynchrony (SOA) of 50, 67, 117, or 217 ms. After the S2 stimulus, an intertrial interval (ITI) of 2.4 s was selected to minimize persistent afterimages in the visual snow patient. **(B)** Sample trial structure. On each trial, a high-contrast stimulus was selected to serve as S2, paired with a randomly selected non-identical image as S1. Participants monitored for the appearance of an infrequent target (checkerboard pattern), which occurred on 10% of trials. **(C,D)** Grand average waveform for C2 response in **(C)** controls and **(D)** visual snow patient, as identified from the unadapted S1 condition. **(E,F)** Adaptation of the C2 response in **(E)** controls and **(F)** visual snow patient for each tested SOA (green: 217 ms, gold: 117 ms, orange: 67 ms, fuschia: 50 ms). Grand average waveforms are time-locked to the onset of the S2 stimulus (dotted line, 0 ms), with the C2 response visible ~100 ms after stimulus onset. Grand averages in **(F)** reflect the average of two separate sessions in the visual snow patient.

keypress to the appearance of an infrequent target stimulus, a checkerboard pattern, which occurred in 10% of the total trials. Target trials were randomly intermixed with experimental double-pulse trials, and all double-pulse presentation conditions were randomly interleaved within participants. The experiment was programmed and displayed in Matlab (Mathworks, Natick, MA) using PsychToolbox (22) stimulus presentation software.

Control participants each completed a single session of testing with all four SOA conditions, for a total of 400 trials

per participant. To verify that the VEP response observed in the patient reflected a consistent pattern, he participated in two separate recording sessions ~1 month apart. All statistical analyses were performed for data averaged across both sessions.

### EEG Data Acquisition and Preprocessing

Continuous EEG data were collected using a 128-channel BioSemi ActiveTwo system (Biosemi B.V., Amsterdam, Netherlands). Data were digitized at 512 Hz with bilateral

mastoid references. Offline data processing was performed in the EEGLAB toolbox (23). Data preprocessing steps included resampling to 500 Hz, re-referencing to an average reference, linear detrending, high-pass filtering at 1 Hz, notch filtering at 60 Hz, extraction of epochs time-locked to S1 (−500 to 800 ms), and removal of artifactual noise via independent components analysis (24) using second-order blind identification (25, 26). Finally, 600-ms epochs time-locked to the S2 stimulus (−200 ms to 400 ms) were extracted for analysis.

## VEP Data Analysis

VEP waveforms were extracted from the EEG recording by averaging time-locked signals across trials in each condition. The C2 component of the VEP was defined as a negative deflection occurring ~100–120 ms after stimulus onset at posterior sensors (Figures 1C,D). Sensors of interest (SOIs) were defined individually for each participant 100–120 ms post-stimulus onset at posterior sensors based on the amplitude of VEPs to the S1 stimulus, using a threshold of z-scored amplitude  $\leq -1.5$ . Local peak amplitude and latency for the S2 response were then determined for each participant and condition using a 10-point (20-ms) window in the ERPLAB (27) toolbox for Matlab. Amplitude of the C2 response to the S2 stimulus was normalized by the amplitude of the preceding S1 response ( $C2_{S2}/C2_{S1}$ ) to quantify attenuation and/or potentiation of the second C2 response. To examine the trial-by-trial variability in the C2 VEP, we identified the independent component (IC) associated with the negative C2 deflection at midline occipital sensors from one session in the visual snow patient and a representative control participant.

In order to verify that the pattern of double-pulse adaptation for the C2 VEP was distinct from that for the previously-described P1 component, it was necessary to directly compare the current results to normalized amplitude values derived from our prior study (14). Here we focused only on the two extreme conditions (50 vs. 217 ms SOA), further identifying a separate IC that showed a scalp topography and average waveform consistent with the pattern-onset P1 component. Although by necessity these results build on data previously reported in a separate publication (14), these secondary analyses are largely based on a different analytical approach, with the goal of providing complementary information to our original analysis.

Finally, to shed light on the neural sources of the C2 response, dipole fitting was applied using the DIPFIT plugin in EEGLAB. Equivalent current dipoles were fit to ICs associated with the pattern-onset C2 and P1 scalp VEPs from one session in the visual snow patient. A template boundary element model (BEM) based on the MNI brain was used for the head model, with manual co-registration of the EEG electrode locations to the head model. The appropriate ICs for dipole fitting were identified based on scalp topography and average waveform responses, and then fit via a two-step iterative process in EEGLAB, consisting of an initial coarse grid search followed by a fine-grain fitting via a non-linear optimization algorithm. The number of dipoles and symmetry constraint for each IC were determined based on minimizing residual variance (RV), while the dipole moment

ratio (DMR) was checked to ensure that both dipoles contributed to fitted models with two dipoles (28).

## RESULTS

Although the polarity of the C2 varies depending on which hemifield is visually stimulated, it has typically been reported as a negative deflection emerging from 100 to 130 ms after stimulus onset (11), perhaps due to superposition with the N1 component in the same time window (13). Examining the response to the S1 stimulus, we successfully identified a VEP matching these parameters in 4 control participants (Figure 1C), as well as in the patient with visual snow (Figure 1D). As shown by the individual waveforms plotted in Figure 1C, the C2 component recorded at the scalp showed substantial individual variation in terms of its amplitude and latency. Nonetheless, no differences in amplitude were observed between the  $C2_{S1}$  component in controls and the visual snow patient (Table 1), as evidenced by a one-sample *t*-test [ $t_{(3)} = -0.54$ ,  $p = 0.63$ ]. Likewise, latency of the  $C2_{S1}$  response was similar across controls and the visual snow patient (Table 1), and not significantly different between the groups [ $t_{(3)} = -0.31$ ,  $p = 0.78$ ].

Next, we quantified the C2 response to double-pulse stimulus presentation across varying SOAs in controls (Figure 1E). In line with previous findings, the controls showed a pattern of decreasing adaptation at longer SOAs (16), with the  $C2_{S2}$  responses at shorter SOAs of 50 and 67 ms appearing partially integrated with the initial  $C2_{S1}$  response. At the shortest SOA, positive average  $C2_{S2}$  amplitude ( $5.99 \pm 4.31 \mu\text{V}$ ) reflected a 160.5% decrease relative to  $C2_{S1}$ . However, at a SOA of 117 ms, average  $C2_{S2}$  amplitude was still attenuated ( $-3.02 \pm 4.61 \mu\text{V}$ , 69.5% decrease), in contrast to our earlier findings for the  $P1_{S2}$  response (14). Recovery was only complete by the longest SOA ( $-10.9 \pm 4.69 \mu\text{V}$ ). Therefore, even within the neurotypical brain, the pattern-onset P1 and C2 components may be distinguished not only by their retinotopic organization (13), but also by their double-pulse adaptation profiles.

A very different pattern was observed for the patient with visual snow (Figure 1F). At the shortest SOAs, associated with complete or partial integration of the  $C2_{S2}$  response in controls, the patient showed a clear double peak, suggesting a relative lack of attenuation (50 ms SOA: mean =  $-6.4 \pm 1.58 \mu\text{V}$ , 26.4% decrease). Conversely, for the longest SOA of 217 ms—associated with complete recovery in controls—the patient's  $C2_{S2}$  peak was dramatically reduced (mean =  $-2.93 \pm 0.97 \mu\text{V}$ , 66.3% decrease). Thus, longer intervals between stimulus presentations produce abnormal adaptation of the C2 response in this patient. One clue to the origin of this effect comes from the strong positive deflection following the patient's C2 component 200–300 ms post-stimulus onset (Figure 1D). Strikingly, this peak for the *unadapted*  $C2_{S1}$  response in the patient parallels the pattern of attenuation at short SOAs in controls (Figure 1E), who show a positive deflection 150–200 ms post-stimulus onset in lieu of the negative  $C2_{S2}$  response.

However, one potential confound arises from the fact that the scalp VEP may reflect the superposition of multiple cortical

**TABLE 1** | C2 component in controls vs. visual snow.

	Controls (N = 4)	Visual snow (n = 2)	P-value
Average amplitude ( $\mu\text{V}$ ) $\pm$ SD	$-9.89 \pm 4.44$	$-8.7 \pm 1.2$	0.63
Amplitude range ( $\mu\text{V}$ )	$-5.43$ to $-16.0$	$-7.85$ to $-9.55$	
Average peak latency (ms) $\pm$ SD	$109.7 \pm 21.6$	$113 \pm 1.41$	0.78
Latency peak range (ms)	88–132.3	112–114	

Average amplitude and latency of the C2 component in 4 controls compared to the visual snow patient (2 sessions). Although data from both sessions in the visual snow patient were averaged for statistical analysis, the standard deviation and range are presented here to demonstrate the high consistency of the C2 component in the patient across experimental sessions.

sources, particularly in the short time frame of early visual processing. To address this issue, previous research has used independent component analysis (ICA) to separate the C2 component from other early VEPs (13). For each participant, we identified an independent component (IC) corresponding to the C2 response, which was distributed over midline occipital electrodes (Figure 2A). In controls, the average waveform obtained from back-projecting these ICs showed a clear negative deflection  $\sim$ 100–120 ms after stimulus onset in the 217 ms SOA condition (Figure 2B, top), in line with the VEP observed at the sensor level (Figure 2B, bottom). Thus, the selected ICs appear to satisfactorily capture the C2 VEP measured at the scalp. Trial-by-trial data from a single representative participant indicate that the average waveforms reflect highly consistent peaks in the data which are reliably time-locked to the stimulus (Figure 2D), including the positive deflection associated with rapid double-pulse presentation in the 50 ms SOA condition (Figure 2F).

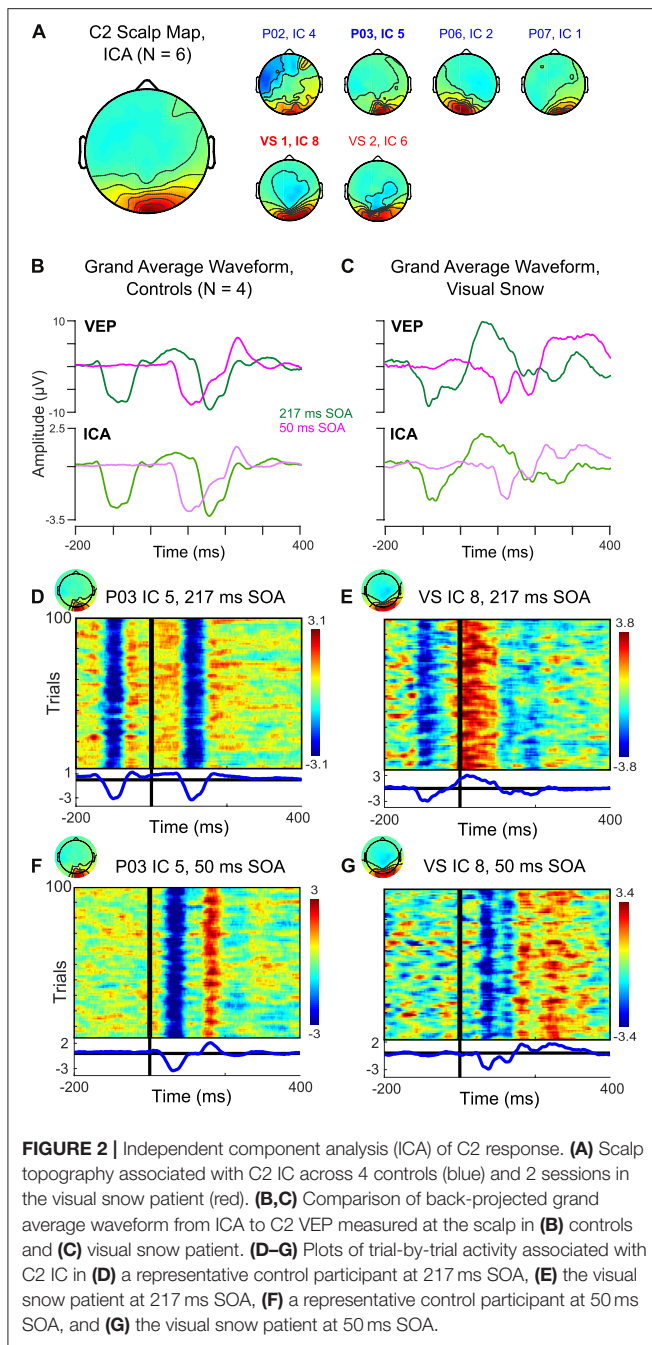
Figure 2C compares the IC back-projected average and scalp VEP for our single patient with visual snow. Notably, the IC data preserves the pattern of a large positive deflection following the S1 stimulus in the 217 ms SOA condition. Likewise, the double peak in the 50 ms SOA condition is present, albeit somewhat reduced. These results further support the idea that differences in the C2 response observed in this particular visual snow patient arise from changes in the response properties of this VEP's neural generators, rather than from a superposition of multiple sources in the visual association cortex. Visualization of the trial-by-trial IC data for the 217 ms (Figure 2E) and 50 ms SOA conditions (Figure 2G) in one session underscores that these waveforms are highly consistent from trial to trial, making it unlikely that the distinctive characteristics of the C2 in this individual reflect a small number of outlying trials.

These data provide preliminary evidence for distinct patterns of attenuation for the C2 VEP in normal controls compared to a patient with visual snow syndrome. The pattern of C2 VEP adaptation in this patient with visual snow also appears to differ dramatically from the potentiation observed across SOAs for the pattern-onset P1 response in a previous analysis (14). Whereas the visual snow patient showed sustained potentiation of the P1 VEP across the shortest and longest SOAs, the same individual evinced a reduction of C2 amplitude at the longer SOA (Figures 3A,B, red squares). In contrast, controls consistently showed increases in amplitude with increasing SOAs

(Figures 3A,B, blue circles), in line with previous reports (15, 16). To quantify these effects, we computed the difference in amplitude of the P1 and C2 components at 217 vs. 50 ms SOAs, then calculated the difference of differences to determine how the two components varied from each other  $[(P1_{\text{Long}} - P1_{\text{Short}}) - (C2_{\text{Long}} - C2_{\text{Short}})]$ . Comparing the values of the control group to the visual snow patient using a one-sample *t*-test revealed a significant effect [ $t_{(3)} = -4.59, p = 0.019$ ], reflecting a disparity between controls (mean P1-C2 difference score =  $-0.98 \pm 0.67$ ) and the visual snow patient (P1-C2 difference score = 0.57), largely driven by the patient's reduced C2 attenuation at short SOAs. Thus, the adaptation profiles for the pattern-onset P1 and C2 VEPs observed at the sensor level appear to be distinct within a single patient with visual snow syndrome.

Finally, previous research suggests that the C2 may be part of a VEP complex distinct from the pattern-onset P1 response, both in terms of retinotopic organization and putative neural sources (13). To test this idea in our data, we identified ICs associated with the pattern-onset P1 (IC 5, Figure 3C) vs. C2 (IC 8, Figure 3D) VEPs. As in the IC-level analysis above, the differential pattern of habituation between these two responses remained visible in VEPs back-projected from the selected ICs, suggesting that these results do not merely reflect superposition of multiple sources. An exploratory equivalent current dipole fitting analysis for both ICs (Figures 3E,F) found that two-dipole solutions produced the lowest residual variance (IC 5: 1.45%, IC 8: 2.45%). Dipole moment ratios near 1 (IC 5: DMR = 1.4, IC 8: DMR = 1.0) indicated that the decreased residual variance for each of these fits reflected meaningful contributions from both dipoles rather than overfitting of model noise. Critically, the dipole solutions for the two ICs indicated different neural sources. Whereas the IC associated with the P1 was localized to sources in the right ventral extrastriate cortex (MNI coordinates: 14,  $-75, -12$ ) and left cerebellum ( $-5, -55, -2$ ), the IC associated with the C2 VEP was best fit by symmetric dipoles originating from dorsal extrastriate cortex ( $0, -90, 19$ ) oriented in opposite directions. Although these results should be interpreted with caution given the low spatial resolution of EEG, they provide preliminary support for the idea that C2 attenuation may reflect distinct neural mechanisms from the previously observed potentiation of the P1 VEP in this individual with visual snow.





## DISCUSSION

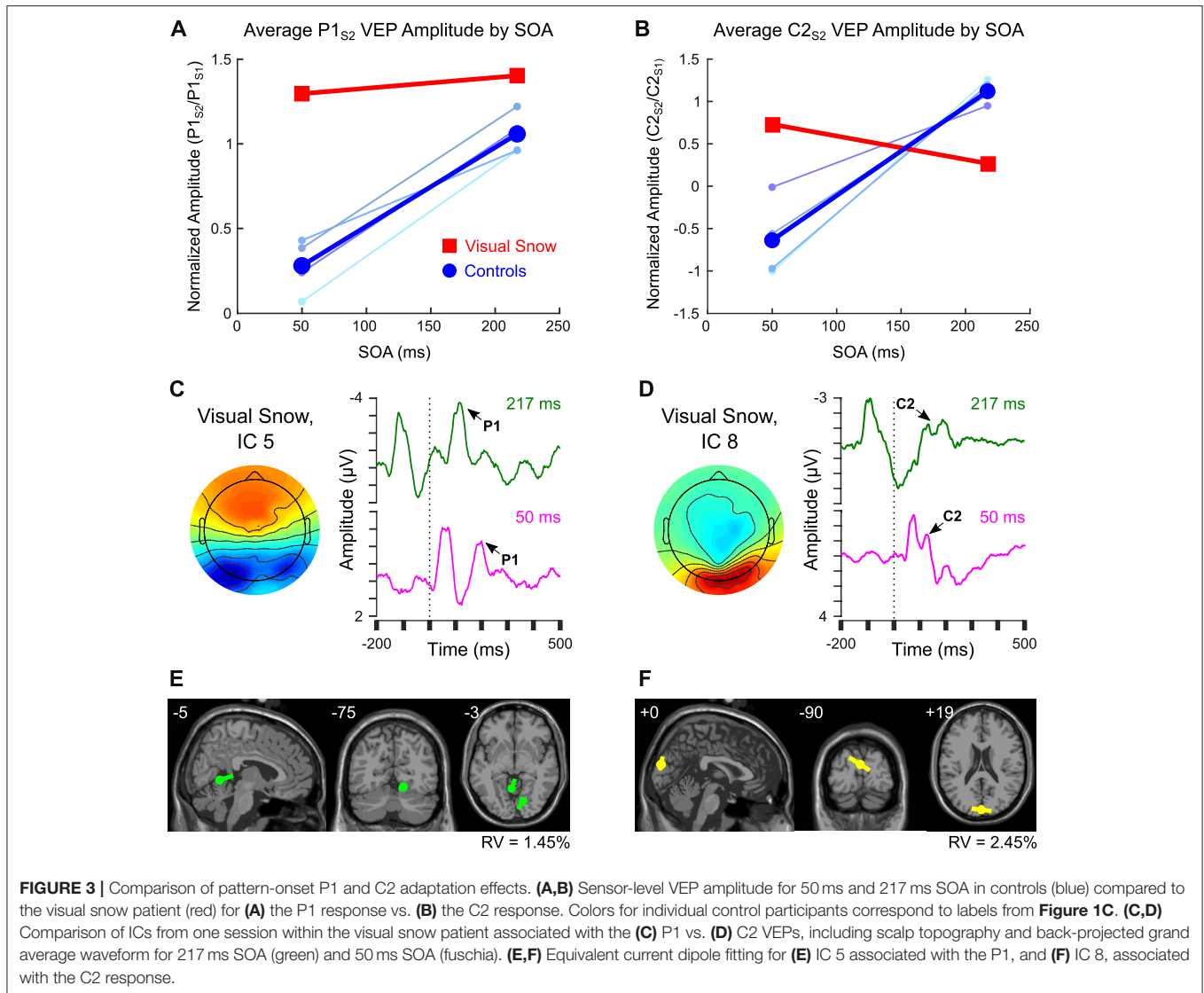
Lack of VEP habituation in visual snow syndrome has been cited as evidence for the idea that this condition reflects altered neuronal responsiveness to sensory stimulation (6, 7). Yet the majority of these studies have relied on pattern-reversal presentation paradigms, which elicit strong pattern-offset VEPs thought to be driven by both magnocellular and parvocellular systems (8–10). Therefore, the role of cortical responses to foveal stimulus onset, as indexed by the C2 component (8, 10, 11),

has been relatively unexplored in visual snow. In this study, we reanalyzed existing data using a double-pulse adaptation paradigm in order to quantify adaptation of the C2 response in neurotypical controls in comparison to a patient with visual snow syndrome.

The C2 was visible both in control participants and in the visual snow patient as a negative-going deflection  $\sim 100$ – $120$  ms after stimulus onset at midline occipital electrodes. As far as we know, this is the first reported characterization of this component in a patient with visual snow, suggesting that early pattern-onset VEPs can be identified in this neurological condition. However, the response properties of the C2 component differed dramatically between controls and the visual snow patient. Whereas controls showed increasing attenuation at shorter SOAs, in line with previous data (16), the visual snow patient displayed the opposite pattern, with a clear double peak at the shortest SOA but reduced amplitude at the longest SOA. This differential response was associated with an enhanced positive deflection following the C2<sub>S1</sub> response, which was strongest at the 50 ms SOA in controls but most visible for the 217 ms SOA in the visual snow patient. Although the generalizability of results from a single patient is extremely limited, these results nevertheless provide a provisional first description of abnormal VEP responsiveness of the C2 component in association with visual snow symptoms. Given the putative role of parvocellular input in the C2 response (10), these results complement colorimetry findings attributed to imbalances in the koniocellular and/or magnocellular pathways in visual snow (3), possibly suggesting more general abnormalities across systems receiving input from the different visual pathways.

The adaptation profile of the C2 response in the visual snow patient clearly contrasted with the potentiation of his pattern-onset P1 response, described in a previous study (14). Exploratory dipole fitting in data from one recording session in the patient further suggested that the pattern-onset P1 and C2 VEPs in this individual may be localized to separate sources in extrastriate cortex. Specifically, the P1 response was associated with asymmetric dipoles in regions of the right ventral extrastriate cortex and left cerebellum. Interestingly, these coordinates were similar to those reported previously in a neuroimaging study of hypermetabolism in visual snow (29), though caution in comparing these methodologies is warranted given the poor spatial resolution of EEG. In contrast, the IC associated with the C2 VEP in this patient was best fit by symmetric dipoles originating from dorsal extrastriate cortex. Although equivalent current dipole fits rely on numerous assumptions, and should thus be interpreted with care, these results nonetheless join other studies supporting the idea that the C2 and P1 VEPs recorded at the scalp originate from distinct cortical sources (13).

Together, these results corroborate the idea that VEPs measured at the scalp may reflect heterogeneous sources in the early visual processing stream (13), leading to the striking observation of differential attenuation or potentiation of the VEP response *within a single individual* with visual snow. Previous work suggests that the scalp VEP captures cortical responses both to increases and decreases in contrast, with



positive “contrast decrease” signals at pattern offset contributing particularly to the pattern-reversal VEP (8). This “contrast decrease” response may be anomalous in patients with visual snow, contributing to previously-reported differences in pattern-reversal P100 amplitude (30) or habituation (6, 7) which may occur as part of, or in addition to, decreases in cortical inhibition following visual stimulation (14). At the same time, through its interaction with foveal “contrast increase” signals, this atypical “contrast decrease” component could explain the C2 attenuation observed here for a single visual snow patient. As the interval between stimuli decreases, the pattern-offset signal may be attenuated, resulting in the recovery of the C2 component at short SOAs. Further experiments directly comparing VEP components to pattern onset, offset, and reversal within patients with visual snow will be necessary to test this hypothesis.

One major caveat of the present study is that these data come from a single patient, limiting the generalizability of these

results. Therefore, it is essential that these findings be replicated with a larger sample of patients, as well as including greater heterogeneity in terms of gender, age, and co-morbid factors such as migraine with aura. However, despite the exploratory nature of these results, they support using diverse experimental paradigms and stimulation protocols to assess cortical visual function in visual snow. While pattern-reversal VEP habituation is valuable given its extensive characterization at the clinical level, it depends on stimulation parameters (5), may be conflated with changes in attention and arousal (21), and shows high intra-individual variability (31). These factors may contribute to failures to replicate decreased habituation in migraine and visual snow [e.g., (21, 30, 32)]. Our data join other recent results (13) suggesting that VEPs may emerge from multiple cortical sources and reflect differential neural responses to pattern onset and offset. A more refined understanding of how these signals are perturbed in visual snow syndrome could help to shed light on how neuronal

responsiveness of the visual processing stream is affected by this debilitating condition.

## DATA AVAILABILITY STATEMENT

The raw data supporting the conclusions of this article will be made available by the authors, without undue reservation. Requests to access these datasets should be directed to Alison Harris, aharris@cmc.edu.

## REFERENCES

- Schankin CJ, Maniyar FH, Digre KB, Goadsby PJ. 'Visual snow' - a disorder distinct from persistent migraine aura. *Brain*. (2014) 137:1419–28. doi: 10.1093/brain/awu050
- Lauritzen M. Pathophysiology of the migraine aura: the spreading depression theory. *Brain*. (1994) 117:199–210. doi: 10.1093/brain/117.1.199
- Lauschke JL, Plant GT, Fraser CL. Visual snow: a thalamocortical dysrhythmia of the visual pathway? *J Clin Neurosci*. (2016) 28:123–7. doi: 10.1016/j.jocn.2015.12.001
- Megela AL, Teyler TJ. Habituation and the human evoked potential. *J Comparat Physiol Psychol*. (1979) 93:1154. doi: 10.1037/h0077630
- Coppola G, Pierelli F, Schoenen J. Habituation and migraine. *Neurobiol Learn Memory*. (2009) 92:249–59. doi: 10.1016/j.nlm.2008.07.006
- Unal-Cevik I, Yildiz FG. Visual snow in migraine with aura: further characterization by brain imaging, electrophysiology, and treatment—case report. *Headache*. (2015) 55:1436–41. doi: 10.1111/head.12628
- Yildiz FG, Turkyilmaz U, Unal-Cevik I. The clinical characteristics and neurophysiological assessments of the occipital cortex in visual snow syndrome with or without migraine. *Headache*. (2019) 59:484–94. doi: 10.1111/head.13494
- Estevez O, Spekrijse H. Relationship between pattern appearance-disappearance and pattern reversal responses. *Exp Brain Res*. (1974) 19:233–8. doi: 10.1007/BF0023231
- Shawkat FS, Kriss A. A study of the effects of contrast change on pattern VEPs, and the transition between onset, reversal and offset modes of stimulation. *Doc Ophthalmol*. (2000) 101:73–89. doi: 10.1023/A:1002750719094
- Shawkat FS, Kriss A. Sequential pattern-onset, -reversal and -offset VEPs: comparison of effects of checksize. *Ophthalmic Physiol Opt*. (1998) 18:495–503. doi: 10.1046/j.1475-1313.1998.00393.x
- Jeffreys DA, Axford JG. Source locations of pattern-specific components of human visual evoked potentials. I. Component of striate cortical origin. *Exp Brain Res*. (1972) 16:1–21. doi: 10.1007/BF00233371
- Di Russo F, Pitzalis S, Spitoni G, Aprile T, Patria F, Spinelli D, et al. Identification of the neural sources of the pattern-reversal VEP. *NeuroImage*. (2005) 24:874–86. doi: 10.1016/j.neuroimage.2004.09.029
- Capilla A, Melcon M, Kessel D, Calderon R, Pazo-Alvarez P, Carretie L. Retinotopic mapping of visual event-related potentials. *Biol Psychol*. (2016) 118:114–25. doi: 10.1016/j.biopsycho.2016.05.009
- Luna S, Lai D, Harris A. Antagonistic relationship between VEP potentiation and gamma power in visual snow syndrome. *Headache*. (2018) 58:138–44. doi: 10.1111/head.13231
- Musselwhite M, Jeffreys D. Visual evoked potentials to double-pulse pattern presentation. *Vis Res*. (1983) 23:135–43. doi: 10.1016/0042-6989(83)90136-0
- Hoffken O, Grehl T, Dinse HR, Tegenthoff M, Bach M. Paired-pulse behavior of visually evoked potentials recorded in human visual cortex

## ETHICS STATEMENT

The studies involving human participants were reviewed and approved by Claremont McKenna College Institutional Review Board. The patients/participants provided their written informed consent to participate in this study.

## AUTHOR CONTRIBUTIONS

AH was responsible for conceiving of the analyses, analyzing and interpreting the data, and writing the manuscript.

- using patterned paired-pulse stimulation. *Exp Brain Res*. (2008) 188:427–35. doi: 10.1007/s00221-008-1374-0
- Jeffreys DA. Evoked potential studies of face and object processing. *Vis Cogn*. (1996) 3:1–38. doi: 10.1080/713756729
- Harris A, Nakayama K. Rapid face-selective adaptation of an early extrastriate component in MEG. *Cereb Cortex*. (2007) 17:63–70. doi: 10.1093/cercor/bh124
- Privman E, Fisch L, Neufeld MY, Kramer U, Kipervasser S, Andelman E, et al. Antagonistic relationship between gamma power and visual evoked potentials revealed in human visual cortex. *Cereb Cortex*. (2011) 21:616–24. doi: 10.1093/cercor/bhq128
- Harris A, Nakayama K. Rapid adaptation of the M170 response: importance of face parts. *Cereb Cortex*. (2008) 18:467–76. doi: 10.1093/cercor/bhm078
- Sand T, Vingen JV. Visual, long-latency auditory and brainstem auditory evoked potentials in migraine: relation to pattern size, stimulus intensity, sound and light discomfort thresholds and pre-attack state. *Cephalalgia*. (2000) 20:804–20. doi: 10.1046/j.1468-2982.2000.00098.x
- Brainard DH. The psychophysics toolbox. *Spat Vis*. (1997) 10:433–6. doi: 10.1163/156856897X00357
- Delorme A, Makeig S. EEGLAB: an open source toolbox for analysis of single-trial EEG dynamics including independent component analysis. *J Neurosci Meth*. (2004) 134:9–21. doi: 10.1016/j.jneumeth.2003.10.009
- Jung TP, Makeig S, Humphries C, Lee TW, McKeown MJ, Iragui V, et al. Removing electroencephalographic artifacts by blind source separation. *Psychophysiology*. (2000) 37:163–78. doi: 10.1111/1469-8986.3720163
- Belouchrani A, Abed-Meraim K, Cardoso J-F, Moulines E. A blind source separation technique using second-order statistics. *IEEE Trans Signal Proc*. (1997) 45:434–44. doi: 10.1109/78.554307
- Tang AC, Sutherland MT, McKinney CJ. Validation of SOBI components from high-density EEG. *NeuroImage*. (2005) 25:539–53. doi: 10.1016/j.neuroimage.2004.11.027
- Lopez-Calderon J, Luck SJ. ERPLAB: an open-source toolbox for the analysis of event-related potentials. *Front Hum Neurosci*. (2014) 8:213. doi: 10.3389/fnhum.2014.00213
- Pion-Tonachini L, Kreutz-Delgado K, Makeig S. The ICLLabel dataset of electroencephalographic (EEG) independent component (IC) features. *Data Brief*. (2019) 25:104101. doi: 10.1016/j.dib.2019.104101
- Schankin CJ, Maniyar FH, Sprenger T, Chou DE, Eller M, Goadsby PJ. The relation between migraine, typical migraine aura and "visual snow". *Headache*. (2014) 54:957–66. doi: 10.1111/head.12378
- Eren O, Rauschel V, Ruscheweyh R, Straube A, Schankin CJ. Evidence of dysfunction in the visual association cortex in visual snow syndrome. *Ann Neurol*. (2018) 84:946–9. doi: 10.1002/ana.25372
- Rauschel V, Ruscheweyh R, Krafczyk S, Straube A. Test-retest reliability of visual-evoked potential habituation. *Cephalalgia*. (2016) 36:831–9. doi: 10.1177/0333102415613613

32. Omland PM, Uglem M, Hagen K, Linde M, Tronvik E, Sand T. Visual evoked potentials in migraine: Is the “neurophysiological hallmark” concept still valid? *Clin Neurophysiol.* (2016) 127:810–6. doi: 10.1016/j.clinph.2014.12.035

**Conflict of Interest:** The author declares that the research was conducted in the absence of any commercial or financial relationships that could be construed as a potential conflict of interest.

**Publisher’s Note:** All claims expressed in this article are solely those of the authors and do not necessarily represent those of their affiliated organizations, or those of

the publisher, the editors and the reviewers. Any product that may be evaluated in this article, or claim that may be made by its manufacturer, is not guaranteed or endorsed by the publisher.

*Copyright © 2021 Harris. This is an open-access article distributed under the terms of the Creative Commons Attribution License (CC BY). The use, distribution or reproduction in other forums is permitted, provided the original author(s) and the copyright owner(s) are credited and that the original publication in this journal is cited, in accordance with accepted academic practice. No use, distribution or reproduction is permitted which does not comply with these terms.*



# Case Report: Transformation of Visual Snow Syndrome From Episodic to Chronic Associated With Acute Cerebellar Infarct

Francesca Puledda<sup>1\*</sup>, María Dolores Villar-Martínez<sup>1</sup> and Peter J. Goadsby<sup>1,2</sup>

<sup>1</sup> Headache Group, Wolfson Centre for Age-Related Diseases (CARD), SLaM Biomedical Research Centre, Institute of Psychiatry, Psychology and Neuroscience, King's College London, National Institute for Health Research (NIHR)-Wellcome Trust King's Clinical Research Facility, King's College Hospital, London, United Kingdom, <sup>2</sup> Department of Neurology, University of California, Los Angeles, Los Angeles, CA, United States

## OPEN ACCESS

### Edited by:

Owen B. White,  
Monash University, Australia

### Reviewed by:

Melissa Tien,  
National Healthcare Group Eye  
Institute, Singapore  
Helen Victoria Danesh-Meyer,  
University of Auckland, New Zealand  
Dan Milea,  
Singapore Eye Research Institute  
(SERI), Singapore

### \*Correspondence:

Francesca Puledda  
francesca.puledda@kcl.ac.uk

### Specialty section:

This article was submitted to  
Neuro-Ophthalmology,  
a section of the journal  
Frontiers in Neurology

**Received:** 08 November 2021

**Accepted:** 24 January 2022

**Published:** 15 February 2022

### Citation:

Puledda F, Villar-Martínez MD and  
Goadsby PJ (2022) Case Report:  
Transformation of Visual Snow  
Syndrome From Episodic to Chronic  
Associated With Acute Cerebellar  
Infarct. *Front. Neurol.* 13:811490.  
doi: 10.3389/fneur.2022.811490

Visual snow syndrome is a novel neurological condition characterized by a panfield visual disturbance associated with several additional symptoms. Although it is usually a continuous and primary disorder, cases of intermittent visual snow have been described in the literature, as well as rare secondary forms. This report is the first description of a case of intermittent visual snow syndrome, which transformed into a persistent form following a posterior circulation stroke due to vertebral artery dissection. At 1 and 2 years after experiencing the acute cerebellar infarct, the patient's only neurological sequelae was visual snow. This case provides a description of how visual snow syndrome may be caused by an underlying brain disorder, and highlights the importance of the cerebellum in the pathophysiology of this relatively unknown condition. It further shows evidence of how existing predispositions might be relevant to the development of visual snow, in certain subjects and following specific circumstances.

**Keywords:** visual snow, visual snow syndrome, acute stroke, cerebellum, infarct-vertebral artery dissection

## INTRODUCTION

Visual snow (VS) is a neurological disorder typically manifest as a panfield visual disturbance consisting of uncountable small dots that are continuously moving. Visual snow syndrome (VSS) manifests as that visual disturbance in association with other symptoms, such as palinopsia (1). VS is reported to occur in about 3.7% of the population (2). VSS is typically persistent after onset, either from as early as a patient can remember, or from a particular day, with only variation by degree over time (3). One case of occipital stroke precipitating a change from intermittent to persistent VS has been reported that had their visual symptoms resolve after 1 year (4). Here we present a case of intermittent VSS that became persistent after a posterior circulation stroke involving the cerebellum.

## CASE DESCRIPTION

A 44-year-old male came to our attention in the headache clinic at King's College Hospital, London in October 2020. One year prior, in October 2019, he had had a posterior circulation ischemic stroke, for which the history follows.

### Stroke

One afternoon, about 5–10 min after some physical exercise, he started noticing some gait imbalance, external vertigo and visual disturbance characterized by a right-sided hemianopia and possibly diplopia. These symptoms were self-limited and lasted in total around 10 min; they had not been preceded by any other unusual sensations. After going to bed that evening, he woke up in the middle of the night feeling extremely dizzy and nauseous. He was not able to sit or stand up on his own, and was immediately taken to A&E. He does not recall the ambulance ride, during which he had reduced consciousness and multiple episodes of vomiting.

In hospital he underwent an initial CT scan, which showed an infarct in the right superior cerebellar hemisphere. A further CT angiogram showed evidence of a right vertebral artery dissection. On the following day, an MRI head scan confirmed an acute infarct in the right superior cerebellar artery territory (**Figure 1**). A repeat CT angiogram 6 months after the acute episode showed that the right vertebral dissection had fully healed.

The patient was initially treated with aspirin followed by clopidogrel while in hospital. However, further screening showed evidence of an atrial arrhythmia in the form of atrial flutter and atrial fibrillation, following which he was started on apixaban. The atrial arrhythmia was considered coincidental. The remaining tests he underwent were unremarkable.

### Persistent Visual Symptoms

His present symptoms started perhaps a day after the onset of the stroke, although the patient cannot exclude it being present from the very onset, given his more serious symptoms and the lowered level of consciousness he was experiencing at the time, which might have masked the visual disturbance. In the beginning, and up to 4–5 months after the event, he remembers the visual symptoms being less intrusive and possibly not constant. They have however been quite clearly continuous and unvaried for the 6 months prior to review.

In the headache clinic he reported a continuous unremitting multi-colored and flashing TV-like static, present in the entire visual field. The static was more noticeable when looking at a darker area, and could disappear for a few seconds when he looked at a well-light bright area. In addition, he described prominent afterimages, without trailing, and blue field entoptic phenomenon, floaters, spontaneous photopsia, self-light of the eye, photophobia (particularly when tired) without photic allodynia, and some degree of nyctalopia. He had no tinnitus. He reported the

static to be the most bothersome symptom, being quite distracting and made working at a computer screen as part of his job very tiresome. Stress could worsen the static. Prescription sunglasses helped with photophobia but not with the static.

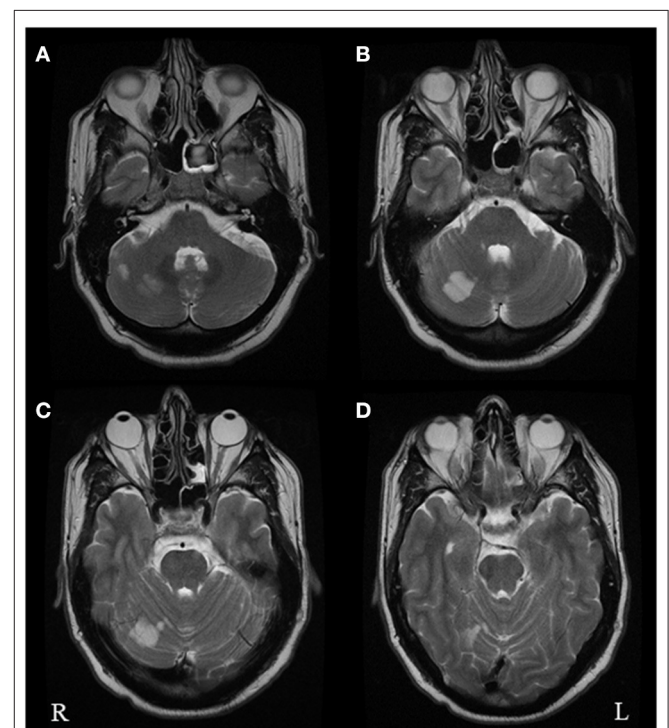
The patient was subsequently reviewed in October 2021, at 2 years from the acute vascular event, and his symptomatology remained completely unchanged.

### Intermittent, Pre-stroke, Visual Symptoms

Before October 2019, the patient reported having the same panfield multi-colored static and associated symptoms, with the only difference that they were not continuous. He remembered first noticing this disturbance in his teenage years, when he would get regular episodes of visual static perhaps once per month, lasting about 12 h and which would usually go away with sleep. He had no headache with these episodes, but he would get photophobia and feel quite tired. He had regular episodes throughout his twenties and thirties, up until October 2019.

### Other History

As general medical history, he had a diagnosis of hypercholesterolemia and gout and occasional migraine without aura, coming perhaps once per year. He would sometimes take



**FIGURE 1** | Axial T2 brain MRI images performed in October 2019 following the acute vascular event. The images show multiple foci of restricted diffusion in the right superior cerebellar hemisphere (**A–C**) within the territory of the right superior cerebellar artery, consistent with acute infarcts. There was no restricted diffusion within the left occipital lobe (**D**).

paracetamol for the migraine and had never needed a preventive in the past.

He was an ex-smoker up to 10 years prior, of <10 cigarettes a day. He reported drinking about 4–5 units of alcohol per week; he was a heavier drinker up to 4 years prior, with weekly binges. He reported no current use of recreational drugs, including cannabis; he had occasionally used ecstasy in his mid-twenties. Importantly, his episodic visual snow had started at least 10 years prior to any recreational drug use; however, he does recall some visual symptoms such as trailing following previous ecstasy intake. With regards to family history, his father had a previous stroke, while his sister, mother and maternal grandmother all reportedly had migraine.

His ongoing medication at the time he was reviewed in our clinic was apixaban 5 mg BD for atrial fibrillation/secondary stroke prevention, atorvastatin 40 mg OD, allopurinol 200 mg and colchicine 5 mg BD for gout. He had not taken any medication for his visual disturbance since the onset.

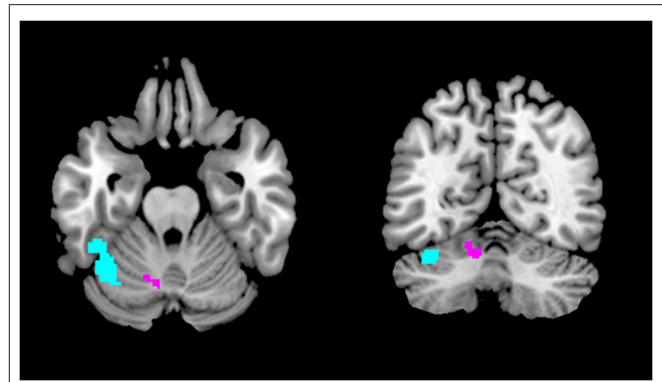## DISCUSSION

This clinical case is unique as it represents the only report in the literature of recurring episodic visual snow, then becoming chronic following a cerebellar stroke. It also offers some very important insight on VSS pathophysiology, particularly highlighting the role of the cerebellum.

Visual snow is a newly defined neurological entity consisting of an unremitting panfield visual disturbance described as numerous tiny flickering dots, or static (5). On the same clinical spectrum of visual snow is VSS (3), in which the static is accompanied by intrusive visual symptoms of the type of palinopsia, enhanced entoptic phenomena, photophobia, and nyctalopia (6). The pathophysiology of visual snow and its associated syndrome are still unclear, and available treatment is lacking (7, 8). Recently, however, neuroimaging, neurobehavioral and electrophysiological studies have helped to define what is most likely a complex network disorder characterized by a disturbance in the interaction between different areas of the visual system, as well as other brain regions involved in visual and sensory processing (9–14).

There has only been one report of ischemic stroke associated with visual snow phenomenon in the literature, reported by Catarci (4). Similar to our case, in this description of a 74 year old patient with occipital infarct following a right posterior cerebral artery occlusion, VS symptoms changed from transient to continuous (although occupying only one part of the visual field) immediately after the acute vascular event. Interestingly, one case with an opposite outcome has also been described, where a haemorrhagic stroke of the left thalamus was followed by a 1-week resolution of visual snow symptoms, in a 25 year old female (15).

The region of the infarct in our patient corresponded to the territory of the superior cerebellar artery, and in



**FIGURE 2** | Regions of the cerebellum implicated in VSS pathophysiology. The area in purple showed gray matter volume increase with VBM (16), whereas the region in light blue showed increased regional cerebral blood flow with ASL (17) and altered functional connectivity to the posterior cingulate cortex with resting state fMRI (18).

anatomical terms to cerebellar Crus I-lobule VI. Importantly, very similar regions have recently been implicated in visual snow pathophysiology. A structural MRI study by our team found a gray matter volume increase specifically in Crus I-lobule VI (16) (**Figure 2**). Functional MRI has also demonstrated cerebellar changes in VSS: arterial spin labeling (17) detected increased perfusion in the lateral and posterior cerebellum (**Figure 2**); whereas a further functional connectivity analysis (18) revealed that this same cerebellar region, which is known to form part of the dorsal attentional network (19), showed altered connectivity to the posterior elements of the default mode network. These functional changes, which implicate abnormal activity within networks that regulate major brain functions, were found regardless of the underlying brain state, signifying that they might have a relevant role in the basic neurobiology of VSS.

Due to its extensive circuitry with cortical and sub-cortical structures of the prefrontal and parietal regions, the posterior cerebellum plays a key role not only in motor functions but also in sensori-motor and cognitive integration (20–22). The Crus I-lobule VI regions in particular have been described as part of the “cognitive cerebellum” (23), which can regulate complex functions such as attention, decision making, visual working memory and even emotional processing (24). Cerebellar dysfunction has been implicated in several pathological brain states, including depression (25) and autism (26). It is thus not entirely surprising that a similar network-type disorder such as visual snow syndrome (27) might be caused by at least a partial involvement of this complex brain region.

Although much still needs to be understood about visual snow, it is becoming clear that some forms of the condition might arise in the aftermath of a specific incident, such as a change in headache comorbidity (1), an infection (28) or the start of new medication (29). In these cases, it is possible to hypothesize that some underlying vulnerability might exist in specific subjects, allowing an inciting event

to easily trigger the phenomenon (15). The presence of episodic visual snow in our patient, previously dismissed as a somewhat normal perception, seems to characterize him as one of these predisposed individuals; it then took an independent brain insult in a region directly involved in visual snow pathogenesis to facilitate the resurfacing of the dysfunction, causing a complete and continuous manifestation of the disorder.

## DATA AVAILABILITY STATEMENT

The original contributions presented in the study are included in the article/supplementary material, further inquiries can be directed to the corresponding author/s.

## REFERENCES

- Schankin CJ, Maniyar FH, Digre KB, Goadsby PJ. 'Visual snow' - a disorder distinct from persistent migraine aura. *Brain*. (2014) 137:1419–28. doi: 10.1093/brain/awu050
- Kondziella D, Olsen MH, Dreier JP. Prevalence of visual snow syndrome in the UK. *Eur J Neurol*. (2020) 27:764–72. doi: 10.1111/ene.14150
- Puledda F, Schankin C, Goadsby PJ. Visual snow syndrome. A clinical and phenotypical description of 1,100 cases. *Neurology*. (2020) 94:e564–74. doi: 10.1212/WNL.00000000000008909
- Catarci T. Occipital ischaemic stroke after visual snow phenomenon - a case report. *Cephalalgia*. (2021) 41:871–4. doi: 10.1177/033310242020985444
- Puledda F, Schankin C, Digre K, Goadsby PJ. Visual snow syndrome: what we know so far. *Curr Opin Neurol*. (2018) 31:52–8. doi: 10.1097/WCO.0000000000000523
- Headache Classification Committee of the International Headache Society (IHS). The international classification of headache disorders, 3rd edition. *Cephalalgia*. (2018) 38:1–211. doi: 10.1177/0333102417738202
- Puledda F, Vandenbussche N, Moreno-Ajona D, Eren O, Schankin C, Goadsby PJ. Evaluation of treatment response and symptom progression in 400 patients with visual snow syndrome. *Br J Ophthalmol*. (2021). doi: 10.1136/bjophthalmol-2020-318653. [Epub ahead of print].
- van Dongen RM, Waaijer LC, Onderwater GLJ, Ferrari MD, Terwindt GM. Treatment effects and comorbid diseases in 58 patients with visual snow. *Neurology*. (2019) 93:e398–403. doi: 10.1212/WNL.00000000000007825
- Schankin CJ, Maniyar FH, Chou DE, Eller M, Sprenger T, Goadsby PJ. Structural and functional footprint of visual snow syndrome. *Brain*. (2020) 143:1106–13. doi: 10.1093/brain/awaa053
- Eren O, Rauschel V, Ruscheweyh R, Straube A, Schankin CJ. Evidence of dysfunction in the visual association cortex in visual snow syndrome. *Ann Neurol*. (2018) 84:946–9. doi: 10.1002/ana.25372
- Puledda F, Ffytche D, Lythgoe DJ, O'Daly O, Schankin C, Williams SCR, et al. Insular and occipital changes in visual snow syndrome: a BOLD fMRI and MRS study. *Ann Clin Trans Neurol*. (2020) 7:296–306. doi: 10.1002/acn3.50986
- Michels L, Stämpfli P, Aldusary N, Piccirelli M, Freund P, Weber KP, et al. Widespread white matter alterations in patients with visual snow syndrome. *Front Neurol*. (2021) 12:723805. doi: 10.3389/fneur.2021.723805
- Aldusary N, Traber GL, Freund P, Fierz FC, Weber KP, Baeshen A, et al. Abnormal connectivity and brain structure in patients with visual snow. *Front Hum Neurosci*. (2020) 14:582031. doi: 10.3389/fnhum.2020.582031
- McKendrick AM, Chan YM, Tien M, Millist L, Clough M, Mack H, et al. Behavioral measures of cortical hyperexcitability assessed in people who experience visual snow. *Neurology*. (2017) 88:1243–9. doi: 10.1212/WNL.0000000000003784
- Mehta DG, Garza I, Robertson CE. Two hundred and forty-eight cases of visual snow: a review of potential inciting events and contributing comorbidities. *Cephalalgia*. (2021) 41:1015–26. doi: 10.1177/0333102421996355
- Puledda F, Bruchhage M, O'Daly O, Ffytche D, Williams SCR, Goadsby PJ. Occipital cortex and cerebellum gray matter changes in visual snow syndrome. *Neurology*. (2020) 95:e1792–9. doi: 10.1212/WNL.00000000000010530
- Puledda F, Schankin CJ, O'Daly O, Ffytche D, Eren O, Karsan N, et al. Localised increase in regional cerebral perfusion in patients with visual snow syndrome: a pseudo-continuous arterial spin labelling study. *J Neurol Neurosurg Psychiatry*. (2021) 92:918–26. doi: 10.1136/jnnp-2020-325881
- Puledda F, O'Daly O, Schankin C, Ffytche D, Williams SC, Goadsby PJ. Disrupted connectivity within visual, attentional and salience networks in the visual snow syndrome. *Hum Brain Mapp*. (2021) 42:2032–44. doi: 10.1002/hbm.25343
- Guell X, Schmammann JD, Gabrieli JDE, Ghosh SS. Functional gradients of the cerebellum. *eLife*. (2018) 7:e36652. doi: 10.7554/eLife.36652
- Stoodley CJ, Schmammann JD. Evidence for topographic organization in the cerebellum of motor control versus cognitive and affective processing. *Cortex*. (2010) 46:831–44. doi: 10.1016/j.cortex.2009.11.008
- Strick PL, Dum RP, Fiez JA. Cerebellum and nonmotor function. *Annu Rev Neurosci*. (2009) 32:413–34. doi: 10.1146/annurev.neuro.31.060407.125606
- Allen G, Buxton RB, Wong EC, Courchesne E. Attentional activation of the cerebellum independent of motor involvement. *Science*. (1997) 275:1940–3. doi: 10.1126/science.275.5308.1940
- Stoodley CJ, Schmammann JD. Functional topography in the human cerebellum: a meta-analysis of neuroimaging studies. *NeuroImage*. (2009) 44:489–501. doi: 10.1016/j.neuroimage.2008.08.039
- King M, Hernandez-Castillo CR, Poldrack RA, Ivry RB, Diedrichsen J. Functional boundaries in the human cerebellum revealed by a multi-domain

## AUTHOR CONTRIBUTIONS

FP wrote the first draft of the manuscript. MDVM and PG edited the final version of the manuscript. All authors reviewed and discussed the case, contributed to the article, and approved the submitted version.

## FUNDING

This work was funded by NIHR SLaM Biomedical Research Centre at South London, Maudsley NHS Foundation Trust, King's College London (IS-BRC-1215-20018), and the Visual Snow Initiative. FP is funded by the King's Prize Fellowship and Anthony Mellows medal.



- task battery. *Nat Neurosci.* (2019) 22:1371–8. doi: 10.1038/s41593-019-0436-x
25. Schmahmann JD. Disorders of the cerebellum: ataxia, dysmetria of thought, and the cerebellar cognitive affective syndrome. *J Neuropsychiatry Clin Neurosci.* (2004) 16:367–78. doi: 10.1176/jnp.16.3.367
26. D’Mello AM, Stoodley CJ. Cerebro-cerebellar circuits in autism spectrum disorder. *Front Neurosci.* (2015) 9:408. doi: 10.3389/fnins.2015.00408
27. Klein A, Schankin C. Visual snow syndrome as a network disorder: a systematic review. *Front Neurol.* (2021) 12:724072. doi: 10.3389/fneur.2021.724072
28. Bracerros KK, Asahi MG, Gallemore RP. Visual snow-like symptoms and posterior uveitis following COVID-19 infection. *Case Rep Ophthalmol Med.* (2021) 2021:6668552. doi: 10.1155/2021/6668552
29. Eren OE, Schöberl F, Schankin CJ, Straube A. Visual snow syndrome after start of citalopram—novel insights into underlying pathophysiology. *Eur J Clin Pharmacol.* (2020) 77:271–2. doi: 10.1007/s00228-020-02996-9

**Conflict of Interest:** The authors declare that the research was conducted in the absence of any commercial or financial relationships that could be construed as a potential conflict of interest.

**Publisher’s Note:** All claims expressed in this article are solely those of the authors and do not necessarily represent those of their affiliated organizations, or those of the publisher, the editors and the reviewers. Any product that may be evaluated in this article, or claim that may be made by its manufacturer, is not guaranteed or endorsed by the publisher.

Copyright © 2022 Puledda, Villar-Martínez and Goadsby. This is an open-access article distributed under the terms of the Creative Commons Attribution License (CC BY). The use, distribution or reproduction in other forums is permitted, provided the original author(s) and the copyright owner(s) are credited and that the original publication in this journal is cited, in accordance with accepted academic practice. No use, distribution or reproduction is permitted which does not comply with these terms.

# Advantages of publishing in Frontiers



## OPEN ACCESS

Articles are free to read for greatest visibility and readership



## FAST PUBLICATION

Around 90 days from submission to decision



## HIGH QUALITY PEER-REVIEW

Rigorous, collaborative, and constructive peer-review



## TRANSPARENT PEER-REVIEW

Editors and reviewers acknowledged by name on published articles

## Frontiers

Avenue du Tribunal-Fédéral 34  
1005 Lausanne | Switzerland

Visit us: [www.frontiersin.org](http://www.frontiersin.org)

Contact us: [frontiersin.org/about/contact](http://frontiersin.org/about/contact)



## REPRODUCIBILITY OF RESEARCH

Support open data and methods to enhance research reproducibility



## DIGITAL PUBLISHING

Articles designed for optimal readership across devices



## FOLLOW US

@frontiersin



## IMPACT METRICS

Advanced article metrics track visibility across digital media



## EXTENSIVE PROMOTION

Marketing and promotion of impactful research



## LOOP RESEARCH NETWORK

Our network increases your article's readership