

# Visualization of anatomical structures in the fetlock region of the horse using cone beam computed tomography (CBCT) in comparison with conventional multidetector computed tomography (MDCT)

J. Bierau<sup>1</sup>, A. Cruz<sup>1</sup>, C. Koch<sup>2</sup>, G. Manso-Diaz<sup>3</sup>, J. Burk<sup>1</sup>, K. Büttner<sup>4</sup>, C. Staszuk<sup>5</sup>, M. Röcken<sup>1</sup>

<sup>1</sup> Equine Clinic (Surgery, Orthopedics), Justus-Liebig-University Giessen, Germany

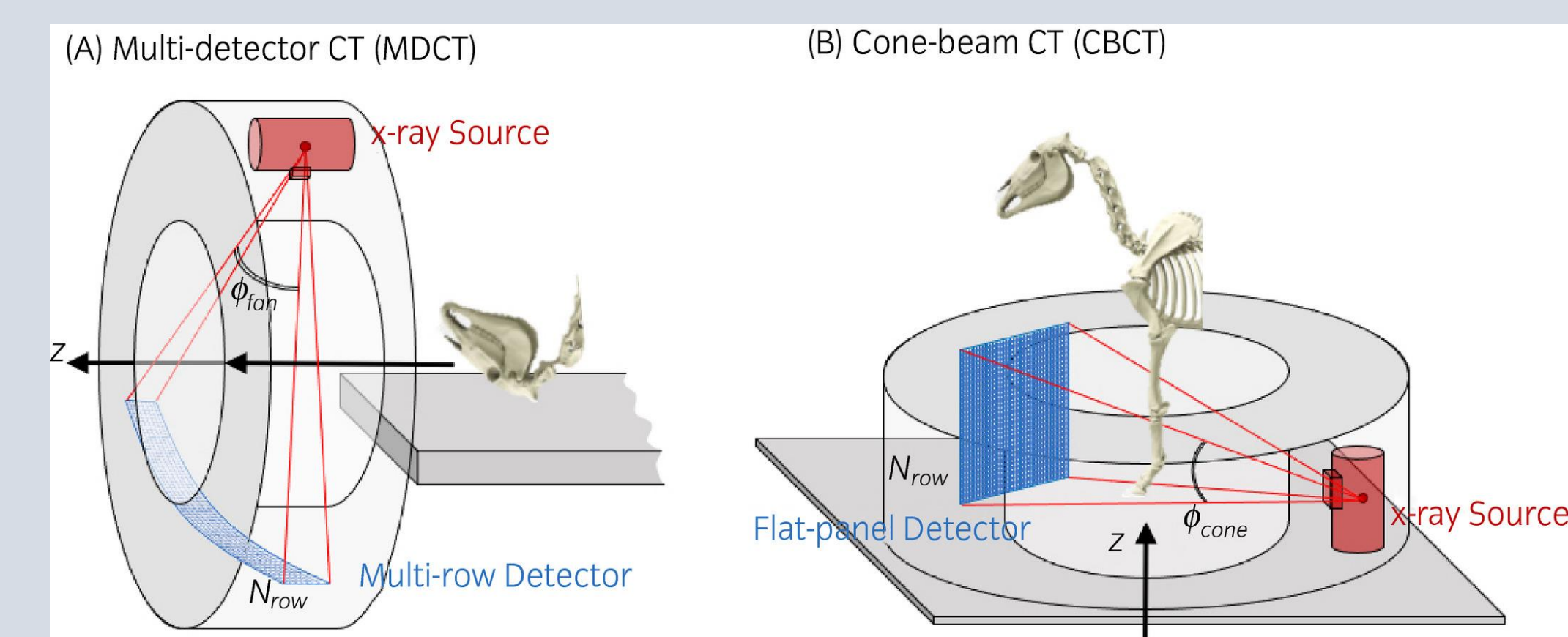
<sup>2</sup> Swiss Institute of Equine Medicine (ISME), Department of Clinical Veterinary Medicine, Vetsuisse Faculty, University of Bern, Switzerland

<sup>3</sup> Faculty of Veterinary Medicine, Department of Animal Medicine and Surgery, Universidad Complutense de Madrid, Spain

<sup>4</sup> Unit for Biomathematics and Data Processing, Justus-Liebig-University Giessen, Germany

<sup>5</sup> Institute of Veterinary-Anatomy, -Histology and -Embryology Faculty of Veterinary Medicine Justus-Liebig- University Giessen, Germany

## Background

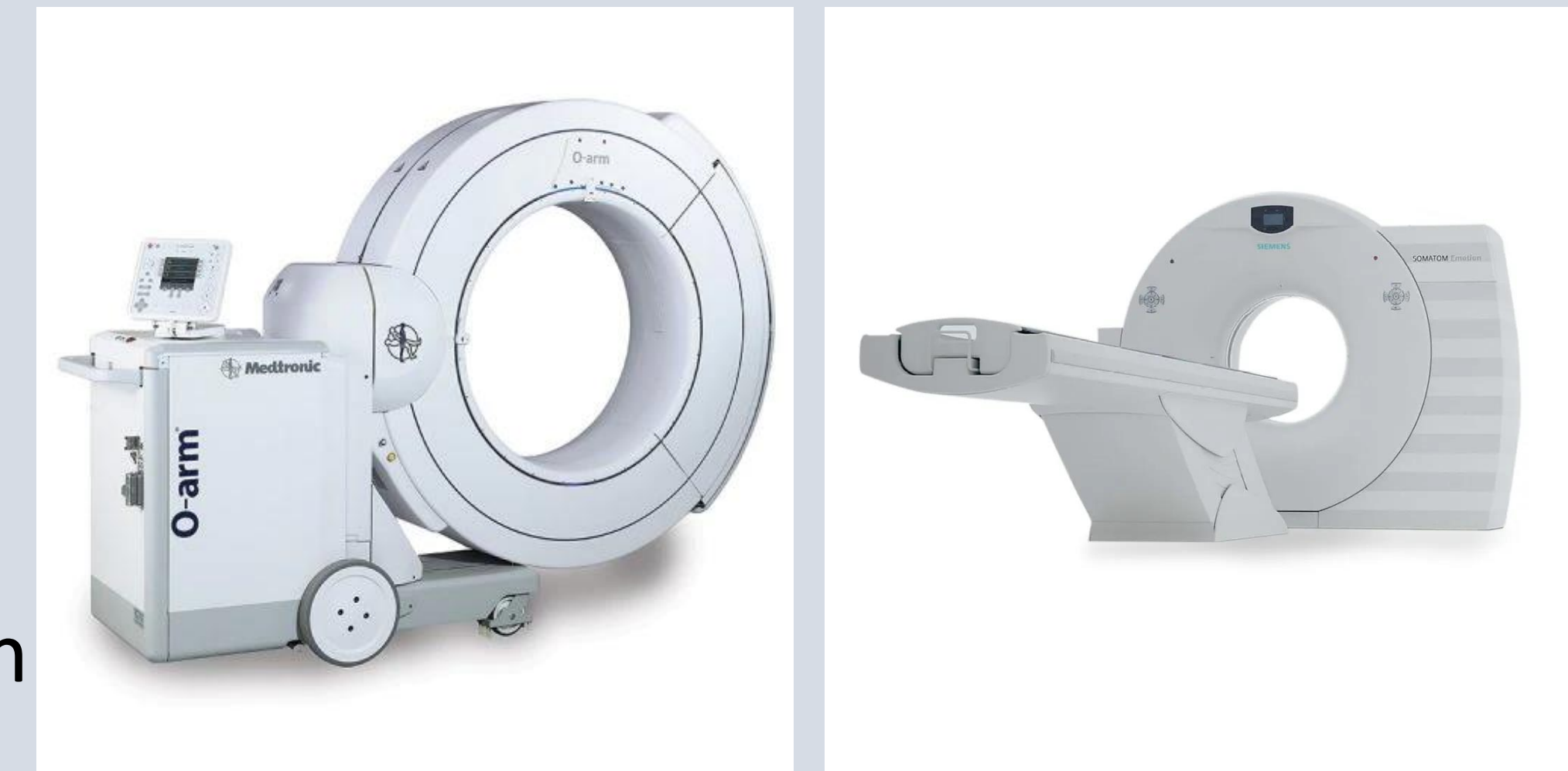

### MDCT

- narrow, fan-shaped X-ray beam
- slice by slice along the patient's z-axis

### CBCT

- cone-shaped X-ray beam and a large flat panel detector
- multiple projections from a single rotation around the region of interest



## Materials & Methods

### Specimens

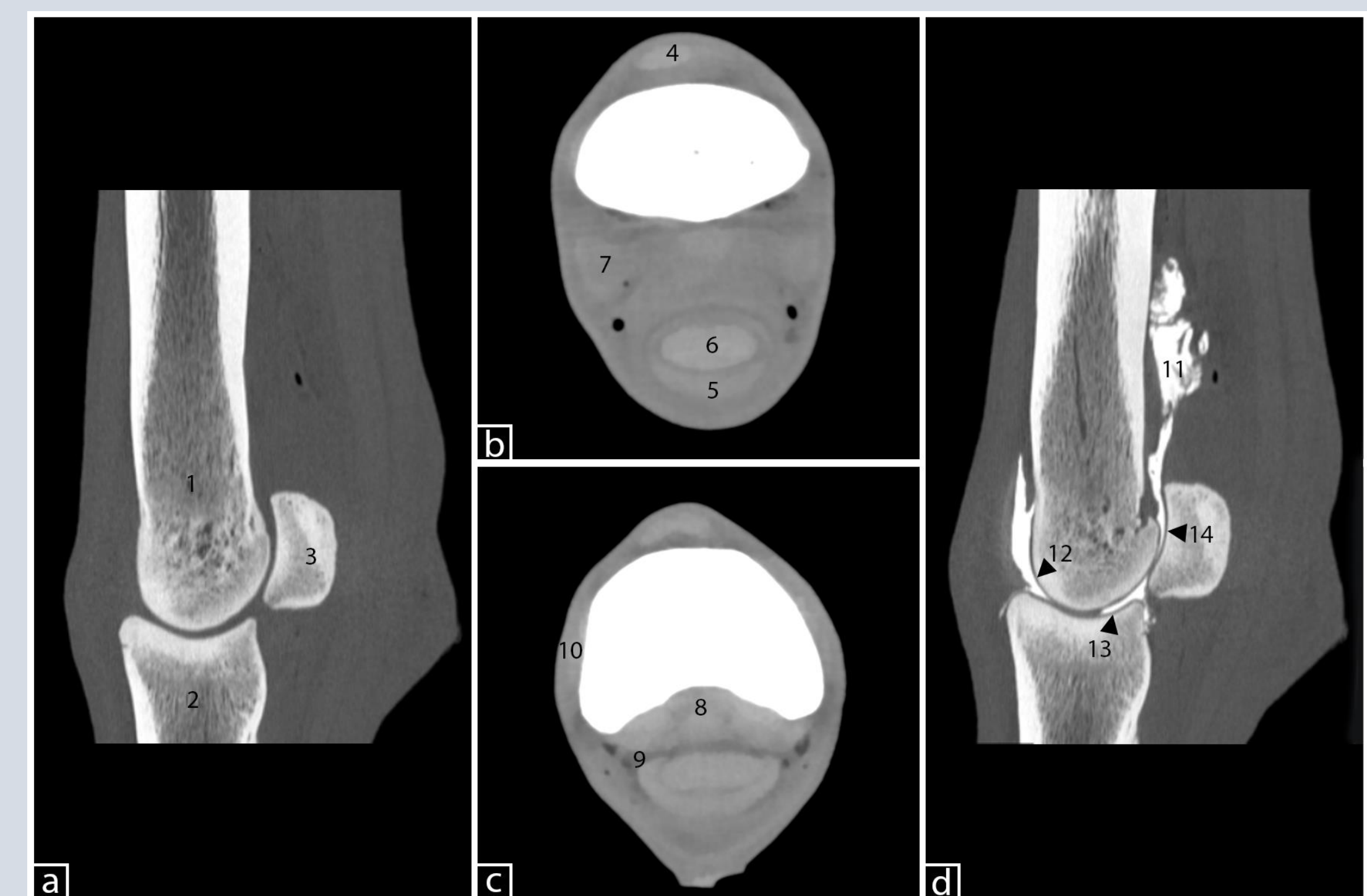
Twenty-nine limbs from nine horses euthanized for reasons unrelated to this study

### CBCT and MDCT scans

A native and post contrast scan was performed in the area of the fetlock joint in the CBCT and in the MDCT

### Image Evaluation / Scoring system

- 0: structure was not visible
- 1: structure was poorly visualized, but detectable, and was identified by its location and signal intensity/density, but not by margins, shape or size
- 2: structure was clearly identified by its location, shape and signal intensity/density, but the margins were not clearly delineated
- 3: structure was well visualized and clearly delineated by location, shape, signal intensity/density, size and margins



## Results

### bony structures

no differences between CBCT and MDCT were detected in terms of the described scoring criteria (mean score 3)

### cartilage

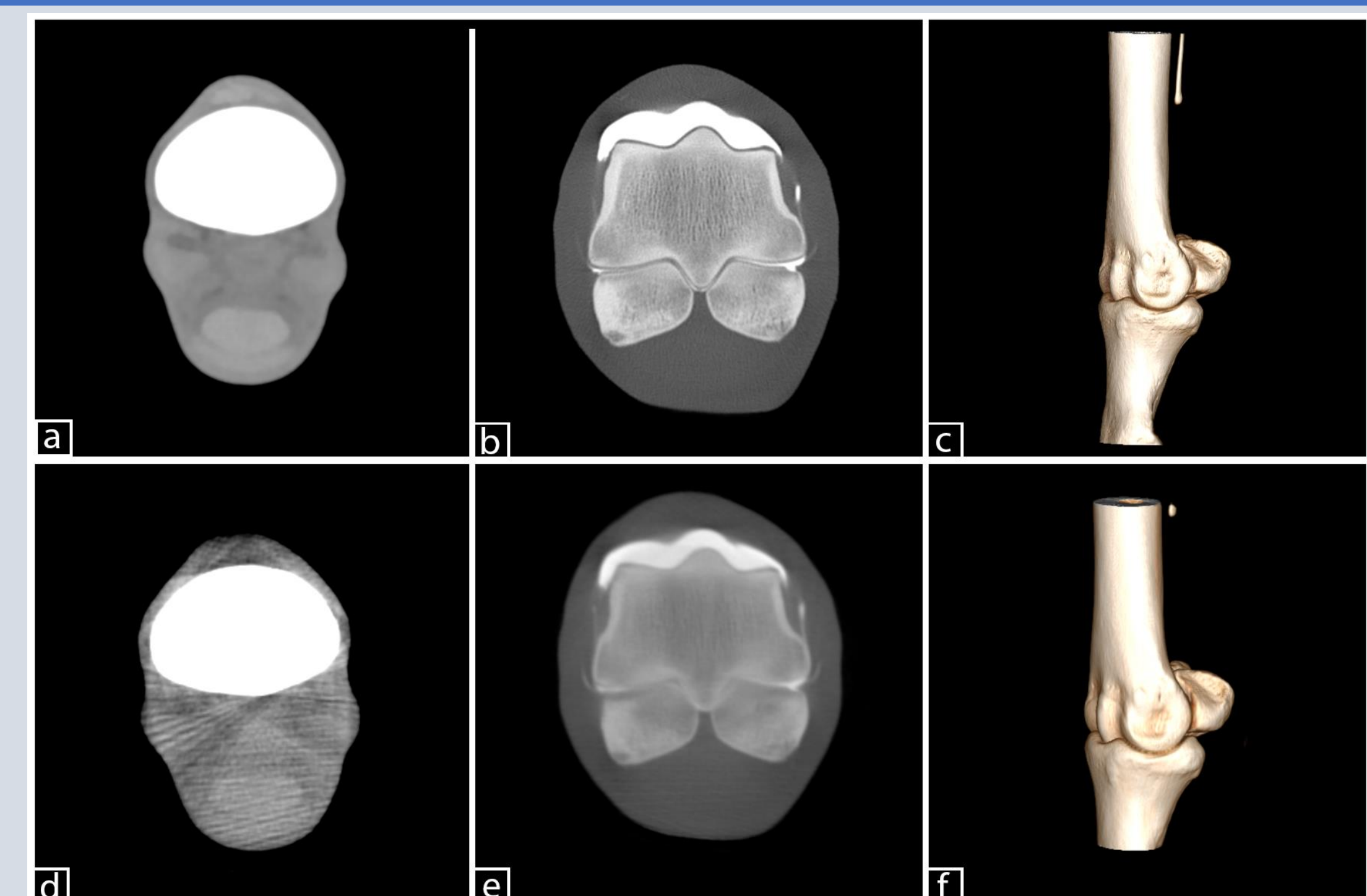
no differences between CBCT and MDCT were detected in terms of the described scoring criteria (nativ: mean score 0; post contrast: score= 2-3 )

### soft tissue

A weak to moderate correlation of soft tissue of MDCT and CBCT was noted. MDCT was always able to obtain a better representation of soft tissue (CBCT mean=0.58 vs. MDCT mean= 1.72)

### ligaments

Visualization of ligaments could be detected very poorly in both modalities (score=0-1)



(a: MDCT; d: CBCT): soft tissue window  
(b: MDCT; e: CBCT): arthrography fetlock joint  
(c: MDCT; f: CBCT): field of view

## Conclusion

CBCT can be used in case of an indication for imaging of bony structures and cartilage after contrast injection. Another advantage is mobility of the device, giving the possibility to use it in different rooms and allowing a very high flexible adjustment to examined horse.

## Acknowledgments & References

1. Stewart, Holly L., et al. "Use of cone-beam computed tomography for advanced imaging of the equine patient." *Equine veterinary journal* 53.5 (2021): 872-885.
2. Vallance, S. A., et al. "Comparisons of computed tomography, contrast enhanced computed tomography and standing low-field magnetic resonance imaging in horses with lameness localised to the foot. Part 1: anatomic visualisation scores." *Equine Veterinary Journal* 44.1 (2012): 51-56.