




Article

The Feasibility of Immunocryosurgery in the Treatment of Non-Superficial, Facial Basal Cell Carcinoma That Relapsed after Standard Surgical Excision: An Experience Report from Two Centers

Georgios Gaitanis ^{1,2,*} , Athanasia Zampeta ¹, Panagiota Tsintzou ¹, Grigorios Fillis ², Konstantinos Seretis ³ , Laurence Feldmeyer ⁴ and Ioannis Bassukas ¹ 

¹ Department of Skin and Venereal Diseases, Faculty of Medicine, School of Health Sciences, University of Ioannina, 45100 Ioannina, Greece

² DELC Clinic, 2502 Biel/Bienne, Switzerland

³ Department of Plastic and Reconstructive Surgery, Faculty of Medicine, School of Health Sciences, University of Ioannina, 45100 Ioannina, Greece

⁴ Department of Dermatology, Inselspital, Bern University Hospital, University of Bern, 3010 Bern, Switzerland

* Correspondence: ggaitan@uoi.gr

Abstract: In this retrospective, chart review study, we evaluated the feasibility of immunocryosurgery in facial, non-superficial basal cell carcinomas (BCC) that had relapsed after standard surgery. Inclusion criteria were (a) ‘biopsy confirmed relapse of facial BCC’, (b) known ‘calendar year of surgical excision(s)’, and (c) ‘relapse within 10 years after the last surgical excision’. Tumors treated from 1 January 2011 to 31 December 2020 with a standard 5-week immunocryosurgery cycle (daily imiquimod application for 5 weeks and a cryosurgery session at day 14) were included. Descriptive statistics, Kaplan–Meier method, and Cox proportional hazards model were calculated with significance at $p < 0.05$. From the $n = 27$ BCC evaluated, $n = 20$ ($74.1 \pm 8.4\%$) cleared after one immunocryosurgery cycle. Two of the remaining cases cleared completely after a repeat cycle, one patient favored surgery, and four BCC did not clear despite additional immunocryosurgery cycles (feasibility $81.5 \pm 7.5\%$). Of the 22 tumors with clinical outcome ‘complete clearance with immunocryosurgery’, three BCC relapsed at 9, 28, and 50 months. Overall, the 5-year treatment efficacy rate was $60.2 \pm 13.4\%$ (mean follow-up 94.6 ± 15.1 months). In total, 20/27 BCC relapses after surgery (74.1%) were tumor-free at the end of personalized follow-up times ($66.7 \pm 12.4\%$ tumor free patients at 5-year follow-up). Number of tumor relapses before immunocryosurgery was the single predictor of tumor progression after immunocryosurgery ($p = 0.012$). Conclusively, immunocryosurgery could be further evaluated as an alternative, definitive treatment of selected facial BCC relapsing after surgery.

Keywords: immunocryosurgery; imiquimod; cryosurgery; basal cell carcinoma



Citation: Gaitanis, G.; Zampeta, A.; Tsintzou, P.; Fillis, G.; Seretis, K.; Feldmeyer, L.; Bassukas, I. The Feasibility of Immunocryosurgery in the Treatment of Non-Superficial, Facial Basal Cell Carcinoma That Relapsed after Standard Surgical Excision: An Experience Report from Two Centers. *Curr. Oncol.* **2022**, *29*, 8475–8482. <https://doi.org/10.3390/curroncol29110668>

Received: 17 September 2022

Accepted: 31 October 2022

Published: 7 November 2022

Publisher’s Note: MDPI stays neutral with regard to jurisdictional claims in published maps and institutional affiliations.



Copyright: © 2022 by the authors. Licensee MDPI, Basel, Switzerland. This article is an open access article distributed under the terms and conditions of the Creative Commons Attribution (CC BY) license (<https://creativecommons.org/licenses/by/4.0/>).

1. Introduction

Immunocryosurgery is a minimally invasive therapeutic approach that utilizes the synergistic potential of a fixed timing combination of cryosurgery and topical imiquimod. A standard immunocryosurgery treatment cycle consists of once-daily 5% imiquimod cream application for 5 weeks and a rather mild cryosurgery session at day 14 of the imiquimod course [1]. Immunocryosurgery has demonstrated efficacy in the treatment of primary, non-superficial, basal cell carcinomas (BCC) with cure rates comparable to that of standard surgery [1–4]. Thus, after only one treatment cycle with immunocryosurgery, the 5-year recurrence rate of primary BCC with a maximal diameter ≤ 2 cm was $91.4 \pm 2.8\%$ for the per protocol and $87.7 \pm 3.1\%$ for the per intention to treat analyses [3]. Notably, with immunocryosurgery repeat cycles for partial responders and relapses, only three BCC sites were not tumor free at last follow-up (effectiveness: $97.1 \pm 1.6\%$ per protocol

or $93.2 \pm 2.3\%$ per intention to treat analyses) [3]. Moreover, neither tumor size (tumor diameter smaller vs. larger than 1.0 cm; $p = 0.865$) nor tumor localization (within vs. outside the H-region of the face; $p = 0.233$) seemed to modulate the treatment outcome [2,3]. The distinct efficacy of immunocryosurgery can most probably be attributed to the particular timing of the combination [5] as ‘cryosurgery during imiquimod application’ proved to be more effective compared to other timing protocols (e.g., ‘cryosurgery preceding imiquimod application’) [6]. At the tissue level, the cryoablation of the preconditioned from imiquimod application tumor seemed to abrogate the expected immune tolerance phenomena that continued imiquimod application induces and triggered a vivid specific antineoplastic inflammatory response [7]. The latter is both temporally and spatially mostly confined to the treated tumor. Corresponding alterations in the profile of cytokines and immune cells in the blood reflect this induction of immunoenhancing effects during the local treatment of BCC [8]. Due to its satisfactory feasibility including the treatment of older and frail patients and the excellent safety profile, immunocryosurgery is gaining recognition and is used in the outpatient setting in addition to the treatment of BCC and Bowen’s disease in immunocompetent and immunocompromised patients [9–11] as well as in the therapy of selected cases of *lentigo maligna* [12,13], Merkel cell carcinoma [14], and squamous cell carcinoma [15]. Of note, immunocryosurgery is a tissue sparing modality whose efficacy is not really limited by the tumors’ localization, tumor histology, or patients’ overall health condition [1,16].

BCC relapses after surgery, standard excision or Mohs’ procedure, constitute a subset of challenging, difficult to treat tumor cases, for which the standard of treatment recommendation is Mohs’ micrographic surgery [17]. However, Mohs’ surgery [17,18] is resource-intensive, not widely available and, in addition, there are recently rising concerns that it may carry an increased risk for the possible overtreatment of elderly BCC patients with limited life expectancy [19].

In the past decade, we had sporadically treated relapsed BCC with immunocryosurgery (including five already reported cases [20,21]) with promising efficacy and adequate tissue sparing results. In the present retrospective study, based on the compilation of these latter cases, we sought to evaluate the feasibility of immunocryosurgery as performed in a tertiary hospital (Ioannina, Greece) and an ambulatory clinic (Clinic DELC, Biel/Bienne, Switzerland) to treat BCC relapsing after standard surgical excision.

2. Materials and Methods

The University Hospital of Ioannina Institutional Review Board Committee granted permission (Approval No. 6/17.02.2022, 0.26 from 17 February 2022) and the files of patients with relapsed BCC treated with immunocryosurgery from 1 January 2011 to 31 December 2020 in the Dermatology Department of the Hospital as well as in an outpatient dermatology center in Switzerland (Dermatologie Esthétique Laser Chirurgie, [DELC Clinique] Biel/Bienne) were included in the study. All patients prior to treatment with immunocryosurgery were offered as a first choice the repeat of standard surgical excision. Notably, immunocryosurgery was introduced in the latter of the above centers in 2019, so in addition to restricted patient numbers, the relevant follow-up time was not expected to be more than 24 months. Inclusion criteria were (a) ‘relapse of a non-superficial, facial BCC’ (i.e., biopsy proven BCC tissues within or in contact with the surgical scar of a previously surgically treated and biopsy confirmed facial BCC), (b) known ‘calendar year of surgical excision(s) in the past’, and (c) ‘relapse within a 10-year period after the last surgical excision’. This latter criterion was specifically included to avoid the inclusion of new tumors that could have possibly developed in the direct proximity of the postsurgical scars and thus would constitute a new BCC and not a relapse. The results as per 31 December 2021 are reported.

A non-ablative therapeutic modality as an alternative to surgical treatment for BCC must present with an adequately high rate of complete tumor clearance (‘cure’) [22]. Accordingly, we differentiated between two distinct treatment failure endpoints for the evaluation

of the overall feasibility of immunocryosurgery in the present setting: (a) ‘no achievement of complete tumor clearance’ (no ‘complete response’, no CR), and (b) ‘relapse’ of a ‘complete responder’ during subsequent follow-up. Presently, for the *per intension* to treat analysis of the efficacy of immunocryosurgery, the above disease-progression events were analyzed both separately and jointly. After treatment, the tumor sites were followed up clinically for relapses including dermoscopy and optical coherence tomography in some cases. Relapses of BCC after immunocryosurgery appear as an enlarging papule within the scar of the previous treatment and present all the typical clinical and dermoscopic features of BCC. Therefore, follow-up was performed as in our previous studies [2,3,6], with clinical and dermatoscopic examination of the treated sites and in a case of a suspected recurrence, a biopsy was performed. Times to first disease progression event or to last follow-up information were calculated from the moment of the initiation of the first immunocryosurgery treatment cycle. For non-complete responders, the times-to-event were arbitrarily set at 0 (i.e., the moment of the initiation of the immunocryosurgery treatment). However, evaluation of a no-CR can be conducted at the 3-month follow-up appointment, in which immunocryosurgery-induced inflammation has subsided and tumor remnants are detectable during clinical examination including dermoscopy of the area.

In all cases, treatment started with a standard 5-week immunocryosurgery cycle that involved the daily application of imiquimod for 5 weeks and a relatively mild cryosurgery session (liquid N₂, open spray, two cycles of 15 s each) at day 14. The cryosurgery technique has recently been described in detail [1,11]. Incomplete responses and relapses after immunocryosurgery were scheduled to be treated with (repeat) immunocryosurgery cycles [11]; however, surgery or radiotherapy was also offered according to patient preferences. Once vismodegib was made available, it was also suggested as an alternative.

Data are summarized with descriptive statistics. Times-to-events were analyzed employing the Kaplan–Meier calculator and Cox proportional hazards model (backward stepwise Wald method) using SPSS (Statistics for Windows; IBM Corp., Armonk, NY, USA). Statistical significance was set up at $p < 0.05$.

3. Results

$n = 30$ BCC were identified in the databases, which were referred to as relapses after surgery and treated with immunocryosurgery. In the final analysis, $n = 27$ tumors were included (Table S1, Supplementary Materials); two cases were excluded due to unknown calendar year of reported surgery and in one case, the instigated surgical intervention was dated more than 10 years earlier (20 years). Twenty-three tumors were treated in the Department of Skin and Venereal Diseases in the University Hospital of Ioannina and the remaining four in DELC. From the 27 relapsing tumors, six BCC (22%) were of aggressive histology: four neoplasms were of basosquamous, one of mixed (basosquamous and micronodular), and one of keratotic micromorphology (Table S1).

Twenty tumors (percent \pm standard error: $74.1 \pm 8.4\%$) cleared after one immunocryosurgery treatment cycle (exemplary case in Figure 1).

From the remaining seven tumors, two cases cleared completely after a repeat immunocryosurgery cycle, one patient favored surgery at that point, and four BCC did not clear after additional immunocryosurgery treatment cycles (Figure 2) (i.e., the feasibility of immunocryosurgery to induce tumor clearance (cure) of relapsed BCC was $81.5 \pm 7.5\%$ (22/27 cases)).

Of the four above patients with treatment outcome ‘no clearance’, one patient preferred surgery after the second immunocryosurgery treatment cycle. In the remaining three patients, stabilization of the achieved partial remission was accomplished with periodically repeated immunocryosurgery treatment cycles to the end of follow-up (two of them at 6 and 44 follow-up months) or to the time of vismodegib initiation (one patient at 67 months follow-up). Of the 22 tumors with clinical outcome ‘cure with immunocryosurgery’, three BCC relapsed at 9, 28, and 50 months, respectively, after treatment initiation. Taken together, the tumor relapses after immunocryosurgery and the never cleared cases with

this modality correspond to an overall 5-year treatment efficacy rate of $60.2 \pm 13.4\%$ with a mean follow-up time without a disease progression event of 94.6 ± 15.1 months (Table 1 and Figure 3). Of the three tumor relapses after immunocryosurgery, one BCC cleared after a single immunocryosurgery treatment cycle repetition and two were referred for surgical treatment. In total, 20/27 BCC relapses after surgery (74.1%) were tumor-free at the end of personalized follow-up times. This corresponded to a 5-year disease free rate of $66.7 \pm 12.4\%$ after treatment exclusively with immunocryosurgery (respective mean time in sustained tumor control: 101.9 ± 14.2 months; Table 1 and Figure 3).

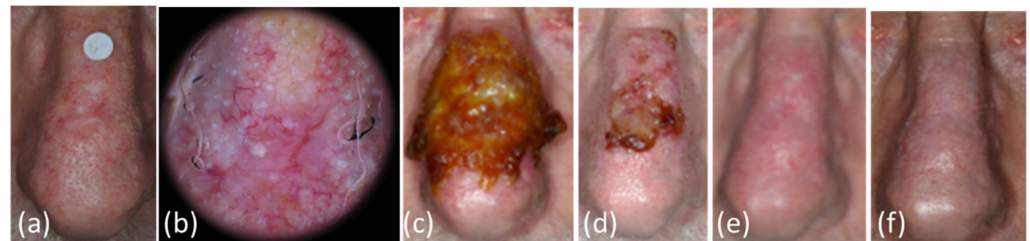

Figure 1. Patient/tumor 14 (Table S1, Supplementary Materials). (a,b) Clinical and dermoscopic picture of the relapsed basal cell carcinoma one year after surgery in a 67 year old patient. The tumor diameter was measured at 15 mm with the absence of clear borders. Solar damage of the surrounding skin of the nose was also evident. (c) After 2 weeks of daily imiquimod treatment at the day of cryosurgery treatment. There was extended skin inflammation due to the application of imiquimod on the whole of the nose. The cryosurgery was spatially confined on the initial tumor area and a narrow skin rim around it. (d) At the last day of imiquimod application (day 35), end of treatment. The intense inflammatory response had subsided. (e) At the one-month post-treatment follow-up appointment. (f) Thirty-six months after the end of treatment: no relapse and an excellent cosmetic outcome were recorded.

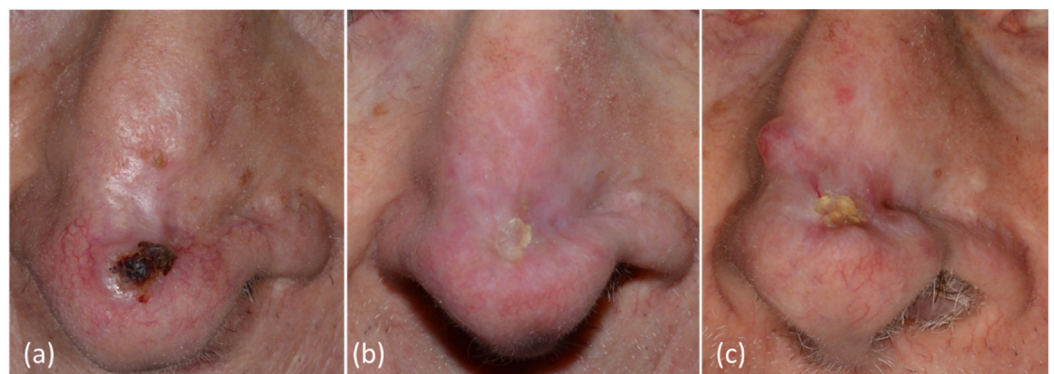


Figure 2. Patient/tumor 12 (Table S1, Supplementary Materials). (a) Basal cell carcinoma relapse after surgery in an 86-year-old patient at baseline. (b) Twelve months after initiation of immunocryosurgery treatment cycles: partial response; (c) At 44 months of follow-up: slow disease progression. At this point, the already 90-year-old patient denied any further therapeutic interventions.

Stable disease at the end of the available follow-up time is an optional treatment outcome in the cohort of, in their majority, elderly patients with relapsed BCC. The overall efficacy of the proposed immunocryosurgery-based therapeutic approach to ensure at least stable disease to the end of the individual follow-up time was 85.2% (22/27 BCC). Only in 5/27 cases was this therapy revised in favor of other modalities (surgery in four cases and vismodegib in one).

Table 1. Probability of disease-free tumor sites (standard error, S.E.) as a function of follow-up time after treatment initiation with immunocryosurgery for basal cell carcinoma (BCC) that had relapsed after standard surgical excision (Kaplan–Meier method).

Follow-up [months]	Cases in Follow-up (% of Initial Cases)	BCC Sites not Disease Free (in Interval)	Disease-Free [S.E.] %	
			All Cases (n = 27)	Cleared BCC (n = 22) #
0 *	22 (81.5)	5	81.5 [7.5]	100
12	21 (77.8)	1 &,\$	77.8 [8.0]	95.5 [4.4]
18	16 (59.3)	0		
24	15 (55.6)	0		
36	11 (40.7)	1 &,+	72.2 [9.2]	
48	9 (33.3)	0		
60	4 (14.8)	1 &,\$	60.2 [13.4]	81.8 [13.2]

* 0 months: arbitrary time for no complete tumor clearance with immunocryosurgery ('not cleared'). & Relapse. \$ Treatment with surgery. † Complete response with an immunocryosurgery treatment cycle. # Complete responders with immunocryosurgery.

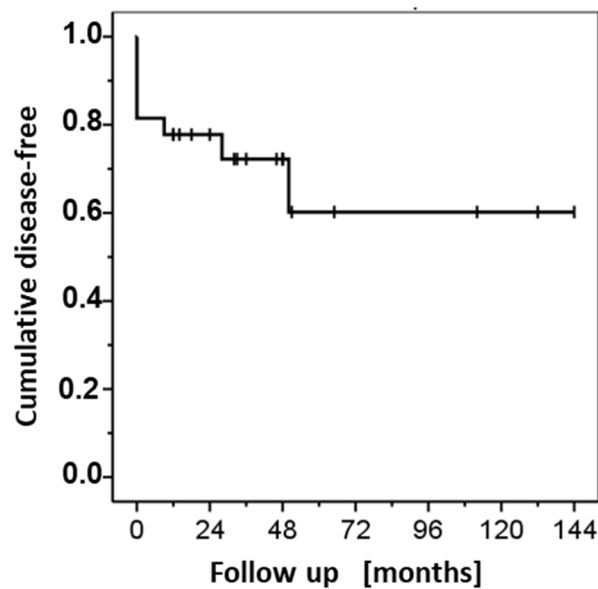


Figure 3. Immunocryosurgery for basal cell carcinoma relapses after surgery. Probability of disease-free tumor site as a function of follow-up time after the first immunocryosurgery treatment cycle (solid line). Short perpendicular bars represent points of censoring events (i.e., times to last available follow-up information of no relapse).

The impact of potential predictors of immunocryosurgery effectiveness as a treatment modality for BCC relapses after standard surgical excision was evaluated with the Cox proportional hazards model. From the inserted regressors (age of the patients, maximal tumor diameter, average tumor growth rate, i.e., maximal tumor diameter/time after the last surgical treatment in mm/year, number of tumor relapses before immunocryosurgery and counts of risk factors for relapse before surgery) only the number of tumor relapses before immunocryosurgery was a statistically significant predictor of a tumor progression event (either no complete response or relapse) after starting immunocryosurgery ($p = 0.012$; Table S2, Supplementary Materials). Notably, treatment effectiveness did not differ between older (≥ 75 years old) and younger patients ($p = 0.967$, log rank test; Figure S1, Supplementary Materials).

The adverse events of the treatment included the ones anticipated during immunocryosurgery (inflammation at the treated site, oozing, and crusting, particularly during the time following the cryosurgery session) [1]. One patient complained about a limited flu-like episode without fever the day following the cryosurgery session.

4. Discussion

In the present retrospective study, two thirds (66.7%) of BCC that had relapsed after surgery were relapse-free with immunocryosurgery after 5 years of follow-up, a noticeable long-term treatment efficacy for tumors of this challenging cohort. Moreover, at least stable disease (mostly complete responses) was achieved in a remarkably high percentage of the tumors treated (85.2%) and only in five out of the 27 cases was the therapy revised in favor of surgery (four cases) or vismodegib (one case). The treatment of BCC relapses after surgery remains a therapeutic challenge. Guidelines for the treatment of BCC including the European guidelines [23], recommend Mohs' micrographic surgery or radiotherapy for this BCC subset. However, as herein confirmed for immunocryosurgery, the efficacy of all therapeutic modalities including the effectiveness of Mohs' surgery [13] is lower in this setting compared to that of the primary tumors. Nevertheless, the optimization of treatment selection for BCC in frail patients or patients with limited life expectancy is a crucial issue that demands redefinition of the treatment targets in order to avoid possible overtreatment with the use of disproportionately aggressive and burdensome procedures [19]. Our present findings further underline the impact of immunocryosurgery, an office- and, even, house-compatible modality, as an effective alternative to highly specialized treatment methods. Likewise, many of the tumors treated herein fall into the not-clearly defined category of "locally advanced BCC", which would be suitable for hedgehog inhibitor treatment [24]. Interestingly, facial localization and size ≥ 2 cm were criteria for the inclusion of BCC cases in this category of locally advanced tumors, in a recent real world clinical study that comprised 433 BCC [25]. Although, not directly comparable, immunocryosurgery seems to achieve higher cure rates compared to hedgehog inhibitors, but lower than the ones reported for Mohs' surgery of relapsed BCC [25].

An intriguing finding in the present study is that the number of relapses before immunocryosurgery was a predictive factor for a tumor relapse after immunocryosurgery (Table S2, Supplementary Materials). In comparison, other parameters such as patient age or tumor size did not affect the treatment outcome in the present study, probably due to the limited number of cases. However, unpublished data from our center show that BCC size can be a predicting factor in tumors with maximal diameter > 2 cm, as the efficacy of a standard 5-week immunocryosurgery cycle falls significantly in larger tumors with a maximal diameter between 2 to 4 cm. Thus, for larger BCC, individualized approaches are required [1]. This supports previous observations that within the population of BCC exist tumors with deviated biological behavior exist that affects treatment susceptibility. Likewise, the BCC histological subtype is a well-known determinant of the effectiveness of surgery [26] but does not seem to play a similarly significant role with immunocryosurgery [2]. Accordingly, tumors carrying resistance mutations to hedgehog inhibitors fail treatment with these agents [27]. Imiquimod monotherapy also seems to differentiate two subgroups of BCC according to therapeutic response: those that achieve a lasting complete remission and those that fail to achieve clearance [28]. As immune mediated phenomena underly imiquimod monotherapy [29,30] and the proposed immunocryosurgery, any alterations in the tumor or patient immune profile may impact the response to treatment. Regarding immunocryosurgery, this is eloquently presented by the differential response of individual BCC within the same patient [21] and the limited restricted response of immunosuppressed patients [11]. These findings point to the presence of, on one hand, universal predictive 'tumor-specific' factors for the response of BCC to treatment, common to all different therapeutic modalities, destructive or not, and on the other, of modality-specific predictive factors of treatment failure. Knowledge of these factors may guide us in the future to the selection of the most appropriate for a particular tumor treatment modality. However, focusing on the elaboration of such 'inherent' factors that mediate global treatment resistance, independent of the employed therapeutic modalities, may help to understand the peculiarly low rate of aggressive BCC cases. In this latter framework, our present results suggest that history of multiple relapses after surgery is also a predictor of treatment failure with immunocryosurgery.

The major restrictions of the present study are its retrospective design and the heterogeneity of the tumors included.

5. Conclusions

Immunocryosurgery, which is a minimally invasive and highly efficacious modality for primary BCC irrespective of the localization or the tumor histology, could be evaluated in the future as an adjuvant treatment of selected relapsing BCC.

Supplementary Materials: The following supporting information can be downloaded at: <https://www.mdpi.com/article/10.3390/curroncol29110668/s1>, Figure S1: Immunocryosurgery for BCC relapses after surgery: Disease free tumor sites for patients older from 75 years vs. younger. p: log rank (Mantel-Cox test); Table S1: Patient and tumor characteristics included in the study; Table S2: Multivariate comparison of predictors of the treatment outcome of basal cell carcinoma relapses after surgery with immunocryosurgery. Cox proportional hazards model for the prediction of a disease-free tumor site ('clearance') at last follow-up.

Author Contributions: Conceptualization, G.G. and I.B.; Methodology, G.G. and I.B.; Formal analysis, G.G., A.Z. and I.B.; Data curation, A.Z., P.T., G.F. and K.S.; Writing—original draft preparation, G.G. and A.Z.; Writing—review and editing, K.S., L.F. and I.B.; Supervision, I.B.; Project administration, A.Z. All authors have read and agreed to the published version of the manuscript.

Funding: This study was partially funded by the University of Ioannina Research Committee Account no. 22195.

Institutional Review Board Statement: This study was conducted with the approval of the Institutional Review Board Committee of University Hospital of Ioannina (Approval No. 6 0.26 from 17 February 2022).

Informed Consent Statement: Informed consent was obtained from all subjects involved in the study.

Data Availability Statement: The data are contained within the article or supplementary material.

Conflicts of Interest: The authors declare no conflict of interest.

References

1. Gaitanis, G.; Bassukas, I.D. A Review of Immunocryosurgery and a Practical Guide to Its Applications. *Diseases* **2021**, *9*, 71. [[CrossRef](#)] [[PubMed](#)]
2. Gaitanis, G.; Bassukas, I.D. Immunocryosurgery for non-superficial basal cell carcinoma: A prospective, open-label phase III study for tumours ≤ 2 cm in diameter. *Acta Derm.-Venereol.* **2014**, *94*, 38–44. [[CrossRef](#)] [[PubMed](#)]
3. Gaitanis, G.; Bassukas, I.D. Immunocryosurgery for non-superficial basal cell carcinomas ≤ 20 mm in maximal diameter: Five-year follow-up. *J. Geriatr. Oncol.* **2019**, *10*, 475–478. [[CrossRef](#)] [[PubMed](#)]
4. Mosterd, K.; Krekels, G.A.; Nieman, F.H.; Ostertag, J.U.; Essers, B.A.B.; Dirksen, C.D.; Steijlen, P.M.; Vermeulen, A.; Neumann, H.; Kelleners-Smeets, N.W.J. Surgical excision versus Mohs' micrographic surgery for primary and recurrent basal-cell carcinoma of the face: A prospective randomised controlled trial with 5-years' follow-up. *Lancet Oncol.* **2008**, *9*, 1149–1156. [[CrossRef](#)]
5. Bassukas, I.D.; Gaitanis, G. Combination of cryosurgery and topical imiquimod: Does timing matter for successful immunocryosurgery? *Cryobiology* **2009**, *59*, 116–117. [[CrossRef](#)]
6. Gaitanis, G.; Alexopoulos, E.C.; Bassukas, I.D. Cryosurgery is more effective in the treatment of primary, non-superficial basal cell carcinomas when applied during and not prior to a five week imiquimod course: A randomized, prospective, open-label study. *Eur. J. Dermatol.* **2011**, *21*, 952–958. [[CrossRef](#)]
7. Nomikos, K.; Lampri, E.; Spyridonos, P.; Bassukas, I.D. Alterations in the inflammatory cells infiltrating basal cell carcinomas during immunocryosurgery. *Arch. Dermatol. Res.* **2019**, *311*, 499–504. [[CrossRef](#)]
8. Gaitanis, G.; Ganiatsa, A.; Vartholomatos, G.; Karamoutsios, A.; Pappas, P.; Bassukas, I.D. Immunocryosurgery for basal cell carcinoma: Impact on circulating CD4 + CD25 high T regulatory cells and serum cytokines. *Eur. J. Dermatol.* **2020**, *30*, 605–606. [[CrossRef](#)]
9. Nakuçi, M.; Bassukas, I.D. Office-based treatment of basal cell carcinoma with immunocryosurgery: Feasibility and efficacy. *Acta Dermatovenerol. Alp. Panon. Adriat.* **2013**, *22*, 35–38.
10. Gaitanis, G.; Bassukas, I.D. Immunocryosurgery—An effective combinational modality for Bowen's disease. *Dermatol. Ther.* **2016**, *29*, 334–337. [[CrossRef](#)]
11. Tsironi, T.; Gaitanis, G.; Pappas, C.; Koutlas, V.; Dounousi, E.; Bassukas, I.D. Immunocryosurgery is a safe and feasible treatment for basal cell carcinoma and Bowen disease in renal transplant recipients. *Dermatol. Ther.* **2022**, *35*, e15405. [[CrossRef](#)] [[PubMed](#)]

12. Oro-Ayude, M.; Gonzalez-Sixto, B.; Faraldo-Lorenzo, J.M.; Feal, C.; Flórez, A. Periocular lentigo maligna successfully treated with immunocryosurgery. *Dermatol. Ther.* **2021**, *34*, e14561. [[CrossRef](#)] [[PubMed](#)]
13. Matas-Nadal, C.; Sòria, X.; García-de-la-Fuente, M.R.; Huerva, V.; Ortega, E.; Vilardell, F.; Gatiús, S.; Casanova, J.M.; Martí, R.M. Immunocryosurgery as monotherapy for lentigo maligna or combined with surgical excision for lentigo maligna melanoma. *J. Dermatol.* **2018**, *45*, 564–570. [[CrossRef](#)]
14. Voulgari, P.V.; Gaitanis, G.; Markatseli, T.E.; Kempf, W.; Bassukas, I.D. In transit recurrence of merkel cell carcinoma associated with polyarthritis effectively treated with immunocryosurgery. *Acta Derm. Venereol.* **2014**, *94*, 739–740. [[CrossRef](#)] [[PubMed](#)]
15. Gaitanis, G.; Vlachos, C.; Bassukas, I.D. Individualized, Adjuvant-Intensified Immunocryosurgery for the Treatment of Squamous Cell Carcinoma in the Oldest Old: An Exploratory Case Series. *Actas Dermosifiliogr.* **2022**, *113*, 750–753. [[CrossRef](#)]
16. Gaitanis, G.; Kalogeropoulos, C.D.; Bassukas, I.D. Cryosurgery during Imiquimod (Immunocryosurgery) for Periocular Basal Cell Carcinomas: An Efficacious Minimally Invasive Treatment Alternative. *Dermatology* **2016**, *232*, 17–21. [[CrossRef](#)]
17. Ceder, H.; Grönberg, M.; Paoli, J. Mohs micrographic surgery for primary versus recurrent or incompletely excised facial high-risk basal cell carcinomas. *Acta Derm.-Venereol.* **2021**, *101*, adv00381. [[CrossRef](#)]
18. Trakatelli, M.; Morton, C.; Nagore, E.; Ulrich, C.; Del Marmol, V.; Peris, K.; Basset-Seguín, N. Update of the European guidelines for basal cell carcinoma management. *Eur. J. Dermatol.* **2014**, *24*, 312–329. [[CrossRef](#)]
19. Linos, E.; Schroeder, S.A.; Chren, M.M. Potential overdiagnosis of basal cell carcinoma in older patients with limited life expectancy. *J. Am. Med. Assoc.* **2014**, *312*, 997–998. [[CrossRef](#)]
20. Gaitanis, G.; Nomikos, K.; Vava, E.; Alexopoulos, E.C.; Bassukas, I.D. Immunocryosurgery for basal cell carcinoma: Results of a pilot, prospective, open-label study of cryosurgery during continued imiquimod application. *J. Eur. Acad. Dermatol. Venereol.* **2009**, *23*, 1427–1430. [[CrossRef](#)]
21. Gaitanis, G.; Nomikos, K.; Vlachos, C.; Bassukas, I.D. Immunocryosurgery for patients with therapeutically challenging basal cell carcinomas: Report of two representative cases. *J. Dermatol. Treat.* **2012**, *23*, 70–71. [[CrossRef](#)] [[PubMed](#)]
22. Bath-Hextall, F.; Ozolins, M.; Armstrong, S.J.; Colver, G.B.; Perkins, W.; Miller, P.S.J.; Williams, H.C. Surgical excision versus imiquimod 5% cream for nodular and superficial basal-cell carcinoma (SINS): A multicentre, non-inferiority, randomised controlled trial. *Lancet Oncol.* **2014**, *15*, 96–105. [[CrossRef](#)]
23. Peris, K.; Fargnoli, M.C.; Garbe, C.; Kaufmann, R.; Bastholt, L.; Seguin, N.B.; Bataille, V.; Del Marmol, V.; Dummer, R.; Harwood, C.A.; et al. Diagnosis and treatment of basal cell carcinoma: European consensus-based interdisciplinary guidelines. *Eur. J. Cancer* **2019**, *118*, 10–34. [[CrossRef](#)] [[PubMed](#)]
24. Peris, K.; Licitra, L.; Ascierto, P.A.; Corvò, R.; Simonacci, M.; Picciotto, F.; Gualdi, G.; Pellacani, G.; Santoro, A. Identifying locally advanced basal cell carcinoma eligible for treatment with vismodegib: An expert panel consensus. *Future Oncol.* **2015**, *11*, 703–712. [[CrossRef](#)] [[PubMed](#)]
25. Sekulic, I.A.; Yoo, S.; Kudchadkar, R.; Guillen, J.; Rogers, G.; Chang, A.L.S.; Guenther, S.; Raskin, B.; Dawson, K.; Mun, Y.; et al. Real-world assessment and treatment of locally advanced basal cell carcinoma: Findings from the RegiSONIC disease registry. *PLoS ONE* **2022**, *17*, e0262151. [[CrossRef](#)]
26. Bichakjian, C.K.; Olencki, T.; Aasi, S.Z.; Alam, M.; Andersen, J.S.; Berg, D.; Bowen, G.M.; Cheney, R.T.; Daniels, G.A.; Glass, L.F.; et al. Basal Cell Skin Cancer, Version 1.2016, NCCN Clinical Practice Guidelines in Oncology. *J. Natl. Compr. Cancer Netw.* **2016**, *14*, 574–597. [[CrossRef](#)]
27. Pellegrini, C.; Maturo, M.; Di Nardo, L.; Ciciarelli, V.; Gutiérrez García-Rodrigo, C.; Fargnoli, M.C. Understanding the Molecular Genetics of Basal Cell Carcinoma. *Int. J. Mol. Sci.* **2017**, *18*, 2485. [[CrossRef](#)]
28. Lomas, A.; Leonardi-Bee, J.; Bath-Hextall, F. A systematic review of worldwide incidence of nonmelanoma skin cancer. *Br. J. Dermatol.* **2012**, *166*, 1069–1080. [[CrossRef](#)]
29. Schön, M.P.; Schön, M. Imiquimod: Mode of action. *Br. J. Dermatol.* **2007**, *157* (Suppl. S2), 8–13. [[CrossRef](#)]
30. Hanna, E.; Abadi, R.; Abbas, O. Imiquimod in dermatology: An overview. *Int. J. Dermatol.* **2016**, *55*, 831–844. [[CrossRef](#)]