Journal Pre-proof



Growing fat tissue after grafting for dural sealing

Basil Erwin Grüter, MD, Lukas Andereggen, MD

PII: S1878-8750(22)01634-5

DOI: https://doi.org/10.1016/j.wneu.2022.11.082

Reference: WNEU 19798

To appear in: *World Neurosurgery*

Received Date: 17 November 2022

Accepted Date: 18 November 2022

Please cite this article as: Grüter BE, Andereggen L, Growing fat tissue after grafting for dural sealing, *World Neurosurgery* (2022), doi: https://doi.org/10.1016/j.wneu.2022.11.082.

Growing fat tissue after grafting for dural sealing

Basil Erwin Grüter, MD[1,2] and Lukas Andereggen, MD[1,3]

[1]Department of Neurosurgery, Kantonsspital Aarau, Aarau, Switzerland

[2] Institute of Neuroradiology, Kantonsspital Aarau, Aarau Switzerland

[3]Faculty of Medicine, University of Bern, Bern, Switzerland

Correspondence to:

Lukas Andereggen, MD

Department of Neurosurgery

Kantonsspital Aarau

5000 Aarau, Switzerland

Email: lukas.andereggen@ksa.com

Phone number: +41 62 838 66 90

Fax number: +41 62 838 66 29

Orcid ID: 0000-0003-1764-688X

Number of words: 235

Number of references: 5

Number of figures: 1

Number of tables: None

Disclosure: The authors report no disclosures.

Funding: No funding was received for this work.

Competing interests None.

Ethics approval: Ethical review and approval was not required. The patient provided written informed consent to participate in this study. This work is original and has not been published elsewhere nor is it currently under consideration for publication elsewhere.

Abstract

We report on a young patient with a growing retroauricular benign fat tissue tumour after juvenile fat grafting for dural sealing of a placed ventriculoperitoneal shunt. The clinical images indicates fat tissue rather than a cerebrospinal fluid (CSF) leak due to potential shunt malfunction suspected on plain radiography. Human adipose tissue is a source of stem cells that can replicate rather than undergo necrosis, in particular when transplanted during development.

Clinical Images

A man in his mid forties was referred by his barber for a growing painless retroauricular swelling. The patient's history was uneventful except for preterm birth with perinatal intraventricular hemorrhage. A ventriculoperitoneal shunt was subsequently placed due to progressive ventriculomegaly at the age of three years. [1] Nine years later, shunt revision became necessary, and the parietal burr hole was sealed with an abdominal fat graft to prevent cerebrospinal fluid (CSF) leakage. [2, 3]

Clinical examination revealed a soft, fluctuating resistance. Computer tomography showed a hypodense mass at 110 Hounsfield units, indicating fat tissue rather than a CSF leak (Fig.1 A) due to potential shunt malfunction on plain radiography (Fig.1 B). Surgery confirmed the presence of a benign fat tissue tumour (Fig.1 C) without shunt discontinuation.

growing fat tissue after infantile fat grafting for dural repair is an uncommon phenomenon. Human adipose tissue is a source of stem cells with neovascularization and angiogenesis being vital processes in the regenerative fate of fat tissue,[4] that might replicate rather than undergo necrosis, in particular when transplanted during development.[5, 6]

Figure 1 Parietal fat tissue tumor mimicking cerebrospinal fluid leakage

(**A**) Axial head CT-scan depicting a hypodense mass located over the burr hole comprising the shunt. Note that the signal density is similar to the adjacent subcutaneous fat tissue (arrow). (**B**) X-ray shows a radiolucent segment of the proximal shunt close to the retroauricular burr hole. (**C**) Macroscopic image of the encapsulated resected benign fat tissue

tumour (inlet) with histological confirmation of the adipose tissue (HE, 2x magnification). Note the numerous capillaries in between fat vacuoles.

References:

1. Gross BA, Jankowitz BT, Friedlander RM. Cerebral Intraparenchymal Hemorrhage: A Review. *JAMA.* 2019;321(13): 1295-1303. https://doi.org/10.1001/jama.2019.2413.
2. Isaacs AM, Ball CG, Sader N, et al. Reducing the risks of proximal and distal shunt failure in adult hydrocephalus: a shunt outcomes quality improvement study. *J Neurosurg.* 2021: 1-10. https://doi.org/10.3171/2021.2.JNS202970.
3. Pujari S, Kharkar S, Metellus P, Shuck J, Williams MA, Rigamonti D. Normal pressure hydrocephalus: long-term outcome after shunt surgery. *J Neurol Neurosurg Psychiatry.* 2008;79(11): 1282-1286. https://doi.org/10.1136/jnnp.2007.123620.
4. Hutchings G, Janowicz K, Moncrieff L, et al. The Proliferation and Differentiation of Adipose-Derived Stem Cells in Neovascularization and Angiogenesis. *Int J Mol Sci.* 2020;21(11). https://doi.org/10.3390/ijms21113790.
5. Jurgens WJ, Oedayrajsingh-Varma MJ, Helder MN, et al. Effect of tissue-harvesting site on yield of stem cells derived from adipose tissue: implications for cell-based therapies. *Cell Tissue Res.* 2008;332(3): 415-426. https://doi.org/10.1007/s00441-007-0555-7.
6. Prantl L, Eigenberger A, Brix E, Kempa S, Baringer M, Felthaus O. Adipose Tissue-Derived Stem Cell Yield Depends on Isolation Protocol and Cell Counting Method. *Cells.* 2021;10(5). https://doi.org/10.3390/cells10051113.

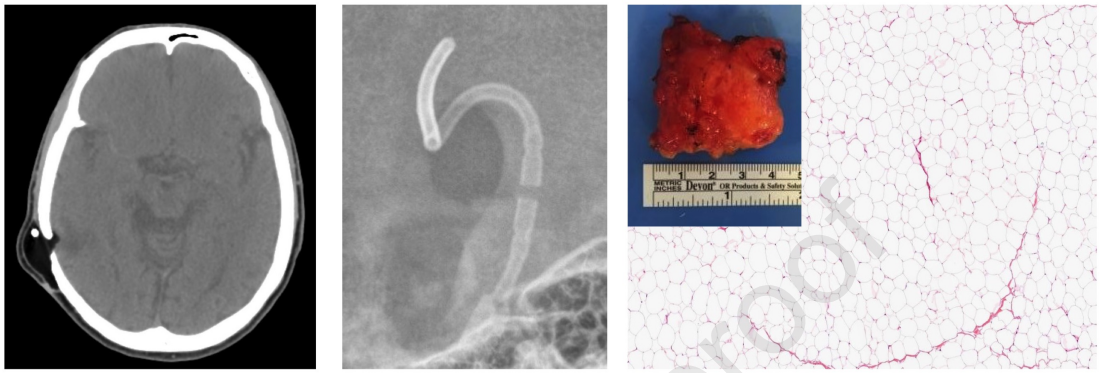

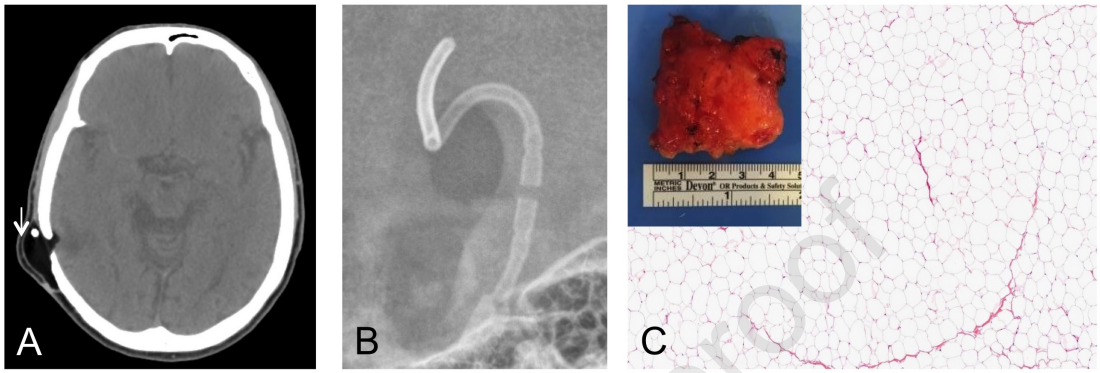

EINVERSTÄNDNISERKLÄRUNG / PATIENT CONSENT FORM

Deutsch

Ich, die unterzeichnende Person, gebe mein Einverständnis zur Verwendung von meiner Fallgeschichte für einen Artikel, welcher in einer medizinischen Fachzeitschrift publiziert wird.
Ich habe diese Einverständniserklärung mit Dr. med. B. Grüter besprochen, welche/r als einer der Autoren diesen Artikel verfasst. Der Autor ist verpflichtet, die Anonymisierung der Bildgebung und die Herkunft der Daten zu gewährleisten. Ich habe verstanden, dass alle medizinischen Fachpublikationen unter Umständen auch in gedruckter und digitaler Form (Internet) für ein breiteres Publikum (inkl. Journalisten oder Personen ohne medizinischen Hintergrund) einsehbar sein können ohne Hinweis auf die Person und dessen Herkunft der Daten.

English

I, the undersigned, give my consent for my case history to be published in an article in a medical journal.
I have discussed this consent form with _____, who is an author of this paper, and I understand that all healthcare journals may be available in both print and on the internet, and will be available to subscribers and sometimes a broader audience through marketing channels and other third parties. The author is obliged to assure the anonymization of imaging and the origin of data.
Therefore, anyone can read material published. This may include not only doctors and researchers but also journalists and members of the public. Tracing the origin of data is made impossible by anonymization.

Wieland
Erwin
6163

41162848
12.12.1986
M
Stationär
P
Tel.9637

Name Patient/in
Erwin Wieland

Name Unterzeichnender/Signed by (name)
E. Wieland

WICHTIG:
- *Falls der Patient/die Patientin unter 18 Jahre ist, muss dieses Formular von einem Elternteil oder Erziehungsberechtigten unterzeichnet werden*
- *Falls der Patient/die Patientin verstorben ist, muss das Formular von einem/einer Angehörigen unterzeichnet werden.*

NOTE:
- *If the patient is less than 18 years of age, this must be signed by their parent or legal guardian.*
- *If the patient is deceased, this must be signed by their next of kin.*

Datum/Date _____

Unterschrift/Signature _____

Beziehung zum Patienten, falls zutreffend / Relationship to patient, if applicable

_____

Author name Basil E. Grüter

Date 9.3.2021

Signed

V2_20210311_Fall /Case-Report

cerebrospinal fluid (CSF)

Growing lipoma after fat grafting for dural sealing

Disclosure: The authors report no disclosures.

Funding: No funding was received for this work.

Competing interests None.

Ethics approval: Ethical review and approval was not required. The patient provided written informed consent to participate in this study. This work is original and has not been published elsewhere nor is it currently under consideration for publication elsewhere.