

Monje Alberto (Orcid ID: 0000-0001-8292-1927)  
Roccuzzo Andrea (Orcid ID: 0000-0002-8079-0860)  
Wang Hom-Lay (Orcid ID: 0000-0003-4238-1799)

## Significance of buccal bone wall thickness on the fate of peri-implant hard and soft tissues: A systematic review

Alberto Monje<sup>\*†‡</sup>, Andrea Roccuzzo<sup>†</sup>, Daniel Buser<sup>¶</sup>, Hom-Lay Wang<sup>\*</sup>

\* Department of Periodontology and Oral Medicine, University of Michigan, Ann Arbor, MI, USA

‡ Department of Periodontology, Universitat Internacional de Catalunya, Barcelona, Spain

† Department of Periodontology, University of Bern, Bern, Switzerland

¶ School of Dental Medicine, University of Bern, Bern, Switzerland

Corresponding author:

Alberto Monje, DDS, MS, PhD

Department of Periodontology

Universitat Internacional de Catalunya

C/ Josep Trueta s/n

08195 - Sant Cugat del Vallès

Barcelona (Spain)

E-mail: amonjec@umich.edu

Telephone: +34935042000 / +34924203045

Word account: 4000

Running title: Critical buccal bone thickness

One-sentence summary: Thin baseline buccal bone is exposed to greater bone loss and mucosal recession

Conflicts of interest: The authors have no direct financial interests with the products and instruments listed in the paper.

This article has been accepted for publication and undergone full peer review but has not been through the copyediting, typesetting, pagination and proofreading process which may lead to differences between this version and the [Version of Record](#). Please cite this article as doi: [10.1111/clr.14029](https://doi.org/10.1111/clr.14029)

This article is protected by copyright. All rights reserved.

## Abstract

**Background:** The significance on the association between the peri-implant bucco-lingual dimension (BLD) at the stage of implant placement and the occurrence of biological and aesthetic complications is yet unknown.

**Material and methods:** Systematic screening of electronic sources was carried out to identify clinical and preclinical studies reporting on the baseline BLD and/or buccal bone thickness (BBT) values. A secondary objective was to assess the effect of simultaneous grafting at sites with deficient or no buccal bone wall (BBW) at baseline. The primary outcome variables were BBT, BLD and vertical bone loss (VBL) at re-evaluation. Moreover, radiographic, clinical and patient-reported outcome measures (PROMs) were evaluated.

**Results:** Overall, 12 clinical and 4 preclinical studies met the inclusion criteria. The clinical evidence demonstrated that during healing, dimensional changes occur in the alveolar bone and in the BBW that may compromise the integrity of bone around a dental implant. The preclinical evidence validated the fact that implants placed in the presence of thin BBW are more prone to exhibit major dimensional changes. Moreover, the clinical and preclinical data supported that in scenarios where dehiscence-type defects are left for spontaneous healing, greater VBL and mucosal recession (MR) together with the occurrence of biologic complications are expected. Furthermore, the augmentation of dehiscence-type defects is associated with hard and soft tissue stability.

**Conclusions:** Dimensional changes occur as a result of implant placement in healed ridges that may lead to VBL and MR. Thin BBW ( $\leq 2$ mm) are prone to exhibit major post-changes that may compromise the integrity of the buccal bone, biologic and esthetic complications.

## Introduction

Implant failures due to biological complications or unsatisfactory esthetic outcomes very often originate from implant malpositioning or errors during implant surgery (Monje, Galindo-Moreno, Tozum, Suarez-Lopez del Amo, & Wang, 2016). Interestingly, peri-implantitis and esthetic failures are more commonly noted on the buccal aspects (Monje & Nart, 2022). Implants placed in healed sites must have an adequate buccal bone wall thickness (BBT) to ensure that the implant is circumferentially embedded in vital bone at completion of bone healing. Once initial bone healing and remodeling has taken place, the entire micro-rough implant surface must be osseointegrated and circumferentially covered by vital bone (Spray, Black, Morris, & Ochi, 2000).

It is known that the outer layer of the buccal bone wall (BBW) is predominantly composed of cortical bone, which receives most of its vascular blood supply from the outside (the periosteum) and from the inside (the endosteum) (Roush, Howard, & Wilson, 1989). The central portion of the alveolar ridge is characterized by cancellous bone with a good blood supply. When a flap is raised to gain access for implant placement, the blood supply from the periosteum is interrupted. In addition, by inserting the implant into the prepared implant bed, the endosteal blood supply is interrupted as well, when the buccal bone wall is mainly comprised of cortical bone. The interruption of the blood supply from the outside as well as from the inside results in necrosis of the buccal bone. This process is called "avascular necrosis" (Mankin, 1992) and leads to vertical bone loss (VBL), most often on the buccal aspect of the implant (Monje et al., 2019). This contributes to exposure of the micro-rough implant surface into the peri-implant sulcus, and consequently into the oral cavity - facilitating the potential access of bacteria and the perpetuation of pathological conditions (Roux & Orcel, 2000), as well as mucosal recession that leads to an unpleasing aesthetic appearance (Monje et al., 2019). In consequence, the exposed micro-rough implant surface becomes a significant risk factor for biological complications as it can be set as the niche for pathogenic bacteria.

It has been suggested that dehiscence-like bone defects resulting from previous unsuccessful regenerative procedures (Schwarz, Sahm, & Becker, 2012) or during implant placement in pristine alveolar bone (Jung et al., 2017) may lead to instability of the soft and hard peri-implant tissues, resulting in a greater risk of developing biological complications (Monje et al., 2016). In fact, the presence of a thin BBW, often conditioned by the implant position (Grunder, Gracis, & Capelli, 2005), has been shown to be related to a greater risk of peri-implant bone resorption during initial healing -

Accepted Article

resulting in a greater susceptibility to develop unfavorable peri-implant conditions (Monje et al., 2019), including mucosal recession (Farronato et al., 2020), peri-implantitis (Monje et al., 2019) and eventually implant failure (Spray et al., 2000). In contrast, one clinical study reported that alveolar bone dimensions did not show a negative impact on clinical and radiographic outcomes at 3-year follow-up (Temmerman, Keestra, Coucke, Teughels, & Quirynen, 2015). Considering the above, the aim of the present systematic review was to shed light on the influence of critical buccal bone wall thickness (BBT) and the overall dimensions of alveolar bone upon soft and hard tissue stability, and to thus assess the need for simultaneous bone augmentation procedures according to the residual BBW. Findings derived from the present systematic review may assist in providing a clinical practice in implant dentistry more predictable in preventing esthetic and biological complications.

### Material and Methods

The study protocol was registered and received identification number CRD42021288604 in the PROSPERO International Prospective Register of Systematic Reviews, hosted by the National Institute for Health Research, University of York, Centre for Reviews and Dissemination.

**Focused question 1:** What is the peri-implant critical BBT that may compromise bone integration at the buccal aspect of dental implants placed in healed ridges?

### PECO question 1 for clinical research

- Patient: Partially or completely edentulous patients
- Exposure: Dental implants placed in native healed ridges exhibiting thin BBW or lack of BBW
- Comparison:
  - Comparison<sub>1</sub>: Thick BBW
  - Comparison<sub>2</sub>: Presence of BBW
- Outcome:
  - Outcome<sub>primary</sub>: VBL
  - Outcome<sub>secondary (1)</sub>: BBT, BLD changes and
  - Outcome<sub>secondary (2)</sub>: Peri-implant proximal bone level
  - Outcome<sub>secondary (3)</sub>: Peri-implant clinical parameters, clinical health and aesthetics
  - Outcome<sub>secondary (4)</sub>: Patient-reported outcome measures (PROMs)

**Focused question 2:** What is the effect in terms of dimensional, clinical and radiographic outcomes of simultaneous bone augmentation in scenarios below the critical BBT in healed ridges?

#### **PICO question 2 for clinical research**

- Patient: Partially or completely edentulous patients
- Intervention: Dental implants placed in native healed ridges exhibiting thin BBW or lack of BBW
- Comparison:
- Comparison<sub>3</sub>: Augmented BBW
- Outcome:
- Outcome<sub>primary</sub>: VBL
- Outcome<sub>secondary (1)</sub>: BBT, BLD changes and
- Outcome<sub>secondary (2)</sub>: Peri-implant proximal bone level
- Outcome<sub>secondary (3)</sub>: Peri-implant clinical parameters, clinical health and aesthetics
- Outcome<sub>secondary (4)</sub>: Patient-reported outcome measures (PROMs)

#### **Eligibility criteria**

Inclusion and exclusion criteria are listed in Table 1. It should be noted that whenever a study included implants placed immediately in fresh extraction sockets and healed sockets, only data from the latter were retrieved and included in the analysis.

#### **The Preferred Reporting Items for Systematic Reviews and Meta-Analyses (PRISMA)**

For describing and summarizing the results of our review, use was made of the 27-item PRISMA (Preferred Reporting Items for Systematic Reviews and Meta-Analyses) statement (Page et al., 2021).

#### **Search strategy**

Two independent reviewers (AM and AR) performed the manual search and read the title and abstract of the entries obtained from the literature search. After completing the screening process, both reviewers assessed the full-text version of potentially eligible studies and established a final article selection. Disagreements between the reviewers were resolved by open discussion. If no consensus could be reached, a third author

(HLW) was consulted. Any missing information that could contribute to the systematic review was requested from the corresponding author(s) via e-mail.

### **Information sources**

An electronic search of three databases (MEDLINE via PubMed, the Cochrane Library of the Cochrane Collaboration and the New York Academy of Medicine Grey Literature) was conducted for studies published up to November 2021 (included), without language or year restrictions. The search strategy combined MeSH terms and text words with Boolean operators (OR, AND) filtered by “humans” and “animals” and sorted according to the most recent publications. For the PubMed database, the search terms applied were the following: (dental implant[MeSH Terms]) OR (abutment, dental[MeSH Terms])) OR (dental implantation, osseointegrated[MeSH Terms])) AND (implantation, osseointegrated dental[MeSH Terms])) OR (alveolar bone dimension[Title/Abstract])) OR (buccal bone[Title/Abstract])) OR (buccal bone thickness[Title/Abstract])) OR (critical buccal bone[Title/Abstract])) OR (facial bone[Title/Abstract])) AND (facial bone thickness[Title/Abstract])) AND (bone regeneration[MeSH Terms])) OR (bone augmentation[Title/Abstract])) OR (guided bone regeneration[Title/Abstract])) OR (bone reconstruction[Title/Abstract])) AND (bone dehiscence[Title/Abstract])) OR (alveolar bone loss[MeSH Terms]) ) OR (buccal bone level[Title/Abstract])) OR (facial bone level[Title/Abstract])) OR (peri-implant condition[Title/Abstract])) OR (peri-implant health[Title/Abstract])) OR (peri-implantitis[Title/Abstract])). In turn, the Cochrane database and the Grey Literature Database were screened for unpublished papers in the New York Academy of Medicine in accordance with the AMSTAR checklist. The list of references of the included studies and related review articles were further screened to check for additional relevant studies.

### **Data extraction**

The following data were extracted and recorded in duplicate by two independent reviewers (AM and AR): 1) citation and year of publication; 2) experimental group; 3) sample size; 4) BBT and/or BLD at baseline and at re-assessment; 5) method of assessment; 6) timing of assessment; 6) clinical and radiographic outcomes and; 7) take home message

### **Risk of bias in individual studies**

Methodological quality of the included observational studies (i.e., case series, prospective studies) was assessed based on the Newcastle-Ottawa Quality Assessment Scale for Cohort studies (Wells GA 2014) while for RCTs, the Risk of Bias 2.0. tool was

adopted (Sterne et al., 2019). With respect to animal studies, the SYRCLE's risk of bias tool was used (Hooijmans et al., 2014).

## Results

The PRISMA flowchart for literature selection is depicted in Figure 1. In summary, 1700 records were identified after duplicates were removed. Ninety of these records were assessed for full-text. One more article was identified screening the references from included papers. Overall, 16 were included in the qualitative synthesis. Of these, 12 were human studies (Barone, Toti, Quaranta, Derchi, & Covani, 2015; Cardaropoli, Lekholm, & Wennstrom, 2006; Covani, Bortolaia, Barone, & Sbordone, 2004; Farronato et al., 2020; Jung et al., 2017; Li Manni et al., 2020; Marconcini et al., 2018; Nohra et al., 2018; Oda et al., 2021; Schwarz et al., 2012; Spray et al., 2000; Temmerman et al., 2015), while 4 were preclinical studies (G. Baffone et al., 2015; Bengazi et al., 2014; Monje et al., 2019; Vignoletti et al., 2019). The most frequent reason for exclusion based on the full-text evaluation was no baseline dimensional data or missing information (n=41) (Table 2). The heterogeneity of the sample across the included studies precluded the conduction of meta-analyses.

## Study and sample characteristics

### *Clinical studies (Table 3)*

The dominant study design was the prospective cohort (PC) (Cardaropoli et al., 2006; Covani et al., 2004; Farronato et al., 2020; Nohra et al., 2018; Schwarz et al., 2012; Spray et al., 2000; Temmerman et al., 2015), followed by the randomized clinical trial (RCT) (Barone et al., 2015; Jung et al., 2017; Li Manni et al., 2020; Marconcini et al., 2018). Only one retrospective cohort (RC) study (Oda et al., 2021) was included. Overall, 3237 sites (implants) were included and evaluated. The vast majority of the studies tested dimensional changes under spontaneous healing, while two studies (Jung et al., 2017; Schwarz et al., 2012) further tested simultaneous guided bone regeneration (GBR) on deficient ridges. Moreover, two studies (Barone et al., 2015; Marconcini et al., 2018) compared alveolar bone changes according to the insertion torque recorded during implant placement. One study (Nohra et al., 2018) explored the effect of implant torque and BBT on bone remodeling. Li Manni et al. (Li Manni et al., 2020) evaluated two different implant macro-designs. All the articles except one provided the BBT as baseline parameter. Covani et al. (Covani et al., 2004) reported the baseline BLD. One PC study (Temmerman et al., 2015) grafted only when dehiscences or fenestrations were noted. Caliper, periodontal probe and cone-beam computed tomography (CBCT) were the methods used to assess the alveolar bone dimension at baseline.

Seven studies assessed the radiographic outcome (Barone et al., 2015; Cardaropoli et al., 2006; Jung et al., 2017; Li Manni et al., 2020; Marconcini et al., 2018; Nohra et al., 2018; Temmerman et al., 2015) - 5 of them reporting by means of periapical radiographs (Barone et al., 2016; Cardaropoli et al., 2006; Jung et al., 2017; Marconcini et al., 2018; Temmerman et al., 2015) and 2 using CBCT (Li Manni et al., 2020; Nohra et al., 2018). Furthermore, 5 studies reported clinical outcomes at latest follow-up assessment (Barone et al., 2015; Farronato et al., 2020; Jung et al., 2017; Marconcini et al., 2018; Schwarz et al., 2012). The length of study periods ranged from 4-72 months. Only one study described patient-reported outcomes (PROMs) (Li Manni et al., 2020).

#### *Preclinical studies (Table 4)*

The preclinical model testing the influence of the BBT on the fate of the peri-implant hard and soft tissues was the canine model in all the studies included. Overall, 152 sites (implants) were included and evaluated. Spontaneous healing was the most reported intervention (G. Baffone et al., 2015; Bengazi et al., 2014; Monje et al., 2019; Vignoletti et al., 2019), while one study further assessed experimental peri-implantitis using a ligature-induced model (Monje et al., 2019). Baffone et al. (G. Baffone et al., 2015) evaluated the influence of ridge width and abutment width upon the alveolar dimensional changes. Bengazi et al. (Bengazi et al., 2014) analyzed the influence of the anatomical site (molar/premolar) and the presence/absence of peri-implant keratinized mucosa upon the alveolar changes. Monje et al. (Monje et al., 2019) in turn evaluated the influence of BBT ( $\geq 1.5$  mm versus  $< 1.5$  mm) upon VBL of the BBW. Vignoletti et al. (Vignoletti et al., 2019) analyzed spontaneous healing in two early stages (2 and 8 weeks of follow-up). Two studies (G. Baffone et al., 2015; Bengazi et al., 2014) used calipers to measure the alveolar dimension at baseline, one study (Monje et al., 2019) used a tracking system, and another study (Vignoletti et al., 2019) used a periodontal probe. All the studies performed histological analysis at latest follow-up. Spontaneous healing was assessed over a range of 2-12 weeks, though an arm of one study (Monje et al., 2019) evaluated the dimensional changes in an experimentally induced peri-implantitis model at 5 months follow-up.

#### **Influence of baseline BLD upon BLD changes**

##### *Clinical studies*

Only two studies (Covani et al., 2004; Temmerman et al., 2015) reported on the baseline alveolar bone dimension, and only one of them documented the alveolar bone changes. Covani et al. (Covani et al., 2004) demonstrated that after an average of four months after implant placement, the BLD was reduced by about 3 mm. None of the studies reported on the BBT changes.



### *Preclinical studies*

Only one study assessed the BLD changes at baseline. Baffone et al. (G. Baffone et al., 2015) showed that the narrower the baseline BLD, the thinner the BBW after three months of follow-up. Thus, implants installed in regular-sized alveolar ridges exhibited greater horizontal bone loss when compared to implants installed in narrower ridges. However, lesser vertical buccal bony crestal resorption was recorded compared to implants installed in reduced alveolar ridges.

### **Influence of baseline BLD upon clinical and radiographic outcomes**

#### *Clinical studies*

No clinical study reported on the integrity of the BBW or the BBT using three-dimensional radiographic techniques. Only one study examined the radiographic findings (Temmerman et al., 2015), documenting a mean radiographic peri-implant marginal bone loss of approximately 0.8 mm (mean from mesial and distal linear measurements) at three years of follow-up with implants placed in narrow alveolar crests (4.5 mm).

#### *Preclinical studies*

None of the preclinical studies reported on the clinical or radiographic outcomes.

### **Influence of baseline BLD upon biological complications**

#### *Clinical studies*

None of the clinical studies reported on BLD and its association to biological complications.

#### *Preclinical studies*

None of the preclinical studies reported on the occurrence of biological complications.

### **Influence of baseline BLD upon PROMs**

No clinical study assessed the association between BLD and PROMs.

### **Influence of BBT upon buccal bone changes**

#### *Clinical studies*

All the included studies except one (Covani et al., 2004) reported on baseline BBT. Mean BBW ranged from 0 mm (Jung et al., 2017; Schwarz et al., 2012) (dehiscence-like defect) to 1.84 mm (Spray et al., 2000). Few studies presented ranges instead of mean values (Barone et al., 2016; Farronato et al., 2020; Marconcini et al., 2018; Nohra et al., 2018; Temmerman et al., 2015). Overall, 7 studies provided data referring to VBL or BBT

at re-assessment (Cardaropoli et al., 2006; Jung et al., 2017; Li Manni et al., 2020; Nohra et al., 2018; Oda et al., 2021; Schwarz et al., 2012; Spray et al., 2000). Dimensional changes were noted in BBW ranging from approximately 0.3 mm to approximately 1.75 mm. Spray et al., in a large sample size study, showed that whenever  $\geq 1.8$  mm of BBW was present during implant placement, no VBL occurred (which demonstrates the integrity of the BBW), while in thinner BBW ( $< 1.8$  mm) assessed in the implant placement stage, a rising tendency was evidenced towards greater VBL values (Spray et al., 2000). Nohra et al. showed that implants presenting BBT  $< 2$  mm at baseline exhibited 8x greater VBL (2.34 mm vs. 0.31 mm) when compared to implants displaying BBT  $\geq 2$  mm (Nohra et al., 2018). One study (Jung et al., 2017) further demonstrated progressive VBL of 0.17 mm when a dehiscence-like defect of 3.2 mm was left for spontaneous non-assisted healing.

#### *Preclinical studies*

Two studies (Bengazi et al., 2014; Vignoletti et al., 2019) reported on the mean baseline BBT, while one study (Monje et al., 2019) clustered this variable into ranges. Mean BBT ranged from 0.9 mm (Bengazi et al., 2014) to 2.29 mm (Vignoletti et al., 2019). All the included studies documented VBL at re-assessment, while two studies (Bengazi et al., 2014; Vignoletti et al., 2019) reported BBT at re-assessment (range from approximately 0.1 mm to approximately 1.3 mm). Data from three studies (Bengazi et al., 2014; Monje et al., 2019; Vignoletti et al., 2019) demonstrated that VBL occurs regardless of the baseline BBT over a range of approximately 0.3 mm to approximately 4 mm. Data from one study (Monje et al., 2019) showed that on average, a baseline BBW  $< 1.5$  mm is exposed to approximately 4 mm of VBL under spontaneous healing, while in scenarios where BBW is  $\geq 1.5$  mm, VBL is limited to about 0.1 mm. This tendency was sustained in experimentally-induced peri-implantitis, showing a difference of approximately 0.9 mm in favor of BBW  $\geq 1.5$  mm. One study (G. Baffone et al., 2015) that did not report baseline BBT, found that narrower alveolar ridges tended to have thinner BBW at re-entry.

#### **Influence of baseline BBT upon clinical and radiographic outcomes**

##### *Clinical studies*

Overall, 5 studies (Barone et al., 2016; Farronato et al., 2020; Jung et al., 2017; Marconcini et al., 2018; Schwarz et al., 2012) reported on the clinical parameters, with mucosal recession (MR) being the most frequently documented parameter. No notable differences were observed in probing pocket depth (PPD) according to baseline BBT or to baseline vertical bone defect in dehiscence-type defects. In contrast, bleeding on probing was seen to increase in deeper vertical bone defects in dehiscence-type

defects. Mucosal recession (MR) was significantly increased in the presence of thinner BBT or deeper vertical bone defects in dehiscence-type defects. In turn, 7 studies (Barone et al., 2016; Cardaropoli et al., 2006; Jung et al., 2017; Li Manni et al., 2020; Marconcini et al., 2018; Nohra et al., 2018; Temmerman et al., 2015) further reported on marginal bone level (MBL) using radiographic analyses. The MBL values ranged from 0.2 to 1.9 mm under spontaneous healing. No comparisons could be made, due to the heterogeneity of the groups. Interestingly, Nohra et al. showed that implants presenting BBT <2mm at baseline exhibited 10x greater MBL (0.36 mm vs. 0.03 mm), respectively, when compared to implants displaying BBT  $\geq$ 2mm (Nohra et al., 2018)

#### *Preclinical studies*

Only one study (Monje et al., 2019) examined the clinical and radiographic parameters in experimental ligature-induced peri-implantitis. Greater PPD, MR, sulcular bleeding index (mSBI) and suppuration were noted under a baseline BBW < 1.5 mm when compared to BBW  $\geq$  1.5 mm. Mean bone loss was approximately 5 mm in both groups.

### **Influence of baseline BBT upon biological complications**

#### *Clinical studies*

None of the clinical studies reported on BBT and its association to biological complications.

#### *Preclinical studies*

One study (Monje et al., 2019) examined the progression of peri-implantitis in an experimental model. In general terms, a more acute inflammatory condition together with MR was noted in BBW < 1.5 mm.

### **Influence of baseline BBT upon PROMs**

A single study (Li Manni et al., 2020) noted no difference in PROMs according to the type of implant or the baseline BBT.

### **Influence of bone regeneration upon the buccal bone changes**

#### *Clinical studies*

One study (Jung et al., 2017) showed that VBL was significantly increased at 6 months of follow-up under conditions of spontaneous healing when compared to simultaneous bone regeneration.

#### *Preclinical studies*

No preclinical study evaluated the impact of bone regeneration upon buccal bone changes.

### **Influence of bone regeneration upon the clinical and radiographic outcomes**

#### *Clinical studies*

A single study (Jung et al., 2017) demonstrated greater PPD (approximately 0.3 mm), MR (approximately 0.3 mm) and MBL (approximately 0.3 mm) when spontaneous healing was applied in dehiscence-type defects compared to augmented sites.

#### *Preclinical studies*

No preclinical study explored the impact of bone regeneration upon the clinical and radiographic outcomes of augmented sites.

### **Influence of bone regeneration upon biological complications**

#### *Clinical studies*

One study (Schwarz et al., 2012) showed that the larger the dehiscence-type defect after regeneration, the greater the risk of biological complications (i.e., peri-implant mucositis) at four years of follow-up.

#### *Preclinical studies*

No preclinical study explored the impact of bone regeneration upon the occurrence of biological complications.

### **Risk of bias**

Risk of bias for clinical and preclinical studies are presented in supplementary tables (supplementary table t1, 2 and 3). In summary, the 4 RCTs, evaluated with the Risk of Bias 2.0. tool, were scored at "some concerns" of bias. When considering the additional 8 clinical non-RCTs, based on the COHORT version of the Newcastle-Ottawa Scale, 5 studies were graded at "high risk" of bias (3 to 6 stars) and 3 studies (8 stars) were scored at "low risk" of bias. Finally, with respect to the 4 animal studies included, 2 of them were scored "low" and 2 "unclear" risk of bias.

### **Discussion**

#### *Main findings*

Given the frequency of biological and esthetic complications in implant dentistry associated to buccal bone resorption, the question to be addressed is: What is the minimum BBT required to secure favorable outcomes conditioned to the dimensional

changes after implant placement? The present systematic review yielded the following findings: (1) Clinical evidence indicated that increased risk of dimensional changes seem to occur in scenarios with reduced BBW (< 2 mm); (2) Preclinical evidence validated the fact that implants placed in the presence of thin BBW (< 2 mm) are more prone to exhibit major dimensional changes; (3) Clinical and preclinical data indicated that in scenarios where dehiscence-type defects are left to heal spontaneously, greater VBL and MR together with the occurrence of biological and esthetic complications are to be expected; (4) In a ligature-induced peri-implantitis model, scenarios involving a thin BBW (< 1.5 mm) at baseline were characterized by progression of the disease with more mucosal inflammation, MR and VBL when compared to thick BBW; and (5) The augmentation of dehiscence-type defects is associated to hard and soft tissue stability. However, the present systematic review (6) failed to identify a specific threshold for guaranteeing residual alveolar bone in the buccal wall after implant placement. Nonetheless, (7) it seems that preclinical and clinical evidence points towards BBT < 1.5-2 mm tended to show greater VBL and BBT reduction.

#### *Findings from clinical studies*

Clinical data demonstrated changes in BBW after implant placement in healed ridges over a range of approximately 0.3-1.75 mm during up to 72 months of follow-up, with changes in the BLD of approximately 3 mm at 6 months of follow-up. Moreover, it was shown that completely intact BBW was guaranteed in scenarios that presented  $\geq 1.8$  mm at implant placement (Spray et al., 2000). On the other hand, scenarios characterized by approximately 1.2 mm during initial examination displayed > 3 mm of VBL (Spray et al., 2000). Nohra et al. showed that implants presenting BBT < 2 mm at baseline exhibited 8x and 10x greater VBL (2.34 mm vs. 0.31 mm) and MBL (0.36 mm vs. 0.03 mm), respectively, when compared to implants displaying BBT  $\geq 2$  mm (Nohra et al., 2018). It is remarkable however that in sub-crestal implants placed in reduced BLD (< 4.5 mm), implant therapy can yield solid outcomes with minimal peri-implant bone loss as determined by periapical radiographs (Temmerman et al., 2015). Nonetheless, it should be noted that this study did not evaluate VBL at the buccal aspect during re-examination or assess the clinical parameters during the study period. Moreover, early dimensional changes yielded minimal changes in the posterior maxilla (Li Manni et al., 2020). In fact, confounders other than BBT could further impact upon the dimensional changes. For instance, the shape of the edentulous ridge dictates that the more apical the BLD is examined in a cross-sectional view, the wider it is when compared to the most coronal location, since it follows a divergent morphology (H. Chen, Liu, Hu, Wu, & Gu, 2021). This strategy may assist in compensating for the thin BBW at the most coronal

aspect of the ridge. In turn, the anatomical area also may play a relevant role. The mandibular process is predominantly composed of cortical bone, which is poorly vascularized, while the maxillary bone is more cancellous and richer in blood supply. In fact, the thickness of the cortical layer at the coronal aspect of the mandibular ridge is approximately 1.4 mm (Chatvaratthana, Thaworanunta, Seriwatanachai, & Wongsirichat, 2017), versus approximately 2 mm at 3 mm below the crest in the molar area (Katranji, Misch, & Wang, 2007) - being significantly thinner in the edentulous maxilla (Katranji et al., 2007). Moreover, Lindhe et al. showed that the cortical crest was wider in the mandible than in the maxilla, and widest in the symphysis region of the mandible. Further, it was demonstrated that the proportion of bone marrow was greater in the maxilla than in the mandible (Lindhe et al., 2013). Hence, it is hypothesized that the thickness of the cortical bone may dictate the extent of the remodeling process, being more critical in the mandibular anterior than in the posterior maxillary ridges.

Simultaneous augmentation was seen to mitigate dimensional changes, VBL, MR and biological complications. One RCT (Jung et al., 2017) explored soft and hard tissue changes of dehiscence-type defects left for spontaneous healing and simultaneous horizontal bone augmentation using GBR. In fact, simultaneously grafted sites showed a significant gain in vertical bone, while non-grafted sites exhibited progressive VBL and greater MR. A four-year PC study (Schwarz et al., 2012) showed that successful lateral regeneration procedures during implant placement that secure complete buccal bone (BBT = 0.8 mm) are less prone to experience biological complications during the study period (4-year follow-up). Thus, data from these two studies highlight the role of simultaneous bone augmentation in scenarios characterized by a lack of buccal bone. The question of whether implants with thin BBW clinically benefit from regeneration was not addressed, however.

#### *Findings from preclinical studies*

In light of measurement errors derived from radiographic methods (i.e., CBCT) to determine peri-implant bone dimensions, preclinical studies were further considered. insight on the actual significance Preclinical data afforded insight to the influence of BBT upon the dimensional changes. It was seen that dimensional changes may compromise BLD and BBW in healed alveolar ridges after implant placement. A range from approximately 0.1-1.4 mm in BBT changes was noted. Vertical bone loss ranged from approximately 0.3-4 mm. It is relevant to note that narrower alveolar ridges have a greater tendency to show a thin BBW at re-assessment (G. Baffone et al., 2015). Data from one study (Monje et al., 2019) showed that a baseline BBW < 1.5 mm is exposed on

average to about 4 mm of VBL under spontaneous healing, while in scenarios where BBW is  $\geq 1.5$  mm, VBL is limited to approximately 0.1 mm. This tendency was sustained in experimentally-induced peri-implantitis, showing a difference of approximately 0.9 mm in favor of BBW  $\geq 1.5$  mm. Moreover, two studies (Bengazi et al., 2014; Vignoletti et al., 2019) reported changes in BBT at re-assessment ranging from approximately 0.2 mm to approximately 1.5 mm. The abovementioned study (Monje et al., 2019) further provided information on the soft and hard tissues during experimental peri-implantitis. In general lines, a more acute inflammatory condition together with greater VBL and MR were noted in scenarios where the initial BBW was  $< 1.5$  mm. Another confounder in relation to the influence of initial BBT upon dimensional changes was the nature of the alveolar mucosa (Bengazi et al., 2014). Greater VBL changes occurred when implants were surrounded by thin non-keratinized mucosa at the time of implant placement, in contrast to keratinized mucosa. Therefore, based on preclinical data, it seems that dimensional changes occur as a consequence of implant placement, and that major resorption that may compromise the integrity of bone along the buccal aspect of the implant may lead to more aggressive peri-implantitis.

#### *Understanding the biological mechanism behind these findings*

This systematic review evidenced the dimensional changes that occur after implant placement in healed alveolar ridges. This may reflect an avascular necrosis phenomenon as a consequence of damage to the alveolar bone (Chang, Greenspan, & Gershwin, 1993; Roux & Orcel, 2000). The alveolar process is composed of cortical bone at the outer aspect, whereas the central portion of the mandible is characterized by a more cancellous structure. The cortical bone receives its blood supply branched from the outside through blood vessels of the periosteum, and from the inside from the endosteum (Roush et al., 1989). Therefore, when an implant is inserted with an open-flap procedure, the blood supply from both sources is disrupted (Roux & Orcel, 2000). Avascular necrosis following implant placement is initiated 12 hours after disruption of the blood supply, when the hematopoietic cells that are particularly sensitive to low oxygen levels die. This event is followed by the death of bone cells such as osteocytes and osteoblasts, leading to more noticeable osteoclast activity (Mankin, 1992). In consequence, the blood supply might not be sufficient to repair the bone at the buccal aspect. In response, osteoclasts activated by the RANKL/RANK pathway and mediated by a transcription factor (nuclear factor of activated T cells) induce buccal bone resorption (Roux & Orcel, 2000). VBL together with buccal MR are thus attributable to this process. These changes may have a detrimental impact upon the integrity of the buccal bone and mucosal stability, compromising the functional and esthetic outcomes.

### *Clinical implications*

Considering that the clinical and preclinical data indicated that scenarios with an initial thin BBW ( $\leq 1.5$  mm) may experience major dimensional changes that can compromise the integrity of the buccal bone and/or the stability of the soft tissues, simultaneous bone augmentation is encouraged (Figure 2). This may gain further importance in the mandibular bone (Figure 3) and in scenarios lacking keratinized mucosa. Other graftless clinical strategies to compensate BBW in narrower ridges include slightly submerging bone-level implants using transmucosal abutments. This concept is not applicable to tissue-level implants, owing to the increased depth of the mucosal tunnel that may lead to mucosal inflammation (Chan, Pelekos, Ho, Cortellini, & Tonetti, 2019). The use of narrow-diameter implants (NDI) may be also a potential solution to approach situations of thin BBW. However, NDIs are mostly limited to premolar sites in both jaws and anterior implant sites in the mandible to achieve the desired emergence profile. For instance, the use of narrow-diameter bone-level implants in the posterior mandible may contribute to a convex emergence profile, which in turn may increase the risk of peri-implant biological complications (Katafuchi, Weinstein, Leroux, Chen, & Daubert, 2018). Another option to reduce the risk for an exposed micro-rough surface to the peri-implant sulcus is the utilization of a so-called hybrid design (HD) implant (Tarnow, 1993). A HD implant has by definition a micro-rough surface in the endo-osseous portion for improved bone anchorage, and a machined surface in the neck/shoulder area for the trans- and supra-crestal area to reduce the risk for biofilm colonization, and hence the development of biologic complications over time (Monje, Eick, Buser, & Salvi, 2021; Serrano, Sanz-Sanchez, Serrano, Montero, & Sanz, 2022). The essence and inspiration of all HD implants is the tissue-level implant by Straumann first utilized in 1986 (Sutter, Schroeder, & Buser, 1988). Long-term studies seem to document the increased risk for peri-implantitis for non-HD implants, when the micro-rough is exposed to the supra-crestal area (Derks et al., 2016; Windael, Collaert, De Buyser, De Bruyn, & Vervaeke, 2021). A 10-year study with 1482 implants showed an odds ratio for the development of periimplantitis of more than 5 for implants that exceeded an early bone loss of more than 0.5 mm during the first year of function. The overall incidence of periimplantitis was 11.8% on an implant level, on top of a failure rate of 5.26% (Windael et al., 2021). In contrast, a 10-year clinical with 511 tissue-level implants with an HD, the failure rate was at 1.2% and the prevalence of periimplantitis at 1.8% (Buser et al., 2012).

### *Limitations and recommendations for future research*

Due to the heterogeneity of the data (i.e., different methods of assessment and landmarks), no meta-analyses could be performed. Moreover, it must be highlighted



that conclusions are mainly derived from preclinical and non-randomized clinical trials. Therefore, cautiousness must be exercised when interpreting the findings. Based on deficiencies identified in this systematic review, there are several open questions which should be addressed with appropriate pre-clinical and clinical studies. Most important, the details of post-surgical bone resorption induced by avascular necrosis should be further examined with pre-clinical studies using sequential histologic analysis during the first 8 weeks of healing. This would allow a better understanding of the biology behind this phenomenon including information on the sequence and involved cells. Then, it is also of interest to explore the differences between implant sites in the maxilla and in the mandible, since differences in density of the BBW might result in different threshold values between thin and thick. Moreover, studies are needed to assess the impact of bone augmentation in scenarios characterized by a thin BBW, in order to gain insight into the influence of bone augmentation upon long-term soft and hard tissue stability.

### **Conclusions**

Dimensional changes occur as result of implant placement in healed ridges that may lead to VBL and MR. Thin BBW ( $\leq 2$ mm) are prone to exhibit major changes that may compromise the integrity of the buccal bone, biologic and esthetic complications. Hence, simultaneous bone augmentation of dehiscence-type defects or thin BBW may attenuate the buccal hard and soft tissue collapse that may jeopardize the long-term success and stability.

### **Acknowledgements**

The authors thank Simon S. Jensen (University of Copenhagen, Denmark) for his review and lead during the performance of the systematic review and manuscript preparation.

## References

- Abrahamsson, I., Berglundh, T., Linder, E., Lang, N. P., & Lindhe, J. (2004). Early bone formation adjacent to rough and turned endosseous implant surfaces. An experimental study in the dog. *Clin Oral Implants Res*, 15(4), 381-392. doi:10.1111/j.1600-0501.2004.01082.x
- Abrahamsson, I., Berglundh, T., Moon, I. S., & Lindhe, J. (1999). Peri-implant tissues at submerged and non-submerged titanium implants. *J Clin Periodontol*, 26(9), 600-607. doi:10.1034/j.1600-051x.1999.260907.x
- Abrahamsson, I., Berglundh, T., Wennstrom, J., & Lindhe, J. (1996). The peri-implant hard and soft tissues at different implant systems. A comparative study in the dog. *Clin Oral Implants Res*, 7(3), 212-219. doi:10.1034/j.1600-0501.1996.070303.x
- Abrahamsson, I., Welander, M., Linder, E., & Berglundh, T. (2014). Healing at implants placed in an alveolar ridge with a sloped configuration: an experimental study in dogs. *Clin Implant Dent Relat Res*, 16(1), 62-69. doi:10.1111/j.1708-8208.2012.00460.x
- Baffone, G., Lang, N. P., Pantani, F., Favero, G., Ferri, M., & Botticelli, D. (2015). Hard and soft tissue changes around implants installed in regular-sized and reduced alveolar bonyridges. An experimental study in dogs. *Clin Oral Implants Res*, 26(1), 96-101. doi:10.1111/clr.12306
- Baffone, G. M., Botticelli, D., Canullo, L., Scala, A., Beolchini, M., & Lang, N. P. (2012). Effect of mismatching abutments on implants with wider platforms--an experimental study in dogs. *Clin Oral Implants Res*, 23(3), 334-339. doi:10.1111/j.1600-0501.2011.02320.x
- Baffone, G. M., Botticelli, D., Pantani, F., Cardoso, L. C., Schweikert, M. T., & Lang, N. P. (2011). Influence of various implant platform configurations on peri-implant tissue dimensions: an experimental study in dog. *Clin Oral Implants Res*, 22(4), 438-444. doi:10.1111/j.1600-0501.2010.02146.x
- Barone, A., Alfonsi, F., Derchi, G., Tonelli, P., Toti, P., Marchionni, S., & Covani, U. (2016). The Effect of Insertion Torque on the Clinical Outcome of Single Implants: A Randomized Clinical Trial. *Clin Implant Dent Relat Res*, 18(3), 588-600. doi:10.1111/cid.12337
- Barone, A., Toti, P., Quaranta, A., Derchi, G., & Covani, U. (2015). The Clinical Outcomes of Immediate Versus Delayed Restoration Procedures on Immediate Implants: A Comparative Cohort Study for Single-Tooth Replacement. *Clin Implant Dent Relat Res*, 17(6), 1114-1126. doi:10.1111/cid.12225
- Becker, J., Ferrari, D., Herten, M., Kirsch, A., Schaer, A., & Schwarz, F. (2007). Influence of platform switching on crestal bone changes at non-submerged titanium implants: a histomorphometrical study in dogs. *J Clin Periodontol*, 34(12), 1089-1096. doi:10.1111/j.1600-051X.2007.01155.x
- Becker, K., Klitzsch, I., Stauber, M., & Schwarz, F. (2017). Three-dimensional assessment of crestal bone levels at titanium implants with different abutment microstructures and insertion depths using micro-computed tomography. *Clin Oral Implants Res*, 28(6), 671-676. doi:10.1111/clr.12860

- Bengazi, F., Botticelli, D., Favero, V., Perini, A., Urbizo Velez, J., & Lang, N. P. (2014). Influence of presence or absence of keratinized mucosa on the alveolar bony crest level as it relates to different buccal marginal bone thicknesses. An experimental study in dogs. *Clin Oral Implants Res*, 25(9), 1065-1071. doi:10.1111/clr.12233
- Beolchini, M., Lang, N. P., Ricci, E., Bengazi, F., Triana, B. G., & Botticelli, D. (2015). Influence on alveolar resorption of the buccal bony plate width in the edentulous ridge expansion (E.R.E.)--an experimental study in the dog. *Clin Oral Implants Res*, 26(1), 109-114. doi:10.1111/clr.12308
- Bozkaya, S., Uraz, A., Guler, B., Kahraman, S. A., & Turhan Bal, B. (2021). The stability of implants and microbiological effects following photobiomodulation therapy with one-stage placement: A randomized, controlled, single-blinded, and split-mouth clinical study. *Clin Implant Dent Relat Res*, 23(3), 329-340. doi:10.1111/cid.12999
- Bratu, E. A., Tandlich, M., & Shapira, L. (2009). A rough surface implant neck with microthreads reduces the amount of marginal bone loss: a prospective clinical study. *Clin Oral Implants Res*, 20(8), 827-832. doi:10.1111/j.1600-0501.2009.01730.x
- Buser, D., Janner, S. F., Wittneben, J. G., Bragger, U., Ramseier, C. A., & Salvi, G. E. (2012). 10-year survival and success rates of 511 titanium implants with a sandblasted and acid-etched surface: a retrospective study in 303 partially edentulous patients. *Clin Implant Dent Relat Res*, 14(6), 839-851. doi:10.1111/j.1708-8208.2012.00456.x
- Calvo-Guirado, J. L., Delgado Ruiz, R. A., Ramirez-Fernandez, M. P., Abboud, M., Janjic, B., & Mate Sanchez de Val, J. E. (2016). Histological and histomorphometric analyses of narrow implants, crestal and subcrestally placed in severe alveolar atrophy: a study in foxhound dogs. *Clin Oral Implants Res*, 27(4), 497-504. doi:10.1111/clr.12569
- Carcuac, O., Abrahamsson, I., Derks, J., Petzold, M., & Berglundh, T. (2020). Spontaneous progression of experimental peri-implantitis in augmented and pristine bone: A pre-clinical in vivo study. *Clin Oral Implants Res*, 31(2), 192-200. doi:10.1111/clr.13564
- Cardaropoli, G., Lekholm, U., & Wennstrom, J. L. (2006). Tissue alterations at implant-supported single-tooth replacements: a 1-year prospective clinical study. *Clin Oral Implants Res*, 17(2), 165-171. doi:10.1111/j.1600-0501.2005.01210.x
- Carmagnola, D., Araujo, M., Berglundh, T., Albrektsson, T., & Lindhe, J. (1999). Bone tissue reaction around implants placed in a compromised jaw. *J Clin Periodontol*, 26(10), 629-635. doi:10.1034/j.1600-051x.1999.261001.x
- Carmo Filho, L. C. D., Faot, F., Madruga, M. M., Marcello-Machado, R. M., Bordin, D., & Del Bel Cury, A. A. (2019). Effect of implant macrogeometry on peri-implant healing outcomes: a randomized clinical trial. *Clin Oral Investig*, 23(2), 567-575. doi:10.1007/s00784-018-2463-5
- Cesaretti, G., Lang, N. P., Salata, L. A., Schweikert, M. T., Gutierrez Hernandez, M. E., & Botticelli, D. (2015). Sub-crestal positioning of implants results in higher bony crest resorption: an experimental study in dogs. *Clin Oral Implants Res*, 26(12), 1355-1360. doi:10.1111/clr.12467
- Chacun, D., Lafon, A., Courtois, N., Reveron, H., Chevalier, J., Margossian, P., . . . Grosogoeat, B. (2021). Histologic and histomorphometric evaluation of new zirconia-based ceramic

- dental implants: A preclinical study in dogs. *Dent Mater*, 37(9), 1377-1389. doi:10.1016/j.dental.2021.06.010
- Chan, D., Pelekos, G., Ho, D., Cortellini, P., & Tonetti, M. S. (2019). The depth of the implant mucosal tunnel modifies the development and resolution of experimental peri-implant mucositis: A case-control study. *J Clin Periodontol*, 46(2), 248-255. doi:10.1111/jcpe.13066
- Chang, C. C., Greenspan, A., & Gershwin, M. E. (1993). Osteonecrosis: current perspectives on pathogenesis and treatment. *Semin Arthritis Rheum*, 23(1), 47-69.
- Chatvaratthana, K., Thaworanunta, S., Seriwatanachai, D., & Wongsirichat, N. (2017). Correlation between the thickness of the crestal and buccolingual cortical bone at varying depths and implant stability quotients. *PLoS One*, 12(12), e0190293. doi:10.1371/journal.pone.0190293
- Checchi, V., Felice, P., Zucchelli, G., Barausse, C., Piattelli, M., Pistilli, R., . . . Esposito, M. (2017). Wide diameter immediate post-extractive implants vs delayed placement of normal-diameter implants in preserved sockets in the molar region: 1-year post-loading outcome of a randomised controlled trial. *Eur J Oral Implantol*, 10(3), 263-278.
- Chen, H., Liu, Z., Hu, X., Wu, B., & Gu, Y. (2021). Comparison of mandibular cross-sectional morphology between Class I and Class II subjects with different vertical patterns: based on CBCT images and statistical shape analysis. *BMC Oral Health*, 21(1), 238. doi:10.1186/s12903-021-01591-3
- Chen, S. T., Darby, I. B., & Reynolds, E. C. (2007). A prospective clinical study of non-submerged immediate implants: clinical outcomes and esthetic results. *Clin Oral Implants Res*, 18(5), 552-562. doi:10.1111/j.1600-0501.2007.01388.x
- Cooper, L. F., De Kok, I. J., Rojas-Vizcaya, F., Pungpapong, P., & Chang, S. H. (2007). The immediate loading of dental implants. *Compend Contin Educ Dent*, 28(4), 216-225; quiz 226.
- Cooper, L. F., Reside, G., Stanford, C., Barwacz, C., Feine, J., Abi Nader, S., . . . McGuire, M. (2015). A multicenter randomized comparative trial of implants with different abutment interfaces to replace anterior maxillary single teeth. *Int J Oral Maxillofac Implants*, 30(3), 622-632. doi:10.11607/jomi.3772
- Covani, U., Bortolaia, C., Barone, A., & Sbordone, L. (2004). Bucco-lingual crestal bone changes after immediate and delayed implant placement. *J Periodontol*, 75(12), 1605-1612. doi:10.1902/jop.2004.75.12.1605
- Crespi, R., Toti, P., Covani, U., Crespi, G., & Menchini-Fabris, G. B. (2021). Clinical and Radiographic Evaluation of Modified Transalveolar Two-Step Osteotome-Mediated Localized Maxillary Sinus Elevation: A Retrospective Computed Tomography Study with a 3-Year Follow-up. *Int J Oral Maxillofac Implants*, 36(3), 553-560. doi:10.11607/jomi.8573
- da Silva Pereira, S. L., Sallum, A. W., Casati, M. Z., Caffesse, R. G., Weng, D., Nociti, F. H., Jr., & Sallum, E. A. (2000). Comparison of bioabsorbable and non-resorbable membranes in the treatment of dehiscence-type defects. A histomorphometric study in dogs. *J Periodontol*, 71(8), 1306-1314. doi:10.1902/jop.2000.71.8.1306

- Deporter, D. A., Watson, P. A., Pilliar, R. M., Howley, T. P., & Winslow, J. (1988). A histological evaluation of a functional endosseous, porous-surfaced, titanium alloy dental implant system in the dog. *J Dent Res*, *67*(9), 1190-1195. doi:10.1177/00220345880670090801
- Derks, J., Schaller, D., Hakansson, J., Wennstrom, J. L., Tomasi, C., & Berglundh, T. (2016). Effectiveness of Implant Therapy Analyzed in a Swedish Population: Prevalence of Peri-implantitis. *J Dent Res*, *95*(1), 43-49. doi:10.1177/0022034515608832
- Di Raimondo, R., Sanz-Esporrin, J., Martin, I. S., Vignoletti, F., Nunez, J., Munoz, F., . . . Sanz, M. (2021). Hard tissue volumetric and soft tissue contour linear changes at implants with different surface characteristics after experimentally induced peri-implantitis: an experimental in vivo investigation. *Clin Oral Investig*, *25*(6), 3905-3918. doi:10.1007/s00784-020-03720-8
- Duong, M., Mealey, B. L., Walker, C., Al-Harhi, S., Pihoda, T. J., & Huynh-Ba, G. (2020). Evaluation of healing at molar extraction sites with and without ridge preservation: A three-arm histologic analysis. *J Periodontol*, *91*(1), 74-82. doi:10.1002/JPER.19-0237
- Dursun, E., Tulunoglu, I., Canpinar, P., Uysal, S., Akalin, F. A., & Tozum, T. F. (2012). Are marginal bone levels and implant stability/mobility affected by single-stage platform switched dental implants? A comparative clinical study. *Clin Oral Implants Res*, *23*(10), 1161-1167. doi:10.1111/j.1600-0501.2011.02277.x
- Farronato, D., Pasini, P. M., Orsina, A. A., Manfredini, M., Azzi, L., & Farronato, M. (2020). Correlation between Buccal Bone Thickness at Implant Placement in Healed Sites and Buccal Soft Tissue Maturation Pattern: A Prospective Three-Year Study. *Materials (Basel)*, *13*(3). doi:10.3390/ma13030511
- Fenner, M., Vairaktaris, E., Stockmann, P., Schlegel, K. A., Neukam, F. W., & Nkenke, E. (2009). Influence of residual alveolar bone height on implant stability in the maxilla: an experimental animal study. *Clin Oral Implants Res*, *20*(8), 751-755. doi:10.1111/j.1600-0501.2008.01570.x
- Fienitz, T., Schwarz, F., Ritter, L., Dreiseidler, T., Becker, J., & Rothamel, D. (2012). Accuracy of cone beam computed tomography in assessing peri-implant bone defect regeneration: a histologically controlled study in dogs. *Clin Oral Implants Res*, *23*(7), 882-887. doi:10.1111/j.1600-0501.2011.02232.x
- Finelle, G., Papadimitriou, D. E. V., Souza, A. B., Katebi, N., Gallucci, G. O., & Araujo, M. G. (2015). Peri-implant soft tissue and marginal bone adaptation on implant with non-matching healing abutments: micro-CT analysis. *Clin Oral Implants Res*, *26*(4), e42-e46. doi:10.1111/clr.12328
- Fiorellini, J. P., Llobell, A., Norton, M. R., Sarmiento, H. L., Chang, Y. C., & Wada, K. (2020). Healed Edentulous Sites: Suitability for Dental Implant Placement, Need for Secondary Procedures, and Contemporary Implant Designs. *Int J Oral Maxillofac Implants*, *35*(5), 924-930. doi:10.11607/jomi.8215
- Gehrke, S. A., Braganca, L. K., Velasco-Ortega, E., & Calvo-Guirado, J. L. (2018). Evaluation of dimensional behavior of peri-implant tissues in implants immediately exposed or submerged in fresh extraction and healed sites: a histological study in dogs. *Int J Implant Dent*, *4*(1), 5. doi:10.1186/s40729-018-0120-z

- Glibert, M., Ostman, S., De Bruyn, H., & Ostman, P. O. (2018). The Influence of Initial Hard and Soft Tissue Dimensions on Initial Crestal Bone Loss of Immediately Loaded Dental Implants. *Int J Periodontics Restorative Dent*, 38(6), 873-878. doi:10.11607/prd.3458
- Grunder, U., Gracis, S., & Capelli, M. (2005). Influence of the 3-D bone-to-implant relationship on esthetics. *Int J Periodontics Restorative Dent*, 25(2), 113-119.
- Hooijmans, C. R., Rovers, M. M., de Vries, R. B., Leenaars, M., Ritskes-Hoitinga, M., & Langendam, M. W. (2014). SYRCLE's risk of bias tool for animal studies. *BMC Med Res Methodol*, 14, 43. doi:10.1186/1471-2288-14-43
- Hur, Y., Ogata, Y., Kim, D. W., Pham, C. M., Yoon, T. H., & Ogata, H. (2017). Bone Resorption During Submerged Healing After Guided Bone Regeneration: A Prospective Case Series. *Implant Dent*, 26(6), 820-825. doi:10.1097/ID.0000000000000686
- Jemt, T., & Lekholm, U. (2003). Measurements of buccal tissue volumes at single-implant restorations after local bone grafting in maxillas: a 3-year clinical prospective study case series. *Clin Implant Dent Relat Res*, 5(2), 63-70. doi:10.1111/j.1708-8208.2003.tb00185.x
- Jemt, T., & Lekholm, U. (2005). Single implants and buccal bone grafts in the anterior maxilla: measurements of buccal crestal contours in a 6-year prospective clinical study. *Clin Implant Dent Relat Res*, 7(3), 127-135. doi:10.1111/j.1708-8208.2005.tb00056.x
- Jonker, B. P., Wolvius, E. B., van der Tas, J. T., Tahmaseb, A., & Pijpe, J. (2020). Esthetics and Patient-Reported Outcomes of Implants Placed with Guided Bone Regeneration and Complete Native Bone: A Prospective Controlled Clinical Trial. *Int J Oral Maxillofac Implants*, 35(2), 406-414. doi:10.11607/jomi.7751
- Jung, R. E., Herzog, M., Wolleb, K., Ramel, C. F., Thoma, D. S., & Hammerle, C. H. (2017). A randomized controlled clinical trial comparing small buccal dehiscence defects around dental implants treated with guided bone regeneration or left for spontaneous healing. *Clin Oral Implants Res*, 28(3), 348-354. doi:10.1111/clr.12806
- Katafuchi, M., Weinstein, B. F., Leroux, B. G., Chen, Y. W., & Daubert, D. M. (2018). Restoration contour is a risk indicator for peri-implantitis: A cross-sectional radiographic analysis. *J Clin Periodontol*, 45(2), 225-232. doi:10.1111/jcpe.12829
- Katranji, A., Misch, K., & Wang, H. L. (2007). Cortical bone thickness in dentate and edentulous human cadavers. *J Periodontol*, 78(5), 874-878. doi:10.1902/jop.2007.060342
- Kim, D. G., Elias, K. L., Jeong, Y. H., Kwon, H. J., Clements, M., Brantley, W. A., . . . Han, J. S. (2016). Differences between buccal and lingual bone quality and quantity of peri-implant regions. *J Mech Behav Biomed Mater*, 60, 48-55. doi:10.1016/j.jmbbm.2015.12.036
- Koutouzis, T., Koutouzis, G., Gadalla, H., & Neiva, R. (2013). The effect of healing abutment reconnection and disconnection on soft and hard peri-implant tissues: a short-term randomized controlled clinical trial. *Int J Oral Maxillofac Implants*, 28(3), 807-814. doi:10.11607/jomi.3022
- Lee, J., Fiorini, T., Gamborena, I., Wenzel, B. A., Schupbach, P., Wikesjo, U. M., & Susin, C. (2016). Effect of Platform Shift/Switch on Crestal Bone Levels and Mucosal Profile Following Flapless Surgery and Crestal/Subcrestal Implant Placement. *Clin Implant Dent Relat Res*, 18(1), 73-81. doi:10.1111/cid.12243

- Lee, J., Yoo, J. M., Amara, H. B., Lee, Y. M., Lim, Y. J., Kim, H., & Koo, K. T. (2019). Bone healing dynamics associated with 3 implants with different surfaces: histologic and histomorphometric analyses in dogs. *J Periodontal Implant Sci*, 49(1), 25-38. doi:10.5051/jpis.2019.49.1.25
- Li Manni, L., Lecloux, G., Rompen, E., Aouini, W., Shapira, L., & Lambert, F. (2020). Clinical and radiographic assessment of circular versus triangular cross-section neck Implants in the posterior maxilla: A 1-year randomized controlled trial. *Clin Oral Implants Res*, 31(9), 814-824. doi:10.1111/clr.13624
- Lin, D., Li, Q., Li, W., & Swain, M. (2009). Dental implant induced bone remodeling and associated algorithms. *J Mech Behav Biomed Mater*, 2(5), 410-432. doi:10.1016/j.jmbbm.2008.11.007
- Lindhe, J., Bressan, E., Cecchinato, D., Corra, E., Toia, M., & Liljenberg, B. (2013). Bone tissue in different parts of the edentulous maxilla and mandible. *Clin Oral Implants Res*, 24(4), 372-377. doi:10.1111/clr.12064
- Mankin, H. J. (1992). Nontraumatic necrosis of bone (osteonecrosis). *N Engl J Med*, 326(22), 1473-1479. doi:10.1056/NEJM199205283262206
- Marconcini, S., Giammarinaro, E., Toti, P., Alfonsi, F., Covani, U., & Barone, A. (2018). Longitudinal analysis on the effect of insertion torque on delayed single implants: A 3-year randomized clinical study. *Clin Implant Dent Relat Res*, 20(3), 322-332. doi:10.1111/cid.12586
- Monje, A., Chappuis, V., Monje, F., Munoz, F., Wang, H. L., Urban, I. A., & Buser, D. (2019). The Critical Peri-implant Buccal Bone Wall Thickness Revisited: An Experimental Study in the Beagle Dog. *Int J Oral Maxillofac Implants*, 34(6), 1328-1336. doi:10.11607/jomi.7657
- Monje, A., Eick, S., Buser, D., & Salvi, G. E. (2021). Microbial and host-derived biomarker changes during ligature-induced and spontaneous peri-implantitis in the Beagle dog. *J Periodontol*, 56(1), 93-100. doi:10.1111/jre.12797
- Monje, A., Galindo-Moreno, P., Tozum, T. F., Suarez-Lopez del Amo, F., & Wang, H. L. (2016). Into the Paradigm of Local Factors as Contributors for Peri-implant Disease: Short Communication. *Int J Oral Maxillofac Implants*, 31(2), 288-292. doi:10.11607/jomi.4265
- Monje, A., & Nart, J. (2022). Management and sequelae of dental implant removal. *Periodontol* 2000, 88(1), 182-200. doi:10.1111/prd.12418
- Moses, O., Pitaru, S., Artzi, Z., & Nemcovsky, C. E. (2005). Healing of dehiscence-type defects in implants placed together with different barrier membranes: a comparative clinical study. *Clin Oral Implants Res*, 16(2), 210-219. doi:10.1111/j.1600-0501.2004.01100.x
- Nemcovsky, C. E., & Artzi, Z. (2002). Comparative study of buccal dehiscence defects in immediate, delayed, and late maxillary implant placement with collagen membranes: clinical healing between placement and second-stage surgery. *J Periodontol*, 73(7), 754-761. doi:10.1902/jop.2002.73.7.754
- Nir-Hadar, O., Palmer, M., & Soskolne, W. A. (1998). Delayed immediate implants: alveolar bone changes during the healing period. *Clin Oral Implants Res*, 9(1), 26-33. doi:10.1034/j.1600-0501.1998.090104.x

- Noelken, R., Donati, M., Fiorellini, J., Gellrich, N. C., Parker, W., Wada, K., & Berglundh, T. (2014). Soft and hard tissue alterations around implants placed in an alveolar ridge with a sloped configuration. *Clin Oral Implants Res*, 25(1), 3-9. doi:10.1111/clr.12079
- Nohra, J., Dagher, M., Matni, G., Mokbel, N., Jobaili, E., & Naaman, N. (2018). Effect of Primary Stability and Soft- and Hard-Tissue Thickness on Marginal Bone Loss: A Prospective Pilot Study. *Implant Dent*, 27(5), 542-546. doi:10.1097/ID.0000000000000810
- Novaes, A. B., Jr., Suaid, F., Queiroz, A. C., Muglia, V. A., Souza, S. L., Palioto, D. B., . . . Grisi, M. F. (2012). Buccal bone plate remodeling after immediate implant placement with and without synthetic bone grafting and flapless surgery: radiographic study in dogs. *J Oral Implantol*, 38(6), 687-698. doi:10.1563/AAID-JOI-D-10-00176
- Nowzari, H., Chee, W., Yi, K., Pak, M., Chung, W. H., & Rich, S. (2006). Scalloped dental implants: a retrospective analysis of radiographic and clinical outcomes of 17 NobelPerfect implants in 6 patients. *Clin Implant Dent Relat Res*, 8(1), 1-10. doi:10.2310/j.6480.2005.00034.x
- Oda, Y., Mori, G., Sasaki, H., Furuya, Y., Ito, T., Iijima, T., . . . Yajima, Y. (2021). Dimensional changes of buccal bone in the edentulous maxilla with telescopic-retained implant-supported fixed dental prostheses. *J Prosthet Dent*. doi:10.1016/j.prosdent.2021.08.006
- Oeschger, C. E., Bosshardt, D. D., Roehling, S., Gahlert, M., Cochran, D. L., & Janner, S. F. M. (2020). Crestal bone response to loaded zirconia and titanium implants: a radiographic and histometric analysis in canines. *Clin Oral Investig*, 24(10), 3609-3617. doi:10.1007/s00784-020-03235-2
- Onem, E., Baksi, B. G., & Sogur, E. (2012). Changes in the fractal dimension, feret diameter, and lacunarity of mandibular alveolar bone during initial healing of dental implants. *Int J Oral Maxillofac Implants*, 27(5), 1009-1013.
- Page, M. J., McKenzie, J. E., Bossuyt, P. M., Boutron, I., Hoffmann, T. C., Mulrow, C. D., . . . Moher, D. (2021). The PRISMA 2020 statement: An updated guideline for reporting systematic reviews. *Int J Surg*, 88, 105906. doi:10.1016/j.ijso.2021.105906
- Palombo, D., Rahmati, M., Vignoletti, F., Sanz-Esporrin, J., Haugen, H. J., & Sanz, M. (2021). Hard and soft tissue healing around implants with a modified implant neck configuration: An experimental in vivo preclinical investigation. *Clin Oral Implants Res*, 32(9), 1127-1141. doi:10.1111/clr.13812
- Patil, Y. B., Asopa, S. J., Deepa, Goel, A., Jyoti, D., Somayaji, N. S., & Sabharwal, R. (2020). Influence of Implant Neck Design on Crestal Bone Loss: A Comparative Study. *Niger J Surg*, 26(1), 22-27. doi:10.4103/njs.NJS\_28\_19
- Penarrocha-Oltra, D., Demarchi, C. L., Maestre-Ferrin, L., Penarrocha-Diago, M., & Penarrocha-Diago, M. (2012). Comparison of immediate and delayed implants in the maxillary molar region: a retrospective study of 123 implants. *Int J Oral Maxillofac Implants*, 27(3), 604-610.
- Pons, R., Carreno, M., Amerio, E., Gargallo-Albiol, J., Nart, J., & Monje, A. (2021). Hard tissue dimensional changes following implant removal due to peri-implantitis: A retrospective study. *Clin Implant Dent Relat Res*, 23(3), 432-443. doi:10.1111/cid.13004
- Qahash, M., Susin, C., Polimeni, G., Hall, J., & Wikesjo, U. M. (2008). Bone healing dynamics at buccal peri-implant sites. *Clin Oral Implants Res*, 19(2), 166-172. doi:10.1111/j.1600-0501.2007.01428.x

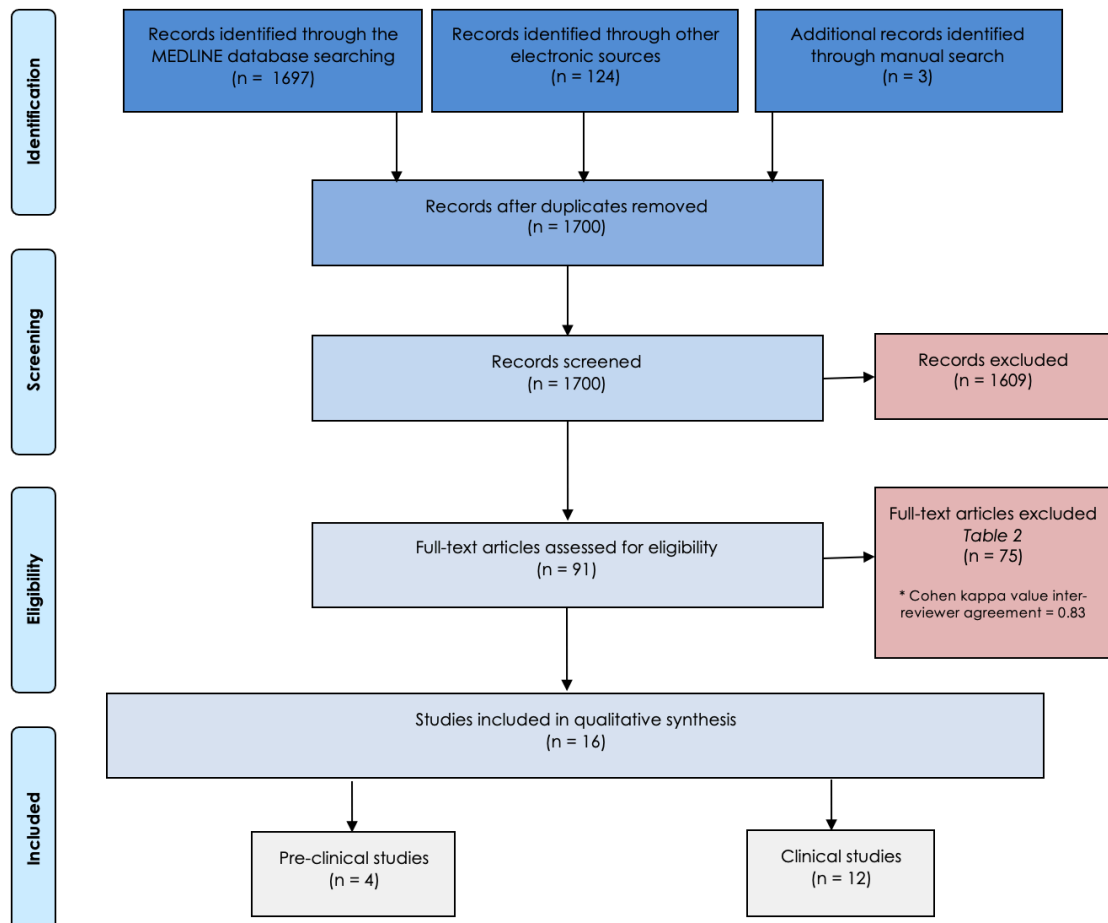


- Raes, S., Eghbali, A., Chappuis, V., Raes, F., De Bruyn, H., & Cosyn, J. (2018). A long-term prospective cohort study on immediately restored single tooth implants inserted in extraction sockets and healed ridges: CBCT analyses, soft tissue alterations, aesthetic ratings, and patient-reported outcomes. *Clin Implant Dent Relat Res*, 20(4), 522-530. doi:10.1111/cid.12613
- Rodriguez-Ortiz, G., Chen, S., Davies, H., Fitzgerald, W., & Darby, I. (2021). Early implant placement in ridge preserved extraction sockets: A pre-clinical in vivo study. *Clin Oral Implants Res*, 32(6), 745-755. doi:10.1111/clr.13744
- Roush, J. K., Howard, P. E., & Wilson, J. W. (1989). Normal blood supply to the canine mandible and mandibular teeth. *Am J Vet Res*, 50(6), 904-907.
- Roux, S., & Orcel, P. (2000). Bone loss. Factors that regulate osteoclast differentiation: an update. *Arthritis Res*, 2(6), 451-456. doi:10.1186/ar127
- Sanz-Martin, I., Vignoletti, F., Nunez, J., Permuy, M., Munoz, F., Sanz-Esporrin, J., . . . Sanz, M. (2017). Hard and soft tissue integration of immediate and delayed implants with a modified coronal macrodesign: Histological, micro-CT and volumetric soft tissue changes from a pre-clinical in vivo study. *J Clin Periodontol*, 44(8), 842-853. doi:10.1111/jcpe.12747
- Sarment, D. P., & Meraw, S. J. (2008). Biological space adaptation to implant dimensions. *Int J Oral Maxillofac Implants*, 23(1), 99-104.
- Schliephake, H., Wichmann, M., Donnerstag, F., & Vogt, S. (2003). Imaging of periimplant bone levels of implants with buccal bone defects. *Clin Oral Implants Res*, 14(2), 193-200. doi:10.1034/j.1600-0501.2003.140209.x
- Schropp, L., Wenzel, A., Spin-Neto, R., & Stavropoulos, A. (2015). Fate of the buccal bone at implants placed early, delayed, or late after tooth extraction analyzed by cone beam CT: 10-year results from a randomized, controlled, clinical study. *Clin Oral Implants Res*, 26(5), 492-500. doi:10.1111/clr.12424
- Schwarz, F., Herten, M., Sager, M., Wieland, M., Dard, M., & Becker, J. (2007). Bone regeneration in dehiscence-type defects at chemically modified (SLActive) and conventional SLA titanium implants: a pilot study in dogs. *J Clin Periodontol*, 34(1), 78-86. doi:10.1111/j.1600-051X.2006.01008.x
- Schwarz, F., Sager, M., Golubovic, V., Iglhaut, G., & Becker, K. (2016). Horizontal mucosal thickness at implant sites as it correlates with the integrity and thickness of the buccal bone plate. *Clin Oral Implants Res*, 27(10), 1305-1309. doi:10.1111/clr.12747
- Schwarz, F., Sahm, N., & Becker, J. (2012). Impact of the outcome of guided bone regeneration in dehiscence-type defects on the long-term stability of peri-implant health: clinical observations at 4 years. *Clin Oral Implants Res*, 23(2), 191-196. doi:10.1111/j.1600-0501.2011.02214.x
- Scipioni, A., Bruschi, G. B., Giargia, M., Berglundh, T., & Lindhe, J. (1997). Healing at implants with and without primary bone contact. An experimental study in dogs. *Clin Oral Implants Res*, 8(1), 39-47. doi:10.1111/j.1600-0501.1997.tb00006.x
- Serrano, B., Sanz-Sanchez, I., Serrano, K., Montero, E., & Sanz, M. (2022). One-year outcomes of dental implants with a hybrid surface macro-design placed in patients with history of

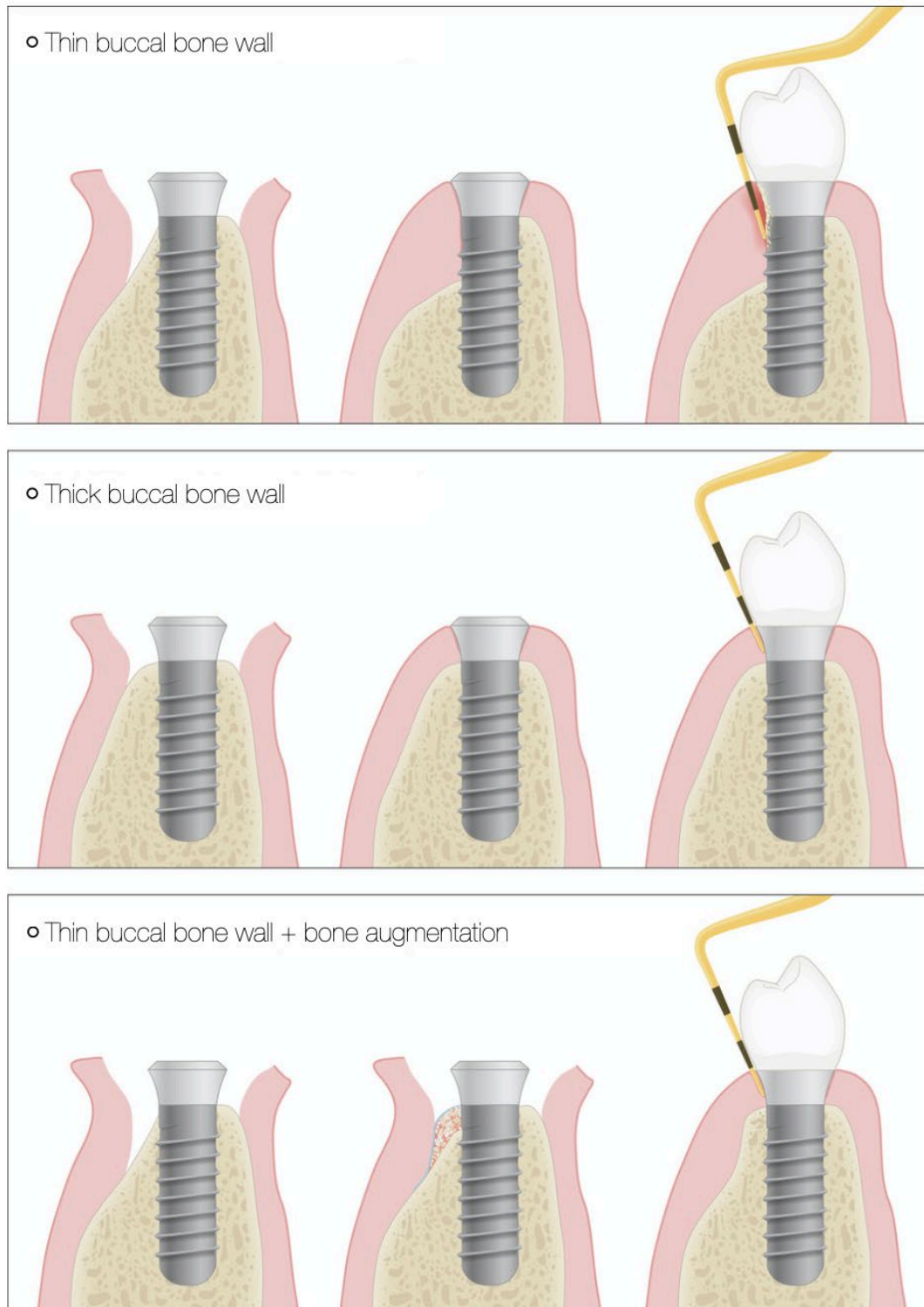
- periodontitis: A randomized clinical trial. *J Clin Periodontol*, 49(2), 90-100. doi:10.1111/jcpe.13575
- Souza, A. B., Alshihri, A., Kammerer, P. W., Araujo, M. G., & Gallucci, G. O. (2018). Histological and micro-CT analysis of peri-implant soft and hard tissue healing on implants with different healing abutments configurations. *Clin Oral Implants Res*, 29(10), 1007-1015. doi:10.1111/clr.13367
- Spray, J. R., Black, C. G., Morris, H. F., & Ochi, S. (2000). The influence of bone thickness on facial marginal bone response: stage 1 placement through stage 2 uncovering. *Ann Periodontol*, 5(1), 119-128. doi:10.1902/annals.2000.5.1.119
- Sterne, J. A. C., Savovic, J., Page, M. J., Elbers, R. G., Blencowe, N. S., Boutron, I., ... Higgins, J. P. T. (2019). RoB 2: a revised tool for assessing risk of bias in randomised trials. *BMJ*, 366, l4898. doi:10.1136/bmj.l4898
- Suaid, F. A., Novaes, A. B., Jr., Queiroz, A. C., Muglia, V. A., Almeida, A. L., & Grisi, M. F. (2014). Buccal bone plate remodeling after immediate implants with or without synthetic bone grafting and flapless surgery: a histomorphometric and fluorescence study in dogs. *Clin Oral Implants Res*, 25(2), e10-21. doi:10.1111/clr.12036
- Sutter, F., Schroeder, A., & Buser, D. (1988). [NewITI implant concept--technical aspects and methods (I)]. *Quintessenz*, 39(11), 1875-1890.
- Tal, H., Artzi, Z., Moses, O., Nemcovsky, C. E., & Kozlovsky, A. (2001). Spontaneous early exposure of submerged endosseous implants resulting in crestal bone loss: a clinical evaluation between stage I and stage II surgery. *Int J Oral Maxillofac Implants*, 16(4), 514-521.
- Tanaka, K., Sailer, I., Iwama, R., Yamauchi, K., Nogami, S., Yoda, N., & Takahashi, T. (2018). Relationship between cortical bone thickness and implant stability at the time of surgery and secondary stability after osseointegration measured using resonance frequency analysis. *J Periodontal Implant Sci*, 48(6), 360-372. doi:10.5051/jpis.2018.48.6.360
- Tarnow, D. (1993). Esthetic excellence with the single-tooth implant. *Dent Econ*, 83(3), 80-82.
- Temmerman, A., Keestra, J. A., Coucke, W., Teughels, W., & Quirynen, M. (2015). The outcome of oral implants placed in bone with limited bucco-oral dimensions: a 3-year follow-up study. *J Clin Periodontol*, 42(3), 311-318. doi:10.1111/jcpe.12376
- Thoma, D. S., Lim, H. C., Paeng, K. W., Jung, U. W., Hammerle, C. H. F., & Jung, R. E. (2019). Tissue integration of zirconia and titanium implants with and without buccal dehiscence defects-A histologic and radiographic preclinical study. *Clin Oral Implants Res*, 30(7), 660-669. doi:10.1111/clr.13451
- van Eekeren, P., van Elsas, P., Tahmaseb, A., & Wismeijer, D. (2017). The influence of initial mucosal thickness on crestal bone change in similar macrogeometrical implants: a prospective randomized clinical trial. *Clin Oral Implants Res*, 28(2), 214-218. doi:10.1111/clr.12784
- Vera, C., De Kok, I. J., Chen, W., Reside, G., Tyndall, D., & Cooper, L. F. (2012). Evaluation of post-implant buccal bone resorption using cone beam computed tomography: a clinical pilot study. *Int J Oral Maxillofac Implants*, 27(5), 1249-1257.
- Vignoletti, F., Sanz-Esporrin, J., Sanz-Martin, I., Nunez, J., Luengo, F., & Sanz, M. (2019). Ridge alterations after implant placement in fresh extraction sockets or in healed crests: An

- experimental in vivo investigation. *Clin Oral Implants Res*, 30(4), 353-363. doi:10.1111/clr.13421
- Wadamoto, M., Akagawa, Y., Sato, Y., & Kubo, T. (1996). The three-dimensional bone interface of an osseointegrated implant. I: A morphometric evaluation in initial healing. *J Prosthet Dent*, 76(2), 170-175. doi:10.1016/s0022-3913(96)90302-9
- Wells GA , S. B., D O'Connell, Peterson J, Welch V, Losos M, Tugwell P. (2014). The Newcastle–Ottawa Scale (NOS) for assessing the quality of non-randomized studies in meta-analysis. . *Appl Eng Agric*.
- Windael, S., Collaert, B., De Buyser, S., De Bruyn, H., & Vervaeke, S. (2021). Early peri-implant bone loss as a predictor for peri-implantitis: A 10-year prospective cohort study. *Clin Implant Dent Relat Res*, 23(3), 298-308. doi:10.1111/cid.13000
- Yi, H. Y., Park, Y. S., Pippenger, B. E., Lee, B., Miron, R. J., & Dard, M. (2017). Dimensional Changes Following Immediate and Delayed Implant Placement: A Histomorphometric Study in the Canine. *Int J Oral Maxillofac Implants*, 32(3), 541-546. doi:10.11607/jomi.5145
- Yoda, N., Zheng, K., Chen, J., Li, W., Swain, M., Sasaki, K., & Li, Q. (2017). Bone morphological effects on post-implantation remodeling of maxillary anterior buccal bone: A clinical and biomechanical study. *J Prosthodont Res*, 61(4), 393-402. doi:10.1016/j.jpjor.2016.12.010

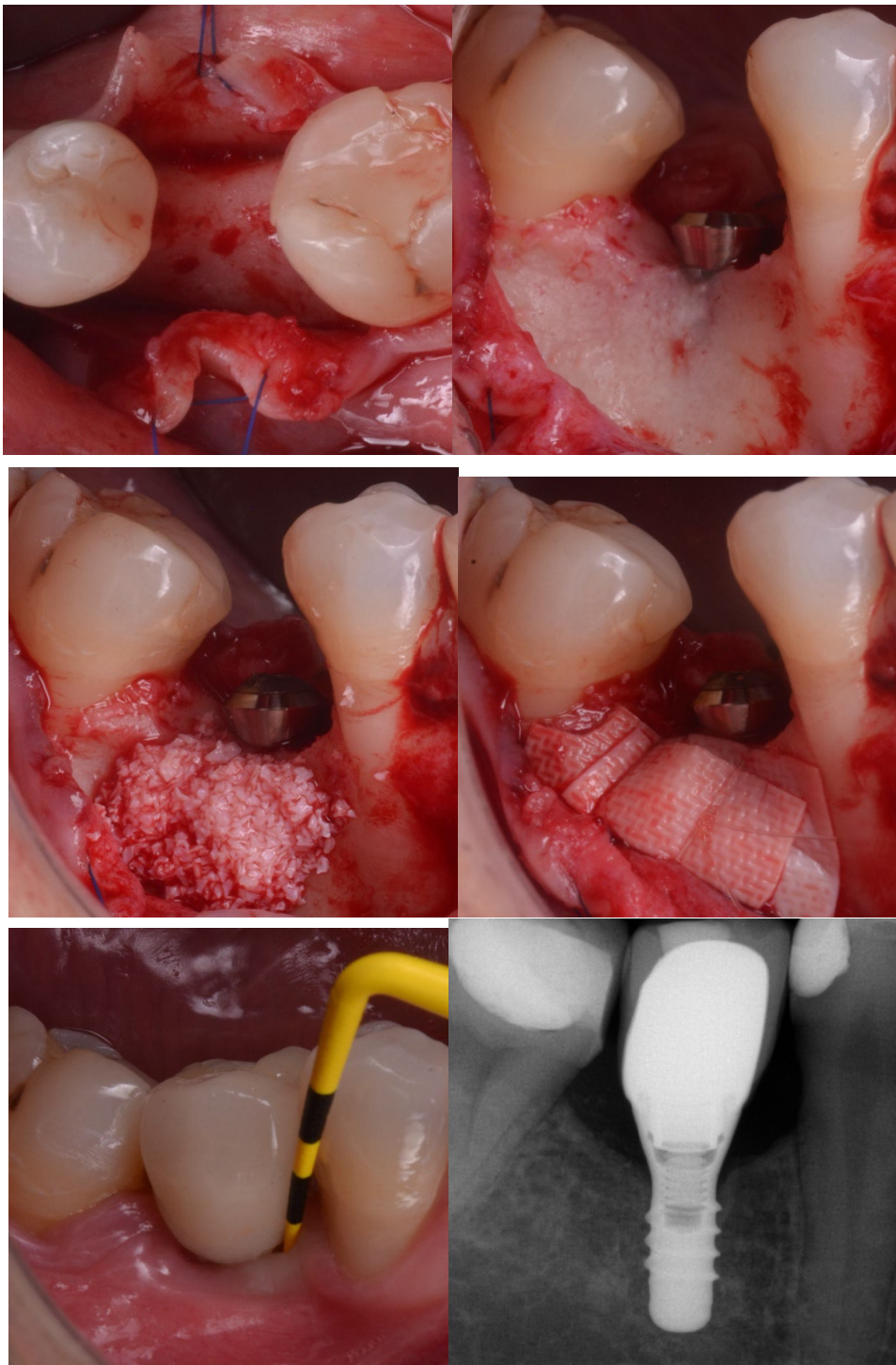**Figure 1.** Flowchart of the systematic review.



**Figure 2.** Schematic representation of avascular necrosis of the buccal bony wall according to the baseline BBW and the potential of bone augmentation to compensate scenarios characterized by  $BBW < 1.5$  mm according to the findings by Monje et al. (2019).



**Figure 3.** Case scenario of thin BBT in the posterior mandible; (a) occlusal view indicating the narrow alveolar dimension, (b) implant three-dimensional position must solely be dictated by the desired emergence profile, (c) grafting with autogenous bone and slowly reabsorbing bone in two layers, (d) cross-linking suture is used in line with the principle of compartmentalization, (e) clinical outcomes show stability and peri-implant health, (d) bone levels remain stable.



**Table 1.** Eligibility criteria for the systematic review.

<b>Inclusion criteria</b>	<b>Exclusion criteria</b>
Clinical single- or multiple-arm trials (CCT, RCT, CS)	Case reports (<10 cases)
Preclinical trials	In vitro research
Clinical, radiographic, histological and/or volumetric examination	Non-validated tools for examination
Baseline data on the buccal and/or alveolar bone dimension	Lack of data on the buccal/alveolar bone dimension
Baseline and follow-up data	Lack of baseline and/or follow-up data
Implants placed in healed ridges	Implants placed in fresh extraction sockets
Systemically healthy patients	Patients with disease conditions and/or heavy smokers ( $\geq 10$ cigarettes/day)

**Table 2.** Excluded articles and reasons for exclusion.

Reason for exclusion	Reference
Simultaneous grafting procedure with no control group	(Fenner et al., 2009; Fienitz et al., 2012; Hur et al., 2017; Moses, Pitaru, Artzi, & Nemcovsky, 2005; Nemcovsky & Artzi, 2002; Qahash, Susin, Polimeni, Hall, & Wikesjo, 2008)
Early placement protocol with simultaneous bone regeneration	(Nir-Hadar, Palmer, & Soskolne, 1998; Rodriguez-Ortiz, Chen, Davies, Fitzgerald, & Darby, 2021)
Grafted sockets with no baseline dimension	(Crespi, Toti, Covani, Crespi, & Menchini-Fabris, 2021; Duong et al., 2020)
Immediate implant placement protocol	(Barone et al., 2015; S. T. Chen, Darby, & Reynolds, 2007; Novaes et al., 2012; Penarrocha-Oltra, Demarchi, Maestre-Ferrin, Penarrocha-Diago, & Penarrocha-Diago, 2012; Suaid et al., 2014)
Implant stability quotient with no dimensional data	(Bozkaya, Uraz, Guler, Kahraman, & Turhan Bal, 2021)
No baseline dimensional data/missing information	(Abrahamsson, Berglundh, Linder, Lang, & Lindhe, 2004; Abrahamsson, Berglundh, Moon, & Lindhe, 1999; Abrahamsson, Berglundh, Wennstrom, & Lindhe, 1996; Abrahamsson, Welander, Linder, & Berglundh, 2014; G. M. Baffone et al., 2012; G. M. Baffone et al., 2011; J. Becker et al., 2007; K. Becker, Klitzsch, Stauber, & Schw arz, 2017; Bratu, Tandlich, & Shapira, 2009; Carcuac, Abrahamsson, Derks, Petzold, & Berglundh, 2020; Carmagnola, Araujo, Berglundh, Albrektsson, & Lindhe, 1999; Carmo Filho et al., 2019; Cesaretti et al., 2015; Chacun et al., 2021; Checchi et al., 2017; Cooper, De Kok, Rojas-Vizcaya, Pungpapong, & Chang, 2007; Cooper et al., 2015; Di Raimondo et al., 2021; Finelle et al., 2015; Gehrke, Braganca, Velasco-Ortega, & Calvo-Guirado, 2018; Jemt & Lekholm, 2003, 2005; Jonker, Wolvius, van der Tas, Tahmaseb, & Pijs, 2020; Kim et al., 2016; Koufouzis, Koutouzis, Gadalla, & Neiva, 2013; Lee et al., 2016; Lee et al., 2019; Noelken et al., 2014; Nowzari et al., 2006; Oeschger et al., 2020; Palombo et al., 2021; Patil et al., 2020; Raes et al., 2018; Sanz-Martin et al., 2017; Schropp, Wenzel, Spin-Neto, & Stavropoulos, 2015; Schw arz et al., 2007; Schw arz, Sager, Golubovic, Ighaut, & Becker, 2016; Souza, Alshihri, Kammerer, Araujo, & Gallucci, 2018; Thoma et al., 2019; van Eekeren, van Elsas, Tahmaseb, & Wismeijer, 2017; Vera et al., 2012; Yi et al., 2017)
Implant removal procedures	(Pons et al., 2021)
Survey analysis	(Fiorellini et al., 2020)
Only descriptive data on dimensional features	(Glibert, Ostman, De Bruyn, & Ostman, 2018)
Retracted article	(Calvo-Guirado et al., 2016)
Ridge expansion procedures	(Beolchini et al., 2015; Scipioni, Bruschi, Giorgia, Berglundh, & Lindhe, 1997)
Outside scope	(da Silva Pereira et al., 2000; Deporter, Watson, Pilliar, Howley, & Winslow, 1988; Dursun et al., 2012; Lin, Li, Li, & Swain, 2009; Onem, Baksi, & Sogur, 2012; Sarment & Meraw, 2008; Schliephake, Wichmann, Donnerstag, & Vogt, 2003; Tal, Artzi, Moses, Nemcovsky, & Kozlovsky, 2001; Wadamoto, Akagawa, Sato, & Kubo, 1996)
Case report	(Yoda et al., 2017)
Only cortical thickness provided	(Tanaka et al., 2018)



**Table 3.** Clinical studies included in the qualitative analysis.

Author (year)	Study design	Experimental group	Sample size (implants)	Buccal bone wall thickness in implant placement stage (mm)	Alveolar bucco-lingual dimension (mm)	Vertical bone defect (mm)	Buccal bone wall thickness at re-assessment (mm)	Alveolar bucco-lingual dimension at re-assessment (mm)	Vertical bone loss (mm)	Method of assessment	Time of re-assessment (months)	Length of study period (months)	Clinical outcome					Radiographic outcome		Take home message	
													Probing pocket depth (mm)	Bleeding on probing (%)	Mucosal recession (mm)	Suppuration (%)	Clinical attachment level (mm)	Method of assessment	Marginal bone level (mm)		
Barone et al. (2016)	RCT	Spontaneous healing after implant placement with bone with high (50-100 Ncm) insertion torque (50 Ncm)	58	<1	NR	NR	NR	NR	NR	NR	NR	12	NR	NR	1.07	NR	NR	Peri-apical radiograph	0.71 (0.39)	Sites with a thick buccal bone wall ( $\geq 1$ mm) are less prone to buccal soft tissue recession than sites with a thin buccal bone wall	
				$\geq 1$	NR	NR	NR	NR	NR	NR	NR	NR	NR	0.78	NR	NR					
		Spontaneous healing after implant placement with regular insertion torque (50 Ncm)	58	<1	NR	NR	NR	NR	NR	NR	NR	NR	NR	NR	NR	0.35	NR		NR		1.11 (0.39) (12m)
				$\geq 1$	NR	NR	NR	NR	NR	NR	NR	NR	NR	NR	NR	0.15	NR		NR		
Cardaropoli et al. (2006)	PC	Spontaneous healing	11	1.2 (1)	NR	NR	0.8 (0.3)	NR	NR	Caliper	6	12	NR	NR	NR	NR	NR	Peri-apical radiograph	1.9 (1.1)	Following implant placement in the healed alveolar ridge, remodeling of bone takes place, which is manifested in diminished dimensions, both horizontally and vertically, at the facial aspect of the implant	
Covani et al. (2004)	PC	Spontaneous healing	15	NR	8.8 (2.3)	NR	NR	5.8 (1.3)	NR	Probe	4	4	NR	NR	NR	NR	NR	NR	NR	Implants placed in healed ridges undergo dimensional changes due to bone resorption	
Faronato et al. (2020)	PC	Spontaneous healing	23	<0.5	NR	NR	NR	NR	NR	Caliper	NR	36	NR	NR	1.22	NR	NR	NR	NR	The buccal bone thickness at the time of implant placement may potentially affect buccal mucosal margin stability	
				>0.5<1.5	NR	NR	NR	NR	NR				NR	NR	NR	NR					
				$\geq 1.5$	NR	NR	NR	NR	NR				NR	NR	NR	(+) 0.77	NR				NR
Jung et al. (2017)	RCT	Spontaneous healing (<5 mm in height dehiscence defect)	12	0	NR	3.2 (1.1)	NR	NR	0.17 (1.7)	Probe	6	18	2.9 (0.9)	0.07 (0.1)*	3.3	NR	NR	Peri-apical radiograph	0.3 (0.4)	Sites that are left for spontaneous healing reveal more vertical bone loss at the buccal aspect within the early stages of healing and less bone stability during follow-up	
		Simultaneous guided bone regeneration (<5 mm in height dehiscence defect)	10	0	NR	3.6 (1.3)	NR	NR	(+) 1.7 (2.2)				2.6 (1.0)	0.07 (0.1)*	3.07	NR	NR		(+) 0.02 (0.4)		
Li Manni et al. (2020)	RTC	Spontaneous healing with circular-neck implant	17	1.34 (1.08)	NR	NR	1.03 (1.05)	NR	NR	CBCT	12	12	NR	NR	NR	NR	NR	CBCT	0.42 (0.67)	Minimal dimensional changes are expected when a minimal buccal bone thickness is present in the posterior maxilla	
		Spontaneous healing with triangular-neck implant	17	1.34 (0.74)	NR	NR	1.08 (0.72)	NR	NR				NR	NR	NR	NR	NR		NR		NR
Marconcini et al. (2018)	RCT	Spontaneous healing after implant placement with bone with high (50-100 Ncm) insertion torque (50 Ncm)	58	<1	NR	NR	NR	NR	NR	NR	NR	NR	36	NR	NR	1.53	NR	NR	Peri-apical radiograph	1.03 (0.12)	Sites with a thick buccal bone wall ( $\geq 1$ mm) are less prone to buccal soft tissue recession than sites with thin buccal bone wall
				$\geq 1$	NR	NR	NR	NR	NR	NR	NR	NR	NR	NR	NR	NR	NR				
		Spontaneous healing after implant placement with regular insertion	58	<1	NR	NR	NR	NR	NR	NR	NR	NR	NR	NR	NR	NR	0.57	NR		NR	

		torque (50 Ncm)		≥1	NR	NR	NR	NR	NR	NR			NR	NR	0.11	NR	NR							
<b>Nohra et al. (2018)</b>	PC	Spontaneous healing with 3 different ranges of insertion torque	18	<2	NR	NR	NR	NR	NR	2.34 (2.16)	Caliper	12	12	NR	NR	NR	NR	NR	NR	CBCT	0.36 (0.34)	Insertion torque and mucosal tissue thickness do not influence implant survival or marginal bone loss. Buccal bone thickness of ≥2 mm was associated with a minimal marginal bone remodelling		
		Spontaneous healing with 3 different ranges of insertion torque	21	≥2	NR	NR	NR	NR	NR	0.31 (0.63)				NR	NR	NR	NR	NR	NR		0.03 (0.42)			
<b>Oda et al. (2021)</b>	RC	Spontaneous healing	17	1.43	NR	NR	0.8	NR	NR		CBCT	72	72	NR	NR	NR	NR	NR	NR	NR	NR	Significant buccal bone loss occurs over the long-term in the edentulous maxilla		
<b>Schwarz et al. (2012)</b>	PC	Simultaneous guided bone regeneration	8	0	NR	0	NR	NR	NR		Caliper	4	48	2.9 (0.7)	29.1 (21.3)	0.2 (0.3)	NR	3.1 (0.8)	NR	NR	NR	Implants exhibiting residual defect height values >1 mm are at a greater risk of developing peri-implant disease and are associated to an increase in MR		
			8	0	NR	1	0	NR	NR	2.8 (0.7)				45.8 (30.5)	0.5 (0.7)	NR	3.3 (0.8)							
			8	0	NR	3.6 (1.5)	0	NR	NR	2.7 (0.8)				54.1 (24.8)	0.4 (0.6)	NR	3.1 (1.2)							
<b>Spray et al. (2000)</b>	PC	Spontaneous healing	140	1.26 (0.87)	NR	>3	0.7 (1.70)*	NR	NR		Caliper and probe	Mandible (3-4) - Maxilla (3-8)	NR	NR	NR	NR	NR	NR	NR	NR	NR	The greatest bone resorption occurs when the buccal plate at implant placement is <1.4 mm. Bone loss decreases with <1.7 mm baseline buccal plates. If bone is ≥1.8, changes are in-existent.		
			189	1.54 (1.11)	NR	2.1-3		NR	NR	NR				NR	NR	NR	NR	NR	NR	NR				
			415	1.67 (1.10)	NR	1.1-2		NR	NR	NR				NR	NR	NR	NR	NR	NR	NR	NR			
			733	1.75 (1.41)	NR	0.1-1		NR	NR	NR				NR	NR	NR	NR	NR	NR	NR	NR		NR	
			716	1.83 (1.10)	NR	0		NR	NR	NR				NR	NR	NR	NR	NR	NR	NR	NR		NR	NR
			474	1.84 (1.41)	NR	0		NR	NR	NR				NR	NR	NR	NR	NR	NR	NR	NR		NR	NR
<b>Temmerman et al. (2015)</b>	PC	Spontaneous healing for buccal plates <1 mm and simultaneous guided bone regeneration when dehiscence/fenestration of implants placed 2 mm sub-crestal	98	<1	<4.5	NR	NR	NR	NR		NR	3.6	NR	NR	NR	NR	NR	NR	NR	Peri-apical radiograph	0.79	At sites with limited buccolingual dimensions (≤4.5 mm), implants can be successful if placed sub-crestal		

\* Refers to mean value of the modified sulcular bleeding index; NR: not reported; PC: prospective cohort; RC: retrospective cohort; RCT: randomized controlled trial; CBCT: cone beam computed tomography

**Table 4.** Preclinical studies included in the qualitative analysis.

Author (year)	Experimental model	Experimental design	Sample (implants)	Experimental group	Method of assessment	Buccal bone wall thickness in implant placement stage (mm)	Bucco-lingual alveolar bone dimension at implant placement (mm)	Buccal bone thickness at re-assessment (mm)	Bucco-lingual alveolar bone dimension at re-assessment (mm)	Vertical bone loss (mm)	Time of re-assessment (months)	Clinical outcome					Radiographic outcome		Take home message
												Probing pocket depth (mm)	Modified sulcular bleeding index (mean)	Mucosal recession (mm)	Suppuration (%)	Clinical attachment level (mm)	Method of assessment	Marginal bone level (mm)	
Balfone et al. (2015)	Labrador dog	Spontaneous healing	6	Narrow ridge - Narrow abutment (3.3mm)	Caliper	NR	4.1 (0.4)	1 (0.7)	NR	1.7 (1.7)	3	NR	NR	NR	NR	NR	NR	Implants installed in regular-sized alveolar ridges have greater horizontal, but lesser vertical buccal bony crestal resorption compared to implants installed in reduced alveolar ridges.	
			6	Wide ridge - Wide abutment (4.6mm)		NR	5.4 (1.3)	1 (0.5)	NR	1.3 (0.9)		NR	NR	NR	NR				
			6	Narrow ridge - Wide abutment (3.3mm)		NR	3.7 (0.4)	0.7 (0.4)	NR	0.9 (0.3)		NR	NR	NR	NR				
			6	Wide ridge - Narrow abutment (4.6mm)		NR	6.2 (1.2)	1.5 (0.7)	NR	1.5 (0.5)		NR	NR	NR	NR				
Benazzi et al. (2014)	Beagle dog	Spontaneous healing	6	Remolar-Alveolar mucosa	Caliper	0.9 (0.0)	NR	0.7 (0.3)	NR	1.7 (0.6)	3	NR	NR	NR	NR	NR	NR	Greater buccal bony crestal resorption and a more apical soft tissue marginal position should be expected when implants are surrounded with thin alveolar mucosa at the time of placement, independently of the thickness of the buccal bony crest.	
			6	Remolar-Masticatory mucosa		0.9 (0.0)	NR	0.4 (0.6)	NR	0.9 (0.6)		NR	NR	NR	NR				
			6	Molar-Alveolar mucosa		2.3 (0.3)	NR	2.2 (0.5)	NR	2.3 (0.9)		NR	NR	NR	NR				
			6	Molar-Masticatory mucosa		2.4 (0.1)	NR	1.5 (0.8)	NR	1.4 (0.5)		NR	NR	NR	NR				
Morje et al. (2019)	Beagle dog	Spontaneous healing	18	Thin buccal bone	Tracking system	<1.5	NR	NR	NR	4.07	2	NR	NR	NR	NR	NR	Lower bone levels are expected when the		
			18	Thick buccal bone		21.5	NR	NR	NR	0.11		NR	NR	NR	NR	NR			

		Experimental peri-implantitis	18	Thin buccal bone		<1.5	NR	NR	NR	3.69	5	3.6	1.31	0.14	17	NR	CT	502	cificial buccal bone thickness is <1.5 mm. Experimental peri-implantitis is, in part, attributable to the greater vertical resorption of the buccal plate during initial remodeling. Clinical parameters are greater for implants placed in ridges under the buccal bone thickness when compared to implants placed 21.5 mm of buccal bone thickness.
			18	Thick buccal bone		≥1.5	NR	NR	NR	2.83		3.21	1.1	†0.08	3	NR			
Vignolle et al. (2019)	Beagle dogs	Spontaneous healing	16	2week healing	Probe	2.29 [5.15]	NR	1.56 [5.9]	NR	0.29 [0.18]	<1	NR	NR	NR	NR	NR	NR	NR	Rounded buccolingual ridge alterations and vertical bone loss are noted at 2 and 8 weeks after implant placement in healed ridges
			16	8week healing		2.29 [5.15]	NR	0.94 [0.79]	NR	0.59 [0.58]	2	NR	NR	NR	NR	NR	NR	NR	