Comparison of Corneal Thickness Measurements After Customized Corneal Crosslinking Using High-Resolution Optical Coherence Tomography and Scheimpflug Tomography

Tiago Mendes Baiao, MMed,†‡ Jascha Wendelstein, MD,*§¶ and Theo G. Seiler, MD*‡||***

Purpose: The aim of this study was to compare the evolution of corneal pachymetry after customized corneal crosslinking (CXL) between Scheimpflug-based and optical coherence–based corneal tomography (OCT).

Methods: In this retrospective study, central corneal thickness (CCT), thinnest corneal thickness, and epithelial thickness of 33 eyes of 33 patients with keratoconus were measured preoperatively and 1, 3, and 12 months after customized CXL using the Pentacam HR and the MS-39. The mean pachymetry values of measurements were compared with a paired sample *t* test. Bland–Altman plots and 95% limits of agreement (LoA) were used to assess the agreement between the measurements of the 2 devices.

Results: The mean age of the participants was 29.7 ± 11.4 years. At baseline, the mean CCT measurements were equal with Pentacam HR (478.30 ± 36.77 μm) and MS-39 (478.46 ± 38.01 μm). After CXL, CCT obtained by Pentacam HR was 460.65 ± 38.69 μm, 464.65 ± 44.45 μm, and 476.77 ± 39.85 μm, and by MS-39 was 478.18 ± 39.50 μm, 472.89 ± 40.92 μm, and 479.51 ± 39.20 μm at 1, 3, and 12 months, respectively. Pentacam HR measured significantly lower CCT ($P < 0.05$) at months 1 and 3 after CXL. The agreement was smallest between both devices at month 1 (95% LoA −59 to 24 μm) followed by month 3 (95% LoA: −41 to 23 μm). Epithelial thickness, measured with OCT alone, increased significantly at 1 month and regained preoperative levels at 3 months and thereafter.

Conclusions: After CXL, corneal pachymetry significantly differs between OCT-based and Scheimpflug-based corneal tomography. Pentacam HR seems to underestimate pachymetry when haze is present.

Received for publication April 26, 2022; revision received August 5, 2022; accepted August 14, 2022.

From the *Institut für Refraktive und Ophthalmo-Chirurgie (IROC), Zurich, Switzerland; †Berner Augenklinik am Lindenhofspital, Bern, Switzerland; ‡Medical Faculty, University of Bern, Bern, Switzerland; §Medical Faculty, Department of Ophthalmology, Johannes Kepler University Linz, Linz, Austria; ¶Institute of Experimental Ophthalmology, Saarland University, Homburg, Germany; ||Universitätsklinik für Augenheilkunde, Inselspital Bern, Bern, Switzerland; and **Klinik für Augenheilkunde, Universitätsklinikum Düsseldorf, Duesseldorf, Germany.

T. G. Seiler is a scientific consultant for Glaukos

Correspondence: Theo G. Seiler, MD, Institut für Refraktive und Ophthalmo-Chirurgie (IROC AG), Stockerstrasse 37, 8002 Zürich, Switzerland (e-mail: theo@seiler.tv).

Copyright © 2023 Wolters Kluwer Health, Inc. All rights reserved.

Key Words: comparison, corneal thickness, crosslinking, CXL, keratoconus, MS-39, OCT, pachymetry, Pentacam

(*Cornea* 2023;00:1–6)

Keratoconus is an asymmetrical, bilateral noninflammatory corneal ectasia characterized by a progressive thinning and forward bulging of the cornea.[1] Among all parameters given by corneal topographers and tomographers, keratometry and corneal thickness are the 2 most important parameters for keratoconus diagnosis,[2] corneal crosslinking (CXL) treatment indication,[3,4] and follow-up examinations.[5]

The development of CXL more than 20 years ago was a turning point in keratoconus treatment because physicians were now able to stabilize corneal ectasia.[6] The technique was further refined with accelerated protocols[7] and customized treatment patterns.[8] A known problem in eyes treated with CXL, however, is the development of transient stromal haze that usually peaks between months 1 and 6 after the procedure.[9] Stromal haze has been shown to affect optical measurement of corneal thickness, leading to potentially erroneous corneal pachymetry.[10,11] The techniques most affected by this optical phenomenon seem to be Scheimpflug-scanning and slit-scanning imaging,[12] both technologies are based on backscattering of blue light as opposed to optical coherence tomography (OCT), which is based on reflection of the near-infrared light. Because of the inverse relation of wavelength and scattering, Scheimpflug imaging using shorter wavelengths (blue light) is more affected by corneal haze after CXL, thus providing less accurate pachymetry values.[13]

The objective of this study was to compare the changes in corneal pachymetry over a course of 12 months after customized CXL between the MS-39, a newly developed anterior-segment spectral-domain (SD) optical coherence tomographer, and the Scheimpflug-based Pentacam HR tomographer, putting an emphasis on data from baseline to 3 months after surgery, when the influence of stromal haze on pachymetry measurement can be expected to peak.

Copyright © 2023 Wolters Kluwer Health, Inc. Unauthorized reproduction of this article is prohibited.

TABLE 1. Mean ± SDs and 95% Confidence Interval of Central Corneal Thickness Measured by the Pentacam HR and the MS-39 Devices at Baseline and at All Follow-Up Visits After CXL

	Baseline	1 mo	3 mo	12 mo
Pentacam HR CCT [μm]	478.30 ± 36.77	460.65 ± 38.69	464.65 ± 44.45	476.77± 39.85
95% confidence interval	466.63–491.79	447.22–474.08	451.23–479.99	464.60–490.87
P (between baseline and the subsequent time points)		**0.017**	**0.009**	0.628
MS-39 CCT [μm]	478.46 ± 38.01	478.18 ± 39.50	472.89 ± 40.92	479.51 ± 39.20
95% confidence interval	466.05–492.75	463.67–492.69	459.93–488.92	466.81–494.14
P (between baseline and the subsequent time points)		0.383	0.132	0.861

Bold indicates statistical significant difference is given if $p<0.05$.

PATIENTS AND METHODS

Study Group

Thirty-three eyes of 33 patients with documented progressive primary keratoconus who underwent customized CXL at the Institut für Refraktive und Ophthalmo-Chirurgie (IROC) in Zurich, Switzerland, between July 2017 and January 2019 were enrolled in this retrospective study. The institutional review committee (Ethikkommission des Kantons Zürich) approved the study protocol in accordance with the Declaration of Helsinki. Exclusion criteria were previous ocular surgery (including CXL), penetrating trauma, glaucoma, aphakia, endothelial cell count less than 2300 cells/mm^2, intraoperative corneal thickness below 400 μm before UV irradiation, pellucid marginal degeneration, corneal scars that may interfere with Scheimpflug imaging, history of recurrent erosions, pregnancy and breast feeding, neurodermatitis, and connective tissue disorders.

According to our standard of care after customized CXL, every patient was seen at 1, 3, and 12 months after CXL. At each visit, a complete ophthalmological examination including Pentacam HR (Oculus Optikgeräte GmbH, Wetzlar, Germany) and high-resolution anterior-segment OCT (MS-39, CSO, Scandicci, Italy) was performed.

Corneal Crosslinking Technique

All patients were treated with customized crosslinking with epithelial debridement followed by the application of 0.1% riboflavin in 1.1% hydroxypropyl methylcellulose for 10 minutes (Vibex Rapid, Avedro Inc, Waltham, MA) and a customized UV irradiation (Mosaic, Avedro Inc). The profiles were designed as a concentric superposition of 2 elliptic (ranging from 2.5 to 5.5 mm) and 1 circular area (8 mm) centered on the maximum of the posterior elevation. The radiant exposure in the inner ellipse was 10 J/cm^2, in the middle 7.7 J/cm^2, and in the outer circle 5.4 J/cm^2. The used irradiance was 15 mW/cm^2, leading to a maximal irradiation time of 11.1 minutes for 10 J/cm^2. During the irradiation, riboflavin was applied once after 5 minutes. Ultrasound pachymetry (SP-100; Tomey, Nagoya, Japan) at the thinnest point was performed before the UV irradiation to ensure a minimal corneal thickness of 400 μm.

Instruments and Acquisition

Scheimpflug images were acquired using Pentacam HR. In brief, Pentacam HR is a rotating Scheimpflug camera with a slit light (blue light emitting diode at 475 nm) that rotates around its axis of fixation and captures at least 25 images.[14] The MS-39 combines Placido disk corneal topography with high-resolution SD-OCT-based anterior segment tomography. This system achieves high-resolution imaging (axial >3.6 μm; transversal 35 μm).[15] The MS-39 acquires 1 Placido top-view image and a sequence of 12 SD-OCT transversal field sections using an 845-nm wavelength laser. Each 12-mm section is reconstructed from 1200 A-scans. Both devices automatically display the central corneal thickness (CCT) at the apex and the overall thinnest pachymetry value (TCT).

The scans were acquired sequentially under controlled environmental light conditions by a trained technician in accordance with the manufacturer's guidelines. Only scans meeting the acquisition quality criteria of the manufacturer (respectively quality specification of "OK" for the Pentacam HR and "✓" for the MS-39) were included. In addition, epithelial thickness values were acquired manually at the corneal apex from the epithelial thickness measurement map given by the MS-39.

Data Evaluation

Statistical analyses were performed using SPSS software (version 25.0, SPSS Inc) and WinSTAT for Excel

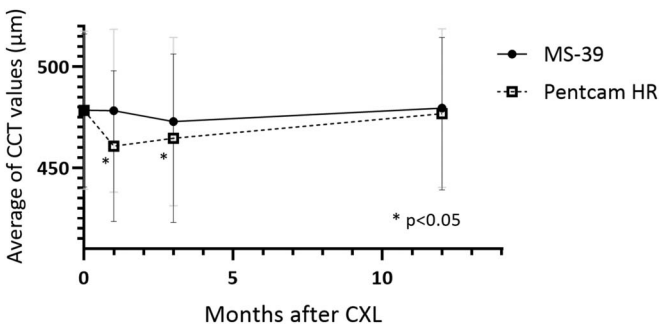

FIGURE 1. Changes in mean CCT ± SD over time after customized CXL. Circles and gray bars represent OCT-obtained thickness, and squares and black bars represent Scheimpflug-obtained thickness measurements.

Copyright © 2023 Wolters Kluwer Health, Inc. All rights reserved.

Copyright © 2023 Wolters Kluwer Health, Inc. Unauthorized reproduction of this article is prohibited.

TABLE 2. Mean ± SDs of TCT and Kmax by the Pentacam HR and the MS-39 Devices at Baseline and at All Follow-Up Visits After Customized Crosslinking and Their Differences (Δ)

	Pentacam HR	MS-39	Difference Δ	*P*
TCT [μm]				
Baseline	466.12 ± 37.25	464.84 ± 38.49	1.27	0.884
1 mo	449.12 ± 38.35*	460.59 ± 39.61	−11.46	**0.006**
3 mo	446.68 ± 43.63*	458.00 ± 40.89	−11.58	**0.007**
12 mo	460.29 ± 40.14	463.61 ± 38.62	−3.32	0.190
Kmax [D]				
Baseline	54.05 ± 6.76	52.77 ± 5.90	−1.27	**0.007**
1 mo	54.30 ± 7.42	53.39 ± 6.03	−0.91	**0.028**
3 mo	53.00 ± 6.63*	52.90 ± 6.23	−0.09	0.789
12 mo	52.72 ± 6.55*	52.05 ± 5.33*	−0.66	0.170
Epithelial thickness at the cornea apex [μm]				
Baseline	—	52.36 ± 8.18		
1 mo	—	56.35 ± 7.80*		
3 mo	—	53.12 ± 6.47		
12 mo	—	51.10 ± 6.24		

Apical epithelial thickness is given by the MS-39.
Bold indicates statistical significant difference is given if $p<0.05$
* is indicating statistically significant difference ($p<0.05$) from baseline.

(R. Finch Software, 2015). The CCT values calculated with Pentacam HR and MS-39 have been presented as mean ± SD. The Shapiro–Wilk test revealed that data were normally distributed for both devices at the different visits.

Postoperative changes in CCT for each device and differences along certain points in time were analyzed using repeated-measures ANOVA. The relationship between the 2 methods was further evaluated using Bland–Altman plotting.[16] Statistical significance was accepted if *P* values were less than 0.05.

Post hoc adjustments for multiple testing correction were performed using the false discovery rate method. To analyze whether our sample size was sufficient, a priori power analysis for the paired sample *t* test (change in CCT from preoperative measurement to measurement 3 months after surgery) was performed using G*Power 3.1.9.7. Considering an observed effect size of Cohen $d = 0.575$, alpha = 0.05, and $1 - ß = 0.9$, a sample size of 28 eyes was required.

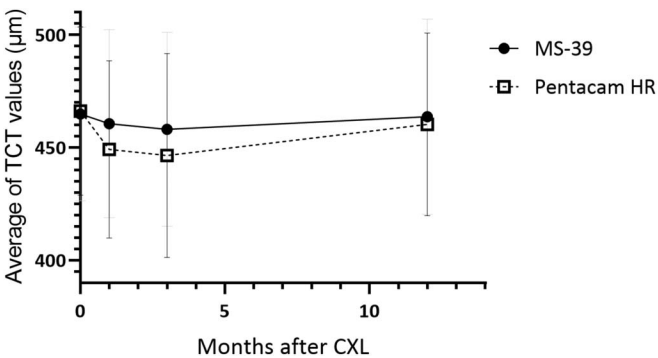

FIGURE 2. Changes in mean TCT ± SD over time after customized CXL. Circles and gray bars represent OCT-obtained thickness, and squares and black bars represent Scheimpflug-obtained thickness measurements.

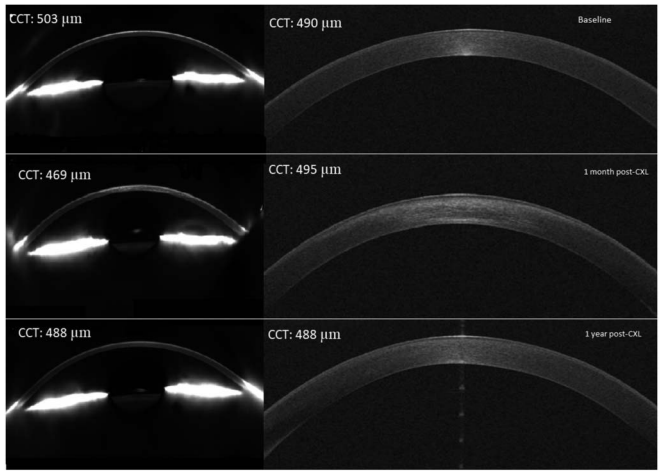

FIGURE 3. Representative case depicting Pentacam HR images (left) and MS-39 OCT scans (right) of a study participant. CCT measured by the MS-39 remains relatively unchanged throughout the follow-up period, whereas Pentacam HR displayed a massive thinning at month 1. Scans taken between 2- and 5-o'clock positions.

RESULTS

The mean age of the participants was 29.7 ± 11.4 years (range: 14–54) with 68% men. Based on the preoperative maximal anterior keratometry (Kmax) from the Pentacam HR, 6 eyes had a Kmax ≤ 48 D, 15 had a Kmax between 48D and 53D, and 12 eyes had a Kmax > 53D.

Changes in CCT

The mean CCT measurements by the Pentacam HR were statistically significantly lower at months 1 (460.65 μm; Δ −17.65 ± 15.71 μm; $P = 0.017$) and 3 (464.65 μm, Δ −13.65 ± 17.13 μm; $P = 0.009$) after CXL compared with the mean baseline readings of 478.30 μm. The lowest value was measured at month 1. Afterward, the measured mean CCT progressively increased and regained preoperative levels at 12 months (476.77 μm; Δ −1.53 ± 14.10 μm; $P = 0.628$; Table 1, Fig. 1). In comparison, CCT obtained with the MS-39 remained stable during the entire post-CXL observation time (baseline: 478.46 μm/month 1: 478.18 μm (Δ −0.28 ± 18.78 μm)/month 3: 472.89 μm (Δ −5.57 ± 13.42 μm)/month 12: 479.51 μm (Δ 1.05 ± 13.70 μm)), and no statistical significance was found (Table 1, Fig. 1). A similar, although less pronounced, trend was found for the thinnest corneal thickness (Table 2, Fig. 2).

Difference in CCT Between Pentacam HR and MS-39

At baseline, the difference of the mean CCT between both devices was not significant and substantially increased 1

Copyright © 2023 Wolters Kluwer Health, Inc. All rights reserved.

Copyright © 2023 Wolters Kluwer Health, Inc. Unauthorized reproduction of this article is prohibited.

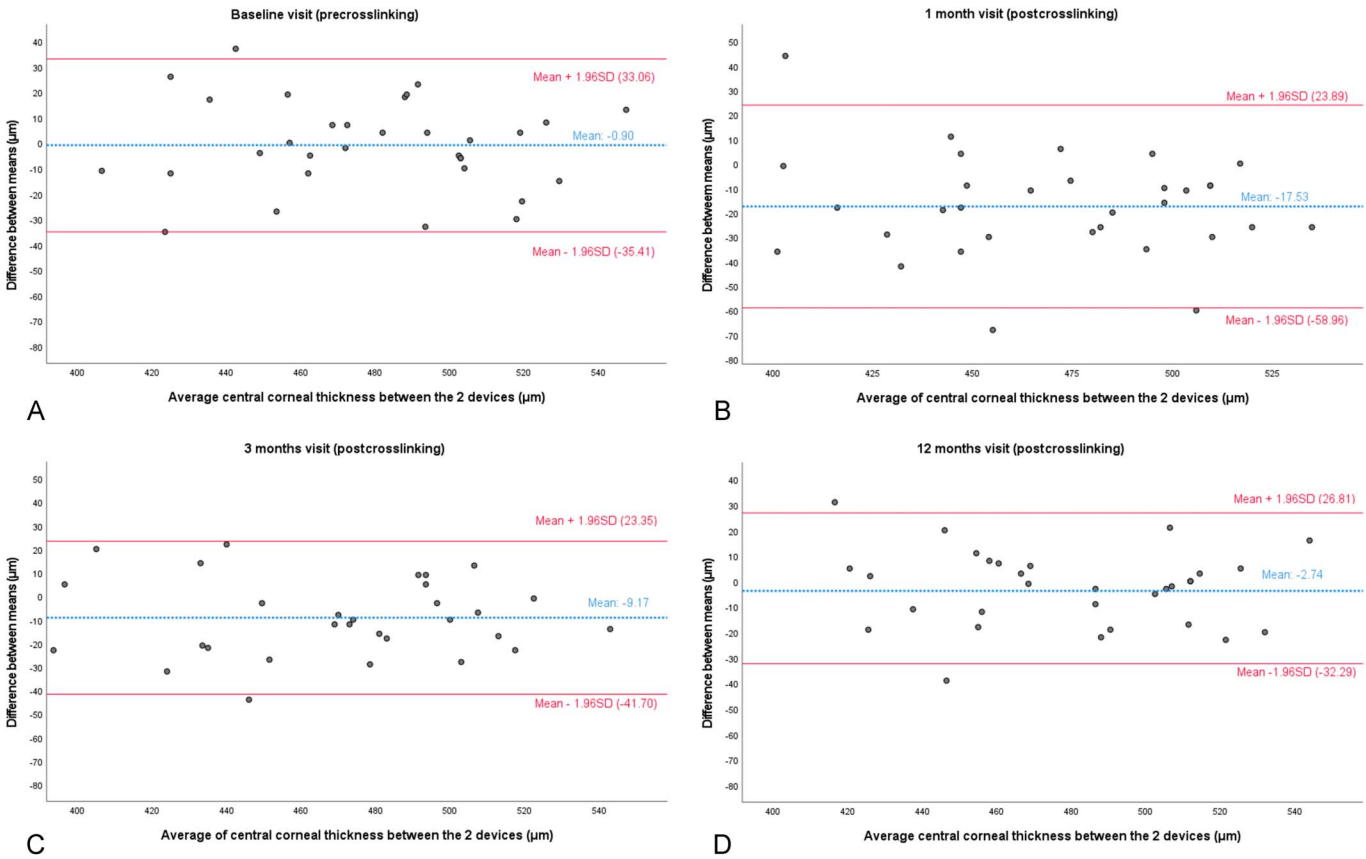

FIGURE 4. Bland–Altman plots including LoA between Pentacam HR and MS-39 preoperatively (A) and at every follow-up visit (B–D) after customized CXL. (The full color version of this figure is available at www.corneajrnl.com.)

month after CXL (difference 17.53 µm; $P = 0.004$). Thereafter, CCT of the Pentacam HR and MS-39 converged, but the difference was still statistically significant at month 3 (8.24 µm; $P = 0.006$) and showed no significant difference at 1 year. Once again, a similar trend was observed for the TCT (Table 2, Fig. 2). A representative clinical course is depicted in Figure 3.

Agreement Between Pentacam HR and MS-39

The respective Bland–Altman plots between both devices and the Bland–Altman 95% limits of agreement (LoA) are shown in Figure 4 and Table 3. The 95% LoA spiked at month 1 (worst agreement) with a very scattered Bland–Altman plot (−59 to 24 µm).

Behavior of Epithelial Thickness and Maximal Keratometry

A decrease of the maximal anterior keratometry (Kmax) could be distinguished during the first year after customized CXL (Table 2), even if this diminution was more marked in the Pentacam HR compared with the MS-39 (−1.32 D vs. −0.72 D). The evolution of the epithelial thickness at the apex is listed in Table 2. Remarkably, a significant increase of 3.99 µm was observed at month 1 ($P = 0.035$).

DISCUSSION

The main findings of the study were 1) after CXL, a postoperative corneal thinning is detected using Scheimpflug tomography, but not using OCT and 2) this corneal thinning detected by Scheimpflug tomography reversibly decreased during the first year after CXL. Accurate measurements of keratometry and corneal thickness are crucial for the follow-up of patients who underwent CXL and to detect a potential treatment failure in the postoperative course. Currently, a plethora of modalities are available to measure corneal thickness; ultrasound pachymetry (USP) being considered

TABLE 3. Differences in Mean Central Corneal Thickness (Pentacam HR Subtracted by MS-39), SD, and LoA Between Both Devices Calculated at Each Visit

CCT Difference Δ (µm)	Baseline	1 mo	3 mo	12 mo
Pentacam HR—MS-39	−0.90	−17.53	−8.24	−2.74
SD	17.60	21.13	16.60	15.08
95% LoA	−35.41 to 33.60	−58.96 to 23.89	−41.70 to 23.35	−32.28 to 26.81
P		**0.004**	**0.006**	0.798

Bold indicates statistical significant difference is given if $p<0.05$.

Copyright © 2023 Wolters Kluwer Health, Inc. All rights reserved.

Copyright © 2023 Wolters Kluwer Health, Inc. Unauthorized reproduction of this article is prohibited.

as the gold standard.[17] However, USP is a contact-mode procedure and does not provide maps of corneal thickness. Noncontact optical tomographers are usually calibrated by means of USP, but there is no consensus on which modality reflects most accurately corneal thickness, in particular for keratoconus and crosslinking patients, even if previous studies favored OCT-based pachymetries.[5,13,18]

Both examined devices yield similar preoperative corneal thickness measurements at the apex (CCT), as well as after 1 year following customized CXL, which is not surprising because both techniques are similarly calibrated by USP. Analyzing the CCT data at each follow-up visit reveals that Pentacam HR provides consistently lower CCT values peaking at 1 month. The difference gradually decreases with time over the 12-month follow-up period. Whether this apparent "transient corneal thinning" is real or merely an artifact of Scheimpflug imaging is still under debate. However, Antonios et al[19] found a significant difference of 32 μm between SD-OCT and dual Scheimpflug-based pachymetry at month 1 post-CXL, whereas no difference was observed between SD-OCT-obtained and USP-obtained CCT. Mencucci et al[20] showed that the Pentacam substantially underestimated corneal thickness measurements compared with USP by a mean of −19.5 μm, −15.6 μm, −17.9 μm, and −12.5 μm at 1, 3, 6, and 12 months, respectively. This suggests that Scheimpflug technology is underestimating CCT, whereas OCT values are closer to the real CCT. It is also known that Scheimpflug imaging provides biased pachymetry values when corneal haze is present, thus inducing a statistically significant diminution of the repeatability and reliability. The amount of bias is even correlated with the degree of haze.[13,19] The amount of backscattered light is substantially stronger for blue light compared with near-infrared light overloading the photosensors during the imaging of hazy corneas and, consequently, the identification of light steps (corneal surfaces) may become systemically wrong.[21] It is remarkable that this corneal thinning shows a similar temporal evolution like corneal haze after crosslinking as reported by Greenstein et al.[9,22] In contrast to transient corneal haze after CXL, permanent corneal scars show even a greater difference in CCT obtained by Scheimpflug and OCT of more than 65 μm as reported by Das et al.[21]

It would be beneficial to quantify the haze with both devices; however, currently, there is no dedicated software analysis of corneal scarring/haze included with the MS-39 and the evaluation remains only qualitatively at the discretion of the user. Recently, Dhaini et al[23] developed a software able to detect automatically and classify haze formation according to its intensity, area occupation, and location within the cornea. This could provide useful and objective information and is certainly an interesting field of research for years to come.

Although not being the primary focus of this study, we recorded the changes in the epithelial thickness at the corneal apex. Previously, it was shown that the MS-39 has the ability to accurately assess the corneal epithelial thickness in keratoconus eyes.[24] The data presented here show epithelial thickening at month 1 after crosslinking, followed by a subsequent return to baseline values. This is consistent with other previous reports[25] and explains the transient increase in Kmax at month 1.

The 2 major limitations of this study are its retrospective design which did not allow for the inclusion of ultrasound pachymetry measurements and the relatively small sample size. To the best of our knowledge, this study is the first to investigate the CCT and thinnest corneal thickness with the MS-39 in a population who underwent customized CXL and compare it with the Pentacam HR over the course of 1 year. In conclusion, the here presented results indicate that the Pentacam HR consistently underestimates the CCT in the postoperative course after CXL and we advise not to rely on pachymetry values obtained by Scheimpflug imaging during the first year after CXL because it could mislead to a suspicion of treatment failure or disease progression.

REFERENCES

1. Rabinowitz YS. Keratoconus. *Surv Ophthalmol.* 1998;42:297–319.
2. Belin MW, Villavicencio OF, Ambrósio RR, Jr. Tomographic parameters for the detection of keratoconus: suggestions for screening and treatment parameters. *Eye Contact Lens*. 2014;40:326–330.
3. Gomes JAP, Tan D, Rapuano CJ, et al. Group of Panelists for the Global Delphi Panel of Keratoconus and Ectatic Diseases. Global consensus on keratoconus and ectatic diseases. *Cornea*. 2015;34:359–369.
4. Borgardts K, Menzel-Severing J, Geerling G, et al. Treatment indications for corneal crosslinking and clinical results of new corneal crosslinking techniques. *Ophthalmologe*. 2022;119:350–357.
5. Seiler TG, Mueller M, Mendes Baiao T. Repeatability and comparison of corneal tomography in mild to severe keratoconus between the anterior segment OCT MS-39 and Pentacam HR. *J Refract Surg.* 2022;38:250–255.
6. Wollensak G, Spoerl E, Seiler T. Riboflavin/ultraviolet-a-induced collagen crosslinking for the treatment of keratoconus. *Am J Ophthalmol.* 2003;135:620–627.
7. Jain V, Gazali Z, Bidayi R. Isotonic riboflavin and HPMC with accelerated cross-linking protocol. *Cornea*. 2014;33:910–913.
8. Seiler TG, Fischinger I, Koller T, et al. Customized corneal cross-linking: one-year results. *Am J Ophthalmol.* 2016;166:14–21.
9. Greenstein SA, Fry KL, Bhatt J, et al. Natural history of corneal haze after collagen crosslinking for keratoconus and corneal ectasia: Scheimpflug and biomicroscopic analysis. *J Cataract Refract Surg.* 2010;36:2105–2114.
10. Altan-Yaycioglu R, Pelit A, Akova YA. Comparison of ultrasonic pachymetry with Orbscan in corneal haze. *Graefes Arch Clin Exp Ophthalmol.* 2007;245:1759–1763.
11. Boscia F, La Tegola MG, Alessio G, et al. Accuracy of orbscan optical pachymetry in corneas with haze. *J Cataract Refract Surg.* 2002;28:253–258.
12. Shetty R, Agrawal A, Deshmukh R, et al. Effect of post crosslinking haze on the repeatability of Scheimpflug-based and slit-scanning imaging devices. *Indian J Ophthalmol.* 2017;65:305–310.
13. Maloca PM, Studer HP, Ambrósio R, Jr, et al. Interdevice variability of central corneal thickness measurement. *PLoS One*. 2018;13:e0203884.
14. OCULUS, Inc. *Technical Data by Pentacam® Model*. Available at: https://www.pentacam.com/int/ophthalmologist-surgeon-without-pentacam/technology/technical-data.html?utm_content=leaderboard-eyetube-en%2525252525252525252525252525252525252525. Accessed April 24, 2022.
15. CSO Ophthalmic. *Technical Data of the MS-39 AS-OCT*. Available at: https://www.csoitalia.it/en/prodotto/info/63-ms-39-as-oct. Accessed April 24, 2022.
16. Bland JM, Altman DG. Statistical methods for assessing agreement between two methods of clinical measurement. *Lancet*. 1986;1:307–310.
17. Brumm MV, Shahzad MI. Corneal pachymetry. In: Copeland RA, Jr, Afshari N, eds. *Copeland and Afshari's Principles and Practice of Cornea*. 1st ed. Jaypee Brothers Medical Pub; 2013:109.
18. Prospero Ponce CM, Rocha KM, Smith SD, et al. Central and peripheral corneal thickness measured with optical coherence tomography, Scheimpflug imaging, and ultrasound pachymetry in normal,

Copyright © 2023 Wolters Kluwer Health, Inc. All rights reserved.

Copyright © 2023 Wolters Kluwer Health, Inc. Unauthorized reproduction of this article is prohibited.

keratoconus-suspect, and post-laser in situ keratomileusis eyes. *J Cataract Refract Surg.* 2009;35:1055–1062.
19. Antonios R, Fattah MA, Maalouf F, et al. Central corneal thickness after cross-linking using high-definition optical coherence tomography, ultrasound, and dual Scheimpflug tomography: a comparative study over one year. *Am J Ophthalmol.* 2016;167:38–47.
20. Mencucci R, Paladini I, Virgili G, et al. Corneal thickness measurements using time-domain anterior segment OCT, ultrasound, and Scheimpflug tomographer pachymetry before and after corneal cross-linking for keratoconus. *J Refract Surg.* 2012;28:562–566.
21. Das M, Menda SA, Panigrahi AK, et al. Repeatability and reproducibility of slit lamp, optical coherence tomography, and Scheimpflug measurements of corneal scars. *Ophthalmic Epidemiol.* 2019;26:251–256.
22. Greenstein SA, Shah VP, Fry KL, et al. Corneal thickness changes after corneal collagen crosslinking for keratoconus and corneal ectasia: one-year results. *J Cataract Refract Surg.* 2011;37:691–700.
23. Dhaini AR, Abdul Fattah M, El-Oud SM, et al. Automated detection and classification of corneal haze using optical coherence tomography in patients with keratoconus after cross-linking. *Cornea*. 2018;37:863–869.
24. Vega-Estrada A, Mimouni M, Espla E, et al. Corneal epithelial thickness intrasubject repeatability and its relation with visual limitation in keratoconus. *Am J Ophthalmol.* 2019;200:255–262.
25. Lautert J, Doshi D, Price Jr FW, et al. Corneal epithelial remodeling after standard epithelium-off corneal cross-linking in keratoconic eyes. *J Refract Surg.* 2018;34:408–412.

Copyright © 2023 Wolters Kluwer Health, Inc. All rights reserved.

Copyright © 2023 Wolters Kluwer Health, Inc. Unauthorized reproduction of this article is prohibited.