Safety and Efficacy of Surgical Correction of Anomalous Aortic Origin of Coronary Arteries: Experiences from two Tertiary Cardiac Centers

Fabio Pregaldini[1*], Hannah Widenka[1], Mohamed Barghout[2,3], Christoph Gräni[4], Martin Czerny[2,3], Fabian Kari[2,3], Salome Chikvatia[2,3], Alexander Kadner[1] and Matthias Siepe[1,2,3]

1. Center for Congenital Heart Disease, Department of Cardiac Surgery, Inselspital, Bern University Hospital, University of Bern, Switzerland

2. Clinic for Cardiovascular Surgery, University Heart Centre Freiburg-Bad Krozingen, Germany

3. Faculty of Medicine, Albert Ludwigs University Freiburg, Germany

4. Department of Cardiology, Inselspital, Bern University Hospital, University of Bern, Switzerland

*Corresponding author. Department of Cardiac Surgery, Inselspital, University Hospital Bern, Freiburgstrasse 18, 3010 Bern, Switzerland. Tel: +41-31-6322111; e-mail: fabio.pregaldini@insel.ch

The Abstract of this manuscript has been accepted for presentation at the 36th EACTS Annual Meeting, 5-8 October 2022, Milan, Italy.

Word count: 5195 words

Visual abstract:

Key question: Is correction for anomalous aortic origin of coronary artery (AAOCA) safe and effective?

Key findings: No cardiovascular mortality and 96% freedom from major complications. Symptom relief in 2/3 of the patients.

Take-home message: Surgical repair for AAOCA is efficient and safe and enables long-term relief of symptoms.

Central image: Symptom evolution after correction for AAOCA

Central image legend: Life-threatening symptoms: Acute heart failure, acute myocardial infarction, cardiac arrest. Severe symptoms: angina pectoris, ventricular arrhythmia, syncope. Moderate symptoms: atypical chest pain, dyspnea, or malaise.

ACCEPTED MANUSCRIPT

Downloaded from https://academic.oup.com/ejcts/advance-article/doi/10.1093/ejcts/ezad075/7078113 by Universitaetsbibliothek Bern user on 16 March 2023

source: https://doi.org/10.48350/180191 | downloaded: 12.10.2024

The Author(s) 2023. Published by Oxford University Press on behalf of the European Association for Cardio-Thoracic Surgery. All rights reserved.

Abstract

OBJECTIVES: This study aims to describe the outcomes of surgical correction for anomalous aortic origin of coronary artery (AAOCA) with regard to symptom relief.

METHODS: We performed a retrospective multicenter study including surgical patients who underwent correction for AAOCA between 2009 and 2022. Patients who underwent concomitant cardiac procedures were also included. However, to analyze symptom relief we only assessed the subgroup of symptomatic patients who underwent isolated correction for AAOCA.

RESULTS: A total of 71 consecutive patients (median age 55, range 12–83) who underwent surgical correction for AAOCA were included in the study. Right-AAOCA was present in 56 patients (79%), left-AAOCA in 11 patients (15%), single coronary ostium AAOCA in 4 patients (6%). Coronary unroofing was performed in 72% of the patients, coronary reimplantation in 28% and an additional neo-ostium patchplasty in 13% of the patients. In 39% of the patients a concomitant cardiac procedure was performed. During follow-up, no cardiovascular-related death was observed. Three patients (4.2%) had a myocardial infarction and underwent postoperative coronary artery bypass grafting. Six patients (8.5%) needed postoperative temporary mechanical circulatory support. Among the 34 symptomatic patients who underwent isolated AAOCA correction, 70% were completely asymptomatic after surgery, 12% showed symptom improvement and no symptom improvement was observed in 18% of the patients (median follow-up 3.5 years, range 0.3 – 11.1).

CONCLUSION: Correction for AAOCA can be safely performed with or without concomitant cardiac procedures. Performing AAOCA correction leads to a significant improvement in symptoms for most patients.

ACCEPTED MANUSCRIPT

Downloaded from https://academic.oup.com/ejcts/advance-article/doi/10.1093/ejcts/ezad075/7078113 by Universitaetsbibliothek Bern user on 16 March 2023

Keywords: Cardiac surgery · Anomalous aortic origin of coronary artery · Congenital · Outcome · Symptoms

ABBREVIATION

CCA	Coronary artery anomaly
AAOCA	Anomalous aortic origin of the coronary artery
CT	Computed tomography
MRI	magnetic resonance imaging
RCA	Right coronary artery
SCD	Sudden cardiac death
CABG	Coronary artery bypass grafting
CHD	Congenital heart disease
MACCE	Major adverse cardiac and cerebrovascular events
MI	Myocardial infarction
CAD	Coronary artery disease
MCS	Mechanical circulatory support
ECLS	Extracorporeal life-support system

ACCEPTED MANUSCRIPT

Downloaded from https://academic.oup.com/ejcts/advance-article/doi/10.1093/ejcts/ezad075/7078113 by Universitaetsbibliothek Bern user on 16 March 2023

INTRODUCTION

Coronary artery anomalies (CAA) are rare and frequently asymptomatic aberrations. Nowadays, such anomalies are often observed as incidental findings due to increased use of cardiac imaging techniques including cardiac computed tomography (CT), magnetic resonance imaging (MRI), and coronary artery angiography. A cardiac catheterization database analysis of 126,595 patients reported an incidence of 1.3% of coronary anomalies [1], whereas the incidence seems to be higher in noninvasive cardiac computed tomography at 2.1%[2].

The anomalous aortic origin of a coronary artery (AAOCA) with left main coronary artery originating from the right sinus of valsalva (left-AAOCA) or with the right coronary artery (RCA) originating from the left sinus of valsalva (right-AAOCA) is of particular interest. Both clinical studies and autopsy series show that right-AAOCA occurs more frequently than left-AAOCA[3].

AAOCA could be potentially dangerous and clinically relevant in presence of intramural course, slit-like ostia or unfavorable angulation since these anatomical anomalies expose the aberrant coronary artery to wall stress and reduce blood flow[4,5]. For this reason, AAOCA is associated with an increased risk of myocardial ischemia, ventricular arrhythmia, and sudden cardiac death[6].

Symptomatic patients or patients at risk of sudden cardiac death (SCD) are mainly treated surgically[7,8].

Several techniques have been proposed for the surgical management of AAOCA includinganatomical surgical correction by transposition and reimplantation of the anomalous coronary artery to the appropriate sinus[9], unroofing of the intramural course[10], transposition of the main pulmonary artery, and coronary artery bypass grafting[11-13].

ACCEPTED MANUSCRIPT

Downloaded from https://academic.oup.com/ejcts/advance-article/doi/10.1093/ejcts/ezad075/7078113 by Universitaetsbibliothek Bern user on 16 March 2023

Among these different approaches, coronary bypass grafting is increasingly viewed as the less favorable strategy in light of the potential competitive flow between the non-stenosed anomalous coronary artery and the bypass graft. Indeed, bypass graft failure for correction of AAOCA has often been reported, especially without proximal ligation of the native coronary artery[14].

On the other hand, both anatomical surgical correction and conservative observational options are appropriate for asymptomatic patients without evidence of ischemia or compromised coronary perfusion[15].

Due to the current lack of knowledge about the safety and efficacy of the surgical correction of AAOCA, there is still no general consent on the optimal management and a treatment recommendation has yet to be established[16].

The first aim of this study is to explore the general outcome and safety profile of surgical correction of AAOCA and the second is to determine its efficacy in terms of symptom relief.

MATERIALS AND METHODS

Ethics Statement

This study has been approved from the cantonal ethics committee in Bern, Switzerland (indentification nr: 2020-00841). Patients enrolled at the Bern University Hospital have given their written formal consent. Patients enrolled at the University Heart Centre Freiburg-Bad Krozingen have given their oral consent.

Methods

ACCEPTED MANUSCRIPT

Downloaded from https://academic.oup.com/ejcts/advance-article/doi/10.1093/ejcts/ezad075/7078113 by Universitaetsbibliothek Bern user on 16 March 2023

A retrospective review of all patients who underwent elective surgical correction of AAOCA at two tertiary centers (Bern University Hospital and University Heart Centre Freiburg-Bad Krozingen) between 2009 and 2022 was performed.

Patients with coronary anomalies other than AAOCA (e.g. fistula, anomalous left coronary artery from the pulmonary artery, and other CHD) were excluded. Furthermore, patients who underwent CABG instead of an anatomical surgical correction for AAOCA were excluded. This patients were also excluded, because usually CABG patients treated at our centers also suffered from an atherosclerotic coronary disease (CAD) and our therapeutic strategy is based on the assumption that CABG might not be an effective treatment for patients with AAOCA without any concomitant CAD.

Pre-, intra- and postoperative data was obtained from internal record review. The early outcome was assessed by review of the medical record during the postoperative hospital stay. Follow-up data was obtained by review of internal and outpatient records from primary cardiologists and by directly contacting the patients on the telephone. Review of medical records was approved by local hospital committees on clinical investigation.

Anatomical and symptomatic classification

Coronary anomalies were classified as right-AAOCA, left-AAOCA and single ostium AAOCA.

Surgical correction of AAOCA was defined as unroofing orcoronary reimplantation, with or without additional neo-ostium patchplasty.

Patients were divided among asymptomatic and symptomatic. Symptoms were classified as moderate, severe, or life threatening. Moderate symptoms were defined by atypical chest pain, dyspnea, or malaise; severe symptoms by angina pectoris, arrhythmia, or syncope. Acute

ACCEPTED MANUSCRIPT

Downloaded from https://academic.oup.com/ejcts/advance-article/doi/10.1093/ejcts/ezad075/7078113 by Universitaetsbibliothek Bern user on 16 March 2023

heart failure with pulmonary edema, acute myocardial infarction, and cardiac arrest were considered life threatening symptoms. The patients' symptoms were assessed by reviewing their preoperative medical record and their record at the last available follow up visit, or by directly contacting the patients on the telephone. Patients were normally seen 3 months after surgery and once yearly after that.

Study endpoints and subgroup analysis design

The primary endpoint of this study is the freedom from postoperative major adverse cardiac and cerebrovascular events (MACCE) during follow up time.

Major adverse cardiac and cerebrovascular events were defined by cardiovascular death, myocardial infarction (MI), and cerebrovascular accident. Myocardial infarction was defined as acute ventricular dysfunction with improvement after CABG procedure or with angiographic confirmation of acute coronary artery stenosis. Cerebrovascular accident was defined as neurological impairment confirmed by imaging.

The secondary endpoint is the freedom from symptoms after surgical correction of AAOCA. For this analysis, we considered a subgroup of symptomatic patients prior to surgery who underwent correction of AAOCA without any concomitant procedure. Patients with a follow-up shorter than 3 months were excluded.

Statistical analysis

For this study only a descriptive analysis was performed. The results are reported as the number and percentage for categorical variables and median(range) for continuous variables.

RESULTS

ACCEPTED MANUSCRIPT

Downloaded from https://academic.oup.com/ejcts/advance-article/doi/10.1093/ejcts/ezad075/7078113 by Universitaetsbibliothek Bern user on 16 March 2023

Patient characteristics

Surgical correction of coronary anomalies was performed in 153 patients between 2009 and 2022. After application of exclusion criteria, 71 patients were included in the final analysis (figure 1). Patient baseline characteristics are presented in Table 1. The median age was 55 years (range 12- 83 years) and 41% were female.

Right-AAOCA was observed in 56 patients (79%), left-AAOCA in 11 patients (15%), single coronary ostium AAOCA in 4 patients (6%), of which 2 presenting left single coronary ostium and 2 presenting right single coronary ostium.

In the entire cohort, 5 patients were asymptomatic prior to intervention. Symptoms were observed in 93% (n=66) of the patients; 42% (n=30) had moderate symptoms, 42 % (n=30) had severe symptoms and 8.5% (n=6) life threatening symptoms, respectively.

The indication for correction of AAOCA was mainly due to symptoms and/or anatomical high-risk characteristics such as long intramural course between the aorta and pulmonary artery.

Types of surgical corrections of AAOCA

Coronary unroofing was performed in 72% of the patients (n=51), coronary reimplantation in 28% of the patients (n=20), and an additional neo-ostium patchplasty was performed in 13% of the patients (n=9). From the entire cohort, 39% of the patients underwent a concomitant procedure (n=28). The most common concomitant procedure was aortic valve replacement (n=9). Surgical data is shown in Table 2.

Early results

At hospital discharge, the survival rate was 100% and freedom from MACCE was 95.8% (n=68). Six patients (8.5%) needed temporary mechanical cardiocirculatory support (MCS) after

ACCEPTED MANUSCRIPT

Downloaded from https://academic.oup.com/ejcts/advance-article/doi/10.1093/ejcts/ezad075/7078113 by Universitaetsbibliothek Bern user on 16 March 2023

surgery. Of these, 3 suffered from myocardial infarction (MI) and presented hemodynamic instability. Two other patients presented severely impaired left ventricular function prior to surgery and a direct weaning from CPB was not possible. The last patient suffered from ventricular fibrillation after surgery and needed MCS; in the following coronary angiography no coronary stenosis was observed. An overview of the patients needing postoperative MCS is shown in Table 3.

One of the patients who suffered from postoperative MI was a young female who underwent unroofing of R-AACOA. After an initially stable early postoperative course, this patient developed severe biventricular dysfunction and needed resuscitation. Because of persisting hemodynamic instability, the patient had to be put on ECLS and a CABG using the right thoracic artery on the RCA was performed. The biventricular function improved after reperfusion but the patient needed MCS for two further days. The coronary angiography performed after the patient was stabilized showed a wide-open right coronary artery. The cause of the patient's postoperative hemodynamic difficulty remains unknown.

The second patient was a 65-year old male who underwent unroofing of R-AAOCA with concomitant aortic valve replacement. This patient similarly presented an initially stable postoperative course but showed progressive low cardiac output and developed ventricular fibrillation needing resuscitation 12 hours after surgery. The coronary angiography showed an ostial occlusion of the corrected R-AAOCA, which was treated with emergency CABG using a vein on the RCA without revision of the neo ostium. After reperfusion, the patient showed improvement in the biventricular function. In order to improve coronary perfusion, an intra-aortic balloon pump was implanted.

The last MI patient was a 75 year old female who underwent a complex unroofing procedure with extended commissural manipulation in order to create the neo ostium. Since the patient

ACCEPTED MANUSCRIPT

Downloaded from https://academic.oup.com/ejcts/advance-article/doi/10.1093/ejcts/ezad075/7078113 by Universitaetsbibliothek Bern user on 16 March 2023

developed ventricular fibrillation briefly after sternal closure, a re-sternotomy was performed. The patient was put on CPB and a CABG using a vein on the RCA was performed. Unfortunately, no postoperative diagnostic cardiac imaging confirming coronary stenosis is available for this patient. However, because of the sudden and early onset of ventricular fibrillation after surgery, we believe that MI was probably caused by aninsufficient neo ostium. All these 3 patients recovered completely after surgery and presented no residual symptoms at the last follow-up.

Two further patients needed early re-intervention. The first of the two patients needed reinterventiondue to bleeding with pericardial tamponade. The second patient needed a pacemaker implantation following a complete atrioventricular block after correction of right AAOCA with concomitant removal of a myxoma from the left atrium. An overview of complications is shown in Table 4.

Late results

Eight patients (11.3%) were lost to follow-up after hospital discharge. Median follow-up was 3.1 years (range 0.1 – 12.4 years). In the course of long-term follow-up, 5 patients died. One patient died of COPD exacerbation at 62 years (8 years after surgery), 2 patients died of SARS-COVID-19 infection at 70 years (5.5 years after surgery) and at 73 years (2.5 years after surgery) respectively, and 2 patients died of unknown causes at 72 years (3 months after surgery) and at 61 years (3.9 years after surgery) respectively. No late major adverse cardiac and cerebrovascular events in the patients with complete follow-up were observed. Two patients underwent late reoperation due to sternal infection. One patient who underwent CABG after AAOCA correction died of SARS-COVID-19 infection 5.5 years after the re-operation, and 1 patient who underwent reimplantation for a left single coronary ostium died of unknown causes 3.9 years after surgery.

ACCEPTED MANUSCRIPT

Downloaded from https://academic.oup.com/ejcts/advance-article/doi/10.1093/ejcts/ezad075/7078113 by Universitaetsbibliothek Bern user on 16 March 2023

Subgroup analysis for isolated AAOCA correction in symptomatic patients

Thirty-four patients (48%) were considered eligible for this subgroup analysis (Figure 1). Patient characteristics and surgical data are shown in Table 5. Of the 34 patients, 38% (n=13) showed moderate symptoms, 50% (n=17) severe symptoms, and 12% (n=4) life threatening symptoms. The median follow-up after surgical correction of symptomatic AAOCA is complete and corresponds to 3.5 years (range 0.3 – 11.5).

At last follow-up, 70 % (n=24) of the patients were completely asymptomatic (Figure 2). In 12 % (n=4) of the patients, no complete symptom relief was observed. In 18 % (n=6) of the patients, no symptom improvement was found.

Of the 10 patients who were still symptomatic after surgery, 8 underwent unroofing of R-AAOCA, 1 reimplantation of R-AAOCA and 1 reimplantation of L-AAOCA. In 6 patients postoperative coronary imaging was performed (3 MRI, 2 CT scans and 1 coronary angiography). In all these exams, the coronaries did no present any stenoses. In 4 of these 6 cases additional testing for ischemia was performed (2 cardiac stress MRI, 2 cardiac stress echocardiographies). The results of all the 4 exams revealed no sign of myocardial ischemia.

Of the remaining 4 patients, 2 underwent ergometry which presented negative results. In the last 2 patients no further diagnostic tests were performed.

ACCEPTED MANUSCRIPT

DISCUSSION

This study reports the experience and outcome for surgical correction of AAOCA in a heterogeneous cohort with various concomitant cardiac pathologies in two tertiary cardiovascular centers.

Downloaded from https://academic.oup.com/ejcts/advance-article/doi/10.1093/ejcts/ezad075/7078113 by Universitaetsbibliothek Bern user on 16 March 2023

Congenital coronary anomalies are rare and surgical correction of AAOCA is not a frequent procedure. In the literature, there are only few studies with a larger cohort compared to this study. Jegatheeswaran et al.[17] and Padalino et al.[18] presented both a large multicenter study including 395 and 156 patients respectively. Other relevant studies on the topic presented a cohort more similar to the one analyzed for this study[19,20].

As far as follow-up duration is concerned, there are only few studies with a duration longer than 5 years[19,21]. The duration of the follow-up period taken into account by most studies is of 2 years or less[17,19,23]. To our best knowledge, symptom relief has never been investigated in as thoroughly as in the present study.

Similarly to previous studies, this research found a comparable distribution of AAOCA subtypes, with the majority of patients showing a R-AAOCA (79%)[17-20;22-26]. Equally, the majority of patients (93%) were symptomatic. Additional cardiac pathologies were present in 41% of the patients. The most frequent concomitant pathology was aortic valve regurgitation (17%). While this is consistent with the results reported by Padalino et al., other studies, probably due to the younger age of their cohorts, found additional cardiac pathologies less frequently, the majority of which were congenital cardiac diseases[19,20,24]. Since this study focused mainly on adult patients, the median age of our patient cohort is 55 years and, in contrast to the average age of most studies on AACOA, which involve patients younger than 30[17,18,21-23].

The increasing age of patients operated for AAOCA is might also be attributable to the use of increasingly accurate and frequent cardiac diagnostic techniques, more precisely more sensitive and specific imaging and stress tests. Similarly, the improvement of surgical techniques with reported outcomes and complication rates might result in greater preference

ACCEPTED MANUSCRIPT

Downloaded from https://academic.oup.com/ejcts/advance-article/doi/10.1093/ejcts/ezad075/7078113 by Universitaetsbibliothek Bern user on 16 March 2023

for surgery over conservative treatment. Furthermore, increased physical activity in old age may expose an ageing population to the risk of myocardial ischemia and sudden cardiac death.

However, this is very speculative, and the pathomechanism for which AAOCA may still be relevant in old age is still unclear.

As far as corrective surgical techniques are concerned, the vast majority of patients underwent either unroofing (72%) or reimplantation (28%), with or without patchplasty of the neo-ostium. The preferred approach in the analyzed cohort was the performance of unroofing of the intramural course, and coronary reimplantation was mostly performed when unroofing would have required commissural detachment or when the intramural coronary course had a very small caliber. In these cases, an additional patch osteoplasty was sometimes performed to create an adequate neo ostium. No pulmonary translocation was performed since coronary reimplantation in the proper sinus was preferred.

Patients who underwent CABG as correction for AAOCA were excluded from this study. We are convinced that CABG presents the least favorable option for the treatment of AAOCA; first, in light of frequently reported high graft failure due to competitive flow[14,27] and, second, because at the two cardiac centers involved in this study CABG is not considered an effective treatment in elective cases. When atherosclerotic coronary disease was observed in the anomalous coronary artery, CABG was preferred in both centres.

Although 30-day mortality was 0%, a high rate of postoperative complications was observed, with 15 adverse events occurring in 10 patients (Table 4). Previous studies have reported a large variability of complication rates, ranging between 0% and 67%[10,28,29].

Three patients required emergency CABG for suspected failure of the coronary correction and hemodynamic instability and 6 (8.5%) patients required MCS for various reasons. Other

ACCEPTED MANUSCRIPT

Downloaded from https://academic.oup.com/ejcts/advance-article/doi/10.1093/ejcts/ezad075/7078113 by Universitaetsbibliothek Bern user on 16 March 2023

studies have shown a lower rate of postoperative CABG procedure or MCS after AAOCA correction.

Padalino et al.[18] described an MCS rate of 3.8% after surgery in a population slightly younger than our cohort (mean age at surgery 39.5 years). Jegatheeswaran et al.[17] showed a postoperative MCS rate of 0.3% in a much younger population despite a composite risk of surgical adverse events of 13%, while a study by Sharma et al.[20] indicated a comparable rate of 3% for CABG after AAOCA correction.

We assume that the elevated rate of MCS employment and CABG procedures performed in this cohort is attributable to a high rate of patients with preexisting impaired heart function and need for concomitant procedures as well as to the high median age of the cohort. Technical failure after correction of AAOCA is rare but it can lead to serious complications such as MI. This was the case for at least 2 of the patients (2.8%) in this cohort. The postoperative management of these patients can be challenging. An optimal postoperative coronary perfusion should be the primary goal in order to avoid myocardial ischemia, which can lead to malignant arrhythmia.

In order to assess the efficacy in reducing the symptoms after correction of AAOCA, we analyzed a subgroup of 34 patients who were symptomatic prior to surgery and underwent isolated AAOCA correction. At a median follow-up of 3.5 years (range 0.3 – 11.1), 70% of the patients were asymptomatic. The management of patients who were still symptomatic after correction of AAOCA is challenging. In our cohort, we could rule out a coronary origin of the symptoms in 60% of these patients. In the remaining symptomatic patients, insufficient diagnostics was performed (i.e. ergometry only). The lack of data and evaluation of the potential persistence of myocardial ischemia in these patients presents a limitation. A technical failure of the correction of AAOCA cannot be excluded in these patients. However,

ACCEPTED MANUSCRIPT

Downloaded from https://academic.oup.com/ejcts/advance-article/doi/10.1093/ejcts/ezad075/7078113 by Universitaetsbibliothek Bern user on 16 March 2023

in many cases, the persistence of dyspnea, syncope or chest pain was attributed to associated comorbidities, such as COPD, epilepsy, or post cardiotomy syndrome rather than myocardial ischemia. Importantly, to the best of our knowledge SCD did not occur in the whole cohort during follow-up.

In the literature, the percentage of patients becoming asymptomatic after correction of AAOCA ranges from 54% to 100%. Nevertheless, symptoms suggestive of cardiac ischemia do not always correlate with positive cardiac stress tests. In the study by Sachdeva et al.[26], 46% of patients were found to be symptomatic after surgery, but among these patients there were also some previously asymptomatic patients who developed symptoms only after surgery. In the postoperative cardiac stress analysis, most of the symptomatic cases did not show signs of ischemia. On the other hand, patients without symptoms after surgery may still show signs of cardiac ischemia[23]. Therefore, both symptomatic and asymptomatic patients should be followed regularly regarding possible onset of cardiac ischemia.

Management of AAOCA remains controversial due to limited data and the consequent lack of evidence-based guidelines. Generally, surgical treatment is recommended for cases of symptomatic AAOCA causing myocardial ischemia. However, for a large proportion of asymptomatic AAOCA patients with an anatomical morphology considered to be associated with the risk of SCD or unrecognized ischemia, the decision to proceed with a surgical intervention is difficult and is associated with uncertainty regarding the outcome of surgical correction. Moreover, the increasing employment of cardiac imaging will most likely lead to more asymptomatic patients with an incidental diagnosis of AAOCA.

Surgical correction of AAOCA as reported in this study is an efficient procedure for most patients and is associated with very low mortality. However, the observed complication rate

ACCEPTED MANUSCRIPT

Downloaded from https://academic.oup.com/ejcts/advance-article/doi/10.1093/ejcts/ezad075/7078113 by Universitaetsbibliothek Bern user on 16 March 2023

is relevant and should not be ignored. Consequently, patient selection, counseling, and the decision to proceed with a surgical intervention is of greatest importance. Ideally, treatment, work-up, and discussion of AAOCA patients should be performed by a dedicated interdisciplinary team of experts. We also believe that patients with coronary artery anomalies might profit from a structure of combined congenital and adult cardiac surgery programs. Recently, our group proposed a systematic diagnostic work-up and decision-making algorithm, which might function to assist in the treatment of AAOCA patients[30]. However, most importantly, the acquisition of more multicentric data and reports on experience with the treatment of this rather rare malformation is necessary in order to improve treatment and outcome of AAOCA surgery.

Limitations

This is a retrospective study with its intrinsic limitations. The choice of whether to treat patients surgically was not driven by a protocol at the time of selection and might have been slightly different between the two centers. The assessment of symptoms is subjective and its interpretation should be careful. Lack of objective evidence for the elimination of ischemia is certainly a limitation of the study. Due to incomplete follow-up, it is possible that complications, especially in the long term, have been underestimated. Although our 3-year follow-up may be sufficient for symptom assessment, a longer follow-up is definitely necessary to ascertain whether the onset of atherosclerosis may have an influence on surgical correction of AAOCA.

CONCLUSIONS

ACCEPTED MANUSCRIPT

Downloaded from https://academic.oup.com/ejcts/advance-article/doi/10.1093/ejcts/ezad075/7078113 by Universitaetsbibliothek Bern user on 16 March 2023

Anatomic correction of AAOCA with unroofing or coronary reimplantation is safe. It can be performed with low morbidity and mortality even in combination with other cardiac operations showing satisfying rates of freedom from coronary-related reintervention. Most patients can benefit from this procedure in terms of symptom relief. More multicenter studies and prospective analyses are needed to improve the general patient selection process in order to accurately counsel and treat patients with AAOCA.

Conflict of interest: Dr. Gräni receives funding from the Swiss National Science Foundation grant number 320030 200871/1. Further Dr. Gräni receives funding from the InnoSuisse, the Center of Artificial Intelligence University Bern and the GAMBIT foundation, outside of the submitted work.

Data Availability Statement: *The data underlying this article will be shared on reasonable request to the corresponding author.*

Author contribution

Fabio Pregaldini: Conceptualization; Data curation; Formal analysis; Investigation; Methodology; Software; Validation; Visualization Writing-Original draft. **Hannah Widenka:** Conceptualization**,** Investigation, Validation; Writing-Original draft. **Mohamed Barghout:** Data curation**,** Validation; Writing-Original draft. **Christoph Gräni:** request of ethical committee approval, Writing-Original draft**,** Validation**. Martin Czerny:** Supervision, Validation. **Fabian Kari:** Supervision, Data curation, Validation. **Salome Chikvatia:** Data curation**,** Validation. **Alexander Kadner:** Conceptualization; Data curation; Formal analysis; Investigation; Methodology; Supervision; Validation; Writing-Original draft. **Matthias Siepe:** Conceptualization, Data curation; Investigation; Methodology; Project administration, Supervision; Validation; Visualization; Writing-Original draft.

ACCEPTED MANUSCRIPT

Downloaded from https://academic.oup.com/ejcts/advance-article/doi/10.1093/ejcts/ezad075/7078113 by Universitaetsbibliothek Bern user on 16 March 2023

Tables

Table 1: Baseline characteristics	All
	n = 71 (100%)
Age (years)	55 (range 12 – 83)
Sex (female)	29 (41%)
Type of coronary anomaly	
Right-AAOCA	56 (79 %)
Left-AAOCA	11 (15%)
Left single coronary ostium	2 (3%)
Right single coronary ostium	2 (3%)
Symptoms	
Asymptomatic	5 (7%)
Moderate	32 (45%)
Severe	29 (41%)
Life threatening	5 (7%)
Patients with concomitant cardiac diseases	29 (41%)
Cumulative cardiac pathologies	44 (100%)
Aortic valve regurgitation	12 (27%)
Aortic valve stenosis	6 (14%)
Mitral valve regurgitation	7 (16%)
Coronary artery disease in other vessels	10 (23%)
Aortic aneurysm	8 (18%)
Atrial septum defect	1 (2%)
Cardiovascular risk factors	
Positive family history	21 (30%)
Smoking	29 (41%)
Hypertension	38 (54%)
Diabetes	10 (14%)
Adipositas	18 (25%)
Dyslipidemia	30 (42%)

ACCEPTED MANUSCRIPT

Downloaded from https://academic.oup.com/ejcts/advance-article/doi/10.1093/ejcts/ezad075/7078113 by Universitaetsbibliothek Bern user on 16 March 2023

Table 2: Surgical data	n = 71 (100%)
Types of AAOCA correction	
Unroofing	51 (72%)
Reimplantation	20 (28%)
Additional neo-ostium patchplasty	9 (13%)
Patients who underwent concomitant procedures	28 (39%)
Concomitant procedures	30
Aortocoronary bypass grafting (of the non anomalous coronary artery)	2 (3%)
Aortic valve replacement	9 (13%)
Valve sparing aortic root replacement	3 (4%)
Aortic root replacement with composite graft	5 (7%)
Aortic valve repair	1 (1%)
Aortic arch replacement	3 (4%)
Supracoronary ascending aorta replacement	1 (1%)
Mitral valve repair	4 (6%)
Atrial myxoma removal	1 (1%)
Atrial septum defect closure	1 (1%)

ACCEPTED MANUSCRIPT

Downloaded from https://academic.oup.com/ejcts/advance-article/doi/10.1093/ejcts/ezad075/7078113 by Universitaetsbibliothek Bern user on 16 March 2023

Table 3: Pre-Op and perioperative data as follow-up data of patients who needed temporary mechanical support after surgery

Patient	Age at surgery (years)	Type of AAOCA	Type of AAOCA correction	Concomitant procedure	Pre-OP LVEF function (%)	Indication for MCS	Type of post-OP temporary MCS	Re-operation	Follow up
1	15	R-AAOCA	Coronary unroofing		60%	MI	ECMO	CABG	Recovered
2	79	R-AAOCA	Coronary reimplantation	Aortic root replacement with a composite graft and mitral valve repair	30%	Difficult weaning from CPB	ECMO		Recovered
3	75	R-AAOCA	Coronary unroofing		60%	MI	ECMO	CABG	Recovered
4	66	R-AAOCA	Coronary unroofing		60%	Ventricular fibrillation after surgery	ECMO		Recovered
5	65	R-AAOCA	Coronary unroofing	Aortic valve replacemnt	60%	MI	IABP	CABG	Late non cardiovascular death*
6	57	Left single coronary ostium	Coronary reimplantation	Aortic root replacement with a composite graft	30%	Difficult weaning from CPB	IABP		Late unknown cause of death**

* Death of SARS-Covid 19 5.5 years after surgery
** Unknown cause of death 3.9 years after surgery

MCS: mechanical circulatory support; MI: myocardial infarction; CPB: cardiopulmonary bypass, CABG: coronary artery bypass grafting. ECMO: extracorporeal membrane oxygenation; IABP: intra-aortic balloon pump

ACCEPTED MANUSCRIPT

Downloaded from https://academic.oup.com/ejcts/advance-article/doi/10.1093/ejcts/ezad075/7078113 by Universitaetsbibliothek Bern user on 16 March 2023

Table 4: Postoperative complications

	Early (< 30d)	Late (> 30d)
Cardiovascular death	0	0
Death other than cardiovascular	0	3
Unknown cause of death	0	2
Myocardial infarction	3	0
Stroke	1	0
Reoperation		
Coronary artery bypass grafting	3	0
Pericardial drain due to tamponade	1	0
Sternal wound infection	0	2
Pacemaker implantation	1	0
Cardiovascular mechanical support		
ECMO	4	0
IABP	2	0

ECMO: extracorporeal membrane oxygenation; IABP: intra-aortic balloon pump

ACCEPTED MANUSCRIPT

Downloaded from https://academic.oup.com/ejcts/advance-article/doi/10.1093/ejcts/ezad075/7078113 by Universitaetsbibliothek Bern user on 16 March 2023

Table 5: Pre- and perioperative data of the subgroup

	n = 34 (100%)
Age in years, median (range)	53y (Range 12 - 78)
Sex (female)	14 (41%)
Types of coronary anomaly	
Right-AAOCA	27 (79 %)
Left-AAOCA	5 (15%)
Left Single coronary ostium	2 (6%)
Types of correction for AAOCA	
Unroofing	25 (74%)
Coronary reimplantation	9 (26%)
Additional neo-ostium patchplasty	6 (18%)
Pre-operative symptoms	
Asymptomatic	0
Moderate	13 (38%)
Severe	17 (50%)
Life threatening	4 (12%)
Cardiovascular risk factors	
Positive family history	8 (24%)
Smoking	16 (47%)
Hypertension	18 (51%)
Diabetes	2 (6%)
Adipositas	8 (23%)
Dyslipidemia	13 (37%)

Table 5 shows the pre- and perioperative data of the subgroup of symptomatic patients who underwent correction for AAOCA without any concomitant cardiac procedure

ACCEPTED MANUSCRIPT

Downloaded from https://academic.oup.com/ejcts/advance-article/doi/10.1093/ejcts/ezad075/7078113 by Universitaetsbibliothek Bern user on 16 March 2023

REFERENCES

1. Yamanaka O, Hobbs R. Coronary artery anomalies in 126,595 patients undergoing coronary arteriography. Cathet Cardiovasc Diagn 1990;21:28-40.
2. Mostefa Kara M, Fournier E, Cohen S, Hascoet S, Van Aerschot I, Roussin R, et al. Anomalous aortic origin of coronary arteries: is the unroofing procedure always appropriate? Eur J Cardiothorac Surg. 2021 Apr 13;59(3):705-710.
3. Gräni C, Benz D, Steffen D, Clerc O, Schmied C, Possner M, et al. Outcome in middle-aged individuals with anomalous origin of the coronary artery from the opposite sinus: a matched cohort study. Eur Heart J. 2017 Jul 1;38(25):2009-2016.
4. Borns J, Gräni C, Kadner A, Gloeckler M, Pfammatter J. Symptomatic Coronary Anomalies and Ischemia in Teenagers - Rare but Real. Front Cardiovasc Med. 2020 Sep 22;7:559794.
5. Bigler M, Ashraf A, Seiler C, Praz F, Ueki Y, Windecker S, et al. Hemodynamic Relevance of Anomalous Coronary Arteries Originating From the Opposite Sinus of Valsalva-In Search of the Evidence. Front Cardiovasc Med. 2021 Jan 21;7:591326.
6. Eckart R, Shry E, Burke A, McNear J, Appel D, Castillo-Rojas L, et al. Sudden death in young adults: an autopsy-based series of a population undergoing active surveillance. J Am Coll Cardiol. 2011;58:1254–61.
7. Krasuski R, Magyar D, Hart S, Kalahasti V, Lorber R, Hobbs R, et al. Long-term outcome and impact of surgery on adults with coronary arteries originating from the opposite coronary cusp. Circulation. 2011;123:154–62.
8. Bigler M, Gräni C. To screen or not to screen - and other pending questions within the enigma of coronary artery anomalies. Trends Cardiovasc Med. 2022 Jun 9:S1050-1738(22)00085-8.
9. Di Lello F, Mnuk J, Flemma R, Mullen D. Successful coronary reimplantation for anomalous origin of the right coronary artery from the left sinus of Valsalva. J Thorac Cardiovasc Surg. 1991 Sep;102(3):455-6
10. Romp R, Herlong J, Landolfo C, Sanders S, Miller C, Ungerleider R, et al. Outcome of unroofing procedure for repair of anomalous aortic origin of left or right coronary artery. Ann Thorac Surg. 2003 Aug;76(2):589-95; discussion 595-6.
11. Gräni C, Kaufmann P, Windecker S, Buechel R. Diagnosis and Management of Anomalous Coronary Arteries with a Malignant Course. Interv Cardiol. 2019 May 21;14:83-88
12. Brandt B, Martins J, Marcus M. Anomalous origin of the right coronary artery from the left sinus of Valsalva. N Engl J Med. 1983 Sep 8;309:596-8
13. Ghosh P, Agarwal S, Kumar R, Chandra N, Puri V. Anomalous origin of right coronary artery from left aortic sinus. J Cardiovasc Surg (Torino). 1994 Feb;35(1):65-70
14. Fedoruk L, Kern J, Peeler B, Kron I. Anomalous origin of the right coronary artery: right internal thoracic artery to right coronary artery bypass is not the answer. J Thorac Cardiovasc Surg. 2007 Feb;133(2):456-60.
15. Gräni C, Buechel R, Kaufmann P, Kwong R. Multimodality Imaging in Individuals With Anomalous Coronary Arteries. JACC Cardiovasc Imaging. 2017 Apr;10(4):471-481.
16. Stout K, Daniels C, Aboulhosn J, Bozkurt B, Broberg C, Colman J, et al. 2018 AHA/ACC Guideline for the Management of Adults With Congenital Heart Disease: Executive Summary: A Report of the American College of Cardiology/American

ACCEPTED MANUSCRIPT

Downloaded from https://academic.oup.com/ejcts/advance-article/doi/10.1093/ejcts/ezad075/7078113 by Universitaetsbibliothek Bern user on 16 March 2023

Heart Association Task Force on Clinical Practice Guidelines. J Am Coll Cardiol. 2019 Apr 2;73(12):1494-1563. doi: 10.1016/j.jacc.2018.08.1028. Epub 2018 Aug 16. Erratum in: J Am Coll Cardiol. 2019 May 14;73:2361. PMID: 30121240.
17. Jegatheeswaran A, Devlin P, Williams W, Brothers J, Jacobs M, DeCampli W, et al. Outcomes after anomalous aortic origin of a coronary artery repair: A Congenital Heart Surgeons' Society Study. J Thorac Cardiovasc Surg. 2020 Sep;160(3):757-771
18. Padalino M, Franchetti N, Hazekamp M, Sojak V, Carrel T, Frigiola A, et al. Surgery for anomalous aortic origin of coronary arteries: a multicentre study from the European Congenital Heart Surgeons Association†. Eur J Cardiothorac Surg. 2019 Oct 1;56(4):696-703
19. Mainwaring R, Reddy V, Reinhartz O, Petrossian E, Punn R, Hanley F. Surgical repair of anomalous aortic origin of a coronary artery. Eur J Cardiothorac Surg. 2014 Jul;46(1):20-6
20. Sharma V, Burkhart H, Dearani J, Suri R, Daly R, Park S, et al. Surgical unroofing of anomalous aortic origin of a coronary artery: a single-center experience. Ann Thorac Surg. 2014 Sep;98(3):941-5
21. Courand P, Bozio A, Ninet J, Boussel L, Bakloul M, Galoin-Bertail C, et al. Diagnosis and treatment of anomalous aortic origin of coronary artery: A twenty-year retrospective study of experience and decision-making in children and young adults. Int J Cardiol. 2021 Aug 15;337:54-61
22. Fabozzo A, DiOrio M, Newburger J, Powell A, Liu H, Fynn-Thompson F, et al. Anomalous Aortic Origin of Coronary Arteries: A Single-Center Experience. Semin Thorac Cardiovasc Surg. 2016 Winter;28(4):791-800.
23. Feins E, DeFaria Yeh D, Bhatt A, Stefanescu A, Youniss M, Ghoshhajra B, et al. Anomalous Aortic Origin of a Coronary Artery: Surgical Repair With Anatomic- and Function-Based Follow-Up. Ann Thorac Surg. 2016 Jan;101(1):169-75
24. Mery C, De León L, Molossi S, Sexson-Tejtel S, Agrawal H, Krishnamurthy R, et al. Outcomes of surgical intervention for anomalous aortic origin of a coronary artery: A large contemporary prospective cohort study. J Thorac Cardiovasc Surg. 2018 Jan;155(1):305-319.
25. Kooij M, Vliegen H, De Graaf M, Hazekamp M. Surgical treatment of aberrant aortic origin of coronary arteries. Eur J Cardiothorac Surg. 2015 Nov;48(5):724-30; discussion 730-1
26. Sachdeva S, Frommelt M, Mitchell M, Tweddell J, Frommelt P. Surgical unroofing of intramural anomalous aortic origin of a coronary artery in pediatric patients: Single-center perspective. J Thorac Cardiovasc Surg. 2018 Apr;155(4):1760-1768
27. Brothers J, McBride M, Seliem M, Marino B, Tomlinson R, Pampaloni M, et al. Evaluation of myocardial ischemia after surgical repair of anomalous aortic origin of a coronary artery in a series of pediatric patients. J Am Coll Cardiol. 2007;50:2078-82.
28. Tavaf-Motamen H, Bannister S, Corcoran P, Stewart R, Mulligan C, DeVries W. Repair of anomalous origin of right coronary artery from the left sinus of Valsalva. Ann Thorac Surg. 2008 Jun;85(6):2135-6
29. Mumtaz M, Lorber R, Arruda J, Pettersson G, Mavroudis C. Surgery for anomalous aortic origin of the coronary artery. Ann Thorac Surg. 2011;91:811-5.
30. Bigler M, Kadner A, Räber L, Ashraf A, Windecker S, Siepe M, et al. Therapeutic Management of Anomalous Coronary Arteries Originating From the Opposite Sinus

ACCEPTED MANUSCRIPT

Downloaded from https://academic.oup.com/ejcts/advance-article/doi/10.1093/ejcts/ezad075/7078113 by Universitaetsbibliothek Bern user on 16 March 2023

of Valsalva: Current Evidence, Proposed Approach, and the Unknowing. J Am Heart Assoc. 2022 Oct 7:e7869.

ACCEPTED MANUSCRIPT

Downloaded from https://academic.oup.com/ejcts/advance-article/doi/10.1093/ejcts/ezad075/7078113 by Universitaetsbibliothek Bern user on 16 March 2023

Central image

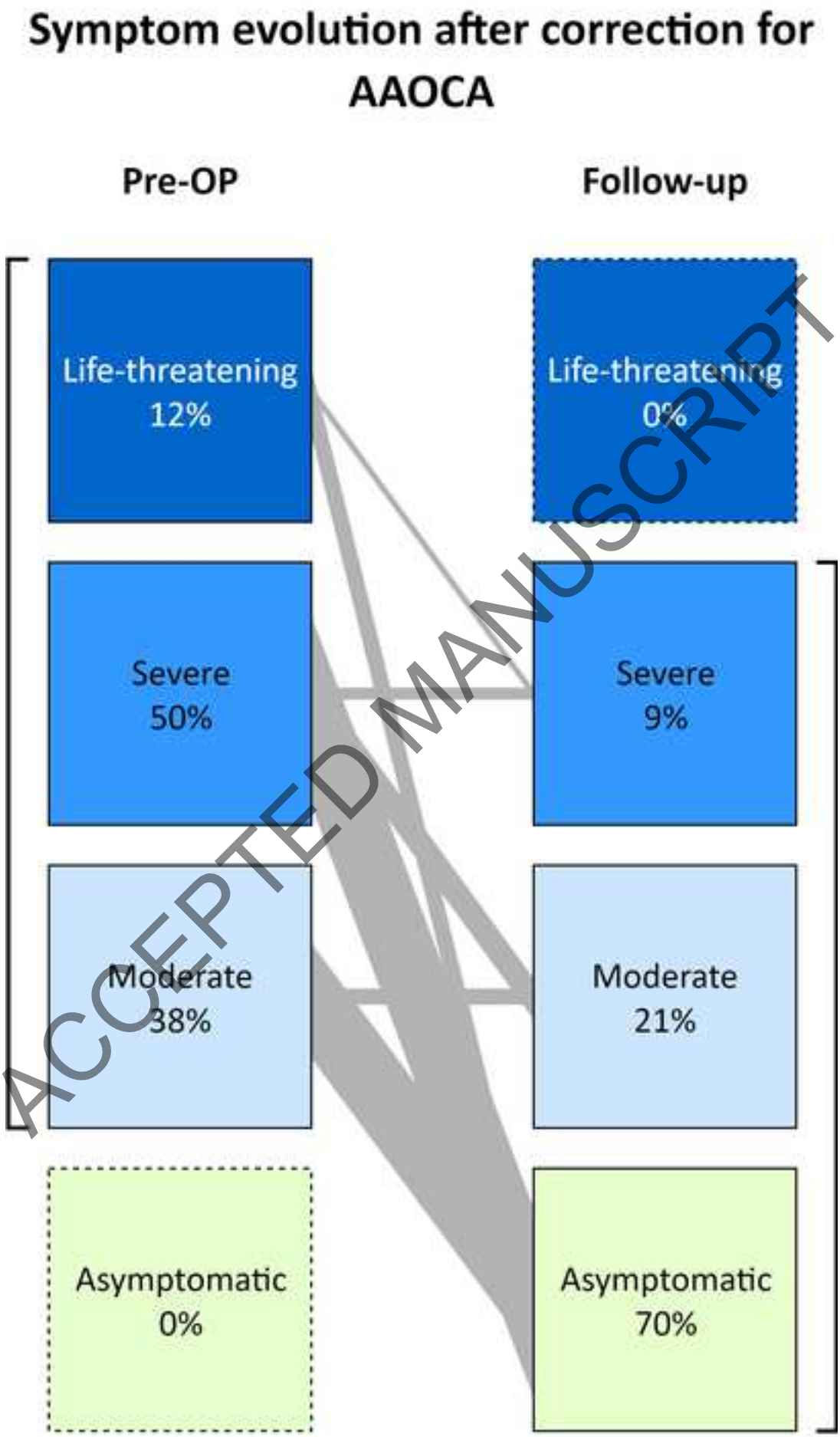

ACCEPTED MANUSCRIPT

Downloaded from https://academic.oup.com/ejcts/advance-article/doi/10.1093/ejcts/ezad075/7078113 by Universitaetsbibliothek Bern user on 16 March 2023

FIGURES

Figure 1: Exclusion flowchart

Legend Figure 1:

*Patients included in the study

**Patients further analyzed with regard to symptom relief

Figure 2: Symptom evolution after correction for AAOCA

Legend figure 2:

Life-threatening symptoms: Acute heart failure, acute myocardial infarction, cardiac arrest. Severe symptoms: angina pectoris, ventricular arrhythmia, syncope. Moderate symptoms: atypical chest pain, dyspnea, or malaise.

ACCEPTED MANUSCRIPT

Downloaded from https://academic.oup.com/ejcts/advance-article/doi/10.1093/ejcts/ezad075/7078113 by Universitaetsbibliothek Bern user on 16 March 2023

Click here to access/download;Figure;Figure 1 Exclusion flowchart_R2.jpg

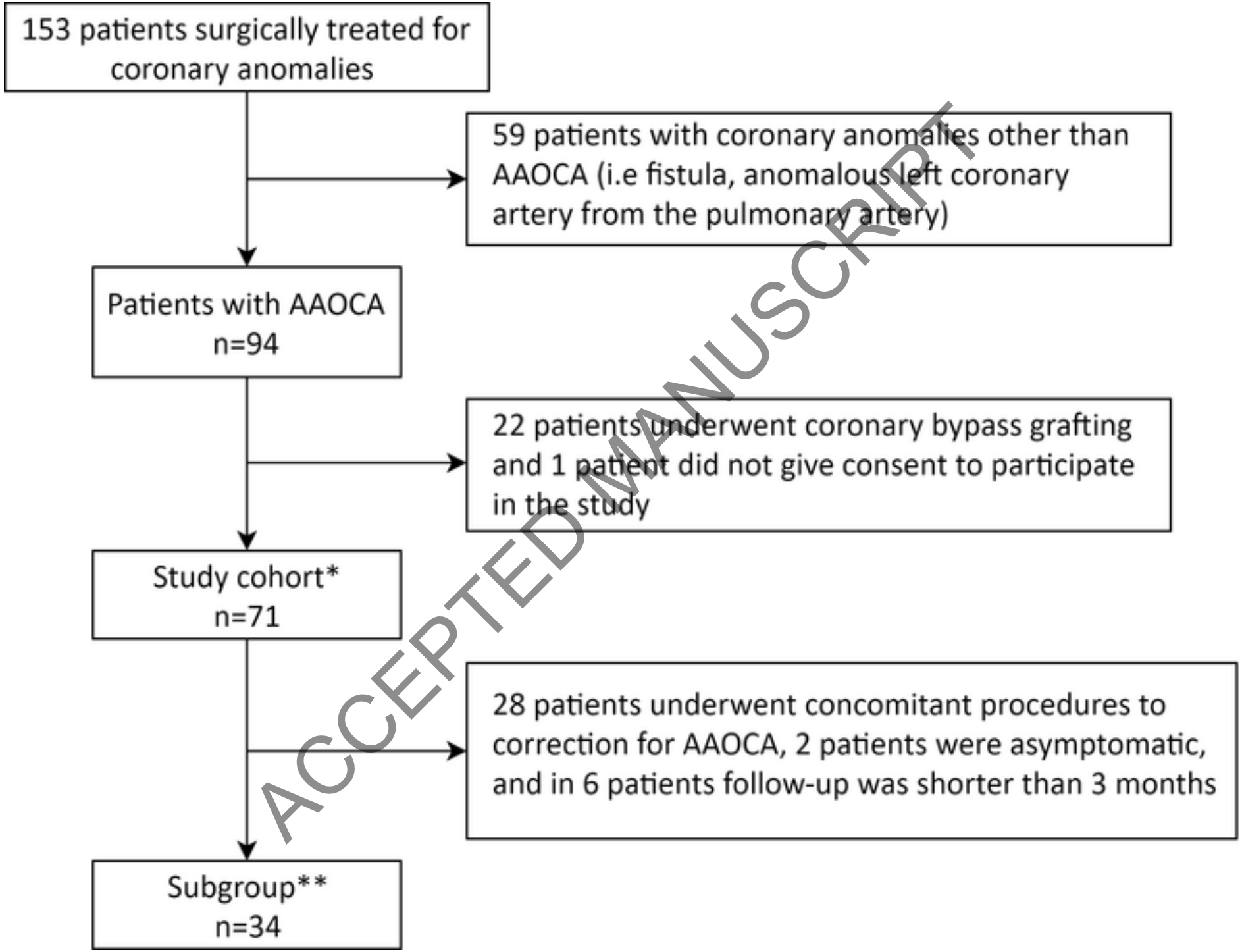

ACCEPTED MANUSCRIPT

Downloaded from https://academic.oup.com/ejcts/advance-article/doi/10.1093/ejcts/ezad075/7078113 by Universitaetsbibliothek Bern user on 16 March 2023

Click here to access/download;Figure;Figure 2 Symptom evolution.jpg

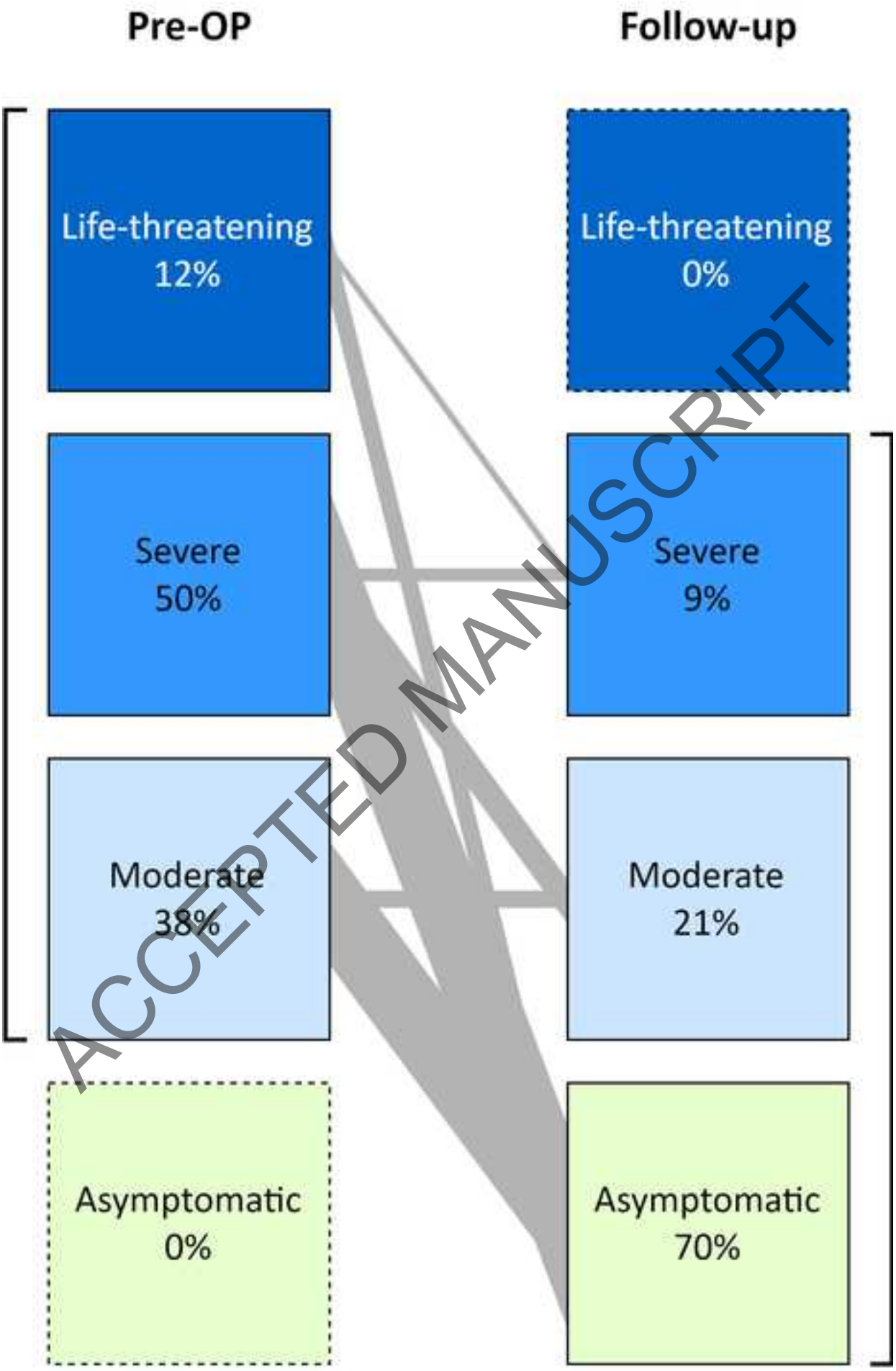

ACCEPTED MANUSCRIPT

Downloaded from https://academic.oup.com/ejcts/advance-article/doi/10.1093/ejcts/ezad075/7078113 by Universitaetsbibliothek Bern user on 16 March 2023