Journal Pre-proof



Fibrosis in neovascular age-related macular degeneration: A review of definitions based on clinical imaging

Isabel Bachmeier, Beatriz Garcia Armendariz, Siqing Yu, Ralf Josef Jäger, Andreas Ebneter, Carl Glittenberg, Daniel Pauleikhoff, SriniVas R Sadda, Usha Chakravarthy, Sascha Fauser

PII: S0039-6257(23)00049-8

DOI: https://doi.org/10.1016/j.survophthal.2023.03.004

Reference: SOP7214

To appear in: *Survey of Ophthalmology*

Please cite this article as: Isabel Bachmeier, Beatriz Garcia Armendariz, Siqing Yu, Ralf Josef Jäger, Andreas Ebneter, Carl Glittenberg, Daniel Pauleikhoff, SriniVas R Sadda, Usha Chakravarthy and Sascha Fauser, Fibrosis in neovascular age-related macular degeneration: A review of definitions based on clinical imaging, *Survey of Ophthalmology,* (2023) doi:https://doi.org/10.1016/j.survophthal.2023.03.004

This is a PDF file of an article that has undergone enhancements after acceptance, such as the addition of a cover page and metadata, and formatting for readability, but it is not yet the definitive version of record. This version will undergo additional copyediting, typesetting and review before it is published in its final form, but we are providing this version to give early visibility of the article. Please note that, during the production process, errors may be discovered which could affect the content, and all legal disclaimers that apply to the journal pertain.

© 2023 Published by Elsevier.

source: https://doi.org/10.48350/181599 | downloaded: 12.10.2024

Fibrosis in neovascular age-related macular degeneration: A review of definitions based on clinical imaging

Isabel Bachmeier * [#], Beatriz Garcia Armendariz*, Siqing Yu, Ralf Josef Jäger, Andreas Ebneter, Carl Glittenberg, Daniel Pauleikhoff, SriniVas R Sadda, Usha Chakravarthy, Sascha Fauser

* equally contributing authors
[#] corresponding author

Institutional affiliations and addresses:

Isabel Bachmeier, MD, Pharma Research and Early Development, F. Hoffmann-La Roche Ltd., 124 Grenzacherstrasse, 4058 Basel, Switzerland

Beatriz Garcia Armendariz, PhD, Pharma Research and Early Development, F. Hoffmann-La Roche Ltd., 124 Grenzacherstrasse, 4058 Basel, Switzerland

Siqing Yu, MD, PhD, Pharma Research and Early Development, F. Hoffmann-La Roche Ltd., 124 Grenzacherstrasse, 4058 Basel, Switzerland

Ralf Josef Jäger, PhD, Pharma Research and Early Development, F. Hoffmann-La Roche Ltd., 124 Grenzacherstrasse, 4058 Basel, Switzerland

Andreas Ebneter, MD, PhD, Department of Ophthalmology, Cantonal Hospital St. Gallen, University of Bern, Switzerland

Carl Glittenberg, MD, Pharma Research and Early Development, F. Hoffmann-La Roche Ltd., 124 Grenzacherstrasse, 4058 Basel, Switzerland

Daniel Pauleikhoff, MD, Augenzentrum am St. Franziskus Hospital, Hohenzollernring 74, 48145 Münster, Germany

SriniVas Sadda, MD, Doheny Eye Institute, University of California – Los Angeles, 150 N. Orange Grove Blvd, Pasadena, CA 91103 USA

Usha Chakravarthy, MD, PhD, Honorary and Emerita Professor of Ophthalmology, Queens University of Belfast, Institute of Clinical Science Block A, RVH site, Belfast BT12 6BA

Sascha Fauser, MD, Pharma Research and Early Development, F. Hoffmann-La Roche Ltd., 124 Grenzacherstrasse, 4058 Basel, Switzerland

Journal Pre-proof

Abstract

Despite the success of antiangiogenic therapy in controlling exudation in neovascular age-related macular degeneration (nAMD), the involvement of the outer retina in fibrosis results in gradual vision loss over time. The development of drugs that prevent or ameliorate fibrosis in nAMD requires that it is accurately detected and quantified with reliable endpoints and identification of robust biomarkers. Achievement of such an aim is currently challenging due to the lack of a consensus definition of fibrosis in nAMD.

As a first step towards the establishment of a clear definition of fibrosis, we provide an extensive overview of the imaging modalities and criteria used to characterize fibrosis in nAMD. We observed variety in the selection of individual and combinations of imaging modalities, and criteria for detection. We also observed heterogeneity in classification systems and severity scales for fibrosis. The most commonly used imaging modalities were color fundus photography (CFP), fluorescence angiography (FA) and optical coherence tomography (OCT). A multimodal approach was frequently utilized. Our review suggests that OCT offers a more detailed, objective and sensitive characterization than CFP/FA. Thus, we recommend it as a primary modality for fibrosis evaluation.

This review provides a basis for future discussions to reach a consensus definition using standardized terms based on a detailed characterization of fibrosis, its presence and evolution, and taking into consideration impact on visual function. Achieving this goal is of paramount importance for the development of antifibrotic therapies.

Key words:

fibrosis; neovascular age-related macular degeneration; ocular imaging; optical coherence tomography; definition; consensus; nomenclature

Abbreviations:

AMD, age-related macular degeneration; BCVA, best-corrected visual acuity; BM, Bruch's membrane; CATT, Comparison of Age-Related Macular Degeneration Treatment Trials; CFP, color fundus photography; CNV, choroidal neovascularization; CONAN, Consensus on Neovascular AMD Nomenclature; ECM, extracellular matrix; ELM, external limiting membrane; EZ, ellipsoid zone; FA, fluorescein angiography; FAF, fundus autofluorescence; FS, fibrotic scar; HRM, hyperreflective material; IR, Infrared; IS/OS, inner segments/outer segments; IVAN, Inhibition of VEGF in Age-related choroidal neovascularization; MC, multicolor; MNV, macular neovascularization; MP, microperimetry; nAMD, neovascular age-related macular degeneration; NFS, non-fibrotic scar; OCT, optical coherence tomography; OCT-A, OCT-angiography; PDGF,

Journal Pre-proof

platelet-derived growth factor; PDT, photodynamic therapy; PED, pigment epithelial detachment; PS-OCT, polarization-sensitive OCT; RCT, randomized controlled trials; RPE, retinal pigment epithelium; SD-OCT, spectral-domain OCT; SHE, subretinal hyperreflective exudation; SHRM, subretinal hyperreflective material; SS-OCT, swept-source OCT; TD-OCT, time-domain OCT; UWF, ultra-wide field; VEGF, vascular endothelial growth factor.

I. Introduction

Despite the introduction of anti-vascular endothelial growth factor (anti-VEGF) therapies, the progression to fibrosis remains an important cause of vision loss in patients with neovascular AMD (nAMD). In long-term follow-up of large anti-VEGF trials half of all eyes developed fibrosis 5 to 7 years after initiation of therapy.[25,32,85] Fibrosis is an exacerbated wound-healing response of neovascular membranes driven by inflammation, cytoskeletal changes, de-differentiation and migration of retinal pigment epithelium (RPE) cells into a mesenchymal phenotype and recruitment of fibrocytes, ultimately resulting in collagen deposition and the formation of a scar.[48,108] Fibrous tissue consists of cellular components (e.g. endothelial cells, RPE, macrophages, fibroblasts) and extracellular matrix (ECM) materials (e.g. collagens, laminins, fibronectin).[48]

The term “fibrosis” has its origins in histological examination of ocular tissues obtained at surgery or post mortem. On microscopic examination the criteria for the presence of fibrosis are clear: fibrosis is characterized by the excessive deposition of ECM components in locations where they should be physiologically scarce (e.g. internal to Bruch’s membrane, BM).[45,98] Since a direct assessment of fibrosis in vivo is not possible, indirect and noninvasive assessments via ophthalmic imaging are applied. Certain features observed on clinical modalities *in vivo* were concordant with features of fibrosis on histology post mortem in clinicopathological correlations. Thus clinicians adopted the histological term “fibrosis” to describe findings visible on clinical examination, despite the term not being directly transferable: historical clinical definitions of fibrosis were based on color fundus photography (CFP) and fluorescein angiography (FA).[10] The introduction of high resolution spectral-domain optical coherence tomography (SD-OCT) has allowed detailed visualization of the posterior pole of the eye and in particular the macular retina. Therefore, the ability of repeated, easy and rapid imaging of the macular retina during clinical visits has permitted a better understanding of the pathological features of nAMD at onset and subsequently during treatment. New terms such as subretinal hyperreflective material

Journal Pre-proof

(SHRM) were proposed and linked to the imaging characteristics of fibrosis that were previously described on CFP and FA.[107] SHRM however can consist of fibrin, whole blood, and neovascular complexes, of which fibrosis may only be a subset.[92] Thus, the relevance and optimal definition of these features on clinical imaging requires investigation. Newer imaging modalities (e.g. polarization-sensitive OCT, PS-OCT) may be helpful to more completely characterize the fibrotic process.[84]

The definitions and modalities applied for fibrosis detection may impact at what rates the prevalences of fibrosis are estimated. A clear definition of fibrosis as an endpoint in clinical trials is a prerequisite for the development of anti-fibrotic therapies, but is challenging for multiple reasons: the molecular mechanisms leading to fibrosis in nAMD are poorly understood because of the lack of good animal models, there is no consensus for the clinical definition of fibrosis and there is no agreement on the optimal imaging modalities and imaging biomarkers to assess fibrosis. As a first step towards a clearer definition and understanding of fibrosis in nAMD, we have conducted an extensive literature review of the terms and criteria used to characterize fibrosis or fibrosis-related processes in nAMD, taking into account the availability of different imaging modalities. This work can serve as the basis for further steps and consensus meetings.

II. Results

Our literature search retrieved 104 publications that had specified criteria for the presence of fibrosis, a description of fibrosis-related features and/or a classification for fibrosis on clinical imaging.

A. Terms used to refer to “fibrosis”

The terms used to refer to fibrosis identified in our results included: “(subretinal/subfoveal/macular) fibrosis”, “(subretinal) fibrous tissue”, “fibrovascular/fibrotic tissue”, “fibrotic lesion”, “scarring”, “(subfoveal/macular) scar”, “scar tissue”, “natural/disciform scar”, “fibrotic disciform/fibrocellular lesion”, “fibrotic/non-fibrotic/fibrovascular/fibrous scar”, “fibrotic CNV” and “fibrous tissue complex”. Two main term groups were identified: “scar”-related terms (“scar”, “fibrotic scar” etc.) and “fibrosis”-related terms (“fibrosis”, “fibrous tissue” etc.), with the latter appearing more frequently (unique use of “fibrosis” vs. “scar”: 43.3% vs 22.1%, see Supplementary table S1), especially after the introduction of anti-VEGF therapy. In 34.6% of the publications both term groups were used.

Journal Pre-proof

B. Fibrosis on clinical imaging - definitions per modality

The majority of the criteria retrieved were based on CFP (including biomicroscopy, clinical examination, ophthalmoscopy), FA and OCT. The criteria were more homogeneous for the traditionally used modalities CFP and FA, as compared to OCT, that showed more variability. The details for each publication can be found in Supplementary table S2.

1. Color fundus Imaging

Characterization of fibrosis on CFP addressed mainly color, elevation and delineation of the margins: Fibrosis color was usually reported as white(ish), yellow(ish) and/or gray(ish).[56,79] On ultra-wide field CFP (UWF-CFP) fibrosis was described as green-yellowish,[29] and on multicolor imaging (MC) as bright lime-green or yellowish.[29,40,77]

We observed consensus on the delineation of the margins of fibrosis, with terms like "well-defined in shape", "well-demarcated", "well-circumscribed", "well-delineated".[12,21,56,A] Fibrosis presence was often reported as an "(elevated) mound", or "raised clusters of tissue" on stereoscopic photography or biomicroscopy.[58,98]

A solid appearance and an obscuration of the underlying choroid and/or RPE [56,79] were reported less frequently. One publication described fibrosis as a "stranded appearance with tension lines, curved edges, occasional pigment infiltration and an outline that is more irregular than that produced by expanding fluid".[7]

The Comparison of Age-Related Macular Degeneration Treatment Trials (CATT) group introduced the concepts of "fibrotic scars" and "non-fibrotic scars".[26] CATT defined fibrotic scars as "well-demarcated elevated mounds of yellowish white tissue", in line with the above description, whereas "non-fibrotic scars" were defined as "flat, depigmented lesions with varying amounts of signet-shaped peripheral dark pigmentation that conformed to the baseline CNV area", the latter being distinct from the commonly used characterization of fibrosis.

2. Fluorescein angiography and fundus autofluorescence

On FA, fibrosis has usually been described as a region of blocked fluorescence and/or staining, with minimal or no leakage in late angiographic frames.[10,28,96] The blocked fluorescence or (early) hypofluorescence can be explained by the obstruction of the fluorescence signal from the underlying choroid due to the presence of fibrotic tissue. Staining is characterized by a well-demarcated hyperfluorescence without progressive leakage in the late phase of the angiogram. Chuang et al. included a description in angiographic dynamics describing an "even and slow appearance of hyperfluorescence corresponding with the scar".[22] "If accompanied by CNV,

Journal Pre-proof

scars also may demonstrate leakage on angiography"[10] as stated in the "Guidelines for evaluation and treatment in the Macular Photocoagulation Study".[10] Miere et al. specified "minimal leakage" as "leakage of less than 50% of lesion area" in the late phase. They further detailed the shape of the lesion on FA as "heterogeneous lesion with concave borders".[69]

The angiographic properties of "fibrotic scars" described in CATT were in concordance with the above mentioned criteria: "early hypofluorescent and minimally stained in the late-phase". "Non-fibrotic scars" showed a fluorescence pattern that corresponded to the depigmented (early and persistently hyperfluorescent) and hyperpigmented areas (hypofluorescent) on CFP.[26]

On fundus autofluorescence (FAF), fibrosis was associated with a decreased autofluorescence signal compared to normal RPE. The regions surrounding the fibrotic area can show increased autofluorescence due to irregular pigmentation, which is formed by multilayered RPE.[6]

3. Optical coherence tomography

Fibrosis was almost invariably described to be "(highly) hyperreflective" on OCT,[86] with a location "between neurosensory retina and RPE/Bruch's membrane (BM)", "in the subretinal or sub-RPE space/compartment" or "at the RPE level".[8,63,94] Early publications using time-domain OCT (TD-OCT) described only a "highly reflective band" and its approximate location in relation to the RPE. The advent of SD-OCT (and later swept-source OCT, SS-OCT) allowed for a more granular characterization. This included internal structure, reflectivity, delineation of the margins, extent, detailed location in relation to the RPE and intactness of adjacent retinal structures. Fibrosis was commonly characterized as a "dense/compact/uniform/sheet-like/homogeneous" material [14,65,69,94,95] with "well-demarcated/well-defined/well-delineated/sharp borders",[11,53,54,99] and a "uniform, spindle-shaped or fusiform",[65] "lamellar" [88] or "multilaminar" [97] shape. Sub-RPE fibrosis in particular was referred to as a "multilayered PED",[73] a specific appearance of chronic fibrovascular pigment epithelial detachment (PED) receiving serial anti-VEGF therapy.

For some groups the characterization of fibrosis depended on its extent or thickness, e.g. "more than 50% of (the lesion) area was occupied by a compact, hyperreflective material",[69,95,110] or "fibrotic scar thicker than 100 µm",[69] or "lamellar subfoveal lesion of at least 25-µm elevation from Bruch membrane".[88]

In relation to the surrounding retinal tissue, fibrosis has been described to have "either obscured or replaced the normal reflectivity and banding of the neurosensory retina and RPE/Bruch's membrane complex".[60] Several publications outlined a potential impact of fibrosis on the overlying photoreceptors and the adjacent RPE in the form of ellipsoid zone (EZ) and external limiting membrane (ELM) disruption, RPE loss, and/or outer nuclear layer thinning,[7,37,54,62,69,96,101]

Journal Pre-proof

highlighting the deleterious effect of fibrosis to vision.Our analysis demonstrated a large variability in the level of detail when fibrosis was characterized on SD-/SS-OCT (see table 1).

SHRM has been proposed as an important OCT biomarker and surrogate for fibrosis.[12] Subretinal tissue ("any hyperreflective material in the subretinal space") was introduced in 2007,[51] and subsequently CATT used the term "SHRM"[30] that has become entrenched within the literature. The Consensus on Neovascular AMD Nomenclature (CONAN) group defined SHRM as "exudation in the subretinal space of material that is hyperreflective as compared with fluid".[97] The composition of SHRM can include macular neovascularization (MNV) components, blood, lipids, vitelliform material, fibrin and fibrotic tissue.[92]

There is inconsistency in the use of the term "SHRM". De Rosa and coworkers applied the term "SHRM" only to a hyperreflective lesion when it was a "moderately hyperreflective deposit with fuzzy edges (...), often associated with other signs of CNV activity (...) and a dynamic aspect"[29] (i.e. change over time), with characteristics similar to "subretinal hyperreflective exudation" (SHE). Shah and coworkers introduced the term "SHE" and defined it as "a homogeneous accumulation of material with a level of hyperreflectivity greater than that of subretinal fluid but less than that seen with subretinal fibrosis, pigment hyperplasia, and lipid".[92]

Other groups used SHRM [76] or HRM [11] as a more generic term and distinguished between an undefined HRM ("... with low reflectivity and whose borders were less well distinguishable from surrounding neural components") and a well-defined HRM ("... with high reflectivity whose boundaries can be clearly delineated from the surrounding neural components of the retina"). De Rosa did not use the term "well-defined SHRM", but instead called it "fibrosis" when detecting a "well-delineated, highly hyperreflective lesion whose edges are well defined and whose aspect is not as dynamic as the SHRM's from one visit to another".[29]

Aside from these linguistic observations, the studies from Casalino [11] and Pokroy [76] on SHRM dynamics supported the use of well-defined persistent hyperreflective material on OCT as a proxy for fibrosis. Using OCT alone, Kherani defined fibrosis presence when SHRM was "highly reflective with well-demarcated, sharp borders and loss or disruption of overlying ellipsoid zone and external limiting membrane".[54]

4. Infrared Imaging, *en face* OCT, OCT-angiography and polarization-sensitive OCT

Few publications reported the use of en face infrared images (IR) to identify fibrosis, described as hyperreflective regions on this imaging modality.[5,77] One publication specified *en face* OCT

Journal Pre-proof

findings in fibrosis, where “bright regions were visible due to light scatter from the hypopigmented fibrotic scar”.[71]

The presence of fibrosis is inherently linked to neovascularization. Miere and coworkers used OCT-angiography (OCT-A) to distinguish 3 features of neovascularization inside a fibrous scar: “pruned vascular tree, tangled network, (and) vascular loop”.[69] The latter two could also be grouped into a “blossoming tree” phenotype. Fibrotic or atrophic disciform scars have been associated with a hyper-mature vascular pattern (“dead tree” morphology) with long, straight, dilated filamentous vessels.[109]

Polarization-sensitive OCT (PS-OCT) is a high-resolution imaging modality that can detect changes in the polarization state of light as a consequence of its interaction with tissue. This increases contrast and allows a better separation of the different layers.[44] Birefringence was uniformly mentioned as the characteristic property of fibrosis on PS-OCT. Some listed, in addition, other related properties like “(optic axis) uniformity” [39,72,B] and “(local) phase retardation”.[39,68,C] PS-OCT was reported to be able to distinguish fibrosis from other hyperreflective features (MNV, blood, lipids, fibrin etc.) and the RPE.[72]

C. Fibrosis on clinical imaging - unimodal vs. multimodal approaches

We analyzed whether the selected studies used a single imaging modality or multiple imaging modalities for fibrosis detection. For this, we included only publications that specified the imaging modalities used to determine the presence of fibrosis (e.g. introduced with “the presence of fibrosis was defined on CFP as […]”), and excluded publications that described imaging findings in the context of fibrosis, but did not use the features that they described as a criterion for reporting the presence of fibrosis (24 publications). We have described the criteria for each imaging modality above, and they can also be found in Supplementary table S2.

When a unimodal approach was reported (33.8%), CFP was the most common modality (used over many decades), followed by OCT (Supplementary table S3). The use of FA, MC and PS-OCT on their own was rare.

Amongst multimodal approaches (63%), there was a predominant use of CFP together with FA, followed by CFP + OCT and CFP + FA + OCT (Supplementary table S4). In our analyzed set of publications, the combination of CFP and FA was the only one used up to 2007 inclusive, but with the introduction of OCT, this modality also became gradually included from 2009 on. From 2015 on, OCT was commonly used for fibrosis detection, in combination with either CFP (most frequently), FA, or both.

Journal Pre-proof

In more recent publications, PS-OCT was also suggested as a primary modality, either in combination with CFP and OCT [83] or with CFP and FA.[82] PS-OCT, however, is not currently commercially available.

Only 2 studies used functional assessments, in addition to imaging modalities, for defining fibrosis. In one publication, the characteristic findings on CFP and OCT had to be "combined with low BCVA when the lesion was subfoveal".[39] In the other, microperimetry (MP) was referred to when CFP, FA and PS-OCT showed disagreement, and reduced retinal sensitivity values were used as indicative for the presence of fibrosis.[82]

The CONAN group suggested the following multimodal definition for fibrosis: "white or yellow-white accumulation of material, usually in the subretinal or sub-RPE space. On OCT the material is hyperreflective and may have a multilaminar appearance." [97]

Figure 1 shows examples of multimodal imaging in eyes with fibrosis in nAMD.

D. Gradings and classification systems for fibrosis

We found several approaches for a classification or a grading of fibrosis, based on a variety of imaging modalities or combinations of those (table 2). The graded features varied, and included presence/absence of fibrosis, severity, morphology, progression stages and response to treatment.

E. Reported prevalence of fibrosis

In order to investigate if and how the definitions and imaging modalities for fibrosis detection influenced prevalence estimates, we analyzed a subset of 39 publications, where prevalence was reported. This subset was extracted from the 104 publications that were retrieved in the initial literature search, that selected publications providing a clear definition of fibrosis. We only considered one entry in cases where prevalences of the same study were reported in several publications. We calculated the prevalence by dividing the number of eyes reported as having fibrosis vs. the total number of eyes for the publications that reported this data. The confidence intervals were obtained using the Wilson score interval.

The treatment of nAMD prior to the anti-VEGF era was by thermal laser or photodynamic therapy (PDT). Our results showed that the prevalence of fibrosis prior to the availability of anti-VEGF treatment ranged from 13.5% to 100% (Supplementary Table S5). Subsequently, on introduction of anti-VEGF biologicals, several large multi-center post-licensing trials (e.g. CATT, IVAN, HARBOR) reported a range of fibrosis prevalence of 43.3% to 79.5% after 2 years of

Journal Pre-proof

treatment (Supplementary table S6). The prevalence reported in some real-world datasets or smaller prospective or retrospective datasets showed a wider range, from 5.1% to 82.8% in treatment-naive eyes after anti-VEGF therapy (Supplementary Table S7), but the observation periods differed widely. Cross-sectional studies (Supplementary Table S8) also exhibited considerable heterogeneity in terms of prevalence of fibrosis, ranging from 9.1% to 93.3%.

Table 3 shows the prevalence estimates of fibrosis by imaging modality after the introduction of anti-VEGF therapies. Overall, we observed greater heterogeneity when only CFP and/or FA were used, compared to studies where OCT was included. The average prevalence estimates were overall similar between en face imaging modalities and OCT.

III. Discussion

In this extensive literature review, we retrieved 104 publications that characterized fibrosis in nAMD eyes using clinical imaging. The imaging modalities used were CFP, FA, OCT, OCT-A, PS-OCT, en face OCT, IR, FAF and MC. Only a few publications took into account functional parameters (i.e. MP, BCVA). Around 34% of the reports defined the presence of fibrosis using just one single modality (commonly CFP or FA or OCT). A multimodal approach was more common (66%), with the most frequent combination being CFP and FA, due to their availability throughout all decades. OCT became increasingly included, representing the main imaging modality in recent years.

We found that certain terms appeared frequently when referring to fibrosis, such as “white/yellow tissue”, “elevated mound”, “well-demarcated” and “solid” appearance on CFP, and “blocked fluorescence” or “early hypofluorescence and late staining” on FA. On OCT, almost without exception the focus was on the “(highly) hyperreflective” nature of fibrosis.

Linguistically, we observed that there was a large variety of terms used to refer to fibrosis, mostly derived from “scar” or “fibrosis”. These 2 groups may represent different aspects, i.e “scar” addressing the entire lesion or an end-stage of the disease, and “fibrosis” describing the underlying biological process and histological lesion component (i.e. collagen deposition). However, they have been used interchangeably, complicating the definition of fibrosis.

Prior to the introduction of biologicals that inhibit VEGF into routine clinical care (i.e. up to 2006) fibrosis was common, with most eyes affected by nAMD evolving into exhibiting large disciform (i.e. disc-shaped) macular scars, and there was a consensus that it reflected “end-stage disease". CFP and/or FA were used to determine the presence of fibrosis, and the criteria applied were uniform. The main features described on CFP were color, delineation of the

Journal Pre-proof

margins and elevation (on stereo imaging and for the detection of elevation of tissue within the macular lesions).

The first reports of fibrosis on TD-OCT were published in the context of PDT.[86] With the advent of anti-VEGF therapy combined with the widespread use of SD-OCT, studies increasingly reported and described findings that were considered a proxy for fibrosis. SD-OCT offered additional possibilities such as analysis of reflectivity, identification of the boundaries, internal structure, quantification of the extent in three dimensions, location in relation to the RPE and the intactness and delineation of the adjacent RPE and photoreceptor layers. Our analysis retrieved a large variety of criteria used to determine the presence of fibrosis on OCT - from the mere presence of hyperreflective material to a detailed description that includes all of the above mentioned features. Our work supports the view that a robust reporting of the presence of fibrosis requires a detailed assessment of potential OCT-detected biomarkers and well agreed-on criteria. While many reports referred to the “high” reflectivity of SHRM in fibrotic lesions, there is still a need to precisely define what is sufficiently “high”. Other considerations such as the thickness and opacity of SHRM may also need to be accounted for.

The traditional imaging techniques CFP and FA suffer from considerable limitations. Both have high inter-grader variability in interpretation, and a high dependency on image quality, which in turn relies on optical media clarity and pupil dilation. FA carries risks associated with dye administration, and it is difficult “to distinguish between staining and leakage”.[105] CFP may lead to an overestimation of the presence and extent of fibrosis due to misinterpretation of atrophy, fibrin and lipids. Furthermore, the visibility of fibrosis on CFP relies heavily on the opaqueness and thickness of fibrotic lesions and thus this modality may be insensitive for the reliable detection of small regions of thin fibrosis. We contend that the correlation between HRM dimensions and visibility of fibrosis on CFP and FA requires systematic investigation.

OCT has the advantage of being non-invasive and shows potential to detect early and subtle forms of fibrosis and enabling machine learning-based image analysis to facilitate automated detection and, even more importantly, (volumetric) quantification of fibrosis. It is generally accepted that fibrosis, when detected by CFP or FA, appears as a hyperreflective lesion on OCT. Conversely, hyperreflective lesions on OCT are not always defined as fibrosis on CFP/FA, especially when applying the most widely accepted criteria (i.e. white color, FA staining). The CATT study differentiated between “fibrotic scars” and “non-fibrotic scars”, based on CFP and FA. Both were associated with hyperreflective material on OCT, consistent with fibrosis,[26] however only fibrotic scars would fulfill the widely accepted criteria on CFP and FA. This further supports the use of OCT as the primary imaging modality, because the use of CFP/FA as the

Journal Pre-proof

main imaging methods for fibrosis detection can potentially underestimate its presence. Nonetheless, even recently conducted major trials have not used OCT alone to report the prevalence and incidence of fibrosis and still appear to rely on confirmation of the presence of pale whitish or yellow tissue on CFP.

On the other hand, without validation and confirmation from histological correlation, it is also possible that a pure OCT-based approach may not be sufficiently specific.

Indeed, subretinal hyperreflective structures that are seen on OCT can arise from components other than fibrosis, such as blood, fibrin, lipids and vitelliform material. This reduces confidence in relying solely on OCT for the detection of fibrosis. In addition, the appearances on OCT of hyperreflective regions can change over time with anti-VEGF treatment. The acute exudative components seen on OCT undergo transformation - from undefined, fuzzy less hyperreflective characteristics (most likely representing fibrin and a high content of resolvable components [11]) to well-defined, structured, highly reflective lesions (very likely representing fibrosis [11]). The determination of the time point of this transition is clearly important as its impact on function and outer retinal disorganization is not trivial and requires sequential high-resolution OCT imaging with standardized grading of the images.[75]

PS-OCT seems to best differentiate fibrosis from other hyperreflective tissues and features like the RPE,[84] and detect the so-called “angiofibrotic switch;”. however, this device is not available outside of the research environment, and further work on correlates with standard OCT or ideally histology is needed.

In some publications it was stated that no attempt was made to distinguish between fibrosis and fibrin.[52,58] Fibrin is generated during blood clotting, but it may represent a precursor of fibrosis.[7] Shah and coworkers hypothesized that fibrin is the major component of the subretinal hyperreflective exudation (SHE) observed in association with active CNV.[92]

The most obvious limitation of the clinical imaging modalities for fibrosis is that data showing a direct correlation of the imaging features with histology is sparse. The early studies performed mainly by Green[41] were instrumental in understanding the pathophysiology of AMD, however they did not include current imaging techniques and were conducted before the introduction of anti-VEGF therapy, thus their learnings cannot be readily translated. There have been more recent publications that included modern imaging techniques, and although their main focus was not fibrosis, they offered insights into its imaging correlates.[16] In the future, approaches like second harmonic generation microscopy, that can image fibrillar collagen in unstained tissue sections, might be instrumental to understand clinicopathological correlates.[19]

Journal Pre-proof

The classification and grading schemes for fibrosis that we have collected reveal considerable heterogeneity of definitions even within a single imaging modality and extensive heterogeneity between studies using different imaging modalities and the features that have been graded. Much of this heterogeneity can be attributed to the fact that classification schemes have changed over time as newer imaging modalities have entered clinical care. Particularly OCT, which has allowed a three-dimensional appreciation of the retinal architecture and the dynamic evolution of the abnormal features that are seen in the treatment-naïve stage to those that appear when the nAMD lesion becomes quiescent. Robust agreement studies between OCT features and established en face technologies are not available. Nor have there been clinicopathological correlation studies with accurate co-localization of ante mortem OCT features to post mortem histology to ensure that what is seen on OCT is tissue with the characteristics of fibrosis. Therefore, at present there is insufficient evidence to recommend any one classification scheme that has been used.

The reported prevalence estimates of fibrosis in our analysis revealed considerable heterogeneity. This is in line with a recently published systematic review of the prevalence and incidence of fibrosis.[20] The review by Cheong and coworkers did not consider the historical definitions of fibrosis and is limited to data acquired during anti-VEGF therapy. In our analysis of prevalence data, we accounted for the potential impact of treatment modalities, study design, differences in follow-up and treatment status. Nevertheless, our results could not confirm that the large variability in prevalence estimates was due to the use of different imaging modalities and criteria, because several other factors might have an impact, including patient population differences (e.g. CNV type distribution, presence of macular hemorrhage at baseline). Surprisingly, we observed less heterogeneity in studies that used OCT (either alone, or in combination with CFP) compared to studies that used only the en face imaging modalities, despite the fact that the definition of fibrosis was less uniform on OCT. However, we feel that it is inappropriate to reach conclusions from this analysis due to the small number of studies per modality/combination of modalities. Our data strongly support the view that despite control of exudation in nAMD lesions even with optimal treatment, such as that performed in clinical trials that do not have time varying confounders, are insufficient to prevent the appearance of fibrosis. It is however obvious from comparison of published images from historical data prior to the anti-VEGF era that nAMD affected eyes treated with anti-VEGF exhibit smaller and less extensive fibrotic lesions. Owing to the lack of an agreed fibrosis severity scale, this observation cannot be backed up by clinical trial data, emphasizing the need for a consensus quantification scheme. Although the prevention of fibrosis is an important goal for future therapeutic approaches, it is

Journal Pre-proof

not the only cause of visual acuity loss in anti-VEGF treated eyes. Even if fibrosis is arrested through inhibition of an angiofibrotic switch, attrition of photoreceptors and the RPE can ensue leading to atrophy with loss of function.

The recently published review of fibrosis[20] and our work both highlight the need for an appropriate characterization of the fibrotic process and agreement and consensus on terminology and the optimal imaging modality as well as identifying the critical time points for assessment. We contend that the present work provides the basis for such an effort.

There are several limitations in the present work. First, the combination of individual and text-mining based literature searches might not have yielded all available relevant publications dealing with fibrosis definitions in nAMD based on clinical imaging. In addition, we designed the primary literature search to retrieve publications that specified a characterization or classification of fibrosis. Subsequent analyses performed (i.e. “scar”- vs. “fibrosis”-related terms, unimodal vs. multimodal approach, prevalence analysis) were limited to the original search results, so we did not consider publications that could have contributed specifically to those questions, because they did not fulfill the primary inclusion criteria.

IV. Conclusion and future directions

In summary, we have conducted an extensive literature review focused on the characterization of fibrosis in nAMD on clinical imaging. Our review revealed that the most commonly used criteria for reporting the presence of fibrosis were “well-demarcated white/yellow mound of tissue” on CFP, “early hypofluorescence with late staining” on FA, and “highly reflective material” on OCT. Our results showed that despite the apparent overall agreement on fibrosis-related imaging features per modality, the nomenclature for fibrosis is not uniform and there is a lack of (1) consensus on how many and which imaging modalities are to be used, (2) an agreed classification system that reflects potential different phenotypes of fibrosis, and (3) a uniformly used objective severity scale or robust way to quantify fibrosis. We also found that the descriptions of fibrosis based on OCT varied in the level of detail provided.

Our review highlights several areas with open questions for future work. Consensus meetings amongst experts may be helpful to answer these open questions, and we suggest that such meetings are focused on the identification of earlier stages of fibrosis rather than advanced stages (“scars”) where there is less disagreement:

Journal Pre-proof

1. Consensus in nomenclature: agreement on the terms used to refer to the fibrotic process that do not give rise to misinterpretations or confusions. When addressing fibrotic lesions that develop under anti-VEGF therapy we might consider moving away from the term “scar” as it is reminiscent of the historically used “disciform scar” and of photocoagulation scars, and rather use “fibrosis” or related terms such as “fibrotic tissue” or “fibrotic lesion”. Another approach could be to use alternative terms to describe different stages in the evolution of the fibrotic process (e.g., “fibrosis” for earlier stages, and “scar” for advanced stages). A further approach may be the use of different terms for differing imaging modalities (e.g., “fibrosis” only for CFP and FA, and “hyperreflective material” for OCT).
2. Choice of imaging modalities to detect fibrosis: consensus on the optimum (set of) imaging modality(ies) to detect fibrosis. While the traditional imaging techniques (FA and CFP) have considerable limitations, OCT is a non-invasive tool that allows for an accurate, detailed and three-dimensional qualitative and quantitative assessment. We recommend that OCT is included in any future study on the prevalence and incidence of fibrosis, particularly until the variability in defining fibrosis on this imaging modality is solved. In the future, it may serve as the main modality for fibrosis detection, with hyperreflective material as a lead biomarker. CFP may act as a supportive modality to rule out non-fibrotic tissues that appear hyperreflective on OCT, like blood. The consensus criteria on the selected imaging modality(ies) for fibrosis should be objective, highly reproducible and capable of detecting early and subtle forms of fibrosis.
3. Biomarkers for fibrosis: Fibrosis is a dynamic process, and there is a distinct need for longitudinal studies to identify robust biomarkers that allow its evaluation in terms of onset, severity and extent (thickness, area, etc.). Visual outcomes are likely to be particularly dependent on the location with respect to the fovea and extent of fibrosis. Patterns of reflectivity, compartmental location (i.e. subretinal, sub-RPE, combined), layers involved in associated atrophy, vascularity of the lesion (vessel density) are amongst others potential additional biomarkers. Clinicopathologic correlation studies are needed to support the evaluation of the relevance and correlates of these OCT biomarkers.
4. Threshold of selected imaging features: Once the preferred imaging modalities and criteria have been defined, a threshold for the different features should be set, including parameters such as thickness, minimum en-face area and volume.

Journal Pre-proof

5. Dynamic assessment: Detection of fibrosis at treatment initiation is challenging, so an agreement on a time point when a formal assessment for these features should be made is needed. This could be for example at month 1, or at disappearance of active exudation.
6. Fibrosis scale: Though there have been various proposals to quantify fibrosis and to establish a severity scale, these have not been agreed upon and used by the broader community, and only very few take OCT into account.
7. Generalizability: Because fibrosis is a common process in many retinal diseases, any definition that is agreed upon (perhaps after DELPHI processes are completed) could potentially be extended to help investigate its development in other conditions.

The proper characterization of fibrosis with standardized terms is of paramount importance for the establishment of endpoints and the identification of biomarkers that allow for the development of therapies focused on preventing fibrosis development, which represents one of the remaining unmet needs in AMD. The fibrotic process is a complex interplay; thus, it is also important to understand what risk factors and baseline characteristics (MNV type, treatment regimen etc.) are involved and how they correlate with functional outcome. Finding the ideal time for intervention to ensure treatment success requires a profound knowledge of the fibrotic process that takes into account not only the morphological features, but also their evolution and impact on visual function.

V. Method of literature search

The authors identified publications that contained a characterization or classification of fibrosis in nAMD on clinical imaging, extended by text-mining searches.

A. Literature Corpus & Software

Text-mining included searches on A) an abstract index (BIOSIS, DDF, EMBASE, GeneRIF, MEDLINE), and B) a fulltext index (Elsevier, Karger, NEJM, SpringerNature, Taylor & Francis, Wiley, PubMed Central, Spandidos, bioRxiv) totalling to 155511046 (April 2022) records, using I2E, version: 6.6R8 by Linguamatics (IQVIA), Cambridge, UK.

Journal Pre-proof

B. Query Description

We built text-mining searches to find the imaging modalities and criteria to characterize fibrosis. Results of searches for simple co-occurrences of a finding (F) and a modality (M) in publications (3328 documents) rarely specified details leading to the definition of fibrosis. Therefore we iteratively developed a set of four subsearches extracting such details in a sentence and potentially describing finding:modality (F:M) relations. When applicable, we used taxonomic concepts, otherwise we used lists of synonyms (e.g. “subretinal fibrosis”, “SF”). Sentences mentioning fibrosis-related findings or modalities alone were optionally extracted for subsequent assessment. This applied also for sample size, study designs and prevalences. Exclusion criteria were: laser, photocoagulation, model, mouse or rat. We used default I2E disambiguation settings.

C. Outcome of searches

The combined results of the subqueries retrieved 788 individual publications (from 1513 including duplicates due to query and content overlaps) qualifying as relevant for the intended in depth analysis. Using the extracted data and by consulting the full text of the publications when required, false positives were eliminated. A curated final set of 104 publications remained and was used for this review (process scheme, see figure 2).

VI. Key references

The Guidelines of the Macular Photocoagulation Study Group from 1991[10] illustrate the historical definition of fibrosis in nAMD, based on CFP and FA. Later, OCT was incorporated to describe fibrosis in addition to these imaging modalities, and the CATT group (Willoughby et al.[107] and Daniel et al.[26]) published highly relevant papers addressing subretinal hyperreflective material (SHRM) and evaluating its association with fibrosis development. Daniel et al.[26] established a distinction between “fibrotic” and “non-fibrotic scars”, referenced extensively by other authors. The work by Casalino et al. on hyperreflective material (HRM) characterization supported the view that well-defined persistent HRM on OCT is not only a risk factor but also a proxy for fibrosis.[11] A study by Kherani et al. is an example of a detailed fibrosis definition based on OCT alone.[54]

Journal Pre-proof

VII. Disclosures

IB: employee of F. Hoffmann La-Roche Ltd.

BGA: employee of F. Hoffmann La-Roche Ltd.

SY: employee of F. Hoffmann La-Roche Ltd.

RJ: employee of F. Hoffmann La-Roche Ltd.

AE: former employee of F. Hoffmann La-Roche Ltd.

CG: employee of F. Hoffmann La-Roche Ltd.

DP: The author reports no proprietary or commercial interest in any product mentioned or concept discussed in this article.

SRS: Consultant for Abbvie/Allergan, Amgen, Apellis, CenterVue, Heidelberg Engineering, Iveric Bio, Pfizer, Novartis, Optos, Oxurion, Roche/Genentech, Biogen, Boehringer-Ingelheim, Janssen, Alexion, Alnylam, Astellas, Bayer, Regeneron, Samsung Bioepis; Honoraria/Speaker Fees: Nidek, Topcon, Heidelberg Engineering, Optos, Novartis, Roche; Recipient of research instruments from Carl Zeiss Meditec, Nidek, Optos, Topcon, Heidelberg Engineering, CenterVue; Research Grant: Carl Zeiss Meditec

UC: Consultant to Abbvie, Alimera, Apellis, Amgen, Deepeye, Iveric, Kyowa Kirin, Retina AI, F. Hoffmann-La Roche Ltd., Unity.

SF: employee of F. Hoffmann La-Roche Ltd.

VIII. References

1. Adrean SD, Morgenthien E, Ghanekar A, Ali FS. Subretinal fibrosis in HARBOR varies by choroidal neovascularization subtype. *Ophthalmol Retina*. 2020;4(7):752-754. doi:10.1016/j.oret.2020.02.012
2. Balaskas K, Ali ZC, Saddik T, Gemenetzi M, Patel P, Aslam TM. Swept- source optical coherence tomography angiography features of sub- retinal fibrosis in neovascular age-related macular degeneration. *Clin Experiment Ophthalmol*. 2019;47(2):233-239. doi:10.1111/ceo.13367
3. Banister K, Cook JA, Scotland G, et al. Non-invasive testing for early detection of neovascular macular degeneration in unaffected second eyes of older adults: EDNA diagnostic accuracy study. *Health Technol Assess*. 2022;26(8):1-142. doi:10.3310/VLFL1739
4. Barbazetto I. Photodynamic therapy of subfoveal choroidal neovascularization with verteporfin: fluorescein angiographic guidelines for evaluation and treatment—TAP and VIP report no. 2. *Arch Ophthalmol*. 2003;121(9):1253. doi:10.1001/archopht.121.9.1253
5. Barresi C, Borrelli E, Fantaguzzi F, et al. Complications associated with worse visual outcomes in patients with exudative neovascular age-related macular degeneration. *Ophthalmologica*. 2021;244(6):512-522. doi:10.1159/000519518
6. Batıoğlu F, Demirel S, Özmert E. Fundus autofluorescence imaging in age-related macular degeneration. *Semin Ophthalmol*. 2015;30(1):65-73. doi:10.3109/08820538.2013.810285

Journal Pre-proof

7. Bloch SB. Implementation studies of ranibizumab for neovascular age-related macular degeneration. *Acta Ophthalmol (Copenh)*. 2013;91:1-22. doi:10.1111/aos.12272
8. Bloch SB, Lund-Andersen H, Sander B, Larsen M. Subfoveal fibrosis in eyes with neovascular age-related macular degeneration treated with intravitreal ranibizumab. *Am J Ophthalmol*. 2013;156(1):116-124.e1. doi:10.1016/j.ajo.2013.02.012
9. Book M, Ziegler M, Rothaus K, et al. Die fibrovaskuläre Umwandlung der CNV bei nAMD unter lang andauernder anti-VEGF-Therapie: Methodenevaluation zur Quantifizierung morphologischer Veränderungen. *Ophthalmol*. 2021;118(10):1024-1030. doi:10.1007/s00347-020-01261-9
10. **Bressler NM, Alexander J, Bressler SB, Maguire MG, Hawkins BS, Fine SL. Subfoveal neovascular lesions in age-related macular degeneration: Guidelines for evaluation and treatment in the macular photocoagulation study. *Arch Ophthalmol*. 1991;109(9):1242. doi:10.1001/archopht.1991.01080090066027**
11. **Casalino G, Bandello F, Chakravarthy U. Changes in neovascular lesion hyperreflectivity after anti-VEGF treatment in age-related macular degeneration: an integrated multimodal imaging analysis. *Invest Ophthalmol Vis Sci*. 2016;57(9):OCT288. doi:10.1167/iovs.15-18753**
12. Casalino G, Stevenson MR, Bandello F, Chakravarthy U. Tomographic biomarkers predicting progression to fibrosis in treated neovascular age-related macular degeneration: A multimodal imaging study. *Ophthalmol Retina*. 2018;2(5):451-461. doi:10.1016/j.oret.2017.08.019
13. Chakravarthy U, Harding SP, Rogers CA, et al. A randomised controlled trial to assess the clinical effectiveness and cost-effectiveness of alternative treatments to Inhibit VEGF in Age-related choroidal Neovascularisation (IVAN). *Health Technol Assess*. 2015;19(78):1-298. doi:10.3310/hta19780
14. Chang AA, Broadhead GK, Hong T, et al. Intravitreal aflibercept for treatment-resistant neovascular age-related macular degeneration: 12-month safety and efficacy outcomes. *Ophthalmic Res*. 2015;55(2):84-90. doi:10.1159/000440886
15. Chen L, Cao D, Messinger JD, et al. Histology and clinical imaging lifecycle of black pigment in fibrosis secondary to neovascular age-related macular degeneration. *Exp Eye Res*. 2022;214:108882. doi:10.1016/j.exer.2021.108882
16. Chen L, Messinger JD, Ferrara D, Freund KB, Curcio CA. Fundus autofluorescence in neovascular age-related macular degeneration: A clinicopathologic correlation relevant to macular atrophy. *Ophthalmol Retina*. 2021;5(11):1085-1096. doi:10.1016/j.oret.2021.01.012
17. Chen M, Yang N, Lechner J, et al. Plasma level of lipocalin 2 is increased in neovascular age-related macular degeneration patients, particularly those with macular fibrosis. *Immun Ageing*. 2020;17(1):35. doi:10.1186/s12979-020-00205-w
18. Chen SJ, Cheng CY, Lee AF, Lee FL, Hsu WM, Liu JH. Pulsatile ocular blood flow of choroidal neovascularization in asymmetric age-related macular degeneration after transpupillary thermotherapy. *Eye*. 2004;18(6):595-599. doi:10.1038/sj.eye.6700723
19. Chen X, Nadiarynkh O, Plotnikov S, Campagnola PJ. Second harmonic generation microscopy for quantitative analysis of collagen fibrillar structure. *Nat Protoc*. 2012;7(4):654-669. doi:10.1038/nprot.2012.009
20. Cheong KX, Cheung CMG, Teo KYC. Review of fibrosis in neovascular age-related macular degeneration. *Am J Ophthalmol*. Published online September 2022:S0002939422003646. doi:10.1016/j.ajo.2022.09.008
21. Cheung CMG, Grewal DS, Teo KYC, et al. The evolution of fibrosis and atrophy and their relationship with visual outcomes in Asian persons with neovascular age-related macular degeneration. *Ophthalmol Retina*. 2019;3(12):1045-1055. doi:10.1016/j.oret.2019.06.002
22. Chuang EL, Bird AC. Repair after tears of the retinal pigment epithelium. *Eye*.

Journal Pre-proof

1988;2(1):106-113. doi:10.1038/eye.1988.22
23. Coscas G. Subretinal neovascularisation in senile macular degeneration. *Eye*. 1987;1(3):364-378. doi:10.1038/eye.1987.56
24. Costagliola C, Semeraro F, Cipollone U, Rinaldi M, della Corte M, Romano MR. Changes in neovascular choroidal morphology after intravitreal bevacizumab injection: Prospective trial on 156 eyes throughout 12-month follow-up. *Graefes Arch Clin Exp Ophthalmol*. 2009;247(8):1031-1037. doi:10.1007/s00417-009-1081-y
25. Daniel E, Pan W, Ying G shuang, et al. Development and course of scars in the Comparison of Age-related macular degeneration Treatments Trials. *Ophthalmology*. 2018;125(7):1037-1046. doi:10.1016/j.ophtha.2018.01.004
26. Daniel E, Toth CA, Grunwald JE, et al. Risk of scar in the Comparison of Age-related macular degeneration Treatments Trials. *Ophthalmology*. 2014;121(3):656-666. doi:10.1016/j.ophtha.2013.10.019
27. Daniel E, Ying G shuang, Kim BJ, et al. Five-year follow-up of nonfibrotic scars in the Comparison of Age-related macular degeneration Treatments Trials. *Ophthalmology*. 2019;126(5):743-751. doi:10.1016/j.ophtha.2018.11.020
28. Dansingani KK, Tan ACS, Gilani F, et al. Subretinal hyperreflective material imaged with optical coherence tomography angiography. *Am J Ophthalmol*. 2016;169:235-248. doi:10.1016/j.ajo.2016.06.031
29. De Rosa I, Ohayon A, Semoun O, et al. Real-color versus pseudo-color imaging of fibrotic scars in exudative age-related macular degeneration. *Retina*. 2020;40(12):2277-2284. doi:10.1097/IAE.0000000000002771
30. DeCroos FC, Toth CA, Stinnett SS, Heydary CS, Burns R, Jaffe GJ. Optical coherence tomography grading reproducibility during the Comparison of Age-related macular degeneration Treatments Trials. *Ophthalmology*. 2012;119(12):2549-2557. doi:10.1016/j.ophtha.2012.06.040
31. Evans RN, Reeves BC, Maguire MG, et al. Associations of variation in retinal thickness with visual acuity and anatomic outcomes in eyes with neovascular age-related macular degeneration lesions treated with anti-vascular endothelial growth factor agents. *JAMA Ophthalmol*. 2020;138(10):1043. doi:10.1001/jamaophthalmol.2020.3001
32. Evans RN, Reeves BC, Phillips D, et al. Long-term visual outcomes after release from protocol in patients who participated in the Inhibition of VEGF in Age-related choroidal Neovascularisation (IVAN) trial. *Ophthalmology*. 2020;127(9):1191-1200. doi:10.1016/j.ophtha.2020.03.020
33. Fajnkuchen F, Cohen SY, Thay N, et al. Bridge arch-shaped serous retinal detachment in age-related macular degeneration. *Retina*. 2016;36(3):476-482. doi:10.1097/IAE.0000000000000746
34. Fassbender JM, Sherman MP, Barr CC, Schaal S. Tissue plasminogen activator for subfoveal hemorrhage due to age-related macular degeneration: Comparison of 3 treatment modalities. *Retina*. 2016;36(10):1860-1865. doi:10.1097/IAE.0000000000001030
35. Finn AP, Pistilli M, Tai V, et al. Localized optical coherence tomography precursors of macular atrophy and fibrotic scar in the Comparison of Age-related macular degeneration Treatments Trials. *Am J Ophthalmol*. 2021;223:338-347. doi:10.1016/j.ajo.2020.11.002
36. Flaxel CJ, Friedrichsen EJ, Smith JO, et al. Proton beam irradiation of subfoveal choroidal neovascularisation in age-related macular degeneration. *Eye*. 2000;14(2):155-164. doi:10.1038/eye.2000.46
37. Freund KB, Zweifel SA, Engelbert M. Do we need a new classification for choroidal neovascularization in age-related macular degeneration? *Retina*. 2010;30(9):1333-1349. doi:10.1097/IAE.0b013e3181e7976b
38. Fu H, Zhang B, Tong J, et al. Relationships of orientation discrimination threshold and

Journal Pre-proof

visual acuity with macular lesions in age-related macular degeneration. Madigan M, ed. *PLOS ONE*. 2017;12(9):e0185070. doi:10.1371/journal.pone.0185070
39. Gräfe MGO, van de Kreeke JA, Willemse J, et al. Subretinal fibrosis detection using polarization sensitive optical coherence tomography. *Transl Vis Sci Technol*. 2020;9(4):13. doi:10.1167/tvst.9.4.13
40. Graham KW, Chakravarthy U, Hogg RE, Muldrew KA, Young IS, Kee F. Identifying features of early and late age-related macular degeneration: A comparison of multicolor versus traditional color fundus photography. *Retina*. 2018;38(9):1751-1758. doi:10.1097/IAE.0000000000001777
41. Green WR. Senile disciform degeneration of the macula: retinal arterialization of the fibrous plaque demonstrated clinically and histopathologically. *Arch Ophthalmol*. 1971;86(5):487. doi:10.1001/archopht.1971.01000010489001
42. Grunwald JE, Daniel E, Ying G shuang, et al. Photographic assessment of baseline fundus morphologic features in the Comparison of Age-related macular degeneration Treatments Trials. *Ophthalmology*. 2012;119(8):1634-1641. doi:10.1016/j.ophtha.2012.02.013
43. Haas A. Morphologic characteristics of disciform scarring after radiation treatment for age-related macular degeneration. *Ophthalmology*. 2000;107(7):1358-1363. doi:10.1016/S0161-6420(00)00154-8
44. Hee MR, Swanson EA, Fujimoto JG, Huang D. Polarization-sensitive low-coherence reflectometer for birefringence characterization and ranging. *J Opt Soc Am B*. 1992;9(6):903. doi:10.1364/JOSAB.9.000903
45. Henderson NC, Rieder F, Wynn TA. Fibrosis: From mechanisms to medicines. *Nature*. 2020;587(7835):555-566. doi:10.1038/s41586-020-2938-9
46. Hirami Y, Mandai M, Takahashi M, Teramukai S, Tada H, Yoshimura N. Association of clinical characteristics with disease subtypes, initial visual acuity, and visual prognosis in neovascular age-related macular degeneration. *Jpn J Ophthalmol*. 2009;53(4):396-407. doi:10.1007/s10384-009-0669-4
47. Hogg R. Identification of lesion components that influence visual function in age related macular degeneration. *Br J Ophthalmol*. 2003;87(5):609-614. doi:10.1136/bjo.87.5.609
48. Ishikawa K, Kannan R, Hinton DR. Molecular mechanisms of subretinal fibrosis in age-related macular degeneration. *Exp Eye Res*. 2016;142:19-25. doi:10.1016/j.exer.2015.03.009
49. Jaffe GJ, Ciulla TA, Ciardella AP, et al. Dual antagonism of PDGF and VEGF in neovascular age-related macular degeneration. *Ophthalmology*. 2017;124(2):224-234. doi:10.1016/j.ophtha.2016.10.010
50. Jaffe GJ, Ying GS, Toth CA, et al. Macular morphology and visual acuity in year five of the comparison of age-related macular degeneration treatments trials. *Ophthalmology*. 2019;126(2):252-260. doi:10.1016/j.ophtha.2018.08.035
51. Joeres S, Tsong JW, Updike PG, et al. Reproducibility of quantitative optical coherence tomography subanalysis in neovascular age-related macular degeneration. *Invest Ophthalmol Vis Sci*. 2007;48(9):4300. doi:10.1167/iovs.07-0179
52. Kaiser PK, Blodi BA, Shapiro H, Acharya NR. Angiographic and optical coherence tomographic results of the MARINA study of ranibizumab in neovascular age-related macular degeneration. *Ophthalmology*. 2007;114(10):1868-1875.e4. doi:10.1016/j.ophtha.2007.04.030
53. Keane PA, Patel PJ, Liakopoulos S, Heussen FM, Sadda SR, Tufail A. Evaluation of age-related macular degeneration with optical coherence tomography. *Surv Ophthalmol*. 2012;57(5):389-414. doi:10.1016/j.survophthal.2012.01.006
54. Kherani S, Scott AW, Wenick AS, et al. Shortest distance from fovea to subfoveal hemorrhage border is important in patients with neovascular age-related macular

Journal Pre-proof

degeneration. *Am J Ophthalmol*. 2018;189:86-95. doi:10.1016/j.ajo.2018.02.015
55. Kim I, Ryu G, Sagong M. Morphological features and prognostic significance of multilayered pigment epithelium detachment in age-related macular degeneration. *Br J Ophthalmol*. 2022;106:1073-1078. doi:10.1136/bjophthalmol-2020-318616
56. Kim JH, Chang YS, Kim JW, Kim CG, Lee DW, Kim YJ. Morphologic features associated with fibrotic scarring after anti-vascular endothelial growth factor therapy in polypoidal choroidal vasculopathy. *Retina*. 2018;38(11):2168-2176. doi:10.1097/IAE.0000000000001845
57. Kim KL, Park SP. Association between serum vitamin D deficiency and age-related macular degeneration in Koreans: Clinical case-control pilot study. *Medicine (Baltimore)*. 2018;97(33):e11908. doi:10.1097/MD.0000000000011908
58. Klein R, Davis MD, Magli YL, Segal P, Klein BEK, Hubbard L. The Wisconsin age-related maculopathy grading system. *Ophthalmology*. 1991;98(7):1128-1134. doi:10.1016/S0161-6420(91)32186-9
59. Krebs I, Haas P, Zeiler F, Binder S. Optical coherence tomography: Limits of the retinal-mapping program in age-related macular degeneration. *Br J Ophthalmol*. 2008;92(7):933-935. doi:10.1136/bjo.2007.128447
60. Lechner J, Chen M, Hogg RE, et al. Peripheral blood mononuclear cells from neovascular age-related macular degeneration patients produce higher levels of chemokines CCL2 (MCP-1) and CXCL8 (IL-8). *J Neuroinflammation*. 2017;14(1):42. doi:10.1186/s12974-017-0820-y
61. Lee JY, Folgar FA, Maguire MG, et al. Outer retinal tubulation in the Comparison of Age-related macular degeneration Treatments Trials (CATT). *Ophthalmology*. 2014;121(12):2423-2431. doi:10.1016/j.ophtha.2014.06.013
62. Little K, Ma JH, Yang N, Chen M, Xu H. Myofibroblasts in macular fibrosis secondary to neovascular age-related macular degeneration - The potential sources and molecular cues for their recruitment and activation. *EBioMedicine*. 2018;38:283-291. doi:10.1016/j.ebiom.2018.11.029
63. Llorente- González S, Hernandez M, González- Zamora J, et al. The role of retinal fluid location in atrophy and fibrosis evolution of patients with neovascular age- related macular degeneration long- term treated in real world. *Acta Ophthalmol (Copenh)*. 2022;100(2). doi:10.1111/aos.14905
64. Maruyama-Inoue M, Sato S, Yamane S, Kadonosono K. Variable response of subretinal hyperreflective material to anti-vascular endothelial growth factor classified with optical coherence tomography angiography. *Graefes Arch Clin Exp Ophthalmol*. 2018;256(11):2089-2096. doi:10.1007/s00417-018-4121-7
65. Mathew R, Pearce E, Sivaprasad S. Determinants of fixation in eyes with neovascular age-related macular degeneration treated with intravitreal ranibizumab. *Am J Ophthalmol*. 2012;153(3):490-496.e1. doi:10.1016/j.ajo.2011.08.034
66. Mehta A, Steel DH, Muldrew A, et al. Associations and Outcomes of Patients with Submacular Hemorrhage Secondary to Age-related Macular Degeneration in the IVAN Trial. *Am J Ophthalmol*. 2022;236:89-98. doi:10.1016/j.ajo.2021.09.033
67. Mekjavic PJ, Kraut A, Urbancic M, Lenassi E, Hawlina M. Efficacy of 12-month treatment of neovascular age-related macular degeneration with intravitreal bevacizumab based on individually determined injection strategies after three consecutive monthly injections. *Acta Ophthalmol (Copenh)*. 2011;89(7):647-653. doi:10.1111/j.1755-3768.2009.01740.x
68. Michels S, Pircher M, Geitzenauer W, et al. Value of polarisation-sensitive optical coherence tomography in diseases affecting the retinal pigment epithelium. *Br J Ophthalmol*. 2008;92(2):204-209. doi:10.1136/bjo.2007.130047
69. Miere A, Semoun O, Cohen SY, et al. Optical coherence tomography angiography features of subretinal fibrosis in age-related macular degeneration. *Retina*.

Journal Pre-proof

2015;35(11):2275-2284. doi:10.1097/IAE.0000000000000819
70. Miura M, Yamanari M, Iwasaki T, et al. Imaging polarimetry in age-related macular degeneration. *Invest Ophthalmol Vis Sci*. 2008;49(6):2661. doi:10.1167/iovs.07-0501
71. Mohammad F, Wanek J, Zelkha R, Lim JI, Chen J, Shahidi M. A method for en face OCT imaging of subretinal fluid in age-related macular degeneration. *J Ophthalmol*. 2014;2014:1-6. doi:10.1155/2014/720243
72. Motschi AR, Roberts PK, Desissaire S, et al. Identification and quantification of fibrotic areas in the human retina using polarization-sensitive OCT. *Biomed Opt Express*. 2021;12(7):4380. doi:10.1364/BOE.426650
73. Ohayon A, De Rosa I, Semoun O, et al. Subretinal pigment epithelium fibrotic tissue morphological changes after a single anti-vascular endothelial growth factor injection in age-related macular degeneration. *Br J Ophthalmol*. 2020;104(8):1085-1088. doi:10.1136/bjophthalmol-2019-314923
74. Parolini B, Grewal DS, Pinackatt SJ, et al. Combined autologous transplantation of neurosensory retina, retinal pigment epithelium, and choroid free grafts. *Retina*. 2018;38(1):S12-S22. doi:10.1097/IAE.0000000000001914
75. Peto T, Evans RN, Reeves BC, et al. Long-term retinal morphology and functional associations in treated neovascular age-related macular degeneration. *Ophthalmol Retina*. 2022;6(8):664-675. doi:10.1016/j.oret.2022.03.010
76. Pokroy R, Mimouni M, Barayev E, et al. Prognostic value of subretinal hyperreflective material in neovascular age-related macular degeneration treated with bevacizumab. *Retina*. 2018;38(8):1485-1491. doi:10.1097/IAE.0000000000001748
77. Querques L, Parravano M, Borrelli E, et al. Anatomical and functional changes in neovascular AMD in remission: Comparison of fibrocellular and fibrovascular phenotypes. *Br J Ophthalmol*. 2020;104(1):47-52. doi:10.1136/bjophthalmol-2018-313685
78. Rahimy E, Freund KB, Larsen M, et al. Multilayered pigment epithelial detachment in neovascular age-related macular degeneration. *Retina*. 2014;34(7):1289-1295. doi:10.1097/IAE.0000000000000130
79. Riusala A, Sarna S, Immonen I. Visual acuity and structural findings in old age-related macular degeneration. *Graefes Arch Clin Exp Ophthalmol*. 2005;243(9):947-950. doi:10.1007/s00417-005-1161-6
80. Riusala AM, Immonen IJR. Predictors of structural findings in old disciform lesions. *Am J Ophthalmol*. 2004;138(2):245-253. doi:10.1016/j.ajo.2004.03.007
81. Roberts P, Sugita M, Deák G, et al. Automated identification and quantification of subretinal fibrosis in neovascular age-related macular degeneration using polarization-sensitive OCT. *Invest Ophthalmol Vis Sci*. 2016;57(4):1699. doi:10.1167/iovs.15-18694
82. Roberts PK, Schranz M, Motschi A, et al. Baseline predictors for subretinal fibrosis in neovascular age-related macular degeneration. *Sci Rep*. 2022;12(1):88. doi:10.1038/s41598-021-03716-8
83. Roberts PK, Schranz M, Motschi A, et al. Morphologic and microvascular differences between macular neovascularization with and without subretinal fibrosis. *Transl Vis Sci Technol*. 2021;10(14):1. doi:10.1167/tvst.10.14.1
84. Roberts PK, Zotter S, Montuoro A, et al. Identification and quantification of the angiofibrotic switch in neovascular AMD. *Invest Ophthalmol Vis Sci*. 2019;60(1):304. doi:10.1167/iovs.18-25189
85. Rofagha S, Bhisitkul RB, Boyer DS, Sadda SR, Zhang K. Seven-year outcomes in ranibizumab-treated patients in ANCHOR, MARINA, and HORIZON. *Ophthalmology*. 2013;120(11):2292-2299. doi:10.1016/j.ophtha.2013.03.046
86. Rogers AH, Martidis A, Greenberg PB, Puliafito CA. Optical coherence tomography findings following photodynamic therapy of choroidal neovascularization. *Am J Ophthalmol*. 2002;134(4):566-576. doi:10.1016/S0002-9394(02)01566-0

Journal Pre-proof

87. Rosenfeld PJ, Shapiro H, Tuomi L, Webster M, Elledge J, Blodi B. Characteristics of patients losing vision after 2 years of monthly dosing in the phase III ranibizumab clinical trials. *Ophthalmology*. 2011;118(3):523-530. doi:10.1016/j.ophtha.2010.07.011
88. Ryu CL, Al-humaid S, Rampakakis E, Galic IJ, Chen JC. Correlation of visual acuity with fibrotic scar location in treated neovascular age-related macular degeneration eyes. *Retina*. 2016;36(7):1324-1330. doi:10.1097/IAE.0000000000000877
89. Sagiv O, Zloto O, Moroz I, Moisseiev J. Different clinical courses on long-term follow-up of age-related macular degeneration patients treated with intravitreal anti-vascular endothelial growth factor injections. *Ophthalmologica*. 2017;238(4):217-225. doi:10.1159/000479437
90. Sahni J, Stanga P, Wong D, Lenfestey P, Kent D, Harding S. Optical coherence tomography analysis of bilateral end-stage choroidal neovascularization where one eye is treated with photodynamic therapy. *Clin Experiment Ophthalmol*. 2007;35(1):13-17. doi:10.1111/j.1442-9071.2006.01385.x
91. Schmidt-Erfurth U, Waldstein SM. A paradigm shift in imaging biomarkers in neovascular age-related macular degeneration. *Prog Retin Eye Res*. 2016;50:1-24. doi:10.1016/j.preteyeres.2015.07.007
92. Shah VP, Shah SA, Mrejen S, Freund KB. Subretinal hyperreflective exudation associated with neovascular age-related macular degeneration. *Retina*. 2014;34(7):1281-1288. doi:10.1097/IAE.0000000000000166
93. Sharma S, Toth CA, Daniel E, et al. Macular morphology and visual acuity in the second year of the Comparison of Age-related macular degeneration Treatments Trials. *Ophthalmology*. 2016;123(4):865-875. doi:10.1016/j.ophtha.2015.12.002
94. Singh A, Falk MK, Subhi Y, Sørensen TL. The association between plasma 25-hydroxyvitamin D and subgroups in age-related macular degeneration: A cross-sectional study. Mori K, ed. *PLoS ONE*. 2013;8(7):e70948. doi:10.1371/journal.pone.0070948
95. Souied EH, Addou-Regnard M, Ohayon A, et al. Spectral-domain optical coherence tomography analysis of fibrotic lesions in neovascular age-related macular degeneration. *Am J Ophthalmol*. 2020;214:151-171. doi:10.1016/j.ajo.2020.02.016
96. Souied EH, Miere A, Cohen SY, Semoun O, Querques G. Optical coherence tomography angiography of fibrosis in age-related macular degeneration. In: Bandello F, Souied EH, Querques G, eds. *Developments in Ophthalmology*. Vol 56. S. Karger AG; 2016:86-90. doi:10.1159/000442783
97. Spaide RF, Jaffe GJ, Sarraf D, et al. Consensus nomenclature for reporting neovascular age-related macular degeneration data. *Ophthalmology*. 2020;127(5):616-636. doi:10.1016/j.ophtha.2019.11.004
98. Tenbrock L, Wolf J, Boneva S, et al. Subretinal fibrosis in neovascular age-related macular degeneration: Current concepts, therapeutic avenues, and future perspectives. *Cell Tissue Res*. Published online September 3, 2021. doi:10.1007/s00441-021-03514-8
99. Teo KYC, Joe AW, Nguyen V, et al. Prevalence and risk factors for the development of physician-graded subretinal fibrosis in eyes treated for neovascular age-related macular degeneration. *Retina*. 2020;40(12):2285-2295. doi:10.1097/IAE.0000000000002779
100. Toth CA, Tai V, Chiu SJ, et al. Linking OCT, angiographic, and photographic lesion components in neovascular age-related macular degeneration. *Ophthalmol Retina*. 2018;2(5):481-493. doi:10.1016/j.oret.2017.09.016
101. Toth CA, Tai V, Pistilli M, et al. Distribution of OCT features within areas of macular atrophy or scar after 2 years of anti-VEGF treatment for neovascular AMD in CATT. *Ophthalmol Retina*. 2019;3(4):316-325. doi:10.1016/j.oret.2018.11.011
102. Toth LA, Stevenson M, Chakravarthy U. Anti-vascular endothelial growth factor therapy for neovascular age-related macular degeneration: Outcomes in eyes with poor initial vision. *Retina*. 2015;35(10):1957-1963. doi:10.1097/IAE.0000000000000583

Journal Pre-proof

103. Trikha R, Morse LS, Zawadzki RJ, Werner JS, Park SS. Ten-year follow-up of eyes treated with stereotactic fractionated external beam radiation for neovascular age-related macular degeneration. *Retina*. 2011;31(7):1303-1315. doi:10.1097/IAE.0b013e318203ee46
104. Tsai DC, Charng MJ, Lee FL, Hsu WM, Chen SJ. Different plasma levels of vascular endothelial growth factor and nitric oxide between patients with choroidal and retinal neovascularization. *Ophthalmologica*. 2006;220(4):246-251. doi:10.1159/000093079
105. van Velthoven MEJ, de Smet MD, Schlingemann RO, Magnani M, Verbraak FD. Added value of OCT in evaluating the presence of leakage in patients with age-related macular degeneration treated with PDT. *Graefes Arch Clin Exp Ophthalmol*. 2006;244(9):1119-1123. doi:10.1007/s00417-005-0209-y
106. Wickremasinghe SS, Janakan V, Sandhu SS, Amirul-Islam FM, Abedi F, Guymer RH. Implication of recurrent or retained fluid on optical coherence tomography for visual acuity during active treatment of neovascular age-related macular degeneration with a treat and extend protocol. *Retina*. 2016;36(7):1331-1339. doi:10.1097/IAE.0000000000000902
107. Willoughby AS, Ying G shuang, Toth CA, et al. Subretinal hyperreflective material in the Comparison of Age-related macular degeneration Treatments Trials. *Ophthalmology*. 2015;122(9):1846-1853.e5. doi:10.1016/j.ophtha.2015.05.042
108. Wynn TA. Common and unique mechanisms regulate fibrosis in various fibroproliferative diseases. *J Clin Invest*. 2007;117(3):524-529. doi:10.1172/JCI31487
109. Xu D, Dávila JP, Rahimi M, et al. Long-term progression of type 1 neovascularization in age-related macular degeneration using optical coherence tomography angiography. *Am J Ophthalmol*. 2018;187:10-20. doi:10.1016/j.ajo.2017.12.005
110. Zhao Z, Yang F, Gong Y, et al. The comparison of morphologic characteristics of type 1 and type 2 choroidal neovascularization in eyes with neovascular age-related macular degeneration using optical coherence tomography angiography. *Ophthalmologica*. 2019;242(3):178-186. doi:10.1159/000497491

Figure Legends

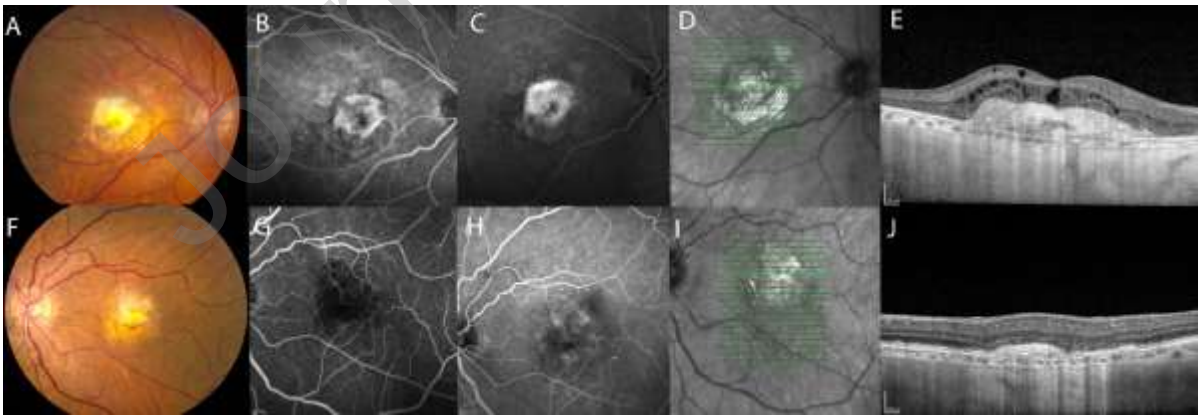

Figure 1.
A-E: Multimodal imaging showing fibrosis in the right eye of a patient with long standing nAMD. On CFP (A), whitish tissue can be seen within the lesion and is bordered at the infero-nasal aspect by a crescentic area of atrophy consistent with an RPE tear. On FA (B, C), the fibrotic tissue stains without leakage in the late frames (C). On the NIR image (D), the scrolled edge of the RPE tear is visible (white asterisk). The highlighted B scan passes through the region of fibrosis and the structural OCT (E) reveals a well-defined linearly oriented region of subretinal hyperreflective material with heterogenous reflectivity.

Journal Pre-proof

F-J: Multimodal imaging showing fibrosis in the left eye of a nAMD patient. On CFP (F), there is a central area of whitish fibrotic tissue surrounded by pallor representing atrophy. FA, early (G) and late (H) frames show hyperfluorescent regions of staining without leakage consistent with fibrotic tissue. NIR (I) shows increased reflectance. On SD-OCT (J), the B-scan transects the area of fibrosis and shows subretinal hyperreflective material (HRM), with increased choroidal hypertransmission adjacent to the HRM and in regions of the HRM with RPE loss and outer retinal layer thinning and disruption.
CPF, color fundus photography. FA, fluorescein angiography. nAMD, neovascular age-related macular degeneration. NIR, near infrared. RPE, retinal pigment epithelium. SD-OCT, spectral-domain optical coherence tomography.

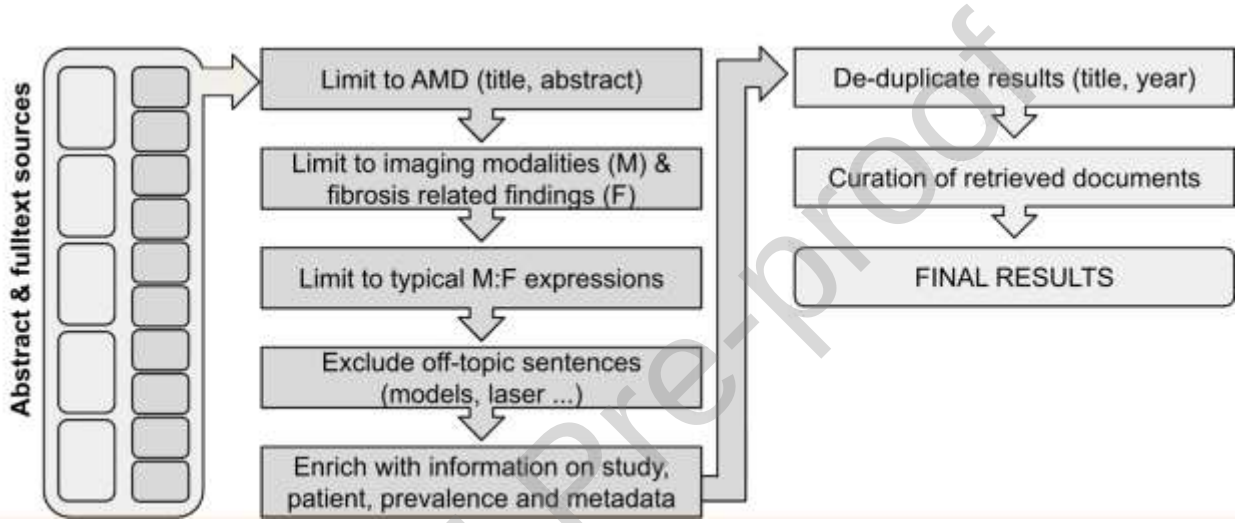

Figure 2: Outline of the process: text-mining steps (dark gray), manual curation steps (light gray).

Table 1. Fibrosis criteria based on SD-/SS-OCT, demonstrating a large variability in the level of detail. Note: this is a subset of publications that used SD-/SS-OCT in a unimodal fashion to determine the presence of fibrosis. The full set of OCT characterizations (including TD-OCT, or when OCT was part of a multimodal approach) can be found in Supplementary table S2. ELM, external limiting membrane; EZ, ellipsoid zone; HRM, hyperreflective material; OCT, optical coherence tomography; PED, pigment epithelial detachment; RPE, retinal pigment epithelium; SHRM, subretinal hyperreflective material.

First author, year	**Definition on SD-/SS-OCT**
Mathew 2012 [65]	Uniform, spindle-shaped or fusiform hyperreflective band that straddles the RPE
Singh 2013 [94]	Dense hyperreflective area between the RPE and neurosensory area or beneath the RPE. Subretinal fibrin exudation was not included in the definition.
Casalino 2016 [11]	Well-defined HRM: Hyperreflective material with high reflectivity whose boundaries can be clearly delineated from the surrounding neural components of the retina. (...) this OCT feature represents fibrosed tissue and/or mature neovascular complexes.
Wickremasinghe 2016 [106]	Increased reflectance at the level of the RPE
Fu 2017 [38]	Well-demarcated, highly hyper-reflective material in the subretinal or sub-RPE space

Journal Pre-proof

Pokroy 2018 [76]	SHRM persistence is consistent with subretinal fibrosis development
Kherani 2018 [54]	When SHRM was highly reflective with well-demarcated, sharp borders and loss or disruption of overlying EZ and ELM.
Ohayon 2020 [73]	Fibrotic multilayered PED
Llorente-Gonzalez 2021 [63]	Hyperreflective lesion at the RPE level

Table 2. Classifications of fibrosis ordered by uni- or multimodal imaging, and per year. CFP, color fundus photography; CNV, choroidal neovascularization; DD, disc diameter; FA, fluorescein angiography; OCT, optical coherence tomography; OCT-A, OCT-angiography; PDT, photodynamic therapy; RPE, retinal pigment epithelium; SD-OCT, spectral-domain OCT; SHRM, subretinal hyperreflective material; SS-OCT, swept-source OCT. *Bloch 2013 abbreviated and adjusted Rogers' stages of 2002.

Imaging modality	**Feature graded**	**Grades/stages/groups**	**Author, Year**
CFP	Subretinal fibrous scar extent	Absent, Questionable, Less than 25%, 25-49%, >50% of the subfield, Cannot grade	Klein, 1991 [58]
CFP	Subretinal fibrosis severity	0= absent. 1= barely visible. 2= mild. 3= moderate. 4= severe.	Jaffe, 2017 [49]
FA	Fibrosis extent (% of lesion)	0 = none, 1 = 1–25%, 2 = 26–50%, 3 = 51–75%, 4 = >75% of the lesion	Hogg, 2003 [47]
TD-OCT	Morphology of CNV after PDT	Stage I: Acute inflammatory response with increased intraretinal and subretinal fluid, no fibrosis. Stage II: resolution of intraretinal and subretinal fluid, no fibrosis. Stage IIIa: reaccumulation of intraretinal and subretinal fluid with early subretinal fibrosis (greater subretinal fluid to fibrosis ratio than IIIb). Stage IIIb: reaccumulation of intraretinal and subretinal fluid with early subretinal fibrosis (more prominent fibrosis and minimal subretinal or intraretinal fluid). Fibrosis on OCT: "highly reflective yellow–red band between the low reflective outer retina and the prominent red band representing the RPE/choriocapillaris". Stage IV: increasing subretinal fibrosis with cystoid macular edema. Involuting CNV on OCT: "highly reflective band merging with RPE/choriocapillaris layer obliterating the double band of fibrosis observed in stage III". Stage V: complete fluid resolution, subretinal fibrosis with retinal atrophy. OCT: "reflective fibrotic CNV that had merged with the RPE/choriocapillaris band in stage IV further matured as an elevated reflective mound".	Rogers, 2002 [86]
SD-OCT	Fibrosis location in relation to the RPE	Type A: located underneath the RPE. Type B: located above the RPE. Type C: the remaining RPE was undistinguishable.	Souied, 2020 [95]

Journal Pre-proof

CFP + FA	Morphology of CNV ("disciform lesion") after radiation	Type I lesions: smaller than 2 disc diameters (DD), with minimal subretinal fibrotic tissue and only few or no exudates, but pronounced RPE atrophy. Type II lesions: extensive growth of the CNV extending to and beyond the arcades, with a marked exudative reaction and with angiographically active loops in the peripheral portions of the neovascularization. Type III lesions: similar to spontaneous disciform fibrosis, with a size between 2 DD and 6 DD and various amounts of fibrotic tissue, hemorrhage, and lipid	Haas, 2000 [43]
CFP + FA	Fibrosis extent (greatest linear dimension)	Small: <3500 µm. Large: 3500–5000 µm. Very large: >5000 µm	Sahni, 2007 [90]
CFP + FA	Fibrosis extent (% of lesion)	0–25%, 26–50%, 51–75%, 76–100% of the lesion	Toth, 2015 [102]
CFP + FA	Fibrosis extent (% of lesion)	No scar, Barely visible: scar involving approximately 25% of the lesion, Mild: scar involving approximately 50% of the lesion, Moderate: scar involving approximately 75% of the lesion, Severe: the entire lesion consisted of a scar	Casalino, 2018 [12]
FA + red-free photography	Fibrosis presence & location	Not detected: absent, any subfoveal: subfoveal fibrosis observed alone or with other locations, extrafoveal only: extrafoveal but not subfoveal, Other: remote location only or not reported	Adrean, 2020 [1]
CFP + SD-OCT	Subfoveal fibrous tissue severity and associated OCT features	Stage I: minimal fibrosis with or without subretinal fluid. Stage II: prominent fibrosis with or without cystoid edema. Stage III: fibrosis with overlying neurosensory retinal atrophy	Bloch, 2013* [8]
CFP + SS-OCT	Fibrosis severity	Mild: subtle whitening of the macular area on fundus imaging and minimal associated SHRM on OCT. Moderate: intense whitening of the macular area and SHRM of more than 100 µm thickness on OCT. Severe fibrosis/fibrotic scars: "mound" of fibrotic material on color fundus image and elevated SHRM on OCT.	Balaskas, 2019 [2]
FA + SD-OCT	Exudation associated with fibrosis	Group A: no exudative signs (i.e. no subretinal or intraretinal fluid on SD-OCT in the last 6 months). Group B: current exudative signs (subretinal and/or intraretinal fluid on SD-OCT).	Miere, 2015 [69]

Table 3. Summary of fibrosis prevalence per imaging modality after the introduction of anti-VEGF therapies reported in publications that provided a clear definition of fibrosis. CFP, color fundus photography; FA, fluorescein angiography; N, number of studies; NA, not applicable. SD-OCT, spectral-domain optical coherence tomography.

Imaging modalit(ies)	Prevalence Mean (%)	Prevalence Range (Min - Max, %)	Difference between Min and Max	N	References
CFP + FA	50.4	17.0 - 82.9	65.9	5	12,13,26,67,102
CFP + SD-OCT	30.7	14.0 – 50.0	36.0	6	8,17,55,84,89,110
CFP	45.1	5.1 - 93.3	88.2	5	49,56,85, A, F

Journal Pre-proof

FA	26.2	9.1-43.3	34.2	2	[1,3]
SD-OCT	42.0	21.4 - 56.3	34.9	5	[11,54,65,76,106]

IX. Other cited material

A. Lindenberg S, Fitzgerald ME, Nittala MG, Verma A, Sadda SR. Subretinal hyperreflective material within regions of atrophy in treated eyes with neovascular age-related macular degeneration. *Invest Ophthalmol Vis Sci.* 2019;60(9):1185-1185.

B. Motschi AR, Desissaire S, Schranz M, et al. Using polarization-sensitive OCT to detect and quantify fibrotic lesions in the human retina. *Invest Ophthalmol Vis Sci.* 2021;62(8):2509.

C. Yamanari M, Matsuzaki M, Takagi S, et al. Polarization-sensitive swept-source OCT imaging of retinal pigment epithelium and subretinal fibrous tissues. *Invest Ophthalmol Vis Sci.* 2018;59:291.

D. Wilda M, Hurtenbach C, Corkery E, Etheridge T, Domalpally A, Blodi BA. Optical coherence tomography characteristics of subretinal fibrosis in neovascular AMD. *Invest Ophthalmol Vis Sci.* 2020;61(7):1804.

E. Schranz M, Roberts PK, Sacu S, et al. How reliable is the clinical diagnosis of subretinal fibrosis in neovascular age-related macular degeneration? *Invest Ophthalmol Vis Sci.* 2019;60(9):4224-4224.

F. Yoshiaki Y, Shinnosuke A, Deepa K, Satoshi S, Masahiro M, Shuichi M. Compact and stable posterior multi-contrast Jones-matrix OCT for pigment, flow, and fibrotic tissue imaging. *Invest Ophthalmol Vis Sci* June 2020. 61(7):1819.

Highlights

- There is no consensus on the clinical definition of fibrosis in nAMD
- The criteria for the presence of fibrosis are not harmonized, especially on OCT
- OCT may enable detection of thin fibrosis and allow a robust quantification
- The latter is currently challenging due to lack of a fibrosis severity scale
- Future work should focus on an OCT-based definition and biomarkers of fibrosis

Journal Pre-proof