

Received: 2022.11.22

Accepted: 2023.03.01

Available online: 2023.03.08

Published: 2023.04.09

# A 24-Year-Old Man with Spontaneous Right Tension Pneumothorax Presenting with Abdominal Pain with an Initial Symptomatic Diagnosis of Acute Pancreatitis

Authors' Contribution:

Study Design A

Data Collection B

Statistical Analysis C

Data Interpretation D

Manuscript Preparation E

Literature Search F

Funds Collection G

ABCDEF 1 **Mohammad F. Al-Hurani**  
CDEF 2,3 **Gregor J. Kocher** 

1 Department of General Surgery, Urology and Anesthesia, Faculty of Medicine, The Hashemite University, Zarqa, Jordan  
2 Department of Thoracic Surgery, Hirslanden Clinic Beau Site Bern and Lindenhof Hospital, Bern, Switzerland  
3 Division of Thoracic Surgery, University of Bern, Bern, Switzerland

**Corresponding Author:** Mohammad F. Al-Hurani, e-mail: [Mohammadf\\_mo@hu.edu.jo](mailto:Mohammadf_mo@hu.edu.jo)  
**Financial support:** None declared  
**Conflict of interest:** None declared

**Patient:** Male, 24-year-old  
**Final Diagnosis:** Tension pneumothorax  
**Symptoms:** Epigastric abdominal pain  
**Clinical Procedure:** —  
**Specialty:** Surgery

**Objective:** Unusual clinical course

**Background:** Tension pneumothorax (TP) is a medical emergency resulting in air accumulation in the pleural cavity of the affected side. Later, this air applies pressure on the mediastinal structures, leading to a shift of these structures toward the contralateral side. This shift results in a picture of obstructive shock with a possibly fatal consequence if not detected and treated early. Treatment should not await radiological confirmation, and the red flags in the history and physical examination are enough to proceed with decompressing the affected hemithorax with a large-bore needle. Usually, patients with TP present to the Emergency Department with pleuritic chest pain and shortness of breath, but rare presentations are still possible.

**Case Report:** We report a case of a 24-year-old male patient with TP who presented to the Emergency Department with severe epigastric abdominal pain with a clinical picture of acute pancreatitis. X-ray showed a right-sided TP. Immediately, we performed a needle decompression followed by chest tube insertion. Four days later, the patient was discharged home uneventfully.

**Conclusions:** In this case report, we aim to draw the attention of physicians in the Emergency Department to the need to consider the possibility of upper abdominal pain elicited by chest pathologies. Furthermore, we need to investigate the effect of TP on coronary perfusion.

**Keywords:** Chest Pain • Pneumothorax • Thoracic Surgery

**Full-text PDF:** <https://www.amjcaserep.com/abstract/index/idArt/939036>



1054



—



2



8



Publisher's note: All claims expressed in this article are solely those of the authors and do not necessarily represent those of their affiliated organizations, or those of the publisher, the editors and the reviewers. Any product that may be evaluated in this article, or claim that may be made by its manufacturer, is not guaranteed or endorsed by the publisher

## Background

Pneumothorax is an accumulation of air in the pleural cavity. It can result from trauma to the chest cavity (traumatic pneumothorax) or underlying disease (secondary spontaneous pneumothorax), while in cases of no identifiable underlying etiology, it is called primary spontaneous pneumothorax (PSP) [1]. PSP is a common cause of pleuritic chest pain and dyspnea in tall young men [2]. It usually results from a ruptured lung bullae or bleb [2].

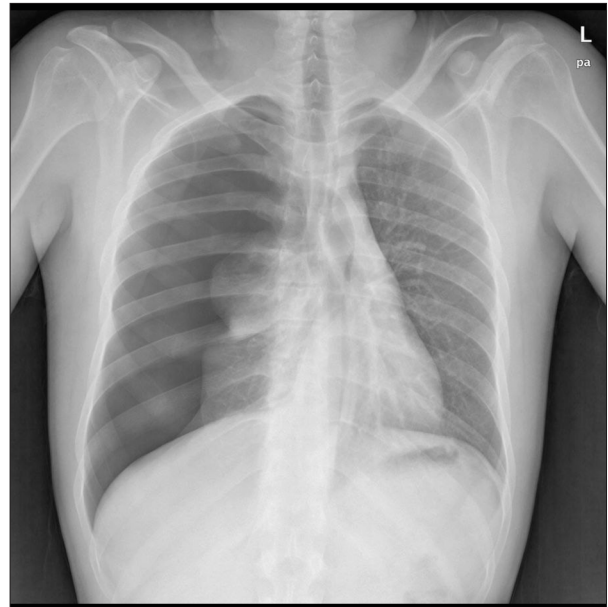
All pneumothoraces, regardless of the etiology, can present without mediastinal displacement (simple pneumothorax) or with mediastinal displacement (tension pneumothorax [TP]), which is considered a fatal condition if left untreated [1,3].

Usually, we diagnose pneumothorax using radiological imaging, including X-ray and computed tomography, except for tension pneumothorax, which is a clinical diagnosis that should be managed initially with needle decompression and then chest tube insertion.

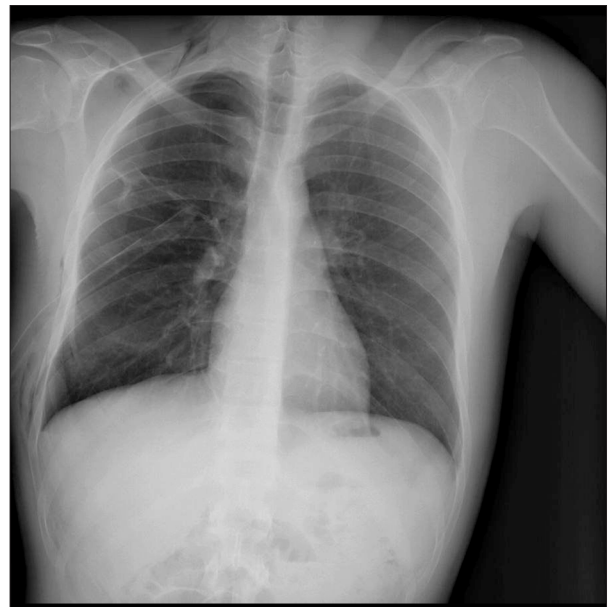We report the case of a 24-year-old healthy male patient who presented to the Emergency Department (ED) complaining of acute onset of severe epigastric abdominal pain due to right-sided TP.

## Case Report

A 24-year-old male patient, with unremarkable medical or surgical history except for heavy smoking, presented to the ED with severe epigastric abdominal pain of a 4-h duration. The pain started suddenly in the epigastric area of the abdomen, with radiation to the back. The pain was continuous and increasing in intensity over time, with mild pain relief when leaning forward. Additionally, it was associated with dyspnea but without any chest pain. On arrival, the patient's vital signs were within normal limits, except for his heart rate, which was 130 beats per min. His temperature was 37.2°C, blood pressure was 100/70 mmHg, and oxygen saturation was 92%. On examination, he had tenderness in the epigastric area; otherwise, his abdominal examination was unremarkable. After the history taking and physical examination, blood samples were sent to the biochemistry laboratory. The laboratory tests included complete blood count, kidney function test, lipase, liver function test, serum glucose, C-reactive protein, and cardiac enzymes. All his laboratory tests were within normal ranges except for a slight elevation in white blood count ( $14 \times 10^9/L$ ) (reference range:  $4-11 \times 10^9/L$ ). Furthermore, an electrocardiogram was performed and did not show any abnormality. Subsequently, an abdominal X-ray was ordered to rule out any free air under the diaphragm due to perforated viscus. Surprisingly, right



**Figure 1.** Posterior-anterior chest X-ray shows tension pneumothorax with mediastinal shifting.



**Figure 2.** Chest X-ray after chest tube insertion. There is complete resolution of the pneumothorax and the right lung is fully expanded.

tension pneumothorax was obvious on his X-ray (Figure 1). Immediately, the decision to decompress the right pleural cavity with a large-bore needle was made. Later, definite treatment with a chest tube was performed in the right triangle of safety. After that, complete resolution of his symptoms was observed, and his right lung regained full expansion (Figure 2). Then, the patient was admitted to the surgical ward in the hospital. Four days later, he was discharged home free of any symptoms.

## Discussion

In this report, we aim to draw the attention of physicians to the need to never neglect pathologies originating from the chest, neither during history taking nor in physical examination of patients presenting with acute upper abdominal pain. Acute abdominal pain is among the most frequent causes of ED visits. Abdominal pain located in the upper abdomen can result from gastrointestinal pathologies of foregut embryological origin or pathologies related to the cardio-thoracic organs, like inferior myocardial infarction (MI) or lower lobe pneumonia. Upper abdominal pain as the main symptom of pneumothorax has only rarely been described in the international literature, and although 3 hypotheses attempt to explain this rare presentation [4], no hypothesis has been proven yet. The first hypothesis claims that the pain originates from depression of the diaphragm on the affected side in patients with TP [5]. The second hypothesis attributes the pain to a small pleural effusion on the affected side [2]. Furthermore, the third hypothesis relates this pain to traction applied to the pulmonary ligament due to lung collapse [6].

However, we hypothesize another explanation that depends on understanding the pathophysiology of TP; namely, displacement of mediastinal structures will affect the filling of the heart, leading to obstructive shock. Consequently, this can also affect cardiac muscle perfusion, giving a clinical picture of inferior MI that presents as epigastric pain [7]. Since we already considered MI in the differential diagnosis, an electrocardiogram and cardiac enzymes were performed, and all were normal.

PSP is a common disease in tall young men. Its etiology relates to a rupture of a lung bulla or lung blebs, which results in the accumulation of air in the pleural cavity leading to pneumothorax [2]. If the volume of leaking air is significant, this can lead to the development of TP.

TP is considered a red flag that should be caught during the primary assessment of any patient. Postponing the treatment

of this condition until radiological confirmation can result in fatal consequences due to the obstructive shock that could develop. Subsequently, there is no rule for conservative treatment in patients with TP; the conservative treatment is preserved for those with uncomplicated PSP [8]. In our case, the initial treatment consisted of needle decompression of the affected side, followed by chest tube insertion once the patient was stabilized.

We searched PubMed and have identified 5 cases of SP presenting with abdominal pain as the main symptom [2,4-6]. All except 1 were treated only with chest tube insertion, without any need for further surgical intervention [2,4-6]. Only 1 case presented as right upper quadrant pain mimicking acute cholecystitis [2], while the other 4 cases presented as epigastric abdominal pain. Furthermore, only 2 cases were documented to have TP, while the other case reports did not mention the development of TP. Additionally, all the reported patients were at young ages with no underlying cause except in the case reported by Mizumoto, in which the patient was a known case of COPD [4]. Interestingly, the patient was treated conservatively [4].

## Conclusions

TP rarely presents as epigastric abdominal pain, especially in the case of SP. The differential diagnosis of upper abdominal pain should always include cardiothoracic pathologies. Therefore, careful history taking and examination performance are crucial as they lead to the correct diagnosis in most cases. Moreover, further studies are needed to investigate the effect of TP on coronary perfusion.

## Declaration of Figures' Authenticity

All figures submitted have been created by the authors who confirm that the images are original with no duplication and have not been previously published in whole or in part.

## References:

1. Jalota Sahota R, Sayad E. Tension pneumothorax. [Updated 2022 Nov 28]. In: StatPearls [Internet]. Treasure Island (FL): StatPearls Publishing; 2022
2. Lien WC, Yuan A, Tsai KC, et al. Primary spontaneous pneumothorax with clinical manifestation mimicking acute cholecystitis. *J Emerg Med.* 2004;26(3):354-56
3. Rojas R, Wasserberger J, Balasubramaniam S. Unsuspected tension pneumothorax as a hidden cause of unsuccessful resuscitation. *Ann Emerg Med.* 1983;12(6):411-12
4. Mizumoto J. Pneumothorax presenting as epigastric pain. *J Gen Fam Med.* 2021;22(5):291-92
5. Hollins GW, Beattie T, Harper I, Little K. Tension pneumothorax: Report of two cases presenting with acute abdominal symptoms. *J Accid Emerg Med.* 1994;11(1):43-44
6. Ogawa R, Yamamoto Y, Haraguchi N, et al. Spontaneous pneumothorax presenting as epigastric pain. *Am J Emerg Med.* 2005;23(4):572-74
7. Culić V, Mirić D, Eterović D. Correlation between symptomatology and site of acute myocardial infarction. *Int J Cardiol.* 2001;77(2-3):163-68
8. Brown SGA, Ball EL, Perrin K, et al. Conservative versus interventional treatment for spontaneous pneumothorax. *N Engl J Med.* 2020;382(5):405-15