



Case Report

Reconstruction during Pancreatic Head Resection in Patients with Altered Anatomy after Roux-Y-Gastric Bypass Surgery

Wenning Anna Silvia¹, Aeschbacher Pauline¹, Storni Federico¹, Nett Philipp C², Gloor Beat^{3*}

¹Department of Visceral Surgery and Medicine, Inselspital, Bern University Hospital, University of Bern; CH-3010 Bern, Switzerland

²Department of Visceral Surgery and Medicine

³Department of Visceral Surgery and Medicine

*Corresponding author: Gloor Beat, Department of Visceral Surgery and Medicine, Inselspital, University Bern; CH-3010 Bern, Switzerland

ASW and PA contributed equally

Citation: Wenning AS, Aeschbacher P, Storni F, Nett PC, Gloor B (2022) Reconstruction during Pancreatic Head Resection in Patients with Altered Anatomy after Roux-Y-Gastric Bypass Surgery. Ann Case Report. 7: 955. DOI: 10.29011/2574-7754.100955

Received Date: 17 September 2022; **Accepted Date:** 21 September 2022; **Published Date:** 23 September 2022

Introduction

In Western countries, obesity is highly prevalent and continues to be frequently treated surgically. Metabolic surgery, in general and specifically, bariatric surgery has become widely used in obese patients, leading to efficient weight loss and improvement of glycaemic control. Roux-Y-gastric bypass consists in a proximal gastric transection, followed by a gastro-jejunal and jejuno-jejunal anastomosis. Excluding the stomach remnant and the duodenum from the intestinal passage heavily reduces the possibilities for endoscopic diagnostic and therapeutically procedures in case of suspected duodenal or pancreatic malignancies. Once the indication for a pancreatic head resection is established, the surgeon must decide on how to deal with the stomach remnant. There are two standard techniques for dealing with the stomach during pancreatic head resection. For a classic pancreatic head resection, the so-called Kausch-Whipple procedure, the antrum of the stomach is resected. The stomach can also be left untouched in the so-called pylorus-preserving pancreatic head resection with dissection within the first two centimetres of the duodenum. Regardless of the resection technique chosen for pancreatic head resection, in patients after bariatric bypass surgery, pancreatic head resection leads to a proximally and distally dissected stomach. Importantly, for both technical variants, the right gastric artery and the gastroepiploic artery are ligated, leaving the left gastric artery

and the short gastric arteries for the arterial supply of the stomach.

Reconstruction of the upper gastrointestinal anatomy after pancreatic head resection must enable drainage of bile and pancreatic juice as well as restoration of intestinal continuity. In patients without gastric bypass surgery, this is performed by either a pancreatico-jejunostomy or a pancreatico-gastrostomy, followed by a hepatico-jejunostomy and a gastro-jejunostomy (for Kausch-Whipple procedures) or a duodeno-jejunostomy in case of a pylorus-preserving resection.

In patients after gastric bypass surgery, several techniques for the pancreatobiliary reconstruction have been published [1, 2].

Here we report two cases with a pancreatico-gastrostomy to the stomach remnant and a hepatico-jejunostomy using the bilio-pancreatic limb, leaving the gastric bypass untouched.

Case Descriptions

Case One

61-year-old female, who underwent a Roux-y-bypass at the age of 48. At that time, her weight was 134kg (BMI 51.8kg/m²). The bilio-pancreatic limb of the gastric bypass was 70cm, the alimentary limb 140cm. The patient was regularly seen in the outpatient clinic. 13 years after gastric bypass surgery, she

weighs 91kg after having been down to 75kg until 2017. In 2021, painless jaundice leads to further radiologic investigations (abdominal ultrasound, CT and MRI). A 13x13mm mass in the head of the pancreas was found, highly suspicious for a pancreatic head cancer. No involvement of venous or arterial vessels were present. Due to the altered anatomy, an endosonography with fine needle aspiration was not pursued. The multidisciplinary tumour board recommends primary pancreatic head resection, which was done in a laparoscopic, pylorus-preserving technique including laparoscopic hepatico-jejunostomy. The small laparotomy for retrieving the resected pancreatic head and duodenum was also used for open pancreatico-gastrostomy and the duodeno-pars I-jejunostomy. The latter was done with the bilio-pancreatic limb, supramesocolic (Figure 1). The pathology report revealed a ductal adenocarcinoma of 1.9cm, stage pT1c pN2 (2/38) L1 V0 Pn1 R0 according to TNM classification of malignant tumours [3]. The postoperative course was uneventful and the patient was discharged home on postoperative day ten. Adjuvant chemotherapy was given.

Case Two

66-year-old female, who underwent a gastric banding in 2003 and a secondary Roux-Y- gastric bypass in 2011. Initially, the BMI was 48kg/m². The bilio-pancreatic limb of the bypass was 50cm, the alimentary limb 160cm. She was regularly seen in the outpatient clinic. In 2022, the BMI was 35kg/m². The general practitioner remarked an elevated serum lipase and an exocrine pancreatic insufficiency. Upper abdomen MRI showed a mixed type IPMN in the head of the pancreas with a main duct dilatation of 8mm in the head and 5mm in the tail of the pancreas. The patient was consented to both a pancreatic head resection and a total pancreatectomy. Intraoperative frozen section at the level of pancreatic transection 2cm left to the superior mesenteric-portal venous axis shows no signs of IPMN in the main pancreatic duct. Therefore, a pylorus-preserving pancreatic head resection is performed. Again, the pancreas was anastomosed to the stomach. The hepatico-jejunostomy and the duodeno-pars-I-jejunostomy were done using the bilio-pancreatic limb (Figure 1). The pathology report revealed a ductal adenocarcinoma of 3mm within a 3.5cm mixed type IPMN, intestinal type, stage pT1a pN0 (0/12) L0 V0 Pn0 R0 according to TNM classification [3].

Fig. 1

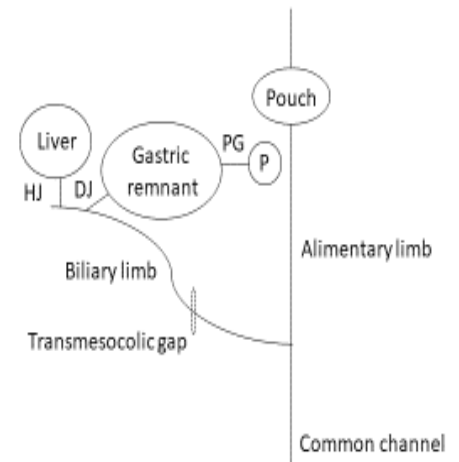


Figure 1: P: Pancreas; PG: Pancreatico-gastrostomy; DJ: Duodeno-pars I-jejunostomy; HJ: Hepatico-jejunostomy

The postoperative course was uneventful and she was discharged home on postoperative day eleven. Adjuvant chemotherapy was given, and further surveillance of the pancreatic remnant was planned.

Discussion

Due to the frequent performance of gastric bypass surgery, an increasing proportion of our patients requiring pancreatic head resection will be seen with an altered intestinal anatomy.

The technique described above is only possible, if the bilio-pancreatic limb of the gastric bypass measures at least 50cm, leaving 40 to 45cm for the hepatico-jejunostomy. However, this is usually ensured with a standard gastric bypass, since the bilio-pancreatic limb always measures about 50cm or more, regardless of the type of gastric bypass [4]. Mobilisation at the Treitz ligament and transection just at the duodeno-jejunal transition allows preservation of a sufficiently long biliary limb.

Pancreatico-gastrostomy is an established alternative technique to pancreatico-jejunostomy [5]. We use this technique primarily in patients with a soft pancreas and a narrow main pancreatic duct. Outcome analysis of pancreatic anastomoses during pancreaticoduodenectomy from two national audits showed pancreatico-gastrostomy to be associated with a higher rate of bleeding complications [6]. In order to prevent these complications we meticulously oversew bleeding points on the pancreatic cut face with non-absorbable sutures. In addition, all patients with a pancreatico-gastrostomy receive therapeutic proton pump inhibitors (e.g. 2x40mg pantoprazole/daily) for two weeks. Hence, using the stomach remnant for pancreatic anastomosis patients after gastric bypass surgery is a valid option despite the published data from Germany and the Netherlands [6].

As in many fields of gastrointestinal surgery, early oral feeding is the preferred feeding strategy also after pancreaticoduodenectomy [7]. Leaving the gastric bypass untouched further supports and facilitates this strategy.

The pancreatic head resection after Roux-Y-gastric bypass study group analysed 96 patients with such a situation. Twenty different reconstructions were reported. None appeared to confer specific benefits [2].

The technique described in this article was not among these 20 technical reconstructive options. Our technique does limit both resection and anastomoses to what is done in a pancreatic head resection. There is no need to resect the gastric remnant, nor does an anastomosis of the gastric bypass need to be redone, limiting the surgical trauma to its minimum.

Conclusion

Performing a pancreatico-gastrostomy in patients with a Roux-Y gastric bypass is a valid option for reconstruction after pancreatic head resection, especially if the biliary limb is sufficiently long to be used for the hepatico-jejunostomy.

References

1. Swain JM, Adams RB, Farnell MB, Que FG, Sarr MG (2010) Gastric and pancreaticoduodenal resection for malignant lesions after previous gastric bypass--diagnosis and methods of reconstruction. *Surg Obes Relat Dis.* 6: 670-675.
2. Trudeau MT, Maggino L, Ecker BL, Vollmer CM (2020) Pancreatic Head Resection Following Roux-en-Y Gastric Bypass: Operative Considerations and Outcomes. *J Gastrointest Surg.* 24: 76-87.
3. Brierley JD, Gospodarowicz MK, Wittekind C (2017) TNM classification of malignant tumours, 8th edition: John Wiley & sons.
4. O'Brien PE, Hindle A, Brennan L, Skinner S, Burton P, et al. (2019) Long-Term Outcomes After Bariatric Surgery: a Systematic Review and Meta-analysis of Weight Loss at 10 or More Years for All Bariatric Procedures and a Single-Centre Review of 20-Year Outcomes After Adjustable Gastric Banding. *Obes Surg.* 29: 3-14.
5. Figueras J, Sabater L, Planellas P, Muñoz-Forner E, Lopez-Ben S, et al. (2013) Randomized clinical trial of pancreaticogastrostomy versus pancreaticojejunostomy on the rate and severity of pancreatic fistula after pancreaticoduodenectomy. *Br J Surg.* 100: 1597-1605.
6. Petrova E, Suurmeijer JA, Mackay TM, Bolm L, Lapshyn H, et al. (2021) Outcome of pancreatic anastomoses during pancreaticoduodenectomy in two national audits. *Surgery.* 170: 1799-1806.
7. Gerritsen A, Besselink MG, Gouma DJ, E Steenhagen, Rinkes IHMB, et al. (2013) Systematic review of five feeding routes after pancreaticoduodenectomy. *Br J Surg* 2013; 100: 589-598.