

# Intestinal infection with *Echinococcus multilocularis* in a dog

Emily J. Jenkins, PhD, DVM<sup>1\*</sup>; Temitope U. Kolapo, PhD, DVM<sup>1</sup>; Maria P. Jarque, MSc, DVM<sup>1</sup>; Cecilia Ruschkowski, DVM<sup>2</sup>; Caroline Frey, DVM, DEVPC<sup>3</sup>

<sup>1</sup>Department of Veterinary Microbiology, Western College of Veterinary Medicine, University of Saskatchewan, Saskatoon, SK, Canada

<sup>2</sup>Oyen Veterinary Services, Oyen, AB, Canada

<sup>3</sup>Institute of Parasitology, University of Bern, Bern, Switzerland

\*Corresponding author: Dr. Jenkins (Emily.jenkins@usask.ca)

Received February 17, 2023

Accepted April 18, 2023

doi.org/10.2460/javma.23.02.0099

## OBJECTIVE

To raise veterinary awareness of a newly recognized parasitic threat to canine and human health, highlight the increasing availability of molecular parasitological diagnostics and the need to implement best practices of cestocidal use in high-risk dogs.

## ANIMAL

A young Boxer dog with vomiting and bloody diarrhea, suspected diagnosis of inflammatory bowel disease.

## CLINICAL PRESENTATION, PROGRESSION, AND PROCEDURES

Bloodwork revealed inflammation, dehydration, and protein loss, addressed with supportive therapy. Fecal culture revealed only *Escherichia coli*. On centrifugal flotation, tapeworm eggs (which could be *Taenia* or *Echinococcus* spp) and, unusually, adult cestodes of *Echinococcus* were observed. The referring veterinarian was contacted to initiate immediate treatment with a cestocide due to zoonotic potential. Diagnosis was confirmed with a coproPCR which has higher sensitivity for *Echinococcus* spp than fecal flotation alone. DNA was identical to an introduced European strain of *E multilocularis* currently emerging in dogs, people, and wildlife. Since dogs can also self-infect and develop hepatic alveolar echinococcosis (severe and often fatal), this was ruled out using serology and abdominal ultrasound.

## TREATMENT AND OUTCOME

Following cestocidal treatment, fecal flotation and coproPCR were negative for eggs and DNA of *E multilocularis*; however, coccidia were detected and diarrhea resolved following treatment with sulfa-based antibiotics.

## CLINICAL RELEVANCE

This dog was serendipitously diagnosed with *E multilocularis*, acquired through ingestion of a rodent intermediate host likely infected from foxes and coyotes. Therefore, as a dog at high risk of reexposure from eating rodents, regular (ideally monthly) treatment with a labeled cestocide is indicated going forward.

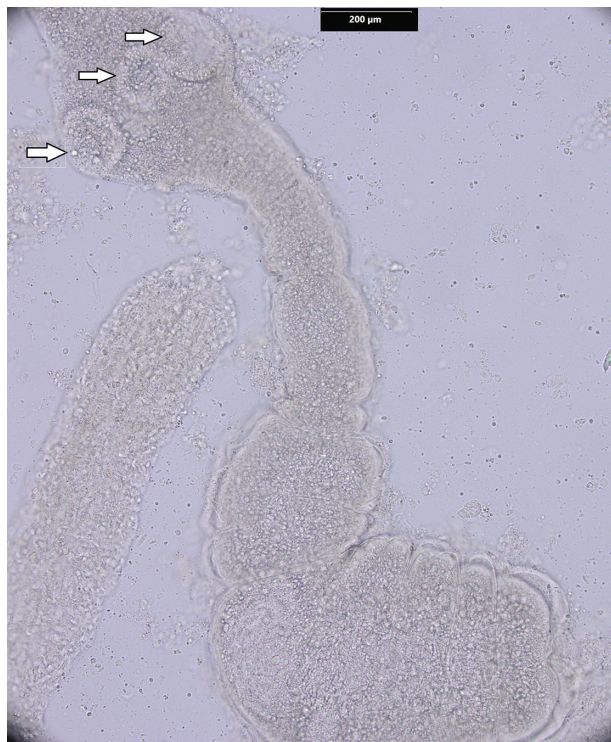
On October 4, 2022, a 10-month-old spayed female Boxer (approximately 15 kg) was admitted to a veterinary clinic in southern Alberta near the Saskatchewan border with depression, a painful abdomen, and bloody diarrhea. The dog had been experiencing episodic vomiting, diarrhea, and anorexia starting 1 week after boarding at a kennel at the end of August. There was no history of foreign body ingestion, and differential diagnoses included inflammatory bowel disease (IBD), gastroenteritis, and giardiasis. The dog had no history of travel out of province or country and had free ranging access to a rural property shared with livestock, wild cervids, foxes, coyotes, and rodents (mice and gophers).

## Diagnostic Findings and Interpretation

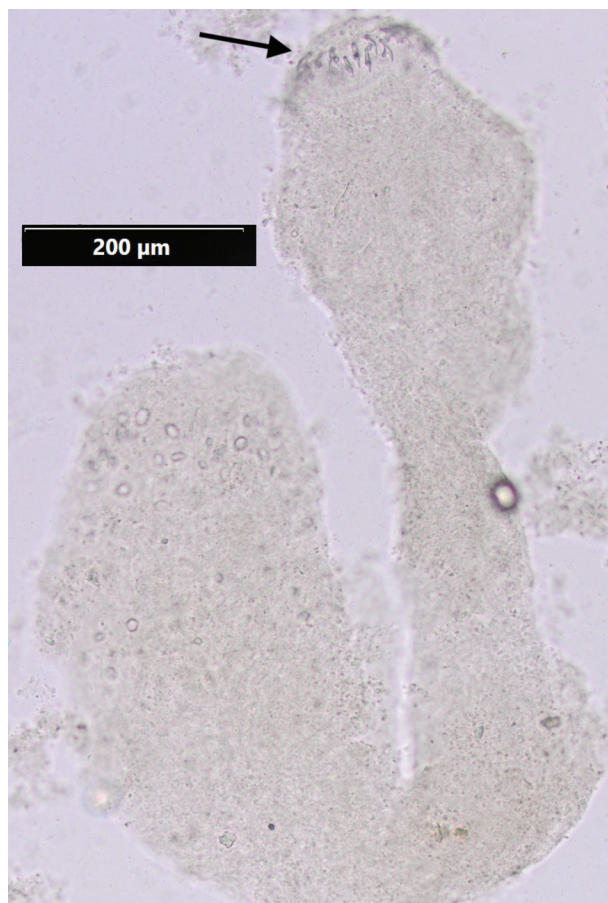
Blood samples were submitted to Prairie Diagnostic Services (PDS), Saskatoon, SK on day 3 after presentation. Bands (1%) and basophils (1%) were marginally

elevated, hematocrit was high (0.612), and serum total protein was low (54 g/L). Urine was concentrated (1.049 specific gravity) and there was mild proteinuria (1+). The dog responded to supportive treatment, including SC fluids (lactated Ringer solution, 600 mL) and maropitant citrate (Cerenia [15 mg], 10 mg/mL) administered SC twice, 4 days apart. Feces were collected on day 4 after presentation and the dog was prescribed metronidazole (250 mg, PO, twice daily for 10 days). Fecal samples were received at PDS 5 days after collection and culture revealed 4+ *Escherichia coli*. A commercial fluorescent antibody test for *Giardia* cysts and *Cryptosporidium* oocysts was negative. Centrifugal fecal flotation with Sheather's sucrose solution (1.27 specific gravity) revealed eggs 30–35 µm in diameter with thick, radially striated shells and visible hooks of hexacanth larvae. These taeniid cestode eggs could be *Taenia* spp, *E canadensis* (cervid strains of *E granulosus* species complex), or *E multilocularis*, all of which are endemic in dogs and wildlife in Canada.

On review of the flotation slide, a parasitology specialist observed whole adult *Echinococcus* spp cestodes (**Figures 1 and 2**), in addition to free eggs and gravid segments (**Figure 3**). The position of the



**Figure 1**—Whole adult *Echinococcus multilocularis* cestode recovered on canine fecal flotation, with suckers visible on the scolex (arrows).

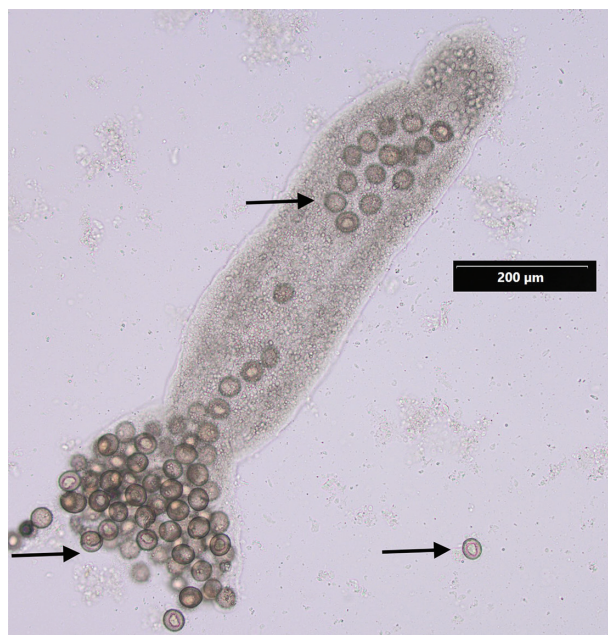


**Figure 2**—Immature adult *Echinococcus multilocularis* tapeworm present on canine fecal flotation, with hooks of the rostellum visible on the scolex (arrow).

lateral genital pore in the mature and gravid segments (which can distinguish *E. multilocularis* from *E. canadensis*/*E. granulosus*) could not be determined due to suboptimal preservation of adult cestodes in Sheather's solution. Therefore, we conducted a real time coproPCR (now commercially available through PDS) that can distinguish *E. canadensis* from *E. multilocularis*, and confirmed the identification on a second, haplotyping PCR using primers for the NAD2 region of mitochondrial DNA.<sup>1</sup> Sequence from the latter was 100% identical over 846 bp for the E3/E4 European haplotype of *E. multilocularis*, the same as isolates from dogs and people with alveolar echinococcosis (AE) and from coyotes with adult cestode infections in western Canada.<sup>2</sup>

## Treatment and Outcome

Because both species of *Echinococcus* are zoonotic, on finding adult cestodes on flotation, the referring veterinarian was immediately notified, and the dog was given 1.5 tablets of Dolpac 10 (praziquantel [50 mg], pyrantel pamoate [144 mg], and oxantel pamoate [559 mg]; Vetoquinol), PO, once daily for 2 days sequentially to kill the adult cestodes, as well as Cerenia (16 mg), PO, once daily for 4 days and teva sucralfate (1 g), once daily for 7 days to manage symptoms. It was also recommended that the owner observe strict hygiene protocols immediately



**Figure 3**—Gravid proglottid of *Echinococcus multilocularis* observed on fecal flotation releasing thick walled, radially striated eggs (arrows) each containing a hexacanth larva infective for intermediate hosts: rodents, dogs, and people.



following treatment, especially as the dog was diarrheic following deworming, and to consult their healthcare provider regarding the risk of zoonotic transmission. At time of writing, the owner had contacted an infectious disease physician to pursue serology at the National Reference Centre for Parasitology in Montreal, Canada.

To ensure that cestocidal treatment was effective, we examined fecal samples from this dog as well as 2 cats and another dog living in the household 6 weeks after treatment; all samples were negative for taeniid eggs on flotation and on coproPCR for *Echinococcus* spp. At this time, the fecal sample from the presenting case had a low intensity of oocysts of *Cystoisospora*, and the dog was treated with apo-sulfatrim (sulfamethoxazole [800 mg] and trimethoprim [160 mg]) at a dose of 0.5 tablet, PO, twice daily for 6 days, which resolved the bloody diarrhea. Despite lack of detection of coccidian oocysts in the initial fecal examination, these parasites can cause bloody diarrhea in the prepatent period, before oocysts are detected in feces.

Confirmation of adult cestodes as European strains of *E. multilocularis* raised the possibility that this dog could self-infect, either through consuming eggs passed in its own feces, or possibly internally through reflux of eggs from the intestine into the stomach.<sup>3</sup> Boxers appear to be particularly susceptible to development of canine AE.<sup>2</sup> Therefore, roughly 4 months after presentation, Zoonotic Parasite Research Unit (ZPRU) conducted serology for the Em95 antigen of the metacestode of *E. multilocularis*, the cause of AE.<sup>3</sup> It was negative, as was abdominal ultrasound for cysts in the liver conducted at the Western College of Veterinary Medicine, although this did reveal mild lymphadenopathy secondary to antigenic stimulation. While these findings were reassuring for canine health, we recommended that the dog be monitored for at least the next year, and that any sign of liver disease should be followed up with ultrasound and/or serology (at moment, only available for research purposes). As per the Canadian Parasitology Expert Panel guidelines (<https://research-groups.usask.ca/cpep/index.php#Protocol>), this dog is considered at high risk for exposure to intestinal parasites as it roams freely on a rural property, has access to wildlife such as rodents, rabbits, birds, or carcasses of livestock or wild cervids, and has an established history of hunting and consuming rodents, and therefore we recommended monthly deworming with praziquantel at 5 mg/kg to kill adult cestodes of *E. multilocularis* before they can shed eggs (about 30 days).

## Comments

This is the first record of intestinal infection with adult cestodes of *Echinococcus multilocularis* in a dog in Canada, although 1 case has been reported in the United States.<sup>4</sup> Unusually, adult cestodes were recovered on fecal flotation, and infection was associated with diarrhea; intestinal infection with *E. multilocularis* is usually thought to be asymptomatic. It is possible that the diarrhea in this case had another cause (coccidiosis or inflammatory bowel disease), which fortuitously caused the adult cestodes to be “washed out” in feces. It is an important reminder to train technicians to recognize tapeworm segments and scolices in fecal flotations (Figures 1 through 3), which may be more frequently shed than eggs for many cestodes. Segments of *Echinococcus* are very small (a few mm long) and rarely detected grossly.

In this case report, detection of adult *Echinococcus* cestodes in feces, followed by application of state-of-the-art molecular and serologic diagnostic assays, led to detection and mitigation of *E. multilocularis* in a dog and follow up testing for other pets and people in the household. This tapeworm poses a threat to both human and canine health, highlighting the need for enhanced awareness and diagnostic capacity for *E. multilocularis* in North America. This tapeworm causes AE, a serious, even fatal zoonosis emerging in dogs and people in Canada<sup>2</sup> and the United States.<sup>5</sup>

Therefore, it is important to distinguish species of taeniid tapeworm eggs shed in dog feces using increasingly available coproPCR methods, as *Echinococcus* and *Taenia* spp produce identical eggs, but pose very different risks to human and canine health. *Echinococcus granulosus*/*E. canadensis* are zoonotic but pose no risk to canine health (dogs do not develop cystic echinococcosis). Adult *Taenia* spp in dogs and cats in North America are common in pets who eat wildlife (deer, rodents, rabbits, etc), cause no clinical signs in dogs and cats, and are not zoonotic. CoproPCR is much more sensitive for *Echinococcus* and *Taenia* spp than fecal flotation, as many pets can be infected with adult tapeworms without detectable eggs on fecal flotation. If a dog is shedding taeniid eggs or known to be infected with *Echinococcus*, fecal samples should be handled carefully and hand washing hygiene should be strictly observed. Eggs are immediately infective and highly resistant to chemicals and standard freezing; eggs can only be inactivated through high heat (greater than 60 °C), ultralow temperatures (-115.6 °C), or strong, fresh bleach solutions. Dogs and people, and to a lesser degree, pigs and horses, can be infected with *E. multilocularis* in the liver. When there are suggestive lesions on medical imaging or microscopic indications of this parasite from biopsy material, PCR can offer definitive diagnosis of AE based on fresh or frozen tissues, fluid aspirated from cysts, or in advanced canine AE cases, fluid aspirated from the abdomen.

## Acknowledgments

The authors have nothing to declare.

Many thanks to Prairie Diagnostic Services technicians and Western College of Veterinary Medicine Veterinary Medical Clinic for medical imaging.

## References

1. Nakao M, Xiao N, Okamoto M, Yanagida T, Sako Y, Ito A. Geographic pattern of genetic variation in the fox tapeworm *Echinococcus multilocularis*. *Parasitol Int*. 2009;58(4):384–389. doi:10.1016/j.parint.2009.07.010
2. Kolapo T, Hay A, Gesy K, et al. Canine alveolar echinococcosis: an emerging and costly introduced problem in North America. *Transbound Emerg Dis*. 2023;2023:1–10. doi:10.1155/2023/5224160
3. Frey CF, Marreros N, Renneker S, et al. Dogs as victims of their own worms: serodiagnosis of canine alveolar echinococcosis. *Parasit Vectors*. 2017;10(1):422 doi:10.1186/s13071-017-2369-0
4. Kuroki K, Morishima Y, Neil J, Beerntsen BT, Matsumoto J, Stich RW. Intestinal echinococcosis in a dog from Missouri. *J Am Vet Med Assoc*. 2020;256(9):1041–1046. doi:10.2460/javma.256.9.1041
5. Zajac A, Fairman D, McGee E, et al. Alveolar echinococcosis in a dog in the eastern United States. *J Vet Diagn Invest*. 2020;32(5):742–746. doi:10.1177/1040638720943842