



Biomechanical Comparison of Double 2.3-mm Headless Cannulated Self-Compression Screws and Single 3.5-mm Cortical Screw in Lag Fashion in a Canine Sacroiliac Luxation Model: A Small Dog Cadaveric Study

AhRan Kang^{1,*} Haebeom Lee^{1,*} Arim Lee¹ Yoonho Roh² Bokyun Sim³ Jaemin Jeong¹

¹ College of Veterinary Medicine, Chungnam National University, Yuseong-gu, Daejeon, Republic of Korea

² Division of Animal Surgery, Department of Clinical Veterinary Medicine, Vetsuisse Faculty, University of Bern, Bern, Switzerland

³ Graduate Program of Biomedical Engineering, Yonsei University, Seoul, Republic of Korea

Address for correspondence Bokyun Sim, MS, Graduate Program of Biomedical Engineering, Yonsei University, Seoul 03722, Republic of Korea (e-mail: bklin83@gmail.com).

Jaemin Jeong, DVM, PhD, College of Veterinary Medicine, Chungnam National University, 99 Daehak-ro, Yuseong-gu, Daejeon, 34134, Republic of Korea (e-mail: klmie800@cnu.ac.kr).

Vet Comp Orthop Traumatol

Abstract

Objective The aim of this study was to evaluate the feasibility of safe positioning of double 2.3-mm headless cannulated self-compression screws (HCS) in a small dog cadaveric sacroiliac luxation model and to compare the static rotational biomechanical properties of fixation repaired using two different screw systems with a minimally invasive osteosynthesis technique: double 2.3-mm HCS and a single 3.5-mm standard cortical screw placed in a lag fashion.

Study Design A unilateral small dog sacroiliac luxation model was stabilized using double 2.3-mm HCS ($n = 11$) or a single 3.5-mm cortical screw ($n = 11$). Radiographic and computed tomography (CT) imaging analyses and biomechanical testing of rotational force on the sacroiliac joint of both fixations were performed. The maximum load at failure and failure modes of each fixation were recorded and compared.

Results Fluoroscopically guided percutaneous application of double HCS was safe in a unilateral sacroiliac luxation model in small dogs without violation of the vertebral and ventral sacral foramen. Furthermore, resistance to rotational force applied on fixation of the sacroiliac joint repaired with double 2.3-mm HCS estimated by maximum failure load was significantly higher than that of a single 3.5-mm cortical screw ($p < 0.001$).

Conclusion Although this was an experimental cadaveric study, based on our results, the use of smaller double HCS may be beneficial as an alternative to the conventional single lag screw for stabilization of sacroiliac luxation in small dogs.

Keywords

- ▶ sacroiliac luxation
- ▶ headless cannulated self-compression screw
- ▶ lag screw
- ▶ biomechanical study
- ▶ dog

* These authors contributed equally to this work.

received
September 15, 2022
accepted after revision
June 27, 2023

DOI <https://doi.org/10.1055/s-0043-1771508>.
ISSN 0932-0814.

© 2023. The Author(s).

This is an open access article published by Thieme under the terms of the Creative Commons Attribution-NonDerivative-NonCommercial-License, permitting copying and reproduction so long as the original work is given appropriate credit. Contents may not be used for commercial purposes, or adapted, remixed, transformed or built upon. (<https://creativecommons.org/licenses/by-nc-nd/4.0/>)
Georg Thieme Verlag KG, Rüdigerstraße 14, 70469 Stuttgart, Germany

Introduction

Sacroiliac luxation is the traumatic dislocation of the iliac wing from the sacrum that commonly occurs with other orthopaedic injuries in small animals. In a retrospective study, of dogs with sacroiliac luxation, 77% had unilateral sacroiliac injury and 85% had concurrent orthopaedic injuries.¹ Conservative management is acceptable for minimally displaced sacroiliac luxation; however, surgical stabilization is indicated in cases of narrowed pelvic canal, displacement that causes signs of pain and nonambulatory state, or neurologic deficits.^{2,3}

Placement of a single cortical or cancellous screw of the largest diameter in lag fashion is the most common surgical treatment for sacroiliac luxation.^{1,4} Although postoperative loosening rate of lag screw fixation for canine sacroiliac luxation has been reported to be as high as 38%, favorable outcomes can be obtained when the screw engages at least 60% of the sacral width.^{1,2,4} Pullout force and resistance to shear and bending forces increase as the screw diameter increases; however, a single larger screw cannot effectively increase the relative resistance to rotation forces compared with double smaller screws.^{5,6} Nonetheless, placement of double screws in a sacral body is challenging and requires a high degree of precision because of the narrow anatomical safe corridor in the canine sacrum.^{2,4,7-9}

Alternatively, a headless cannulated self-compression screw (HCS) has an advantage in precision because the screw can be placed over a positional guidewire under fluoroscopic guidance.¹⁰ Currently, the cannulated screw system is used as a surgical treatment option for internal fixation in human pelvic, articular, or periarticular small bone and joint surgery.¹¹⁻¹³ In veterinary medicine, constructs repaired with 3.0-mm HCS in the canine humeral condylar fracture model showed no difference in the quality of anatomical reduction or yield loads compared with constructs with 3.5-mm cortical lag screw fixation.¹⁴ However, despite the advantages of HCS and mechanical properties of double screw placement, there is a lack of clinical or biomechanical studies on HCS placement for sacroiliac luxation repair in veterinary medicine.

The primary objective of this study was to evaluate the feasibility of safe positioning of double 2.3-mm HCS in a small dog cadaveric sacroiliac luxation model. Our secondary aim was to compare the static rotational biomechanical properties of fixation repaired by two different screw systems with a minimally invasive fixation technique: double 2.3-mm HCS and single 3.5-mm cortical screw (CS) placed in lag fashion. Our first hypothesis was that safe positioning of double 2.3-mm HCS in the sacral body is possible under fluoroscopic guidance. Our second hypothesis was that double 2.3-mm HCS would show superior static mechanical properties to a single 3.5-mm cortical lag screw when standing ground reaction forces were applied.

Materials and Methods

Specimens and Preparation

Twenty-two canine cadavers weighing less than 10 kg from various breeds euthanatized for reasons unrelated to the study

were included in the *ex vivo* study after obtaining informed owner consent. Ethics approval for the cadaveric study protocol was not required by the Institutional Animal Care and Use Committee of Chungnam National University. All cadavers were stored at -20°C and thawed 24 hours before preparation of the luxation model and subsequent implantation at room temperature. To induce the simulated sacroiliac luxation model as described previously,¹⁵ hemipelvic sides were randomly selected and the ipsilateral pubis and ischium were transected using an oscillating saw. Through a ventral approach to the pelvis, the ilium was separated from the sacrum using a no. 11 blade and an osteotome.

Preimplantation Radiographic and Computed Tomography Evaluation

Radiographic and computed tomography (CT) measurements were performed by a single radiologist (AL). Preimplantation radiographs were obtained to confirm the induction of luxation and to estimate the preimplantation pelvic canal diameter ratio (PCDR) and hemipelvic canal width ratio (HCWR).^{16,17} Preimplantation CT (Alexion, Toshiba Medical System, Japan) was performed to estimate the sacral diameter and adequate screw length. The sacral diameter was estimated by a best-fit circle on the sacral sagittal plane, and the percentage of screw size to the sacral diameter was calculated.¹⁸ The length of the implants was chosen to penetrate approximately 70% of the sacral width in the 3.5-mm CS group and 70% for the first and 40% for the second screws in the 2.3-mm HCS group.

Implantation Technique

One surgeon (JJ) performed all implantation procedures. Pelvic positioning and reduction of the sacroiliac joint were evaluated under fluoroscopic guidance (Philips Healthcare, Best, The Netherlands).¹⁸ Total implantation time was recorded from confirmation of reduction to completion of screw placement for each cadaver. Double 2.3-mm HCS fixation (**Fig. 1**) was performed by modifying a reported surgical technique.¹⁵ An 18-gauge needle was inserted percutaneously as an aiming device for guidewire placement at the center of the sacral body for primary screw placement based on visual assessment using fluoroscopic guidance. A 0.8-mm Kirschner wire was inserted into both the ilium and the sacrum through the needle. The insertion of the Kirschner wire was stopped before resistance from the far cortex of the sacrum was felt, and the position of the wire was assessed using fluoroscopy. A second guidewire was inserted in the same fashion through the percutaneous 18-gauge needle parallel to the first guidewire at the desired location for the second screw placement, approximately 4 mm dorso-caudal to the first Kirschner wire (**Fig. 1A**), and needles were removed. Stab incisions were made along the belly of the gluteal muscle adjacent to the wires, and a drill guide was positioned over the preplaced Kirschner wire. Afterward, a cannulated drill bit was driven over the preplaced Kirschner wire through the iliac wing into the sacral body. If the Kirschner wire was jammed and it pulled out during the drill bit removal process due to bone debris, a new Kirschner wire of the same length was manually inserted into the

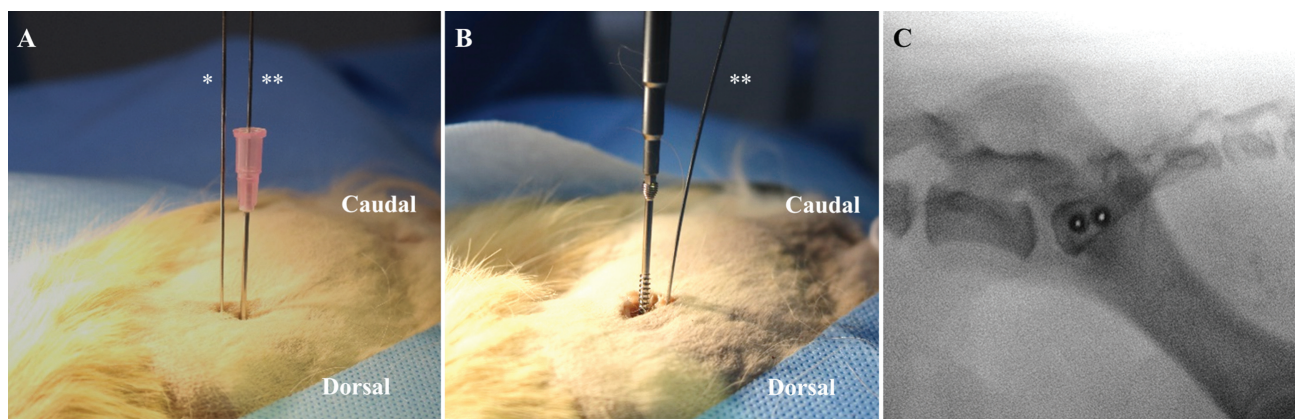


Fig. 1 Implantation procedures of 2.3-mm HCS placement under fluoroscopy guidance. (A) Two guidewires are inserted parallelly through the percutaneous needle. The second guidewire (**) is placed dorsocaudally to the first wire (*). A stab incision was made along the belly of the gluteal muscle adjacent to the wires, and a drill guide was positioned over the preplaced Kirschner wire. Afterward, a cannulated drill bit was driven over the preplaced Kirschner wire through the iliac wing into the sacral body. (B) Insertion of the first 2.3-mm HCS over the guidewire. The second wire (**) is slightly tilted to facilitate screw insertion. (C) Placement of double 2.3-mm HCS is assessed using fluoroscopy. HCS, headless cannulated self-compression screw.

corresponding position. The drilled depth was measured using a cannulated depth gauge over the Kirschner wire. A 2.3-mm titanium HCS (thread diameter (\varnothing) 2.3 mm, core \varnothing 1.8 mm, and head \varnothing 3.1 mm; Jeil Medical, Republic of Korea) was placed over the first guidewire (**Fig. 1B**) until compression was achieved. Subsequently, the second screw insertion was performed in the same manner. Fixation of sacroiliac luxation using 3.5-mm 316L stainless steel CS (thread \varnothing 3.5 mm, core \varnothing 2.4 mm, and head \varnothing 6 mm; Synthes, Switzerland) in lag fashion was performed routinely with the minimally invasive fixation technique.^{16,19}

Postimplantation Radiographic and Computed Tomography Evaluation

All medical images were reviewed using an image software (Zetta PACS, TaeYoung Soft, Republic of Korea). Postimplantation PCDR and HCWR were also assessed. Screw length within the sacral body was estimated as a percentage of the screw length in the sacral width on ventrodorsal radiographs.¹ Postimplantation CT was performed to estimate the percentage of craniocaudal reduction (CCR) and dorsoventral reduction (DVR) of the sacroiliac joint, craniocaudal angle (CCA) and dorsoventral angle (DVA) of each screw (**Fig. 2**), mean entry points of the screws, and cranial margin of the first ventral sacral foramen.^{18,20} Positive CCA or DVA value was defined as the angle of deviation cranially or dorsally from the transverse plane or dorsal plane, respectively. Negative values indicated caudally or ventrally directed angles. Mean entry points of the screws were evaluated on the lateral surface of the sacral body in the transverse and dorsal planes on CT multiplanar reconstruction images.²⁰ Distances of the center of the screw from the cranial end plate of the sacral body in the dorsal plane and from the ventral limit of the spinal canal in the transverse plane were estimated (**Fig. 2C, F**) and transferred to a two-dimensional plane with conversion to ratios to the sacral diameter of each dog (**Fig. 3**). Furthermore, distance of the cranial margin of the first ventral sacral foramen was esti-

mated at the dorsal and ventral points in the dorsal and transverse planes, and the measurements were transferred to a two-dimensional plane in the same manner. Y-values of the dorsal points were assumed to be 0. Lines connecting the mean values of the dorsal and ventral points are presented as a schematic diagram (**Fig. 3**).

Mechanical Test

To conduct mechanical tests, pelvises of 22 cadavers were harvested after fixation. Pelvic limbs and vertebral spines were disarticulated at the coxofemoral joint and level of the lumbosacral and sacrocaudal junctions, respectively. Remaining soft tissues on the pelvis were dissected. The distance between the nearest edge of the two inserted screw heads was measured using a digital caliper in the HCS group. Specimens were then stored in sealed plastic bags at -20°C wrapped with saline-soaked cotton gauze and thawed for 12 hours before mechanical testing at room temperature. The contralateral intact ilium was luxated and discarded, and half of the sacrum was potted in a designed jig with methyl methacrylate resin (Trayplast, Vertex, the Netherlands). A test was designed to estimate the maximum rotational force at the sacroiliac joint before failure by simulating the ground reaction force on a hindlimb by modifying a previous method (**Fig. 4**).⁶ The implanted sacrum was mounted on top of the load cell of the testing machine (ElectroPuls E1000, Instron. Corp., United States). A metal bar simulating the femur was mounted and matched to the acetabulum to distribute the load. The angle between the shaft of the bar and iliac long axis was set at 108 degrees to simulate the standing position of a normal dog.⁶ The hemipelvis was slowly advanced downward, causing a rotational force to be delivered to the repaired construct, and the applied load was recorded. The testing machine provided a constant displacement of 0.099 cm/s. A load–displacement curve was plotted for each sample, and the maximum tolerated load of each fixation was obtained at the point of fixation failure. Load at failure was defined as the point at which the first sudden

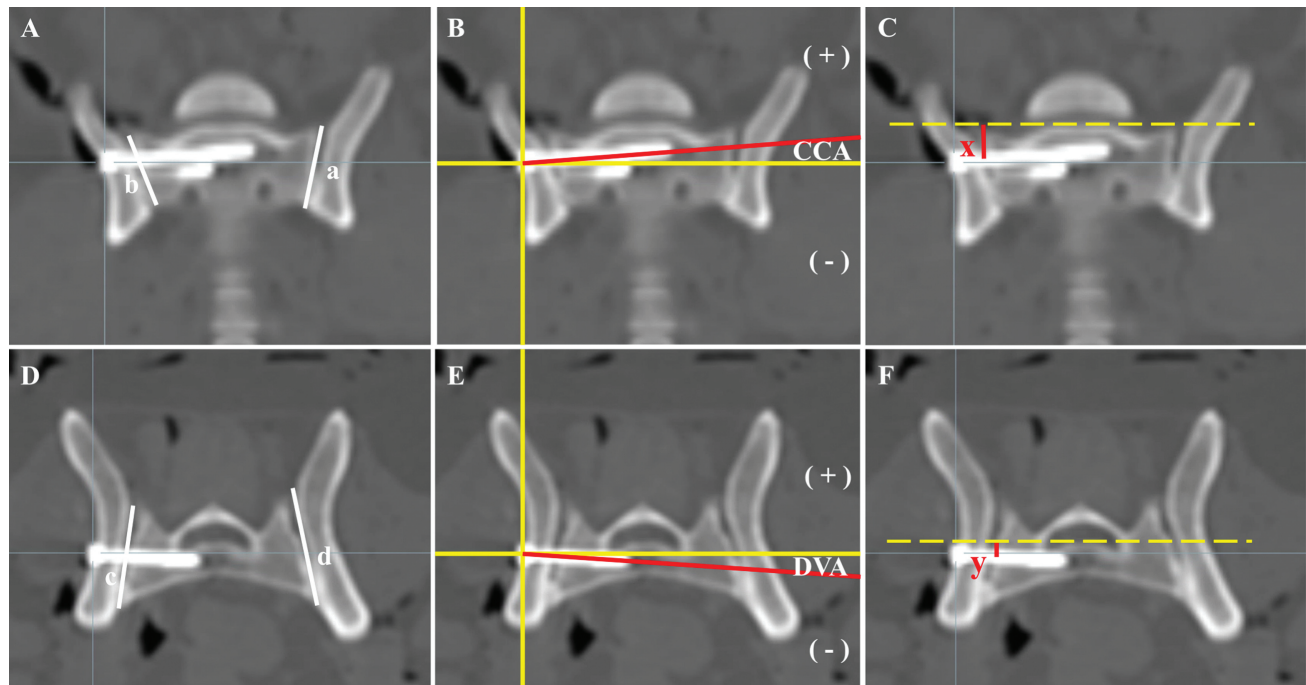


Fig. 2 Postimplantation computed tomography evaluation. (A,D) CCR and DVR are calculated as the length of the sacral wing in contact with the iliac joint surface divided by the total length of the sacral wing at the level of the screw (b/a and c/d , respectively). (B,E) CCA and DVA are measured on multiplanar reconstruction views and is defined as the angle between the axis of the screw and the transverse and dorsal plane, respectively, at the level of screw. Positive values of CCA or DVA are defined as the angle of deviation cranially or dorsally from the transverse plane or dorsal plane, respectively. Negative values indicate caudally or ventrally directed angle. (C) X-values of the distance of the center of the screw from the cranial margin of the sacral body in dorsal plane are evaluated. (F) Y-values of the distance of the center of the screw from the ventral border of the neural canal in the transverse plane are estimated. CCA, craniocaudal angle of screw; CCR, craniocaudal reduction of the sacroiliac joint; DVA, dorsoventral angles of screw; DVR, dorsoventral reduction of the sacroiliac joint.

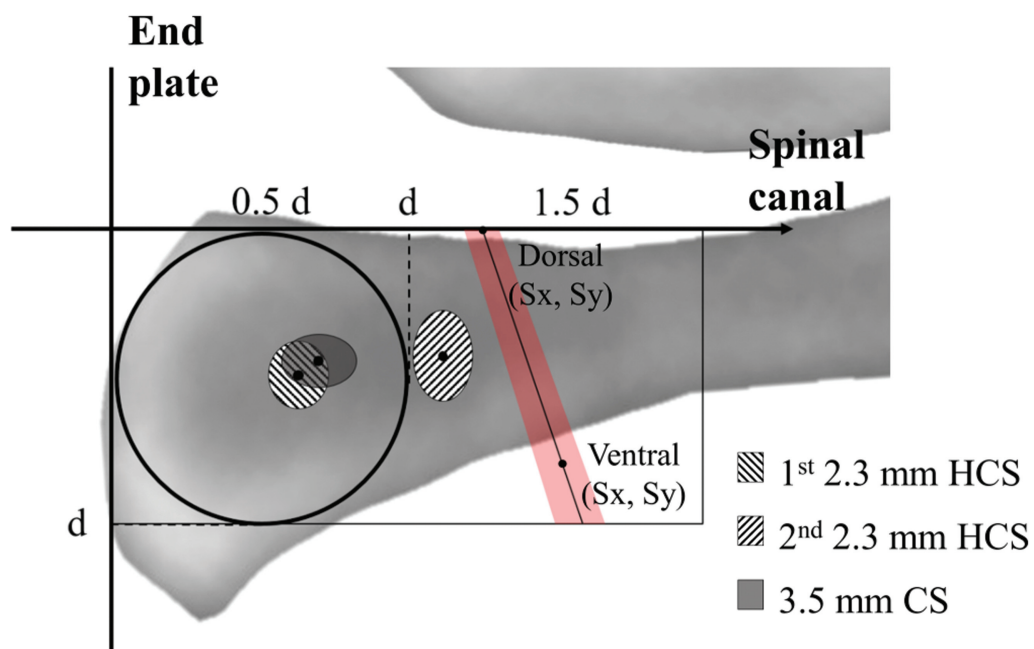


Fig. 3 Schematic diagram of the mean entry positions of the screws and mean points of the cranial edge of the first sacral ventral foramen converted to the sacral diameter ratio. The x-axis and y-axis correspond to the ventral aspect of the spinal canal and cranial end plate of the sacrum, respectively. The axes of the ellipse imply 95% confidence interval of the mean entry positions on the x-axis and y-axis. A line connecting the mean values of dorsal and ventral points of the cranial boundary of sacral ventral foramen is drawn. The minimum x-values of 95% confidence interval of the mean dorsal and ventral points are connected with an *oblique line* and maximum x-values of those points are connected in the same manner. The section is marked in *red*. d , sacral diameter, S_x , x-value of the mean cranial edge point of the first sacral ventral foramen, S_y , y-value of the mean cranial edge point of the first sacral ventral foramen.

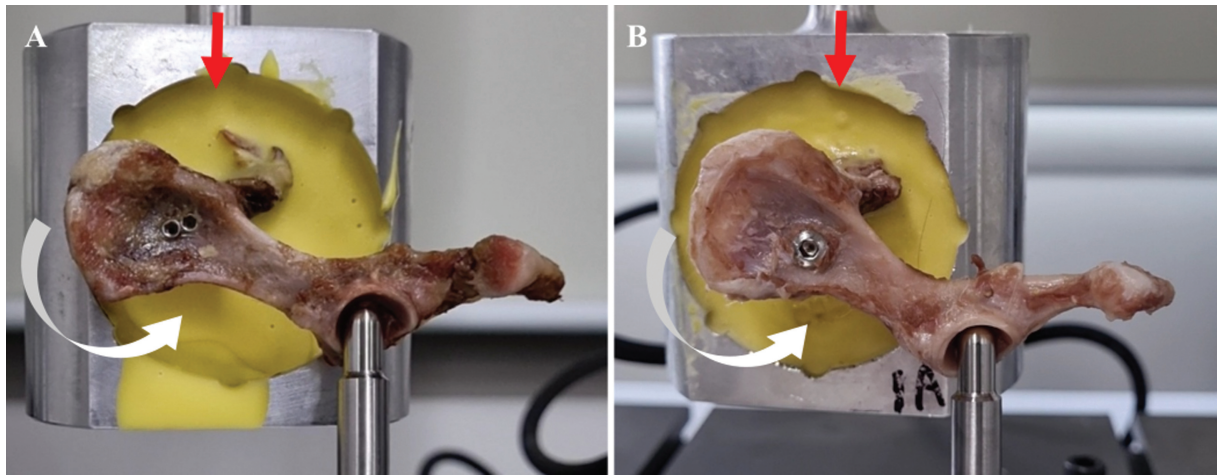


Fig. 4 Mechanical test of fixation to rotational force. Test setup of (A) double 2.3-mm HCS fixation and (B) single 3.5-mm CS fixation. The implanted sacrum was mounted on top of the load cell. The testing machine slowly applied a load (red arrow) to the sacrum, which induced a rotational force (white arrow) to be delivered to the repaired construct. CS, cortical screw; HCS, headless cannulated self-compression screw.

decrease in load occurred on the load–displacement curve. The moment arm estimated from the center of the acetabulum to the center of the fixation point was recorded to calculate the rotational force acting on sacroiliac fixation. Mean maximum rotational force tolerated by each fixation method at failure ($F\tau$) was calculated as follows⁶:

$$F\tau = F \times l$$

where F is the maximum load tolerated and l is the moment arm. The failure mode of each construct was also recorded.

Statistical Analysis

An *a priori* power analysis was performed using statistical software (G*Power V3.1.9.2x, Dusseldorf, Germany) to estimate the number of pelvises required for the study. A sample size of 11 pelvises for each group was estimated based on $\alpha=0.05$, power=0.9, and an estimated effect size (ES; $d=1.731918$) when using the mean and standard deviation (SD) torsional disruptive forces following double versus single screw configuration for repairing sacroiliac luxation model in a previous cadaveric study.⁶ The final sample size was 11 pelvises, with anticipation of 20% expected dropout. A *post hoc* power analysis was conducted on maximum failure load following each group to calculate ES ($d=1.5206358$) with a power of 0.91.

All non-power-related statistical analyses were performed using SPSS software version 26 (IBM Corp., Chicago, IL, United States). Assumption of normality of all continuous numerical data was assessed using the Shapiro–Wilk test. Student's *t*-test was used to analyze and compare the mean values (\pm SD) of body weight, implantation time, percentage of screws engaged in the sacrum, percentage of screw diameter per sacral diameter, CCR, DVR, and maximum failure load between the groups. Pre- and postimplantation values of mean \pm SD of PCDR and HCWR were also compared within each group using the Wilcoxon signed-rank test. The CCA, DVA, and mean entry

points of the screws of the 2.3-mm HCS group and 3.5-mm CS group were compared using one-way analysis of variance. Comparisons between the left and right maximum failure loads within each group were conducted using the Mann–Whitney *U* test. Fisher's exact test was used to determine the difference in failure modes between groups after the mechanical test. Statistical significance was set at $p \leq 0.05$.

Results

Descriptive Data

Data were collected from the pelvises of 22 canine cadavers of various breeds. The mean body weights of the cadavers (2.3-mm HCS: 6.21 ± 1.52 kg, 3.5 mm CS: 6.11 ± 2.13 kg) were not significantly different between the groups ($p=0.899$). The mean total time required for screw placement was 712 ± 138 seconds in the 2.3-mm HCS group and 379 ± 109 seconds in the 3.5-mm CS group ($p < 0.001$). The mean distance between the nearest edge of two 2.3-mm HCS heads was 0.99 ± 0.67 mm (range: 0.3–2.6 mm), and there was no impingement between the screw heads.

Imaging Evaluation

Objective measurements were estimated using the pre- and postimplantation imaging modalities (►Table 1). All screws were positioned in the sacral body without any violation of the spinal canal or first ventral sacral foramen in both groups. The mean percentages of screw length purchased within the sacrum reached the target value by more than 70 and 40% in the first and second screws in the 2.3-mm HCS group, respectively, and more than 70% in the 3.5-mm CS group.

PCDR and HCWR estimated between the preimplantation ($p=0.943$ and 0.491) and postimplantation ($p=0.876$ and 0.949) values were not significantly different between the groups. CCR ($p=0.245$) and DVR (0.703) of the sacroiliac joint on postimplantation CT were evaluated, and neither was significantly different between the groups.

Table 1 Objective measurements estimated on pre- and postimplantation imaging

	Double 2.3-mm HCS group		Single 3.5-mm CS group		p-value
Sacral diameter (mm)	6.15 ± 0.85		5.71 ± 0.56		0.169
Screw diameter/sacral diameter (%)	38.06 ± 5.37 ^a		61.79 ± 5.95 ^a		<0.001
Screw length within sacrum (%)	First	Second	71.91 ± 3.36		0.526 ^b
	73.18 ± 5.58	45.39 ± 3.82			
	Pre	Post	Pre	Post	
PCDR	1.31 ± 0.12	1.33 ± 0.11	1.31 ± 0.12	1.33 ± 0.10	0.859 ^c 0.422 ^d
HCWR	0.95 ± 0.12	0.89 ± 0.12	0.98 ± 0.04	0.89 ± 0.14	0.109 ^c 0.083 ^d
CCR (%)	91.04 ± 7.11		87.34 ± 7.41		0.245
DVR (%)	86.04 ± 9.34		84.36 ± 10.91		0.703
CCA (degrees)	First	Second	4.39 ± 4.34		0.195
	1.19 ± 3.68	1.73 ± 4.87			
DVA (degrees)	-1.82 ± 4.30	-2.02 ± 3.33	-0.70 ± 4.21	0.704	

Abbreviations: CCA, craniocaudal angle of screw; CCR, craniocaudal reduction of the sacroiliac joint; CS, cortical screw; DVA, dorsoventral angles of screw; DVR, dorsoventral reduction of the sacroiliac joint; HCS, headless cannulated self-compression screw; HCWR, hemipelvic canal width ratio; PCDR, preimplantation pelvic canal diameter ratio.

^aStatistically significant differences.

^bp-value between the first screw of the 2.3-mm HCS group and the 3.5-mm CS.

^cp-value in the 2.3-mm HCS.

^dp-value in the 3.5-mm CS group.

Mean CCA ($p = 0.954$) and DVA ($p = 0.992$) of the first and second 2.3-mm HCS were not significantly different between the screws. Neither of these angles was statistically different from the mean CCA ($p = 0.195$) and DVA ($p = 0.704$) of the 3.5-mm CS.

A schematic diagram (►Fig. 3 and ►Table 2) shows the mean entry positions of the screws, which were determined by using the centers of the screws, and the mean points of the cranial edge of the first sacral ventral foramen converted to the sacral diameter ratio. No significant differences in the position on the transverse ($p = 0.664$) and the dorsal planes ($p = 0.751$) of the first 2.3-mm HCS and 3.5-mm CS were observed. The center of the second 2.3-mm HCS was located at 3.93 ± 0.76 mm caudal compared with the center of the first screw, which was approximately 12% caudal to the best-fit circle of sacral diameter. Lines connecting the mean values of the dorsal and ventral points of the cranial boundary of the first sacral ventral foramen and the 95% confidence interval

of the x-values for each point were drawn obliquely. Two of 11 second 2.3-mm HCS were located within this interval; however, none violated the first sacral foramen.

Mechanical Test

Maximum load tolerated by each fixation was observed in all hemipelvises, and objective measurements were tabulated (►Table 3). Mean ± SD failure load ($p = 0.002$) and rotational force ($p = 0.002$) estimated at maximum failure were significantly higher for 2.3-mm HCS than for 3.5-mm CS. The mean failure load (kgf) was not significantly different between the left and right sides of the hemipelvis in either 2.3-mm HCS (left: 4.17 ± 2.67 ; right: 3.69 ± 2.11 ; $p = 0.792$) or 3.5-mm CS group (left: 0.73 ± 0.30 ; right: 1.48 ± 0.48 ; $p = 0.052$).

Loss of anatomical reduction of the sacroiliac joint was observed visually as rotational failure in all hemipelvises of both experimental groups (►Fig. 5A, B). Neither the 2.3-mm HCS nor the 3.5-mm CS head was pulled out of the ilium

Table 2 Mean entry positions of screws and mean points of cranial edge of the first sacral ventral foramen converted to the sacral diameter ratio

	X		Y	
	First	Second	First	Second
Double 2.3-mm HCS group ($n = 11$)	0.64 ± 0.15	1.12 ± 0.15 ^a	-0.50 ± 0.17	-0.43 ± 0.23
Single 3.5-mm CS group ($n = 11$)	0.70 ± 0.19		-0.44 ± 0.13	
Dorsal point of ventral sacral foramen ($n = 22$)	1.25 ± 0.13		0	
Ventral point of ventral sacral foramen ($n = 22$)	1.52 ± 0.15		-0.80 ± 0.10	

Abbreviations: CS, cortical screw; HCS, headless cannulated self-compression screw.

^aStatistically significant among the x-values of the first and second 2.3-mm HCS, and 3.5-mm CS.

Table 3 Objective measurements of mechanical test to rotational force on each fixation

	Double 2.3-mm HCS group	Single 3.5-mm CS group	p-value
Maximum failure load (kgf)	3.91 ± 2.51 ^a	1.14 ± 0.58 ^a	0.002
Moment arm (cm)	3.62 ± 0.36	3.70 ± 0.41	0.631
Maximum rotational force at failure (kgf-cm)	14.30 ± 9.50 ^a	4.16 ± 1.96 ^a	0.002

Abbreviations: CS, cortical screw; HCS, headless cannulated self-compression screw.

^aStatistically significant differences.

surface after the test. The mode of failure was remarkably different between the groups (► **Table 4**). In the HCS group, loss of stability occurred mainly at the sacrum while the trailing thread engaged in the ilium, and cortical bone fracture and breakage of three screw heads (two first screws and one second screw) were observed (► **Fig. 5**). Meanwhile, in all hemipelvises fixated with 3.5-mm CS, the head of the screw maintained its original position, and the ilium rotated around the screw. None of the 3.5-mm CS had implant bending or breakage.

Discussion

This study demonstrated that fluoroscopically guided percutaneous application of double HCS was safe in a unilateral sacroiliac luxation model in small dogs without violation of the vertebral canal and ventral sacral foramen. Moreover,

resistance to rotational force applied on the fixation of the sacroiliac joint repaired with double 2.3-mm HCS estimated by maximum failure load was significantly higher than that of a single 3.5-mm CS. Therefore, our hypotheses were both accepted.

A surgical anatomy study of the canine sacrum for lag screw fixation reported that the area for correct screw placement on the lateral surface of the sacral wing is slightly larger than 1 cm² even in large-breed dogs.² In a study that placed two screws within the sacral body, the authors reported that approximately 20% of screws were not successfully placed in the target area.²¹ The ventral limit of the spinal canal overlaps with the dorsal 45% of the sacral wing height, and the first ventral sacral foramen limits the safe corridor to the caudal 20% of the sacral wing length.⁴ Owing to this anatomical structure, the second 2.3-mm HCS has the potential to damage the spinal canal or the first sacral

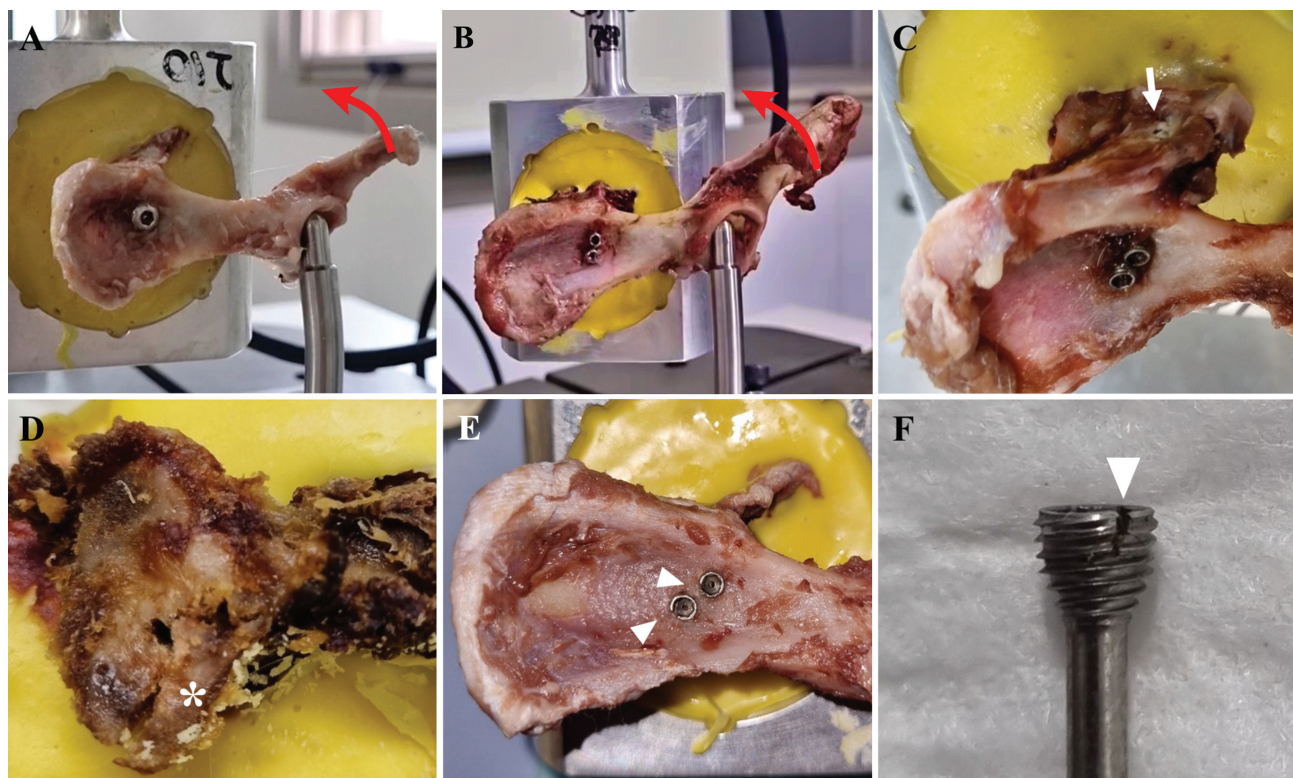


Fig. 5 Failure modes of test groups. Rotational failure of hemipelvis is observed in all hemipelvises of both experimental groups (A and B, red arrows). (A) In hemipelvises using single 3.5-mm CS lag screws, loss of fixation at the level of screw head without implant pullout or breakage is observed. (B) In the 2.3-mm HCS group, the heads of the screws rotated together while trailing threads are engaged in the ilium. (C) Cortical bone fracture of sacral dorsal lamina (arrow) and (D) vertebral body ventral to the screws (asterisk), and (E,F) breakage of screw heads (arrowheads) are observed in the 2.3-mm HCS group. In the other samples of the double 2.3-mm HCS group, the screws lost their stability within the cancellous bone of the sacral body. CS, cortical screw; HCS, headless cannulated self-compression screw.

Table 4 Failure modes of mechanical test and Fisher's exact test results

	Sacral lamina fracture	Ventral sacral body fracture	Sacrum cancellous destruction	Screw head breakage	Compression failure at head	Total	p-value
Double 2.3-mm HCS group (n = 11)	2 (18.2%)	1 (9.1%)	6 (54.5%)	2 (18.2%)	0 (0.0%)	11 (100%)	< 0.001
Single 3.5-mm CS group (n = 11)	0 (0.0%)	0 (0.0%)	0 (0.0%)	0 (0.0%)	11 (100%)	11 (100%)	

Abbreviations: CS, cortical screw; HCS, headless cannulated self-compression screw.

foramen. However, despite the narrow anatomy of the safe corridor and caudal position of the secondary screw in this study, double 2.3-mm HCS were inserted safely using a cannulated screw system without iatrogenic damage to the adjacent structure.

The angles between the first and second 2.3-mm HCS estimated by CCA and DVA were almost parallel as intended. Although it was described that two screws inserted divergent from each other show better mechanical properties in rotational and axial loading,^{22–24} insertion of a double screw divergently in this study was impossible considering the anatomical aspects on preimplantation CT. Mechanically, when two lag screws are placed parallelly, the second screw can provide an additional compression force as well as limit the rotational force.²⁴ Additionally, CCA and DVA in our study show more variable results than the target point compared with previous results reported by Déjardin and colleagues.¹⁸ This result could be a technical issue because we adjusted the aiming device by hand rather than a custom fixture. As another concern, we did not apply a metal artifact reduction protocol to analyze the CT data, which may have affected these results due to artifact errors.

Two-point fixation with double smaller screws showed higher maximum failure load to rotational, bending, and shear forces than a single larger screw in the static mechanical test of conventional lag screws in the canine sacroiliac luxation model.⁶ Moreover, the second screw can act as a rotational force neutralizer, and superior clinical outcomes have been obtained in human scaphoid fractures when using double HCS.²⁵ However, there have been no such studies in small dog sacroiliac luxation models with small HCS. Although we used a titanium HCS, which has lower stiffness and a higher occurrence of elastic deformation than stainless steel implants, double 2.3-mm HCS showed approximately 3.4 times greater resistance to the rotational force than single stainless steel 3.5-mm CS based on our results.²⁶ Therefore, the findings of this study are consistent with those of previous reports on the benefits of an additional antirotation screw. However, we did not conduct cyclic loading or other translational motion tests to evaluate the effect of repeated loading on the fixation constructs, which could further mimic clinical situations regarding fatigue failure of fixation constructs or implants. Further biomechanical studies are necessary to ensure the safety of applying double 2.3-mm HCS in clinical cases.

The failure modes between the two fixation systems were markedly different, which may have resulted from the different principles of compression and the presence of the second screw acting as an antirotational stabilizer. In hemipelvises repaired using 3.5-mm CS in the lag fashion, the compression force that stabilized the constructs was lost between the screw head against the surface of the ilium. Meanwhile, in fixations using double 2.3-mm HCS, loss of stability occurred mainly at the sacrum, while the trailing thread engaged in the ilium. Moreover, breakage of the screw head was observed. This difference may have occurred because the second HCS allowed the stress to be distributed compared with the single screw.²⁵ In addition, we did not apply the 3.5-mm CS with a washer to

reduce the variables that can affect the experimental results, as the application of a washer depends on the surgeon's preference and patients.^{2,16,19,21,27,28} However, the washer allows more compression to be generated by distributing the compressive force over a large area.²⁹ Several studies have reported that the compression that the trailing threads of a HCS achieves is far inferior to that of an Arbeitsgemeinschaft für Osteosynthesefragen (AO) screw with a washer.^{29–31} Therefore, if the 3.5-mm CS were used in conjunction with a washer, the failure loads and modes would be different. Another clinical dilemma arising from our finding is whether treating a sacroiliac luxation through double HCS is universally indicated. Although hemipelvises repaired with double 2.3-mm HCS showed higher maximum failure load compared with the 3.5-mm CS group, the result could be more debilitating to a clinical patient if complications such as sacral body fracture or failure occurred. Therefore, further clinical studies on using double 2.3-mm HCS for sacroiliac luxation are necessary to provide information on the risk regarding the application of double HCS and ensure clinical safety.

One of the interesting findings in our study was that the difference in mean failure load between the left and right sides in the single 3.5-mm CS group was close to being significantly different ($p = 0.052$). We used the conventional right-handed CS, which tightened the sacroiliac joint in the clockwise direction. However, when a standing ground reaction force was applied to the left side, the torsional force would have acted in the anticlockwise direction to the sacroiliac joint. Therefore, it may have contributed to showing weaker results compared with the opposite side in maintaining torque.³² In addition, the statistical significance may have been affected because we did not control for the variables such as the length and torque of the screws. Further investigations on the failure load according to the screw application sides and thread directions in the clinical setting are needed.

Several limitations of this study should be considered when translating the results into clinical situations. First, because of its *ex vivo* nature and our testing methodology, our study does not mimic actual weight-bearing conditions, and soft-tissue support was absent.^{33–35} In clinical cases, fibrous tissue formation around the sacroiliac joint followed by initial fixation may provide additional resistance to the rotational force. Furthermore, induced luxation of the sacroiliac joint model did not have changes, including muscle contracture and edema of the surrounding soft tissue or other pelvic injuries. Therefore, difficulties in the reduction and safe placement of double HCS may differ from the clinical cases. However, our experimental findings highlight the usefulness of augmentation with a second screw for sacroiliac luxation with regard to acute failure load in a clinical setting. Second, since only one surgeon performed the procedures, the results related to experience may vary. Finally, we did not use a metal artifact reduction protocol during the CT scan. Therefore, there could be artifact errors in the measurements of the mean insertion angles and entry points of the screws.

The feasibility of safe placement of double 2.3-mm HCS in a cadaveric small dog sacroiliac luxation model was confirmed in this study. Further, our results suggest that constructs

using double 2.3-mm HCS are mechanically superior to the resistance of the rotational force than single 3.5-mm CS placed in the lag fashion. Although this was an experimental cadaveric study, based on our results, the use of smaller double HCS may be beneficial as an alternative to the conventional single lag screw for stabilization of sacroiliac luxation in small dogs. Further investigations on the clinical application of 2.3-mm HCS are necessary.

Authors' Contribution

JJ, HL, and BS contributed to the conception of the study and study design. All the authors contributed to the acquisition of data, and data analysis and interpretation. All the authors also drafted, revised, and approved the submitted manuscript.

Funding

This work was supported by Korea Institute of Planning and Evaluation for Technology in Food, Agriculture and Forestry (IPET) through Companion Animal Whole Cycle Industrialization Technology Development Program, funded by the Ministry of Agriculture, Food and Rural Affairs (MAFRA; 322090).

Conflict of Interest

None declared.

References

- 1 DeCamp CE, Braden TD. Sacroiliac fracture-separation in the dog: a study of 92 cases. *Vet Surg* 1985;14(02):127–130
- 2 Moens NMM, DeCamp CE. Fractures of the pelvis. In: Johnston SA, Tobias KM, eds. *Veterinary Surgery: Small Animal*. 2nd ed. St Louis, MO: Elsevier; 2018:938–956
- 3 Stecyk CN, Jones SC, Hostnik ET, Tinga S, Kieves NR. Conservative management of sacroiliac luxation in 17 dogs: radiographic changes and long-term owner follow-up. *Can Vet J* 2021;62(03):261–265
- 4 DeCamp CE, Braden TD. The surgical anatomy of the canine sacrum for lag screw fixation of the sacroiliac joint. *Vet Surg* 1985;14(02):131–134
- 5 Lin CC, Lin KJ, Chen WC, Wei HW, Lin KP, Tsai CL. Larger screw diameter may not guarantee greater pullout strength for headless screws: a biomechanical study. *Biomed Tech (Berl)* 2017;62(03):257–261
- 6 Radasch RM, Merkley DF, Hoefle WD, Peterson J. Static strength evaluation of sacroiliac fracture-separation repairs. *Vet Surg* 1990;19(02):155–161
- 7 Burger M, Forterre F, Brunnberg L. Surgical anatomy of the feline sacroiliac joint for lag screw fixation of sacroiliac fracture-luxation. *Vet Comp Orthop Traumatol* 2004;17(03):146–151
- 8 Shales CJ, Langley-Hobbs SJ. Canine sacroiliac luxation: anatomic study of dorsoventral articular surface angulation and safe corridor for placement of screws used for lag fixation. *Vet Surg* 2005;34(04):324–331
- 9 Bowlt KL, Shales CJ. Canine sacroiliac luxation: anatomic study of the craniocaudal articular surface angulation of the sacrum to define a safe corridor in the dorsal plane for placement of screws used for fixation in lag fashion. *Vet Surg* 2011;40(01):22–26
- 10 Colgan SA, Hecker AT, Kirker-Head CA, Hayes WC. A comparison of the Synthes 4.5-mm cannulated screw and the Synthes 4.5-mm standard cortex screw systems in equine bone. *Vet Surg* 1998;27(06):540–546

- 11 Shuler TE, Boone DC, Gruen GS, Peitzman AB. Percutaneous iliosacral screw fixation: early treatment for unstable posterior pelvic ring disruptions. *J Trauma* 1995;38(03):453–458
- 12 Fowler JR, Ilyas AM. Headless compression screw fixation of scaphoid fractures. *Hand Clin* 2010;26(03):351–361, vi
- 13 del Piñal F, Moraleda E, Rúas JS, de Piero GH, Cerezal L. Minimally invasive fixation of fractures of the phalanges and metacarpals with intramedullary cannulated headless compression screws. *J Hand Surg Am* 2015;40(04):692–700
- 14 Gonsalves MN, Jankovits DA, Huber ML, Strom AM, Garcia TC, Stover SM. Biomechanical comparison of 3.0 mm headless compression screw and 3.5 mm cortical bone screw in a canine humeral condylar fracture model. *Vet Comp Orthop Traumatol* 2016;29(05):353–360
- 15 Fischer A, Binder E, Reif U, Biel M, Bokemeyer J, Kramer M. Closed reduction and percutaneous fixation of sacroiliac luxations in cats using 2.4 mm cannulated screws - a cadaveric study. *Vet Comp Orthop Traumatol* 2012;25(01):22–27
- 16 Tomlinson JL, Cook JL, Payne JT, Anderson CC, Johnson JC. Closed reduction and lag screw fixation of sacroiliac luxations and fractures. *Vet Surg* 1999;28(03):188–193
- 17 Averill SM, Johnson AL, Schaeffer DJ. Risk factors associated with development of pelvic canal stenosis secondary to sacroiliac separation: 84 cases (1985–1995). *J Am Vet Med Assoc* 1997; 211(01):75–78
- 18 Déjardin LM, Marturello DM, Guiot LP, Guillou RP, DeCamp CE. Comparison of open reduction versus minimally invasive surgical approaches on screw position in canine sacroiliac lag-screw fixation. *Vet Comp Orthop Traumatol* 2016;29(04):290–297
- 19 Tomlinson J. Minimally invasive repair of sacroiliac luxation in small animals. *Vet Clin North Am Small Anim Pract* 2012;42(05): 1069–1077, viii
- 20 Wills DJ, Neville-Towle J, Podadera J, Johnson KA. Computed tomographic evaluation of the accuracy of minimally invasive sacroiliac screw fixation in cats. *Vet Comp Orthop Traumatol* 2022;35(02):119–127
- 21 Singh H, Kowaleski MP, McCarthy RJ, Boudrieau RJ. A comparative study of the dorsolateral and ventrolateral approaches for repair of canine sacroiliac luxation. *Vet Comp Orthop Traumatol* 2016; 29(01):53–60
- 22 Chuckpaiwong B, Easley ME, Glisson RR. Screw placement in subtalar arthrodesis: a biomechanical study. *Foot Ankle Int* 2009;30(02):133–141
- 23 Shi X, Pan T, Wu D, et al. Effect of different orientations of screw fixation for radial head fractures: a biomechanical comparison. *J Orthop Surg Res* 2017;12(01):143
- 24 Amanatullah DF, Khan SN, Curtiss S, Wolinsky PR. Effect of divergent screw fixation in vertical medial malleolus fractures. *J Trauma Acute Care Surg* 2012;72(03):751–754
- 25 Quadlbauer S, Beer T, Pezzeri C, et al. Stabilization of scaphoid type B2 fractures with one or two headless compression screws. *Arch Orthop Trauma Surg* 2017;137(11):1587–1595
- 26 Perren SM, Mathys R, Pohler O. Appendix: implants and materials in fracture fixation. In: Johnson AL, Houlton JEF, Vannini R, eds. *AO Principles of Fracture Management in the Dog and Cat*. Davos Platz, Switzerland: AO Publishing; 2005:476–488
- 27 Shales C, Moores A, Kulendra E, White C, Toscano M, Langley-Hobbs S. Stabilization of sacroiliac luxation in 40 cats using screws inserted in lag fashion. *Vet Surg* 2010;39(06):696–700
- 28 Fauron AH, Déjardin LM. Sacroiliac luxation in small animals: treatment options. *Companion Anim* 2018;23(06):322–332
- 29 Bishop JA, Behn AW, Castillo TN. The biomechanical significance of washer use with screw fixation. *J Orthop Trauma* 2014;28(02): 114–117
- 30 Marshall PD, Evans PD, Richards J. Laboratory comparison of the cannulated Herbert bone screw with ASIF cancellous lag screws. *J Bone Joint Surg Br* 1993;75(01):89–92
- 31 Ray R. Methods of osseous fixation. In: Alan SB, Michael SD, Dennis EM, Stephen JM, eds. *McGlamry's Comprehensive Textbook of Foot and Ankle Surgery*. 3rd ed. Philadelphia, PA: Lippincott Williams & Wilkins; 2001:65–106
- 32 Giachetti RS, Grossi E. Brief review of the self-tightening, left-handed thread. *Int J Mech Mechatron Eng* 2021;15(04):175–179
- 33 Gregory CR, Cullen JM, Pool R, Vasseur PB. The canine sacroiliac joint. Preliminary study of anatomy, histopathology, and biomechanics. *Spine* 1986;11(10):1044–1048
- 34 Carnevale M, Jones J, Li G, Sharp J, Olson K, Bridges W. Computed tomographic evaluation of the sacroiliac joints of young working Labrador Retrievers of various work status groups: detected lesions vary among the different groups and finite element analyses of the static pelvis yields repeatable measures of sacroiliac ligament joint strain. *Front Vet Sci* 2020;7:528
- 35 Saunders FC, Cave NJ, Hartman KM, et al. Computed tomographic method for measurement of inclination angles and motion of the sacroiliac joints in German Shepherd Dogs and Greyhounds. *Am J Vet Res* 2013;74(09):1172–1182