



J. Dairy Sci. TBC

<https://doi.org/10.3168/jds.2023-23315>

© TBC, The Authors. Published by Elsevier Inc. and FASS Inc. on behalf of the American Dairy Science Association®.  
This is an open access article under the CC BY license (<http://creativecommons.org/licenses/by/4.0/>).

## WNT10B: A locus increasing risk of brachygnathia inferior in Brown Swiss cattle

Sarah Widmer,<sup>1,2</sup> Franz R. Seefried,<sup>2</sup> Irene M. Häfliger,<sup>1</sup> Heidi Signer-Hasler,<sup>3</sup> Christine Flury,<sup>3</sup> and Cord Drögemüller<sup>1\*</sup>

<sup>1</sup>Institute of Genetics, Vetsuisse Faculty, University of Bern, 3012 Bern, Switzerland

<sup>2</sup>Qualitas AG, 6300 Zug, Switzerland

<sup>3</sup>School of Agricultural, Forest and Food Sciences, Bern University of Applied Sciences, 3052 Zollikofen, Switzerland

### ABSTRACT

Shortening of the mandible (brachygnathia inferior) is a congenital, often inherited and variably expressed craniofacial anomaly in domestic animals including cattle. Brachygnathia inferior can lead to poorer animal health and welfare and reduced growth, which ultimately affects productivity. Within the course of the systematic conformation scoring, cases with a frequency of about 0.1% were observed in the Brown Swiss cattle population of Switzerland. In contrast, this anomaly is almost unknown in the Original Braunvieh population, representing the breed of origin. Because none of the individually examined 46 living offspring of our study cohort of 145 affected cows showed the trait, we can most likely exclude a monogenic-dominant mode of inheritance. We hypothesized that either a monogenic recessive or a complex mode of inheritance was underlying. Through a genome-wide association study of 145 cases and 509 controls with imputed 624k SNP data, we identified a 4.5 Mb genomic region on bovine chromosome 5 significantly associated with this anomaly. This locus was fine-mapped using whole-genome sequencing data. A run of homozygosity analysis revealed a critical interval of 430 kb. A breed specific frameshift duplication in *WNT10B* (rs525007739; c.910dupC; p.Arg304ProfsTer14) located in this genomic region was found to be associated with a 21.5-fold increased risk of brachygnathia inferior in homozygous carriers. Consequently, we present for the first time a genetic locus associated with this well-known anomaly in cattle, which allows DNA-based selection of Brown Swiss animals at decreased risk for mandibular shortening. In addition, this study represents the first large animal model of a *WNT10B*-related inherited developmental disorder in a mammalian species.

**Key words:** *Bos taurus*, craniofacial development, GWAS, skeletal formation, whole-genome sequencing, Wnt signaling

### INTRODUCTION

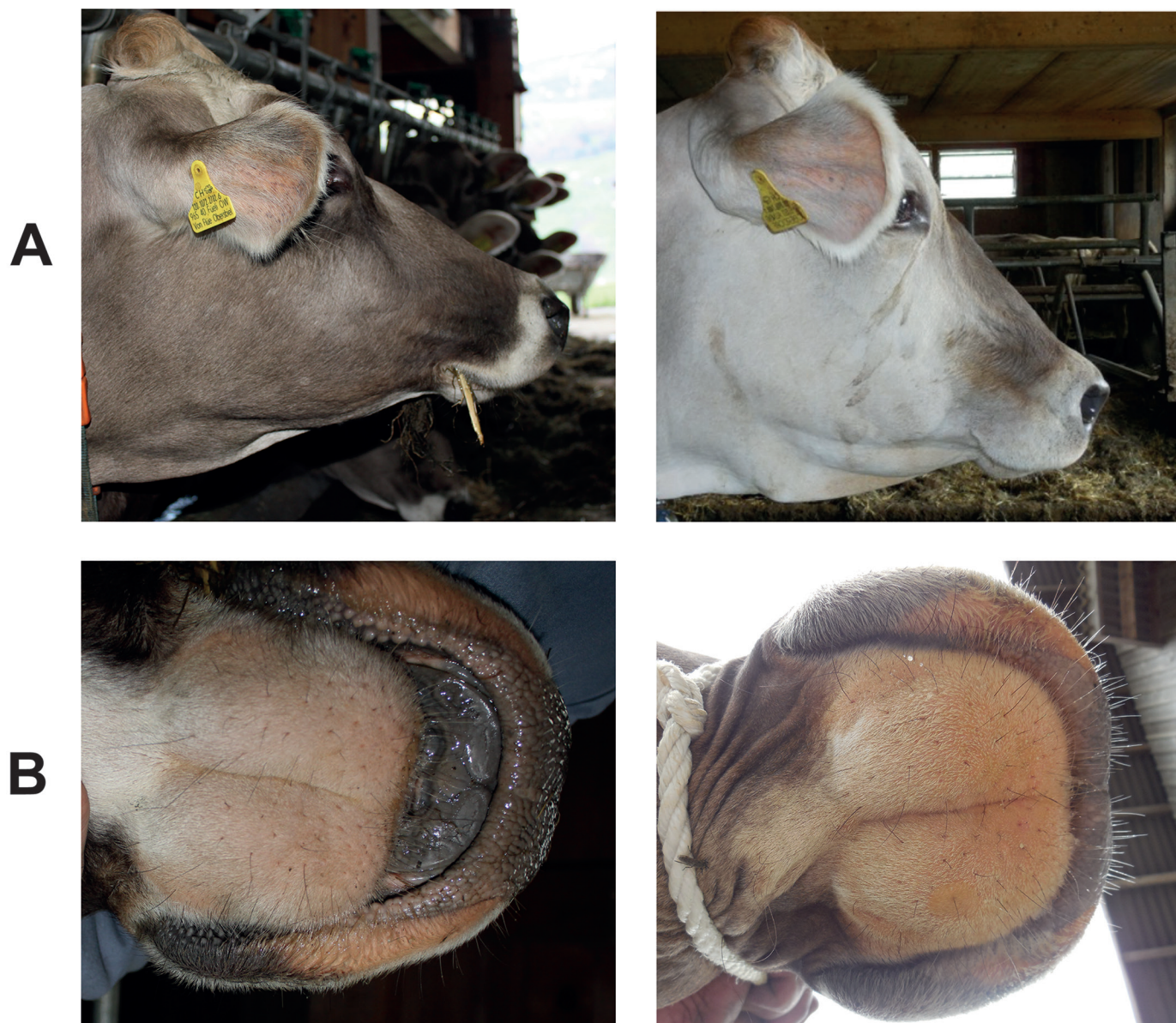Brachygnathia inferior is a well-known congenital and presumably inherited malformation in domestic animals including cattle (OMIA 000147–9913). It is known that chromosomal abnormalities, viral infections such as Schmallenberg virus, teratogenic drugs, or plant alkaloids can also cause such craniofacial malformations, but most often in combination with other abnormalities (Kerkmann et al., 2008; Herder et al., 2012; Peperkamp et al., 2015). A monogenic-recessive inherited cause for a nonsyndromic form of mandibular shortening was first suggested in Shorthorn cattle more than 80 years ago (Annett 1939). In a study of Fleckvieh cattle, a syndromic form of brachygnathia inferior associated with proportionate dwarfism was described as a simple recessive Mendelian *GON4L*-related trait (OMIA 001985–9913; Schwarzenbacher et al., 2016). The undesirable phenotype of shortening of the mandible (lower jaw) resulting in protrusion of the maxilla (upper jaw) is shown in Figure 1 in comparison to an unaffected cow. An extreme degree of brachygnathia inferior could result in reduced growth due to impaired suckling and grazing, as well as poorer animal health and welfare, which could ultimately affect productivity. Therefore, it would be desirable to select against this phenotype and decipher the genetic background of the craniofacial malformation. Based on heterogeneous findings in different mammalian species, either a Mendelian mode of inheritance or a possibly more complex genetic cause could be assumed.

Forms of syndromic and nonsyndromic brachygnathia inferior were also observed in other domestic animal species such as dogs (OMIA 000147–9615), sheep (OMIA 000147–9940; Greber et al., 2013), or horses (OMIA 000147–9796). The molecular causes are rarely known. A study in East Friesian sheep showed

Received January 31, 2023.

Accepted May 15, 2023.

\*Corresponding author: [cord.droegemueller@unibe.ch](mailto:cord.droegemueller@unibe.ch)



**Figure 1.** Brachygnathia inferior in Brown Swiss cattle: photos of the head form (A) and the lower jaw (B) of an affected cow (left side) in comparison to an unaffected control animal (right side).

that the brachygnathic facial type was mainly characterized as a shortened mandible, the upper jaw was not significantly involved (Eriksen et al., 2016), and that it could be reproduced in a breeding experiment, suggesting a complex inheritance (Kerkmann et al., 2008). In sheep, an autosomal recessive *OBSL1*-related brachygnathia, cardiomegaly and renal hypoplasia syndrome was reported (Shariflou et al., 2013; Woolley et al., 2020). In horses, GWAS revealed an associated region on chromosome 13 for prognathism, where the lower jaw outgrows the upper, resulting in an extended chin and a crossbite (Signer-Hasler et al., 2014). Recently,

abnormal shortening of the mandible (brachygnathia inferior) was observed in single cloned dogs, possibly associated with variants in initiators or regulators of the Wnt/cadherin signaling pathway (Choe et al., 2022).

Among the developmental anomalies of the jaw bones in domestic animals, brachygnathia superior represents another form of dysgnathia. The congenital abnormal shortening of the upper jaw (maxilla) leads to protrusion of the lower jaw (mandible) and is reported in sporadic cases, so far without a known inherited cause, in several domestic animal species including cattle (OMIA 000149–9913). A study in a pedigree of German

shorthaired pointer dogs observed that brachygnathia superior was most likely inherited in a simple Mendelian recessive manner (OMIA 000147–9615; Byrne and Byrne, 1992). In humans, prognathism is the most common form of a presumably polygenically inherited malocclusion of teeth and jaws, the genetic causes of which are diverse but largely unknown (Jaruga et al., 2022). For example in the Asian population, the *MATN1* gene encoding a cartilage matrix protein represents a risk locus for mandibular prognathism (Jang et al., 2010). In a Japanese study, *PLXNA2* was identified as a candidate gene for prognathism by GWAS (Kajii et al., 2018). In a family with inherited mandibular prognathism, a possible causal missense variant in the *BEST3* gene was identified (Kajii et al., 2019).

The aim of this study was to decipher the genetic architecture of brachygnathia inferior for the first time in cattle. Therefore, we first analyzed the possible mode of inheritance in the Brown Swiss cattle population of Switzerland. To identify associated genomic regions performing GWAS, we merged genotypes from cohorts with data from animals genotyped for genomic selection. Run of homozygosity (ROH) mapping using whole-genome sequencing (WGS) data were performed to fine map the associated locus. This resulted in the identification of a possible causative protein-changing variant for this craniofacial malformation affecting a member of the Wnt protein family.

## MATERIALS AND METHODS

### Phenotypes

All animals in this study were examined with the consent of their owners. Collection of samples was approved by the Cantonal Committee for Animal Experiments (Canton of Bern; permit 71/19).

The phenotypic and genotypic data were provided by the Swiss cattle breeding organization Braunvieh Schweiz (Zug, Switzerland). The founder breed of Brown Swiss, which originated in North America from animals bred in Switzerland, is the so-called Original Braunvieh population that is still independently bred in Switzerland. Allocation to the subpopulation was made based on the animal's proportion of each subpopulation and where a minimal proportion of 0.6 of the corresponding subpopulation was applied. The presence or absence of brachygnathia inferior is routinely assessed in linear type classification of first lactating cows in the Brown Swiss breeding program. The degree of malformation surveyed (mild or severe) was not considered in our analysis. For 145 out of 365 reported cases, for which we had access to, their malformed phenotype was validated by additional on-farm visits and hair root

samples were taken for subsequent array genotyping. The controls selected were 509 Brown Swiss sires that were screened for this malformation by veterinarians at the time of admission to the insemination station.

### Genotypes

All 654 animals were genotyped within routine genomic selection pipelines using different arrays that encompass between 9k and 850k SNPs. We applied a 2-step imputation approach (first to 150k density and subsequently to high-density) using the FImpute (Version 3) software with default parameters (Sargolzaei et al., 2011). In each step, SNPs with a minor allele frequency <1% and an SNP call rate <0.99 were excluded from the data set. The bovine ARS-UCD1.2 assembly was used as reference genome.

### Whole-Genome Sequencing

GWAS was performed by single SNP regression (SSR) using a mixed model in the software snp1101 (Sargolzaei, 2021). The genomic relationship for the animals used in the analyses was calculated and was fitted in the model to correct for population stratification (VanRaden, 2008). We used the following model:

$$y_i = \mu + \beta g_i + a_i + \varepsilon_i,$$

where  $y_i$  is the phenotype of animal  $i$  (coded as 0 or 1),  $\mu$  is the overall mean,  $\beta$  represents the allele substitution effect,  $g_i$  is the SNP genotype of animal  $i$ , coded as 0, 1, and 2 for SNP genotypes AA, AB, and BB, respectively.  $a_i$  is the random additive polygenic effect of animal  $i$  with a  $\sim N(0, G\sigma_a^2)$  where  $G$  represents the genomic relationship matrix (VanRaden, 2008) and  $\sigma_a^2$  is the polygenic additive genetic variance.  $\varepsilon_i$  is the random residual effect. The aim of this approach was to detect SNPs that were significantly associated with our phenotype of interest. The analysis was conducted using a final data set of 624,374 SNPs and 654 animals (145 cases and 509 controls).

### Whole-Genome Sequencing and ROH Mapping

Of the 145 affected animals, we selected 12 cases for WGS based on DNA quality. WGS data processing of these animals was performed as reported earlier (Häfliger et al., 2020). For 10 of the AI bull controls WGS data were already available (Table 1). Finally, we used WGS data from 22 sequenced animals (12 cases, 10 controls) for homozygosity mapping. The WGS data were screened for possible Mendelian errors using vari-

**Table 1.** Overview of Brown Swiss study cohorts and genotyping results for the *WNT10B* variant (c.910dupC) in Swiss dairy cattle

Group	Subgroup 1	Subgroup 2	Quantity	Genotype <sup>1</sup>		
				Ref/ref	Ref/var	Var/var
Controls <sup>2</sup>	SNP data		509			
		with WGS data (sharing ROH)	10 (1)			
Cases <sup>2</sup>	SNP data		145			
		with WGS data (sharing ROH)	12 (11)			
Population	PCR validation Custom array data		81	16	13	52
			41,335			
	Brown Swiss		16,617	7,063	7,663	1,891
		Original Braunvieh	2,837	2,834	3	
		Holstein	19,045	19,026	19	
		Simmental	2,836	2,835	1	
	Imputed genotypes Brown Swiss <sup>4</sup>		29,498			
Affected <sup>5</sup>		187	32	37	118	
	Unaffected <sup>5</sup>	29,311	16,222	10,933	2,156	

<sup>1</sup>for variant chr5:30,846,506insC.

<sup>2</sup>initial data set using validated phenotypes for GWAS analyses.

<sup>3</sup>low-density (60K) chip designed for Switzerland.

<sup>4</sup>Population wide imputation was carried out using most recent genotype archive of Braunvieh Schweiz, which encompasses newly pheno- and genotyped samples compared with data set used in initial GWAS analyses.

<sup>5</sup>identification through routine conformation scoring.

ant data of 798 sequenced genomes that had been sequenced in the course of the Swiss Comparative Bovine Resequencing project (SCBR; <https://www.ebi.ac.uk/ena/browser/view/PRJEB18113>). A threshold of 0.02 was used for Mendel error filtering. The analysis was performed for the associated 4.5 Mb region on chromosome 5 previously identified by GWAS analysis by using the PLINK software (Chang et al., 2015) under the assumption of a monogenic-recessive inheritance.

### Variant Filtering and Annotation

For the variant filtering, we applied an inhouse software based on a Shell-script using the SCBR vcf file containing the 798 sequenced animals mentioned above. We filtered in the previous identified ROH window for homozygous variants in the 11 cases that shared the identified homozygosity window. In a second step, we analyzed the frequency of the identified variants in the inhouse vcf file and the 1000 Bull Genomes Project Run 9 vcf including 5,116 animals (Hayes and Daetwyler, 2019). The SCBR vcf file contained 629 genomes from the 4 major cattle breeds in Switzerland (271 Holstein, 150 Brown Swiss, 139 Original Braunvieh and 69 Simmental) as well as 168 genomes from different global breeds. We filtered for Brown Swiss specific variants as we observed the studied phenotype in the Brown Swiss breed only. To define a Brown Swiss focusing analysis, we used a threshold of maximum 1% homozygous carriers of the other breeds with at least 50 animals

sequenced in each vcf file. The ARS-UCD1.2 assembly was used as reference genome. The Ensembl genome browser (<http://www.ensembl.org>) was consulted for annotation of the variants (Ensembl bos taurus version 106.12; ARS-UCD1.2) and the visualization of their effect on the associated genes (Ensembl, 2022).

### Odds Ratio Calculation

To determine the risk of an animal to be affected by the malformation when carrying the candidate variant, we calculated the odds ratio. Therefore, we used the data from routinely imputed SNP genotypes and the information from routine conformation scoring for defining the presence or absence of brachygnathia inferior.

### Genotyping of the *WNT10B* Variant (rs525007739)

Sanger sequencing of PCR products using flanking primers (forward: AAGTGCCATGGTACGTCAGG and reverse: GGGTCTCGCTCACAGAAGTC) was carried out to genotype the 1bp duplication in the *WNT10B* gene (NC\_037332.1: g.30,846,510dupC). This was done on a subset of 81 cases for which we still had DNA available from the original cohort of 145 cases (Table 1).

## RESULTS AND DISCUSSION

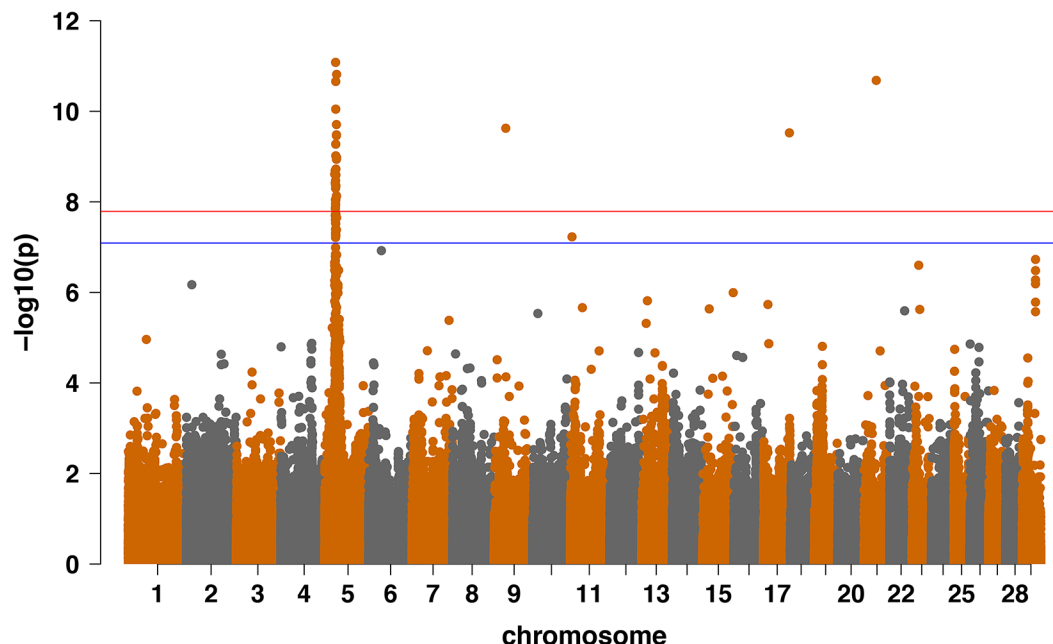
From the routine conformation scoring in the years 2010 until 2022, 274,272 Brown Swiss animals were analyzed and 365 of them were found to have brachygnathia inferior. In the same period, only one cow with brachygnathia inferior was found out of 40,437 scored animals from the Original Braunvieh population, the ancestral breed of the modern Brown Swiss population. Therefore, the frequency of brachygnathia inferior phenotype in the Brown Swiss population was found to be approximately 0.1%, while it is considered zero in Original Braunvieh. The cases are cows in lactation and thus were kept by the breeders. We cannot exclude that we missed animals with very pronounced brachygnathia due to counter-selection by the breeders for aesthetic or practical reasons related to poor growth due to feeding difficulties. Out of the 365 recorded animals with brachygnathia inferior we used a subset of 145 animals with validated phenotypes in our subsequent GWAS analysis, and of these, blood samples were additionally collected from 81 animals for further WGS or PCR applications. In addition, we wanted to determine the possible mode of inheritance. Therefore, we examined 46 living progeny of our cohort of 145 affected cows. Because none of them showed brachygnathia inferior, a simple monogenic-dominant model can most probably be excluded. Consequently, we suspected that either a simple monogenic-recessive or an oligo- or polygenic-recessive or additive inheritance underlies the anomaly.

The results from the SSR analysis using imputed 624k SNP data are shown in a Manhattan plot (Figure 2). There is a single genome-wide significant hit on chromosome 5 (Bonferroni corrected threshold level of 1%). The associated, approximately 4.5 Mb long region spans the interval from 29 to 33 Mb. The top-associated SNPs were at positions 30,420,246 bp and 30,424,685 bp. The proportions of animals homozygous for the top-associated alleles at these 2 positions in the case group was 66% and in the control group 12%. There were single significantly associated SNPs above the population-based significance threshold on additional chromosomes possibly representing false positive associations. Sexes are unbalanced between controls and cases in our analysis here, which could cause a false positive GWAS result and also excluded X-chromosomal genotypes. Indeed, this strategy was applied to have double-validated phenotype data for control group due to narrow animal handling at the AI station. However, a preliminary and unpublished study using a purely female control cohort resulted in the identification of the same major QTL region. In conclusion, for the first time this GWAS analysis revealed an associated locus for this undesirable craniofacial mal-

formation in cattle. For fine mapping, we focused on this single brachygnathia inferior-associated genomic region on chromosome 5.

For the following ROH mapping assuming a recessive disorder using WGS data, we did not find a single window shared by all cases and none of the controls. Such results would fit a simple monogenic-recessive model explaining all 12 sequenced affected animals; however, 2 top ROH windows were detected in 11 out of 12 cases and in 1 out of 10 controls (Table 2). The first shared ROH was 430 kb long and located on chromosome 5 between 30,423,169 and 30,853,973 bp. The second ROH window was smaller, spanning only 5.4 kb from 31,248,867 to 31,254,272 bp. This smaller ROH window was not considered in further analyses because of very short length and the higher probability of having false positive carriers. Because not all cases had the 430 kb ROH, we conclude that there are additional rare variants associated with brachygnathia inferior. In addition, incomplete penetrance of the recessive locus on chromosome 5 beside genetic heterogeneity could be considered. This is in line with the observation of homozygous controls. Furthermore, it is suspected that the single homozygous control animal had a minor mandibular shortening that was not visible during the examination. At the time of this study, this bull had already left the AI station and therefore the phenotype could not be verified. In the 430 kb long ROH interval the 2 top-associated SNPs from the SSR are co-located, one at the upstream boundary and one at the beginning of the ROH (Figure 3A). Within this ROH a total of 17 protein-coding genes and 2 nonprotein-coding genes are annotated.

Subsequent variant filtering within the 430 kb region revealed 326 homozygous variants in the ROH window shared by 11 brachygnathia inferior-affected animals. Filtering for Brown Swiss specific variants resulted in a reduction to 7 and then to 5 variants using the SCBR and then the 1000 Bull Genomes Project variant catalogs, respectively. These 5 variants affect 5 different genes (Table 3 and Figure 3A). Four of them are noncoding variants, and their annotated genes are reportedly not involved in the process of bone formation or known to be in association with bone malformations. Interestingly, one of the 5 variants is a high impact variant predicted to affect the open reading frame of a protein-coding gene that has an impact on bone formation. The single nucleotide duplication is located in exon 5 of the *Wnt family member 10B* (*WNT10B*) gene (NC\_037332.1: g.30,846,510dupC; rs525007739). The deleterious *WNT10B* variant (XM\_010805029.3: c.910dupC) is predicted to result in a frameshift after arginine 304 with a stop codon after 14 altered amino acids (XP\_010803331.1: p.Arg304ProfsTer14). This



**Figure 2.** Manhattan plot showing GWAS results for brachygnathia inferior in Brown Swiss cattle using single SNP regression with Bonferroni corrected threshold level of 5% (blue line) and 1% (red line).

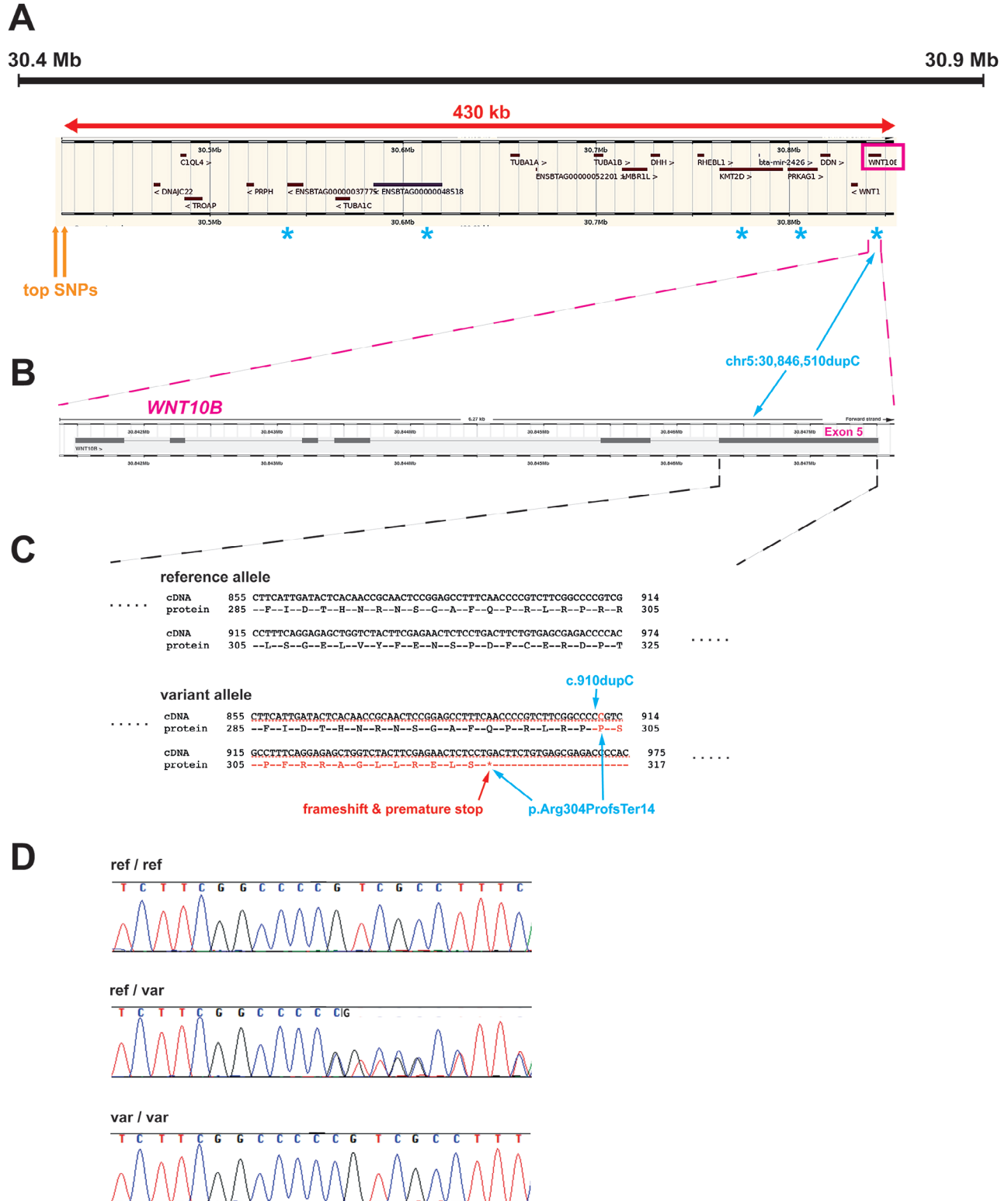
alteration results in a truncated AA sequence of 317 residues compared with the 391 AA long wild type protein (Figure 3B and 3C). The frameshift variant lies close to the C-terminal end of the protein including the Wnt domain. Therefore, the effect of a 20% truncation on protein function, if expressed at all, is potentially harmful, thus the variant represents a most likely loss-of-function mutation. As a member of the Wnt protein family, *WNT10B* encodes a cysteine-rich glycoprotein, a secreted signaling protein that plays a role in oncogenesis and various developmental processes (Mittermeier and Virshup, 2022). *WNT10B* specifically activates canonical Wnt/ $\beta$ -catenin signaling and thus triggers  $\beta$ -catenin/LEF/TCF-mediated transcriptional programs (Wend et al., 2012). Among other organs, the function of *WNT10B* has been well established in bone to be involved in signaling networks controlling stemness, pluripotency and cell fate decisions (Wend et al., 2012). Previous studies have shown that Wnt signaling is important for the complex regulation of the development of craniofacial structures (Dash and

Trainor, 2020). It acts as a key regulator of chondrocyte versus osteocyte cell fate in neural crest cells during skeletogenic differentiation. In contrast, when studying agenesis of bones, ectopic cartilage forms following Wnt inactivation, suggesting that osteogenic progenitors are diverted to a chondrogenic fate in the absence of Wnt signaling (Wend et al., 2012). Enhancing Wnt increases osteogenic potential and Wnt signaling therefore regulates neural crest cell differentiation into both chondrocytes and osteocytes (Bodine and Komm; 2006). Furthermore, Wnt signaling can regulate both endochondral and intramembranous ossification of neural crest cells during cranioskeletal development (Dash and Trainor, 2020). Recently, Wnt signaling was observed to be associated with brachygnathia inferior in cloned dogs (Choe et al., 2022). Human autosomal dominant forms of oligodontia (OMIM 617073) and autosomal recessive forms of split-hand/foot malformation (OMIM 225300) are previously reported as *WNT10B*-related Mendelian diseases. Canonical *Wnt* signaling through *Lrp5* and *Lrp6*, both co-receptors of *Wnt* signaling, plays a critical role in the development of dentition, and can result in a variety of tooth phenotypes, such as tooth agenesis or morphological defects (Kokubu et al., 2004). Although it is speculated that delayed *Wnt* signaling leads to tooth agenesis in humans with pathogenic *WNT10B* variants, there is not yet a reliable animal model to explain the molecular and cellular mechanisms underlying this situation (Kurosaka et al.,

**Table 2.** Results of run of homozygosity (ROH) analysis for the associated region on chromosome 5

Start position <sup>1</sup>	End position <sup>1</sup>	Length (kb)	Case (n)	Control (n)
30,423,169	30,853,973	430.8	11	1
31,248,867	31,254,272	5.4	11	1

<sup>1</sup>ARS-UCD1.2 assembly.



**Figure 3.** (A) Graphical representation of the region identified by run of homozygosity (ROH) mapping. Screenshot of the region on bovine chromosome 5 between 30.4 and 30.9 Mb from Ensembl. The red bar illustrates the 430 kb window identified ROH and the blue stars the 5 variants remaining after variant filtering. The orange arrows show the localization of the top-associated SNPs from GWAS. The gene *WNT10B* is highlighted in pink. (B) Graphical representation of the *WNT10B* gene highlighting the candidate causal variant located in exon 5 (graphical illustration from Ensembl). (C) The 1 bp duplication leads to a frameshift which is predicted to truncate the C-terminus of the *WNT10B* protein. (D) Electropherograms showing the 3 alternative *WNT10B* genotypes.

**Table 3.** Remaining sequence variants after filtering for Brown Swiss specific variants on chromosome 5 against the variant catalogs of the Swiss Comparative Bovine Resequencing project and the 1000 Bull Genomes project

Position <sup>1</sup>	Reference allele	Alternative allele	Variant ID	Minor allele frequency <sup>2</sup>	Predicted effect	Associated gene
30,540,341	C	A	rs134508338	0.304	Modifier	<i>ENSBTAG00000037775</i>
30,612,641	C	T	rs724035615	0.306	Modifier	<i>TUBA1C</i>
30,776,962	G	A	rs458811699	0.313	Modifier	<i>KMT2D</i>
30,807,007	T	C	rs717868271	0.308	Modifier	<i>PRKAG1</i>
30,846,506	G	GC	rs525007739	0.287	High	<i>WNT10B</i>

<sup>1</sup>ARS-UCD1.2 assembly.

<sup>2</sup>in the Brown Swiss population using 1000 Bull Genomes Project Run 9 vcf.

2022). *Wnt10b* null mice are associated with age-progressive osteopenia (Stevens et al., 2010). In summary, in light of what is known about the function of this gene, the identified variant in the bovine *WNT10B* gene appears to us to be a very likely causal mutation. The herein described deleterious bovine *WNT10B* variant is therefore the first in any mammalian species to be associated with brachygnathia inferior, and *WNT10B* should be considered as candidate gene for syndromic forms of cranioskeletal development defects in humans and other animal species. Whether the homozygous cattle have a reduced number of teeth in addition to the visible shortening of the lower jaw is not known to us at this time, as the number of teeth is not checked during routine conformation scoring. In addition, the bovine dentition differs from that of humans, which may result in different phenotypes. We are not aware of any evidence of missing incisors in the affected cattle. Inspection of the more caudally located premolars and molars in cattle cannot be carried out without significant risk to both animal and human.

Interestingly, in the 1000 Bull Genomes Project Run vcf file, we observed a relatively high minor allele frequency for the variant in *WNT10B* at 28% in Brown Swiss. Currently this *WNT10B* variant is routinely genotyped using the latest version of the custom low-density Swiss SNP array, and a minor allele frequency of 34.4% is observed in 16,617 Brown Swiss animals (Table 1). Around 25,000 animals for the 3 other major dairy cattle breeds in Switzerland (Holstein, Original Braunvieh and Simmental) were also genotyped with that array (Table 1). Within this data set, we observed an allele frequency of the *WNT10B* variant of 0.1%, only 23 heterozygous carriers were detected (Table 1). These carriers could be the result of rare genotype errors or true genotypes present in animals of other breeds due to undocumented Brown Swiss heritage. Overall, these data support the postulated possible causality of the *WNT10B* variant. Nevertheless, the rather high allele frequency in Brown Swiss contradicts the very rare occurrence of the anomaly in the studied population. One explanation could be

that the individual phenotype of brachygnathia inferior varies highly; thereby mild malformations could easily be overlooked in routine conformation scoring. Alternatively, it could be speculated that the expression of the anomaly brachygnathia inferior, which is generally considered a complex trait, is co-determined by other genomic factors of the individual's background and cause incomplete penetrance. Furthermore, it is possible that the *WNT10B* variant is not causative and we might have missed to detect the true causal variant. However, by excluding *WNT10B* homozygous animals in both cohorts, the significant signal of the candidate region on chromosome 5 disappeared. The same was observed when we fitted the *WNT10B* genotype as fixed effect in the GWAS. Therefore, we do not assume that we missed flanking regulatory variants. Nonetheless, additional genome-wide located variants influencing the expression of the trait are highly likely.

Furthermore, using routine SNP genotype imputation and routine conformation score data, we calculated an odds ratio of being affected by the anomaly for *WNT10B*-homozygous animals. More than 63% of all genotyped cows with brachygnathia inferior (118 of 187) showed the homozygous variant *WNT10B* genotype, 19.8% were heterozygous carriers and 17.1% were noncarriers (Table 1). In the genotyped population control cohort of more than 29 thousand Brown Swiss cattle assumed to be unaffected, 7.4% were homozygous and 37.3% were heterozygous carriers (Table 1). The calculated odds ratio was 21.54. Therefore, we conclude that the *WNT10B* loss-of-function variant explains a significantly increased risk of developing brachygnathia inferior in homozygous animals.

The SNP data analyzed during the current study are not publicly available but are available from the corresponding author on reasonable request.

## CONCLUSIONS

Our work represents the first comprehensive study of the genetics of brachygnathia inferior in dairy cattle. With the identification of a single associated risk locus



and the associated loss-of-function allele in *WNT10B* there is for the first time a genetic explanation for the development of this long-time known abnormality. Apparently, a single recessively inherited allele, located in a gene significantly involved in the development of bone structure, contributes significantly to the expression of the trait. These findings allow DNA-based selection of Brown Swiss animals with lower risk for mandibular shortening. In addition, this study represents the first large animal model of a *WNT10B*-related inherited developmental disorder in a mammalian species.

## ACKNOWLEDGMENTS

This study was partially supported by the Arbeitsgemeinschaft Schweizerischer Rinderzüchter (Zollikofen, Switzerland) and the Federal Office for Agriculture (Bern, Switzerland). We thank the H.W. Schaumann Stiftung for financially supporting the presentation of this work at the 2022 ADSA annual meeting. The authors are grateful to the Swiss cattle breeding organization Braunvieh Schweiz for providing phenotypic and genotypic data. The 1000 Bull Genomes Project Consortium is acknowledged for providing sequencing data. We thank Astrid Lussi and Raphael Albisser for collecting the samples and taking photos. The authors have not stated any conflicts of interest.

## REFERENCES

- Annett, H. E. 1939. Note on a new recessive lethal in cattle. *J. Genet.* 37:301–302. <https://doi.org/10.1007/BF02982731>.
- Bodine, P. V., and B. S. Komm. 2006. Wnt signaling and osteoblastogenesis. *Rev. Endocr. Metab. Disord.* 7:33–39. <https://doi.org/10.1007/s11154-006-9002-4>.
- Byrne, M. J., and G. M. Byrne. 1992. Inheritance of ‘overshot’ malocclusion in German shorthaired pointers. *Vet. Rec.* 130:375–376. <https://doi.org/10.1136/vr.130.17.375>.
- Chang, C. C., C. C. Chow, L. C. Tellier, S. Vattikuti, S. M. Purcell, and J. J. Lee. 2015. Second-generation PLINK: Rising to the challenge of larger and richer datasets. *Gigascience* 4:7. <https://doi.org/10.1186/s13742-015-0047-8>.
- Choe, Y., T.-Y. Hur, S.-L. Lee, S. Lee, D. Lim, B.-H. Choi, H. Jeong, J.-G. No, and S. A. Ock. 2022. Brachygnathia inferior in cloned dogs is possibly correlated with variants of Wnt signaling pathway initiators. *Int. J. Mol. Sci.* 23:475. <https://doi.org/10.3390/ijms23010475>.
- Dash, S., and P. A. Trainor. 2020. The development, patterning, and evolution of neural crest cell differentiation into cartilage and bone. *Bone* 137:115409. <https://doi.org/10.1016/j.bone.2020.115409>.
- Ensembl. 2022. Ensembl. Accessed Jun. 12, 2022. [https://www.ensembl.org/Bos\\_taurus/Info/Index](https://www.ensembl.org/Bos_taurus/Info/Index).
- Eriksen, T., M. Ganter, O. Distl, and C. Staszuk. 2016. Cranial morphology in the brachygnathic sheep. *BMC Vet. Res.* 12:8. <https://doi.org/10.1186/s12917-016-0634-7>.
- Greber, D., M. Doherr, C. Drögemüller, and A. Steiner. 2013. Occurrence of congenital disorders in Swiss sheep. *Acta Vet. Scand.* 55:27. <https://doi.org/10.1186/1751-0147-55-27>.
- Häfliger, I. M., N. Wiedemar, T. Švara, J. Starič, V. Cociancich, K. Šest, M. Gombač, T. Paller, J. S. Agerholm, and C. Drögemüller. 2020. Identification of small and large genomic candidate variants in bovine pulmonary hypoplasia and anasarca syndrome. *Anim. Genet.* 51:382–390. <https://doi.org/10.1111/age.12923>.
- Hayes, B. J., and H. D. Daetwyler. 2019. 1000 Bull genomes project to map simple and complex genetic traits in cattle: Applications and outcomes. *Annu. Rev. Anim. Biosci.* 7:89–102. <https://doi.org/10.1146/annurev-animal-020518-115024>.
- Herder, V., P. Wohlsein, M. Peters, F. Hansmann, and W. Baumgärtner. 2012. Salient lesions in domestic ruminants infected with the emerging so-called Schmallenberg virus in Germany. *Vet. Pathol.* 49:588–591. <https://doi.org/10.1177/0300985812447831>.
- Jang, J. Y., E. K. Park, H. M. Ryoo, H. I. Shin, T. H. Kim, J. S. Jang, H. S. Park, J. Y. Choi, and T. G. Kwon. 2010. Polymorphisms in the matrilin-1 gene and risk of mandibular prognathism in Koreans. *J. Dent. Res.* 89:1203–1207. <https://doi.org/10.1177/0022034510375962>.
- Jaruga, A., J. Książkiewicz, K. Kuzniarz, and P. Tylzanowski. 2022. Orofacial cleft and mandibular prognathism—Human genetics and animal models. *Int. J. Mol. Sci.* 23:953. <https://doi.org/10.3390/ijms23020953>.
- Kajii, T. S., A. Oka, M. Hatta, J. Yamazaki, J. Yamashita, and J. Iida. 2018. PLXNA2 identified as a candidate gene by genome-wide association analysis for mandibular prognathism in human chondrocytes. *Biomed. Rep.* 9:253–258. <https://doi.org/10.3892/br.2018.1128>.
- Kajii, T. S., A. Oka, F. Saito, J. Mitsui, and J. Iida. 2019. Whole-exome sequencing in a Japanese pedigree implicates a rare non-synonymous single-nucleotide variant in BEST3 as a candidate for mandibular prognathism. *Bone* 122:193–198. <https://doi.org/10.1016/j.bone.2019.03.004>.
- Kerkmann, A., H. Kuiper, M. Ganter, and O. Distl. 2008. [Review of literature and results from test matings of East Friesian milk sheep affected with brachygnathia inferior.] *Berl. Munch. Tierarztl. Wochenschr.* 121:292–305.
- Kokubu, C., U. Heinzmann, T. Kokubu, N. Sakai, T. Kubota, M. Kawai, M. B. Wahl, J. Galceran, R. Grosschedl, K. Ozono, and K. Imai. 2004. Skeletal defects in ringelschwanz mutant mice reveal that Lrp6 is required for proper somitogenesis and osteogenesis. *Development* 131:5469–5480. <https://doi.org/10.1242/dev.01405>.
- Kurosaka, H., S. Itoh, C. Morita, T. Tsujimoto, Y. Murata, T. Inubushi, and T. Yamashiro. 2022. Development of dentition: From initiation to occlusion and related diseases. *J. Oral Biosci.* 64:159–164. <https://doi.org/10.1016/j.job.2022.02.005>.
- Mittermeier, L., and D. M. Virshup. 2022. An itch for things remote: The journey of Wnts. *Curr. Top. Dev. Biol.* 150:91–128. <https://doi.org/10.1016/bs.ctdb.2022.03.007>.
- Peperkamp, N. H., S. J. Luttikholt, R. Dijkman, J. H. Vos, K. Junker, S. Greijdenanus, M. P. Roumen, E. van Garderen, N. Meertens, C. van Maanen, K. Lievaart, L. van Wuyckhuise, and W. Wouda. 2015. Ovine and bovine congenital abnormalities associated with intrauterine infection with Schmallenberg virus. *Vet. Pathol.* 52:1057–1066. <https://doi.org/10.1177/0300985814560231>.
- Sargolzaei, M. Ontario Veterinary College, University of Guelph. <https://Ovc.Uoguelph.ca/Pathobiology/People/Faculty/Mehdi-Sargolzaei> 2021. Accessed Mar. 31, 2021. Accessed.
- Sargolzaei, M., F. Schenkel, and J. Chesnais. 2011. FImpute—An efficient imputation algorithm for dairy cattle populations. *J. Dairy Sci.* 94:421.
- Schwarzenbacher, H., C. Wurmser, K. Flisikowski, L. Misurova, S. Jung, M. C. Langenmayer, A. Schnieke, G. Knubben-Schweizer, R. Fries, and H. Pausch. 2016. A frameshift mutation in GON4L is associated with proportionate dwarfism in Fleckvieh cattle. *Genet. Sel. Evol.* 48:25. <https://doi.org/10.1186/s12711-016-0207-z>.
- Shariflou, M. R., C. M. Wade, J. Kijas, R. McCulloch, P. A. Windsor, I. Tammen, and F. W. Nicholas. 2013. Brachygnathia, cardiomegaly, and renal hypoplasia syndrome (BCRHS) in Merino sheep maps to a 1.1-megabase region on ovine chromosome OAR2. *Anim. Genet.* 44:231–233. <https://doi.org/10.1111/j.1365-2052.2012.02392.x>.
- Signer-Hasler, H., M. Neuditschko, C. Koch, S. Froidevaux, C. Flury, D. Burger, T. Leeb, and S. Rieder. 2014. A chromosomal region on ECA13 is associated with maxillary prognathism in horses. *PLoS One* 9:e86607. <https://doi.org/10.1371/journal.pone.0086607>.

## Widmer et al.: A LOCUS INCREASING RISK OF BRACHYGNATHIA INFERIOR

- Stevens, J. R., G. A. Miranda-Carboni, M. A. Singer, S. M. Brugger, K. M. Lyons, and T. F. Lane. 2010. Wnt10b deficiency results in age-dependent loss of bone mass and progressive reduction of mesenchymal progenitor cells. *J. Bone Miner. Res.* 25:2138–2147. <https://doi.org/10.1002/jbmr.118>.
- VanRaden, P. M. 2008. Efficient methods to compute genomic predictions. *J. Dairy Sci.* 91:4414–4423. <https://doi.org/10.3168/jds.2007-0980>.
- Wend, P., K. Wend, S. A. Krum, and G. A. Miranda-Carboni. 2012. The role of WNT10B in physiology and disease. *Acta Physiol. (Oxf.)* 204:34–51. <https://doi.org/10.1111/j.1748-1716.2011.02296.x>.
- Woolley, S. A., S. E. Hayes, M. R. Shariflou, F. W. Nicholas, C. E. Willet, B. A. O'Rourke, and I. Tammen. 2020. Molecular basis of a new ovine model for human 3M syndrome-2. *BMC Genet.* 21:106. <https://doi.org/10.1186/s12863-020-00913-8>.

## ORCID

- Sarah Widmer  <https://orcid.org/0000-0002-0541-5630>
- Franz R. Seefried  <https://orcid.org/0000-0003-4396-2747>
- Irene M. Häfliger  <https://orcid.org/0000-0002-5648-963X>
- Heidi Signer-Hasler  <https://orcid.org/0000-0001-5193-5306>
- Christine Flury  <https://orcid.org/0000-0002-8649-5571>
- Cord Drögemüller  <https://orcid.org/0000-0001-9773-522X>