

Case Report

# Complete Response on Larotrectinib in NTRK2 Fusion-Positive Non-Small Cell Lung Cancer

Lorenz Frehner<sup>a</sup> Simon Haefliger<sup>a</sup> Ferdinando Cerciello<sup>a</sup> Tobias Grob<sup>b</sup>  
Sabine Schmid<sup>a</sup>

<sup>a</sup>Department of Medical Oncology, Inselspital, Bern University Hospital, University of Bern, Bern, Switzerland; <sup>b</sup>Institute of Tissue Medicine and Pathology, University of Bern, Bern, Switzerland

## Keywords

Targeted therapy · NTRK2 · Non-small cell lung cancer

## Abstract

In patients with non-small cell lung cancer (NSCLC) harboring a fusion of the neurotrophic receptor kinase (NTRK) gene 1 or 3, treatment with tropomyosin kinase (TRK) inhibitors have shown promising results, however so far no data on efficacy of these agents in patients with NSCLC and NTRK2 fusion are available. We present a case of a female patient with NTRK2-positive NSCLC with a complete ongoing response on therapy with larotrectinib, suggesting efficacy of first-generation TRK inhibitors also in NTRK2-positive NSCLC.

© 2023 The Author(s).  
Published by S. Karger AG, Basel

## Introduction

The introduction of targeted therapy and immunotherapy has significantly improved outcomes of patients with metastatic non-small cell lung cancer (NSCLC) [1–4]. With a better understanding of the tumor biology and identification of various genetic alterations, the field of targeted therapies has evolved rapidly with several new therapeutic options for patients with oncogene-driven NSCLC [5, 6]. In this context, NTRK mutations represent a rare oncogenic driver with a strong therapeutic potential [2, 5, 6]. The NTRK family consists of NTRK1, NTRK2, and NTRK3 and encodes for 3 transmembrane proteins TRKA, TRKB, and TRKC [7]. The tropomyosin kinase (TRK)-mediated signaling plays an important role in

Correspondence to:  
Lorenz Frehner, [lorenz.frehner@inselspital.ch](mailto:lorenz.frehner@inselspital.ch)

survival and proliferation in human nervous tissue [8]. NTRK gene fusions have been reported to be rare oncogenic drivers in different cancer types, identified in about 0.3% of all solid tumors and in about 0.1–1% of NSCLC [9–11]. By ligand-independent activation of the kinase function, TRK fusion proteins promote downstream signaling such as the MAPK and PI3K pathways leading to cell proliferation, differentiation, and survival [7, 10, 12].

Data from pooled analyses of phase 1/2 trials have led to the histology-agnostic approval of the two TRK inhibitors larotrectinib [13, 14] and entrectinib [15] in patients with tumors harboring NTRK fusions. In both analyses, a total of 36 NSCLC patients harboring NTRK1 and 3 fusions were included with documented treatment response (26 treated with larotrectinib and 10 treated with entrectinib), however none of these patients harbored a NTRK2 fusion [16]. In our case report, we present a patient with NTRK2 fusion-positive NSCLC with an ongoing complete response (CR) after treatment with larotrectinib.

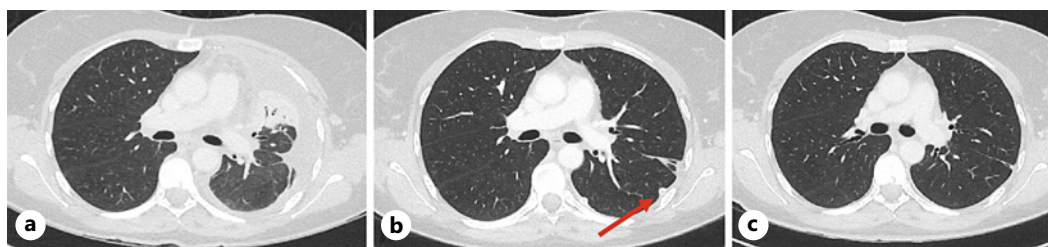
### Case Presentation

A 51-year-old female never-smoker patient presented with progressive shortness of breath and new left-sided pleural effusion in September 2022 (shown in Fig. 1). Cytological examination of the pleural effusion showed TTF-1-positive adenocarcinoma cells; however, no pulmonary primary tumor or other distant metastases could be identified by computed tomography scan and MRI of the brain (clinical staging cT0, cN0, cM1a). Next-generation sequencing of the tumor cells (TSO500 DNA and RNA) revealed a SQSTM1(exon 4)-NTRK2(exon 16) in-frame fusion (NM 003900, NM 006180). No additional targetable alterations were identified (shown in Table 1) and immunohistochemical staining of tumor cells for PD-L1 was 15%.

A talc pleurodesis was performed and pleural drainage was set. In October 2022, first-line therapy with larotrectinib 200 mg daily orally was initiated. After 9 weeks of therapy, computed tomography scan showed CR with no evidence of the pleural effusion or any other tumor manifestation. After 10 weeks of treatment, the pleural drain could be removed due to minimal flow rate (1 mL per week). From week 9 to week 18, therapy had to be interrupted due to a grade 3 elevation of transaminases (ALT > AST). The serum bilirubin level and a coagulation test were normal. Hepatopathy screening revealed no evidence of viral or autoimmune etiology with signs of mild hepatic steatosis on ultrasound and normal FibroScan. After a 2-month treatment break, recovery to grade 1 hepatitis was observed. Re-exposure to larotrectinib at 50% dosage at week 18 resulted in a recurrence of grade 3 hepatitis within 9 days. As a result, the therapy had to be interrupted again (shown in Fig. 2) and even after renewed start with 20% of dose, a consecutive ALT increase occurred; therefore, treatment was permanently discontinued and a trial of treatment with entrectinib was instead initiated. The CARE Checklist has been completed by the authors for this case report, attached as online supplementary material (for all online suppl. material, see <https://doi.org/10.1159/000533572>).

### Discussion

Results of early phase 1/2 trials including patients with different cancer types harboring NTRK1, NTRK2, or NTRK3 gene fusions have led to the histology-agnostic approval of the two oral TRK inhibitors larotrectinib and entrectinib [13–15]. In our case, we describe ongoing complete remission in a patient with NSCLC harboring a NTRK2 fusion treated with larotrectinib. So far, no data on treatment with NTRK inhibitors in patients with NTRK2-positive NSCLC have been reported, as patients included in the respective trials with NSCLC all had either NTRK1 or NTRK3 fusions.



**Fig. 1.** Radiological response to treatment with larotrectinib. **a** Pretherapeutic CT image demonstrating pleural effusion left. **b** CT scan shows CR after 8 weeks with pleural drainage in situ (red arrow). **c** CT scan shows persistent CR after 14 weeks. CT, computed tomography.

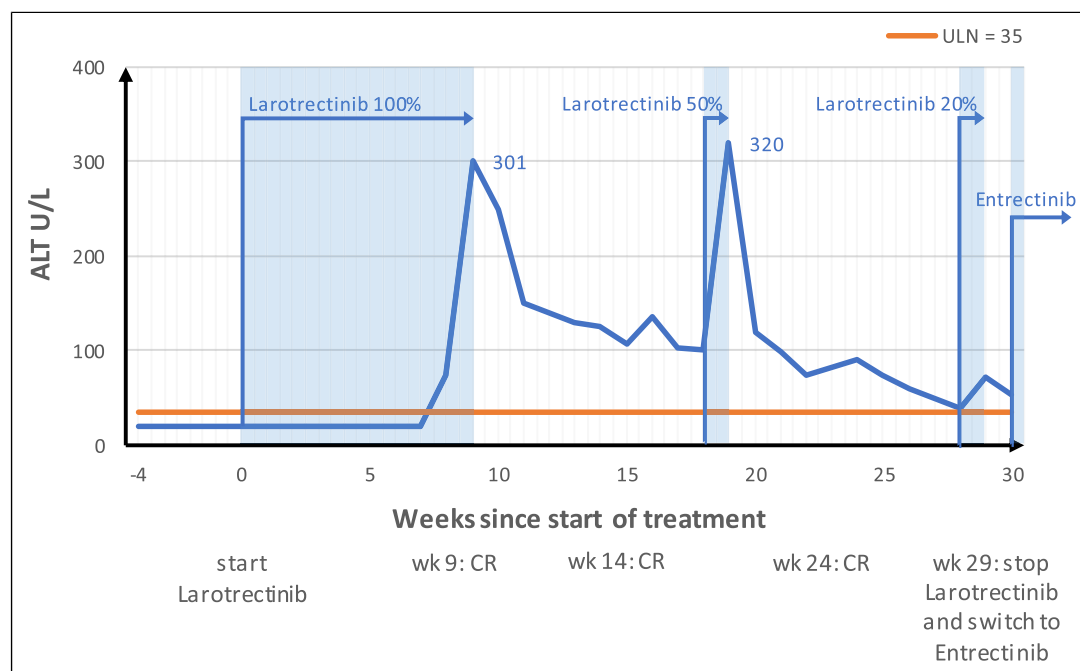
An interim analysis of three phase I/II trials exploring the activity of larotrectinib in the first 55 pediatric and adult patients with different cancer types with NTRK1, NTRK2, or NTRK3 fusions including 4 patients with NSCLC showed an overall response rate (ORR) of 75% (95% CI 61–85%) including 13% with CR [13]. In this overall analysis, only 4 patients with NTRK2 fusions were included, none with NSCLC histology. Comparable results were shown with entrectinib in the pooled analyses of three phase 1/2 trials including a total of 54 NTRK-positive solid tumor patients (10 with NSCLC). Again, only 1 patient with NTRK2 fusion was included [15]. More recently, findings from an interim analysis of two ongoing phase 1/2 trials confirmed the efficacy of larotrectinib in 26 patients with lung cancer. Seventeen out of 23 evaluable patients had a partial response and 2 patients had a CR with an ORR of 83% (95% CI, 61–95%); median duration of response was not reached [16]. With a median follow-up of 14.6 months, median progression-free survival was not reached. Whereas 21 patients with a NTRK1 gene fusion and 5 patients with a NTRK3 gene fusion have been included, no patients harboring a NTRK2 fusion were included.

The lack of NTRK2 fusion in previous studies reflects the reported distribution of NTRK fusions in NSCLC, with NTRK1 and NTRK3 occurring more frequently than NTRK2 [11, 17]. A recent review reported a prevalence of 0.07–3.3% for NTRK1, 0.02% for NTRK2, and 0.08% for NTRK3 in patients with NSCLC [17]; similarly, NTRK1 and NTRK3 fusions are more common than NTRK2 fusions in the majority of other tumor entities [11, 12, 17, 18]. In contrast, NTRK2 fusions are significantly more common than NTRK1 and NTRK3 fusions in NTRK-positive CNS tumors [12, 19, 20]. In a study by Perreault et al. [20], 38 patients with an NTRK+ CNS tumor (mostly gliomas) were treated with larotrectinib, with 28/38 patients (74%) harboring an NTRK2 fusion. With an ORR of 30% (95% CI, 16–47%) and a median progression-free survival of 16 months (95% CI, 6.7 months – not estimable), the authors confirmed the efficacy of larotrectinib in a predominantly NTRK2+ cohort [20].

In an interim analysis, the authors specified the fusion partners of 33 of these patients (24 NTRK2+). The most common fusion found in these patients was BCR-NTRK2 [20], but interestingly, the fusion SQSTM1-NTRK2 identified in our case was not included in this cohort of NTRK2+ CNS tumors and therefore no insight on efficacy of larotrectinib for this specific fusion can be extrapolated from this cohort. However, SQSTM1-NTRK2 has been documented as rare fusion in patients with NSCLC [21]. Westphalen et al. [10] identified 88 different NTRK fusion partners in a group of 889 patients with NTRK fusion. The most frequent fusion partners in this larger mixed tumor type cohort were ETV6:NTRK3 (27.2%), TMP3:NTRK1 (21.5%), and LMNA:NTRK1 (9.5%) depending on tumor location. Other fusion partners were represented only in very small numbers ( $N = 1–4$ ) and the majority of 88 fusion partners were identified only once. The fusion partner SQSTM1 reported in our case was detected in only 3 of 295 patients with known fusion partners (one each for NTRK1, NTRK2, NTRK3).

**Table 1.** NGS TSO500 DNA and RNA (hybrid capture-based next-generation sequencing assay targeting 523 tumor-associated genes and assessing tumor mutational burden and microsatellite instability)

Gene	Variant	
SQSTM1-NTRK2	SQSTM1(exon 4)-NTRK2(exon 16)	397 reads
TP53	p.R248Q (c.743G>A)	6.0% VAF
NFE2L2	p.E79Q (c.235G>C)	7.1% VAF
NOTCH3	p.N778K (c.2334C>A)	44.1% VAF
KDR	p.I915V (c.2743A>G)	50.4% VAF
DAXX	p.R230L (c.689G>T)	47.9% VAF
CCND3	p.S259A (c.774_775delinsTG)	52.8% VAF
ABL1	p.R764Q (c.2291G>A)	56.0% VAF



**Fig. 2.** Clinical course. CT, computed tomography; CR, complete response (CT scan); wk, week.

Interestingly, in the setting of other driver alterations such as anaplastic lymphoma kinase (ALK) fusion-positive NSCLC, the type of fusion partner has been shown to have a major impact on the development of resistance mechanisms and clinical outcome [6, 22, 23]. To date, several mechanisms of resistance have been described under therapy with 1st generation TRK inhibitors in NTRK1 and NTRK3 fusion positive cancers [17]: on-target mechanisms involving secondary mutations at the kinase domain of the TRK gene as well as off-target mechanisms involving bypass signaling [24, 25]. Second-generation TRK inhibitors such as selitrectinib, repotrectinib, and taletrectinib are currently being investigated to overcome resistance mutations acquired during treatment with first-generation TRK-TKI [17]. Due to the overall rarity of NTRK fusions, the different distribution of type of NTRK fusion across cancer types, as well as the large heterogeneity of fusion partners, prediction of treatment efficacy of TRK inhibitors such as larotrectinib in rare NTRK fusions remains a

challenge. Furthermore, mechanisms of resistance may depend on the type of fusion partner and therefore better understanding in different NTRK fusion variants will facilitate development of next-generation TRK inhibitors [21]. Collection of further fusion-specific data in clinical trials as well as description of individual cases may enhance our understanding of the biology of these rare cancers and will help us predict treatment efficacy and outcomes more accurately in specific fusion variants in the future.

In general, NTRK inhibitors are well tolerated with few CTCAE grade 3 or higher adverse events reported in previous studies [13–15]. Elevated aminotransferase levels in serum to grade 1 or 2 occur frequently but are usually well manageable by treatment interruption and dose reduction [26]. However, in our case, therapy with larotrectinib had to be interrupted several times due to recurrent grade 3 hepatitis and the fact that the patient did not tolerate even the manufacturer's lowest recommended dose of 2 times 50 mg daily. In response to the relatively small body size of our patient, we performed an off-label low-dose regimen based on the use of larotrectinib in the pediatric setting. However, even these low doses did result in subsequent ALT increase, leading to the decision to switch within the drug class to entrectinib. Even though hepatotoxicity is a typical adverse event of both drugs and known class effect, as with other TKIs such as ALK-, EGFR-, or MET inhibitor treatment, tolerability with another drug within the same drug class sometimes can be better and is therefore the preferred option before abandoning targeted therapy in oncogene-addicted NSCLC [27–31].

In conclusion, multiple targeted treatment options for patients with oncogene-addicted NSCLC have emerged leading to significant improvement in outcomes in these patients [2, 32]. To the best of our knowledge, we report the first case of effective treatment with larotrectinib in NTRK2 fusion-positive NSCLC with a CR within 8 weeks of treatment, underlining the value of targeted therapy in patients with metastatic oncogene-addicted NSCLC. Better understanding and overcoming of treatment resistance as well as implementation of targeted treatment also in earlier disease stages may further improve survival in patients with oncogene-addicted NSCLC [2, 32, 33].

### Statement of Ethics

Ethical approval is not required for this study in accordance with local guidelines. Written informed consent was obtained from the patient for publication of the details of her medical case and the accompanying images.

### Conflict of Interest Statement

Sabine Schmid – grants (institutional): AstraZeneca, Janssen, and BMS; advisory boards (institutional): MSD, Merck, BMS, AstraZeneca, and Roche; and travel support: Takeda, MSD, and Amgen. Simon Haefliger – advisory boards: AstraZeneca, Lilly, Novartis, Roche, and Takeda. Ferdinando Cerciello (institutional): PharmaMar and BMS. All other authors declare no conflicts of interest.

### Funding Sources

There was no funding for this study.

### Author Contributions

Lorenz Frehner did the conceptualization, data curation, visualization, wrote the first draft, and reviewed and edited the final manuscript. Ferdinando Cerciello, Simon Haefliger, and Tobias Grob reviewed and edited the final manuscript. Sabine Schmid did the conceptualization, wrote the first draft, and reviewed and edited the final manuscript.

### Data Availability Statement

All data generated or analyzed during this study are included in this article and its online supplementary material. Further inquiries can be directed to the corresponding author.

### References

- 1 Hendriks LE, Kerr KM, Menis J, Mok TS, Nestle U, Passaro A, et al. Non-oncogene-addicted metastatic non-small-cell lung cancer: ESMO Clinical Practice Guideline for diagnosis, treatment and follow-up. *Ann Oncol*. 2023 Jan;34(4):358–76.
- 2 Hendriks LE, Kerr KM, Menis J, Mok TS, Nestle U, Passaro A, et al. Oncogene-addicted metastatic non-small-cell lung cancer: ESMO Clinical Practice Guideline for diagnosis, treatment and follow-up. *Ann Oncol*. 2023 Jan; 34(4):339–57.
- 3 Santoni M, Rizzo A, Kucharz J, Mollica V, Rosellini M, Marchetti A, et al Complete remissions following immunotherapy or immuno-oncology combinations in cancer patients: the MOUSEION-03 meta-analysis. *Cancer Immunol Immunother*. 2023;72(6):1365–79.
- 4 Rizzo A. Identifying optimal first-line treatment for advanced non-small cell lung carcinoma with high PD-L1 expression: a matter of debate. *Br J Cancer*. 2022 Nov;127(8):1381–2.
- 5 Herrera-Juárez M, Serrano-Gómez C, Bote-de-Cabo H, Paz-Ares L. Targeted therapy for lung cancer: beyond EGFR and ALK. *Cancer*. 2023 Apr;129(12):1803–20.
- 6 Tan AC, Tan DSW. Targeted therapies for lung cancer patients with oncogenic driver molecular alterations. *J Clin Oncol*. 2022 Feb;40(6):611–25.
- 7 Amatu A, Sartore-Bianchi A, Siena S. NTRK gene fusions as novel targets of cancer therapy across multiple tumour types. *ESMO Open*. 2016 Mar;1(2):e000023.
- 8 Huang EJ, Reichardt LF. Trk receptors: roles in neuronal signal transduction. *Annu Rev Biochem*. 2003 Mar;72: 609–42.
- 9 Iannantuono GM, Riondino S, Sganga S, Rosenfeld R, Guerriero S, Carlucci M, et al. NTRK gene fusions in solid tumors and TRK inhibitors: a systematic review of case reports and case series. *J Pers Med*. 2022 Nov;12(11): 1819.
- 10 Westphalen CB, Krebs MG, Le Tourneau C, Sokol ES, Maund SL, Wilson TR, et al. Genomic context of NTRK1/2/3 fusion-positive tumours from a large real-world population. *NPJ Precis Oncol*. 2021;5(1):69.
- 11 Farago AF, Taylor MS, Doebele RC, Zhu VW, Kummar S, Spira AI, et al. Clinicopathologic features of non-small-cell lung cancer harboring an NTRK gene fusion. *JCO Precis Oncol*. 2018 Jul;2018(2):1–12.
- 12 Gatalica Z, Xiu J, Swensen J, Vranic S. Molecular characterization of cancers with NTRK gene fusions. *Mod Pathol*. 2019 Aug;32(1):147–53.
- 13 Drilon A, Laetsch TW, Kummar S, DuBois SG, Lassen UN, Demetri GD, et al. Efficacy of larotrectinib in TRK fusion-positive cancers in adults and children. *N Engl J Med*. 2018 Feb;378(8):731–9.
- 14 Hong DS, DuBois SG, Kummar S, Farago AF, Albert CM, Rohrberg KS, et al. Larotrectinib in patients with TRK fusion-positive solid tumours: a pooled analysis of three phase 1/2 clinical trials. *Lancet Oncol*. 2020 Apr; 21(4):531–40.
- 15 Doebele RC, Drilon A, Paz-Ares L, Siena S, Shaw AT, Farago AF, et al. Entrectinib in patients with advanced or metastatic NTRK fusion-positive solid tumours: integrated analysis of three phase 1-2 trials. *Lancet Oncol*. 2020 Feb;21(2):271–82.
- 16 Drilon A, Lin JJ, Kummar S, Tan DSW, Parel JD, Lassen NU, et al. Updated efficacy and safety of larotrectinib in patients with tropomyosin receptor kinase (TRK) fusion lung cancer. *JCO*. 2022;40:9024.
- 17 Liu F, Wei Y, Zhang H, Jiang J, Zhang P, Chu Q. NTRK fusion in non-small cell lung cancer: diagnosis, therapy, and TRK inhibitor resistance. *Front Oncol*. 2022 Mar 17;12:864666.
- 18 Rosen EY, Goldman DA, Hechtman JF, Benayed R, Schram AM, Cocco E, et al. TRK fusions are enriched in cancers with uncommon histologies and the absence of canonical driver mutations. *Clin Cancer Res*. 2020 Apr; 26(7):1624–32.

- 19 Doz F, van Tilburg CM, Georger B, Højgaard M, Øra I, Boni V, et al. Efficacy and safety of larotrectinib in TRK fusion-positive primary central nervous system tumors. *Neuro Oncol*. 2022;24(6):997–1007.
- 20 Perreault S, Drilon A, Lassen UN, Georger B, Nysom K, Øra I, et al. Long-term control and safety of larotrectinib in a cohort of adult and pediatric patients with tropomyosin receptor kinase (TRK) fusion primary central nervous system (CNS) tumors. *J Clin Oncol*. 2022 Jun;40(16\_Suppl):2010.
- 21 Zhao X, Kotch C, Fox E, Surrey LF, Wertheim GB, Baloch ZW, et al. NTRK fusions identified in pediatric tumors: the frequency, fusion partners, and clinical outcome. *JCO Precis Oncol*. 2021 Jan;1(5):204–14.
- 22 Früh M, Peters S. EML4-ALK variant affects ALK resistance mutations. *J Clin Oncol*. 2018 Apr 20;36(12):1257–9.
- 23 Lin JJ, Zhu VW, Yoda S, Yeap BY, Schrock AB, Dagogo-Jack I, et al. Impact of EML4-ALK variant on resistance mechanisms and clinical outcomes in ALK-positive lung cancer. *J Clin Oncol*. 2018 Apr;36(12):1199–206.
- 24 Russo M, Misale S, Wei G, Siravegna G, Crisafulli G, Lazzari L, et al. Acquired resistance to the TRK inhibitor entrectinib in colorectal cancer. *Cancer Discov*. 2016 Jan;6(1):36–44.
- 25 Cocco E, Schram AM, Kulick A, Misale S, Won HH, Yaeger R, et al. Resistance to TRK inhibition mediated by convergent MAPK pathway activation. *Nat Med*. 2019 Sep;25(9):1422–7.
- 26 [LiverTox: Clinical and research information on drug-induced liver injury](#). Bethesda (MD): National Institute of Diabetes and Digestive and Kidney Diseases; 2012. Larotrectinib. Updated 2019 Apr 15 [cited 2023 April 21]. Available from: <https://www.ncbi.nlm.nih.gov/books/NBK548088/?report=classic>.
- 27 Hashiguchi MH, Sato T, Yamamoto H, Watanabe R, Kagyo J, Domoto H, et al. Successful tepotinib challenge after capmatinib-induced interstitial lung disease in a patient with lung adenocarcinoma harboring *MET* exon 14 skipping mutation: case report. *JTO Clin Res Rep*. 2022;3(2):100271.
- 28 Makimoto G, Kawakado K, Nakanishi M, Tamura T, Kuyama S. Successful treatment with lorlatinib after the development of alectinib-induced liver damage in ALK-positive non-small-cell lung cancer: a case report. *Case Rep Oncol*. 2021 Mar;14(1):197–201.
- 29 Peng L, Xiao K, Cui J, Ye XH, Zhang YC, Mao L, et al. Successful treatment with ensartinib after alectinib-induced hyperbilirubinemia in ALK-positive NSCLC. *Onco Targets Ther*. 2021 May;14:3409–15.
- 30 Skribek M, Rounis K, Tsakonas G, Ekman S. Complications following novel therapies for non-small cell lung cancer. *J Intern Med*. 2022 June;291(6):732–54.
- 31 Ueda H, Hayashi H, Kudo K, Takeda M, Nakagawa K. Successful treatment with afatinib after gefitinib- and erlotinib-induced hepatotoxicity. *Invest New Drugs*. 2016 Aug;34(6):797–9.
- 32 Guo H, Zhang J, Qin C, Yan H, Liu T, Hu H, et al. Biomarker-targeted therapies in non-small cell lung cancer: current status and perspectives. *Cells*. 2022 Oct;11(20):3200.
- 33 Tsuboi M, Herbst RS, John T, Kato T, Majem M, Grohé C, et al. Overall survival with osimertinib in resected *EGFR*-mutated NSCLC. *N Engl J Med*. 2023 Jul;389(2):137–47.