

## A Proposal to Develop a New Classification for Pulp Chamber Anatomy

 **Hany Mohamed Aly AHMED**,<sup>1</sup>  **Ali KELEŞ**,<sup>2,3</sup>  **Thomas Gerhard WOLF**,<sup>4,5</sup>  
 **Giampiero ROSSI-FEDELE**,<sup>6</sup>  **Paul Michael Howell DUMMER**<sup>7</sup>

<sup>1</sup>Department of Restorative Dentistry, Universiti Malaya, Faculty of Dentistry, Kuala Lumpur, Malaysia

<sup>2</sup>Department of Endodontics, Ondokuz Mayıs University, Faculty of Dentistry, Samsun, Türkiye

<sup>3</sup>Department of Endodontics, Bolu Abant İzzet Baysal University, Faculty of Dentistry, Bolu, Türkiye

<sup>4</sup>Department of Restorative, Preventive and Pediatric Dentistry, University of Bern, School of Dental Medicine, Switzerland

<sup>5</sup>Department of Periodontology and Operative Dentistry, University Medical Center of the Johannes Gutenberg University Mainz, Germany

<sup>6</sup>Adelaide University, Adelaide Dental School, Adelaide, Australia

<sup>7</sup>Cardiff University, School of Dentistry, College of Biomedical and Life Sciences, Cardiff, United Kingdom

### Introduction

It is well known that the human dentition varies considerably in terms of the anatomy of roots, pulp chambers and root canals (1–5). This variation is obvious between tooth types, individuals and population groups and is influenced by age, caries, tooth surface loss, developmental defects, anomalies, trauma and a range of other conditions (2–5). The pulp chamber is defined as the portion of the pulp space within (or extending just apical) the anatomic crown of the tooth that contains the coronal pulp tissue and consists of the pulp horn(s) and body leading to the orifice(s) of the root canal(s) (6, 7). The shape, size and position of the chamber originally reflects the anatomy of the crown (8), but is particularly subject to morphological changes as a result of age and as a defensive mechanism against irritation (1, 9) (Fig. 1).

Understanding the anatomy of pulp chambers (including their position, shape and size) is important in every tooth type and in every patient. This editorial briefly reviews the main factors that have an impact on pulp chambers and sets out the need for a new classification of pulp chamber anatomy for use in research, education, and clinical practice.

### Response of the Coronal Dentine and Pulp Tissue to Irritation

The pulp and the dentine form an integrated system that is generally referred to as the den-

tine-pulp complex (10). Several factors can impact on the integrity of a tooth and pulp, for example carious lesions, trauma, and non-carious tooth surface loss such as erosion, abrasion, attrition and abfraction (10). This is in addition to the problem of cracked teeth that have incomplete fractures involving enamel and dentine, often extending to the pulpal chamber and/or periodontal tissues (11). Many of these irritants lead to tertiary dentine formation within the chamber through the action of either the pre-existing primary odontoblasts (reactionary dentine) or of newly differentiated odontoblast-like cells (reparative dentine) (10) (Fig. 2). In general terms, radiographs and other imaging techniques can reveal the amount and position of tooth tissue loss and its proximity to the pulpal chamber, as well as the shape, position and dimensions of the pulp chamber. These factors must be taken into account to when determining the condition of the pulp and whether exposure of the pulp during tooth preparation is likely to occur and alert the clinician of the potential risks (12).

Caries extending deeply towards the pulp chamber is common (13), and can result in loss of substantial amounts of tooth tissue, pulpitis and apical periodontitis if not managed correctly (13–15). Removal of caries and the concomitant cavity preparation of the tooth (if needed) must be carried out with a deep understanding of the anatomy of the pulp chamber in

#### Please cite this article as:

Ahmed HMA, Keleş A, Wolf TG, Rossi-Fedele G, Dummer PMH. A Proposal to Develop a New Classification for Pulp Chamber Anatomy. *Eur Endod J*

#### Address for correspondence:

Hany Mohamed Aly Ahmed  
 Department of Restorative  
 Dentistry, Universiti Malaya,  
 Faculty of Dentistry, Kuala Lumpur,  
 Malaysia  
 E-mail:  
 hanyendodontist@um.edu.my

Published online: November 22, 2023  
 DOI 10.14744/eej.2023.82713

This work is licensed under  
 a Creative Commons  
 Attribution-NonCommercial  
 4.0 International License.



order to avoid iatrogenic exposure of the pulp and/or unnecessary exposure during stepwise and selective caries removal (12), both of which could compromise the integrity and health of the pulp (12). A pink discolouration observed through dentine, usually indicates that less than 0.5 mm of remaining dentine is covering the pulp with small pulpal exposures potentially being present, but not visible to the naked eye or even with a microscope (10). The dentine around the pulp horns is more permeable compared to other areas of coronal dentine (16), which requires an understanding of the structure of dentine, pulp horn morphology and their location in every tooth type. Additionally, it is important for the operator to understand the "reaction" of the dentine and coronal pulp tissue to various "restorative" procedures such as the formation of tertiary dentine (dentine bridge), as well as the development of diffuse calcifications and pulp chamber obliteration which can often be observed on intra-oral radiographs and on images produced by other imaging techniques (17, 18).

It is important to consider the thickness of enamel and dentine and their relation to the proximity of the pulp chamber in each region of a tooth (12). It is known that secondary dentine is deposited preferentially within the pulp horns and on the pulp chamber roof and floor, which over time creates a narrow chamber in the occluso-gingival direction (12). Therefore, caries removal and cavity preparation on teeth of younger patients has the potential to result in a significantly greater chance of pulp exposure than on those of an older patient (12).

It is known that the shape of the pulpal chamber roof follows the morphology of the tooth cusps and that the use of bitewing radiographs provides an estimate of the pulp chamber size in the mesio-distal and occluso-gingival directions. Therefore, when a cavity preparation is performed to create a flat cavity floor for some restorative materials (such as amalgam), failure to follow the external contour of the crown will result in areas where pulp tissue is closer to the cavity wall and floor, resulting in a greater risk of an acute pulp reaction and even accidental exposure (12). Mandibular first premolars, for example, have a large discrepancy in the size of the buccal and lingual cusps, resulting in a much larger buccal pulp horn than the lingual one. Therefore, the classic shape of the cavity must be modified to avoid accidental exposure of the coronal pulpal tissue (12).

## Endodontics

### **1. Understanding anatomy of normal teeth, anomalies and those with disorders of dentine**

The pulp chamber of each tooth type has characteristic anatomical features that must be understood before commencing root canal treatment (10). Anatomical variations of the pulp chamber (shape, size and floor) also occur in teeth with dental anomalies such as dens invaginatus, dens evaginatus, C-shaped canals, taurodontism, tooth fusion and gemination (9, 19–22). This is in addition to characteristic features for the pulp chamber of teeth with dentine disorders such as dentine dysplasia (23).

### **2. Pulp sensibility testing**

The overall size of the pulp chamber and the thickness of the overlying dentine and enamel has an impact on pulp testing; when the chamber is reduced in size as a consequence of reparative dentine deposition, the stimulus and response will be affected (24, 25) (Fig. 3). Calcified pulp chambers are likely to have a delayed response in teeth compared to those with larger pulp chambers that usually have prominent pulp horns (24, 25). The pulp horns correspond to the incisal edge or major cusps in anterior and posterior teeth, respectively (9). The location of pulp horns will impact on the location where pulp sensibility tests (thermal and electric pulp testing) should be applied (24, 26–28).

### **3. Access cavity preparation**

Accessing the pulp chamber space is the first step in root canal treatment. Inability to appreciate anatomical variations of the pulp chamber can result in a number of consequences in posterior teeth, such as the removal of excessive amounts of dentine (especially when the floor of the pulp chamber at the root canal orifices is calcified), perforation of the floor of the chamber and the inability to locate canal orifices. If the pulp chamber space is large, the operator will have the tactile feedback of the bur entering (dropping into) the pulp chamber during access cavity preparation (29) (Figs. 3a, 4a, b). However, if the pulp chamber is calcified, the operator may not have the necessary tactile feedback to detect when exposure of the pulp chamber is achieved (29) (Figs. 3b, 4c, 4d). In anterior teeth, there is a risk of inappropriate alignment of access cavities leading to gouging and even perforation of the root on its labial aspect (10).

### **4. Tooth discolouration**

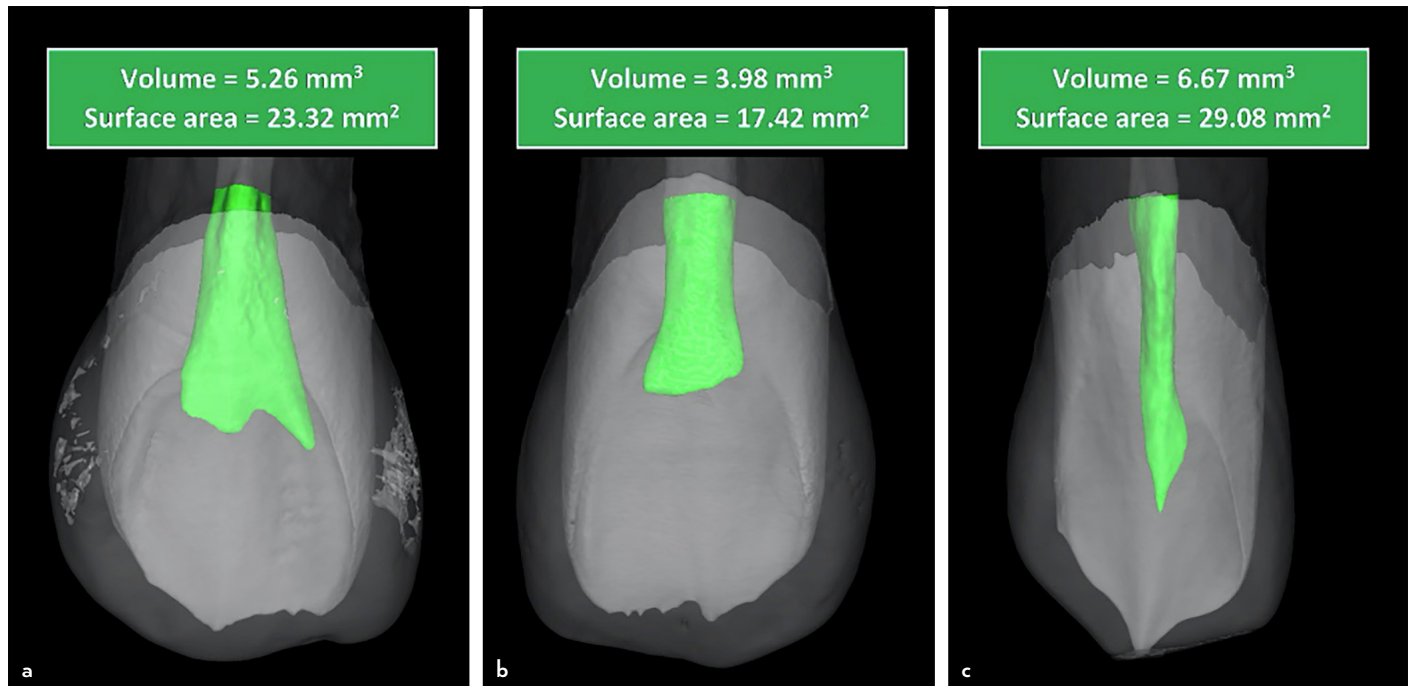
Apart from pulp necrosis, calcifications and resorption defects, tooth discolouration can occur when remnants of pulp tissue and/or root canal filling materials in root canal treated teeth are left in the chamber and pulp horns, which often occurs when the extension of access cavities is inadequate (30, 31). Therefore, successful detection and removal of overhanging pulp chamber roofs will facilitate complete removal of pulp tissue (30, 31).

### **5. Minimal invasive endodontic procedures**

There has been an increased interest in minimally invasive endodontic procedures in recent years (32, 33). Carrying out pulp capping, pulpotomy procedures and conservative access cavity preparations require meticulous understanding of pulp chamber anatomy in all teeth (10). This is in addition to the application of guided access cavity preparation techniques for locating obliterated root canals through guided drilling into calcified pulp chambers to preserve tooth tissue compared to conventional manual access cavity preparation that often leads to excessive and unnecessary loss of tooth tissue (34–36).

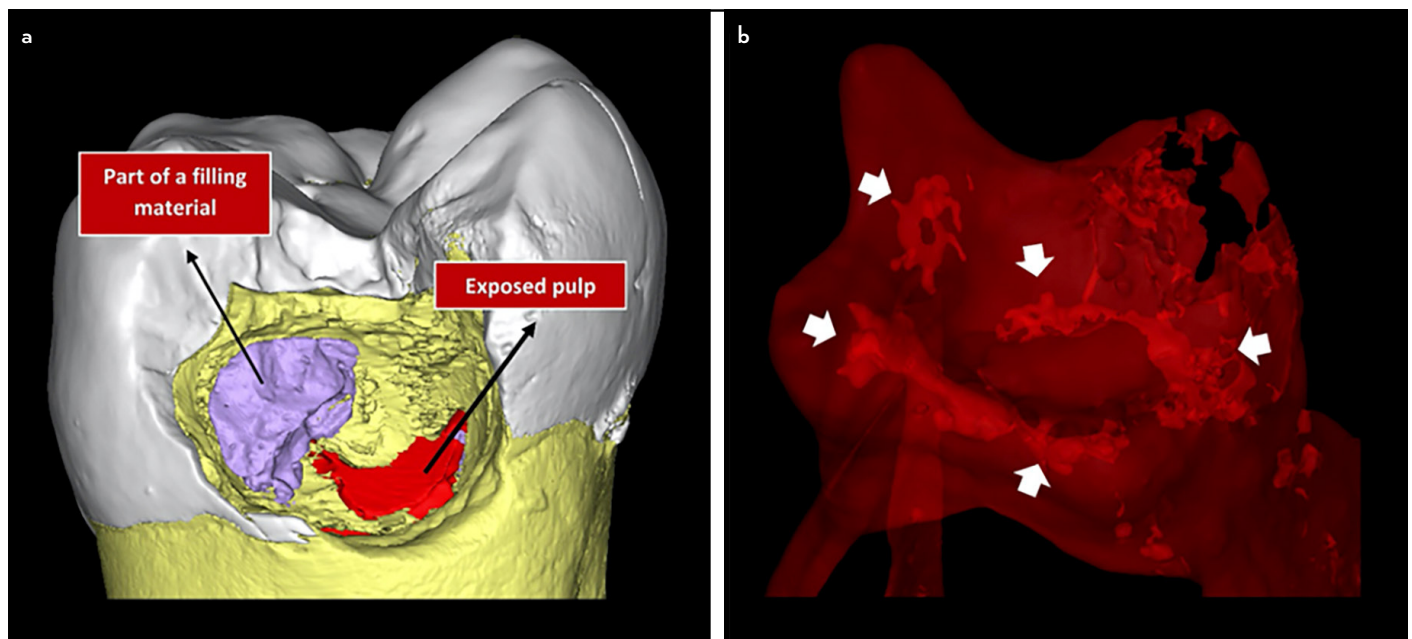
### **Periodontal Disease**

The pulp and periodontal tissues have a range of communicating pathways including the apical foramen, accessory canals and others which allow the propagation of microbial irritants between the two tissue types (37). A recent micro-computed tomography (micro-CT) study reported the presence of patent chamber canals in 2.8% and 0.3% of mandibular and maxillary



**Figure 1.** Micro-CT reconstructed images showing morphological and volumetric variations in the pulp chambers of (a, b) maxillary incisors and (c) canine tooth (from left to right). The level of the pulp chamber floor was defined at the level of the cemento-enamel junction

Micro-CT: Micro-computed tomography



**Figure 2.** Micro-CT reconstructed images showing pulp chamber calcifications in a previously restored carious mandibular second molar tooth (a). (b) 3D reconstructed image of the pulp chamber showing diffuse calcifications in the pulp chamber (white arrows)

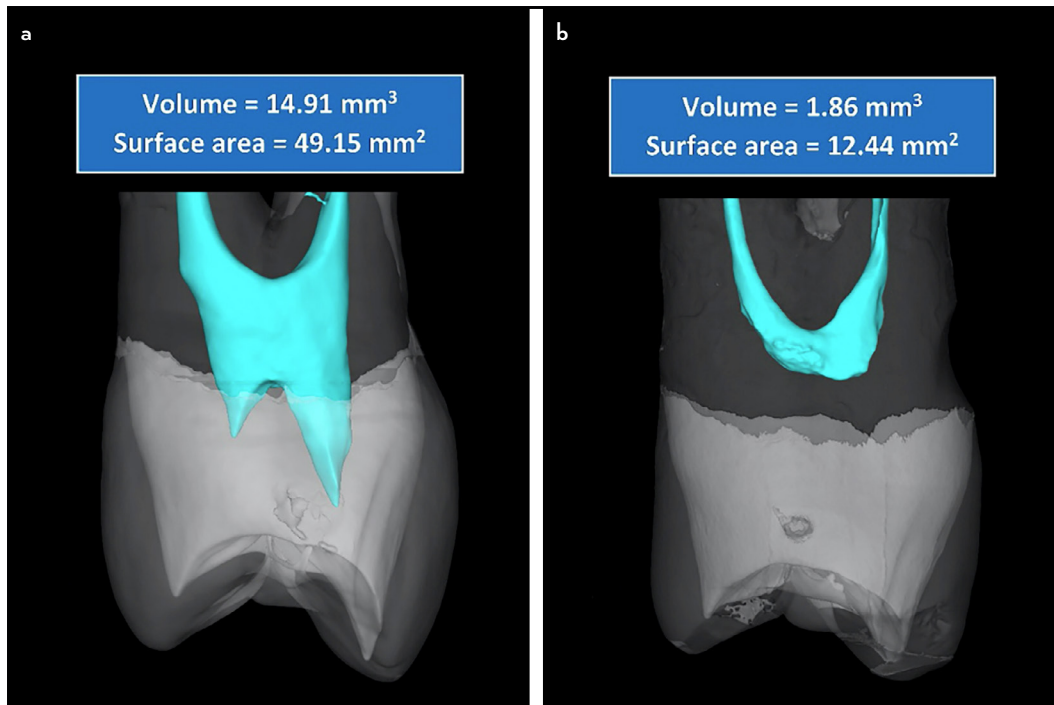
molars (38); respectively – such a rare minor anatomy can be identified in clinical settings (39). A cone beam computed tomography (CBCT) study reported that periodontal disease is associated with a significant reduction in pulp volume (chamber and canals) (40). A recent report documented a wide range of inflammatory responses of the pulp tissues (including the coronal pulp tissue in the chamber) to microbial irritation from periodontal disease (41), consistent with another study which found that the pulpal chamber and parts of the root canal were filled with

calcified masses as a response to moderate/severe periodontal disease (42). The more severe the periodontitis, the greater degree of pulp pathosis was found (42).

**Dental Trauma**

Traumatic injuries to teeth vary in extent and severity (43, 44). Complicated crown fractures involve the pulp chamber as well as a substantial volume of tooth tissue. Knowledge of the anatomy of pulp chambers in mature and immature teeth is





**Figure 3.** Micro-CT reconstructed images showing morphological variations in the pulp space anatomy including presence (a) and absence (b) of pulp horns in maxillary premolars

important when managing such injuries (43). Other pathological changes can occur in the pulp chamber following trauma such as internal inflammatory root resorption which is characterised by the radiographic appearance of an oval-shaped enlargement exhibiting a characteristic clinical appearance of a pinkish hue that is classically described as a pink tooth (45); this is in addition to coronal calcification (46).

#### Prosthodontic Procedures

Understanding pulp chamber anatomy is also important before crown preparation of teeth with vital pulps (47). One study reported consistent over-preparation along the labio-proximal line angle of maxillary central incisors with a tendency to leave considerably less than 2 mm of residual dentine protecting the pulp, due to the proximity of the pulp horns in this region (47). Extra-coronal tooth preparation can also lead to iatrogenic pulp exposure if the operator fails to recognise the alignment of the tooth in the arch and the size and position of the chamber (12); this undesirable incident has been reported among dental students and practitioners (48, 49).

On some occasions, the pulp chamber space within root canal treated teeth can be used for retention of restorations (such as amalgam cores), especially when the dimensions of the pulpal chamber are adequate and the surrounding dentine has sufficient bulk and strength, as that will provide a suitable area of dentine for mechanical retention of the restoration whilst also providing the necessary load resistance to the tooth (12). Endo-crowns are another treatment option that are formed from a monoblock containing the crown that is integrated into the section that fills the pulp chamber space, and possibly the root canal entrances (50). Therefore, the width, cross-sectional shape and depth of the pulp chamber are important features to consider for these restorations (51).

#### Primary Dentition

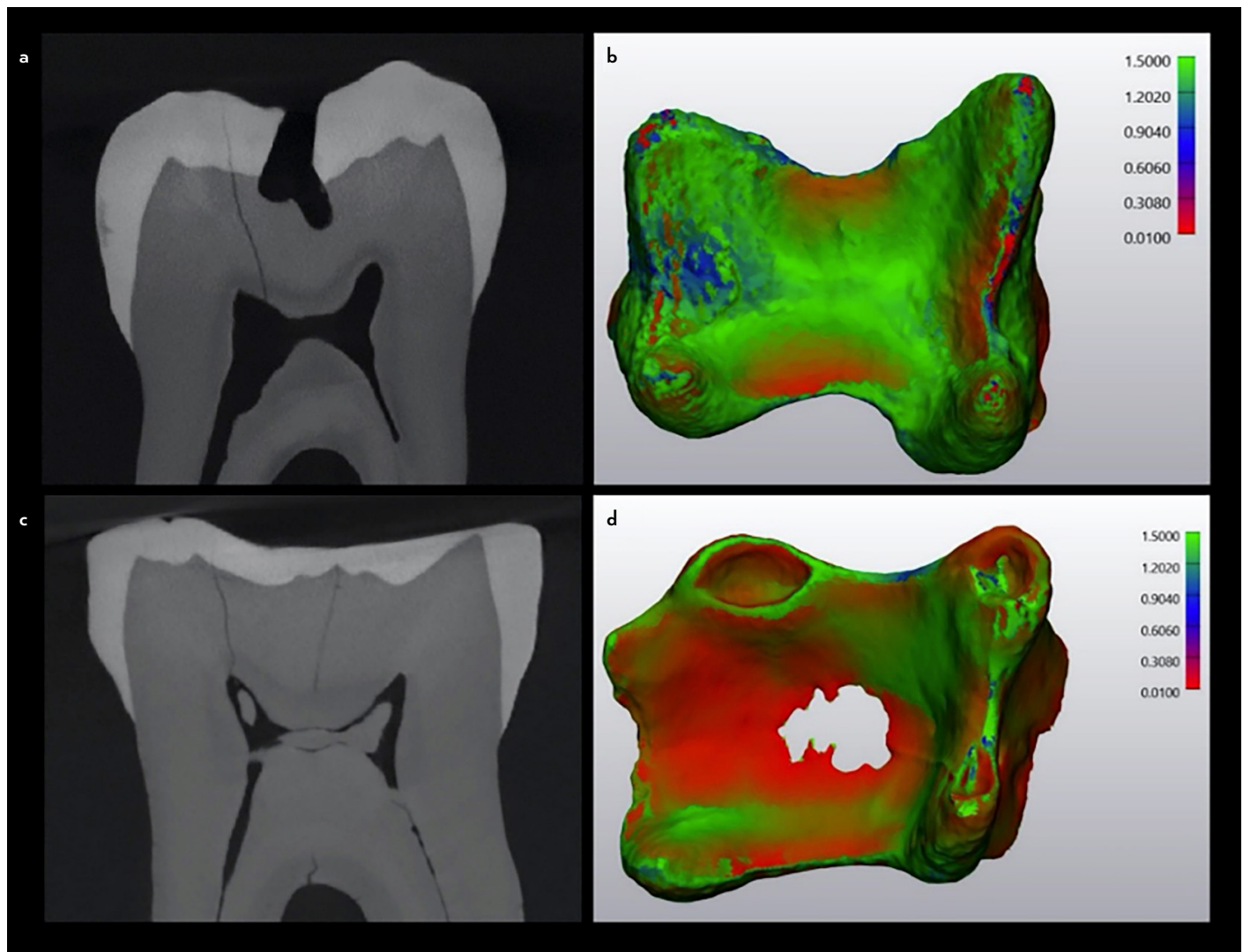
The anatomy of pulp chambers in the primary dentition varies from the permanent counterparts (52). A wide range of variations in the morphology, size of the pulp chamber in relation to the crown of primary molars, location and number of pulp horns as well as the pulp chamber floor have been reported (10). These anatomical features require careful attention during caries excavation and other restorative procedures to prevent pulp exposure (53), considering the fact that the size of the pulp chamber affects the thickness of the external tooth structure, especially in first molars and the mesio-buccal cusp of maxillary second molars (53). This is in addition to access cavity preparations during root canal treatment of primary molars, which also requires special consideration, to prevent furcal perforations (54, 55).

#### Pulp Chamber Anatomy in Contemporary Research Methods

The volume of pulp chambers and root canals (56, 57) and their size in 2-dimensions (58, 59), have been used for standardisation of experimental samples in several studies related to conservative access preparations (such as debridement of the pulp chamber, root canal detection, instrumentation efficacy and fracture resistance). Using such measurements for sample selection would reduce the potential confounding factors related to the variation in pulp chamber anatomy in the same tooth type.

#### Justification for a New System to Classify Pulp Chamber Anatomy

Over the years, the application of a wide range of research methods on various teeth and population groups together with technological advances in imaging devices, such as CBCT and micro-CT, has resulted in an improved understanding of the complexities of tooth anatomy. This paved the way for the introduction of several systems to define and classify root and canal



**Figure 4.** Micro-CT reconstructed images showing the thickness of the pulp chamber space in mandibular molars – (a, b) normal sized pulp chamber, (c, d) pulp chamber with calcifications and reduced thickness. Red areas refer to parts of the pulp chamber with reduced thickness

morphology (60–63). For example, Ahmed et al. (64) introduced a classification system for root and canal morphology that has also been supplemented with complementary codes for accessory canals (65), and dental anomalies (66).

The current classification systems and guidelines characterising the anatomical features related to pulp chamber anatomy have focused mainly on the morphological features of the pulp chamber “floor” in the posterior dentition (20, 67–69). Obviously, such classifications are important for the clinician to understand the anatomical variations of the floor in different teeth and the most likely locations of the root canal orifices using the ‘roadmap’ on the pulp chamber floor as well as minimising procedural errors such as perforations and missed canals. However, based on an electronic search in Scopus and PubMed search engines, conducted in August 2023, using following keywords – “Pulp” AND “Chamber” AND “Anatomy” OR “Morphology” AND “Classification”, no system has been created to classify other important anatomical landmarks of the pulp chamber which have relevance in clinical practice, research and education such as pulp horns and body in terms of position, shape and size.

### General Concepts and Steps for Developing a Classification System for Pulp Chamber Anatomy

The root and canal coding system introduced by Ahmed et al. (64) was based on a critical analysis of the literature and the identification of deficiencies in previous classifications, such as the inability to define the number of roots in anterior and premolar teeth, inability to address complex canal configurations, etc. These issues have been discussed in a recent systematic review (70). However, it is obvious that the same strategy cannot be applied when attempting to classify pulp chamber anatomy because of the limited number of classifications used to characterise the anatomy of the pulp chamber (which are only related to the pulp chamber floor), and the limited literature available on the topic using high resolution imaging devices (such as micro-CT and CBCT). Therefore, a proposal to develop a new classification of pulp chambers will be carried out following a detailed analysis of pulp chamber anatomy in different tooth types using high resolution imaging techniques. The project team will identify the anatomical landmarks to be included in the system, which will be explained and elaborated in future publications.

## REFERENCES

1. Vertucci FJ. Root canal morphology and its relationship to endodontic procedures. *Endod Topics* 2005; 10(1):3–29.
2. Deutsch AS, Musikant BL, Gu S, Isidro M. Morphological measurements of anatomic landmarks in pulp chambers of human maxillary furcated bicuspids. *J Endod* 2005; 31(8):570–3.
3. Versiani MA, Ordinola-Zapata R, Keleş A, Alcin H, Bramante CM, Pécora JD, et al. Middle mesial canals in mandibular first molars: a micro-CT study in different populations. *Arch Oral Biol* 2016; 61:130–7.
4. Martins JNR, Marques D, Mata A, Caramés J. Root and root canal morphology of the permanent dentition in a Caucasian population: a cone-beam computed tomography study. *Int Endod J* 2017; 50(11):1013–26.
5. Ahmed HMA. A critical analysis of laboratory and clinical research methods to study root and canal anatomy. *Int Endod J* 2022; 55(Suppl 2):229–80.
6. Ahmed HMA, Ibrahim N, Mohamad NS, Nambiar P, Muhammad RF, Yusoff M, et al. Application of a new system for classifying root and canal anatomy in studies involving micro-computed tomography and cone beam computed tomography: Explanation and elaboration. *Int Endod J* 2021; 54(7):1056–82.
7. American Association of Endodontists (AAE). Glossary of Endodontic Terms. Available at: <https://www.aae.org/specialty/download/glossary-of-endodontic-terms/>. Accessed Sep 26, 2023.
8. Nelson SJ, Ash MM Jr. *Wheeler's Dental Anatomy, Physiology, and Occlusion*. 9<sup>th</sup> ed. St. Louis: Saunders Elsevier; 2010. p. 209–55.
9. Ahmed HMA, Wolf TG, Rossi-Fedele G, Dummer PMH. The study and relevance of pulp chamber anatomy in endodontics – a comprehensive review. *Eur Endod J* 2023 Nov 22. doi: 10.14744/eej.2023.76598. [Epub ahead of print].
10. de Mello Torres AC, Gomes APM, Kubo CH, Torres CRG. Protection of the Dentin-Pulp Complex. In: Torres CRG, ed. *Modern Operative Dentistry: Principles for Clinical Practice*. New York: Springer; 2020. p. 289–333.
11. Ricucci D, Siqueira JF Jr, Loghin S, Berman LH. The cracked tooth: histopathologic and histobacteriologic aspects. *J Endod* 2015; 41(3):343–52.
12. Torres CRG, Schwendicke F. General Principles of Tooth Preparation and Carious Tissue Removal. In: Torres CRG, ed. *Modern Operative Dentistry: Principles for Clinical Practice*. New York: Springer; 2020. p. 183–221.
13. European Society of Endodontology (ESE) developed by: Duncan HF, Galler KM, Tomson PL, Simon S, El-Karim I, Kundzina R, et al. European Society of Endodontology position statement: management of deep caries and the exposed pulp. *Int Endod J* 2019; 52(7):923–34.
14. Abbott PV. Pulp, root canal, and periradicular conditions. In: Ahmed HMA, Dummer PMH, eds. *Endodontic Advances and Evidence-Based Clinical Guidelines*. New Jersey: John Wiley & Sons Ltd; 2022.
15. Abbott PV. Classification, diagnosis and clinical manifestations of apical periodontitis. *Endod Topics* 2004; 8(1):36–54.
16. Pashley DH. Clinical considerations of microleakage. *J Endod* 1990; 16(2):70–7.
17. Katge FA, Patil DP. Comparative analysis of 2 calcium silicate-based cements (biocentine and mineral trioxide aggregate) as direct pulp-capping agent in young permanent molars: a split mouth study. *J Endod* 2017; 43(4):507–13.
18. Linu S, Lekshmi MS, Varunkumar VS, Sam Joseph VG. Treatment outcome following direct pulp capping using bioceramic materials in mature permanent teeth with carious exposure: a pilot retrospective study. *J Endod* 2017; 43(10):1635–9.
19. Bishop K, Alani A. *Dens invaginatus*. Part 2: clinical, radiographic features and management options. *Int Endod J* 2008; 41(12):1137–54.
20. Min Y, Fan B, Cheung GS, Gutmann JL, Fan M. C-shaped canal system in mandibular second molars Part III: The morphology of the pulp chamber floor. *J Endod* 2006; 32(12):1155–9.
21. Aydin H, Mobaraki S. Comparison of root and canal anatomy of taurodont and normal molar teeth: a retrospective cone-beam computed tomography study. *Arch Oral Biol* 2021; 130:105242.
22. Tsesis I, Steinbock N, Rosenberg E, Kaufman AY. Endodontic treatment of developmental anomalies in posterior teeth: treatment of geminated/fused teeth—report of two cases. *Int Endod J* 2003; 36(5):372–9.
23. Barron MJ, McDonnell ST, Mackie I, Dixon MJ. Hereditary dentine disorders: dentinogenesis imperfecta and dentine dysplasia. *Orphanet J Rare Dis* 2008; 3:31.
24. Jafarzadeh H, Abbott PV. Review of pulp sensibility tests. Part I: general information and thermal tests. *Int Endod J* 2010; 43(9):738–62.
25. Reynolds RL. The determination of pulp vitality by means of thermal and electrical stimuli. *Oral Surg Oral Med Oral Pathol* 1966; 22:231–40.
26. Peters DD, Baumgartner JC, Lorton L. Adult pulpal diagnosis. I. Evaluation of the positive and negative responses to cold and electrical pulp tests. *J Endod* 1994; 20(10):506–11.
27. Udoye CI, Jafarzadeh H, Okechi UC, Aguwa EN. Appropriate electrode placement site for electric pulp testing of anterior teeth in Nigerian adults: a clinical study. *J Oral Sci* 2010; 52(2):287–92.
28. Filippatos CG, Tsatsoulis IN, Floratos S, Kontakiotis EG. The variability of electric pulp response threshold in premolars: a clinical study. *J Endod* 2012; 38(2):144–7.
29. Peters OA. Accessing root canal systems: knowledge base and clinical techniques. *ENDO (Lond Engl)* 2008; 2(2):87–104.
30. Ahmed HMA, Krastl G, Zimmerli B, Amer M, Parashos P. Management of coronal discoloration. In: Ahmed HMA, Dummer PMH, eds. *Endodontic Advances and Evidence-Based Clinical Guidelines*. New Jersey: John Wiley & Sons Ltd; 2022.
31. Ahmed HMA, Abbott PV. Discolouration potential of endodontic procedures and materials: a review. *Int Endod J* 2012; 45(10):883–97.
32. Ballester B, Giraud T, Ahmed HMA, Nabhan MS, Bukiet F, Guivarc'h M. Current strategies for conservative endodontic access cavity preparation techniques-systematic review, meta-analysis, and decision-making protocol. *Clin Oral Investig* 2021; 25(11):6027–44.
33. Krastl G, Galler K, Dammaschke T, Schäfer E. Is pulpotomy a valid treatment option for irreversible pulpitis? *Dtsch Zahnärztl Z* 2021; 3(2):80–7.
34. Dianat O, Nosrat A, Tordik PA, Aldahmash SA, Romberg E, Price JB, et al. Accuracy and efficiency of a dynamic navigation system for locating calcified canals. *J Endod* 2020; 46(11):1719–25.
35. Chaniotis A, Ordinola-Zapata R. Present status and future directions: management of curved and calcified root canals. *Int Endod J* 2022; 55(Suppl 3):656–84.
36. Peña-Bengoa F, Valenzuela M, Flores MJ, Dufey N, Pinto KP, Silva EJNL. Effectiveness of guided endodontics in locating calcified root canals: a systematic review. *Clin Oral Investig* 2023; 27(5):2359–74.
37. Ahmed HMA. Different perspectives in understanding the pulp and periodontal intercommunications with a new proposed classification for endo-perio lesions. *ENDO (Lond Engl)* 2012; 6(2):87–104.
38. Anderegg AL, Hajdarevic D, Wolf TG. Interradicular canals in 213 mandibular and 235 maxillary molars by means of micro-computed tomographic analysis: an *ex vivo* study. *J Endod* 2022; 48(2):234–9.
39. Kuoch P, Duplan MB, Berès F, Bonte É, Couvrechel C. Clinical identification and endodontic management of furcation canals: a case series. *Braz Dent J* 2023; 34(1):132–8.
40. Terlemez A, Alan R, Gezgin O. Evaluation of the periodontal disease effect on pulp volume. *J Endod* 2018; 44(1):111–4.
41. Ricucci D, Siqueira JF Jr, Rôças IN. Pulp response to periodontal disease: novel observations help clarify the processes of tissue breakdown and infection. *J Endod* 2021; 47(5):740–54.
42. Wan L, Lu HB, Xuan DY, Yan YX, Zhang JC. Histological changes within dental pulps in teeth with moderate-to-severe chronic periodontitis. *Int Endod J* 2015; 48(1):95–102.
43. Donnelly A, Foschi F, McCabe P, Duncan HF. Pulpotomy for treatment of complicated crown fractures in permanent teeth: a systematic review. *Int Endod J* 2022; 55(4):290–311.
44. Olsburgh S, Jacoby T, Krejci I. Crown fractures in the permanent dentition: pulpal and restorative considerations. *Dent Traumatol* 2002; 18(3):103–15.
45. Patel S, Ricucci D, Durak C, Tay F. Internal root resorption: a review. *J Endod* 2010; 36(7):1107–21.
46. Jacobsen I, Kerekes K. Long-term prognosis of traumatized permanent anterior teeth showing calcifying processes in the pulp cavity. *Scand J Dent Res* 1977; 85(7):588–98.
47. Davis GR, Tayeb RA, Seymour KG, Cherukara GP. Quantification of residual dentine thickness following crown preparation. *J Dent* 2012; 40(7):571–6.
48. Raustia AM, Nääpänkangas R, Salonen AM. Complications and primary failures related to fixed metal ceramic bridge prostheses made by dental students. *J Oral Rehabil* 1998; 25(9):677–80.

49. Gümüş HÖ, Kocaağaoğlu HH, Aslan T, Albayrak H, Sağsen B. Prevalence of pulp exposures during tooth preparation for fixed prosthetics. *Euro J Prosthodontics* 2014; 2(2):48.
50. Biacchi GR, Mello B, Basting RT. The endocrown: an alternative approach for restoring extensively damaged molars. *J Esthet Restor Dent* 2013; 25(6):383–90.
51. Topkara C, Keleş A. Examining the adaptation of modified endocrowns prepared with CAD-CAM in maxillary and mandibular molars: a micro-computed tomography study. *J Prosthet Dent* 2022; 127(5):744–9.
52. Cleghorn BM, Boorberg NB, Christie WH. Primary human teeth and their root canal systems. *Endod Topics* 2010; 23:6–33.
53. Cheong J, Chiam S, King NM, Anthonappa RP. Pulp chamber analysis of primary molars using micro-computed tomography: preliminary findings. *J Clin Pediatr Dent* 2019; 43(6):382–7.
54. Bandeira AVL, Lima MDM, Lima CCB, Moura MS, Cury AADB, Moura LFAD. Topography of primary molar pulp chamber floor: a scanning electron microscopy and micro-computed tomography analysis. *Pesqui Bras Odontopediatria Clín Integr* 2021; 21:e0033.
55. Diéguez-Pérez M, Ticona-Flores JM. Three-dimensional analysis of the pulp chamber and coronal tooth of primary molars: an *in vitro* study. *Int J Environ Res Public Health* 2022; 19(15):9279.
56. Silva AA, Belladonna FG, Rover G, Lopes RT, Moreira EJJ, De-Deus G, et al. Does ultraconservative access affect the efficacy of root canal treatment and the fracture resistance of two-rooted maxillary premolars? *Int Endod J* 2020; 53(2):265–75.
57. Silva EJNL, Lima CO, Barbosa AFA, Augusto CM, Souza EM, Lopes RT, et al. Preserving dentine in minimally invasive access cavities does not strength fracture resistance of restored mandibular molars. *Int Endod J* 2021; 54(6):966–74.
58. Neelakantan P, Khan K, Hei Ng GP, Yip CY, Zhang C, Pan Cheung GS. Does the orifice-directed dentin conservation access design debride pulp chamber and mesial root canal systems of mandibular molars similar to a traditional access design? *J Endod* 2018; 44(2):274–9.
59. Rover G, Belladonna FG, Bortoluzzi EA, De-Deus G, Silva EJNL, Teixeira CS. Influence of access cavity design on root canal detection, instrumentation efficacy, and fracture resistance assessed in maxillary molars. *J Endod* 2017; 43(10):1657–62.
60. Vertucci FJ. Root canal anatomy of the human permanent teeth. *Oral Surg Oral Med Oral Pathol* 1984; 58(5):589–99.
61. Zhang Q, Chen H, Fan B, Fan W, Gutmann JL. Root and root canal morphology in maxillary second molar with fused root from a native Chinese population. *J Endod* 2014; 40(6):871–5.
62. Fan B, Cheung GS, Fan M, Gutmann JL, Bian Z. C-shaped canal system in mandibular second molars: Part I—Anatomical features. *J Endod* 2004; 30(12):899–903.
63. Briseño-Marroquín B, Paqué F, Maier K, Willershausen B, Wolf TG. Root canal morphology and configuration of 179 maxillary first molars by means of micro-computed tomography: an *ex vivo* study. *J Endod* 2015; 41(12):2008–13.
64. Ahmed HMA, Versiani MA, De-Deus G, Dummer PMH. A new system for classifying root and root canal morphology. *Int Endod J* 2017; 50(8):761–70.
65. Ahmed HMA, Dummer PMH. A new system for classifying tooth, root and canal anomalies. *Int Endod J* 2018; 51(4):389–404.
66. Ahmed HMA, Neelakantan P, Dummer PMH. A new system for classifying accessory canal morphology. *Int Endod J* 2018; 51(2):164–76.
67. Acosta Vigouroux SA, Trugeda Bosaans SA. Anatomy of the pulp chamber floor of the permanent maxillary first molar. *J Endod* 1978; 4(7):214–9.
68. Krasner P, Rankow HJ. Anatomy of the pulp-chamber floor. *J Endod* 2004; 30(1):5–16.
69. Pawar AM, Singh S. New classification for pulp chamber floor anatomy of human molars. *J Conserv Dent* 2020; 23(5):430–5.
70. Ahmed HMA, Rossi-Fedele G, Dummer PMH. Critical analysis of a new system to classify root and canal morphology - a systematic review. *Aust Endod J* 2023 Sep 8. doi: 10.1111/aej.12780. [Epub ahead of print].