

Beatrice U. Mueller · Thomas Pabst

## Cutaneous zygomycosis at catheter insertion site in AML-M4Eo

Received: 27 September 2005 / Accepted: 12 November 2005 / Published online: 4 January 2006  
© Springer-Verlag 2006

Dear Sir,

A 46-year-old male farmer presented with anaemia (63 g/l), thrombocytopenia ( $22 \times 10^9/l$ ) and leukocytosis ( $26.6 \times 10^9/l$ ; with 34% blasts). The bone marrow showed a 90% infiltration with myelomonocytic blasts and abnormal eosinophils. Molecular and cytogenetic analysis documented the pericentric inversion of chromosome 16, inv(16) (p13q22). A diagnosis of AML-M4Eo was made, and a treatment with cytarabine and idarubicin was initiated.

Eighteen days after the onset of chemotherapy, the patient developed a single necrotic lesion at his right lower arm doubling daily in size (Fig. 1, upper panel). At this time, the patient was under cefipime for 3 days. Surgical resection revealed extensive necrotic debris of the entire dermis extending to the subdermal tissue. Blood vessels were filled with inflammatory cells, and extensive angioinvasion was observed with fungal elements (Fig. 1, middle panel). A fungal-specific stain such as Gomori methenamine silver easily demonstrated the fungal elements (Fig. 1, lower panel). Further characterization identified the fungal elements to be *Mucorales* species, one of the two groups of *Zygomycetes*.

Cultures from blood, bone marrow, urine and bronchi-alveolar fluid showed no evidence of fungi. Computed tomography (CT) scan revealed no fungal infection. A

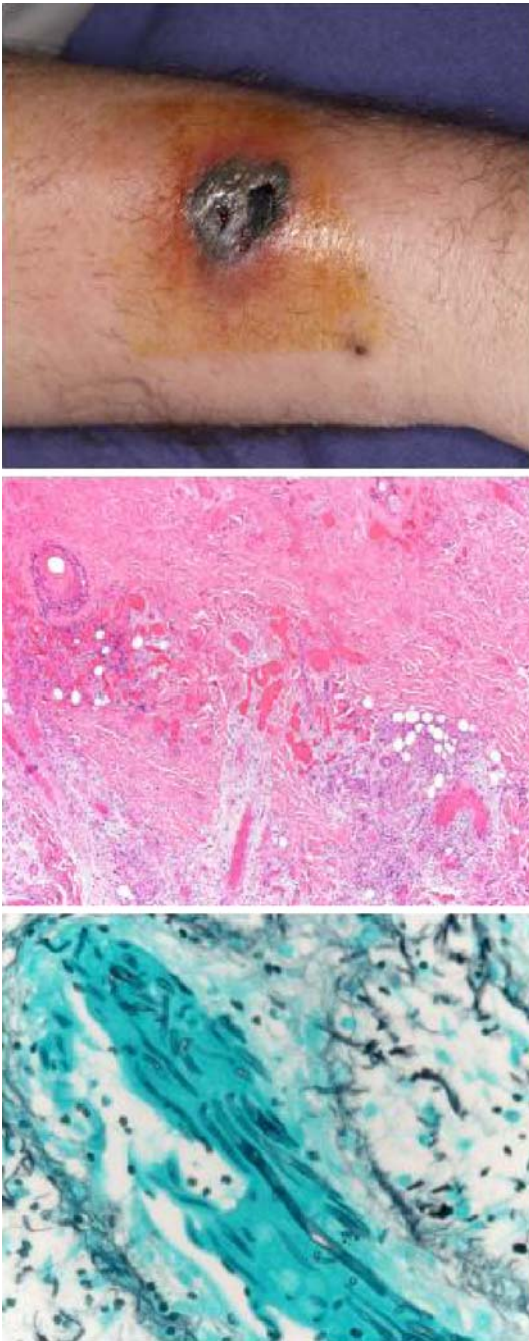
treatment with amphotericin B was started and changed to the liposomal preparation due to impaired renal function. The bone marrow showed a complete remission from leukaemia at day 19. No inv(16) transcripts were detectable after two cycles. Antifungal therapy was continued throughout chemotherapy cycles two and three, and no evidence of relapsing fungal infection was observed.

The *Zygomycetes* represent relatively uncommon isolates in the clinical laboratory. Human zygomycosis caused by the *Mucorales* generally occurs in immunocompromised hosts as opportunistic infections. Therapy for zygomycosis requires surgical intervention, antifungal therapy and medical management of the underlying condition. Interestingly, the patient presented here received a blood transfusion at the day of hospitalization, and the cutaneous zygomycosis developed at this particular catheter insertion site. The breakdown in the integrity of the cutaneous barrier, therefore, has to be assumed as the predisposing event together with the immunosuppression mediated by the outbreak of acute leukaemia and the onset of chemotherapy.

---

B. U. Mueller  
Department of Internal Medicine, University Hospital,  
3010 Bern, Switzerland

T. Pabst (✉)  
Institute of Medical Oncology, University Hospital,  
3010 Bern, Switzerland  
e-mail: thomas.pabst@insel.ch  
Tel.: +41-31-6328430  
Fax: +41-31-6324120



**Fig. 1** (*upper panel*) Single necrotic lesion at the right lower arm of the patient. (*middle panel*) Extensive necrotic debris of the entire dermis extending to the subdermal tissue. (*lower panel*) Gomori methenamine silver stain demonstrated the fungal elements