Ahead of print

Med Ultrason 2023:0, 1-9 Online first
DOI: 10.11152/mu-4302

Comments on and illustrations of the WFUMB CEUS liver guidelines: Rare malignant mesenchymal liver lesions

Ehsan Safai Zadeh[1], Nicole Schreiber[2], Christian Görg[3], Katharina Paulina Huber[4], Kathleen Möller[5], Analisa Berzigotti[6], Thomas Thomsen[7], Christian Jenssen[8], Ernst-Michael Jung[9], Adrian Lim[10], Masayuki Kitano[11], Ryo Shimizu[12], Yi Dong[13], Xin Wu Cui[14], David Srivastava[2, 15,] Christoph F Dietrich[2]

[1]Department of Biomedical Imaging and Image-Guided Therapy, Medical University of Vienna, Vienna, Austria, [2]Department Allgemeine Innere Medizin, Kliniken Hirslanden, Beau Site, Salem und Permanence, Bern, Switzerland, [3]Interdisciplinary Center of Ultrasound Diagnostics, University Hospital Giessen and Marburg, Philipps University Marburg, Baldingerstraße, Marburg, Germany, [4]Department of General Internal Medicine and Psychosomatics, University Hospital Heidelberg, Germany, [5]Medical Department I/Gastroenterology; SANA Hospital Lichtenberg, Berlin, Germany, [6]Department of Visceral Surgery and Medicine, Inselspital, Bern University Hospital, University of Bern, Switzerland, [7]Department of Internal Medicine, Westkuestenkliniken, Brunsbuettel, Germany, [8]Medical Department, Krankenhaus Maerkisch-Oderland, Strausberg. Brandenburg Institute of Clinical Medicine at Medical University Brandenburg, Germany, [9]Department of Radiology, University Medical Center Regensburg, Germany, [10]Imperial College London and Healthcare NHS Trust, London, UK, [11]Second Department of Internal Medicine, Wakayama Medical University, Japan, [12]Second Department of Internal Medicine, Wakayama Medical University, Japan, [13]Department of Ultrasound, Xinhua Hospital Affiliated to Shanghai Jiaotong University School of Medicine, Shanghai, China, [14]Department of Medical Ultrasound, Tongji Hospital, Tongji Medical College, Huazhong University of Science and Technology, Wuhan, China, [15]Inselspital, Bern, Switzerland

Abstract

The diagnosis or rare mesenchymal malignant lesions of the liver may be a challenge owing to the rarity of the disease and is usually made by histological confirmation. An ultrasound examination with, if required, color Doppler sonography and contrast-enhanced ultrasound, taking into account the clinical background of the patient, may help to focus the differential diagnosis. In this review, we describe the pathological and ultrasound features of several rare mesenchymal malignant liver lesions which include undifferentiated sarcoma of the liver, leiomyosarcoma, angiosarcoma, fibrosarcoma, liposarcoma, and epithelioid hemangioendothelioma.

Keywords: ultrasound; CEUS; diagnosis; liver; mesenchymal malignant lesion

Introduction

The World Federation for Ultrasound in Medicine and Biology (WFUMB) has published guidelines on the use of contrast-enhanced ultrasound (CEUS) for the evaluation of focal liver lesions (FLLs) [1-5]. Improved detection and characterization of common FLLs are the main topics of these guidelines. In recent years, conventional ultrasound (US) and CEUS features of uncommon FLLs have been described in detail. Current published papers with gold-standard histology cover cholangiocellular adenoma [6], peliosis [7-9], hemangioendothelioma [10,11], and hepatocellular carcinoma (HCC) in the non-cirrhotic liver. There are also several papers and reports on the uncommon and esoteric hepatic lesions. These include characterization of fibrolamellar hepato-

Received 24.07.2023 Accepted 13.09.2023
Med Ultrason
2023:0 Online first, 1-9
Corresponding author: Prof. Dr. med. Christoph F. Dietrich
Department Allgemeine Innere Medizin (DAIM)
Kliniken Beau Site, Salem und Permanence,
Hirslanden, Bern, CH-3036 Bern, Switzerland
Phone: +41 764408150
E-mail: c.f.dietrich@googlemail.com

cellular carcinoma [12,13], very small HCC (<10 mm) [14], mixed HCC and cholangiocellular carcinoma [15], nodular regenerative hyperplasia [16], sarcoma [17], inflammatory pseudotumour [18], sarcoidosis [19-22], tuberculosis [23,24], hydatid cysts [25-28], alveolar echinococcosis [26], schistosomiasis [29,30], ascariasis [31,32], fasciolosis [33], clonorchis and opisthorchis [34], toxocariasis [35], bacillary angiomatosis [36], and amyloidosis with spontaneous hemorrhage [37], as well as rare FLLs in pediatric patients [38,39] and further published comments and illustrations of the WFUMB CEUS guidelines [40-46].

Rare non-hematological malignant lesions of the liver include those of mesenchymal origin, such as undifferentiated sarcoma of the liver, leiomyosarcoma, angiosarcoma, fibrosarcoma, liposarcoma, epithelioid hemangioendothelioma and neuroendocrine tumors, hepatoblastoma and cystadenocarcinomas of the liver. In this review, we describe the pathologic and US features of rare malignant mesenchymal liver lesions. However, it must be pointed out that the majority of descriptions of tumor features on imaging modalities are based on single causalities or small case series.

Sarcomas of the liver

Primary sarcomas of the liver are rare. They represent approximately 2% of all hepatic malignancies [47,48]. Hepatic sarcomas must be differentiated from other tumor entities, especially spindle cell dedifferentiated/pleomorphic cell carcinomas, and occasionally also from amelanotic malignant melanomas or aggressive non-Hodgkin's lymphomas, as well as from inflammatory pseudotumors and monomorphic angiomyolipomas [48]. Particularly in gastrointestinal stromal tumors or even in leiomyosarcomas, liver metastases may be the first clinical manifestation of an unknown primary tumor [48]. Due to their rarity and varied morphologic appearance, sarcomas in the liver present a particular morphological challenge, especially in biopsy material [48].

Liver metastases occur comparatively rarely in sarcomas, in contrast to lung metastases. They occur mainly in intra-abdominal or visceral and in retroperitoneal sarcomas, whereas, in sarcomas of the head and neck, trunk, and extremities, pulmonary metastases are the most common [48]. In a collective of 4270 patients with soft tissue sarcomas (age range 15–91 years) treated at Memorial Sloan-Kettering Cancer Center in New York, NY, USA, over the period 1982–2000, the incidence of liver metastases was nearly 8% [48,49]. Furthermore, in the data from major reviews of surgical resection of liver metastases from 1995 to 2000, the proportion of sarcoma metastases was approximately 1% [48,50].

Undifferentiated (embryonal) sarcoma of the liver

Undifferentiated (embryonal) sarcomas of the liver are extremely rare primary liver tumors originating from undifferentiated malignant mesenchymal cells [51]. The disease represents only 0.1% of surgically excised primary liver lesions [51,52]. They mainly occur in children between 6 and 10 years of age and are the fourth most common liver tumors of childhood, with a frequency of 6–13% [48,53,54]. The disease is rarely reported in adults and accounts for less than 1% of all primary liver neoplasms [51,55]. The etiology of the disease is unclear. Mesenchymal hamartoma and undifferentiated sarcoma are described as entities of the same disease spectrum due to their same cytogenetic anomaly [51]. The clinical symptoms of the patients are non-specific. The patients may report symptoms such as abdominal pain, fever, and hepatomegaly [51]. Furthermore, the laboratory tests and the features in imaging methods are non-specific, and therefore the preoperative misdiagnosis rate is high. The final diagnosis of the disease is usually made based on histopathology and immunohistochemistry. Therefore, at the time of diagnosis, most patients are already in an advanced stage. Furthermore, the postoperative recurrence rate of the disease is high. The overall prognosis is described as poor, and the survival rate is low, at 37% [51]. The treatment of choice is radical resection of the tumor with adjuvant chemotherapy [51].

Cross-sectional imaging

On CT, the lesions are detected as cystic, solid, mixed, hypodense masses [51]. The solid components may show mild or marked enhancement in the arterial phase of the contrast-enhanced CT [51]. The enhancement may be increased in the venous phase but still less than that of the surrounding liver parenchyma [51]. On magnetic resonance imaging (MRI), lesions may show mixed intensity of high and low signals [56]. The cysts present as low signal intensity on T1-weighted images and high signal intensity on T2-weighted images [56]. Positron emission tomography (PET) can detect the uptake of 2-(fluorine-18)-fluoro-2-deoxy-D-glucose in the solid components of the tumor [56].

B-mode US and CEUS

On B-mode US, the lesions are visualized as solid with cystic components [51]. Furthermore, infiltration of the hepatic veins can be observed. On CEUS, the lesions may show inhomogeneous enhancement with a washout phenomenon in the parenchymal phase (fig 1).

Leiomyosarcoma

Primary hepatic leiomyosarcoma (PHL) is a rare malignant tumor. Between 6% and 16% of primary he-

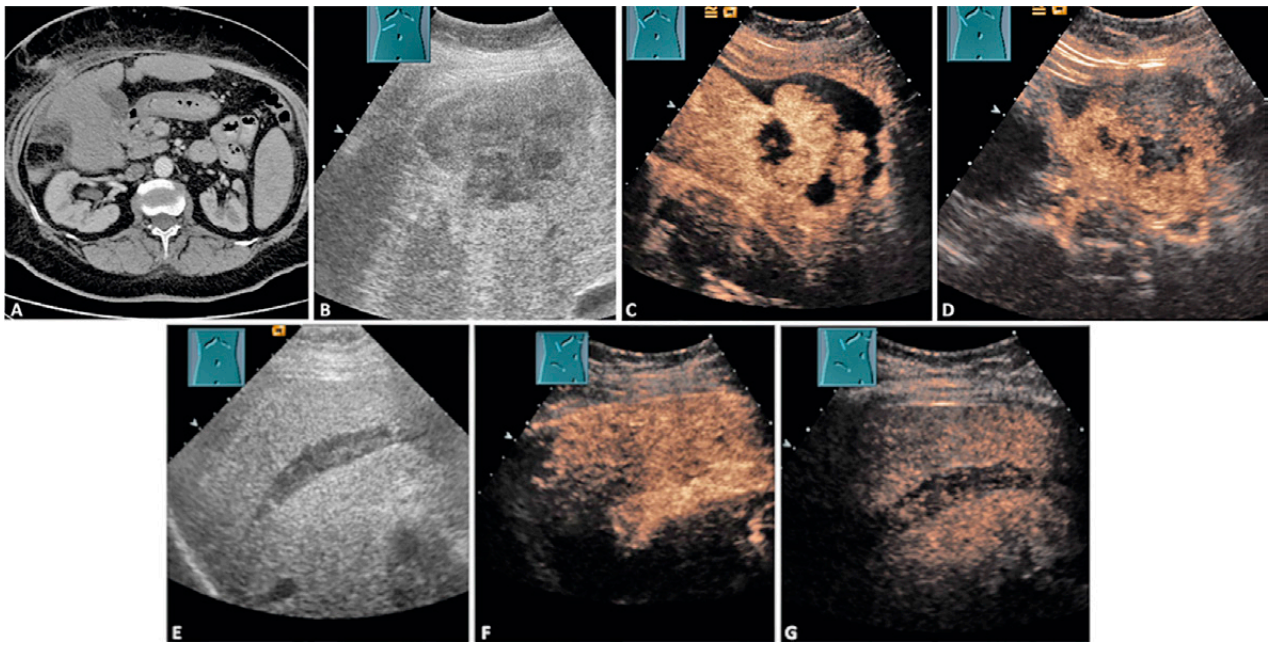

Fig 1. A 63-year-old female patient with a hypoechoic hepatic lesion as an incidental finding. Visualization of the lesion on computed tomography (courtesy of Prof. Dr. Mahnken, Department of Radiology, University Hospital Marburg) (A) and B-mode ultrasound (B). On contrast-enhanced ultrasound, the lesion shows a complex enhancement after 30 s (C), with increasing hypoenhancement after 1 min (D). On B-mode ultrasound, echogenic material is present within the lumen of a hepatic vein (E); the material shows arterial hyperenhancement after 10 s (F) and parenchymal hypoenhancement (G). An ultrasound-guided biopsy of the lesion was performed, and the diagnosis of a highly malignant undifferentiated spindle cell sarcoma (malignancy grade 3) was confirmed histologically.

patic sarcomas are PHLs [57]. PHLs originate from the smooth muscle cells of vascular structures or bile ducts [57-60]. The etiology of the disease is yet unknown. Due to the non-specific symptoms and its rarity, diagnosis of this disease is often difficult [60,61]. The only curative therapy of PHL is radical surgical resection. However, the majority of unoperated patients technically have a non-resectable condition or extra-hepatic distant metastases [57,62]. The role of chemotherapy for neoadjuvant, adjuvant, or palliative purposes in PHL, as well as in leiomyosarcomas in general, remains unclear. Furthermore, the role of liver transplantation is controversial [57]. Transarterial chemoembolization (TACE) may present a further therapy option for PHL [63]. Although the overall prognosis is poor, surgical resection of the leiomyosarcoma is associated with a 5-year survival probability of 65.2% [64]. Therefore, several authors have recommended aggressive surgical interventions, including repeated resections and debulking, even when metastases are present [65].

Cross-sectional imaging

The imaging features of PHL are non-specific and may mimic more common primary liver tumors such as HCC and cholangiocarcinoma [57]. CT may show a well-defined, heterogeneous, and hypodense lesion. Contrast-enhanced CT may reveal peripheral enhancement, or a cystic lesion with an enhanced, thickened wall [57,66]. In some case reports, multiple tortuous vessels have also been reported during the arterial phase [67].

On MRI, the lesions reveal a heterogeneous pattern and are hypointense on T1-weighted images and hyperintense on T2-weighted images without a capsule. Contrast-enhanced MRI reveals a large multilobulated, well-marginated, solid, cystic lesion from the liver with a large exophytic component in the subhepatic region that is hypointense on T1-weighted imaging and mildly hyperintense on T2-weighted imaging [68]. On contrast-enhanced MRI, the lesions show no enhancement during the arterial and portal venous phases, with evident enhancement during the 5-minute delayed phase [69]. Angiography indicates a relatively avascular mass or a vascular tumor without any shunting [65].

PET/CT demonstrates increased fluorodeoxyglucose metabolism in these lesions [69]. Finally, PHL presents as a hypovascular tumor and exhibits no tumor stains in digital subtraction angiography. However, further studies are required to confirm these findings [69].

B-mode US and CEUS

In a case report described by Lv et al, US images revealed well-defined, inhomogeneous, hypoechoic lesions with absent flow signal on CDS [69]. On CEUS, they may show nearly absent enhancement with a small rim

sign [70]. However, these were hepatic metastases of a leiomyosarcoma rather than the primary lesion.

Angiosarcoma

Primary hepatic angiosarcoma (PHA) is an extremely rare hepatic malignant neoplasm originating from endothelial and fibroblastic tissue; it is primarily composed of abundant vasculature [71,72]. The liver is the fifth most common location of angiosarcomas, which are the most common mesenchymal malignancy of the liver. PHAs account for approximately 0.1%–2% of all malignant liver tumors, with a male:female ratio of 3–4:1. In 25% of cases, there is an association with chemical carcinogens, particularly vinylchloride, Thorotrast, and arsenic [72,73].

Although surgical resection remains the only curative treatment, it is difficult to perform because 80% of the patients are at an advanced stage at diagnosis. Chemotherapy and TACE are considered palliative treatment options. Liver transplantation is not recommended owing to the high rate of recurrence and rapid progression of the tumor, with a post-transplantation survival period of less than 7 months [74]. Furthermore, PHA is associated with a poor prognosis. The prognosis of patients with hepatic angiosarcoma depends mainly on tumor histology and the possibility of performing a total tumor resection.

Cross-sectional imaging

Most of the lesions are hypoattenuating on CT, but there is a 17–27% incidence [17] of spontaneous intraperitoneal or intratumoral hemorrhage. Therefore, some tumors may appear hyperdense [75]. Furthermore, the dominant tumors usually exhibit inhomogeneous enhancement, suggesting central necrosis or hemorrhage, and delayed progressive enhancement [71]. Curvilinear calcification is found in some lesions. Angiosarcomas show areas of high signal intensity on T1-weighted images, and a markedly inhomogeneous architecture can be observed on T2-weighted images [66]. Inhomogeneous signal intensities and central septal-like progressive enhancement on MRI should raise the possibility of a hepatic angiosarcoma [76].

B-mode US and CEUS

On B-mode US, PHA may present as an inhomogeneous, hypoechoic, and blurred lesion with patchy macrocalcification [77-79]. On CEUS, the lesions may exhibit peripheral irregular arterial enhancement with some central unenhanced areas (fig 2). Peripheral enhancement declines gradually in the portal phase and is washed out entirely in the late phase [77-79].

Liposarcoma

Primary liposarcomas of the liver are rare. They were first reported in 1973 by Wolloch et al, and since then only 14 case reports of this disease have been described, to the best of our knowledge [80]. Primary liposarcoma is a malignant tumor of adipocyte differentiation. However, because the liver generally does not contain adipocytes, hepatic or circulating mesenchymal stem cells and hepatic progenitor cells have been discussed as possible origins of the adipocytic cells in primary hepatic liposarcoma [80]. The clinical features of hepatic liposarcoma are jaundice, fever, vomiting, nausea, abdominal fullness, abdominal pain, and unclear weight loss [81]. Most symptoms result from the displacement of adjacent anatomic structures. Furthermore, serum levels of liver transaminases, alkaline phosphatase, gamma-glutamyl transferase, and CA19-9 may increase [81]. Surgical resection with negative surgical margins is considered the method of choice in the treatment of primary hepatic liposarcoma. The role of adjuvant therapy has been described as unclear [81]. The use of radiotherapy is possible; however, as the liver can tolerate only a limited dose of radiation, it may be harmful and dangerous [81]. The 5-year survival rate of patients after curative surgical resection or radiotherapy is approximately 50% [81]. In general, the prognosis without treatment is described as poor.

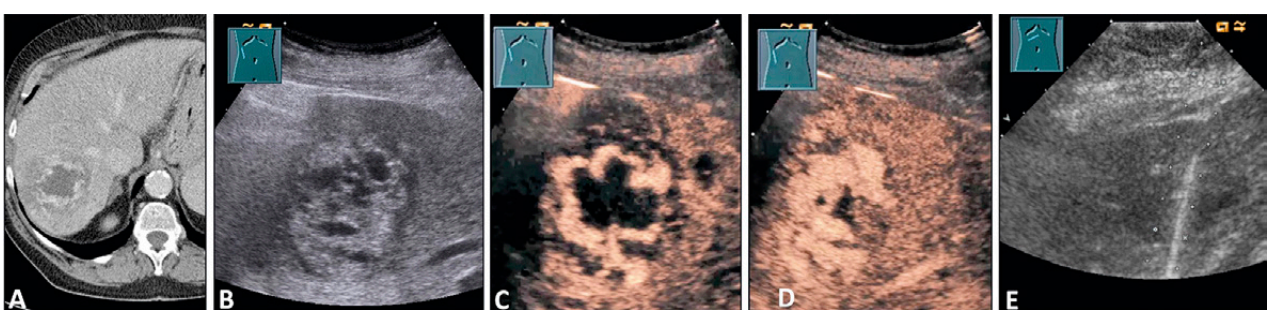

Fig 2. A 64-year-old female patient with a complex hepatic mass and upper abdominal pain. Visualization of the lesion on computed tomography (courtesy of Prof. Dr. Mahnken, Department of Radiology, University Hospital Marburg) (A) and B-mode ultrasound (B). On contrast-enhanced ultrasound, the lesion shows arterial "garland-like" enhancement after 20 s (C), with increasing enhancement of the mass after 30 s (D). An ultrasound-guided biopsy was performed (E), and the diagnosis of primary angiosarcoma of the liver was confirmed histologically.

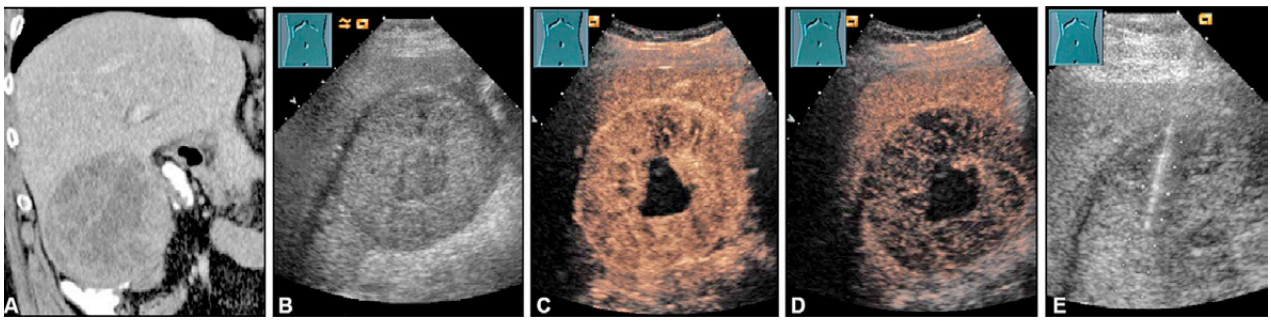

Fig 3. A 60-year-old male patient with a complex hepatic mass and known retroperitoneal liposarcoma. Visualization of the lesion on computed tomography (courtesy of Prof. Dr. Mahnken, Department of Radiology, University Hospital Marburg) (A) and B-mode ultrasound (B). On contrast-enhanced ultrasound, the lesion shows arterial isoenhancement with a central non-perfused area after 30 s (C), with increasing hypoenhancement of the perfused area after 180 s (D). An ultrasound-guided biopsy was performed (E), and the diagnosis of hepatic metastasis of liposarcoma was confirmed histologically.

Cross-sectional imaging

On CT, the lesions are visualized as well-demarcated, almost fatty, lobulated, round masses, with some randomly distributed vascular structures [81]. On T1- and T2-weighted axial MRI, the lesions can be visualized as a hyperintense mass. The lesions may show signal loss on the fat-saturated T1-weighted axial image and enhancement of the small nodular lesions on the dynamic post-contrast fat-saturated T1-weighted axial images [81].

B-mode US and CEUS

Data regarding imaging of primary liposarcomas are very limited and refer to a few case reports; secondary liver metastases of liposarcomas are more frequent. On US, the lesions are seen as well-defined echogenic lesions [81]. On CEUS, the lesions may show inhomogeneous enhancement with a washout phenomenon in the parenchymal phase (fig 3).

Fibrosarcoma

Hepatic fibrosarcoma (HF) is extremely rare, with high malignancy and a poor prognosis. Fibrosarcoma is a soft tissue sarcoma originating from fibroblasts with variable collagen production and, in typical cases, a "herringbone architecture" [82]. The perivascular connective tissue, cellular elements of vessels, perilymphatic tissue, connective tissue of the portal vein, regenerative nodules in the case of cirrhosis, and the wall of a cystic lesion or abscess are considered to be the sites of HF origin [83]. Surgery is considered the most effective treatment, and postoperative chemotherapy is recommended for patients with infiltration or metastasis [84]. Poorly differentiated fibrosarcoma with myxomatous areas indicates myxofibrosarcoma, which is uncommon in the liver. An extensive radiological evaluation, intensive clinical preoperative assessment, careful surgical procedure planning, extensive surgical resection, consecutive treatment, and strict regular follow-ups should be implemented to provide the best prognosis for this malignant disease [83,85].

Cross-sectional imaging

On contrast-enhanced CT scans, HF may be visualized as homogeneous low-density lesions that may show an inhomogeneous enhancement or a hyperenhancement and arteriovenous shunts [84].

B-mode US and CEUS

US usually indicates a large mass in the liver, with complex echogenicity owing to hemorrhage, necrosis, or cystic degeneration [86]. On CDS, vessels may be detected [84]. On CEUS, the lesions may present with inhomogeneous enhancement during the arterial phase and hypoenhancement during the portal and delayed phase [84].

Epithelioid hemangioendothelioma

With an incidence of less than 0.1 per 100,000 population, hepatic epithelioid hemangioendothelioma (HEHE) is a very rare intermediate-malignant vascular tumor of epithelioid origin that primarily involves the liver [87,88]. It was first reported by Ishak et al in a series of 32 patients as a primary liver tumor, usually presenting as multiple hepatic lesions mimicking metastases and with low to moderate malignancy [87]. This tumor primarily affects middle-aged women, with a notably variable clinical course ranging from incidental discovery in completely asymptomatic individuals to a rapid and fatal progression involving bleeding and liver insufficiency [89]. Histologically, HEHE consists of dendritic and epithelioid cells, which mainly proliferate in the periphery of the tumor, often invading and obliterating sinusoids and branches of the portal and hepatic veins. By contrast, the central areas usually consist of fibrous and hypovascularized stroma [90]. Depending on the disease stage, HEHE may appear on imaging as a single nodular lesion or, much more commonly, as multiple nodular lesions, which may be confluent with a diffuse aspect, usually lo-

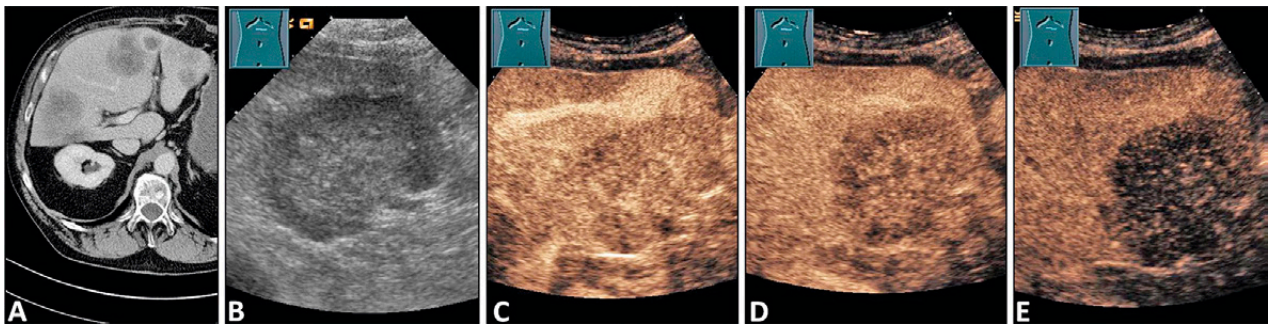

Fig 4. A 50-year-old patient with hypoechoic hepatic lesions and a known history of myelodysplastic syndrome. Visualization of the lesion on computed tomography (courtesy of Prof. Dr. Mahnken, Department of Radiology, University Hospital Marburg) (A) and B-mode ultrasound (B). On contrast-enhanced ultrasound, the lesion shows an isoenhancement after 15 s (C), with increasing hypoenhancement after 1 min (D) and 3 min (E). An ultrasound-guided biopsy was performed, and the diagnosis of hepatic epithelioid hemangioendothelioma was confirmed histologically.

calized in the subcapsular regions [91]. Retraction of the liver capsule is a typical feature of HEHE, observed in approximately 25% of cases, and calcification has been reported in approximately 23% of patients [92,93].

Cross-sectional imaging

On CT, HEHE lesions are hypoattenuating, with a halo or target pattern of enhancement in large lesions [91]. On MRI, the lesions appear hypointense on T1-weighted unenhanced imaging, and, on T2-weighted images, they display heterogeneously increased signal intensity [91]. With gadolinium-enhanced MRI, the lesions may demonstrate target-type enhancement with a peripheral halo or thin peripheral hypointense rim. The "lollipop sign" seems to be specific to HEHE and indicates the aspect of a hepatic or portal vein terminating at the periphery of the liver lesions [94]. In most cases, the specificity of radiological findings is still insufficient to enable the differentiation of this exceptionally rare tumor from other FLLs, particularly from metastatic carcinoma, HCC, angiosarcoma, and atypical hepatic cavernous hemangioma. Therefore, biopsy of these lesions are commonly required in order to determine the final diagnosis [93,95].

B-mode US and CEUS

The US findings have been assessed in only a small number of reports [10,11,38,95-97]. On B-mode US, HEHE can appear as a single or multiple, diffuse hypoechoic lesion (or hyperechoic in a minority of cases). It may be inhomogeneous with irregular margins, usually located near the liver capsule, which may be distorted and invaginated [11,95]. Therefore, multiple subcapsular hypoechoic FLLs of regular shape should raise the possibility of HEHE. On CEUS, HEHE usually presents with peripheral rim-like hyperenhancement in the arterial phase (which can be absent), and the central areas of the lesion appear hypoenhanced [11,95,97]. In the portal venous and late phases, HEHE presents a rapid washout with hypoenhancement, raising suspicion of a malignant tumor (fig 4). Central unenhanced areas are often observed in the late phases [11]. In some cases, CEUS may reveal more lesions than the unenhanced US [11].

Conclusion

The diagnosis of rare malignant mesenchymal liver lesions of the liver are a challenge owing to the rarity of these lesions. An US examination with, if required, color Doppler sonography (CDS) and CEUS, taking into account the clinical background of the patient, may help to focus the differential diagnoses. In most of these lesions, the enhancement pattern is characterized by the absence of portal venous perfusion, known as the washout phenomenon. This is similar to common malignant liver lesions and thus indicates the need for histological confirmation.

Conflict of interest: none

References

1. Dietrich CF, Averkiou M, Nielsen MB, et al. How to perform Contrast-Enhanced Ultrasound (CEUS). Ultrasound Int Open 2018;4:E2-e15.
2. Claudon M, Dietrich CF, Choi BI, C et al. Guidelines and good clinical practice recommendations for contrast enhanced ultrasound (CEUS) in the liver--update 2012: a WFUMB-EFSUMB initiative in cooperation with representatives of AFSUMB, AIUM, ASUM, FLAUS and ICUS. Ultraschall Med 2013;34:11-29.
3. Claudon M, Dietrich CF, Choi BI, et al. Guidelines and good clinical practice recommendations for Contrast Enhanced Ultrasound (CEUS) in the liver - update 2012: A WFUMB-EFSUMB initiative in cooperation with representatives of AFSUMB, AIUM, ASUM, FLAUS and ICUS. Ultrasound Med Biol 2013;39:187-210.
4. Dietrich CF, Nolsøe CP, Barr RG, et al. Guidelines and Good Clinical Practice Recommendations for Contrast-

Enhanced Ultrasound (CEUS) in the Liver-Update 2020 WFUMB in Cooperation with EFSUMB, AFSUMB, AIUM, and FLAUS. Ultrasound Med Biol 2020;46:2579-2604.
5. Dietrich CF, Nolsøe CP, Barr RG, et al. Guidelines and Good Clinical Practice Recommendations for Contrast Enhanced Ultrasound (CEUS) in the Liver - Update 2020 - WFUMB in Cooperation with EFSUMB, AFSUMB, AIUM, and FLAUS. Ultraschall Med 2020;41:562-585.
6. Ignee A, Piscaglia F, Ott M, Salvatore V, Dietrich CF. A benign tumour of the liver mimicking malignant liver disease--cholangiocellular adenoma. Scand.J.Gastroenterol. 2009;44:633-636.
7. Gronlykke L, Tarp B, Dutoit SH, Wilkens R. Peliosis hepatis: a complicating finding in a case of biliary colic. BMJ Case Rep 2013;2013.
8. Loizides A, Glodny B, Zoller H, et al. Contrast enhanced ultrasound of a rare case of Peliosis hepatis. Med Ultrason 2017;19:114-116.
9. Dong Y, Wang WP, Lim A, et al. Ultrasound findings in peliosis hepatis. Ultrasonography 2021;40:546-554.
10. Klinger C, Stuckmann G, Dietrich CF, et al. Contrast-enhanced imaging in hepatic epithelioid hemangioendothelioma: retrospective study of 10 patients. Z Gastroenterol 2019;57:753-766.
11. Dong Y, Wang WP, Cantisani V, et al. Contrast-enhanced ultrasound of histologically proven hepatic epithelioid hemangioendothelioma. World J Gastroenterol 2016;22:4741-4749.
12. Dong Y, Wang WP, Mao F, et al. Imaging Features of Fibrolamellar Hepatocellular Carcinoma with Contrast-Enhanced Ultrasound. Ultraschall Med 2021;42:306-313.
13. Fu T, Ding H, Xu C, Zhu Y, Xue L, Lin F. Imaging findings of fibrolamellar hepatocellular carcinomas on ultrasonography: A comparison with conventional hepatocellular carcinomas. Clin Hemorheol Microcirc 2021;77:49-60.
14. Dong Y, Teufel A, Wang WP, Dietrich CF. Current Opinion about Hepatocellular Carcinoma <10 mm. Digestion 2021;102:335-341.
15. Dong Y, Teufel A, Trojan J, Berzigotti A, Cui XW, Dietrich CF. Contrast enhanced ultrasound in mixed hepatocellular cholangiocarcinoma: Case series and review of the literature. Dig Liver Dis 2018;50:401-407.
16. Faust D, Fellbaum C, Zeuzem S, Dietrich CF. Nodular regenerative hyperplasia of the liver: a rare differential diagnosis of cholestasis with response to ursodeoxycholic acid. Z.Gastroenterol. 2003;41:255-258.
17. Trojan J, Hammerstingl R, Engels K, Schneider AR, Zeuzem S, Dietrich CF. Contrast-enhanced ultrasound in the diagnosis of malignant mesenchymal liver tumors. J.Clin.Ultrasound 2010;38:227-231.
18. Schuessler G, Fellbaum C, Fauth F, et al. [The infammatory pseudotumour -- an unusual liver tumour]. Ultraschall Med. 2006;27:273-279.
19. Tana C, Schiavone C, Ticinesi A, et al. Ultrasound imaging of abdominal sarcoidosis: State of the art. World J Clin Cases 2019;7:809-818.
20. Tana C, Silingardi M, Dietrich CF. New trends in ultrasound of hepatosplenic sarcoidosis. Z Gastroenterol 2015;53:283-284.
21. Hirche TO, Hirche H, Cui XW, Wagner TO, Dietrich CF. Ultrasound evaluation of mediastinal lymphadenopathy in patients with sarcoidosis. Med Ultrason 2014;16:194-200.
22. Tana C, Dietrich CF, Schiavone C. Hepatosplenic sarcoidosis: contrast-enhanced ultrasound findings and implications for clinical practice. Biomed Res Int 2014;2014:926203.
23. Dong Y, Jurgensen C, Puri R, et al. Ultrasound imaging features of isolated pancreatic tuberculosis. Endosc Ultrasound 2018;7:119-127.
24. Barreiros AP, Braden B, Schieferstein-Knauer C, Ignee A, Dietrich CF. Characteristics of intestinal tuberculosis in ultrasonographic techniques. Scand.J.Gastroenterol. 2008;43:1224-1231.
25. Dietrich CF, Douira-Khomsi W, Gharbi H, et al. Cystic echinococcosis, review and illustration of non-hepatic manifestations. Med Ultrason 2020;22:319-324.
26. Dietrich CF, Douira-Khomsi W, Gharbi H, et al. Cystic and alveolar echinococcosis of the hepatobiliary tract - the role of new imaging techniques for improved diagnosis. Med Ultrason 2020;22:75-84.
27. Brunetti E, Tamarozzi F, Macpherson C, et al. Ultrasound and Cystic Echinococcosis. Ultrasound Int Open 2018;4:E70-E78.
28. Dietrich CF, Mueller G, Beyer-Enke S. Cysts in the cyst pattern. Z.Gastroenterol. 2009;47:1203-1207.
29. Richter J, Botelho MC, Holtfreter MC, Akpata R, El Scheich T, Neumayr A, Brunetti E, et al. Ultrasound assessment of schistosomiasis. Z Gastroenterol 2016;54:653-660.
30. Richter J, Azoulay D, Dong Y, et al. Ultrasonography of gallbladder abnormalities due to schistosomiasis. Parasitol Res 2016;115:2917-2924.
31. Dong Y, Mao F, Cao J, Zhang Q, Yang D, Wang WP, Dietrich CF. Differential diagnosis of gallbladder ascariasis debris: the added value of contrast enhanced ultrasound with high frequency transducer. Med Ultrason 2018;20:413-419.
32. Dietrich CF, Sharma M, Chaubal N, et al. Ascariasis imaging: pictorial essay. Z Gastroenterol 2017;55:479-489.
33. Dietrich CF, Kabaalioglu A, Brunetti E, Richter J. Fasciolosis. Z Gastroenterol 2015;53:285-290.
34. Dietrich CF, Atkinson NSS, Lee WJ, et al. Never seen before? Opisthorchiasis and Clonorchiasis. Z Gastroenterol 2018;56:1513-1520.
35. Dietrich CF, Cretu C, Dong Y. Imaging of toxocariasis. Adv Parasitol 2020;109:165-187.
36. Braden B, Helm B, Fabian T, Dietrich CF. [Bacillary angiomatosis of the liver, a suspected ultrasound diagnosis?]. Z.Gastroenterol. 2000;38:785-789.
37. Barreiros AP, Otto G, Ignee A, Galle P, Dietrich CF. Sonographic signs of amyloidosis. Z.Gastroenterol. 2009;47:731-739.
38. Chiorean L, Cui XW, Tannapfel A, et al. Benign liver tumors in pediatric patients - Review with emphasis on imaging features. World J Gastroenterol 2015;21:8541-8561.

39. Schreiber-Dietrich DG, Leuschner I, Tannapfel A, et al. [Primary liver tumours in childhood]. Z Gastroenterol 2015;53:1267-1275.
40. Zander T, Safai Zadeh E, Moller K, et al. Comments and illustrations of the WFUMB CEUS liver guidelines: Rare focal liver lesion - infectious parasitic, fungus. Med Ultrason 2023, doi: 10.11152/mu-4091.
41. Ignee A, Moller K, Thees-Laurenz R, et al. Comments and illustrations of the WFUMB CEUS liver guidelines: Rare focal liver lesions - infectious (bacterial). Med Ultrason 2023, doi: 10.11152/mu-4065.
42. Moller K, Stock B, Ignee A, et al. Comments and illustrations of the WFUMB CEUS liver guidelines: Rare focal liver lesions - non-infectious, non-neoplastic. Med Ultrason 2023, doi: 10.11152/mu-4192.
43. Moller K, Zadeh ES, Gorg C, et al. Comments and illustrations of the WFUMB CEUS liver guidelines: Rare vascular pathology, part II. Med Ultrason 2023;25:189-200.
44. Moller K, Jenssen C, Braden B, et al. Comments on and Illustrations of the EFSUMB CEUS Guidelines: Transabdominal and Endoscopic Ultrasound Features of Intrapancreatic Metastases and the Role of Multiparametric Imaging and EUS-Guided Sampling in Rare Pancreatic Tumors. Cancers (Basel) 2023;15:2549.
45. Moller K, Braden B, Culver EL, et al. Secondary sclerosing cholangitis and IgG4-sclerosing cholangitis - A review of cholangiographic and ultrasound imaging. Endosc Ultrasound 2023;12:181-199.
46. Moller K, Tscheu T, De Molo C, et al. Comments and illustrations of the WFUMB CEUS liver guidelines: rare congenital vascular pathology. Med Ultrason 2022;24:461-472.
47. Carriaga MT, Henson DE. Liver, gallbladder, extrahepatic bile ducts, and pancreas. Cancer 1995;75:171-190.
48. Mechtersheimer G, Penzel R, Hofmann WJ, Schirmacher P. Primäre Sarkome und Sarkommetastasen in der Leber. Der Pathologe 2006;27:251-262.
49. DeMatteo RP, Shah A, Fong Y, Jarnagin WR, Blumgart LH, Brennan MF. Results of hepatic resection for sarcoma metastatic to liver. Ann Surg 2001;234:540-547; discussion 547-548.
50. Lehnert T, Golling M. [Indications and outcome of liver metastases resection]. Radiologe 2001;41:40-48.
51. Zhang C, Jia CJ, Xu C, Sheng QJ, Dou XG, Ding Y. Undifferentiated embryonal sarcoma of the liver: Clinical characteristics and outcomes. World J Clin Cases 2020;8:4763-4772.
52. Cong WM, Dong H, Tan L, Sun XX, Wu MC. Surgicopathological classification of hepatic space-occupying lesions: a single-center experience with literature review. World J Gastroenterol 2011;17:2372-2378.
53. Leuschner I, Schmidt D, Harms D. Undifferentiated sarcoma of the liver in childhood: morphology, flow cytometry, and literature review. Hum Pathol 1990;21:68-76.
54. Stocker JT, Ishak KG. Undifferentiated (embryonal) sarcoma of the liver: report of 31 cases. Cancer 1978;42:336-348.
55. Noguchi K, Yokoo H, Nakanishi K, et al. A long-term survival case of adult undifferentiated embryonal sarcoma of liver. World J Surg Oncol 2012;10:65.
56. Shimagaki T, Sugimachi K, Mano Y, et al. Undifferentiated embryonal sarcoma of the liver occurring in an adolescent: a case report with genomic analysis. Surgical Case Reports 2022;8:170.
57. Esposito F, Lim C, Baranes L, et al. Primary leiomyosarcoma of the liver: Two new cases and a systematic review. Ann Hepatobiliary Pancreat Surg 2020;24:63-67.
58. Gohrbandt AE, Hansen T, Ell C, Heinrich SS, Lang H. Portal vein leiomyosarcoma: a case report and review of the literature. BMC Surg 2016;16:60.
59. Zimmermann A, Leiomyomatous Tumors of the Hepatobiliary Tract. In: Zimmermann A, ed. Tumors and Tumor-Like Lesions of the Hepatobiliary Tract: General and Surgical Pathology. Cham: Springer International Publishing, 2017;1087-1116.
60. Chi M, Dudek AZ, Wind KP. Primary hepatic leiomyosarcoma in adults: analysis of prognostic factors. Onkologie 2012;35:210-214.
61. Iida T, Maeda T, Amari Y, Yurugi T, Tsukamoto Y, Nakajima F. Primary hepatic leiomyosarcoma in a patient with autosomal dominant polycystic kidney disease. CEN Case Rep 2017;6:74-78.
62. Shivathirthan N, Kita J, Iso Y, et al. Primary hepatic leiomyosarcoma: Case report and literature review. World J Gastrointest Oncol 2011;3:148-152.
63. Zhu KL, Cai XJ. Primary hepatic leiomyosarcoma successfully treated by transcatheter arterial chemoembolization: A case report. World J Clin Cases 2019;7:525-531.
64. Matthaei H, Krieg A, Schmelzle M, et al. Long-term Survival After Surgery for Primary Hepatic Sarcoma in Adults. Archives of Surgery 2009;144:339-344.
65. Pinson CW, Lopez RR, Ivancev K, Ireland K, Sawyers JL. Resection of primary hepatic malignant fibrous histiocytoma, fibrosarcoma, and leiomyosarcoma. South Med J 1994;87:384-391.
66. Yu RS, Chen Y, Jiang B, Wang LH, Xu XF. Primary hepatic sarcomas: CT findings. Eur Radiol 2008;18:2196-2205.
67. Liu W, Liang W. Primary hepatic leiomyosarcoma presenting as a thick-walled cystic mass resembling a liver abscess: A case report. Medicine (Baltimore) 2018;97:e13861.
68. Mitra S, Rathi S, Debi U, Dhiman RK, Das A. Primary Hepatic Leiomyosarcoma: Histopathologist's Perspective of a Rare Case. J Clin Exp Hepatol 2018;8:321-326.
69. Lv WF, Han JK, Cheng DL, Tang WJ, Lu D. Imaging features of primary hepatic leiomyosarcoma: A case report and review of literature. Oncol Lett 2015;9:2256-2260.
70. Atlas of Ultrasound Erlangen (Hepatic metastases Leiomyosarcoma). In. https://sonographie.org/hepatic-metastasis-leiomyosarcoma
71. Rujeerapaiboon N, Wetwittayakhlang P. Primary Hepatic Angiosarcoma: A Rare Liver Malignancy - Varying Manifestations but Grave Prognosis. Case Rep Gastroenterol 2020;14:137-149.
72. Chaudhary P, Bhadana U, Singh RA, Ahuja A. Primary hepatic angiosarcoma. Eur J Surg Oncol 2015;41:1137-1143.

73. Kim HR, Rha SY, Cheon SH, Roh JK, Park YN, Yoo NC. Clinical features and treatment outcomes of advanced stage primary hepatic angiosarcoma. Ann Oncol 2009;20:780-787.
74. Zheng YW, Zhang XW, Zhang JL, et al. Primary hepatic angiosarcoma and potential treatment options. J Gastroenterol Hepatol 2014;29:906-911.
75. Ikeda K, Maehara M, Ohmura N, et al. Spontaneous rupture of a necrotic hepatic angiosarcoma: findings on dual-phase computed tomography and angiography. Radiat Med 2006;24:369-372.
76. Koyama T, Fletcher JG, Johnson CD, Kuo MS, Notohara K, Burgart LJ. Primary hepatic angiosarcoma: findings at CT and MR imaging. Radiology 2002;222:667-673.
77. Zhao CK, Xu HX, Guo LH, Sun LP, Yu M. A primary hepatic angiosarcoma mimicking intrahepatic cholangiocarcinoma on conventional ultrasound and contrast-enhanced ultrasound: A case report and review of literatures. Clin Hemorheol Microcirc 2017;66:7-14.
78. Ling W, Qiu T, Ma L, Lei C, Luo Y. Contrast-enhanced ultrasound in diagnosis of primary hepatic angiosarcoma. J Med Ultrason (2001) 2017;44:267-270.
79. Wang L, Lv K, Chang XY, et al. Contrast-enhanced ultrasound study of primary hepatic angiosarcoma: a pitfall of non-enhancement. Eur J Radiol 2012;81:2054-2059.
80. Terunuma Y, Takahashi K, Doi M, et al. Primary pleomorphic liposarcoma of the liver: a case report and literature review. Surg Case Rep 2021;7:244.
81. Binesh F, Akhavan A, Kargar S, Navabii H. Primary liposarcoma of liver: a rare case and literature review. BMJ Case Rep 2012;2012.
82. Folpe AL. Fibrosarcoma: a review and update. Histopathology 2014;64:12-25.
83. Smith D, Rele SR. A case of primary fibrosarcoma of the liver. Postgrad Med J 1972;48:62-63.
84. Huang ML, Wu H, Chen JS, Lv ZL. Hepatic fibrosarcoma in a middle-aged man. Int J Clin Exp Pathol 2019;12:3555-3559.
85. Shao Z, Jiao B, Yu J, Liu H. Primary low grade myxofibrosarcoma of the liver with benign presentation but malignant outcome: a case report. BMC Cancer 2019;19:1098.
86. Ali S, Shah P, Shah UJ, et al. Primary fibrosarcoma of the liver: we don't know much: a case report. Case Rep Gastroenterol 2008;2:384-389.
87. Ishak KG, Sesterhenn IA, Goodman ZD, Rabin L, Stromeyer FW. Epithelioid hemangioendothelioma of the liver: a clinicopathologic and follow-up study of 32 cases. Hum Pathol 1984;15:839-852.
88. Hertl M, Cosimi AB. Liver transplantation for malignancy. Oncologist 2005;10:269-281.
89. Mehrabi A, Kashfi A, Fonouni H, et al. Primary malignant hepatic epithelioid hemangioendothelioma: a comprehensive review of the literature with emphasis on the surgical therapy. Cancer 2006;107:2108-2121.
90. Makhlouf HR, Ishak KG, Goodman ZD. Epithelioid hemangioendothelioma of the liver: a clinicopathologic study of 137 cases. Cancer 1999;85:562-582.
91. Miller WJ, Dodd GD, 3rd, Federle MP, Baron RL. Epithelioid hemangioendothelioma of the liver: imaging findings with pathologic correlation. AJR Am J Roentgenol 1992;159:53-57.
92. Kim EH, Rha SE, Lee YJ, Yoo Ie R, Jung ES, Byun JY. CT and MR imaging findings of hepatic epithelioid hemangioendotheliomas: emphasis on single nodular type. Abdom Imaging 2015;40:500-509.
93. Lin J, Ji Y. CT and MRI diagnosis of hepatic epithelioid hemangioendothelioma. Hepatobiliary Pancreat Dis Int 2010;9:154-158.
94. Alomari AI. The lollipop sign: a new cross-sectional sign of hepatic epithelioid hemangioendothelioma. Eur J Radiol 2006;59:460-464.
95. Schweitzer N, Soudah B, Gebel M, Manns MP, Boozari B. Gray scale and contrast-enhanced ultrasound imaging of malignant liver tumors of vascular origin. United European Gastroenterol J 2015;3:63-71.
96. Mermuys K, Vanhoenacker PK, Roskams T, D'Haenens P, Van Hoe L. Epithelioid hemangioendothelioma of the liver: radiologic-pathologic correlation. Abdom Imaging 2004;29:221-223.
97. Ling WW, Luo Y, Lin L, et al. [Ultrasonographic Features of Hepatic Epithelioid Hemangioendothelioma on B-mode and Contrast-enhanced Ultrasound]. Sichuan Da Xue Xue Bao Yi Xue Ban 2017;48:595-599.