

M. Tannast  
S. B. Murphy  
F. Langlotz  
S. E. Anderson  
K. A. Siebenrock

## Estimation of pelvic tilt on anteroposterior X-rays—a comparison of six parameters

Received: 7 July 2005  
Revised: 24 August 2005  
Accepted: 28 September 2005  
Published online: 20 December 2005  
© ISS 2005

M. Tannast · K. A. Siebenrock  
Department of Orthopedic Surgery,  
Inselspital, University of Bern,  
Bern, Switzerland

M. Tannast · S. B. Murphy  
Center for Computer Assisted and  
Reconstructive Surgery,  
New England Baptist Hospital,  
Boston, MA, USA

M. Tannast · S. B. Murphy  
Tufts University School of Medicine,  
Boston, MA, USA

M. Tannast · S. B. Murphy  
Harvard Medical School,  
Boston, MA, USA

F. Langlotz (✉)  
MEM Research Center for Orthopaedic  
Surgery, Institute for Surgical  
Technologies and Biomechanics,  
University of Bern,  
Stauffacherstrasse 78,  
3014 Bern, Switzerland  
e-mail: frank.langlotz@MEMcenter.  
unibe.ch  
Tel.: +41-31-6315959  
Fax: +41-31-6315960

S. E. Anderson  
Department of Diagnostic  
Interventional and Pediatric Radiology,  
University of Bern,  
Bern, Switzerland

**Abstract Objective:** To compare six different parameters described in literature for estimation of pelvic tilt on an anteroposterior pelvic radiograph and to create a simple nomogram for tilt correction of prosthetic cup version in total hip arthroplasty.

**Design:** Simultaneous anteroposterior and lateral pelvic radiographs are taken routinely in our institution and were analyzed prospectively. The different parameters (including three distances and three ratios) were measured and compared to the actual pelvic tilt on the lateral radiograph using simple linear regression analysis. **Patients:** One hundred and four consecutive patients (41 men, 63 women with a mean age of 31.7

years, SD 9.2 years, range 15.7–59.1 years) were studied. **Results:** The strongest correlation between pelvic tilt and one of the six parameters for both men and women was the distance between the upper border of the symphysis and the sacrococcygeal joint. The correlation coefficient was 0.68 for men ( $P<0.001$ ) and 0.61 for women ( $P<0.001$ ). Based on this linear correlation, a nomogram was created that enables fast, tilt-corrected cup version measurements in clinical routine use. **Conclusion:** This simple method for correcting variations in pelvic tilt on plain radiographs can potentially improve the radiologist's ability to diagnose and interpret malformations of the acetabulum (particularly acetabular retroversion and excessive acetabular overcoverage) and post-operative orientation of the prosthetic acetabulum.

**Keywords** Anteroposterior pelvic radiograph · Pelvic tilt · Total hip arthroplasty · Anteversion · Acetabular retroversion

### Introduction

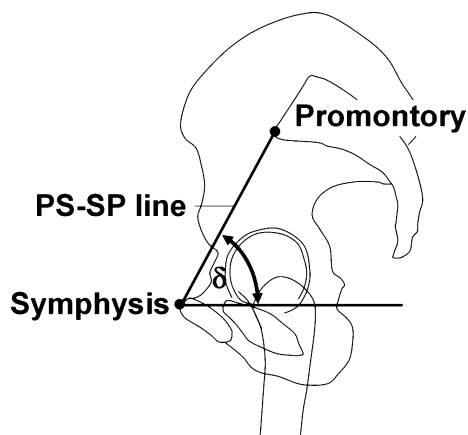
Two-dimensional pelvic radiographs are the standard imaging method for the evaluation of hip pathologies and cup position following total hip arthroplasty (THA) [1–3]. Despite their inferior accuracy in comparison to three-dimensional techniques based on magnetic resonance

imaging [4] or computed tomography [5–9], plain radiographs are widely used for the initial detection of acetabular rim pathomorphologies [10–12] and for post-operative determination of prosthetic cup orientation [13, 14], largely due to the simplicity, availability, and minimal expense associated with acquiring these images. While plain pelvic radiographs are easily obtained, their accurate

interpretation is complicated by the wide variability in individual pelvic position relative to the X-ray plate [6, 15–18]. In THA, increased pelvic tilt (a rotation around the transversal axis, see Fig. 1) results in a significant decrease in apparent prosthetic cup anteversion and vice versa [16, 19]. These position variations affect the accuracy of studies correlating cup position to instability, wear, and osteolysis. Furthermore, in native hips without pathomorphological abnormalities, plain pelvic radiographs obtained with the pelvis tilted excessively can lead to the false appearance of a retroverted acetabulum [17, 18]. This can significantly influence the accurate diagnosis of femoro-acetabular impingement (FAI) and affect potential surgical treatment recommendations such as surgical hip dislocation [20] or periacetabular osteotomy [10].

Pelvic tilt around the transverse axis is difficult to correct for and can vary widely between individuals and between pelvic radiographs taken from the same patient at different times. For example, a range of  $67^\circ$  in individual pelvic tilt measurements in the supine position has been reported [21]. This example demonstrates that a simple and accurate method to correct for this variability would greatly enhance the surgeon's ability to make accurate diagnoses and treatment recommendations and to enable more accurate measurements of critical parameters on plain pelvic radiographs.

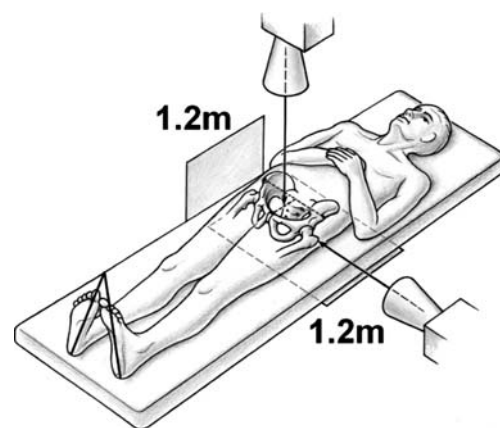
Different attempts were made to correlate pelvic tilt with an appropriate parameter on an AP pelvic radiograph. The current study compares six previously described methods of estimating pelvic tilt on plain AP radiographs [15, 17, 21–24] with the aim of providing the orthopedic surgeon with a simple tool to improve the accuracy of measurements made on plain radiographs.



**Fig. 1** Pelvic tilt,  $\delta$ , is defined as the angle between a horizontal line and a line connecting the upper border of the symphysis with the sacral promontory (PS-SP line)

## Material and methods

In our institution simultaneous AP and lateral pelvic radiographs are taken routinely of patients with clinical suspicion of FAI or developmental dysplasia of the hip (DDH) in order to objectify the individual pelvic tilt. This study used these preoperative images of 104 consecutive patients. Each patient was positioned on the X-ray table in a defined manner (Fig. 2). There were 41 men and 63 women with a mean age of 31.7 years (SD 9.2 years, range 15.7–59.1 years). The radiographs were taken in 81 patients with FAI and in 23 patients with DDH. Patients with a severely dysplastic hip (Grade IIA and higher, according to Severin [25]) were excluded, because a high degree of dysplasia is defined by a (sub-)luxation of the femoral head, which would jeopardize the measurement of the parameters described below. The source-to-image distance (SID) was 1.2 m. The central beam was directed to the midpoint between the symphysis and the center between both anterior superior iliac spines (Fig. 2) [17]. The conventional radiographs were then digitized (Diagnostic RRO Plus Scanner, Vidar System, Herndon, VA, USA). Three distances and three ratios were measured by one examiner (MT) and calculated using commercial software (Photoshop 6.0, Adobe, San Jose, CA, USA). These six parameters were (1) the vertical distance between the upper edge of the symphysis and the mid of the sacrococcygeal joint (distance A) [17], (2) the distance between the upper edge of the symphysis and a line connecting both femoral head centers (distance B) [22], (3) the vertical distance between the upper edge of the symphysis and a line connecting the lower ends of the sacroiliac joints (distance C) [15], (4) the ratio between the vertical and the horizontal diameter of the pelvic foramen (ratio C/D) [21], (5) The ratio be-



**Fig. 2** The radiographic technique of acquiring AP and lateral pelvic radiographs is shown. In the AP direction the central beam was directed to the midpoint between the upper border of the symphysis and the center between both anterior superior iliac spines. The lateral radiograph was centered on the cranial tip of the greater trochanter

tween the vertical and horizontal extends of the obturator foramen (ratio E/F) [21], and (6) the ratio between the vertical extend of the obturator foramen and the distance between the teardrops [24] (ratio E/G) (Fig. 3).

From each patient, an additional lateral radiograph was obtained without repositioning the patient, with the central beam directed to the upper tip of the greater trochanter [19] (Fig. 2). Pelvic tilt was measured on the lateral radiographs and defined as the angle between a horizontal line and a line connecting the pubic symphysis with the sacral promontory (PS-SP line) (Fig. 1) [26–28]. The PS-SP

line was chosen because the corresponding landmarks are easily visible on the lateral radiographs. The parameters characterizing the six methods to measure pelvic tilt on AP radiographs were correlated with the tilt measured on the lateral radiographs to determine the best method of estimating pelvic tilt on an AP pelvic radiograph.

### Statistical analysis

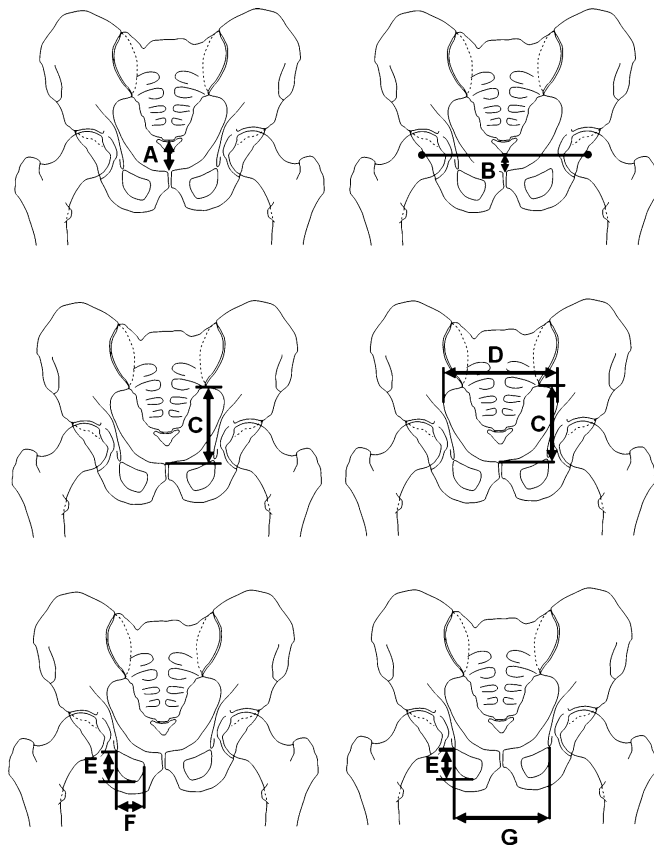
Correlations were analyzed using the simple linear regression model. Since pelvic dimensions are known to be gender dependent, men and women were investigated separately. Pearson's correlation coefficient  $r$  was interpreted as “poor” below 0.3, “fair” from 0.31–0.5, “moderate” from 0.51–0.6, “moderately strong” from 0.61–0.8, and “very strong” from 0.81–1.0 [29]. Gender-dependent differences and differences in pelvic tilt between the FAI and the DDH group were calculated with the Mann-Whitney U-Test. Differences in standard deviation for tilt between men and women were calculated with the F-test. The significance level was set at a probability of less than 0.05.

### Results

None of the analyzed parameters showed a very strong correlation to pelvic tilt. The strongest correlation between pelvic tilt and one of the six parameters for both men and women was found for distance A (Tables 1 and 2). The ratio E/F showed the weakest correlation in men, while the ratio E/G showed the weakest correlation in women. Distance A was the only parameter for which a moderately strong correlation could be found both for men and women (Fig. 4).

Pelvic tilt was statistically significantly higher in women than in men ( $P=0.006$ ). The mean pelvic tilt was  $64.3^\circ$  for men (SD  $5.9^\circ$ , range  $49.8\text{--}74.1^\circ$ ) and  $67.8^\circ$  for women (SD  $5.7^\circ$ , range  $52.6\text{--}82.2^\circ$ ). There was no statistically significant difference in pelvic tilt between the FAI and the DDH group ( $P=0.163$ ). The variability of pelvic tilt did not differ between men and women ( $P=0.98$ ).

With one exception (ratio C/D in men), the correlation coefficients were higher for the three defined distances than



**Fig. 3** The different parameters of pelvic tilt estimation on an AP pelvis radiograph described in the literature and investigated in this study are shown (for explanation, see text)

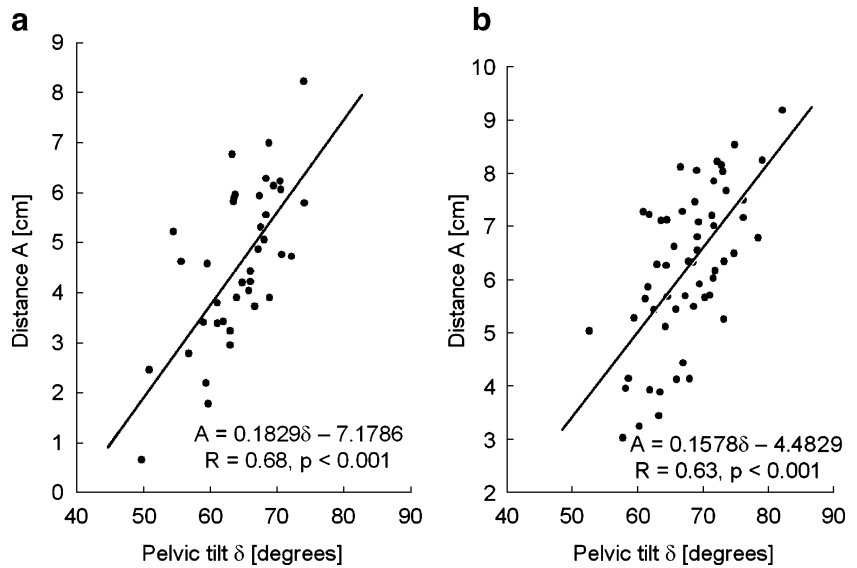
**Table 1** Results of the simple linear regression analysis of the different parameters with pelvic tilt,  $\delta$ , for men

Parameter	$r$	Correlation strength	$P$	Equation
A (cm)	0.68	Moderately strong	<0.001	$A=0.1829\delta-7.1786$
B (cm)	0.66	Moderately strong	<0.001	$B=0.0895\delta-3.38376$
C (cm)	0.60	Moderate	<0.001	$C=0.119\delta+2.4656$
C/D	0.63	Moderately strong	<0.001	$C/D=0.0096\delta+0.0729$
E/F	0.37	Fair	0.024	$E/F=-0.0131\delta-1.8153$
E/G	0.48	Fair	0.001	$E/G=-0.0044\delta+0.5198$

**Table 2** Results of the simple linear regression analysis of the different parameters with pelvic tilt,  $\delta$ , for women

Parameter	<i>r</i>	Correlation strength	<i>P</i>	Equation
A (cm)	0.63	Moderately strong	<0.001	$A=0.1578\delta-4.4829$
B (cm)	0.58	Moderate	<0.001	$B=0.0674\delta-1.4406$
C (cm)	0.56	Moderate	<0.001	$C=0.111\delta+3.563$
C/D	0.46	Fair	<0.001	$C/D=0.0064\delta+0.288$
E/F	0.31	Fair	0.016	$E/F=-0.0088\delta-1.4127$
E/G	0.30	Poor	0.015	$E/G=-0.0018\delta+0.3363$

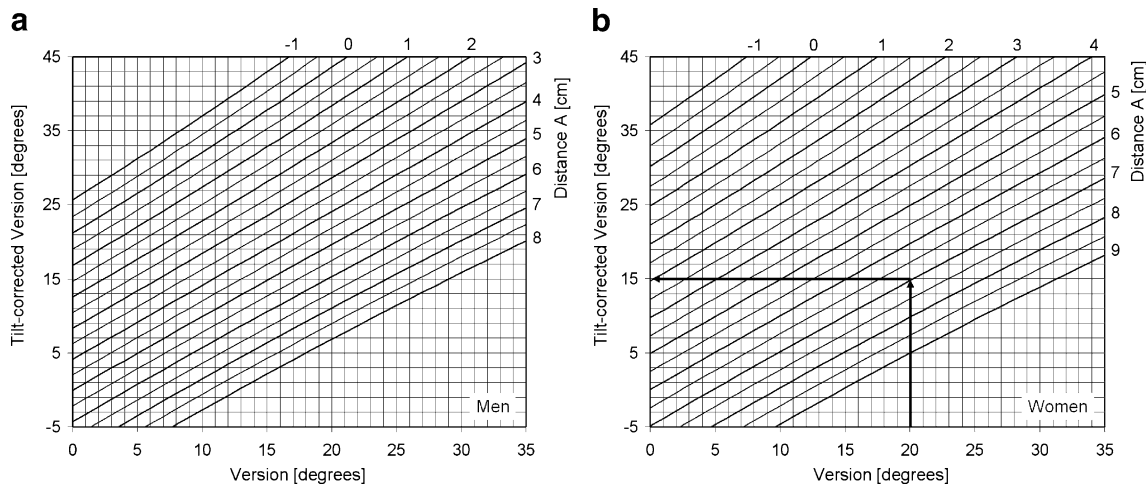
**Fig. 4** For men (a) and women (b) these graphs show the linear correlation analysis between pelvic tilt and the vertical distance between the upper border of the symphysis and the mid of the sacrococcygeal joint (distance A)



for the defined three ratios for both men and women (Tables 1 and 2).

Based on the correlation between distance A and pelvic tilt, a nomogram was created that enables the surgeon to

estimate the tilt-corrected prosthetic cup version using an AP pelvic radiograph (Fig. 5). Mathematical derivation of the nomogram is provided in the Appendix. The application of this nomogram requires two steps. First, the



**Fig. 5** These nomograms can be used for estimation of tilt-corrected cup version angle  $\alpha''$  for men (a) and women (b). A cup abduction of  $40^\circ$  is chosen. First, the non-corrected version is calculated with the formula:  $\text{version } \alpha = \arcsin(\text{short axis}/\text{long axis})$ . Then, after measuring distance A on an AP pelvic radiograph, the

tilt-corrected anteverision can be derived with the nomogram. For example, a measured anteverision of  $20^\circ$  for a female patient with a distance A of 7 cm, leads to a tilt-corrected anteverision of  $15^\circ$  (arrows)

radiographic cup version [13] is calculated as usual from the two axes of the projected ellipse using the inverse sinus function [30]:  $\text{version} = \arcsin(\text{short axis}/\text{long axis})$ . Then, distance A is measured and the corresponding corrected anteversion can be derived from the nomogram (Fig. 5b).

## Discussion

Reliable interpretation of acetabular anatomy and prosthetic cup orientation is only possible if additional information on tilt and rotation of the patient's pelvis is available. The current study compared six different parameters previously described in literature for the estimation of pelvic tilt using an AP pelvic radiograph. The vertical distance between the upper border of the symphysis and the mid of the sacrococcygeal joint turned out to be the most accurate tilt indicator. The ratio between the vertical and horizontal extends of the obturator foramen showed the poorest correlation in men, whereas the ratio between the vertical extend of the obturator foramen and the distance between the teardrops showed the poorest correlation for women. Therefore, it is recommended that distance A be used for tilt estimation on AP pelvic radiographs.

Although some of the other parameters described in the literature were proven to vary linearly with pelvic tilt [24, 31], the presented results show that the reconstruction of the absolute value for both sexes is reliably reproducible with distance A only. A reason for this fact may be that the tilt parameter calibration in previous studies was performed using experimental data of a single cadaveric specimen or a restricted number of samples, whereas this anatomically based comparison study was based on a large patient group.

Theoretically, a ratio between a vertical and a horizontal parameter should be more precise since the individual pelvic size is taken into consideration. Furthermore, a ratio is independent of magnification and SID. Although there may be a justification for the use of a ratio in pediatric orthopedics [32], it could be demonstrated that linear distances are superior to ratios for pelvic tilt estimation of the adult pelvis. This may be because individual differences in pelvic dimensions could be multiplied in a ratio.

This study has limitations. The correlation of the most reliable parameter (distance A) with pelvic tilt is moderately strong. For the prediction of pelvic tilt by distance A, this means that with a probability of 65%, tilt can be estimated with an accuracy of 3.8° for men and 4.2° for women. Therefore, the presented nomogram allows only a limited accuracy correction of cup version measurement. For a more precise determination of pelvic tilt, a one-time calibration of distance A with a lateral radiograph is advisable. Then, changes in the patient's pelvic tilt during the longterm follow-up could be calculated by means of the strongly linear correlations described in literature [17]. A prerequisite for the use of the presented calculation is a standardized radiographic technique. An additional con-

cern is that the presented nomogram requires radiographs without patient rotation around the longitudinal axis. The nomogram does not include a correction for pelvic rotation and therefore does not allow for compensation of complex pelvic malpositioning on the X-ray table. In addition, further studies are necessary to validate the presented nomogram.

In the future, computerized methods will help to compensate for pelvic tilt and rotation errors and will provide accurate calculation of prosthetic cup version as well as the tilt-corrected acetabular rim. This will permit more objective, anatomically based information to be derived from an AP pelvic radiograph. The use of distance A as tilt indicator is strongly recommended; if possible, with an additional calibration by means of a lateral radiograph.

**Acknowledgements** Part of this work was funded by the Swiss National Center of Competence in Research "Computer Aided and Image Guided Medical Interventions (Co-Me)", by a fellowship for prospective researchers of the Swiss National Science Foundation, and by the International Society for Computer Assisted Orthopaedic Surgery (CAOS-International).

## Appendix

### Mathematical derivation of the nomogram

Referring to Fig. 6(a), the relationship between radiological cup version ( $\alpha$ ), cup abduction ( $\beta$ ), and the cup version angle that is projected onto the body's mid plane ( $\gamma$ ), was expressed by Murray as [13]:

$$\tan \alpha = \tan \gamma \cdot \cos \beta \quad (1)$$

A change in pelvic tilt ( $\Delta\delta$ ) would lead to a decreased  $\gamma'$  angle as follows (Fig. 6b):

$$\gamma' = \gamma - \Delta\delta \quad (2)$$

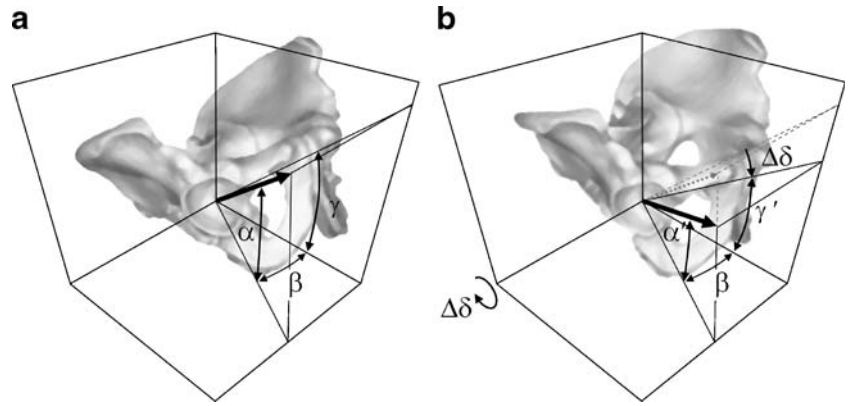
The resulting radiological cup version  $\gamma'$  can now be expressed as

$$\tan \alpha' = \tan \gamma' \cdot \cos \beta = \tan(\gamma - \Delta\delta) \cdot \cos \beta \quad (3)$$

Based on the resulting linear regression model of the present study and subtracting the neutral pelvic tilt of 60° [26, 33, 34] (Fig. 1, Table 1), the relationship between change in pelvic tilt ( $\Delta\delta$ ) and the vertical distance between the upper border of the symphysis and the mid region of the sacrococcygeal joint (distance A) is

$$\Delta\delta_m = \frac{A + 7.1786}{0.1829} - 60^\circ \quad (4)$$

**Fig. 6** The definitions of cup version ( $\alpha$ ), cup abduction ( $\beta$ ), and the cup version angle that is projected onto the body's mid plane ( $\gamma$ ), are shown (a). A pelvic tilt of  $\delta$  would lead to a decreased cup version  $\alpha'$  (b)



for men and

$$\Delta\delta_f = \frac{A + 4.4829}{0.1578} - 60^\circ \quad (5)$$

for women. Inserting Eqs. 4 and 5 for men and women into Eq. 3 yields the following equations of the corrected radiological anteversion ( $\alpha'$ )

$$\alpha'_m = \arctan\left(\tan\left(\gamma - \frac{A + 7.1786}{0.1829} + 60^\circ\right) \cos \beta\right) \quad (6) \quad \text{for men and}$$

for men and

$$\alpha'_f = \arctan\left(\tan\left(\gamma - \frac{A + 4.4829}{0.1578} + 60^\circ\right) \cos \beta\right) \quad (7)$$

for women. The acetabular cup version, measured on a radiograph that is centered to the body's mid axis, is  $5^\circ$  less than measurements centered over the hip [1]. Therefore, the final formulas for creation of the nomograms are

$$\alpha''_m = \arctan\left(\tan\left(\gamma - \frac{A + 7.1786}{0.1829} + 60^\circ\right) \cos \beta\right) + 5^\circ \quad (8)$$

$$\alpha''_f = \arctan\left(\tan\left(\gamma - \frac{A + 4.4829}{0.1578} + 60^\circ\right) \cos \beta\right) + 5^\circ \quad (9)$$

for women.

## References

1. Widmer KH. A simplified method to determine acetabular cup anteversion from plain radiographs. *J Arthroplasty* 2004;19:387–90
2. Fabek L, Farrok D, Trolley M, Descamps PY, Gebhart M, Delince P. A method to measure acetabular cup anteversion after total hip replacement. *Acta Orthop Belg* 1999;65:485–91
3. Pradhan R. Planar anteversion of the acetabular cup as determined from plain anteroposterior radiographs. *J Bone Joint Surg Br* 1999;81:431–5
4. Falliner A, Muhle C, Brossmann J. Acetabular inclination and anteversion in infants using 3D MR imaging. *Acta Radiol* 2002;43:221–4
5. Frick SL, Kim SS, Wenger DR. Pre- and postoperative three-dimensional computed tomography analysis of triple innominate osteotomy for hip dysplasia. *J Pediatr Orthop* 2000;20:116–23
6. Tannast M, Langlotz U, Siebenrock KA, Wiese M, Bernsmann K, Langlotz F. Anatomic referencing of cup orientation in total hip arthroplasty. *Clin Orthop Relat Res* 2005;436:144–50
7. Millis MB, Murphy SB. Use of computed tomographic reconstruction in planning osteotomies of the hip. *Clin Orthop Relat Res* 1992;274:154–9
8. Saxler G, Marx A, Vandeveld D, et al. A comparison of free-hand and computer assisted cup placement in total hip arthroplasty—a multi-center study. *Z Orthop Ihre Grenzgeb* 2004;142:286–91
9. Olivecrona H, Weidenhielm L, Olivecrona L, et al. A new method for measuring cup orientation after total hip arthroplasty. *Acta Orthop Scand* 2004;75:252–60
10. Siebenrock KA, Schöniger R, Ganz R. Anterior femoro-acetabular impingement due to acetabular retroversion and its treatment by periacetabular osteotomy. *J Bone Joint Surg Am* 2003;85:278–86
11. Mast JW, Brunner RL, Zebrack J. Recognizing acetabular version in the radiographic presentation of hip dysplasia. *Clin Orthop Relat Res* 2004;418:48–53
12. Reynolds D, Lucac J, Klaue K. Retroversion of the acetabulum. A cause of hip pain. *J Bone Joint Surg Br* 1999;81:281–8

13. Murray DW. The definition and measurement of acetabular orientation. *J Bone Joint Surg Br* 1993;75:228–32
14. Hassan DM, Johnston GHF, Dust WNC, Watson G, Cassidy D. Radiographic calculation of anteversion in acetabular prosthesis. *J Arthroplasty* 1995;10:369–72
15. Thoren B, Sahlstedt B. Influence of pelvic position on radiographic measurements of the prosthetic acetabular component. *Acta Radiol* 1990;31:133–6
16. Sellers RG, Lyles D, Dorr LD. The effect of pelvic rotation on alpha and theta angles in total hip arthroplasty. *Contemp Orthop* 1988;17:67–70
17. Siebenrock KA, Kalbermatten DF, Ganz R. Effect of pelvic inclination on determination of acetabular retroversion. A study on cadaver pelvis. *Clin Orthop Relat Res* 2003;407:241–8
18. Anda S, Svenningsen S, Groentvedt T, Benum P. Pelvic inclination and spatial orientation of the acetabulum. A radiographic, computed tomographic and clinical investigation. *Acta Radiol* 1990;31:389–94
19. Eddine TA, Migaud H, Chantelot C, Cotten A, Fontaine C, Duquenois A. Variations of pelvic anteversion in the lying and standing positions. Analysis of 24 control subjects and implications for CT measurement of position of a prosthetic cup. *Surg Radiol Anat* 2001;23:105–10
20. Ganz R, Parvizi J, Beck M, Leunig M, Nötzli H, Siebenrock KA. Femoroacetabular impingement: a cause for osteoarthritis of the hip. *Clin Orthop Relat Res* 2003;417:112–20
21. Nishihara S, Sugano N, Nishii T, Ohzono K, Yoshikawa H. Measurements of pelvic flexion angle using three-dimensional computed tomography. *Clin Orthop Relat Res* 2003;411:140–51
22. Kojima A, Nakagawa T, Tohkura A. Simulation of acetabular coverage of femoral head using anteroposterior pelvic radiographs. *Arch Orthop Trauma Surg* 1998;117:330–6
23. Konishi N, Mieno T. Determination of acetabular coverage of the femoral head with use of a single anteroposterior radiograph. A new computerized technique. *J Bone Joint Surg Am* 1993;75:1318–33
24. Katada S, Ando K. A roentgenographic evaluation of the indices for hip dysplasia in children influenced by pelvic tilt. In: Ueno R, Akamatsu N, Itami Y, Tagawa H, Yoshino S, editors. *The hip. Clinical studies and basic research.* Amsterdam: Excerpta Medica; 1984. p. 137–40
25. Severin E. Contribution to the knowledge of congenital dislocation of the hip joint: late results of closed reduction and arthrographic studies of recent cases. *Acta Chir Scand* 1941;84(Suppl 63):1–142
26. Tönnis D. General radiography of the hip joint. In: Tönnis D, editor. *Congenital dysplasia and dislocation of the hip.* Berlin Heidelberg New York: Springer; 1987. p. 100–42
27. Thoms H. Roentgen pelvimetry as a routine prenatal procedure. *Am J Obstet Gynecol* 1940;40:891–905
28. Lehmann KJ, Busch HP, Wischnik A, Georgi M. Obstetric pelvimetry using digital image intensifier radiography (in German). *Rofo* 1989;151:553–7
29. Chan YH. Correlational analysis (Biostatistics 104). *Singapore Med J* 2003;44:614–9
30. McLaren RH. Prosthetic hip angulation. *Radiology* 1973;107:705–6
31. Nishihara S, Sugano N, Nakahodo K, et al. Measurements of pelvic tilting angles during total hip arthroplasty using computer navigation system. In: Delp SL, DiGioia AM, Jaramaz B, editors. *Medical image computing and computer-assisted intervention, MIC-CAI 2000, third international conference, Pittsburgh, Pennsylvania, USA.* Berlin Heidelberg New York: Springer; 2000. p. 1176–9
32. Wagner S, Hofstetter W, Chiquet M, et al. Early osteoarthritic changes of human femoral head cartilage subsequent to femoro-acetabular impingement. *Osteoarthr Cartil* 2003;11: 508–18
33. Lierse W. Becken. In: Lanz T, Wachsmuth W, editors. *Praktische Anatomie.* Berlin Heidelberg New York: Springer; 1984. p. 30–2
34. Williams PL. The skeleton of the lower limb. In: Williams PL, Warkick R, Dyson M, Bannister LH, editors. *Gray's anatomy.* Edinburgh: Churchill Livingstone; 1989. p. 422–46