



Your abstract's disclosure statement has been saved.

## Abstract Submission — Preview



Start



Terms and  
Conditions



Categorisation



Title



Authors &  
Affiliations



Content



Conflicts of  
interest



Preview



Confirmation

Click the button below to finalise your submission.

### Do Cells of Intervertebral Discs with type 1 Modic Change on MRI show a History of Impaired Spinal Fusion? (100381)

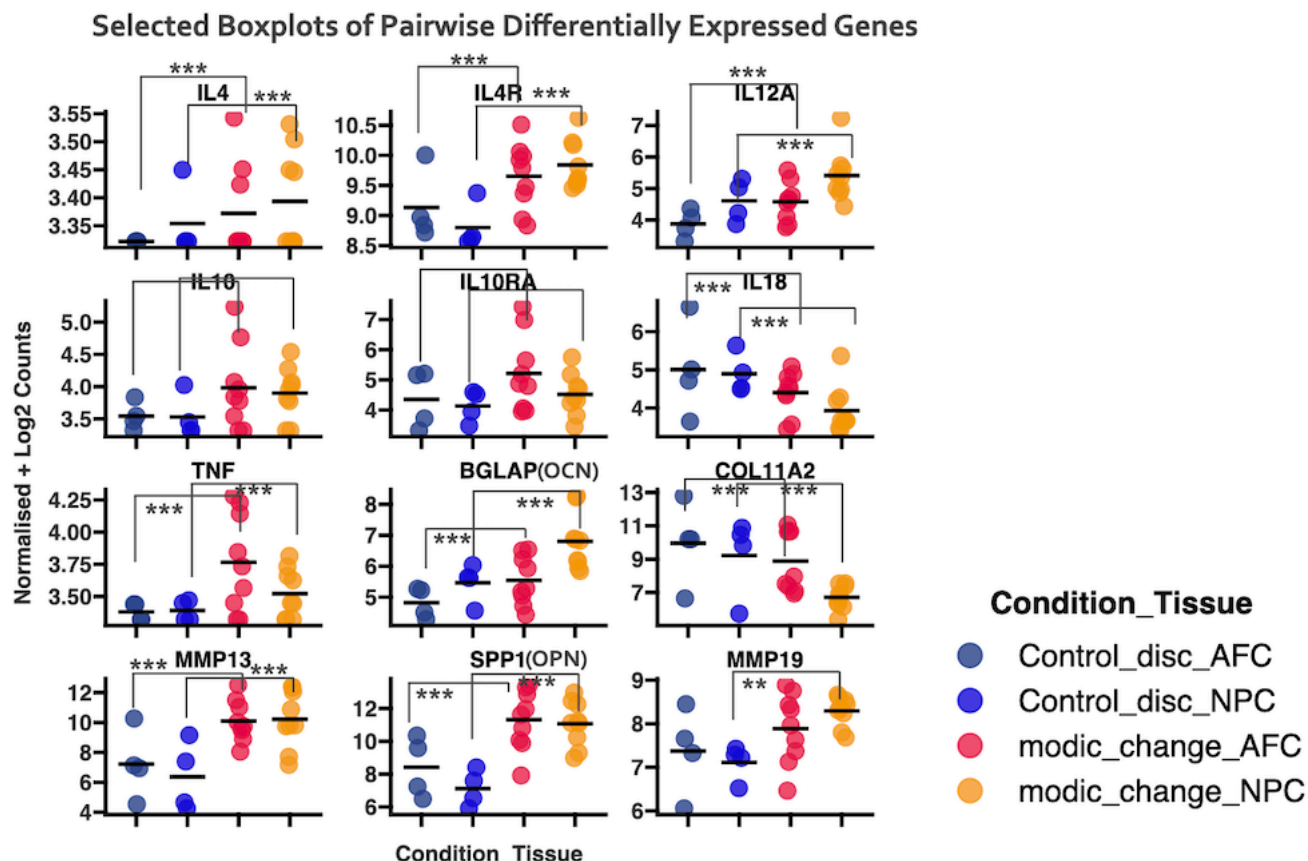
**Benjamin Gantenbein**<sup>1,2</sup>, Andrea Oberli<sup>2</sup>, Tamara Mengis<sup>3</sup>, Harald Bonel<sup>4</sup>, Christoph Albers<sup>1,2</sup>, Oliver Hausmann<sup>5</sup>, Oliver Distler<sup>6</sup>, Stefan Dudli<sup>6</sup>

1. Department of Orthopedic Surgery & Traumatology, Inselspital, University of Bern, Bern, Switzerland
2. Department for BioMedical Research (DBMR), University of Bern, BERN, Switzerland
3. Center of Experimental Rheumatology, University Hospital Zurich and Balgrist University Hospital, University of Zurich, Zürich, Switzerland
4. Department of Diagnostic, Interventional and Paediatric Radiology, Bern University Hospital, Department of Diagnostic, Interventional and Paediatric Radiology, Bern, Switzerland
5. Neuro- and Spine Center, Hirslanden Klinik St. Anna Lucerne, Lucerne, Switzerland
6. Center of Experimental Rheumatology, Balgrist Campus, University Hospital Zurich and Balgrist University Hospital, University of Zurich, Zürich, Switzerland

**INTRODUCTION:** Type 1 Modic changes (MC1) in the spine on magnetic resonance imaging are believed to be related to changes in the crosstalk of the intervertebral disc (IVD) with the neighbouring bone-marrow of the vertebrae and to contribute to low back pain [1]. Here, we hypothesized that cells of the MC1 discs possess a specific transcriptome that is different to relatively healthy non-degenerative cells coming from trauma.

**METHODS:** 13 IVDs were sampled with written consent from seven patients, four IVDs from three trauma ("control") and nine IVDs from four chronic low back pain patients diagnosed with MC1. Total RNA was extracted and purified by silica columns from passage 0 cells that were expanded in normoxia in low glucose Dulbecco Modified Eagle Medium (DMEM) and 10% fetal calf serum after mild enzymatic overnight digestion with pronase/collagenase 2. From each IVD, nucleus pulposus cells (NPC) and annulus fibrosus cells (AFC) were sequenced, thus 26 samples. High-quality total RNA was prepared for sequencing using the Illumina TruSeq Stranded mRNA Library Prep assay. The samples were processed at the Functional Genomics Center of the University of Zürich and were run on an Illumina sequencer. Routine bioinformatic analyses were conducted.

**RESULTS:** The differential expression analysis (DEGs) of the NGS data showed that 811 genes were differentially either up or down-regulated comparing the two groups: 240 in NPC, 240 in AFC and 83 genes in both NPC and AFC when comparing four control IVDs compared to the nine MC1 discs. We found among MC1 and control cells that genes were differentially expressed involved in the matrix synthesis (e.g. COL9A3 -4.04 times down in MC1 (P = 0.00016)). In bone metabolism (e.g. SPP1 = secreted phosphoprotein 1 or better known as Osteopontin and SP7, aka Osterix) among many others (Fig. 1). We detected DEGs related to matrix production between MC1 and the "control" group: COL2A1 P = 0.0003 for NPC and 0.226 for AFC, respectively), SOX9 (P = 0.004 for NPC, and P < 0.0001 for AFC, respectively). Pathway overrepresentation analysis (PRA) revealed that inflammatory pathways and pathways in skeletal system development and ossification and cartilage development were significantly down-regulated in MC1.



**Figure 1:** Selected DEGs that showed a significantly differential gene expression. IVDs grouped according to condition MC1 versus "control". \*\*\*  $p < 0.01$ , \*\*  $p < 0.05$

DISCUSSION & CONCLUSIONS: Pathways of bone turnover and inflammation were over-represented in the NGS data. We cannot exclude from the current data that M could be a risk factor for failure of spinal fusion [2, 3].

1. [1] Herger N, Bermudez-Lekerika P, Farshad M, Albers CE, Distler O, Gantenbein B, Dudli S (2022) Should Degenerated Intervertebral Discs of Patients with Modic T 1 Changes Be Treated with Mesenchymal Stem Cells? *Int J Mol Sci* 23(5):2721. <https://doi.org/10.3390/ijms23052721>
2. [2] Karppinen J, Koivisto K, Ketola J, Haapea M, Paananen M, Herzig KH, Alini M, Lotz J, Dudli S, Samartzis D, Risteli J, Majuri ML, Alenius H, Kyllönen E, Järvinen J, Niinimäki J, Grad S (2021) Serum biomarkers for Modic changes in patients with chronic low back pain. *Eur Spine J* 30(4):1018-1027 <https://doi.org/10.1007/s00586-020-06713-z>
3. [3] Heggli I, Laux CJ, Mengis T, Karol A, Cornaz F, Herger N, Aradi-Vegh B, Widmer J, Burkhard MD, Farshad-Amacker NA, Pfammatter S, Wolski WE, Brunner F, Distler O, Farshad M, Dudli S (2022) Modic type 2 changes are fibroinflammatory changes with complement system involvement adjacent to degenerated vertebral endplate. *JOR Spine* 6(1):e1237. <https://doi.org/10.1002/jsp2.1237>