

Scientific article

**A proof of concept on implant-supported bilateral cantilever bridges: The T-Bridge approach**

Accepted: May 6, 2024  
DOI: [sdj-2024-03-04](https://doi.org/10.48350/196901)  
2024, Vol. 134  
CC BY-ND 4.0

**Kelvin I. Afrashtehfar<sup>1-5</sup>, Bogna Stawarczyk<sup>6</sup>, Danka Micovic Soldatovic<sup>6</sup>, Patrick R. Schmidlin<sup>3,\*</sup>**

<sup>1</sup> Evidence Based Practice Unit, College of Dentistry, Ajman University, Ajman City, UAE

<sup>2</sup> Department of Reconstructive Dentistry and Gerodontology, School of Dental Medicine, University of Bern, Berne, Switzerland

<sup>3</sup> Division of Periodontal and Periimplantitis Sciences, Clinic of Conservative and Preventive Dentistry, Center of Dental Medicine, University of Zurich, Zurich, Switzerland

<sup>4</sup> Private Practice Limited to Implant Dentistry, Richmond, Canada

<sup>5</sup> Private Practice Limited to Prosthodontics, Abu Dhabi, UAE

<sup>6</sup> Department of Prosthodontics, Ludwig-Maximilians-University, Munich, Germany

\*Correspondence: Prof. Dr. Patrick R. Schmidlin, Center of Dental Medicine  
Clinic of Conservative and Preventive Dentistry, Plattenstrasse 11, 8032 Zurich  
Switzerland

Telephone number: +41 44 634 34 17

email: [patrick.schmidlin@zzm.uzh.ch](mailto:patrick.schmidlin@zzm.uzh.ch)

**Keywords**

Biomechanical phenomena, Dental prosthesis design, Fixed dental prosthesis, Dental stress analysis, Implant-supported dental prosthesis

## **Abstract**

The concept of bilateral cantilevers on a single central implant (T-design) for three-unit implant-supported fixed dental prostheses (ISFDPs) has not been explored nor tested. This technical hypothesis aimed to explore the feasibility of such an approach as a cost-effective alternative to conventional treatments. Careful considerations regarding implant diameter, length, ideal position, occlusal scheme, and bone remodeling are essential to ensure adequate support, stability, and prevention of complications. In this proof of concept, we present a preliminary case with this novel design to replace missing posterior teeth in a patient with narrow bone conditions. In addition, a series of planned investigations and preliminary results, including preclinical studies, are presented to illustrate our concept and its potential clinical implications. Clinically, after two-year follow-up, healthy and stable peri-implant tissues around the ISFDP exemplarily demonstrated excellent stability, functionality, and comfort, which is supported by acceptable fracture resistance data in vitro, suggesting indeed the practical potential and suitability. Thus, we claim that such a treatment modality has the at least theoretical potential to revolutionize implant dentistry by providing innovative and cost-effective treatment options for patients with partial ISFDPs in very specific cases. Of course, further research and evaluations are necessary to validate the clinical implications of this innovative hypothesis. Implementing the 3-on-1 T-bridge approach in partial ISFDPs could offer a promising alternative to traditional methods. If proven successful, this technique may lead to significant advancements in clinical practice, providing a less invasive cost-effective treatment option.

## Introduction

Dental implants have revolutionized modern dentistry, providing reliable solutions for patients with missing teeth (1,2). The increasing demand for dental implants has inevitably also led to different innovative restorative concepts, always challenging traditional ideas (3,4). This transformation is elucidated for example in the quest for smaller, more compact implant dimensions, or using less implants, as well as the renewing interest in the use of cantilevers (5-7). The latter allocate support predominantly to one end of a structure, which, when applied to implant-supported bridges, challenges conventional ideas by entrusting a single implant with the responsibility of supporting the pontic component. This innovative approach allows for more compact prostheses, particularly beneficial in cases with space or budget constraints that make additional implants impractical (8,9).

Despite existing knowledge confirming the feasibility of short cantilevers in specific applications (3,10,11), opportunities for further investigation remain. The idea of using bilateral cantilevers on a single central implant to support a three-unit implant-supported fixed dental prosthesis (ISFDP) presents an enticing, yet unexplored, alternative (3,11). Traditionally, a 3-unit ISFDP requires at least two implants (Figs. 1A-C), but the utilization of bilateral cantilevers on a single central implant (Fig. 1D) remains unexplored according to the authors knowledge. This novel approach offers to minimize surgical intervention and optimize prosthetic distribution, potentially offering a viable solution in scenarios with limited bone volume or financial constraints. While this single-implant strategy could simplify treatment, each prosthetic principle, whether conventional or novel, inherently carries distinct surgical and prosthetic implications. For instance, the traditional two-implant-abutment approaches might necessitate additional procedures such as sinus lifts or bone grafts, impacting both cost and patient morbidity. Conversely, the T-bridge approach may present challenges in ensuring biomechanical stability and managing occlusal forces, which could affect long-term outcomes.

Therefore, our proof of concept aims to address this knowledge gap and explore theoretically and practically – based on unique preliminary results - the potential of using bilateral cantilevers on a solitary central implant within partial ISFDPs. We seek to discuss aspects like the safety, efficacy, and clinical feasibility of this innovative approach, with implications that extend to clinical practice. Our endeavor aspires to transform the landscape of oral rehabilitation, combining cutting-edge techniques and patient-centered care to shape the future of reconstructive and implant dentistry.

## Materials and methods

### *Hypothesis*

The T-bridge concept (Fig. 1D and Fig. 2), which proposes a three-unit ISFDP with a single central implant and bilateral cantilevers, can be clinically used and withstands normal oral function and represents a biologically acceptable alternative as compared to conventional approaches in prosthodontics.

### *Evaluation of hypothesis*

We build upon a retrospective study by Ravidà et al. (12) involving 145 patients over an average of 76 months and analyzed three distinct ISFDP types: non-splinted crowns (NSC) on three implants, splinted crowns (SC) on three implants, and the conventional 3-unit implant-supported bridge over two implants (ISB). The ISB, supported by the two implants for restoring a 3-unit posterior edentulous area, emerged as highly successful, displaying the highest survival rates, minimal peri-implantitis issues, and fewer prosthodontic complications, all while being economically prudent (Fig. 1A). The latter gold standard treatment modality advantages for restoring three-unit edentulous regions are undeniable. However, as we explore the T-bridge (Fig. 1D and Fig. 2), we aim to push this idea further and propose an innovative paradigm shift that requires of course a comprehensive and critical validation to uncover its potential (dis)advantages and address underlying challenges. This also highlights the need for preclinical studies to assess its feasibility.

### *Biomechanical basis*

Wolff's Law and the threshold of implant loading (approximately 20 N/cm<sup>2</sup>) serve as the foundation of our idea (13,14). Existing literature reveals the complex interplay between force magnitude, bone remodeling, and implant stability (15-22). We address concerns related to overloading, implant location, and rotational forces.

### *Implications*

The T-bridge provides minimal aesthetic concerns due to its strategic placement in unnoticeable oral areas. It remains discreetly covered by the lips, significantly reducing overt cosmetic concerns when compared to other modalities.

Biomechanical reasoning suggests that the T-bridge is easier to maintain than approaches relying on multiple implants (Fig. 1). The simplified design may contribute to easier oral hygiene practices and, in turn, potentially reduce the risk of peri-implantitis associated with the T-bridge option.

The T-bridge proposal becomes particularly valuable when dealing with limited bone support around the central implant (Fig. 2). In cases where economic factors weigh heavily, such as the cost of additional implants or grafting procedures, the T-bridge also presents itself as a pragmatic and cost-effective choice.

### *Predictions*

Continue with a description on what you did. Add as many subchapters as necessary. The T-bridge does not aim to replace existing standards but offers an alternative approach. Critical dimensions and precise implant placement are key, as is the design of the occlusal scheme to prevent overloading.

The anticipated outcomes of this discussion require thoughtful consideration, especially within the conservative dental practice. Initial skepticism may surround the concept of a 3-

unit ISFDP relying on a single central implant. Concerns may arise about the implant's ability to withstand substantial occlusal forces consistently exerted on the prosthesis, which could lead to potential issues, such as implant failure, subsequent bone loss, and the complications often associated with treatments requiring multiple implants. However, upon closer examination, it becomes evident that the proposed T-bridge innovation does not intend to replace the current standard of care. Instead, it aims to establish itself as an alternative approach, subject to well-defined criteria that must be rigorously followed to address significant concerns.

In the hypothetical scenario of the T-bridge, several critical factors (implant dimensions, implant location, occlusal design, and strategic implant placement) play a crucial role. For instance, the implanted fixture must exceed conventional proportions in both diameter and length. This size increase is essential to provide the implant with the strength required to anchor securely within the surrounding native bone. In addition, implant placement demands high precision. It should not only maximize reinforcement but also ensure even dispersion of the forces it encounters, resulting in optimal load distribution. Ideally, this placement should negate the need for supplementary grafting procedures, relying instead on the inherent strength of the native bone. Also, the occlusal scheme is a decisive consideration. Design contours must promote a harmonious distribution of occlusal forces to maintain optimal balance and prevent overloading of the solitary implant. This careful design is crucial for preserving the implant's structural integrity. Thus, the T-bridge approach relies on careful planning, precise execution, and an understanding of the biomechanical and structural aspects involved to be successful.

## **Preliminary findings and results**

### *Exemplary clinical case*

We present one case that illustrates a notable application of the principles of successful osseointegration and biological factors to overcome mechanical challenges, showcasing the potential of the T-bridge approach. Figure 3 showcases the short-term result of a 60-year-old female patient who is healthy but is a mild smoker with history of periodontitis and significant bone loss in the maxillary left posterior region. The patient expressed her desire for an ISFDP in this challenging scenario.

Given the narrow bone conditions, a conventional bridge on two implants to replace her left premolars and first molar was considered not feasible. However, after thorough consultation with the patient, this novel approach was devised. An implant was strategically placed in the center of the planned screw-retained ISFDP. Following a period of healing, a T-bridge (3-on-1) was successfully delivered as the final restoration and continues being under observation. The results of this intervention were truly remarkable.

Following a diligent 24-month follow-up and maintenance appointment, the superstructure of the T-bridge was carefully removed for a thorough cleaning, revealing healthy peri-implant tissues (Fig. 3A). Subsequently, the ISFDP was reintroduced with satisfactory stability and functionality (Figs. 3B, C). Comprehensive clinical and radiological examinations conducted

during the follow-up period revealed no pathological findings or concerns related to the implant (Fig. 3D).

The 24-month post-loading follow-up and maintenance check revealed that the region of interest is in a healthy and stable condition (Figs. 3E and 3F). The peri-implant tissues showed no signs of bleeding upon probing, maintained a probing depth of less than 3mm, and there was no evident marginal bone loss. With regards to the occlusion, it was observed that the distal pontic (#26) makes minimal contact on the palatal side, which is indicative of intentional infraocclusion to prevent occlusal overload. This case serves as a testimony to the potential clinical viability and success of the T-bridge approach, even in challenging clinical scenarios.

While it may challenge conventional practice, it showcases the significance of considering innovative solutions, especially in clinical scenarios with limited options. Furthermore, patient informed consent was obtained throughout the treatment process.

### *Preclinical testing*

We plan a series of preclinical tests to evaluate the T-bridge concept thoroughly. To do so, we will use a combination of computational simulations and in vivo data collection to assess various aspects of this innovative approach.

Previous 3D finite-element analysis (FEA) studies have predominantly focused on three-unit cantilever ISFDPs with one pontic and two implants. In our study, we will replicate these scenarios to serve as comparators for the T-bridge. This approach allows us to assess the T-bridge's performance relative to conventional alternatives (23-25).

Fracture resistance under both static and dynamic loading conditions, following established protocols have been described in detail elsewhere (26,27). A comparative analysis will be planned, evaluating the performance of the T-bridge in contrast to other commonly reported solutions. Initial data from a pilot study evaluated already the fracture resistance under static loading conditions for four 3-unit bilateral cantilever supported by a single implant compared to a control group consisting of a conventional 3-unit ISFDP supported by two implants with one intermediate pontic (Fig. 4).

In the present preclinical study, Straumann tissue level regular implant analogues with a diameter of 4.1 mm (Straumann, Basel, Switzerland) were used and embedded in Paladur (Pala, Hanau, Germany). SN Variobase® abutments were then mounted with a torque of 35 Nm. Standardized ISFDPs were fabricated from VITA CAD-Temp® multiColor material (Vita Zahnfabrik, Bensheim, Germany) after digital impressions using a Cerec device (Dentsply Sirona, Bensheim, Germany). The abutments were sandblasted with 50 µm aluminium oxide and cemented with Multilink dual-curing cement (Ivoclar, Schaan, Liechtenstein).

All ISFDPs received a high gloss polish for clinical use and were adhesively bonded to the abutments. After 24 hours of incubation at 37°C, the fracture load of the ISFDPs was evaluated using a universal testing machine (Zwick 1445, ZwickRoell; Ulm, Germany) applying vertical force at a rate of 10 mm/min, with a force cut-off threshold of 50%. The force was applied using individually crafted Cobalt-Chromium-Molybdenum (CoCrMo) antagonists, designed to exert forces on each unit of the 3-unit ISFDPs. Regarding failure mode, T-bridges fractured at

the abutment tooth, whereas conventional control bridges exhibited a total fracture. This methodology facilitated a standardized and systematic comparison between the groups.

The preliminary data shows a range of fracture loads in the experimental group (Fig. 4B), with the lowest at 1656.79 N, the highest at 2302.37 N, and an average mean of 2114.75 N (SD = 229.07 N). In contrast, the single specimen in the control group had a higher fracture load of 4352.06 N (Figs. 4C, D). Although this suggests that the control group displayed superior fracture resistance compared to the experimental group. Nevertheless, the experimental group could potentially meet satisfactory thresholds in patients without parafunction or those experiencing less demanding loading conditions during chewing. Further detailed analysis is warranted to substantiate these preliminary findings also testing other materials.

To complement our computational simulations with real-world insights, we plan to gather in vivo data. This involves the use of customized abutments and the installation of 3D piezoelectric force transducers within the implant(s). These transducers will record the loads generated during maximum voluntary clenching and while chewing gum, as previously reported (28). This in vivo data will provide invaluable information about the actual mechanical behavior of the T-bridge and its comparators.

If the results from the preclinical testing phase demonstrate promise and safety, our research will progress to clinical studies. These clinical investigations will further validate and provide valuable insights into the hypothesis and the practical application of the T-bridge approach.

## Discussion

The evaluation of this novel therapeutic approach in implant dentistry requires careful consideration of its potential benefits and risks. Key factors in this assessment include the suitability of candidates for cantilever-supported restorations, which depends on bone support and load distribution. While dual cantilever mechanisms hold promise, they introduce additional biomechanical stresses on both the implant and surrounding bone, demanding caution to prevent potential issues with implant or bone compromise.

A thorough assessment of the implant's clinical condition and the quality of the underlying bone is essential before proceeding with cantilever-based interventions. The extent to which a short-span ISFDP or an implant-sustained crown can exert functional loads on the jawbone without causing adverse complications depends on various factors, including bone composition, volume, implant shape, and design. A comprehensive approach is crucial to ensure the longevity of cantilever-based rehabilitation in modern implantology, considering these complex interplaying factors.

The proposed T-bridge offers a practical and straightforward treatment approach, particularly valuable for patients with financial constraints seeking complex fixed dental restorations that require multiple implants in a single area to replace multiple missing teeth. This approach is especially relevant for posterior edentulous spaces and free-end edentulous areas in the upper or lower jaw. The T-bridge's utility is improved by its potential to avoid delicate anatomical structures, such as the mental nerve or maxillary sinus. Thus, the T-bridge presents itself as a pragmatic and financially accessible option for addressing challenging clinical scenarios within reconstructive dentistry.

Despite advancements in implant-supported prosthetic configurations, occlusal overload, especially in cantilevered prostheses, remains clinically relevant. Prior studies consistently demonstrate that FDPs with cantilever result in similar marginal bone levels compared to non-cantilevered FDPs, irrespective of the spatial orientation of the cantilever extension (11,29,30). However, these studies have not explored into the specific design characteristics of cantilevered elements, emphasizing the need for focused investigations into their impact on implant-supported prostheses.

In our proof of concept, which explores a streamlined prosthetic design, we naturally consider the adequacy of implant support and stability, especially when crown-to-implant ratios exceed the conventional 1:1 threshold (28). While existing literature extensively examines this parameter, detailed insights or definitive contraindications against higher ratios remain unreported. We refrain from discouraging our study, particularly when implants are strategically placed in natural bone with dimensions accommodating the intended prosthetic structure. Larger implant dimensions, in terms of diameter and length, may increase stability and reduce overloading risks. The implant's dimensions can be tailored to the patient's bone density and quality for primary and long-term stability. Additionally, the prosthetic occlusal scheme can be engineered for uniform force distribution, alleviating concerns about high crown-to-implant ratios and avoiding overloading the solitary implant. Therefore, lighter contacts than two-implant abutments or tooth-supported FDPs cases are necessary. Additionally, it is essential to eliminate occlusal interferences, especially in the absence of proper axial loading, to mitigate the adverse effects of lateral forces, which are the most harmful to the fixture.

In our pursuit of the T-bridge innovation, careful consideration must be given to the dimensions, diameter, and length of the solitary implant, harmoniously tailored to the individual's bone density and quality. Equally crucial is the thoughtful management of occlusal load distribution, ensuring even distribution across implants and natural dentition to prevent excessive strain on a single implant. This approach embodies the essence of an implant-supported restoration, designed for optimal force distribution, support, and stability, facilitating appropriate bone remodeling while avoiding detrimental complications (18).

For instance, in the phase of patient selection for the case presented in Figure 3, we considered the contraindication of the T-bridge design for patients exhibiting bruxism due to the increased risk of mechanical complications associated with occlusal overload. During the planning phase, we opted for a design configuration including three premolars or a central molar with mesial and distal premolar pontic to mitigate the risk of cantilever-associated complications. This aligns with evidence suggesting that cantilevers beyond 7mm in length may predispose to a greater incidence of technical failures (29,31). For the implant planning and surgical intervention, we selected a central implant of regular diameter, considering studies indicating higher fracture rates associated with narrower implants, such as the Straumann TL 3.3 RN implants (32). Additionally, the chosen implant design featured an increased surface area, akin to the more aggressive designs, to reduce the risk of aseptic loosening, taking cues from clinical cases (33). The implant-abutment interface during prosthetic phase should also be considered (34). Thus, we opted for a design that provided a beveled or horizontal neck to ensure optimal force distribution and reduced stress concentration. Lastly, avoiding simultaneous guided bone regeneration (GBR) with implant



placement to preserve the cost-effectiveness of the T-bridge approach, was a critical aspect of our concept's proposition.

Polymers were useful for the initial in vitro study but fall short in mimicking zirconia's mechanical strength (35), particularly for fracture resistance and catastrophic failures. Hence, ex vivo studies may translate these early findings to actual clinical settings. These studies will better gauge the T-bridge's effectiveness and suitability for clinical use. Our preliminary research already shows substantial differences in fracture resistance between experimental and control polymer samples. Therefore, future studies will focus on zirconia to address these gaps and provide a more mechanical stability of the T-bridge's performance and clinical utility.

As we revised our manuscript, another research group published an in vitro study on a similar concept, comparing single-implant designs with mesial and distal extensions to traditional dual-implant setups (36). It examined the mechanical durability of monolithic zirconia ISFDPs, using Roxolid Tissue Level (TL) and TLX implants and found no significant differences in failure loads by implant type or configuration, though the design significantly impacted catastrophic fracture outcomes (36). These results further confirm the potential clinical efficacy of the single-implant T-bridge design underpinning our initial idea.

## **Conclusions**

The implementation of a T-bridge with a single middle implant and one pontic on each side may offer a cost-effective alternative to the conventional treatment of three-unit ISFDPs supported by two implants. However, this innovative approach necessitates careful attention to implant specifications, bone volume, remodeling dynamics, and occlusal scheme design to prevent adverse effects and complications. Preliminary in vitro data shows that while fracture resistance is superior in the conventional control group, the resistance of the introduced solution may still fall within an acceptable threshold for specific cases. Using a single implant in the T-bridge concept has the potential to reduce treatment costs and surgical requirements, yet full-scale preclinical studies are necessary to test this hypothesis and validate its clinical viability.

## **Zusammenfassung**

### *Einleitung*

Bilaterale Freidendbrücken, unterstützt von einem zentral platzierten Implantat – das T-Brücken-Konzept –, bieten einen innovativen Ansatz für die Versorgung dreigliedriger implantatgestützter fester Zahnprothesen (ISFDPs). Diese technische Hypothese beleuchtet die Durchführbarkeit einer solchen Konstruktion als kosteneffiziente Alternative zu herkömmlichen Verfahren. Die Planung dieses Konzepts erfordert gründliche Überlegungen hinsichtlich Implantatgröße, Positionierung, okklusalem Schema und Knochenumbau, um adäquate Unterstützung und Stabilität zu gewährleisten sowie Komplikationen zu vermeiden.

### *Material und Methoden*

Wir präsentieren einen Fall, der beispielhaft die bereits erfolgreiche klinische Anwendung des T-Brücken-Konzepts bei einem Patienten mit kompromittiertem Knochenangebot im posterioren Bereich zeigt. Zur Unterstützung des Konzepts werden umfangreiche präklinische Tests durchgeführt, einschließlich 3D-Finite-Elemente-Analyse (FEA) und Sammlung von In-vivo-Daten, um die mechanischen Eigenschaften des T-Brücken-Designs eingehend zu bewerten.

### *Resultate*

Der Fall zeigt ein Implantat, welches strategisch im Zentrum der geplanten dreigliedrigen Brückenarbeit positioniert und nach einer konventionellen Heilungsphase erfolgreich erfolgreich versorgt werden konnte. Die 24-monatige Nachsorge zeigte gesunde und stabile periimplantäre Gewebe und eine prothetische Rehabilitation mit ausgezeichneter Stabilität und Funktionalität, ohne pathologische Befunde im Zusammenhang mit dem Implantat.

Vorläufige Daten aus dem Labor zeigen eine akzeptable Bruchfestigkeit, die für Patienten ohne Parafunktionen oder mit weniger anspruchsvollen Kaukonditionen, durchaus geeignet zu sein scheint. Unsere zukünftige Forschung wird sich auf die Verwendung von Zirkonoxid konzentrieren, um die Beobachtungen aus diesen vorläufigen Studien weiter zu verfeinern.

### *Diskussion*

Diese Behandlungsmethode hat das Potenzial, die Implantologie zu revolutionieren, indem sie innovative und kostengünstige Optionen für Patienten mit partiellen ISFDs in spezifischen Situationen bietet. Weitere Forschung ist jedoch unerlässlich, um die klinischen Auswirkungen dieser innovativen Hypothese zu validieren. Die Implementierung der T-Brücke könnte zu einem Paradigmenwechsel in der klinischen Praxis führen und eine weniger invasive, kosteneffiziente Behandlungsoption für die Versorgung von verkürzten Zahnreihe oder grossen Frendlücken darstellen.

## **Résumé**

### *Introduction*

Les ponts bilatéraux cantilever ancrés sur un implant central (conception T-Bridge) représentent une avancée prometteuse pour les prothèses dentaires fixes implantaires (PDFI) de trois unités. Cette hypothèse technique explore la faisabilité de cette méthode en tant qu'alternative novatrice et économique aux traitements conventionnels. Une attention minutieuse doit être accordée aux spécifications de l'implant, au volume osseux, à la dynamique de remodelage osseux et à la conception du schéma occlusal pour prévenir les effets indésirables et les complications.

### *Matériels et méthodes*

Dans cet exposé technique, nous présentons un cas préliminaire mettant en œuvre cette nouvelle conception pour remplacer les dents postérieures manquantes chez un patient présentant des conditions osseuses étroites. De plus, une série de tests précliniques et de résultats préliminaires, y compris des études de simulation par éléments finis 3D et des

collections de données in vivo, sont détaillés pour illustrer notre concept et ses impacts cliniques potentiels.

### *Résultats*

Cliniquement, après un suivi d'un an, les tissus péri-implantaires sains et stables autour de la PDFI ont montré une excellente stabilité, fonctionnalité et confort, soutenus par des données de résistance à la fracture acceptables in vitro, suggérant ainsi le potentiel pratique et l'adéquation de cette approche.

Ainsi, nous soutenons que cette modalité de traitement a le potentiel de révolutionner la dentisterie implantaire en offrant des options de traitement innovantes et économiques pour les patients nécessitant des PDFI partielles dans des cas très spécifiques. Des recherches et évaluations supplémentaires sont nécessaires pour valider les implications cliniques de cette hypothèse innovante.

### *Discussion*

L'implémentation de l'approche T-Bridge avec un seul implant central et un pontique de chaque côté peut offrir une alternative rentable au traitement conventionnel des PDFI de trois unités soutenues par deux implants. Cependant, cette approche innovante nécessite une attention particulière aux spécifications de l'implant, au volume osseux, aux dynamiques de remodelage et à la conception du schéma occlusal pour prévenir les effets indésirables et les complications. Les données préliminaires in vitro indiquent une résistance à la fracture supérieure dans le groupe témoin (conventionnel) par rapport à la solution introduite, qui pourrait néanmoins être dans un seuil acceptable pour certains cas. Tandis que l'utilisation d'un seul implant dans le concept T-Bridge a le potentiel de réduire les coûts de traitement et les exigences chirurgicales, des études précliniques à grande échelle sont nécessaires pour tester cette hypothèse et valider sa viabilité clinique.

### **Acknowledgements**

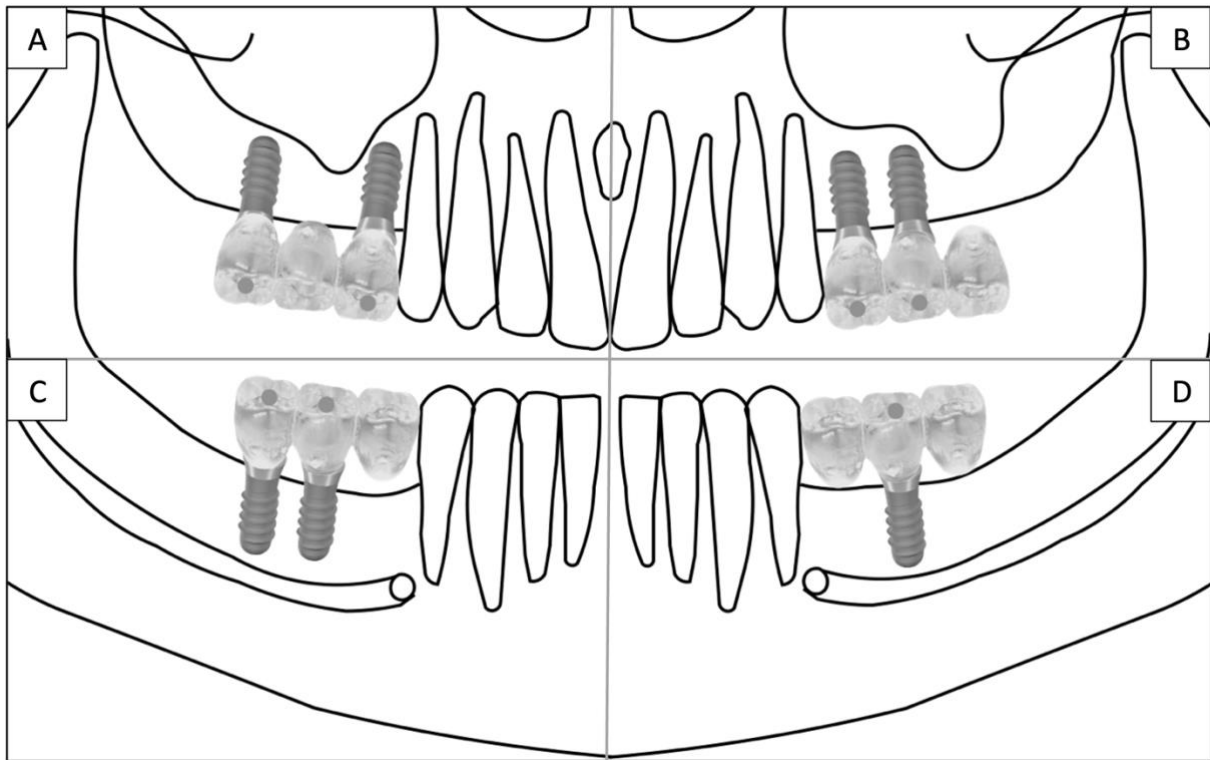
Prof. Dr. Afrashtehfar acknowledges the support of the Ajman University Deanship of Graduate Studies and Research for the Research Travel Grant awarded during the Spring 2023 cycle. Ms. Bernadette Rawyler, Scientific Illustrator at the Department of Multimedia, Dental Clinics of the University of Bern, is credited for sketching Figure 2. The authors declare no conflicts of interest related to this study.

## References

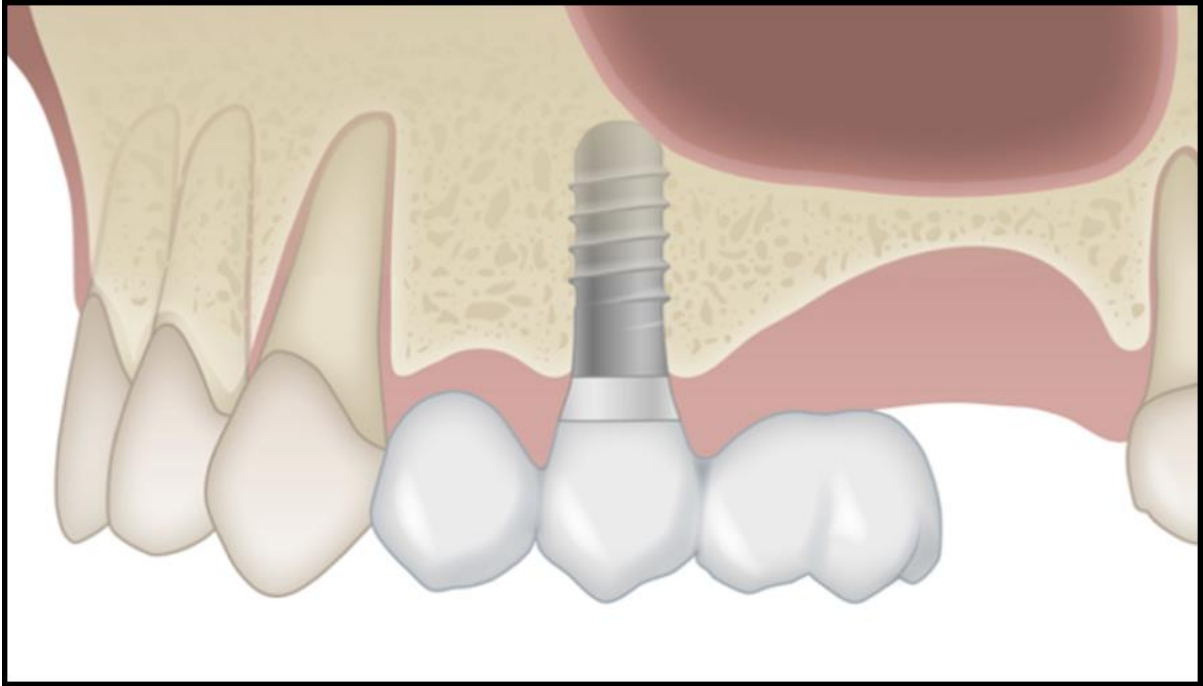
1. Naenni N, Sahrman P, Schmidlin PR, et al. Five-year survival of short single-tooth implants (6 mm): a randomized controlled clinical trial. *J Dent Res*. 2018;97:887-892.
2. Afrashtehfar KI, Del Fabbro M. Clinical performance of zirconia implants: A meta-review. *J Prosthet Dent*. 2020;123:419-426.
3. Lulic M, Brägger U, Lang NP, Zwahlen M, Salvi GE. Ante's (1926) law revisited: a systematic review on survival rates and complications of fixed dental prostheses (FDPs) on severely reduced periodontal tissue support. *Clin Oral Implants Res*. 2007;18(3):63-72.
4. Ghanem H, Afrashtehfar KI, Abi-Nader S, Tamimi F. Impact of a "TED-Style" presentation on potential patients' willingness to accept dental implant therapy: a one-group, pre-test post-test study. *J Adv Prosthodont*. 2015;7:437-445.
5. Dini C, Borges GA, Costa RC, Magno MB, Maia LC, Barão VAR. Peri-implant and esthetic outcomes of cemented and screw-retained crowns using zirconia abutments in single implant-supported restorations - A systematic review and meta-analysis. *Clin Oral Implants Res*. 2021;32:1143-1158.
6. Gamborena I, Sasaki Y, Blatz MB. Predictable immediate implant placement and restoration in the esthetic zone. *J Esthet Restor Dent*. 2021;33:158-172.
7. Vargas-Moreno VF, Ribeiro MCO, Gomes RS, Faot F, Del Bel Cury AA, Marcello-Machado RM. Clinical performance of short and extrashort dental implants with wide diameter: A systematic review with meta-analysis. *J Prosthet Dent*. 2023.
8. Ramanauskaite A, Sader R. Esthetic complications in implant dentistry. *Periodontol 2000*. 2022;88:73-85.
9. Rocuzzo A, Fanti R, Mancini L, Imber JC, Stähli A, Molinero-Mourelle P, et al. Implant-supported fixed dental prostheses with cantilever extensions: State of the art and future perspectives. *Int J Oral Implantol*. 2023;16:13-28.
10. Crothers AJ, Wassell RW, Jepson N, Thomason JM. The use of cantilever bridges. *Dent Update*. 1995;22:190-198.
11. Freitas da Silva EV, Dos Santos DM, Sonogo MV, De Luna Gomes JM, Pellizzer EP, Goiato MC. Does the Presence of a Cantilever Influence the Survival and Success of Partial Implant-Supported Dental Prostheses? Systematic Review and Meta-Analysis. *Int J Oral Maxillofac Implants*. 2018;33:815-823.
12. Ravidà A, Tattan M, Askar H, Barootchi S, Tavelli L, Wang HL. Comparison of three different types of implant-supported fixed dental prostheses: A long-term retrospective study of clinical outcomes and cost-effectiveness. *Clin Oral Implants Res*. 2019;30:295-305.
13. Frost HM. Bone's mechanostat: a 2003 update. *Anat Rec A Discov Mol Cell Evol Biol*. 2003;275:1081-1101.
14. Chen JH, Liu C, You L, Simmons CA. Boning up on Wolff's Law: mechanical regulation of the cells that make and maintain bone. *J Biomech*. 2010;43:108-118.
15. Fu JH, Hsu YT, Wang HL. Identifying occlusal overload and how to deal with it to avoid marginal bone loss around implants. *Eur J Oral Implantol*. 2012;5:S91-103.
16. Hsu YT, Fu JH, Al-Hezaimi K, Wang HL. Biomechanical implant treatment complications: a systematic review of clinical studies of implants with at least 1 year of functional loading. *Int J Oral Maxillofac Implants*. 2012;27:894-904.
17. Afrashtehfar KI, Afrashtehfar CD. Lack of association between overload and peri-implant tissue loss in healthy conditions. *Evid Based Dent*. 2016;17:92-93.
18. Sheridan RA, Decker AM, Plonka AB, Wang HL. The role of occlusion in implant therapy: a comprehensive updated review. *Implant Dent*. 2016;829-838.
19. Wang HL, Decker AM. Effects of occlusion on periodontal wound healing. *Compend Contin Educ Dent*. 2018;39:608-612; quiz 613.

20. Afrashtehfar KI, Moawad RA, F-EdDin AW, Wang HL. Mandibular full-arch fixed prostheses supported by three-dental-implants: A protocol of an overview of reviews. *PLoS One*. 2022;17:e0265491.
21. Di Fiore A, Montagner M, Sivoilella S, Stellini E, Yilmaz B, Brunello G. Peri-implant bone loss and overload: a systematic review focusing on occlusal analysis through digital and analogic methods. *J Clin Med*. 2022;11:4812.
22. Sadowsky SJ. Occlusal overload with dental implants: a review. *Int J Implant Dent*. 2019;5:29.
23. Yokoyama S, Wakabayashi N, Shiota M, Ohyama T. The influence of implant location and length on stress distribution for three-unit implant-supported posterior cantilever fixed partial dentures. *J Prosthet Dent*. 2004;91:234-240.
24. Yoda N, Liao Z, Chen J, Sasaki K, Swain M, Li Q. Role of implant configurations supporting three-unit fixed partial denture on mandibular bone response: biological-data-based finite element study. *J Oral Rehabil*. 2016;43:692-701.
25. Lü J, Liu C, Lan J, Gao X. [Three-dimensional finite element analysis of the effect of the location and diameter of implants on the stress distribution in three-unit implant-supported posterior cantilever fixed partial dentures under dynamic loads]. *Hua Xi Kou Qiang Yi Xue Za Zhi*. 2013;31:552-556.
26. Coello RJ, Aita-Holmes C, Dimalanta WG, Wenger K. An in vitro trial on the effect of arch form on connector size requirements in long span anterior zirconia fixed dental prostheses. *J Prosthodont*. 2022. [Online ahead of print].
27. Karasan D, Canay S, Sailer I, Att W. Zirconia cantilever fixed dental prostheses supported by one or two implants: an in vitro study on mechanical stability and technical outcomes. *Int J Oral Maxillofac Implants*. 2022;37:748-755.
28. Kobari H, Yoda N, Chen J, Kawata T, Sasaki K. An in vivo study on load distribution in different implant configurations for supporting fixed partial dentures. *Int J Oral Maxillofac Implants*. 2016;31:1049-1057.
29. Romeo E, Storelli S. Systematic review of the survival rate and the biological, technical, and aesthetic complications of fixed dental prostheses with cantilevers on implants reported in longitudinal studies with a mean of 5 years follow-up. *Clin Oral Implants Res*. 2012;23:39-49.
30. Storelli S, Del Fabbro M, Scanferla M, Palandrani G, Romeo E. Implant supported cantilevered fixed dental rehabilitations in partially edentulous patients: Systematic review of the literature. Part I. *Clin Oral Implants Res*. 2018;29:253-274.
31. Kim P, Ivanovski S, Latcham N, Mattheos N. The impact of cantilevers on biological and technical success outcomes of implant-supported fixed partial dentures. A retrospective cohort study. *Clin Oral Implants Res*. 2014;25:175-184.
32. Zumstein K, Waller T, Hämmerle CHF, Jung RE, Benic G, Mühlemann S. Clinical performance of monolithic zirconia crowns on titanium-zirconium reduced-diameter implants in the molar area: Interim data at three years of a randomized controlled trial. *Clin Oral Implants Res*. 2023;34:1354-1362.
33. Biel P, Biel T, Chappuis V, Raabe C. Re-osseointegration of a Dental Implant with Aseptic Loosening after Occlusal Correction: a Case Report. *Swiss Dent J*. 2022 Sep 5;132(9):599-606.
34. Mühlemann S. Implant-Prosthodontic Design in the Posterior Edentulous Maxilla. *Forum Implantologicum*. 2017;13(1):45675.
35. Mühlemann S, Truninger TC, Stawarczyk B, Hämmerle CH, Sailer I. Bending moments of zirconia and titanium implant abutments supporting all-ceramic crowns after aging. *Clin Oral Implants Res*. 2014;25:74-81.
36. Molinero-Mourelle P, Abou-Ayash S, Brägger U, et al. Load bearing capacity of 3-unit screw-retained implant-supported fixed dental prostheses with a mesial and distal cantilever on a single implant: A comparative in vitro study. *J Mech Behav Biomed Mater*. 2024;151:106395.

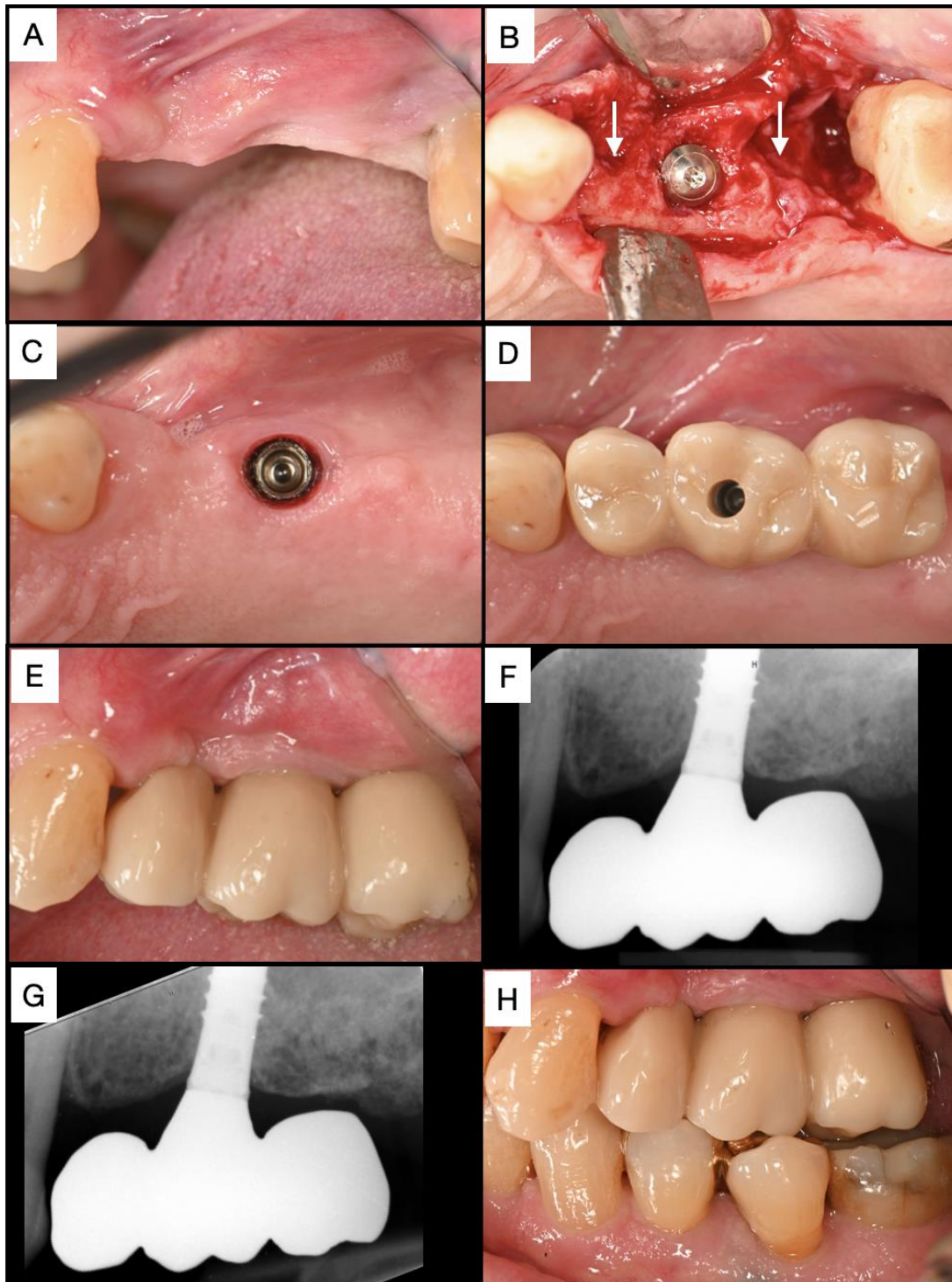
## Figures



**Figure 1.** Solutions for 3-unit implant-supported fixed dental prostheses. (A) Two implants with space between them and a pontic positioned in between. (B) Two implants placed next to each other with a distal cantilever. (C) Two implants placed next to each other with a mesial cantilever. (D) One central implant supporting a 3-unit bridge with bilateral cantilevers. *Note:* Figs. A-C illustrate the traditional approach where conventional bridges are supported by two implants. In contrast, Fig. D presents the T-bridge concept, a novel approach where a 3-unit bridge is supported by a single implant (3-in-1).

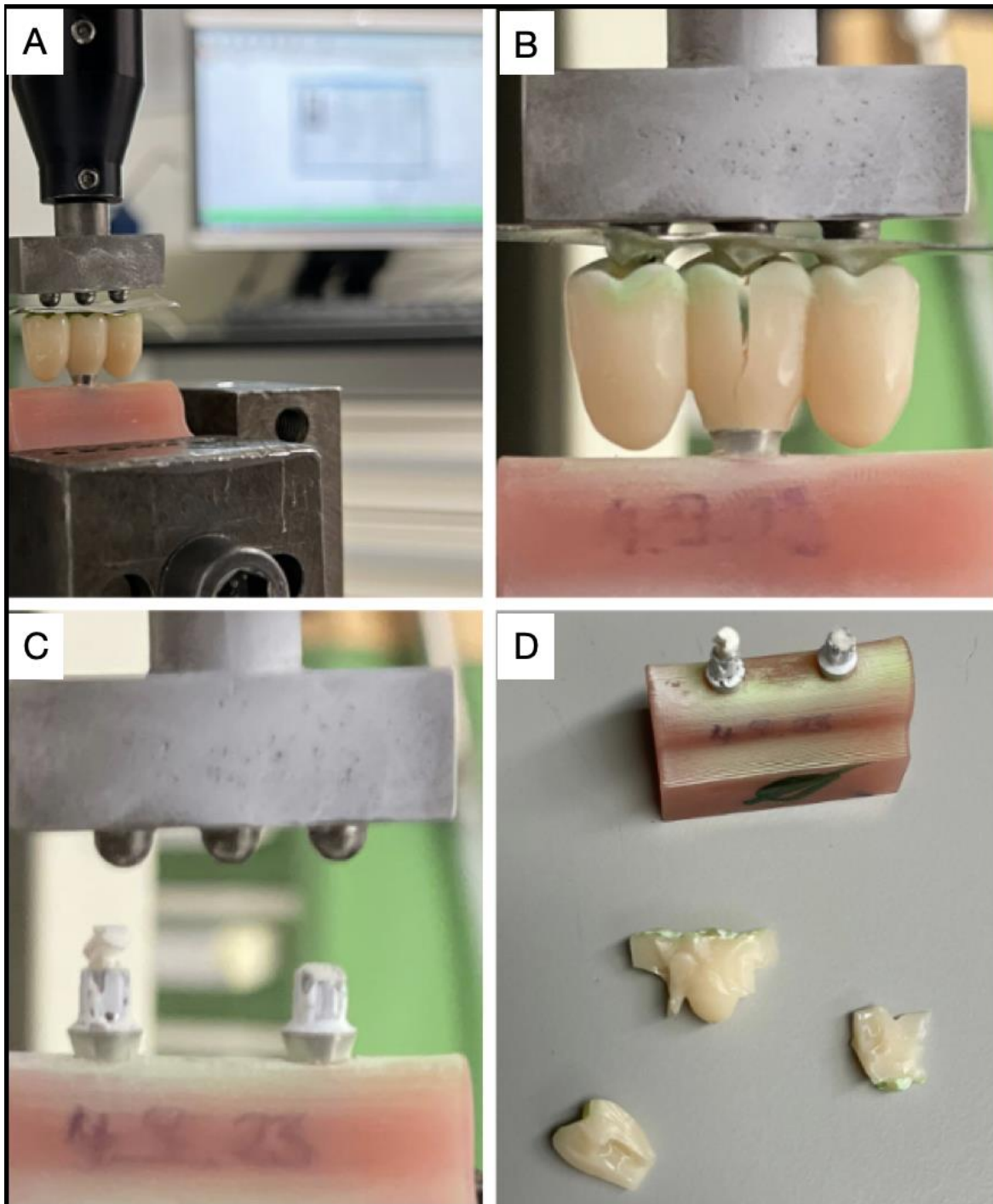


**Figure 2.** Solutions for 3-unit implant-supported fixed dental prostheses. (A) Two implants with space between them and a pontic positioned in between. (B) Two implants placed next to each other with a distal cantilever. (C) Two implants placed next to each other with a mesial cantilever. (D) One central implant supporting a 3-unit bridge with bilateral cantilevers. *Note:* Figs. A-C illustrate the traditional approach where conventional bridges are supported by two implants. In contrast, Fig. D presents the T-bridge concept, a novel approach where a 3-unit bridge is supported by a single implant (3-in-1).



**Figure 3.** Clinical and radiographic evidence of the T-bridge concept. (A) Preoperative view showing initial conditions. (B) Intra-surgical image depicting bone defects at mesial and distal aspects (indicated by arrows); (C) Occlusal intraoral view of the posterior edentulous left side (Quadrant #2) with an implant at the maxillary second premolar site. (D, E) Screw-retained 3-in-1 zirconia bridge observed after one year. (G, H) Periapical radiography displaying healthy marginal bone and stable surrounding tissues, confirming clinical and radiographic stability after the two-year post-loading follow-up (Treatment: Patrick R. Schmidlin, Dental Technology: Nicola Lanfranconi, Zurich).





**Figure 4.** Preliminary assessment of fracture resistance in acrylate polymer long-term temporary implant-supported fixed dental prostheses. (A) Setup for fracture load measurement. (B) Initial fracture trend in the 3-in-1 experimental group. (C) Comparison with the conventional specimen. (D) Fracture pattern in the conventional specimen.