Feasibility Study on Atrial Fibrillation Ablation with Pulsed Field Ablation and concomitant Occlusion of the Left Atrial Appendage

Short title: PFA plus LAAO

Jennifer Beney[1], Roberto Galea MD[1], Georgios Siontis MD[1], Christoph Gräni MD[1], Thomas Kueffer PhD[1], Nicolas Brugger MD[1], Tobias Reichlin MD[1], Lorenz Räber MD, PhD[1], Laurent Roten MD[1]

[1]Department of Cardiology, Inselspital, Bern University Hospital, University of Bern, Bern, Switzerland

Corresponding author

Prof. Dr. med. Laurent Roten

Department of Cardiology, Inselspital, University Hospital Bern, Freiburgstrasse, CH-3010 Bern, Switzerland

E-mail address: laurent.roten@insel.ch

Tel: +41 (0)31 632 52 63

What's new

- Simultaneous left atrial appendage occlusion and atrial fibrillation ablation utilizing pulsed field ablation is feasible and safe
- In patients with suitable left atrial appendage anatomy, the combined procedure can be executed within a short overall procedure duration
- Left atrial appendage occlusion adds <20 minutes to the overall procedure duration

Abstract

Background and Aims

Atrial fibrillation (AF) ablation and left atrial appendage occlusion (LAAO) are increasingly performed as individual procedures. Pulsed field ablation (PFA) has significantly reduced procedure duration and may be advantageous for the combined approach.

Methods

We have launched a program for simultaneous AF ablation using PFA and LAAO for patients qualifying for both treatments and excluding those with complex anatomy. We compare procedure duration and fluoroscopy time against individual procedures (either AF ablation or LAAO alone), all performed by the same operators and using consistent technologies.

Results

We performed the combined procedure in 10 patients (50% male; median age 70 years) and excluded two patients (17%) because of complex LAA anatomy. No death, stroke or major bleeding, including pericardial effusion, occurred. For single procedure comparison, 207 AF ablation procedures and 61 LAAO procedures were available. Total median procedure duration was 79 minutes (range 60; 125) for the combined procedure, 71 minutes (25; 241) for individual AF ablation (51 minutes without and 78 minutes with 3D electroanatomic mapping) and 47 minutes (15; 162) for individual LAAO. Respective fluoroscopy times were 21 (15; 26), 15 (5; 44) and 10 (3; 50) minutes. For the combined procedure, femoral vein access to last PFA application lasted 49 minutes (34; 93) and LAAO added 20 minutes (15; 37).

Conclusion

Simultaneous PFA-based AF ablation and LAAO in carefully selected patients is feasible, safe, and can be executed within a short overall procedure duration.

Keywords

Atrial fibrillation; Catheter ablation; Left atrial appendage occlusion; Pulmonary vein isolation; Pulsed field ablation

Abbreviations

AF	Atrial fibrillation
CCTA	Cardiac computed tomography angiography
LAA	Left atrial appendage
LAAO	Left atrial appendage occlusion
PFA	Pulsed field ablation
PVI	Pulmonary vein isolation
PWA	Posterior wall ablation
TOE	Transoesophageal echocardiography

Introduction

Catheter ablation is the preferred treatment for patients experiencing symptomatic atrial fibrillation (AF). Pulsed Field Ablation (PFA), a novel ablation technology, demonstrates enhanced efficacy and safety compared to traditional, purely thermal ablation methods.(1, 2) In the absence of conclusive data, patients at high thromboembolic risk typically continue oral anticoagulation therapy even after successful AF ablation. Left atrial appendage occlusion (LAAO) offers an alternative to oral anticoagulation for AF patients, especially those with a history of bleeding, or those who are unwilling or unable to maintain oral anticoagulation treatment.(3) With detailed, pre-procedural imaging of the left atrial appendage (LAA) and peri-interventional guiding by transesophageal echocardiography (TOE), LAAO has evolved into a procedure that is both safe and efficient.(4-6) While pulmonary vein isolation (PVI) and LAAO are both conducted in the left atrium and share the same access route, their combination is not conventionally practiced. However, technological advancements that enhance the safety and efficiency of PVI through PFA and reduce procedure duration, along with improvements in the design and implementation process of LAA occluders, make the concurrent application of these procedures more attractive. Furthermore, combining both interventions into a single procedure, rather than staging them in two separate procedures, provides an opportunity to reduce overall healthcare costs. In this report, we detail our initial experience with the simultaneous performance of PVI using PFA and LAAO in patients with favorable LAA anatomy.

Methods

Since August 2021, we have initiated a program of AF ablation using PFA and concomitant LAAO for patients who are candidates for both treatments and have favorable LAA anatomies. For this combined procedure, we exclusively utilized the Watchman FLX occluder (Boston Scientific, MA, US) for LAAO. Patients presenting with complex LAA anatomy, as determined by intraprocedural imaging or preprocedural cardiac computed tomography angiography (CCTA), were excluded from our study. This report details the outcomes of the initial patients who underwent the combined procedure of AF ablation and LAAO until the end of 2023, along with the characteristics of those who were excluded. The combined safety endpoint included death, cerebrovascular event, systemic embolism, major bleeding (BARC 3–5), clinically relevant pericardial effusion, device embolization, or acute kidney injury occurring within 7 days after LAAO. All individuals receiving AF ablation or LAAO at our institution are prospectively included in dedicated AF ablation and LAAO registries. Participation in the registries requires the provision of written informed consent from each patient. Both registries have received approval from the local ethics committee and are conducted in accordance with the declaration of Helsinki. To compare procedural characteristics, such as procedure duration, fluoroscopy time, and radiation dose, between combined procedures (AF ablation and LAAO) and single procedures (either AF ablation alone or LAAO alone), we aggregated and analyzed data from the two registries including procedures performed during the same time period by the same team of operators. For AF ablation, we only included procedures conducted using PFA. For LAAO, only those employing the Watchman FLX LAA occluder were considered.

Concomitant AF ablation and LAAO procedures

Patients scheduled for concomitant PVI and LAAO had a CCTA scan prior to the procedure to rule out left atrial thrombus and to assess LAA anatomy. The combined procedure was performed in general anesthesia. Venous access was obtained with ultrasound guidance. Transseptal puncture with a Brockenbrough needle was aimed at an inferior, posterior site,

guided by transesophageal echocardiography (TOE) imaging, either directly using the Faradrive sheath (Boston Scientific, USA) or a standard transseptal sheath that was then exchanged over the wire for the Faradrive sheath.(10) Heparin was administered after obtaining left atrial access to achieve an activated clotting time target of >350 seconds. A 3D electroanatomical mapping system was used in the first three cases and in both of the redo cases. For PVI or posterior wall ablation (PWA) the Farawave catheter and the Farastar generator (Boston Scientific, USA) were used, as described elsewhere.(11, 12) For PVI, a minimum of 4 applications at 2 kV were delivered in both the basket and flower configuration to each of the pulmonary veins (Figure 1A and 1B). For PWA, four anchor lesions to each vein were delivered with the catheter in flower configuration, wired pulmonary vein and with posterior torque to the sheath and catheter. Additional PFA applications in flower configuration and with retracted wire were applied to cover the entire posterior wall.(12) Successful, acute PVI and PWA was verified by 3D-electroanatomical mapping or, for PVI, by using the Farawave catheter in a basket configuration in all PVs for assessment of entrance and exit block.(11)

Once ablation was completed, the Farawave sheath was exchanged over a stiff 0.035" wire for the Watchman delivery sheath (Boston Scientific, USA). Left atrial appendage (LAA) angiography, coupled with precise measurements of the LAA via transesophageal echocardiography (TOE), was employed to accurately size the Watchman FLX device (Boston Scientific, USA). Subsequently, left atrial appendage occlusion (LAAO) was executed in adherence to the prescribed instructions for use and in alignment with the latest guidelines (Figure 1C).

Follow-up

All patients were followed after 3, 6, and 12 months post-ablation to screen for atrial arrhythmias, usually with a 7-day Holter ECG, supplemented by a 12-lead ECG in the event of symptomatic episodes. Recurrence of atrial arrhythmia was defined as episodes of atrial fibrillation, flutter, or tachycardia lasting longer than 30 seconds. To assess the positioning of

the left LAAO, detect peri-device leaks, and identify any device-related thrombi, all patients received a TOE and/or a CCTA 45 days following the procedure.

Statistical analysis

Continuous variables, when not normally distributed, are reported as medians with their respective ranges. Categorical variables are expressed in terms of frequencies and percentages.

Results

Patient characteristics

Between August 2021 and December 2023, we successfully performed concomitant AF ablation using PFA and LAAO in 10 patients. Details on patient demographics are presented in Table 1. Among these, eight patients were first AF ablation procedures and the remaining two cases were redo procedures. The indications for LAAO included a history of bleeding in seven patients (70%), personal preference in two (20%), and intolerance to oral anticoagulants in one (10%). Two candidates were not considered for the combined treatment due to complex LAA anatomies, as depicted in Figure 2. One patient, with a history of gastrointestinal bleeding, underwent LAAO three months later, employing two 16 mm Amplatzer Occluders to seal a bi-lobulated LAA configuration. The second patient opted out of the initially scheduled LAAO procedure, based on personal preference.

Procedural characteristics

In the 8 patients with first AF ablation, only PVI was performed. In the 2 redo procedures, reconnected veins were re-isolated and the posterior wall was targeted for ablation. A 3D electroanatomic mapping system was used in both redo cases and in three first AF ablation procedures. The median size of the implanted Watchman FLX device was 24 mm (range 20 mm to 27 mm). For single procedure comparison, we aggregated 207 AF ablation procedures conducted using PFA and 61 LAAO procedures using the Watchman FLX LAA

occluder. Among the 207 AF ablation procedures, 137 patients (66%) had paroxysmal AF and 139 (67%) were first AF ablation procedures. A 3D electroanatomical mapping system was employed in 152 of the AF ablation cases (73%). Among the LAAO procedures, median size of the Watchman FLX LAA occluder was 24 mm (range 20 mm; 35 mm). Procedural characteristics of the combined and single procedures are shown in Table 2 and Figure 3. Median procedure time was 79 minutes (range 60; 125 minutes) for the combined procedure, compared to 71 minutes for individual PFA-based AF ablation (25; 241 minutes) and 47 minutes for LAAO (15; 162 minutes). Individual PFA-based AF ablation was 51 minutes without and 78 minutes with 3D electroanatomic mapping during the procedure. Overall, LAAO added 20 minutes (15; 37 minutes) to overall procedure length in the combined procedure. Fluoroscopy time of the combined procedure increased by a median of 6 and 11 minutes compared to individual PFA-based AF ablation and LAAO, respectively (Table 2 and Figure 3).

Procedural safety

No safety endpoint occurred. One patient experienced minor hemoptysis the day following the procedure, which resolved without intervention. No further adverse events were reported.

Follow-Up

Post-procedure, oral anticoagulation therapy was maintained for three months across all patients, after which it was discontinued. Thereafter, either acetylsalicylic acid or clopidogrel was prescribed for 12 months in five patients (50%), and indefinite in the remaining five patients (50%) due to coronary artery disease. TOE and/or CCTA 45 days after the procedure was performed in all patients (8 patients had both TOE and CCTA, one patient only TOE and one only CCTA) and showed no device-related thrombus and correct position of the LAAO. Five patients showed in CCTA LAA patency without intra- or peridevice leaks, whereas two patients showed intra-device leaks, one a mixed intra-/peridevice leak and one showed neither a leak nor patency. After a mean follow-up of 9 months (range 3 - 12 months), 3 patients (30%) had arrhythmia recurrence.

Discussion

Our initial experience in 10 patients indicates that concomitant PFA-based AF ablation and LAAO can be conducted safely and with high procedural efficacy. The median procedure duration was only 79 minutes, and the added LAAO increased the procedure duration by only 20 minutes beyond the last PFA application. Conversely, at our center, the duration of PFA-based AF ablation with and without the use of 3D electroanatomical mapping was 78 and 51 minutes, respectively, while the time for LAAO performed independently was 47 minutes. Similarly, the fluoroscopy time for the combined procedure exhibited a modest increase to 21 minutes, extending only by 6 minutes compared to PFA-based AF ablation alone, and by 11 minutes when compared to LAAO performed singly.

In comparison, the largest published multi-center, prospective registry, which includes data on combined LAAO and AF ablation procedures from the pre-PFA era, reported a mean procedural time of 177 minutes and a mean fluoroscopy time of 31 minutes. Radiofrequency ablation was employed in the majority of these cases.(14) Another study, which utilized cryoablation for AF ablation, reported a mean procedure time of 148 minutes, with cryoablation accounting for an average of 107 minutes and LAAO requiring 40 minutes.(15) PFA-based AF ablation is recognized for its shorter procedure duration compared to AF ablation involving thermal energies.(16) Indeed, in the hands of experienced operators, the mean procedure duration of PFA-based AF ablation is typically less than one hour.(17) Additionally, the duration of left atrial appendage occlusion (LAAO) can be further minimized through the pre-selection of patients with anatomies suitable for the procedure. This strategic combination has enabled the further reduction of procedure duration relative to those reported in published studies. Importantly, this also contributes to decreased left atrial dwell time, which is relevant, as prolonged left atrial dwell times are linked to increased procedural risks.(18) A pre-procedural CCTA scan is not mandatory, as the procedure can be effectively performed using intra-procedural TEE alone. However, the advantage of a pre-procedural

CCTA scan lies in its ability to clarify the LAA anatomy, which can aid in procedural planning. For instance, in cases of complex anatomy, it may be preferable to conduct two separate procedures instead of a concomitant one.

Radiofrequency ablation can result in considerable edema formation, which increases the thickness of the left atrial ridge following the isolation of the left superior pulmonary vein.(19) In contrast, PFA is associated with less edema formation.(20) This reduced edema formation is another advantage of PFA over thermal energies as it has the potential to improve LAAO outcomes by facilitating more accurate device sizing and placement, thereby enhancing the overall safety and efficacy of the combined procedure.

Strategically, our approach for the combined procedure begins with AF ablation and concludes with LAAO for two primary reasons. Firstly, this sequence minimizes the risk of occluder displacement during the manipulation of the left pulmonary veins. Secondly, it avoids the potential for PFA energy short-circuiting during the ablation of the left superior pulmonary vein. This concern is particularly relevant with the Amplatzer Amulet LAA occluder, because its disc that protrudes out of the LAA may come into contact with the electrodes on the splines of the PFA catheter during isolation of the left superior pulmonary vein.(21)

Previous analyses from multicenter registries have reported low rates of adverse events associated with the concurrent performance of AF ablation and LAAO.(22, 23) Similarly, the long-term efficacy of the combined procedure, in terms of both AF-free survival and the prevention of embolic events, has yielded favorable results.(24) To date, only few cases have been published of PFA-based AF ablation and concomitant LAAO.(25, 26) As the number of PFA procedures continues to increase rapidly, it is likely that we will soon see larger studies emerge that report on the concurrent use of PFA-based AF ablation and LAAO. These studies will enhance our understanding of the safety and efficacy of this combined approach.

Two pivotal randomized controlled trials are currently underway, which may further pave the way for the combination of these procedures. Firstly, the OCEAN trial is designed to assess

the need for continued oral anticoagulation following successful AF ablation.(27) Secondly, the OPTION trial aims to determine whether LAAO is noninferior to oral anticoagulation in patients after pulmonary vein isolation.(28) These trials may significantly influence clinical practice by providing evidence-based guidance on the management of patients post AF ablation and boost the number of combined procedures in the future. In light of this, the combination of PFA-based AF ablation with LAAO may come in very handy.

Limitations

As a retrospective analysis, this study is subject to the inherent limitations characteristic of its design. Notably, our cohort of patients undergoing the combined procedure is small, and larger studies are necessary to verify these preliminary findings.

Conclusions

Simultaneous PFA-based AF ablation and LAAO using the Watchman FLX device in patients with suitable LAA anatomy is feasible and safe, and can be performed within a short overall procedure duration. Adding LAAO to PFA-based AF ablation prolongs procedure time by less than 20 minutes.

Funding Statement/Financial dislosures

No funding was obtained for this study.

T. Reichlin: Research grants from the Swiss National Science Foundation, the Swiss Heart Foundation, the sitem insel support fund, Biotronik, Boston Scientific and Medtronic, all for work outside the submitted study. He has received speaker/consulting honoraria or travel support from Abbott/SJM, Biosense-Webster, Biotronik, Boston Scientific and Medtronic. He has received support for his institution's fellowship program from Abbott/SJM, Biosense-Webster, Biotronik, Boston-Scientific and Medtronic.

C. Gräni received funding from the Swiss National Science Foundation, InnoSuisse, Center for Artificial Intelligence in Medicine University Bern, GAMBIT foundation, Novartis

Foundation for Medical-Biological Research, Swiss Heart Foundation, outside of the submitted work. Dr. Gräni serves as Editor-in-Chief of The International Journal of Cardiovascular Imaging, Springer.

T. Kueffer has received research grants from the Swiss Heart Foundation for work outside the submitted study.

R. Galea has received speaker fees / honoraria from Boston Scientific.

L. Räber received research grants to the institution by Abbott, Boston Scientific, Heartflow, Infraredx, Sanofi, Swiss National Science Foundation, and Regeneron and speaker/consultation fees by Abbott, Amgen, Biotronik, Canon, Gentuitity, Novo Nordisc, Medtronic, Occlutech, and Sanofi.

L. Roten has received research grants from Medtronic, the Swiss National Foundation, the Swiss Heart Foundation, the Immanuel and Ilse Straub Foundation and the Sitem Insel Support Fund, all for work outside the submitted study. He has received speaker fees / honoraria from Biosense Webster, Boston Scientific, Abbott and Medtronic.

All remaining authors have declared no conflicts of interest.

Data Availability Statement

All relevant data are within the manuscript and its Supporting Information files.

References

1. Ekanem E, Reddy VY, Schmidt B, Reichlin T, Neven K, Metzner A, et al. Multi-national survey on the methods, efficacy, and safety on the post-approval clinical use of pulsed field ablation (MANIFEST-PF). Europace. 2022;24(8):1256-66.
2. Lemoine MD, Fink T, Mencke C, Schleberger R, My I, Obergassel J, et al. Pulsed-field ablation-based pulmonary vein isolation: acute safety, efficacy and short-term follow-up in a multi-center real world scenario. Clin Res Cardiol. 2023;112(6):795-806.
3. Potpara T, Grygier M, Hausler KG, Nielsen-Kudsk JE, Berti S, Genovesi S, et al. Practical guide on left atrial appendage closure for the non-implanting physician: an international consensus paper. Europace. 2024;26(4).
4. Boersma LV, Schmidt B, Betts TR, Sievert H, Tamburino C, Teiger E, et al. Implant success and safety of left atrial appendage closure with the WATCHMAN device: peri-procedural outcomes from the EWOLUTION registry. Eur Heart J. 2016;37(31):2465-74.
5. Galea R, Aminian A, Meneveau N, De Marco F, Heg D, Anselme F, et al. Impact of Preprocedural Computed Tomography on Left Atrial Appendage Closure Success: A Swiss-Apero Trial Subanalysis. JACC Cardiovasc Interv. 2023;16(11):1332-43.
6. Galea R, Raber L, Fuerholz M, Haner JD, Siontis GCM, Brugger N, et al. Impact of Echocardiographic Guidance on Safety and Efficacy of Left Atrial Appendage Closure: An Observational Study. JACC Cardiovasc Interv. 2021;14(16):1815-26.
7. Galea R, De Marco F, Meneveau N, Aminian A, Anselme F, Grani C, et al. Amulet or Watchman Device for Percutaneous Left Atrial Appendage Closure: Primary Results of the SWISS-APERO Randomized Clinical Trial. Circulation. 2022;145(10):724-38.
8. Galea R, Mahmoudi K, Grani C, Elhadad S, Huber AT, Heg D, et al. Watchman FLX vs. Watchman 2.5 in a Dual-Center Left Atrial Appendage Closure Cohort: the WATCH-DUAL study. Europace. 2022;24(9):1441-50.
9. Price MJ, Friedman DJ, Du C, Wang Y, Lin Z, Curtis JP, et al. Comparative Safety of Transcatheter LAAO With the First-Generation Watchman and Next-Generation Watchman FLX Devices. JACC Cardiovasc Interv. 2022;15(21):2115-23.

10. Kueffer T, Madaffari A, Thalmann G, Muhl A, Galuszka O, Baldinger S, et al. Eliminating transseptal sheath exchange for pulsed field ablation procedures using a direct over-the-needle transseptal access with the Faradrive sheath. Europace. 2023;25(4):1500-2.

11. Kueffer T, Baldinger SH, Servatius H, Madaffari A, Seiler J, Muhl A, et al. Validation of a multipolar pulsed-field ablation catheter for endpoint assessment in pulmonary vein isolation procedures. Europace. 2022;24(8):1248-55.

12. Kueffer T, Tanner H, Madaffari A, Seiler J, Haeberlin A, Maurhofer J, et al. Posterior wall ablation by pulsed-field ablation: procedural safety, efficacy, and findings on redo procedures. Europace. 2023;26(1).

13. Glikson M, Wolff R, Hindricks G, Mandrola J, Camm AJ, Lip GYH, et al. EHRA/EAPCI expert consensus statement on catheter-based left atrial appendage occlusion - an update. Europace. 2020;22(2):184.

14. Phillips KP, Pokushalov E, Romanov A, Artemenko S, Folkeringa RJ, Szili-Torok T, et al. Combining Watchman left atrial appendage closure and catheter ablation for atrial fibrillation: multicentre registry results of feasibility and safety during implant and 30 days follow-up. Europace. 2018;20(6):949-55.

15. Fassini G, Gasperetti A, Italiano G, Riva S, Moltrasio M, Dello Russo A, et al. Cryoballoon pulmonary vein ablation and left atrial appendage closure combined procedure: A long-term follow-up analysis. Heart Rhythm. 2019;16(9):1320-6.

16. Reddy VY, Gerstenfeld EP, Natale A, Whang W, Cuoco FA, Patel C, et al. Pulsed Field or Conventional Thermal Ablation for Paroxysmal Atrial Fibrillation. N Engl J Med. 2023;389(18):1660-71.

17. Schmidt B, Bordignon S, Tohoku S, Chen S, Bologna F, Urbanek L, et al. 5S Study: Safe and Simple Single Shot Pulmonary Vein Isolation With Pulsed Field Ablation Using Sedation. Circ Arrhythm Electrophysiol. 2022;15(6):e010817.

18. Medi C, Evered L, Silbert B, Teh A, Halloran K, Morton J, et al. Subtle post-procedural cognitive dysfunction after atrial fibrillation ablation. J Am Coll Cardiol. 2013;62(6):531-9.

19. Li XX, Tian Y, Shi L, Wang YJ, Zeng LJ, Huang LH, et al. One-stop hybrid procedure combining catheter ablation and left atrial appendage closure increases long-term risk for adverse events in patients with atrial fibrillation. Pacing Clin Electrophysiol. 2020;43(11):1358-65.

20. Nakatani Y, Sridi-Cheniti S, Cheniti G, Ramirez FD, Goujeau C, Andre C, et al. Pulsed field ablation prevents chronic atrial fibrotic changes and restrictive mechanics after catheter ablation for atrial fibrillation. Europace. 2021;23(11):1767-76.

21. Audiat C, Della Rocca DG, de Asmundis C, Chierchia GB. Interference from Lobe-and-Disc Left Atrial Appendage Occluder Affecting Left Superior Pulmonary Vein Pulsed Field Ablation. Heart Rhythm. 2024.

22. Phillips KP, Romanov A, Artemenko S, Folkeringa RJ, Szili-Torok T, Senatore G, et al. Combining left atrial appendage closure and catheter ablation for atrial fibrillation: 2-year outcomes from a multinational registry. Europace. 2020;22(2):225-31.

23. Wintgens L, Romanov A, Phillips K, Ballesteros G, Swaans M, Folkeringa R, et al. Combined atrial fibrillation ablation and left atrial appendage closure: long-term follow-up from a large multicentre registry. Europace. 2018;20(11):1783-9.

24. Qu J, Wang Z, Wang S. Effect of catheter ablation combined with left appendage occlusion for non-valvular atrial fibrillation: a meta-analysis. J Cardiothorac Surg. 2022;17(1):132.

25. Bianchini L, Moltrasio M, Fassini G, Cellucci S, Sicuso R, Ribatti V, et al. Pulsed-field ablation of pulmonary vein and left atrial posterior wall combined with left atrial appendage occlusion as single procedure. Pacing Clin Electrophysiol. 2023.

26. Mills MT, Calvert P, Velavan P, Lip GYH, Gupta D. Concurrent percutaneous left atrial appendage occlusion and catheter ablation for atrial fibrillation: State-of-the-art review. Trends Cardiovasc Med. 2023.

27. Verma A, Ha ACT, Kirchhof P, Hindricks G, Healey JS, Hill MD, et al. The Optimal Anti-Coagulation for Enhanced-Risk Patients Post-Catheter Ablation for Atrial Fibrillation (OCEAN) trial. Am Heart J. 2018;197:124-32.

28. Wazni OM, Boersma L, Healey JS, Mansour M, Tondo C, Phillips K, et al. Comparison of anticoagulation with left atrial appendage closure after atrial fibrillation ablation: Rationale and design of the OPTION randomized trial. Am Heart J. 2022;251:35-42.

Figure legends

Figure 1

Over-the-wire, 31 mm multipolar pulsed field ablation catheter. A) Front view, side view, and x-ray image with the catheter located in the LSPV ostium, all in the basket configuration. B) Further deployment of the catheter results in the “flower” configuration. All electrodes are active during ablation and rotation of the device between applications ensures complete circumferential pulmonary vein isolation. C) View of the left atrial appendage occluder and x-ray image of the occluder implanted in the left atrial appendage.

Figure 2

Left atrial appendage anatomy of excluded cases. A) Left atrial appendage with a chicken wing configuration and insufficient depth for placement of a Watchman FLX LAAO. B) Left atrial appendage with a bi-lobulated configuration. C) Closure of the bi-lobulated left atrial appendage employing two 16 mm Amplatzer Occluders.

Figure 3

Bar graphs showing the respective procedure and fluoroscopy times for the combined and single procedures.

Tables

Table 1. Baseline characteristics of patients undergoing concomitant atrial fibrillation ablation and left atrial appendage occlusion.

Patient characteristics	**N = 10**
Age, years	70 (62; 76)
Male sex	5 (50%)
Hypertension	7 (70%)
Diabetes mellitus	1 (10%)
History of ischemic stroke or transient ischemic attack	-
Coronary artery disease	5 (50%)
History of arterial embolism	1 (10%)
$CHAD_2DS_2Vasc$ Score	2.5 (2; 4)
HAS-BLED Score	3 (1; 4)
Paroxysmal atrial fibrillation	4 (40%)
Persistent atrial fibrillation	6 (60%)
Left Ventricular Ejection Fraction, %	65 (40; 65)
Bleeding history	7 (70%)
Intracranial bleeding history	1 (10%)
Gastrointestinal bleeding history	3 (30%)

Shown are numbers with percentages in parentheses or median with range.

Table 2. Procedural characteristics of patients undergoing concomitant or single procedures.

Procedural characteristics	**Combined procedures N = 10**	**AF ablation only N = 207**			**LAAO only N = 61**
		All	With 3D-EAM N =152	Without 3D-EAM N=55	
Total procedural time, min.	79 (60; 125)	71 (25; 241)	78 (37; 241)	51 (25; 189)	47 (15; 162)
Vein access to transseptal puncture, min.	10 (2; 27)	-	-	-	-
First to last PFA application, min.	24 (17; 43)	-	-	-	-
Transseptal puncture to last PFA application, min.	38 (27; 79)	-	-	-	-
Vein access to last PFA application, min.	49 (34; 93)	-	-	-	-
Last PFA application to occluder insertion, min.	14 (10, 29)	-	-	-	-
LAA occluder insertion to release, min.	5 (2; 17)	-	-	-	-
Last PFA application to LAA occluder release, min.	20 (15;37)	-	-	-	-
Fluoroscopy time, min	21 (15; 26)	15 (5; 44)	15 (5; 44)	15 (6; 30)	10 (3; 50)

Radiation dose, cGy·cm²	1539 (191; 10323)	431 (52; 46’527)	445 (73; 46’527)	367 (52; 10’323)	2’476 (874; 3’2721)

Shown are numbers with percentages in parentheses or medians with ranges. 3D-EAM: 3 dimensional electroanatomical mapping; LAA: left atrial appendage; LAAO: left atrial appendage occlusion; PFA: pulsed field ablation.

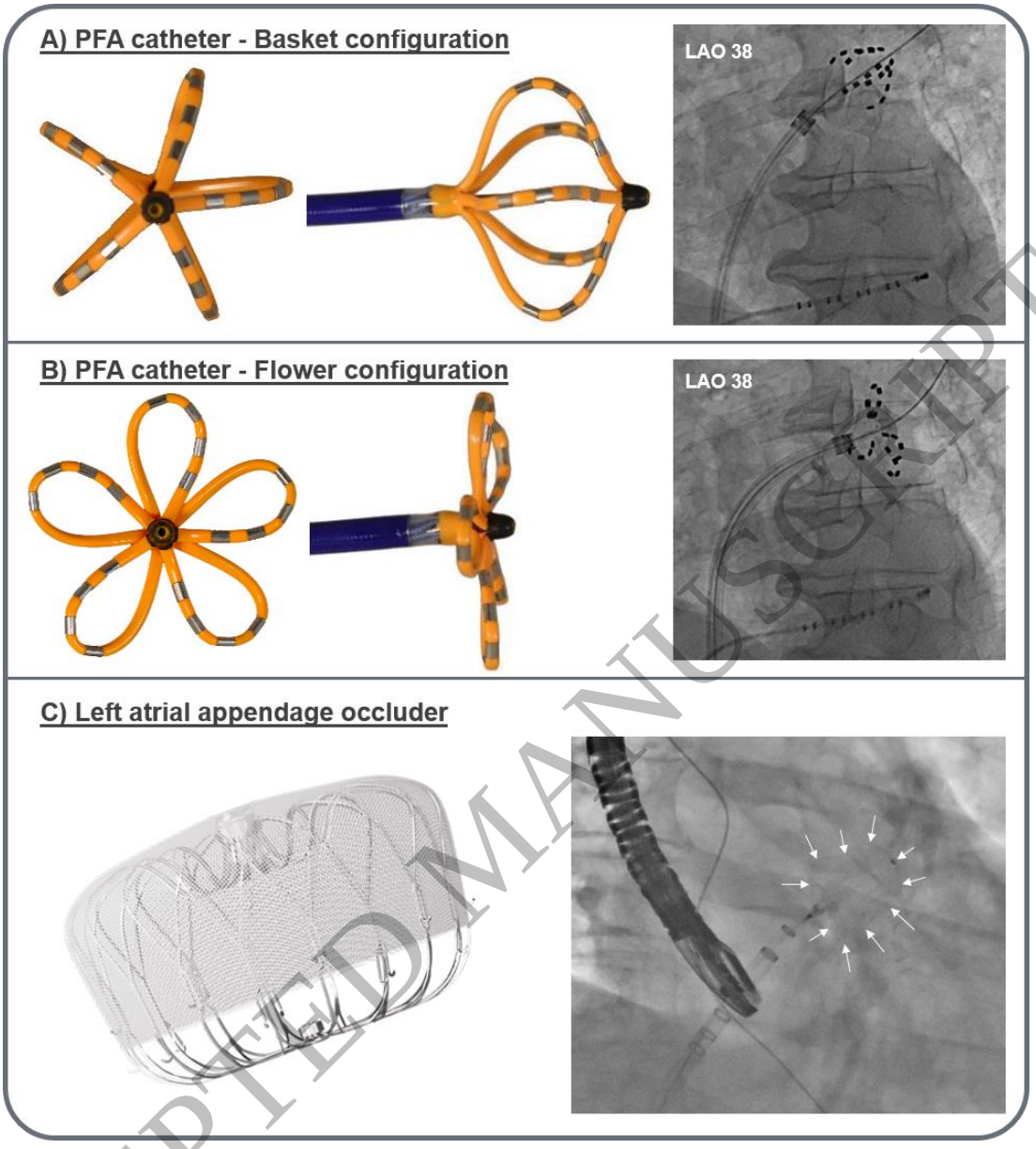

Figure 1
145x160 mm (x DPI)

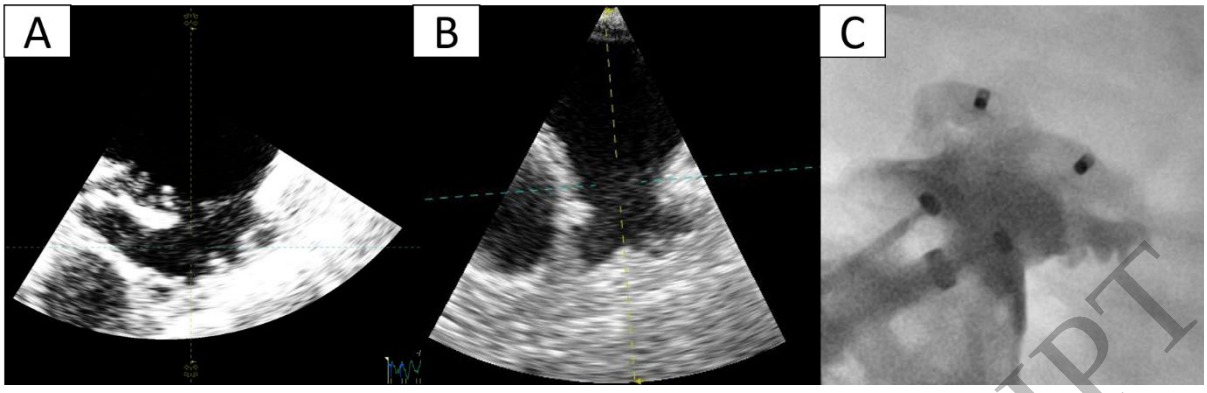

Figure 2
252x83 mm (x DPI)

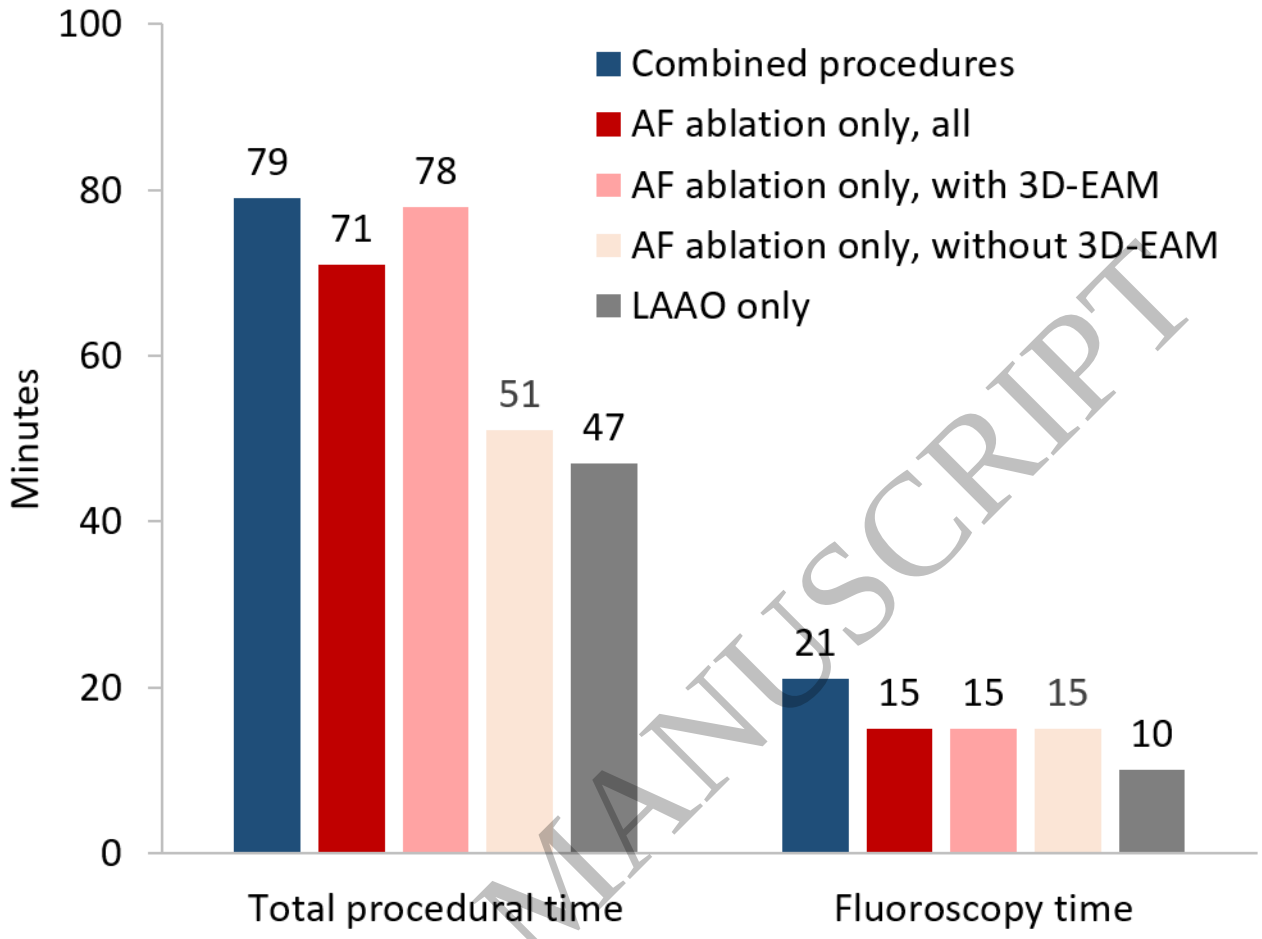

Figure 3
181x130 mm (x DPI)

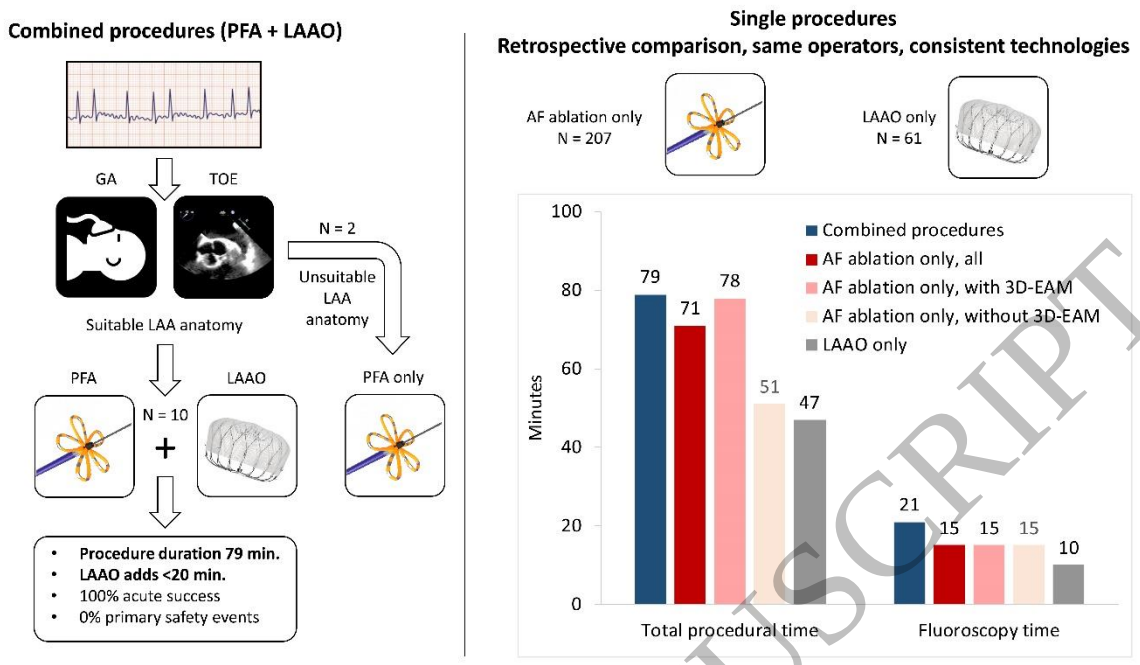

Graphical Abstract