

Splenic Artery Aneurysm Occlusion by Overlapping Gore® Viabahn® Endoprosthesis Devices: A Piece of Cake or - Once in a While - a Real Challenge

Nando Mertineit², Amgad El Mekabaty², Gholam Reza Afarideh³, Carlos Buitrago Tellez², Pascal Kissling³, Stefanie Garni¹, Frank Mosler¹, Gerd Nöldge²

¹Department of Diagnostic, Interventional and Pediatric Radiology, Inselspital, Bern University Hospital, University of Bern, Bern, Switzerland

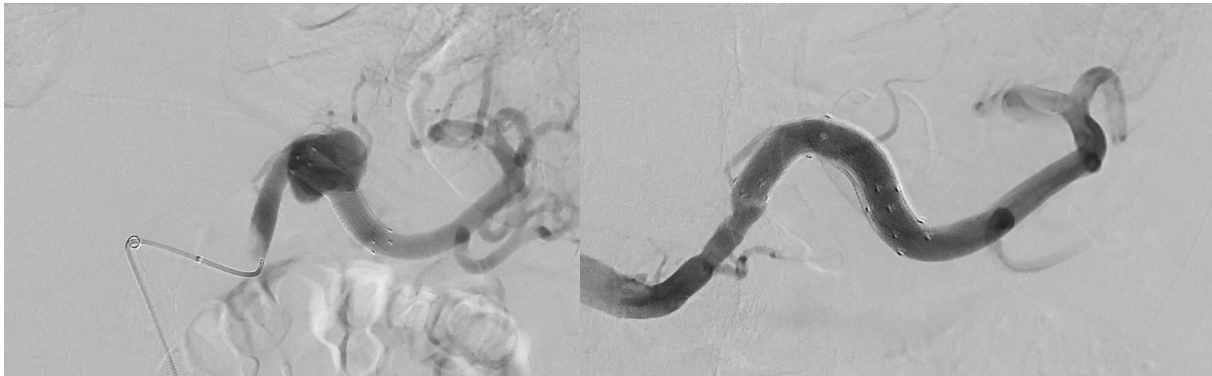
²Institut für Medizinische Radiologie (IMR) Bürgerspital Solothurn, Solothurn, Switzerland

³Gefässzentrum Bürgerspital Solothurn, Solothurn, Switzerland

Swiss Journal of Radiology and Nuclear Medicine - www.sjoranm.com - SJORANM GmbH - CH-3072 Ostermundigen bei Bern - Switzerland

Abstract

The first lienal artery aneurysm was discovered and described for the first time in 1770 by the Frenchman Beaussier during an autopsy. It was first visualised using X-rays in 1920 by the physicians Akbulut and Otan. The first surgical treatment of a splenic artery aneurysm was performed by surgeons MacLeod and Maurice in 1940. The first minimally invasive endovascular therapies using coils, stents or a combination of the two devices for minimally invasive treatment of aneurysms of the lienal artery were reported in 1990, 1994 and 1995 (1,2,3). 63-year-old patient with a known aneurysmal



arteriopathy of the thoracic aorta in the sense of an aortic dissection in coexistence with a 2.2 cm splenic artery aneurysm discovered by chance in the vascular surgery department of the Bürgerspital Solothurn. The interdisciplinary consensus primarily favoured vascular surgery or minimally invasive transcatheter treatment to eliminate the splenic artery aneurysm. The dissected thoracic aortic aneurysm detected in the pre-interventional CT of the thorax and abdomen, extending into the abdominal aorta, (Fig. 1) should only be treated with minimally invasive endovascular treatment using EVAR after stenting of the lienal artery aneurysm detected by CT (Fig. 9, 10, 11). A reverse therapeutic sequence would have allowed access to the lienal artery aneurysm only by fenestration of the EVAR. For the treatment of our patient's wide-neck aneurysm, the use of a Viabahn was chosen from the many known and proven occlusion materials as a significantly less invasive alternative to surgical treatment of the aneurysm by interdisciplinary consensus. Due to a technical complication during the deployment of the first vial, a two-stage angiographic therapeutic intervention was necessary.

Keywords: Occlusion of splenic artery aneurysm, overlapping of 2 stent-grafts, Gore®Viabahn® Endoprosthesis, two steps deployment

²Corresponding author: [Nando Mertineit](mailto:Nando.Mertineit@inselspital.ch) - received: 02.07.2024 - published: 31.07.2024

Introduction

The first lienal artery aneurysm was discovered and described for the first time in 1770 by the Frenchman Beaussier during an autopsy. It was first visualised using X-rays in 1920 by the physicians Akbulut and Otan. The first surgical treatment of a splenic artery aneurysm was performed by surgeons MacLeod and Maurice in 1940. The first minimally invasive endovascular therapies using coils, stents or a combination of the two devices for minimally invasive treatment of aneurysms of the lienal artery were reported in 1990, 1994 and 1995 (1,2,3).

The respective shape and, above all, the width of the aneurysm base, small-neck or wide-neck, determine the choice of treatment today, e.g. by means of coiling in small-neck aneurysms or placement of covered stents or Viabahn devices (WL.Gore and Associates, Flagstaff, Arizona, USA) in the case of a wide-neck aneurysm.

In the case of a very wide aneurysm base and thus a largely absent neck, coiling is primarily prohibited due to the existing increased risk of coil dislocation or protrusion of coils into the lumen of the original vessel with consecutive partial or complete occlusion of the same.

A proven therapy in this case would be the placement of a covered stent as a bridging tool in the form of a vial to safely eliminate such a lienal artery aneurysm (7,8) or in the special case of a recent rupture of the vessel (9).

The use of the Comaneci device (6,10,11), which has been successfully used in interventional neuroradiology for several years, for the temporary bridging of a wide-neck aneurysm neck for the immediate subsequent positioning of coils in the aneurysm sac, makes this possible without the risk of coil dislocation (6,10,11). After complete filling of the aneurysm, described as so-called coil packing, the Comaneci device is then removed again.

The final angiographic controls describe a technical success of up to 98% without coil dislocations in the trunk vessel carrying the aneurysm (6,10,11).

Instead of the Comaneci device, similar success can be achieved to prevent embolisation of placed microcoils in a wide-neck aneurysm to protect against coil dislocation with a bare metal stent bridging the aneurysm neck (12).

Coiling is then carried out through its meshes using a microcatheter.

Another treatment option in the elimination of an aneurysm is the temporary placement of a deployed balloon catheter at the level of the aneurysm neck with microcatheters already positioned in the aneurysm for microcoil application in the aneurysm sac. After successful occlusion of the aneurysm sac, the balloon catheter is deflated if it is angiographically confirmed that no protrusion of microcoils into the parent vessel is recognisable during their application (13).

Both techniques described therefore serve to prevent microcoil dislocations during embolisation. According to the results of the literature, the positioning of the vena cava chosen in our case offers no difficulties in placing it precisely, even if the course of the lienal artery is more tortuous (8,14).

The positioning of a so-called flow diverter (15) or the use of the double microcatheter technique for the staggered application of longer microcoils, which become entangled during the successive advancement into the aneurysm and thus lead to the elimination of wide-neck aneurysms (16,17) are further alternative applications.

These are some minimally invasive endovascular transcatheter treatment options for aneurysms of the lienal artery.

The rapid onset of angiographically proven technical and thus also clinical success of aneurysm elimination using a Viabahn selected in our case is reported in the literature as between 86%, 94% and 100% technical success depending on the location of the aneurysm in the visceral vessels.

The 100 % technical success reported by some authors referred to a total of two lienal artery aneurysms that had been eliminated using Viabahn (8,14).

Unfortunately, technical difficulties in the positioning of Viabahn devices, as in the case of our 63-year-old patient reported by us, cannot always be completely ruled out.

Case report

63-year-old patient with a known aneurysmal arteriopathy of the thoracic aorta in the sense of an aortic dissection in coexistence with a 2.2 cm splenic artery aneurysm discovered by

chance in the vascular surgery department of the Bürgerspital Solothurn, Switzerland.

The interdisciplinary consensus primarily favoured vascular surgery or minimally invasive transcatheter treatment to eliminate the splenic artery aneurysm.

The dissected thoracic aortic aneurysm detected in the pre-interventional CT of the thorax and abdomen, extending into the abdominal aorta, (Fig.1) should only be treated with minimally invasive endovascular treatment using EVAR after stenting of the lienal artery aneurysm detected by CT (Fig. 9, 10, 11).

A reverse therapeutic sequence would have allowed access to the lienal artery aneurysm only by fenestration of the EVAR. For the treatment of our patient's wide-neck aneurysm, the use of a Viabahn was chosen from the many known and proven occlusion materials as a significantly less invasive alternative to surgical treatment of the aneurysm by interdisciplinary consensus.

Due to a technical complication during the deployment of the first vial, a two-stage angiographic therapeutic intervention was necessary, as shown in the following angiography with elimination of the lienal artery aneurysm by vial placement.

Angiography and Intervention

After obtaining the patient's informed consent on the previous day, the procedure was performed under local anaesthesia using the Seldinger technique with retrograde placement of an F-6 sheath via the right common femoral artery. Application of 2,500 IU heparin i.a. This was followed by probing of the coeliac trunk with subsequent superselective visualisation of the splenic artery aneurysm (Fig.4). Using the F-5 Cobra catheter, easy placement of an aneurysm catheter through the aneurysm sac into the splenic hilus with the 0.035 inch Amplatz Superstiff guide wire (Fig.8).

Insertion of a curved F-8 lock, which stretched the A.lienals, an ideal prerequisite for the safe placement of a Viabahn. Difficult advancement of the vena cava due to kinking of the first guide wire. Only after insertion of a stiff Terumo wire into the periphery of the splenic artery was the vial successfully advanced into the aneurysm under angiographic control via the inserted F-8 sheath into the aneurysm neck (Fig.6).

The release and deployment of the Viabahn is only possible by pulling very strongly on the

tearing thread unfolding the stent graft. This results in a pronounced kinking of the Viabahn due to discontinuous deployment with shortening of the stent graft and subsequent misplacement of the same after the Viabahn slips distally towards the splenic hilus with pronounced angiospasm immediately proximal to the aneurysm (Fig.2,3). Angiographic visualisation of unchanged perfusion of the splenic artery aneurysm (Figs.12-14).

Due to the stent-graft presenting with kinking in the vessel, probing the proximal end of the first Viabahn is very difficult for the overlapping placement of a second viabahn planned immediately afterwards. Despite the insertion of various differently stiff microwires (V-18, V-14, PT2), it is not possible to insert a diagnostic catheter or a support catheter (Navicross 0.035 inch and 0.018 inch) via the proximal stent end of the first vena cava. As a result, the intervention was discontinued due to the now existing examination duration of more than 3 hours, the elevated radiation dose and the injected KM quantity of approx. 150 ml of a non-ionic contrast agent. The preliminary final check still shows unrestricted perfusion of the aneurysm sac with technically incorrect placement of the 1st stent-graft (Fig.12). Closure of the puncture access of the right common femoral artery using an F-8 angioplasty without further angiographically recognisable local complications.

We then planned the continuation of the intervention 2 days later after the patient had been hospitalised in the meantime for further close monitoring in the ICU. It took so long because a Viabahn longer than 5 cm had to be ordered from the supplier according to our specifications.

Renewed retrograde access to the AFC under sonographic control. Insertion of a long F-8 sheath. Problem-free probing of the coeliac trunk and the lienal artery. Subsequent various failed attempts at probing using a diagnostic catheter and guide wire, due to the proximal end of the distally dislocated 1st Viabahn, which could only be probed at a right angle. The sheath required for the Viabahn placement is finally successfully pushed up to the aneurysm using an 8-French guiding catheter. However, this is only possible with increased force. Subsequent successful probing of the 1st Viabahn using a microcatheter and microwire. Using the former, insertion of a long 0.018 inch advantage and advancement of the same into the periphery of the splenic artery. Positioning

of a 0.018 PTA balloon catheter in the 1st Viabahn (Armada 5/40) with careful manipulation. After dilating and realigning the 1st misplaced Viabahn using the telescoping technique via the balloon, the 8-French guiding catheter is advanced into the stent graft and a 0.035 in Amplatz Super Stiff guidewire is then inserted via this into the periphery of the lienal artery (Fig.5).

Only under significantly increased pressure it is possible to place a second Viabahn in an overlapping technique (viaplasty 8/50) via this wire after stretching the lienal artery with the sheath slipped back. Only then could the 2nd stent graft be placed without any problems (Figs.17-21). The final angiographic control shows complete bridging and thus elimination of the aneurysm with a now inconspicuous lumen of the lienal artery in the treated vessel section (Fig.15,16). Regular perfusion of the splenic parenchyma without evidence of emboli despite the numerous manipulations in the lienal artery or evidence of active haemorrhage in the spleen (Fig.15). After removal of the catheter and guide wire, the puncture site is closed using an 8-French angio seal.

Assessment:

Technically very complex covered stenting of a lienal artery aneurysm using 2 Viabahn devices in an overlapping technique (8/50mm) with initial dislocation of the 1st stent graft due to large technically induced unfolding and deflation times and difficulty with resulting misplacement. Difficult placement of the 2nd Viabahn due to the almost right-angled approach to the proximal end of the 1st Viabahn. Finally, successful 2-step elimination of a 2.5 cm wide-neck splenic artery aneurysm prior to planned endovascular therapy of a dissected aneurysm of the thoracic aorta, which was detected by CT-A and extended into the abdominal aorta.

Monitoring and progress:

Monitoring of the patient on the ward at half-hourly intervals: RR, pulse, O2 saturation for a period of 5 hours. The patient was discharged the following day to the retirement home and further care by a GP, with normal local findings and stable circulatory conditions. Aspirin cardio was prescribed for a further 3 months.

The angiographic 1-year follow-up of the treated lienal artery aneurysm and the endovascular elimination together with the vascular surgeons of the dissected thoracic artery aneurysm

shows both complete elimination of the dissected thoracic aortic aneurysm without reperfusion as well as regular perfusion of the lienal artery with completely thrombosed minimally invasively treated lienal artery aneurysm (Fig.7,8).

Discussion:

The first minimally invasive transcatheter ablation of splenic artery aneurysms was described in the early 1990s by Miyazaki et al. (1) using gelfoam and coils (1990), by McDermott et al. in 1994 (2) and somewhat later by Kramann et al. in 1995 (3). Kramann et al. (3) have already reported on 13 treated patients whose splenic artery aneurysms were occluded using a coaxial microcatheter system that is very suitable for coil placement. Subsequently, various authors have described up to 100% primary technical success of stent-grafts (Viabahn) for splenic artery aneurysms (7,8,9,10) compared to surgical therapy with the greater risk of complications due to the invasiveness of the therapy potential, in comparison with the minimally invasive transcatheter procedure described by Ruhnke and Kröncke 2017 (4) have been described in the treatment of a total of 43 visceral artery aneurysms, 23 aneurysms and 20 pseudoaneurysms, including 14 lienal artery aneurysms, 4 minor and 1 major complication (4). Fortunately, however, in all cases these have remained without permanent consequential damage for the individual patient. In our case, occlusion was indicated due to the increased risk of rupture in aneurysms with a diameter of more than 2 cm. In the case of rupture, this size is reported to have a mortality rate of 46-47%, especially in the lienal artery in women, for example in multipara, of 25-45%, and in non-pregnant women of 10-25% (20).

Fever and even transient abdominal pain are described by some Chinese authors as a rather unusual complication, which is probably primarily to be assessed as post-embolisation syndrome. Intraprocedural complications during follow-up were reported by M. Cappucci et al. 2017 (5) in 25 patients with 19 aneurysms and 6 pseudoaneurysms, including a total of 12 lienal artery aneurysms with 12 % (4% major, 8% minor). In the follow-up, 2/24 stents showed migration of the stent (8%) and 4/24 stents showed thrombotic occlusions (16%). However, these were not described as primarily technical. The mortality rate is stated as 0 %.

In the early days of aneurysm embolisation, Kramann et al. 1995 reported (3) out of a total of 13 patients with the following complications:

1. Dislocation of the embolisation into the spleen, but without the risk of consecutive procedural splenic necrosis and
2. The occurrence of a rupture, i.e. a comparatively narrower vessel, during embolisation of a hepatic artery aneurysm in the course of minimally invasive therapy in this patient.

In our PubMed search over the last 25 years, no reports of a technical complication of the kind that occurred in our particular case could be found.

In this case, it was the relatively minor cause of the stent graft, which could only be deployed discontinuously, that led to this extremely technically complex and lengthy stent graft placement procedure. If it had been possible to place the primarily sufficient 5 cm long Viabahn correctly, it would certainly have been an almost "piece of cake" situation.

The reason for our technical complication was due to 3 factors:

1. The Viabahn, (GL Gore, Flagstaff , Arizona, USA), which can only be unfolded with exceptionally high tension on the ripcord.
2. Normally, only a slight pull is required for the harmoniously and continuously unfolding VIA track, and
3. The high pushing pressure on the torque-stable Super Stiff guidewire for its placement in a stable position with its soft tip in the vessel section close to the splenic hilus.

The result was that the 1st Viabahn could only be unfolded with a kink formation with subsequent dislocation towards the distal end of the aneurysm sac. As the angiographies showed, it was not possible to eliminate the aneurysm as planned in the first stage of treatment. Due to the kink formation in the longitudinal alignment of the 1st Viabahn, the guide wire and the catheter had to be inserted at an almost right angle into the proximal end of the dislocated vial for placement of the 2nd Viabahn in order to be advanced further into the stable position close to the hilus as a prerequisite for the intended placement of the 2nd longer Viabahn. The stable positioning of the guidewire close to the splenic hilus, over which the 2nd Viabahn was pushed on the 2nd day of the examination, could be held in a safe position close to the splenic hilus even with an inexplicable amount

of force, although the guidewire snapped back several times from the safe position close to the splenic hilus.

In this case, the very rare technical complications were the cause of the time-consuming therapy, which placed high demands on the interventional radiologist in order to successfully complete the elimination of the splenic artery aneurysm.

The largely therapy-resistant vasospasm of the lienal artery caused by the manipulation due to the guide wire repeatedly snapping back from the section of the lienal artery close to the spleen, the long duration of the examination, the amount of contrast medium applied and the total radiation dose were the decisive factors that led to the cancellation of the intervention on the first day of the examination.

The final control angiography showed an almost unobstructed perfusion of the aneurysm sac.

Theoretically, it can be assumed that due to the still recognisable complete perfusion of the aneurysm sac by the 1st Viabahn acting almost as a foreign body, an increased wall tension due to turbulence in the aneurysm sac was to be feared as an increased risk of rupture of the aneurysm sac.

The patient was therefore transferred to the recovery ward for close cardio-circulatory monitoring of blood pressure, oxygen saturation, pulse and local findings in the groin.

During the 2nd therapy attempt, 2 days later, it was then possible to place the 2nd Viabahn with new guidewires, catheters, a longer sheath and a longer Viabahn, which was manufactured by the producer within 2 days, but only with increased technical effort.

The proximal entrance of the first-placed vial could only be successfully passed at an almost right angle and the torquable stiff guidewire in the splenic hilus near the distal section of the vessel could only be held in this position with increased longitudinal pressure on the guidewire. It repeatedly threatened to spring back from this position. In this interplay of pressure on the guidewire and overcoming sliding friction forces on the 2nd Viabahn during positioning, it was then possible to overlap it. Angiography showed complete elimination of the wide-neck aneurysm with an unstricted lumen of the splenic artery. These considerable technical application difficulties have not been described in our Pubmed research in recent years. A safe

alternative would have been to close the aneurysm by using a Comaneci device and protecting it from coil dislocations in order to then safely perform coil packing in the aneurysm sac via a catheter previously inserted into the aneurysm. This methodical technical procedure with the protective temporary Comaneci device is now recommended and has been tried and tested in interventional neuroradiology for some time in order to safely avoid dislocation of coils for small and especially wide-neck aneurysms (6,10,11).

The situation is different with the use of stent grafts, which do not require microcoil embolisation for endovascular elimination and achieve a comparable result in aneurysm elimination. In our case, we had not anticipated such difficulties with positioning and unfolding. We had assumed that the Viabahn track placement would be a regular process.

The question we asked ourselves after the successful implementation of the intervention was why there were hardly any reports of such complications? Learning from the experience of others should always be seen in terms of optimising patient care. One possible explanation for the lack of notification of such events could be:

1. Interventional radiologists work very carefully and cautiously, which can be assumed, and / or
2. there is a lack of willingness on the part of the authors not to publicly discredit their own professional expertise by making such statements.

However, this is always regrettable from the point of view of the learning and teaching effect, especially as complications in interventional radiology, as in any other medical discipline, are unlikely to be avoidable. In our opinion, it should always be a high priority, especially for didactic reasons, to communicate how the examiner was able to control a complication by his own means in the sense of complication management in order to achieve the desired positive result. Surely you only learn from the mistakes of others for the benefit of the patient? This topic has been dealt with for some time now at specialist congresses as part of workshops under the motto of complication management:

"My worst case and what would you have done?"

The Viabahn used by us to eliminate the splenic aneurysm in the treatment of small-neck and,

above all, wide-neck aneurysms has also been described by other authors as very good for bridging with subsequent elimination of splenic artery aneurysms (7,8,9).

This is not only feasible if the vascular anatomy of the lienal artery is almost normal, but there are also reports of treated cases in which the lienal artery leaves the superior mesenteric artery (18,19). In this anatomically very rare vascular anatomy, the risk of rupture is still classified as significantly higher and therefore requires even faster and more effective removal of the aneurysm after diagnosis. The special feature of this situation is that in the event of an aneurysm rupture, 2 important visceral vessels would be affected at the same time, with a significantly increased risk of bleeding for the patient (18,19). The Viabahn is now a firmly established device in the elimination of aneurysms in the arterial pathway. Technical difficulties such as those described by us are likely to be an absolute rarity and will hopefully remain so.

Conclusion

For many years, interventional radiology has been offering an increasingly wide range of minimally invasive methods for the elimination of aneurysms and pseudoaneurysms. Here, *pars pro toto*, coil placement is very successful in the case of small-neck aneurysms, and in the case of wide-neck aneurysms, the placement of a Viabahn or, under the protection of a stent or a passager inflated balloon catheter, so-called coil packing with complete filling of the aneurysm with a very long coil or several coils. Furthermore, the use of the Comaneci device, an asymmetrically expandable, stent-like and retrievable device, which is precisely positioned in the sac of the wide-neck aneurysm to prevent coil dislocations during its placement, protects against coil dislocations during its placement. Before positioning the coil, however, the methodical procedure involves first positioning a selective catheter in the aneurysm so that the coil can then be placed under the protection of the Comaneci device. Another application option for coils is to insert long coils into the aneurysm sac one immediately after the other via 2 microcatheters, whereby the length of the coils causes them to interlock and thus form a ball with a very low risk of coil dislocation due to the application technique.

Which in our case is due to:

1. the numerous repositionings of a torque-stable guidewire required for repeated retraction from its position close to the splenic hilus,

2. the faulty unfolding of the 1st Viabahn with kink formation of the therapy-resistant vasospasm caused by the numerous manipulations that have occurred,
3. the increased amount of contrast medium injected,
4. the applied radiation dose (21) and
5. the long duration of the examination

were the reasons for the cancellation of the attempted and primarily failed aneurysm removal on the first day of the examination. This was the only logical decision to cancel the intervention at this point.

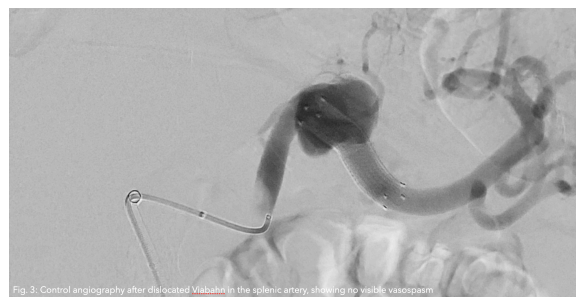
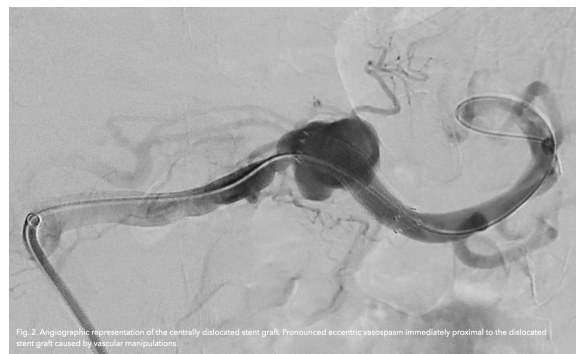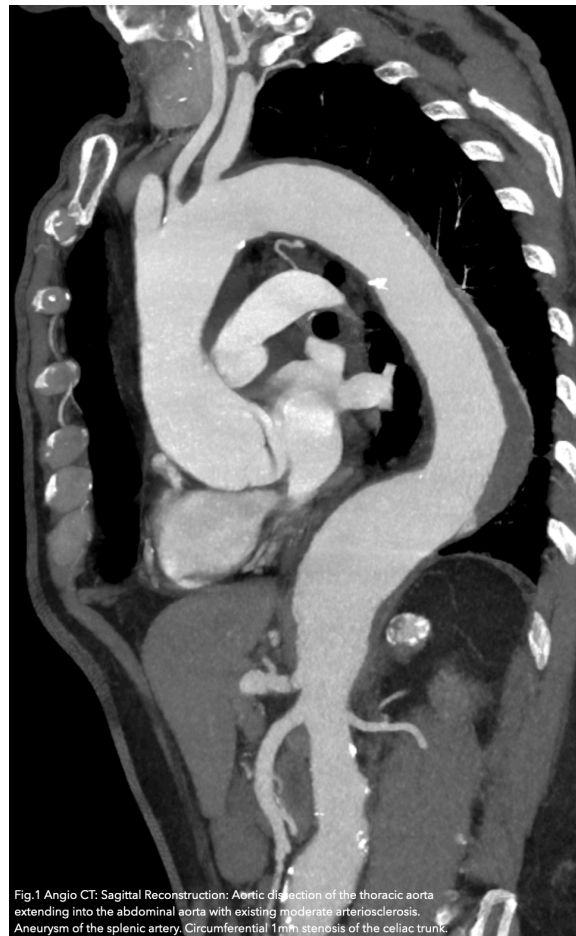Knowing full well that the aneurysm, which had only been primarily treated but was still fully perfused, would be even more at risk of rupture due to the altered flow conditions in the aneurysm sac. In this case, altered flow conditions with the generation of turbulence in the aneurysm sac with consecutive increased vessel wall tension in the aneurysm are to be assumed due to the misplaced 1st stent graft.

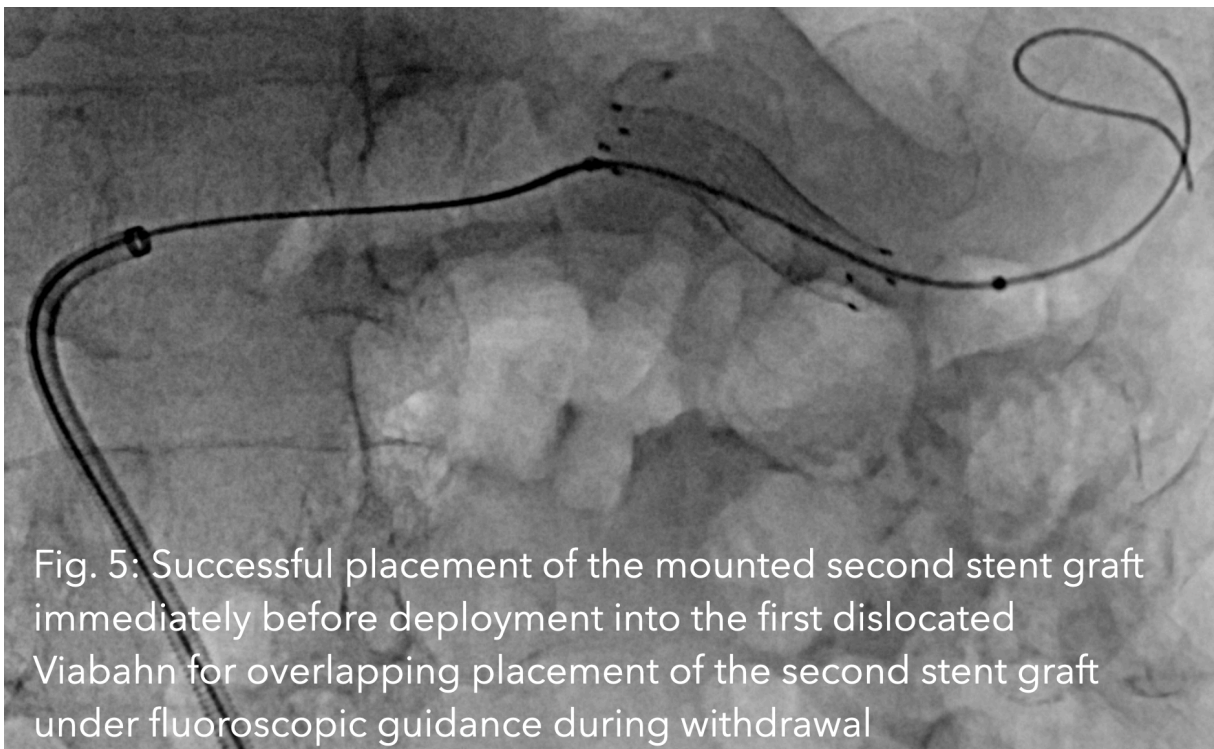
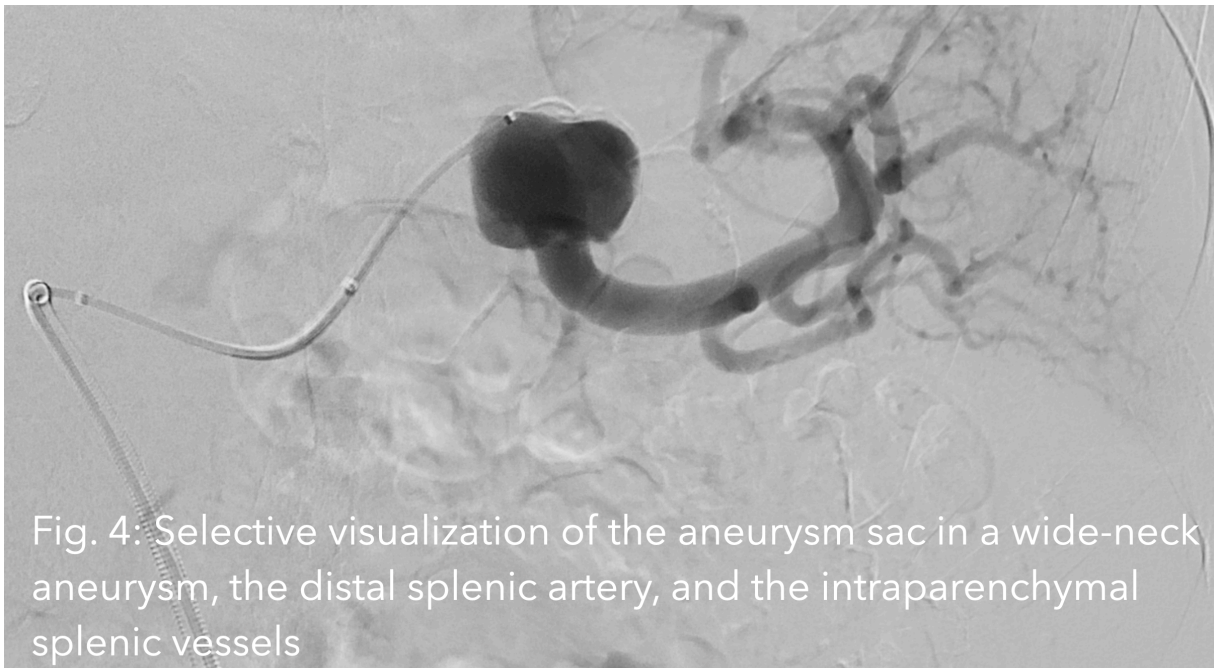
The change in the choice of interventional material used led to the successful elimination of the 2.5 cm lienal artery aneurysm two days later while the patient was hospitalised on the recovery ward. In conclusion, it should be noted that in very rare constellations, a proven and primarily very good and efficient minimally invasive therapy to eliminate an aneurysm can unfortunately not always be carried out as a so-called "piece of cake" therapy.

In such cases, a very careful assessment of the situation is required in order to be able to successfully complete the therapy with great angiographic experience and the use of various guidewires, balloon catheters and sheaths adapted to the changed situation (22). The 1-year final follow-up of the dissected aneurysm of the thoracic aorta using a fenestra-ted EVAR for the outflow of the celiac trunk, that of the superior mesenteric artery and that of the outflows of both renal arteries after the previous removal of a 2.5 cm large lienal artery aneurysm impressively demonstrates the efficiency of minimally invasive endovascular therapy.

However, as in our reported case, this may not always proceed primarily without complications.

Images and Videos





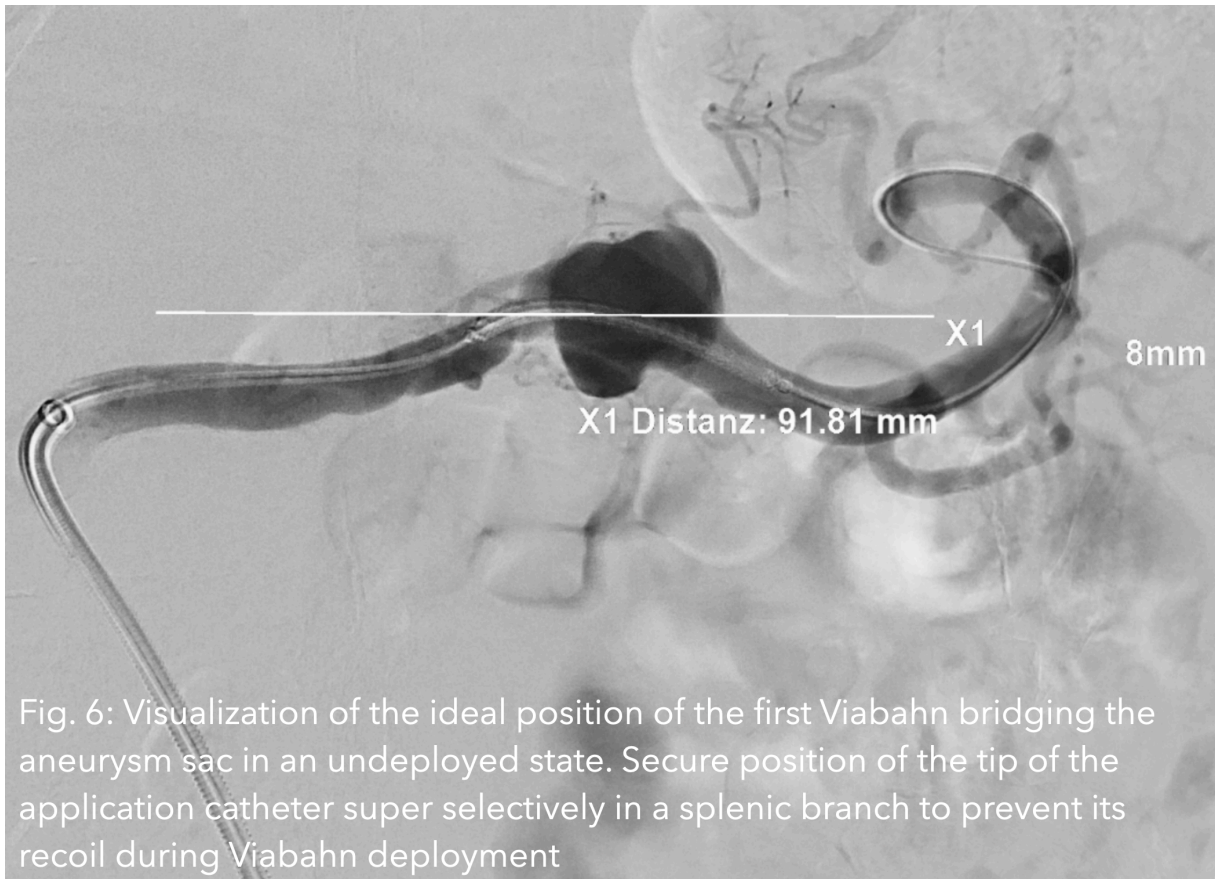


Fig. 6: Visualization of the ideal position of the first Viabahn bridging the aneurysm sac in an undeployed state. Secure position of the tip of the application catheter super selectively in a splenic branch to prevent its recoil during Viabahn deployment

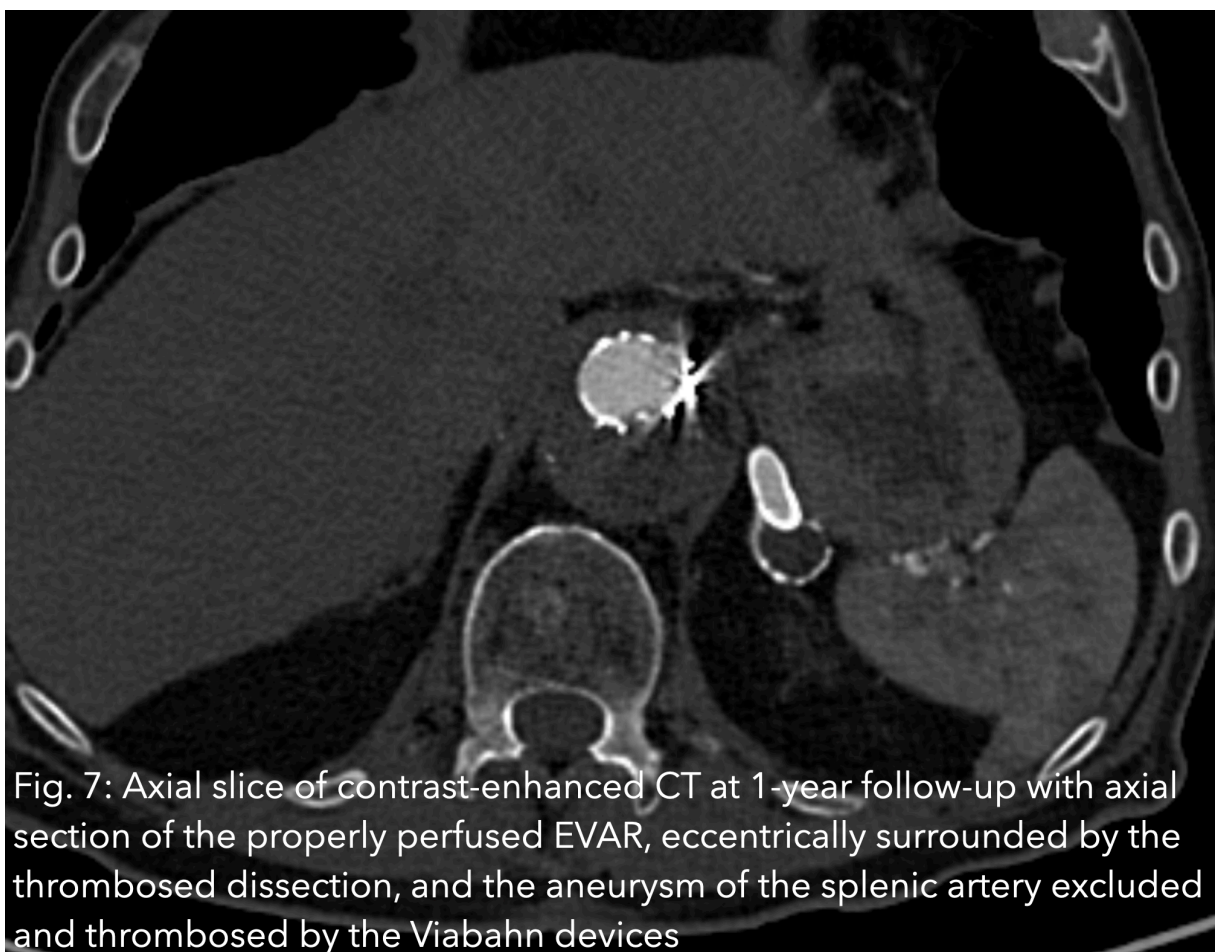

Fig. 7: Axial slice of contrast-enhanced CT at 1-year follow-up with axial section of the properly perfused EVAR, eccentrically surrounded by the thrombosed dissection, and the aneurysm of the splenic artery excluded and thrombosed by the Viabahn devices

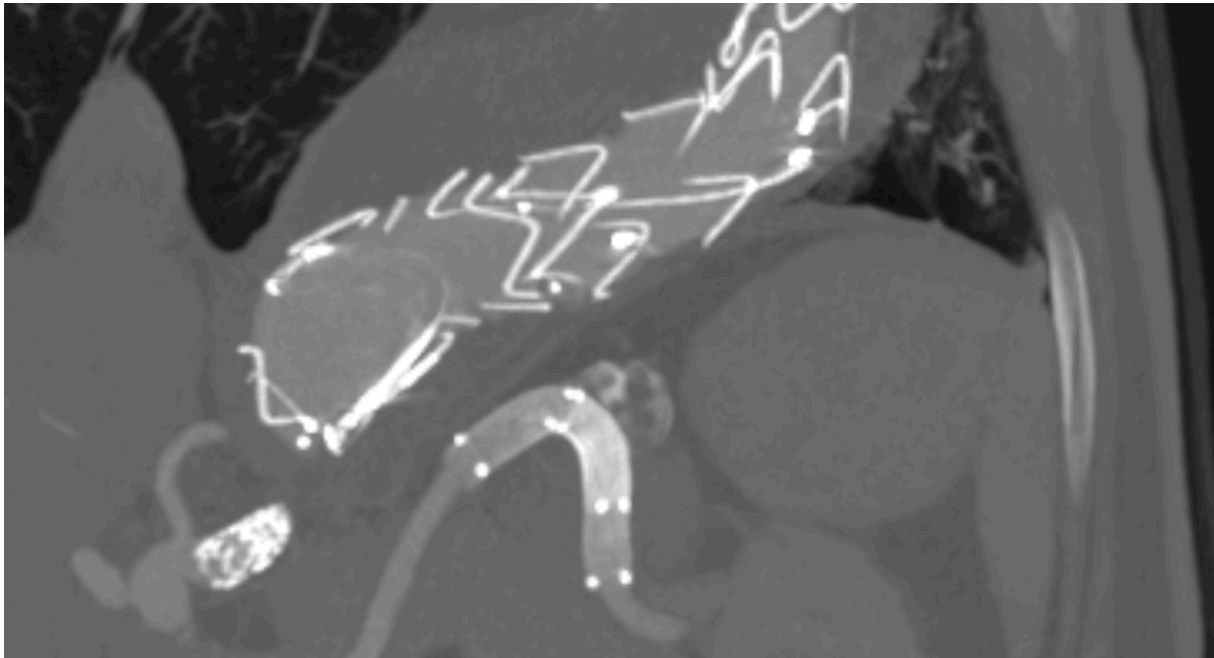


Fig.8: 1-year follow-up in contrast-enhanced CT with partial visualization of the EVAR, stented left renal artery with primary fenestration of the EVAR, and stenting of both renal arteries and the celiac trunk due to the aortic dissection extending into the abdominal aorta and the thrombosed splenic artery aneurysm after Viabahn stenting. Proper perfusion of the visualized sections of the splenic artery

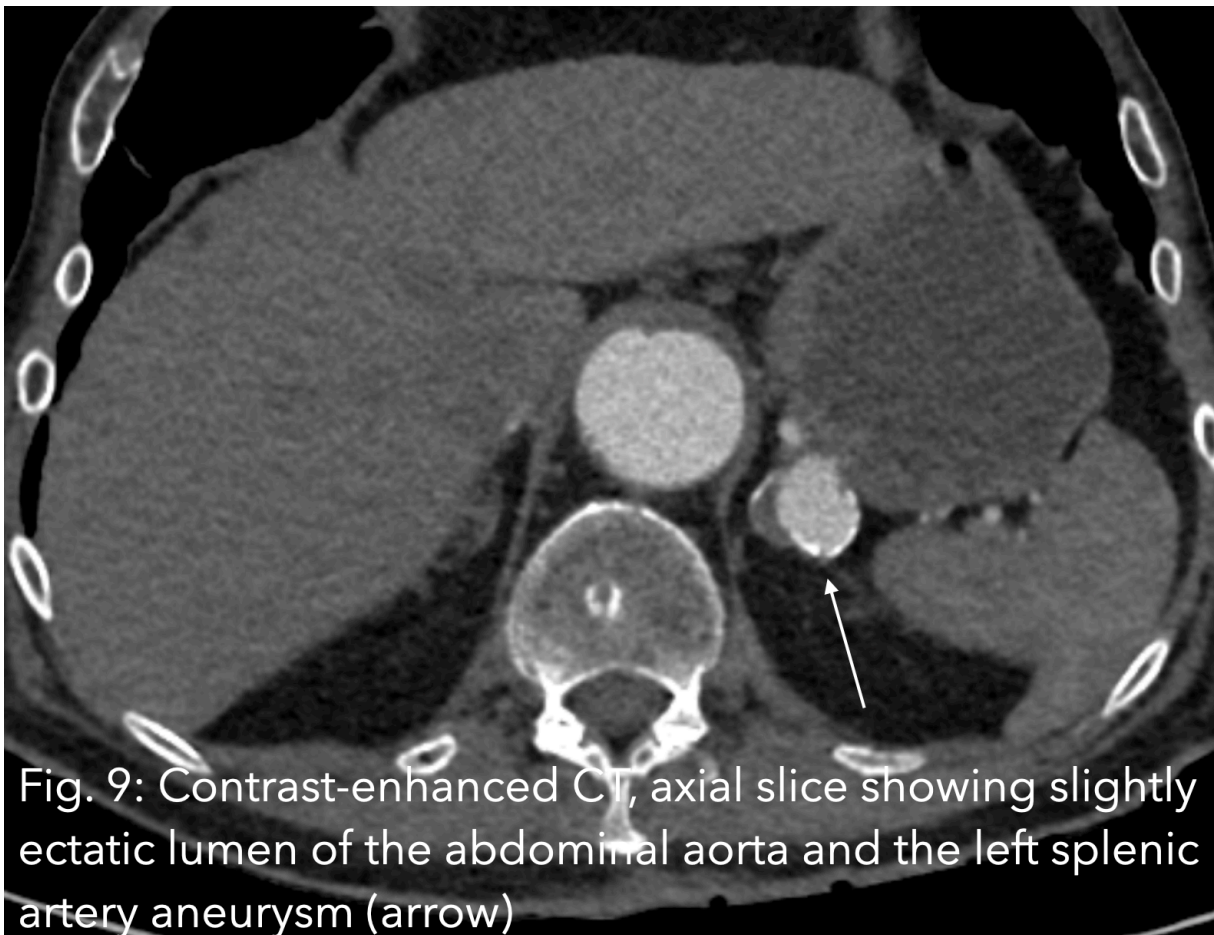

Fig. 9: Contrast-enhanced CT, axial slice showing slightly ectatic lumen of the abdominal aorta and the left splenic artery aneurysm (arrow)

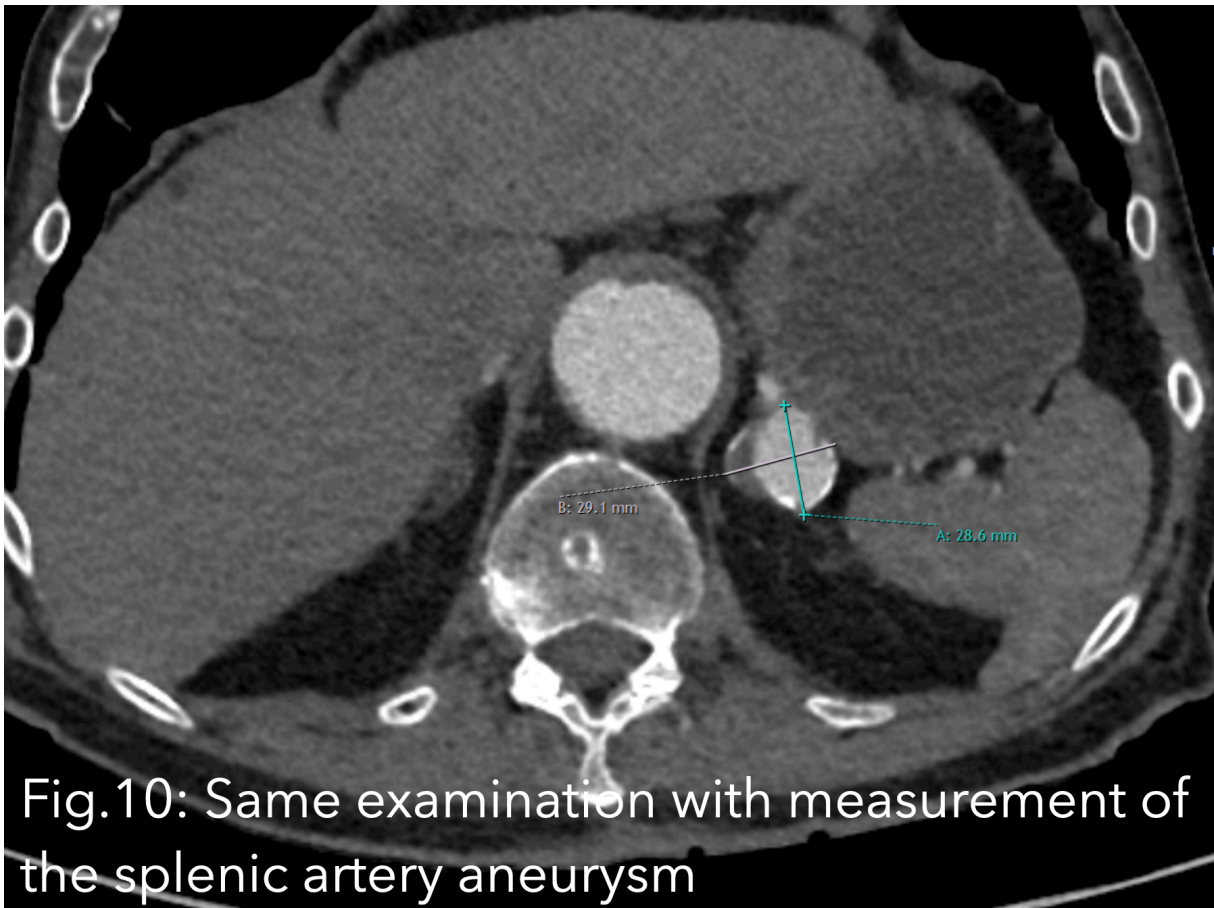

Fig.10: Same examination with measurement of the splenic artery aneurysm

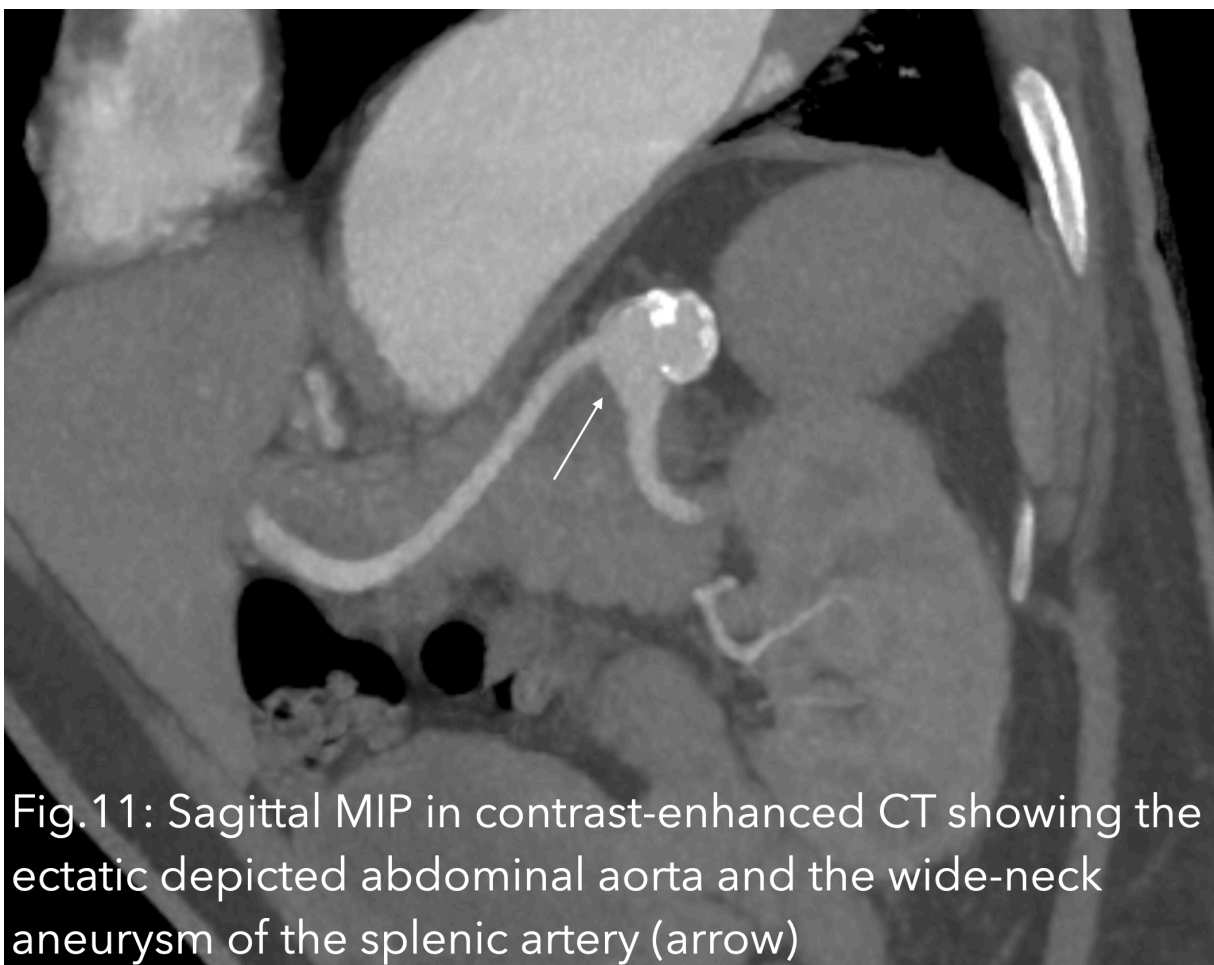

Fig.11: Sagittal MIP in contrast-enhanced CT showing the ectatic depicted abdominal aorta and the wide-neck aneurysm of the splenic artery (arrow)

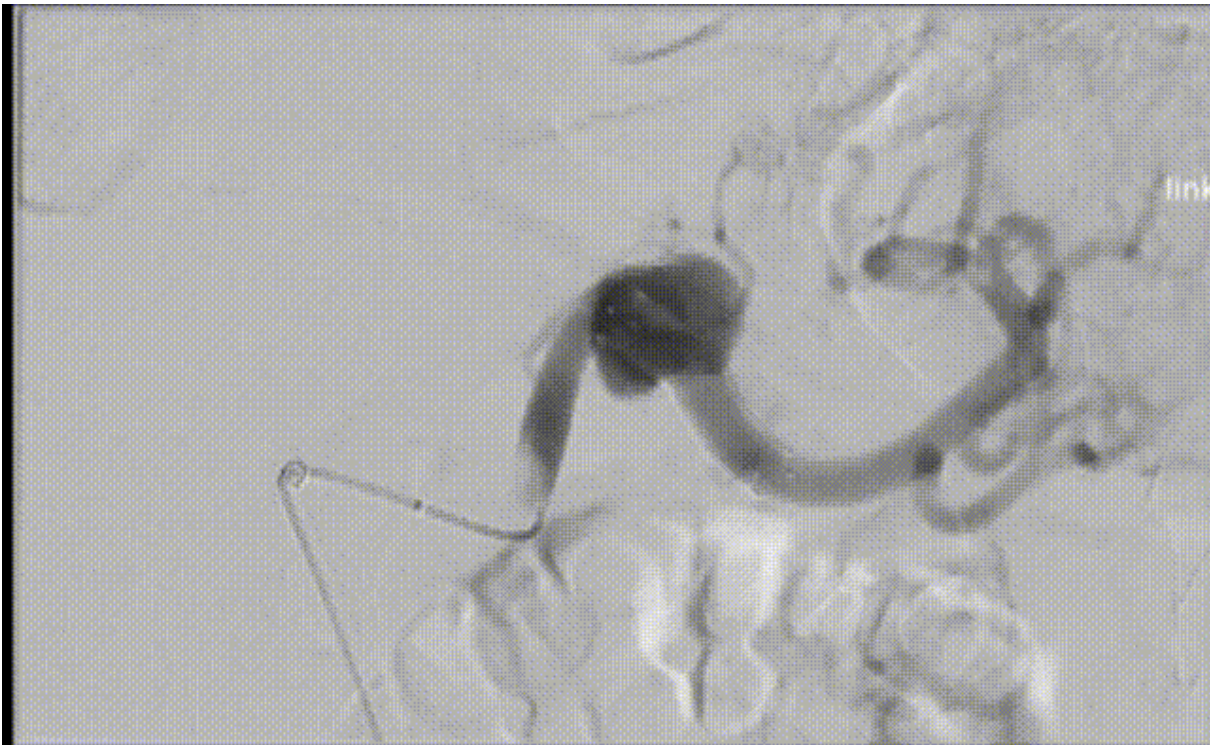


Fig.12: Control angiography after dislocated Viabahn placement (video)

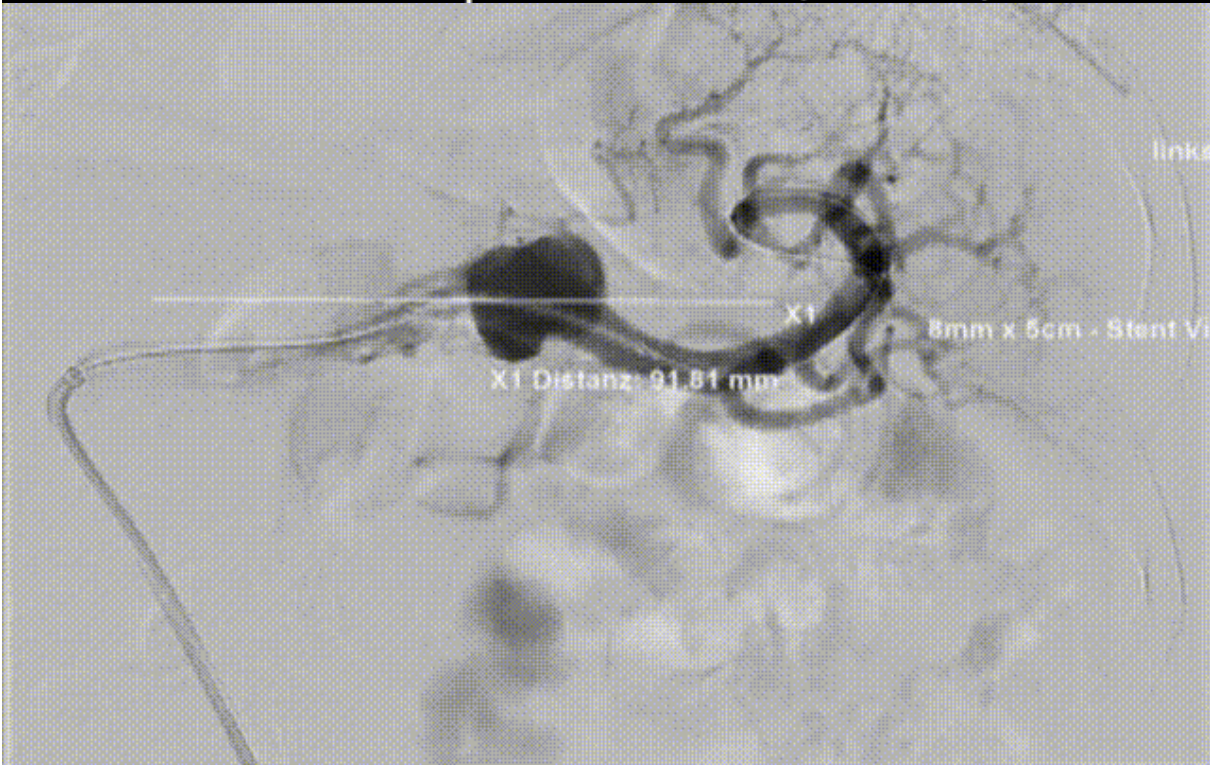


Fig. 13: Control angiography with the undeployed stent graft. Notable is the pronounced eccentric vasospasm induced by catheter manipulation proximal to the aneurysm sac (video)

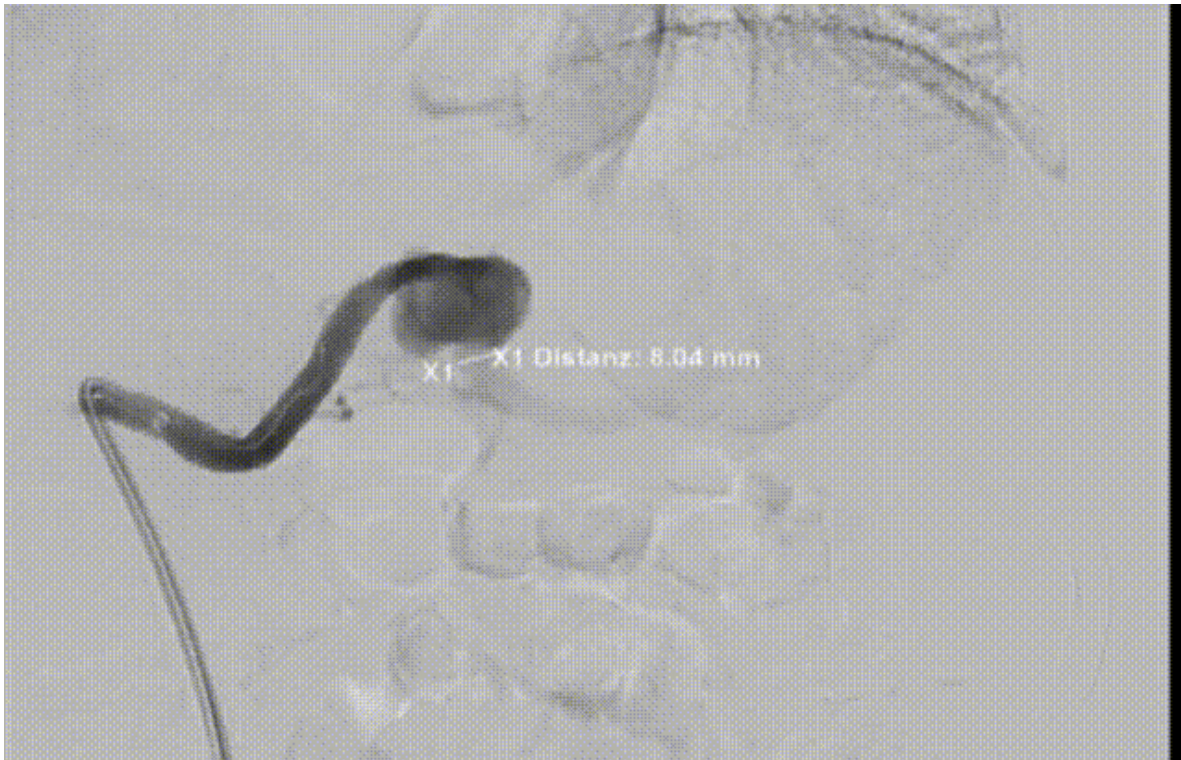
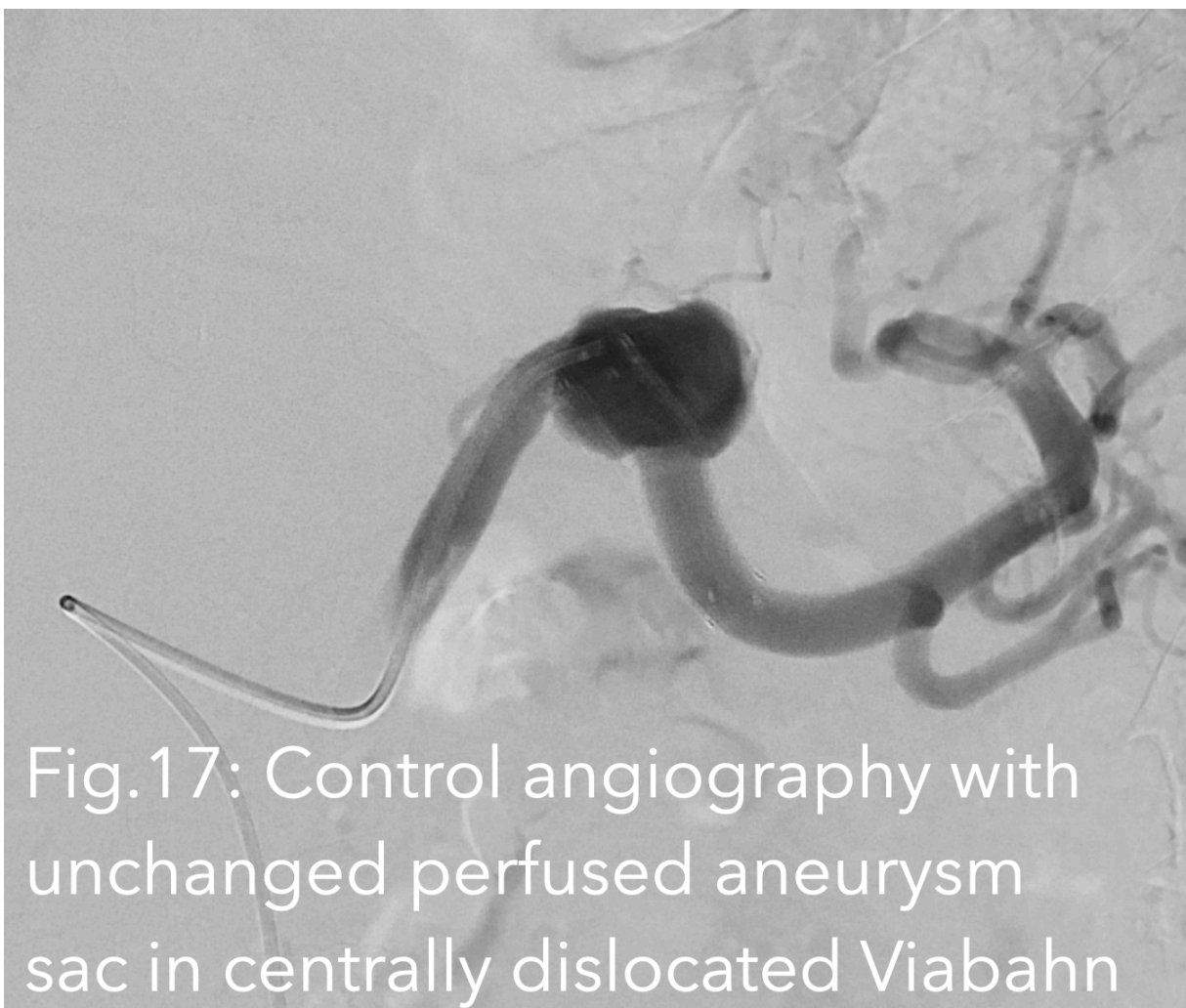
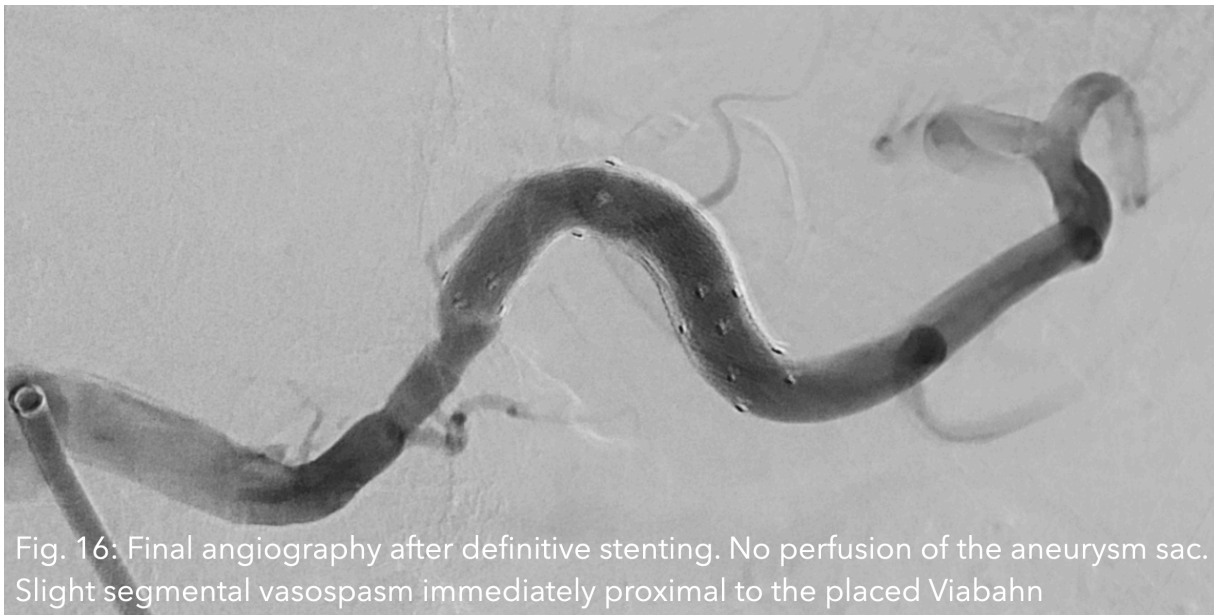Fig.14: Vascular visualization for measurement of the diameter distal to the splenic artery aneurysm




Fig.15: Final angiography of the splenic artery after successful stenting of the wide-neck aneurysm using two overlapping Viabahn devices without evidence of peripheral embolism in the splenic vessels despite numerous vascular manipulations (video)



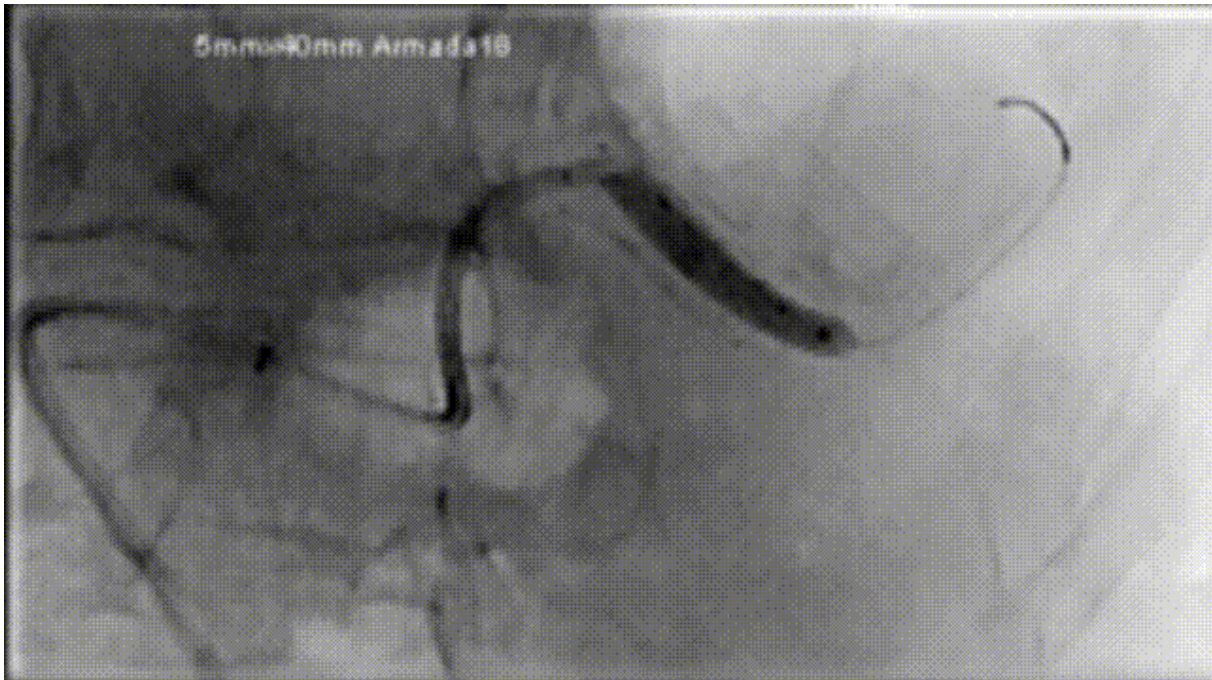


Fig. 18: Distal balloon dilation of the dislocated stent graft, supported by sheath, guiding catheter, and guidewire advanced far into the distal splenic artery to prevent further dislocation of the stent graft in the vessel (video)

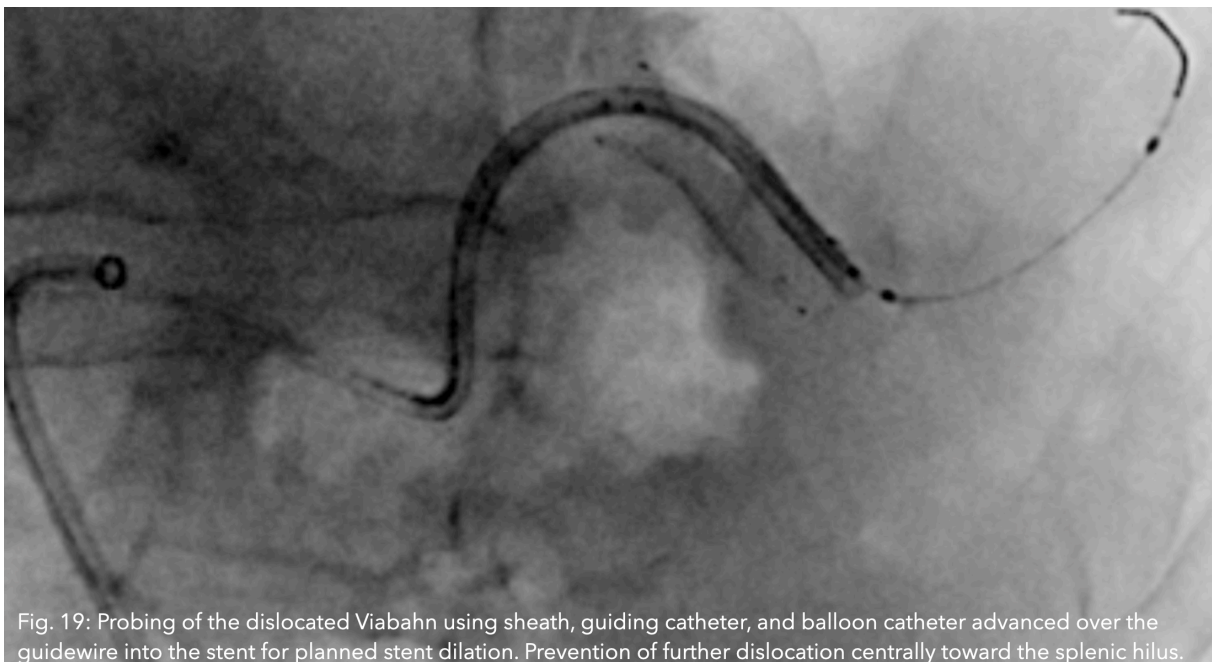


Fig. 19: Probing of the dislocated Viabahn using sheath, guiding catheter, and balloon catheter advanced over the guidewire into the stent for planned stent dilation. Prevention of further dislocation centrally toward the splenic hilus.

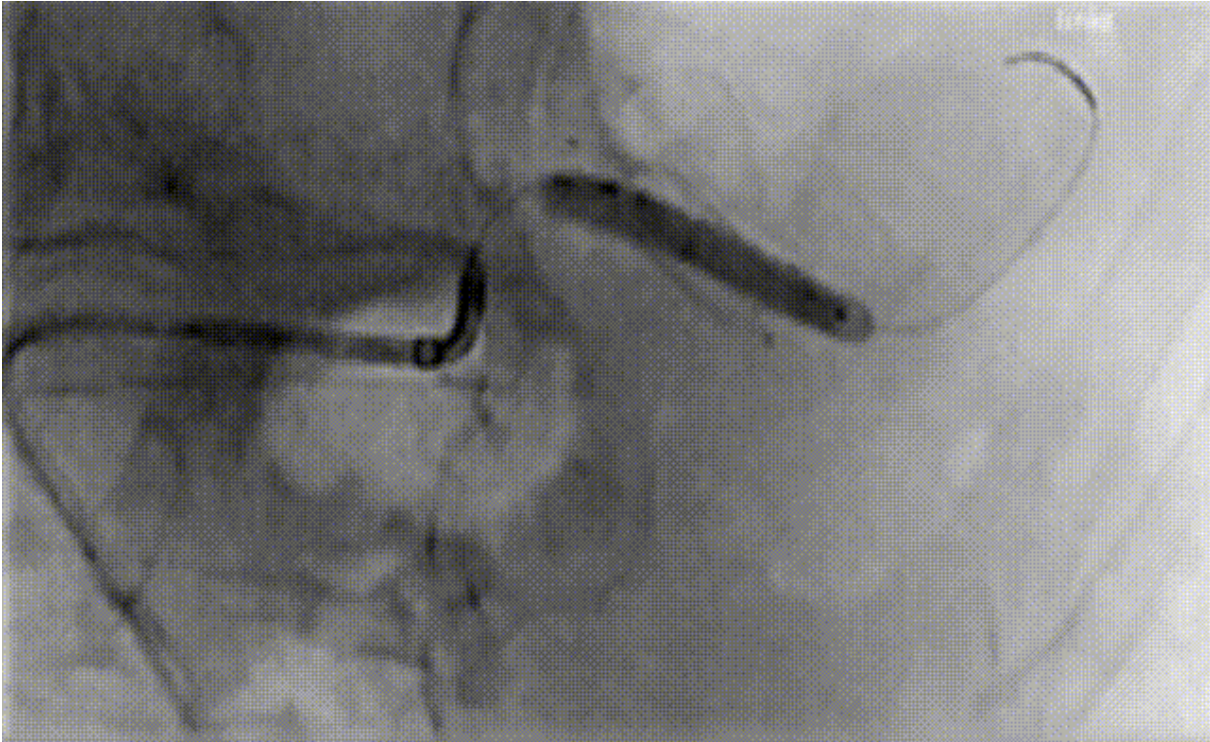


Fig.20: Stent probing with dilated balloon in the dislocated stent

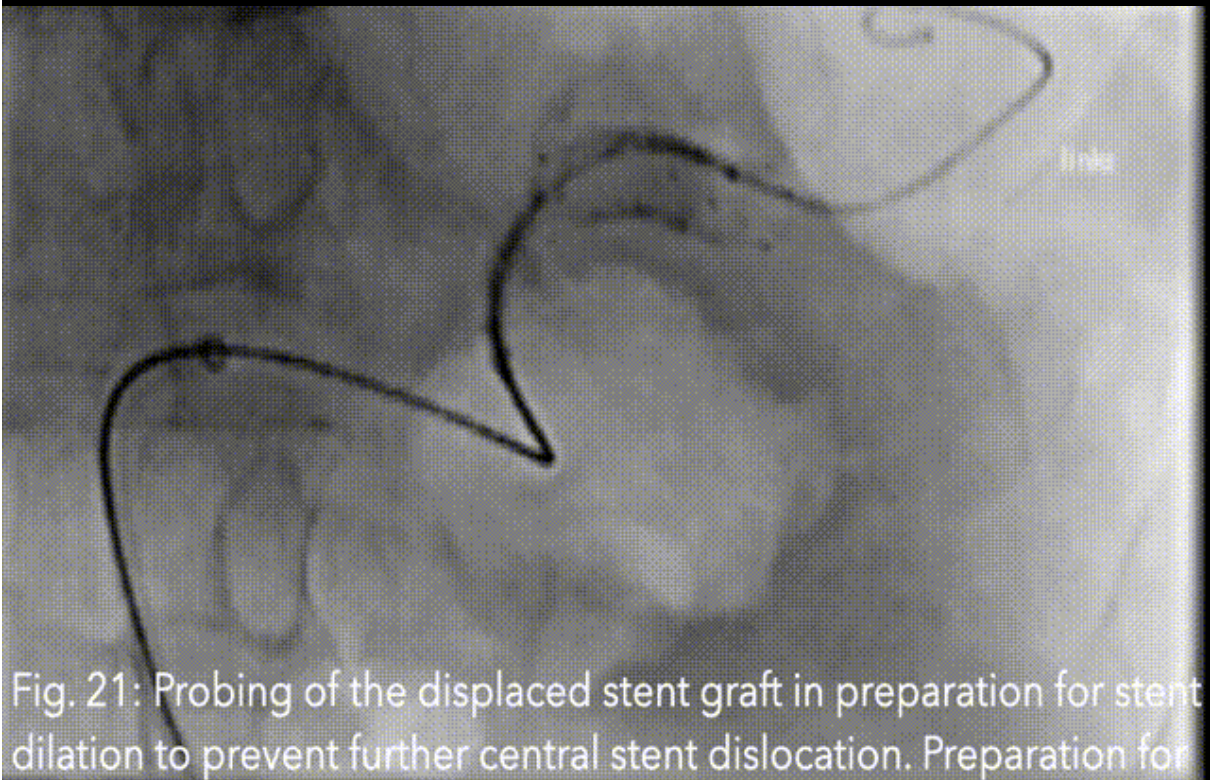


Fig. 21: Probing of the displaced stent graft in preparation for stent dilation to prevent further central stent dislocation. Preparation for the more straightforward placement of a second Viabahn to completely exclude the wide-neck aneurysm (video)

Conflict of interest:

The authors declare that there were no conflicts of interest within the meaning of the recommendations of the International Committee of Medical Journal Editors when the article was written.

Disclaimer/Publisher's Note:

The statements, opinions and data contained in all publications are solely those of the individual author(s) and contributor(s) and not of Swiss J. Radiol. Nucl. Med. and/or the editor(s). Swiss J. Radiol. Nucl. Med. and/or the editor(s) disclaim responsibility for any injury to people or pro-perty resulting from any ideas, methods, instructions or products referred to in the content.

References

1. Miyazaki M, Udagawa I, Koshikawa H, Ito S, Kaiko H, Suzuli K, Okui - Transcatheter embolization of splenic artery aneurysm: a case report: Rinsha Hoshasen. 1990 May;35(5):641-4 <https://pubmed.ncbi.nlm.nih.gov/2381111/>
2. McDermott, Vincent G., Richard Shlansky-Goldberg, and Constantin Cope. "Endovascular management of splenic artery aneurysms and pseudoaneurysms." *Cardiovascular and interventional radiology* 17 (1994): 179-184. <https://link.springer.com/article/10.1007/BF00571531>
3. Kramann, B., et al. "Erfahrungen mit der endovaskulären Embolisierungstherapie von Aneurysmata der Splanchnikusarterien." *RöFo-Fortschritte auf dem Gebiet der Röntgenstrahlen und der bildgebenden Verfahren*. Vol. 163. No. 11. © Georg Thieme Verlag Stuttgart· New York, 1995. <https://www.thieme-connect.com/products/ejournals/abstract/10.1055/s-2007-1016019>
4. Ruhnke, Hannes, and Thomas J. Kröncke. "Visceral artery aneurysms and pseudoaneurysms: retrospective analysis of interventional endovascular therapy of 43 aneurysms." *RöFo-Fortschritte auf dem Gebiet der Röntgenstrahlen und der bildgebenden Verfahren*. Vol. 189. No. 07. © Georg Thieme Verlag KG, 2017. <https://www.thieme-connect.com/products/ejournals/html/10.1055/s-0043-107239>
5. Cappucci, Matteo, et al. "Endovascular treatment of visceral artery aneurysms and pseudoaneurysms with stent-graft: analysis of immediate and long-term results." *Cirugía Española (English Edition)* 95.5 (2017): 283-292. <https://www.sciencedirect.com/science/article/abs/pii/S2173507717301047>
6. Maingard, Julian, et al. "Endovascular treatment of wide-necked visceral artery aneurysms using the neurovascular Comaneci neck-bridging device: a technical report." *Cardiovascular and interventional radiology* 40 (2017): 1784-1791. <https://link.springer.com/article/10.1007/s00270-017-1733-y>
7. Ouchi, Takafumi, et al. "Splenic artery aneurysm treated with endovascular stent grafting: a case report and review of literature." *Vascular and Endovascular Surgery* 52.8 (2018): 663-668. <https://doi.org/10.1177/1538574418785252>
8. Venturini, Massimo, et al. "Endovascular repair of 40 visceral artery aneurysms and pseudoaneurysms with the Viabahn stent-graft: technical aspects, clinical outcome and mid-term patency." *Cardiovascular and Interventional Radiology* 41 (2018): 385-397. <https://link.springer.com/article/10.1007/s00270-017-1844-5>
9. Miyayama, Shiro, et al. "Stent Graft Placement for Injured Visceral Artery." *Interventional Radiology* 8.3 (2023): 173-183. <https://doi.org/10.22575/interventionalradiology.2023-0005>
10. Natrella M, Perazzini C, Cristoferi M, Furfaro D, Alessi M, Fanelli G. Neurovascular Neck-Bridging device in treatment of wide-necked splenic artery aneurysms. *Radiol Case Rep*. 2021 Jul 1;16(9):2404-2410. doi: 10.1016/j.radcr.2021.05.064. PMID: 34257769; PMCID: PMC8260741. <https://doi.org/10.1016/j.radcr.2021.05.064>
11. Lim, Jaims, et al. "Comaneci device for temporary coiling assistance for treatment of wide-necked aneurysms: initial case series and systematic literature review." *World Neurosurgery* 149 (2021): e85 - e91. <https://doi.org/10.1016/j.wneu.2021.02.080>
12. Kim, Jonghoon, Chulhoon Chang, and Young Jin Jung. "Coil Embolization results of the ruptured proximal posterior inferior cerebellar artery aneurysm: a single-center 10 years' experience." *World Neurosurgery* 117 (2018): e645-e652. <https://doi.org/10.1016/j.wneu.2018.06.105>
13. Ross, Ian B., and Gurmeet S. Dhillon. "Balloon assistance as a routine adjunct to the endovascular treatment of cerebral aneurysms." *Surgical neurology* 66.6 (2006): 593-601. <https://doi.org/10.1016/j.surneu.2006.03.050>
14. Cao, Yanyan, et al. "Single-center experience with endovascular treatment for splenic artery aneurysms in long-term follow-up: a retrospective study." *Frontiers in Cardiovascular Medicine* 8 (2022): 793053. <https://doi.org/10.3389/fcvm.2021.793053>
15. Rabuffi, Paolo, et al. "Treatment of visceral artery aneurysms and pseudoaneurysms with the use of cerebral flow diverting stents: initial experience." *CVIR endovascular* 3 (2020): 1-8. <https://doi.org/10.1186/s42155-020-00137-y>

16. Panagrosso, Marco, et al. "Double-Microcatheter Technique through Tortuous Anatomy for Coil Embolization of a Saccular splenic Aneurysm: a Technical Report." *Translational Medicine@ Unisa* 21 (2020): 31. <https://www.ncbi.nlm.nih.gov/pmc/articles/PMC7039270/>
17. Lee, Byung Chan, et al. "Endovascular treatment of wide-necked aneurysms of the visceral and renal arteries using the double microcatheter technique via a single access route." *Diagnostic and Interventional Radiology* 26.5 (2020): 476. <https://dirjournal.org/articles/doi/dir.2020.19361>
18. Zhou, Weimin, et al. "Successful treatment of aberrant splenic artery aneurysm with a combination of coils embolization and covered stents." *BMC surgery* 14 (2014): 1-8. <https://bmcsurg.biomedcentral.com/articles/10.1186/1471-2482-14-62>
19. Kuwada, Noriaki, et al. "Endovascular Stent Graft Placement and Coil Embolization for Splenic Artery Aneurysm with an Anatomical Variant." *International Journal of Angiology* 32.04 (2023): 273-276. <https://www.thieme-connect.com/products/ejournals/abstract/10.1055/s-0042-1742588>
20. Pfabe, F. P. "Das Milzarterienaneurysma: Klinik, Diagnostik und Therapie – Eine Kasuistik und Übersicht." *Zeitschrift für Gefäßmedizin* 11.2 (2014): 18-22. <https://www.kup.at/journals/praxisrelevanz/12240.html>
21. Garni, S. N., N. Mertineit, G. Nöldge, K. Daneshvar, and F. Mosler. "The Regulatory Needs for Radiation Protection Devices Based Upon Artificial Intelligence: State Task or Leave Unregulated?". *Swiss Journal of Radiology and Nuclear Medicine*, vol. 5, no. 1, Feb. 2024, p. 5, doi: <https://doi.org/10.59667/sjoranm.v5i1.11>
22. Mertineit, N., C. Buitrago Tellez, P. Kissling, F. Mosler, J. Heverhagen, and G. Nöldge. "A Complex Retrograde Transarterial Access and Embolization of a Giant Internal Iliac Artery Aneurysm After Occlusion Failure of Micro Vascular plug (MVP) Embolization and preceding EVAR in the Distal Ectatic Aorta and Bilateral Iliac Artery Aneurysms". *Swiss Journal of Radiology and Nuclear Medicine*, vol. 6, no. 1, Mar. 2024, p. 10, doi: <https://doi.org/10.59667/sjoranm.v6i1.12>