Endocrinology, Diabetes & Metabolism CASE REPORTS

EDM Case Reports (2024) **2024** e230090
https://doi.org/10.1530/EDM-23-0090

Received 9 August 2023
Accepted 12 July 2024
Version of Record Published 1 August 2024

Late diagnosis of partial 3*β*-hydroxysteroid dehydrogenase type 2 deficiency – characterization of a new genetic variant

Cagla Margit Øzdemir[1], Mette Mølby Nielsen[2], Jani Liimatta[3,4,5], Clarissa D Voegel[4,6], Rawda Naamneh Elzenaty[3,4,7], Victor S Wasehuus[1], Marie Lind-Holst[8,9], Marie Juul Ornstrup[1,9], Stine Bjørn Gram[10,11], Lilian Bomme Ousager[10,11], Christa E Flück[3,4] and Claus H Gravholt[1,9,12]

[1]Department of Endocrinology, Aarhus University Hospital, Aarhus N, Denmark
[2]Department of Clinical Biochemistry, Aarhus University Hospital, Aarhus N, Denmark
[3]Division of Pediatric Endocrinology, Diabetology and Metabolism, Department of Pediatrics, Bern University Hospital, University of Bern, Switzerland
[4]Department of Biomedical Research, University of Bern, Switzerland
[5]Kuopio Pediatric Research Unit (KuPRu), University of Eastern Finland, Kuopio, Finland
[6]Department of Nephrology, Bern University Hospital, University of Bern, Switzerland
[7]Graduate School of Cellular and Biomedical Sciences, University of Bern, Switzerland
[8]Department of Paediatrics, Odense University Hospital, Odense, Denmark
[9]Department of Molecular Medicine, Aarhus University Hospital, Aarhus N, Denmark
[10]Department of Clinical Genetics, Odense University Hospital, Odense, Denmark
[11]Department of Clinical Research, University of Southern Denmark, Odense, Denmark
[12]Department of Clinical Medicine, Aarhus University Hospital, Aarhus N, Denmark

Correspondence should be addressed to C Gravholt: ch.gravholt@dadlnet.dk

Summary

Congenital adrenal hyperplasia (CAH) is one of the most common inherited rare endocrine disorders. This case report presents two female siblings with delayed diagnosis of non-classical CAH 3β-hydroxysteroid dehydrogenase type 2 (3βHSD2D/*HSD3B2*) despite early hospital admission and apparent CAH manifestations such as infections, hirsutism, menstrual disturbances, and PCOS phenotype. Initially, sister 1 was misdiagnosed with PCOS and then 11-hydroxylase deficiency (*CYP11B1*), based on ultrasound, biochemical findings, and negative genetic testing for 21-hydroxylase deficiency (*CYP21A2*). Additional diagnostic workup was performed when sister 2 also presented with symptoms of androgen excess. Genetic testing for CAH/steroid disorders finally revealed that both siblings were compound heterozygous for two variants in the *HSD3B2* gene: a frameshift variant, c.558dup, p.(Thr187Hisfs*17) and a novel missense variant, c.65T>C, p.(Leu22Ser). A Synacthen test showed an insufficient cortisol increase. *In vitro* studies of the variants in a cell model revealed loss of function for the p.(Thr187Hisfs*17) and partial activity for p.(Leu22Ser) confirming non-classic CAH. Overlapping symptomatology and lack of specialized knowledge on steroid biosynthesis and associated rarest forms of CAH may explain the delayed diagnosis. However, with newer diagnostic methods comprising a less biased approach, very rare forms of non-classical CAH may no longer be overlooked in the future.

Published by Bioscientifica Ltd.
https://edm.bioscientifica.com

EDM Case Reports (2024) **2024** e230090
https://doi.org/10.1530/EDM-23-0090

Learning points

- Non-classic 3βHSD2 is likely underdiagnosed.
- Late diagnosis of mild non-classic 3βHSD2 does occur and one should be aware of this diagnosis.
- Early diagnosis of NCCAH may prevent many consequences such as severe hirsutism, prolonged menstrual irregularities, infertility, or even adrenal crisis with severe infections.
- Comprehensive steroid profiling and genetic testing should be used earlier, especially when in doubt about a diagnosis.

Background

Congenital adrenal hyperplasia (CAH) is one of the most common inherited endocrine disorders (1) and the most frequent cause of primary adrenal insufficiency in children (2). 21-hydroxylase deficiency (21OHD/*CYP21A2*) represents > 95% of all cases of CAH (3), whereas 3β-hydroxysteroid dehydrogenase type 2 deficiency (3βHSD2D/*HSD3B2*) is extremely rare and accounts for < 0.5% of all CAH cases (1, 4). A newly published Danish nation-wide cohort study reported an incidence of 3β-hydroxysteroid dehydrogenase of 0.01 per 1 000 000 (3). CAH is divided into two major types: a classical and a non-classical form (NCCAH). The classical form is furthermore divided into a simple-virilizing and a salt-wasting (SW) type, where the latter accounts for ~75% of classic 21OHD (1). The clinical and hormonal spectrum of CAH is broad and depends on the type of genetic variant, residual enzymatic activity, and age at presentation (1). The enzyme 3β-hydroxysteroid dehydrogenase appears in two isoforms, type 1 and type 2 encoded by the *HSD3B1* and *HSD3B2* genes, respectively. In humans, *HSD3B1* is mainly expressed in the placenta and peripheral tissues including the prostate, liver, skin, and mammary glands, while *HSD3B2* is mostly expressed in the adrenal glands and gonads (1). Mild forms and late-onset 3βHSD2D usually manifest with acne, precocious puberty, growth acceleration in children, menstrual disturbances, hirsutism, and polycystic ovarian syndrome (PCOS) in young females (1, 4).

Individuals with the classical SW phenotype are normally diagnosed at newborn screening or in relation to the development of an adrenal crisis with infections early in life where they present with hyponatremia, hyperkalaemia, metabolic acidosis, and hypoglycaemia. Individuals with NCCAH with mild symptoms are usually diagnosed later, e.g. prior to puberty, in adolescence, or during adulthood (4, 5, 6). Still, some may never be diagnosed, and some researchers even argue for the existence of NCCAH forms of 3βHSD2D, which is rare compared with NCCAH 21OHD (4). We report two Danish sisters with delayed diagnosis of NCCAH due to partially impaired 3βHSD2 activity and characterize both the known and the new genetic variants.

Case presentation

We present two sisters aged 23 (proband; sister 1) and 25 (sister 2). Both were full-term girls who were born to a non-consanguineous Caucasian couple, with an uneventful pregnancy and delivery. Physical examination at birth was with normal findings, no dysmorphic features, no signs of virilization, or any pathological conditions. They have no family history of hormonal disorders, diabetes, cardiovascular diseases, or similar conditions. Through patient records, we obtained medical history, biochemistry, genetics, and phenotypic presentation. Both patients gave written consent to participate in this study. According to local law, further ethical approval was not necessary.

Sister 1: First hospital admission with viral intestinal infection at age 4. Eight years later referred to the paediatrics unit due to growth acceleration and hirsutism, and later because of primary amenorrhoea. Differential diagnoses in chronological order were as follows: acromegaly and hirsutism, primary amenorrhoea, PCOS, and lastly CAH due to 21OHD. Acromegaly was disproven. A Synacthen test at age 10 showed a borderline cortisol response of 437 nmol/L and normal androstenedione, but slightly increased DHEAS of 15.4 (normal range (NR): < 1–12 µmol/L) and testosterone of 4.5 (NR: < 2.4–3.5 nmol/L) (Table 1). Ultrasound revealed polycystic ovaries. Physical examination at age 16 showed pubic hair Tanner 4, mild acne (face, back, and breasts), and normal body mass index and blood pressure. Biochemical values revealed normal electrolytes, increased 17-hydroxyprogesterone (17OHP4) of 33.9 nmol/L (NR: < 3–10 nmol/L), high-normal total testosterone of 3.6 nmol/L (NR: < 2.4–3.5 nmol/L), increased DHEAS at 27 µmol/L (NR: < 1–2 µmol/L), and increased luteinizing hormone (LH) of 16.3 IU/L (NR: < 2.4–12.6 IU/L), but normal basal levels of renin, aldosterone, cortisol, and ACTH. NCCAH due to 21-hydroxylase deficiency was suspected, but the genetic test for *CYP21A2* variants was negative.

EDM Case Reports (2024) **2024** e230090
https://doi.org/10.1530/EDM-23-0090

Table 1 Plasma hormone levels at 0, 30, and 60 min after IV injection of 250 µg Synacthen at a reevaluation of two young adult women aged 23 and 25 years manifesting with ongoing androgen excess and menstrual irregularities.

			Post injection of Synacthen	
Parameter/subject	**RR**	**0 min**	**At 30 min**	**At 60 min**
ACTH	7–64			
Sister 1		39	–	–
Sister 2		73	–	–
Progesterone (nmol/L)	< 3.7			
Sister 1		2.1	2.7	2.8
Sister 2		4.2	5.4	6.2
17OHP4 (nmol/L)	< 3			
Sister 1		7.7	10.4	11.9
Sister 2		3.8	6.0	7.0
Cortisol (nmol/L)	171–536			
Sister 1		356	335	387
Sister 2		329	385	465
Androstenedione (nmol/L)	2.4–8.9			
Sister 1		2.8	2.6	2.7
Sister 2		5.4	6.6	6.8
DHEAS (µmol/L)	1–12			
Sister 1		4.0	4.0	3.3
Sister 2		10.2	11.4	11.6
Androstenedione/DHEAS ratio				
Sister 1		0.70	0.65	0.82
Sister 2		0.53	0.58	0.58
Testosterone (nmol/L)	< 2.4			
Sister 1		0.56	0.51	0.53
Sister 2		0.48	0.93	1.1

17OHP4, 17-hydroxyprogesterone; DHEAS, dehydroepiandrosterone sulphate; RR, reference range.

Karyotype was 46,XX. Therefore, with a picture of polycystic ovaries, low sex hormone-binding globulin (SHBG), relatively high testosterone, and increased DHEAS and LH the diagnosis PCOS was put forward. Exercise was recommended, but no improvement occurred. Further assessment of 24 h urinary steroid metabolites showed increased C19-androgen metabolites and increased 17OHP4 metabolites, and a Synacthen test showed a normal cortisol response of 620 nmol/L and an increase of 17OHP4 to 15.9 nmol/L. Based on these biochemical and clinical findings NCCAH due to 11-hydroxylase deficiency (11OHD) was suspected. Treatment with hydrocortisone (10 + 5 mg) was started, and later dexamethasone (0.1 mg) added since it was not possible to suppress androgens sufficiently with hydrocortisone only. This treatment normalized her menstruation and biochemical findings. The remaining complaint was hirsutism. The gynaecological examination was normal. At age 23 she was referred to genetic counselling.

Sister 2: First hospital admission was at 1 year of age due to fever, vomiting, diarrhoea, flaccidity, poor contact, and possibly pneumonia, described as an episode of near death by the mother. Seven years later hospitalized with fever, dehydration, and vomiting with the suspicion of urinary tract infection and adrenal insufficiency. A Synacthen test was performed showing a peak cortisol of 437 nmol/L. In the following years, the patient had several hospital contacts due to fever, nausea, stomach pain, and headache with spontaneous recovery and no identified causes. At age 16 during an acute event and hospitalization, she was suspected to have Morbus Addison, and a Synacthen test was performed but showed a normal cortisol response of 674 nmol/L (cortisol NR > 500 nmol/L). Follow-up in the gynaecological outpatient clinic due to dysmenorrhoea resulted in treatment with a birth-control pill after an MR scan of internal genitalia revealed normal ovaries with follicles and no pathological findings. Eight years later, at the age of 24 years, diagnostic workup due to hyperandrogenic symptoms, menstrual irregularities, and hirsutism was repeated. Blood samples showed normal androgen levels and 17OHP4. Gynecological examination was normal. At age 25, she was referred to genetic counselling together with sister 1. Treatment with hydrocortisone (10 + 5 mg) was started to control the hyperandrogenic symptoms.

Investigation

Genetic analysis

Genetic testing on DNA extracted from peripheral blood was performed on sister 1 at the age of 23 years using a next-generation sequencing (NGS)-based gene panel targeting 12 genes related to congenital adrenal hyperplasia (*ARMC5*, *CYP11A1*, *CYP11B1*, *CYP11B2*, *CYP17A1*, *CYP21A2*, *HSD3B2*, *PDE11A*, *PDE8B*, *POR*, *PRKAR1A*, *STAR*) (Blueprint Genetics, Finland). The reference genome was GRCh37. Testing for the identified variants in sister 1 was subsequently performed in sister 2.

Hormone analyses

Cortisol was measured using automated chemiluminescence immunoassay (ADVIA® Centaur Cortisol, 10994924, Siemens) on the ADVIA® Centaur XPT Immunoassay System (Siemens). Progesterone was measured using an automated electrochemiluminescence assay (Elecsys Progesterone III, 0709539, Roche Diagnostics) on the Cobas 8000 analyzer, e-module (Roche Diagnostics). 17OHP4, androstenedione, testosterone, and DHEAS were measured using an in-house LCMS-MS assay (Sciex). The assays were calibrated using a commercially available 6-point calibration curve (Chromsystems). These methods are accredited according to the DS/EN ISO 15189.

EDM Case Reports (2024) **2024** e230090
https://doi.org/10.1530/EDM-23-0090

A Synacthen test (sampling before and after 30 and 60 min) was performed after 5 days off medication with hydrocortisone and/or dexamethasone after IV injection of 250 µg Synacthen®. Response levels of cortisol > 500 nmol/L are considered normal in adults, and in most cases exclude adrenocortical insufficiency (7).

Characterization of identified *HSD3B2* variants in non-steroidogenic cells

Construction of expression vectors

Human full-length *HSD3B2* cDNA cloned into a pcDNA3 mammalian expression vector was available from previous work (Flück's laboratory, Bern, Switzerland). Mutant cDNA expression vectors were generated using PCR-based, site-directed mutagenesis following the QuikChange protocol by Stratagene (Agilent Technologies Inc.). For PCR, 2 µL WT-*HSD3B2* plasmid (430 ng/µL) and 1 µL each (forward/reverse) primer (20 µM) were used, and temperatures/time for denaturation, annealing, and extension stages were 95°C/0.5 min, 55°C/1 min, and 68°C/8 min, respectively. The resulting mutated plasmids were selected through digestion with Dpnl (10 U) at 37°C for 60 min and subsequently propagated in *Escherichia coli*. The success of the Dpnl digestion was confirmed by culturing positive (WT without Dpnl) and negative (WT with Dpnl) controls. Mutant plasmids were then extracted from cultivated colonies using PureYield™ Miniprep kit (Promega Corporation), and true colonies with mutant plasmid were confirmed by direct sequencing (MicroSynth AG). Thereafter, colonies with mutant plasmids were grown in big inoculums before extraction using a NucleoBond™ Maxi kit (Macherey-Nagel). Finally, the sequences for extracted WT and mutant plasmids were confirmed by direct sequencing (MicroSynth AG). Primer sequences used in site-directed mutagenesis are available upon request.

Cell line, transient transfection, and steroid profiling

HEK293T cells (ATCC) were cultured in Dulbecco's Modified Eagle Medium (DMEM; Thermo Fisher Scientific) with 10% fetal bovine serum (FBS; Life Technologies Inc.) and 1% penicillin/streptomycin (pen/strep; Life Technologies Inc.) at 37°C in 5% CO_2. The cells were divided into 12-well plates (BD Biosciences) 24 h before transfection in a density of 2×10^5 cells/well. For transfection, Lipofectamine™ 2000 transfection reagent (Thermo Fisher Scientific) was used according to the manufacturer's instructions, and the cells were transiently transfected (1 µg plasmid DNA/well) either with the empty pcDNA3 vector (negative control), WT-*HSD3B2*, or one of the mutant *HSD3B2* plasmids (c.65T>C mutant or c.558dup). One day (24 h) after transfection, cell media was changed and 48 h after transfection the cell medium was enriched with a steroid mixture, which was prepared in DMEM (including 10% FBS and 1% pen/strep) and included substrates for HSD3B2 (pregnenolone, 17-hydroxypregnenolone (17OHP5) and dehydroepiandrosterone (DHEA)) at five different concentrations (0.1, 0.3, 1.0, 3.0, and 10 µM). Twenty-four hours later the cell supernatants were collected for LC-MS steroid profiling, while the cells were frozen for further experiments. Equal expression of the WT and variant HSD3B2 was confirmed by extracting total RNA from frozen cells with TRIzol reagent (Invitrogen AG) and Direct-zol RNA kit (Zymo Research), followed by reverse transcription and PCR amplification with specific primers (data not shown). Primer sequences are available upon request.

Steroid measurements

Collected cell supernatants were stored at −20°C until analysis by an in-house LC-MS/MS using previously described and validated methods (8). Briefly, 500 µL collected cell media were spiked with 38 µL a mixture of internal standards (3.8 nM each), a protein precipitation step using zinc sulphate and methanol followed and steroids were extracted using solid-phase extraction with an OasisPrime HLB 96-well plate (Waters Corporation). Samples were re-suspended in 100 µL 33% methanol in water and 20 µL injected into the LC-MS instrument (Vanquish UHPLC coupled to a QExactive Orbitrap Plus, Thermo Fisher Scientific) using an Acquity UPLC HSS T3 column (Waters Corporation). Data from the mass spectrometer was processed using TraceFinder 4.0. Kinetic conversion parameters were calculated using GraphPad Prism 9 (GraphPad Software Inc.).

Genetic analysis

Genetic testing identified two compound heterozygous variants in the *HSD3B2* gene in both sisters. The first variant, c.558dup, p.(Thr187Hisfs*17), was a duplication of one base pair in exon 4 (out of 4) which generates a frameshift leading to a premature stop codon (Fig. 1A). The variant, in the heterozygous state, is reported in one individual in the population variant database Genome Aggregation Database (gnomAD) and once in the literature in a patient with 3βHSD2D as compound heterozygous with another nonsense variant leading to a severe, classic phenotype (9). Further, it has been reported as pathogenic three times in ClinVar. The second variant was a novel missense variant c.65T>C, p.(Leu22Ser) in exon 2 leading to the substitution of a highly conserved leucine to serine. The variant was absent in gnomAD. It has not been reported in either ClinVar or the literature.

EDM Case Reports (2024) **2024** e230090
https://doi.org/10.1530/EDM-23-0090

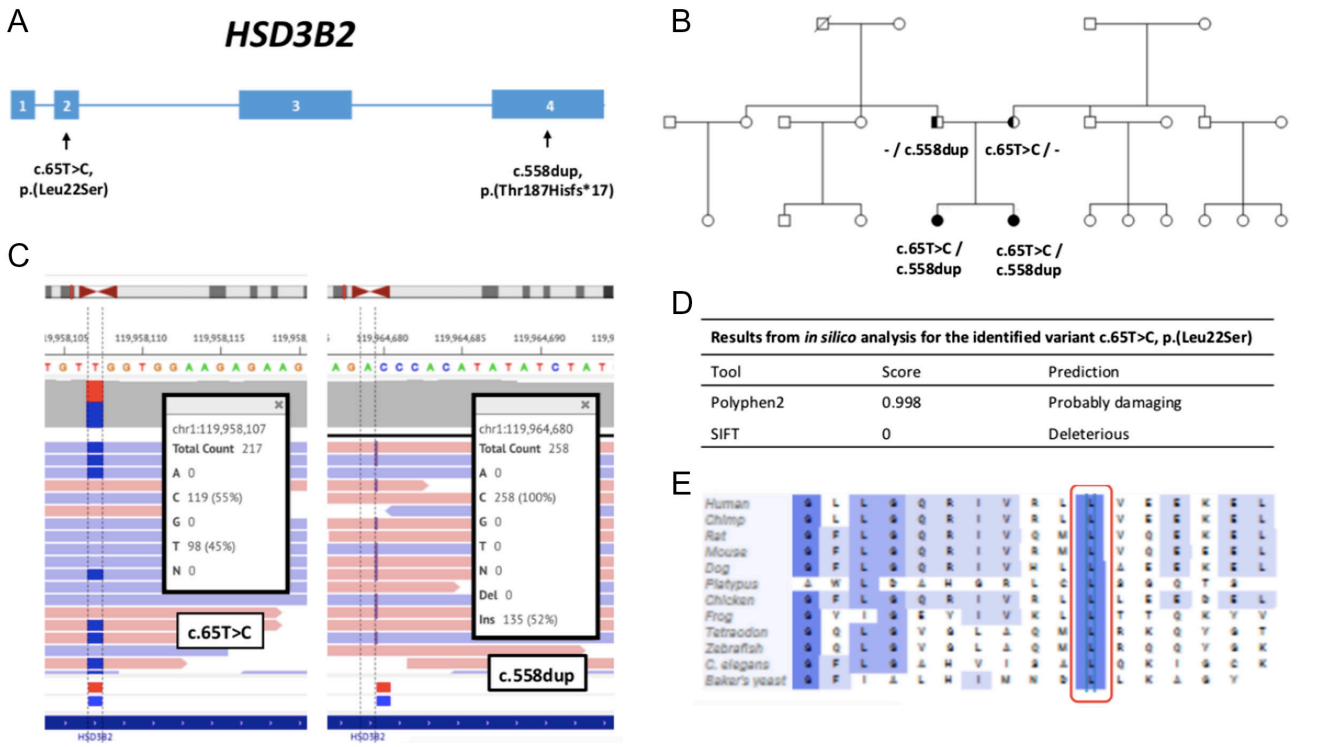

Results from *in silico* analysis for the identified variant c.65T>C, p.(Leu22Ser)

Tool	Score	Prediction
Polyphen2	0.998	Probably damaging
SIFT	0	Deleterious

Figure 1

A–E. Genetic characterization of a novel and a known *HSD3B2* variant. An overview of gene and detected variants, pedigree of the family, variants visualized, *in silico* analysis for the variant, and conservation of the affected amino acid is provided and detected variants in the *HSD3B2* gene. *HSD3B2* contains four exons. The missense variant c.65T>C, p.(Leu22Ser) is located in exon 2 and leads to the substitution of the amino acids leucine to serine. The frameshift variant c.558dup, p.(Thr187Hisfs*17) is a duplication of one base pair in exon 4 leading to a premature stop codon. B. Pedigree of the family. The two affected sisters marked with black are compound heterozygous for the identified variants. The parents are each heterozygous for one of the detected variants in *HSD3B2* and are carriers of the condition. C. Variants visualized using Integrative Genomics Viewer (https://software.broadinstitute.org/software/igv/). As presented in the boxes, the missense variant in *HSD3B2*, c.65T>C is seen in 55 % of the reads in dark blue and the duplication in *HSD3B2*, c.558dup, is seen in 52% of the reads visualized as a small purple line. D. Results from *in silico* analysis for the newly identified variant c.65T>C, p.(Leu22Ser). The variant was predicted to be deleterious to protein function by *in silico* software analysis. E. Conservation of the affected amino acid. The novel variant c.65T>C, p.(Leu22Ser) leads to the substitution of leucine to serine. As indicated by the red square, leucine is present at this position in 12 out of 12 species and is thus a highly conserved amino acid.

The variant is predicted to be deleterious to protein function using PolyPhen-2 and SIFT software analyses (Fig. 1C, D, and E). Based on the collected information on the variants, c.558dup, p.(Thr187Hisfs*17) was considered as pathogenic and c.65T>C, p.(Leu22Ser) as likely pathogenic. Further genetic testing revealed that parents were carriers of one of these variants each (Fig. 1B) confirming compound heterozygosity.

In vitro functional characterization of the identified HSD3B2 variants

To assess the disease-causing effect of the two identified *HSD3B2* variants, we tested the functional activity of the two variants in non-steroidogenic HEK cells for their enzymatic steroid conversion capacity using direct substrates pregnenolone, 17OHP5, and DHEA. While the WT *HSD3B2 enzyme* was able to convert all tested substrates pregnenolone, 17OHP5, and DHEA to progesterone, 17OHP4, and androstenedione, respectively, the frameshift variant p.(Thr187Hisfs*17) showed complete loss of activity and the missense variant p.(Leu22Ser) had partial activity. The activity of p.(Leu22Ser) to convert P5, 17OHP5, and DHEA to progesterone, 17OHP5, and androstenedione was approximately 20–50% of WT activity, with DHEA being still converted by about half of WT activity. Conversion velocities (μM/24 h) of WT and variant (*y*-axis) against substrates P5, 17OHP5, and DHEA (*x*-axis with substrate concentrations) are shown in Fig. 2A, B, and C.

Discussion

We present two female siblings with a delayed diagnosis of NCCAH due to 3βHSD2D. We show clinical data compatible with the diagnosis, biochemical results, and the genetic workup that identified the

EDM Case Reports (2024) **2024** e230090
https://doi.org/10.1530/EDM-23-0090

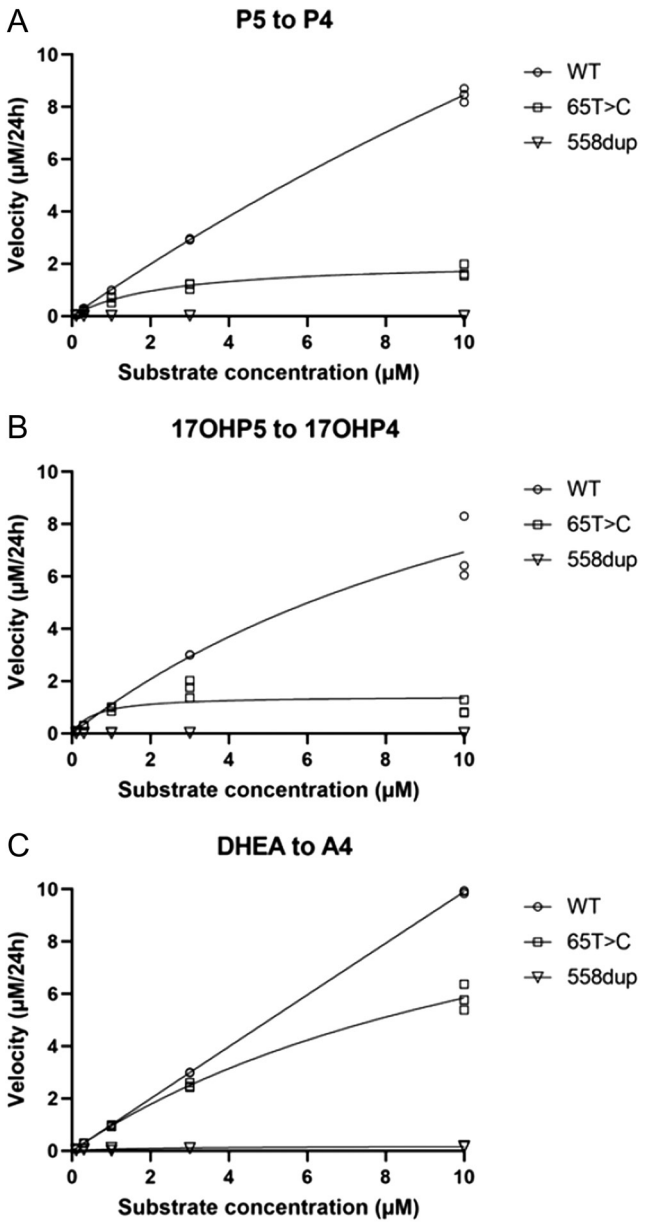

Figure 2

A–C. Functional characterization of two *HSD3B2* variants p.(Thr187Hisfs*17) and p.(Leu22Ser) *in vitro*. Non-steroidogenic HEK cells were transiently transfected with wild-type (WT) and variant HSD3B2 expression vectors for 48 h (A–C). Activity of transfected cells to convert either A) pregnenolone (P5) to progesterone (P4), B) 17-hydroxypregnenolone (17OHP5) to 17-hydroxyprogesterone (17OHP4), or C) dehydroepiandrosterone (DHEA) to androstenedione (A4) at given substrate concentrations (*x*-axis) was assessed by measuring steroids in the supernatants after 24 h incubation by LC-MS/MS. Conversion is given as µM/24 h. Graphs were produced by GraphPad Prism from data of three independent experiments performed in triplicate.

underlying genetic variants in the *HSD3B2* gene. We also provide functional studies attesting loss-of-function to the previously reported frameshift variant p.(Thr187Hisfs*17) (9) and partial activity to the novel missense variant c.65T>C, p.(Leu22Ser), not hitherto reported in the literature or databases.

Delayed diagnosis is a common problem in rare disorders. CAH is a rare disorder and especially patients with the non-classical forms of CAH are often diagnosed with a significant delay (3), especially if other steroid enzymes than 21-hydroxylase (*CYP21A2*) are affected, as they are very rare. Late diagnosis of NCCAH often has severe consequences in terms of androgen excess and fertility issues and it can be difficult to treat (1, 10). Diagnosis of NCCAH is challenging due to an often unspecific phenotype and poor genotype–phenotype correlation (11, 12). Many patients are misdiagnosed with PCOS and therefore do not receive the correct treatment (12). This applies to the case history of sister 1, who went through the differential diagnosis of first NCCAH due to 21OHD, then PCOS, followed by 11OHD, before she was finally diagnosed with 3βHSD2D.

PCOS is the most common endocrine disease among fertile women (13). Studies have shown that many females with NCCAH (mostly due to 21OHD) had initially been diagnosed with PCOS because of overlapping features such as acne, polycystic ovaries, and/or hirsutism (14, 15). Thus all current guidelines for diagnosing PCOS ask for investigations to exclude CAH or other known disorders causing androgen excess before putting the label PCOS on a woman as PCOS is a diagnosis by exclusion (16). In the reported siblings the common clinical symptom and sign was hirsutism, which is known to be the most common phenotypic manifestation of NCCAH (71–96%) (12), together with menstrual irregularities (4). However, not all patients with mild symptoms and hormonal imbalance come to medical attention (17), and on the other hand, not all patients with mild symptoms need treatment (1, 18). Some females are diagnosed for the first time in a fertility clinic due to infertility (19) or as a result of the diagnosis of another family member (12) as sister 2 of this report. She sought medical help after 8 years with hirsutism and dysmenorrhoea after cortisol deficiency was ruled out by an ACTH test at the age of 16.

NCCAH may also affect the metabolism (20). Insulin resistance in NCCAH may be due to the underlying steroid disorder (21, 22) or a consequence of the drug therapy with glucorticosteroids (23).

For CAH (as for many other rare diseases), knowing the specific diagnosis at the molecular level is important for the patient and the caring physician as treatment and management of the disease with all its consequences can be more specific and effective (2). A genetic workup with a broader approach than just a single gene candidate analysis can help in reaching a diagnosis more successfully. This was certainly true for our cases

EDM Case Reports (2024) **2024** e230090
https://doi.org/10.1530/EDM-23-0090

where a gene panel analysis for known genes causing CAH and PAI has led to the final diagnosis.

CAH is a subcategory of primary adrenal insufficiency (PAI), and the most frequent cause of PAI among children (2). PAI is relatively rare and can manifest nonspecific and therefore be overlooked. Even though NCCAH is primarily known to be less severe than classical CAH, there are still some possible consequences, which can be prevented or minimized by early diagnosis and treatment. Treatment with glucocorticoids in patients with NCCAH is only needed in symptomatic patients, and in situations of stress, if the cortisol response after ACTH stimulation is insufficient (12, 18). It is important to realize that patients with NCCAH treated with GCs have an increased risk for an adrenal crisis with severe stress (fever, infections, surgery, etc.). Thus, NCCAH patients given GCs need to be instructed concerning emergency dosing of their GCs, and sick day rules, and should carry an emergency card warning for possible adrenal crisis. Thus, sister 1 should be instructed for emergencies for two reasons, first because she is receiving GCs, and second, because she failed the ACTH test. Sister 2 was not originally treated with GCs, and her latest ACTH test was normal. Nevertheless, in order to control hyperandrogenic symptoms she is now also receiving GCs. In her case, it is noteworthy that her past medical history with multiple hospital stays with infections and unspecific symptoms hints at possible events of relative cortisol deficiency in her past. In fact, a retrospective study by Rushworth *et al.* (24) reported a decline in adverse events due to cortisol insufficiency with increasing age for CAH children.

The typical steroid profile of classic CAH due to HSD3B2D is elevated delta5 steroids (pregnenolone, 17OHP5, and DHEA) with decreased downstream metabolites and increased ratios of delta5/delta4 steroids (e.g. preg/prog, 17OHP5/17OHP4, DHEA/A4). Thus severe 3βHSD2 deficiency leads to mineralocorticoid and glucocorticoid deficiency and variable degree of androgen deficiency, while mild, non-classic 3βHSD2 may manifest with a less clear steroid pattern that may only be recognized after ACTH stimulation and running a comprehensive steroid profile. Both siblings presented with fluctuating single steroid levels over the years, especially testosterone, 17OHP4, and cortisol. Unfortunately, a comprehensive steroid profile including the diagnostic marker steroids for 3beta deficiency was never available. Basal cortisol levels are typically normal in all forms of NCCAH but may be borderline after ACTH stimulation. Testosterone and 17OHP4 are typically elevated upon ACTH stimulation with NCCAH due to 21OHD. Testosterone and 17OHP4 are not typically elevated with NCCAH due to HSD3B2 but may present with slightly elevated levels intermittently as the type 1 enzyme of 3beta may convert precursors in the periphery (25). This may have caused confusion in the reported patients. In addition, the steroids measured did not represent a comprehensive view of all steroid pathways and enzymes (and thus possible forms of CAH) of the adrenal cortex, and were actually only focusing on a possible 21OHD. In addition, the negative genetic testing for *CYP21A2* variants of sister 1 has likely led to the exclusion of NCCAH and contributed further to the delayed diagnosis as other, rarer forms of NCCAH have not been considered.

Conclusion

In conclusion, atypical clinical and hormonal phenotypes of rare steroid disorders and a lack of specific knowledge among endocrinologists or paediatricians may lead to delayed diagnosis. In such cases, comprehensive steroid profiling and/or genetic testing are essential tools leading to a correct diagnosis.

Early diagnoses of NCCAH may prevent consequences such as severe hirsutism, prolonged menstrual irregularities, infertility, or even adrenal crisis with severe infections, and delayed treatment. It is important to consider a very rare, non-*CYP21A2* gene variant form of CAH when females present with hirsutism, menstrual irregularity, PCO, and present with unusual biochemical findings, not compatible with 21OHD. This argues for the need to perform comprehensive steroid profiling and genetic testing, at least in unusual cases, as a correct diagnosis is key to proper treatment, prediction of prognosis, and genetic counselling.

Declaration of interest
The authors declare that there is no conflict of interest that could be perceived as prejudicing the impartiality of the study reported.

Funding
Novo Nordisk Foundation (NNF20OC0060610), Familien Hede Nielsens Fond, Independent Research Fund Denmark (0134-00406A). JL received research fellowship grants from the Sigrid Jusélius Foundation and the Foundation for Pediatric Research (Helsinki, Finland).

Patient consent
Both patients gave written consent to participate in this study. According to local law further ethical approval was not necessary.

Author contribution statement
All authors made individual contributions to authorship. VSW, CAØ, MJO, ML-H, CHG: diagnosis and management of patients and manuscript submission. SBG, LBO: genetic analyses. MMN: biochemical analyses. JL, CDV, RNE, CEF: functional analyses. All authors reviewed and approved the final draft.

References

1 Claahsen-van der Grinten HL, Speiser PW, Ahmed SF, Arlt W, Auchus RJ, Falhammar H, Flück CE, Guasti L, Huebner A, Kortmann BBM, *et al.* Congenital adrenal hyperplasia-current insights in pathophysiology, diagnostics, and management. *Endocrine Reviews* 2022 **43** 91–159. (https://doi.org/10.1210/endrev/bnab016)

2 Guran T, Buonocore F, Saka N, Ozbek MN, Aycan Z, Bereket A, Bas F, Darcan S, Bideci A, Guven A, *et al.* Rare causes of primary adrenal insufficiency: genetic and clinical characterization of a large nationwide cohort. *Journal of Clinical Endocrinology and Metabolism* 2016 **101** 284–292. (https://doi.org/10.1210/jc.2015-3250)

3 Berglund A, Ornstrup MJ, Lind-Holst M, Dunø M, Bækvad-Hansen M, Juul A, Borch L, Jørgensen N, Rasmussen ÅK, Andersen M, *et al.* Epidemiology and diagnostic trends of congenital adrenal hyperplasia in Denmark: a retrospective, population-based study. *Lancet Regional Health. Europe* 2023 **28** 100598. (https://doi.org/10.1016/j.lanepe.2023.100598)

4 Al Alawi AM, Nordenstrom A & Falhammar H. Clinical perspectives in congenital adrenal hyperplasia due to 3β-hydroxysteroid dehydrogenase type 2 deficiency. *Endocrine* 2019 **63** 407–421. (https://doi.org/10.1007/s12020-018-01835-3)

5 Nordenström A, Forest MG & Wedell A. A case of 3beta-hydroxysteroid dehydrogenase type II (HSD3B2) deficiency picked up by neonatal screening for 21-hydroxylase deficiency: difficulties and delay in etiologic diagnosis. *Hormone Research* 2007 **68** 204–208. (https://doi.org/10.1159/000102593)

6 Johannsen TH, Mallet D, Dige-Petersen H, Müller J, Main KM, Morel Y & Forest MG. Delayed diagnosis of congenital adrenal hyperplasia with salt wasting due to type II 3beta-hydroxysteroid dehydrogenase deficiency. *Journal of Clinical Endocrinology and Metabolism* 2005 **90** 2076–2080. (https://doi.org/10.1210/jc.2004-1374)

7 Javorsky BR, Raff H, Carroll TB, Algeciras-Schimnich A, Singh RJ, Colón-Franco JM & Findling JW. New cutoffs for the biochemical diagnosis of adrenal insufficiency after ACTH stimulation using specific cortisol assays. *Journal of the Endocrine Society* 2021 **5** bvab022. (https://doi.org/10.1210/jendso/bvab022)

8 Andrieu T, du Toit T, Vogt B, Mueller MD & Groessl M. Parallel targeted and non-targeted quantitative analysis of steroids in human serum and peritoneal fluid by liquid chromatography high-resolution mass spectrometry. *Analytical and Bioanalytical Chemistry* 2022 **414** 7461–7472. (https://doi.org/10.1007/s00216-022-03881-3)

9 Rhéaume E, Simard J, Morel Y, Mebarki F, Zachmann M, Forest MG, New MI & Labrie F. Congenital adrenal hyperplasia due to point mutations in the type II 3 beta-hydroxysteroid dehydrogenase gene. *Nature Genetics* 1992 **1** 239–245. (https://doi.org/10.1038/ng0792-239)

10 Aveiro-Lavrador M, De Sousa Lages A, Barros L & Paiva I. Late diagnosis of classic congenital adrenal hyperplasia: long-term consequences during adulthood. *Endocrinology, Diabetes and Metabolism Case Reports* 2021 **2021**. (https://doi.org/10.1530/EDM-21-0032)

11 Morel Y, Mébarki F, Rhéaume E, Sanchez R, Forest MG & Simard J. Structure-function relationships of 3 beta-hydroxysteroid dehydrogenase: contribution made by the molecular genetics of 3 beta-hydroxysteroid dehydrogenase deficiency. *Steroids* 1997 **62** 176–184. (https://doi.org/10.1016/s0039-128x(96)00178-x)

12 Livadas S & Bothou C. Management of the female with non-classical congenital adrenal hyperplasia (NCCAH): a patient-oriented approach. *Frontiers in Endocrinology (Lausanne)* 2019 **10** 366. (https://doi.org/10.3389/fendo.2019.00366)

13 Papadakis G, Kandaraki EA, Tseniklidi E, Papalou O & Diamanti-Kandarakis E. Polycystic ovary syndrome and NC-CAH: distinct characteristics and common findings. A systematic review. *Frontiers in Endocrinology (Lausanne)* 2019 **10** 388. (https://doi.org/10.3389/fendo.2019.00388)

14 Yarman S, Dursun A, Oguz F & Alagol F. The prevalence, molecular analysis and HLA typing of late-onset 21-hydroxylase deficiency in Turkish woman with hirsutism and polycystic ovary. *Endocrine Journal* 2004 **51** 31–36. (https://doi.org/10.1507/endocrj.51.31)

15 Kamel N, Tonyukuk V, Emral R, Corapçioğlu D, Baştemir M & Güllü S. The prevalence of late onset congenital adrenal hyperplasia in hirsute women from Central Anatolia. *Endocrine Journal* 2003 **50** 815–823. (https://doi.org/10.1507/endocrj.50.815)

16 Costello MF, Misso ML, Balen A, Boyle J, Devoto L, Garad RM, Hart R, Johnson L, Jordan C, Legro RS, *et al.* Evidence summaries and recommendations from the international evidence-based guideline for the assessment and management of polycystic ovary syndrome: assessment and treatment of infertility. *Human Reproduction Open* 2019 **2019** hoy021. (https://doi.org/10.1093/hropen/hoy021)

17 Speiser PW, Knochenhauer ES, Dewailly D, Fruzzetti F, Marcondes JA & Azziz R. A multicenter study of women with nonclassical congenital adrenal hyperplasia: relationship between genotype and phenotype. *Molecular Genetics and Metabolism* 2000 **71** 527–534. (https://doi.org/10.1006/mgme.2000.3036)

18 Merke DP & Auchus RJ. Congenital adrenal hyperplasia due to 21-hydroxylase deficiency. *New England Journal of Medicine* 2020 **383** 1248–1261. (https://doi.org/10.1056/NEJMra1909786)

19 Livadas S, Stratakis CA & Macut D. Editorial: congenital adrenal hyperplasia, unresolved issues and implications on clinical management. *Frontiers in Endocrinology (Lausanne)* 2020 **11** 170. (https://doi.org/10.3389/fendo.2020.00170)

20 Williams RM, Deeb A, Ong KK, Bich W, Murgatroyd PR, Hughes IA & Acerini CL. Insulin sensitivity and body composition in children with classical and nonclassical congenital adrenal hyperplasia. *Clinical Endocrinology* 2010 **72** 155–160. (https://doi.org/10.1111/j.1365-2265.2009.03587.x)

21 Nordenstrom A & Falhammar H. Management of endocrine disease: diagnosis and management of the patient with non-classic CAH due to 21-hydroxylase deficiency. *European Journal of Endocrinology* 2019 **180** EJE-0712.

22 Falhammar H, Frisen L, Hirschberg AL, Norrby C, Almqvist C, Nordenskjold A & Nordenstrom A. Increased cardiovascular and metabolic morbidity in patients with 21-hydroxylase deficiency: a Swedish population-based national cohort study. *Journal of Clinical Endocrinology and Metabolism* 2015 **100** 3520–3528. (https://doi.org/10.1210/JC.2015-2093)

23 de Oliveira DM, Tura A, Vasques ACJ, Camilo DF, Lima MM, de Lemos-Marini SHV, Goncalves EM, Guerra-Junior G & Geloneze B. Insulin resistance in congenital adrenal hyperplasia is compensated for by reduced insulin clearance. *Journal of Clinical Endocrinology and Metabolism* 2021 **106** e1574–e1585. (https://doi.org/10.1210/clinem/dgab010)

24 Rushworth RL, Falhammar H, Munns CF, Maguire AM & Torpy DJ. Hospital admission patterns in children with CAH: admission rates and adrenal crises decline with age. *International Journal of Endocrinology* 2016 **2016** 5748264. (https://doi.org/10.1155/2016/5748264)

25 Burckhardt MA, Udhane SS, Marti N, Schnyder I, Tapia C, Nielsen JE, Mullis PE, Rajpert-De Meyts E & Flück CE. Human 3β-hydroxysteroid dehydrogenase deficiency seems to affect fertility but may not harbor a tumor risk: lesson from an experiment of nature. *European Journal of Endocrinology* 2015 **173** K1–K12. (https://doi.org/10.1530/EJE-15-0599)