

Istvan Vajtai · Rahel Sahli · Andreas Kappeler

Pituitary prolactinoma with T cell rich inflammatory infiltrate: a possible example of antitumoral immune response to be differentiated from lymphocytic hypophysitis

Received: 21 February 2006 / Revised: 8 March 2006 / Accepted: 8 March 2006 / Published online: 5 April 2006
© Springer-Verlag 2006

Inflammatory disorders of the pituitary comprise a nosologically heterogeneous group of lesions, the wide spectrum of which actually belies the perceived rarity of individual entities. These range from “bystander” involvement by inflammation of adjacent skull base or meninges (secondary hypophysitis), to self-perpetuating reparative lesions (sellar xanthogranuloma), to mononuclear infiltrates that can involve the pituitary either primarily or as part of systemic autoimmune disease [7, 9, 10].

Among the latter, lymphocytic hypophysitis (LYH) stands out as the single most important lesion, both because of its relative frequency and complex differential diagnosis [3, 7]. LYH tends to come to attention by virtue of its local tissue destruction or space-occupying character. While virtually every combination of site-specific clinical symptoms may result, hyperprolactinemia—especially one referable to “stalk section effect”—may occasionally occur as well [7].

In the context of ongoing or recently completed pregnancy, and more generally female gender and reproductive age, LYH has been notorious for often being nearly indistinguishable—if thought of at all—from prolactinoma, on clinical grounds. Histological confirmation of either diagnosis has been regarded as one excluding its alternative counterpart, for there is no reference in the literature to any case of pituitary harboring both prolactinoma and lymphocytic inflammation.

We recently had the privilege of studying an adenectomy specimen with concurrent prolactinoma and conspicuous intratumoral infiltration by reactive lymphocytes.

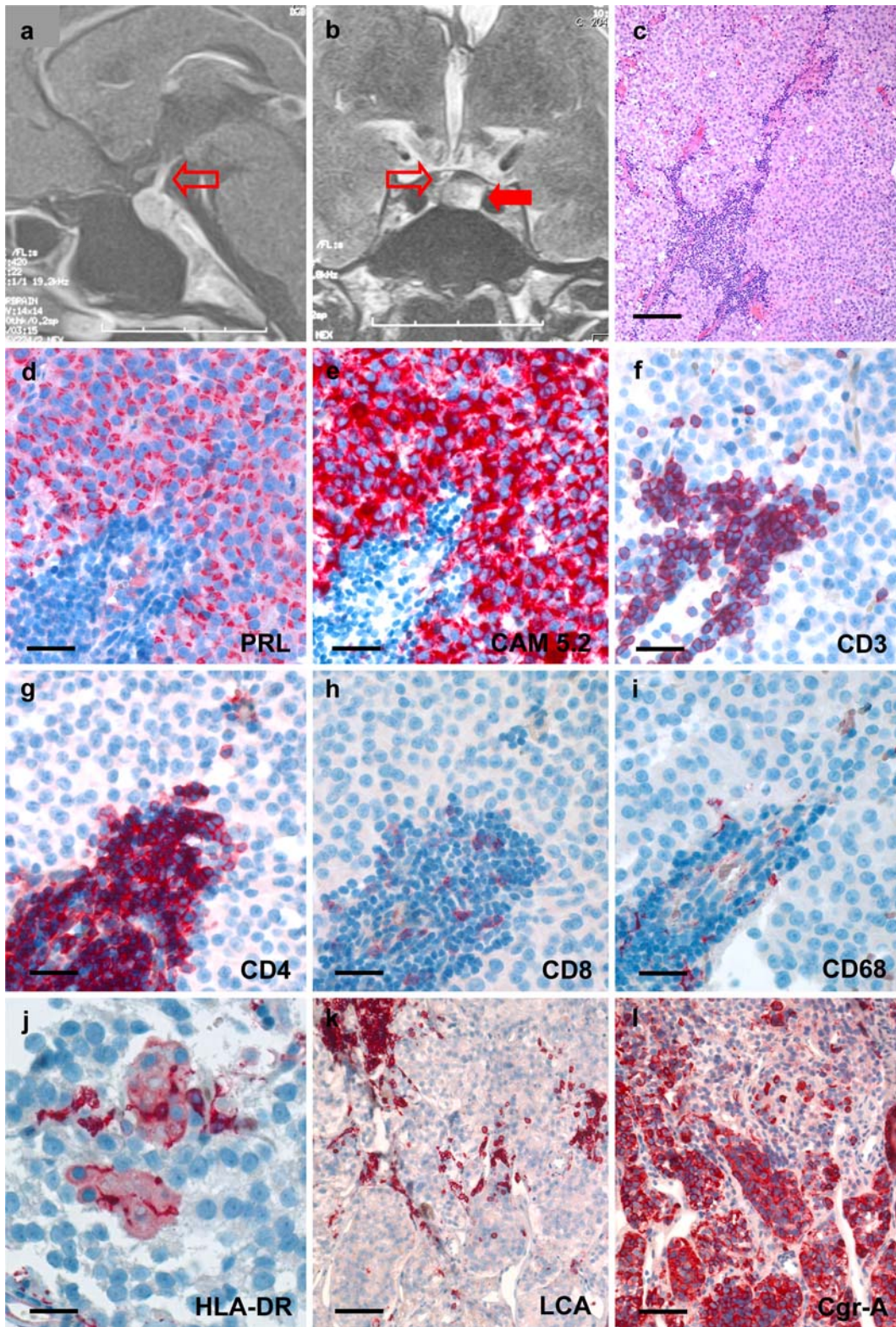
The patient, a 31-year-old nulliparous woman, underwent transsphenoidal microsurgery for oligo-amenorrhea with laboratory evidence of moderate hyperprolactinemia (140 µg/l). No preoperative dopaminergic therapy was attempted. The referring physician negated any clinical evidence of coexistent systemic inflammatory or autoimmune disease. Magnetic resonance imaging (MRI) showed a macroadenoma of 12 mm in diameter with intact sellar contours (Fig. 1a, b).

A fairly generous surgical specimen of 1.2 × 1 × 0.3 cm was available for processing, complete with some well-preserved residues of nontumorous adenohypophysis as well as small fragments of posterior lobe. The neoplastic moiety consisted of a slightly basophilic prolactin cell adenoma (WHO grade I) with monotypic expression of prolactin (PRL) in a Golgi-bound pattern, as well as robust CAM 5.2 (for cytokeratin 8 and cytokeratin 18) positivity (Fig. 1d, e). In addition, multiple angiocentric infiltrates of mononuclear cells were seen along intratumoral vascular septa (Fig. 1c). These comprised mostly CD3⁺ T lymphocytes, among which CD4⁺ helper cells predominated over those of CD8⁺ suppressor phenotype (Fig. 1f, h). Cytotoxic T cells featuring Granzyme-B or TIA-1 positive granules occurred very rarely (not shown). There were lesser amounts of interspersed CD79a⁺ B cells and only scarce CD68⁺ monocytes (Fig. 1i). Only seldom did the latter assume macrophage morphology; neither epithelioid cells nor granulomas were present. Morphological evidence of cell destruction, especially apoptotic figures or necrosis were absent, as was fibrosis. However, occasional CD68⁺ cells were seen intimately engaged with minute clusters of MHC II (HLA-DR) expressing adenoma cells via dendritic processes (Fig. 1j). The infiltrate was felt to be confined within intratumoral boundaries, while the adjacent residual parenchyma remained remarkably free of any inflammatory cells (Fig. 1k, l).

Our review of the literature yielded a mere two specific references to simultaneous neoplastic and inflammatory pathologies of the pituitary. The case reported by Holck and Laursen [4] involved a prolactinoma coexisting with

I. Vajtai (✉) · A. Kappeler
Institute of Pathology, University of Bern,
Murtenstrasse 31, Postfach 62, 3010 Bern, Switzerland
E-mail: istvanvajtai@yahoo.com
Tel.: +41-31-6323210
Fax: +41-31-6329938

R. Sahli
Department of Endocrinology,
University Hospital Bern, Bern, Switzerland



and indeed infiltrated by granulomatous hypophysitis. The authors' discussion is mainly focused on potential analogies between different forms of granulomatous reaction in endocrine organs. This article does not provide subtyping of inflammatory cells. In a second publication

by McConnon et al. [8], a sparsely granulated somatotroph cell adenoma in the context of otherwise classic LYH is dealt with. The inflammatory infiltrate is described as one focally impinging upon, rather than primarily involving neoplastic tissue.

◀
Fig. 1 **a** Sagittal post-Gadolinium MRI scan to show moderately enhancing pituitary mass with minimal suprasellar extension, yet unaffected bony contours. Slight displacement of pituitary stalk is evident (*empty arrow*). **b** T2 weighted frontal scan reveals intratumoral hyperintensity as compared to displaced residual pituitary parenchyma (*solid arrow*). Discreet outward kinking of pituitary stalk is appreciated (*empty arrow*). **c** Histological overview of inflammatory prolactinoma to show otherwise unremarkable, slightly basophilic adenoma tissue permeated by lymphocytes along vascular septa. **d, e** Tumor cells are identified as ones of lactotroph lineage by coexpression of PRL and low molecular weight cytokeratin. Note juxtannuclear Golgi-pattern of PRL immunoreactivity. **f–i** Perivascular area of tumor represented on serial sections to show cellular composition of inflammatory cuffs. Predominance of CD4⁺ T lymphocytes is appreciated by comparing **g** and **h**. **j** Occasional mononuclear elements with dendritic processes interact with small clusters of adenoma cells displaying conspicuous surface expression of MHC class II antigens. **k, l** Overview of adenoma/pituitary interface to show sparing of nontumorous tissue (lower half) by the process—which is quite pronounced in this field. Faint immunoreactivity of adenoma cells for Chromogranin assists in localizing transition zone. Slide in **c** was stained with hematoxylin and eosin; **d–l** were developed with EnVision (DAKO®) using new fuchsin as chromogen. *Bars:* **c** 120 μm; **d–i** 40 μm; **j** 32 μm; **k, l** 80 μm

The present case fulfills morphologic criteria of cell-mediated host immune reaction to bodily antigens, as seen in both tumors and under non-neoplastic conditions, including the pituitary [3]. This is unlikely to represent a mere coincidence, since the nontumorous adenohypophysis was remarkably exempt from inflammation. While postulating host defense mounted against adenoma cells readily comes to mind, diagnostic experience with pituitary adenomas fails to provide supporting evidence to this effect. Although pituitary epithelial cells do secrete potential autoantigens—among them PRL—the intratumoral microenvironment of adenomas seems to be lacking competence for antigen presentation [2, 5]. Pituitary adenomas have been shown not to depend on mitogenic signals conveyed by, and indeed tend to be devoid of folliculostellate cells—ones capable of antigen presentation in the context of MHC II molecules [1, 11]. To the best of our knowledge, expression of the latter has not been systematically investigated in pituitary adenomas. We document surface expression of HLA-DR molecules in a small minority of adenoma cells, ones consistently associated with CD68⁺ monocytes of dendritic morphology. Keeping in mind the versatile immunomodulatory effects of PRL, especially on

Th₁ and Th₂ lymphocytes in the early phase of inflammation, we propose that the lesion described here may reflect a short-lived cell mediated response directed at a subpopulation of tumor cells [2]. Whether proficient in eliminating individual tumor cells or not, this process is possibly ephemeral, and will eventually subside in the nonaccommodating immunologic milieu of the tumor. Since most prolactinomas only come to surgery after weeks to months of unresponsiveness to medication with dopamine agonists, this transitory phenomenon—should the present example be more than just a fortuitous occurrence—is likely to be missed [6].

References

1. Bodey B, Bodey B Jr, Kaiser HE (1997) Dendritic type, accessory cells within the mammalian thymic microenvironment. Antigen presentation in the dendritic neuro-endocrine-immune cellular network. *In Vivo* 11:351–370
2. De Bellis A, Bizzarro A, Pivonello R, Lombardi G, Bellastella A (2005) Prolactin and autoimmunity. *Pituitary* 8:25–30
3. Gutenberg A, Buslei R, Fahlbusch R, Buchfelder M, Bruck W (2005) Immunopathology of primary hypophysitis. Implications for pathogenesis. *Am J Surg Pathol* 29:329–338
4. Holck S, Laursen H (1983) Prolactinoma coexistent with granulomatous hypophysitis. *Acta Neuropathol* 61:253–257
5. Horvath E, Vidal S, Syro LV, Kovacs K, Smyth HS, Uribe H (2001) Severe lymphocytic adenohypophysitis with selective disappearance of prolactin cells: a histologic, ultrastructural and immunoelectron microscopic study. *Acta Neuropathol* 101:631–637
6. Kontogeorgos G, Horvath E, Kovacs K, Coire C, Lloyd RV, Scheithauer BW, Smyth HS (2006) Morphologic changes of prolactin-producing pituitary adenomas after short treatment with dopamine agonists. *Acta Neuropathol* 111:46–52
7. Leung GKK, Lopes MBS, Thorner MO, Vance ML, Laws ER Jr (2004) Primary hypophysitis: a single center experience in 16 cases. *J Neurosurg* 101:262–271
8. McConnon JK, Smyth HS, Horvath E (1991) A case of sparsely granulated growth hormone cell adenoma associated with lymphocytic hypophysitis. *J Endocrinol Invest* 14:691–696
9. Paulus W, Honegger J, Keyvani K, Fahlbusch R (1999) Xantho-granuloma of the sellar region: a clinicopathological entity different from adamantinomatous craniopharyngioma. *Acta Neuropathol* 97:377–382
10. Sautner D, Saeger W, Ludecke DK, Jansen V, Puchner MJ (1995) Hypophysitis in surgical and autoptical specimens. *Acta Neuropathol* 90:637–644
11. Ueta Y, Levy A, Chowdrey HS, Lightman SL (1995) S-100 antigen-positive folliculostellate cells are not the source of IL-6 gene expression in human pituitary adenomas. *J Neuroendocrinol* 7:467–474