Eur Radiol (2006) 16: 285–298
DOI 10.1007/s00330-005-2882-y

UROGENITAL

Karen Kinkel
Kathrin A. Frei
Corinne Balleyguier
Charles Chapron

Diagnosis of endometriosis with imaging: a review

Received: 17 February 2005
Revised: 27 June 2005
Accepted: 28 July 2005
Published online: 10 September 2005

K. Kinkel (✉)
Institut de Radiologie,
Clinique et fondation des Grangettes,
7, chemin des Grangettes,
1224 Chêne-Bougeries/Geneva,
Switzerland
e-mail: Karen.Kinkel@grangettes.ch
Tel.: +41-22-3050779

K. A. Frei
Department of Obstetrics
and Gynaecology,
University Hospital Bern,
Inselspital, Effingerstrasse 102,
3010 Bern, Switzerland

C. Balleyguier
Radiology Department,
Institut Gustave Roussy,
39, rue Chemin Camille Desmoulins,
94805 Villejuif, France

C. Chapron
Service de Gynécologie Obstétrique II,
Unité de Chirurgie,
Clinique Universitaire Baudelocque,
CHU Cochin,
Groupe Hospitalier Ouest,
Assistance Publique—Hôpitaux
de Paris,
123, bd Port-Royal,
75014 Paris, France

Abstract Endometriosis corresponds to ectopic endometrial glands and stroma outside the uterine cavity. Clinical symptoms include dysmenorrhoea, dyspareunia, infertility, painful defecation or cyclic urinary symptoms. Pelvic ultrasound is the primary imaging modality to identify and differentiate locations to the ovary (endometriomas) and the bladder wall. Characteristic sonographic features of endometriomas are diffuse low-level internal echos, multilocularity and hyperchoic foci in the wall. Differential diagnoses include corpus luteum, teratoma, cystadenoma, fibroma, tubo-ovarian abscess and carcinoma. Repeated ultrasound is highly recommended for unilocular cysts with low-level internal echoes to differentiate functional corpus luteum from endometriomas. Posterior locations of endometriosis include utero-sacral ligaments, torus uterinus, vagina and recto-sigmoid. Sonographic and MRI features are discussed for each location. Although ultrasound is able to diagnose most locations, its limited sensitivity for posterior lesions does not allow management decision in all patients. MRI has shown high accuracies for both anterior and posterior endometriosis and enables complete lesion mapping before surgery. Posterior locations demonstrate abnormal T2-hypointense, nodules with occasional T1-hyperintense spots and are easier to identify when peristaltic inhibitors and intravenous contrast media are used. Anterior locations benefit from the possibility of MRI urography sequences within the same examination. Rare locations and possible transformation into malignancy are discussed.

Keywords Endometriosis · Ovary, cysts · Ultrasound, comparative studies · Magnetic Resonance, comparative studies · Pelvis, MR

Introduction

Endometriosis may be defined as a disease characterized by the presence of functional endometrial glands and stroma in ectopic locations outside the uterine cavity. The ectopic endometrial tissue responds to hormones and drugs in a similar manner to eutopic endometrium. Endometriosis remains a challenging condition for clinicians, research sci-

entists, and patients alike. The difficulties include problems of explanation, of etiology, pathophysiology, and progression; and there problems determining who, when, how, and for how long to treat individuals once its presence has been confirmed.

Continued growth of endometriotic tissue, as with that of the endometrium, is dependent upon estrogen. Thus, endometriosis is prevalent in the reproductive years with a peak incidence between 30 and 45 years of age. The estimated prevalence of endometriosis ranges between 10% and even more than 50%, depending on the underlying problems of the women studied [1, 2]. The precise etiology of endometriosis remains unknown.

Pain is probably the cardinal symptom of endometriosis. Various types of pain are associated with the disease; dysmenorrhoea, deep dyspareunia, and pelvic pain unrelated to intercourse or menstruation, such as pain during defecation or urinating. Infertility is another commonly associated complaint. The diagnosis of endometriosis still presents several problems resulting from similarities in clinical symptoms to other benign or malignant gynecological diseases. These gynecological symptoms may, however, be of diagnostic help in the suspicion of endometriosis, which should be a differential diagnosis in any patient presenting with worsening dysmenorrhoea, pelvic pain, dyspareunia, or other cycle-associated symptoms related particularly to the bowel or bladder with or without infertility. Imaging techniques currently used to diagnose endometriosis are sonography and magnetic resonance imaging (MRI). Sonographic examination of the pelvis is the initial method of choice to identify and characterize adnexal cystic structures. Transabdominal ultrasound is used to explore the entire pelvis and is followed by transvaginal ultrasound to obtain a more detailed description of anatomical structures close enough to the endovaginal probe, such as the ovaries, the uterus, the uterosacral ligaments, and the rectal wall. Hysterosalpingography remains the key examination for patients complaining about infertility and should be scheduled between days 8 and 12 of the menstrual cycle to prevent radiation of possible early pregnancy after ovulation. MRI is performed in selected patients according to the results of ultrasound and the severity of symptoms. Due to spontaneous T1 hyperintensity of blood after 8 days of bleeding, MRI should not be scheduled earlier than day 8 of the menstrual cycle. In our institution, MRI of the pelvis requires 6 h of prior fasting, an intramuscular injection of a peristaltic inhibitor, and is performed with a pelvic phase array coil in a 1.5 T magnet. The imaging protocol for patients with suspected endometriosis uses anterior and posterior saturation bands covering subcutaneous fat and include at least two T2-weighted sequences (repetition time 4,000 ms, echo time 90 ms, matrix 256×512, three signal-acquired 4- to 5-mm-section thickness) in different slice orientations (sagittal and coronal oblique or axial oblique according to the axis of the uterine cavity), followed by three T1-weighted sequences in an identical imaging plane that best demonstrates the pathology (TR 500 ms, TE 14 ms): native T1-weighted without fat suppression and fat-suppressed T1-weighted before and after intravenous injection of gadolinium contrast media.

During laparoscopy, endometriosis is classified according to the revised American Fertility Society classification (rAFS) [3] into minimal, mild, moderate, or severe endometriosis. The rAFS classification is based on a number of points given for the presence of ovarian or peritoneal endometriosis (subdivided into superficial or deep), the presence of adhesions, and posterior cul de sac obliteration. Lesions located elsewhere, such as at the tubes, the rectum, or the bladder do not account for the calculation of the state. Due to fair reproducibility [4] and absent correlation between the stage of disease, various pain symptoms [5], and the severity of disease [6], the clinical value of the actual classification is criticized by many gynecologists who claim further refinement [6, 7].

Endometriosis is particularly difficult to treat. Often, response to therapy relies on recognition of the disease in its earliest possible stages. Current treatment is essentially surgical, medical, or a combination of both approaches. A combined medical and surgical treatment might utilize medical therapy before, after, or both before and following surgical intervention. Factors to consider in management include the age and reproductive desires of the patient, the stage of the disease, and, most importantly, the symptoms. Therapeutic options include no treatment, medical therapy, surgery, or combination therapy. Oral contraceptives, androgenic agents, progestins, and gonadotropin releasing hormone (GnRH) analogs have all been used successfully although at the present time, the latter represents the most popular medical therapy for endometriosis. Surgical therapy is appropriate, especially for advanced stages of the disease. Laparoscopy is an effective surgical approach with the goal of excision of visible endometriosis in a hemostatic fashion [8]. Radical surgery is reserved for those patients with severe symptoms where there is no desired fertility potential and especially when other forms of treatment have failed. Total abdominal hysterectomy and bilateral salpingo-oophorectomy are performed along with resection of any endometriotic lesions as completely as possible. For extended surgery, an interdisciplinary approach is mandatory.

Anatomic location and distribution of endometriosis

The most common initial location of endometriosis is the ovary, also defined as an endometrioma. Peritoneal lesions can be superficial or deep (exceeding a depth of 5 mm) and cause formation of adhesions and invasion of adjacent organs. The invasion of the bladder wall, and particularly of the detrusor muscle, defines bladder endometriosis, which is also classified as anterior endometriosis [9]. Posterior endometriosis includes a variety of anatomic locations; the

Table 1 Specific locations of deep endometriosis, their frequency and corresponding associated symptoms[a]

Anatomical location	Frequency	Clinical symptoms
Torus uterinus and uterosacral ligament	69.2%	Deep dyspareunia
Vagina	14.5%	Painful defecation Gastrointestinal symptoms
Bowel	9.9%	Noncyclic pain Gastrointestinal symptoms
Bladder	6.4%	Lower urinary symptoms
Rectovaginal pouch adhesion	/	Severe dysmenorrhea

[a]Extracted from 241 patients with 344 pathologically proven lesions of deep endometriosis (44) and (9). Rectovaginal pouch adhesions are frequently associated with endometriosis but are not classified as deeply infiltrating lesions

most frequent one corresponds to endometriosis of the uterosacral ligaments and the upper portion of the posterior cervix described by anatomists as "torus uterinus" (Table 1) [10]. Torus uterinus is anatomically defined as a small, transverse thickening that binds the insertion of both uterosacral ligaments at the posterior uterus and is therefore treated together with lesion of the uterosacral ligaments [11]. Vaginal endometriosis belongs to posterior endometriosis and is located either in the upper portion of the posterior vaginal wall, the rectovaginal pouch, or the posterior vaginal fornix [12]. Ureteral endometriosis and bowel endometriosis (with invasion of the muscularis propria) are less frequent locations of posterior endometriosis (Table 1). Concerning the pathogenesis of these posterior deep lesions, MRI results suggest that deep endometriosis originates from an area located above the rectovaginal septum, below the torus uterinus, and at the level of the posterior vaginal fornix and upper third of the posterior vaginal wall [12]. Frequency and associated symptoms of these locations of deep endometriosis are listed in Table 1. Identification of specific locations of deep endometriosis is important, as management of rectal or urinary locations will lead to a multidisciplinary surgical approach.

Diagnosis of endometrioma

Ultrasound is the method of choice to identify endometriomas corresponding to a benign ovarian neoplasm persisting after 3 months. The typical sonographic presentation corresponds to diffuse low-level internal echoes with hyperechoic foci in the wall of a multilocular cyst [13]. Suren et al. analyzed lesion size and uni- versus multilocularity in 122 histologically verified endometriomas: Unilocularity was found in 43% of endometriomas [14]; 81% of the endometriomas ranged between 30 and 59 mm in largest diameter. Patel et al. studied sonographic criteria of 252 adnexal masses at ultrasound in 226 women. The positive predictive value of sonography to predict endometriosis was evaluated at 75% when criteria such as diffuse low-level internal echoes and absent neoplastic features were used [13] (Fig. 1). The use of color Doppler images helps to show absent flow within the sometimes heterogeneous cystic content. The presence of hyperechoic foci alone at the surface of the ovary is not a sign for endometriosis [15]. Differential diagnosis between teratomas and endometriosis appears important, as teratomas smaller than 6 cm tend to be treated with expectancy in premenopausal woman [16]. Teratomas typically present as echo-

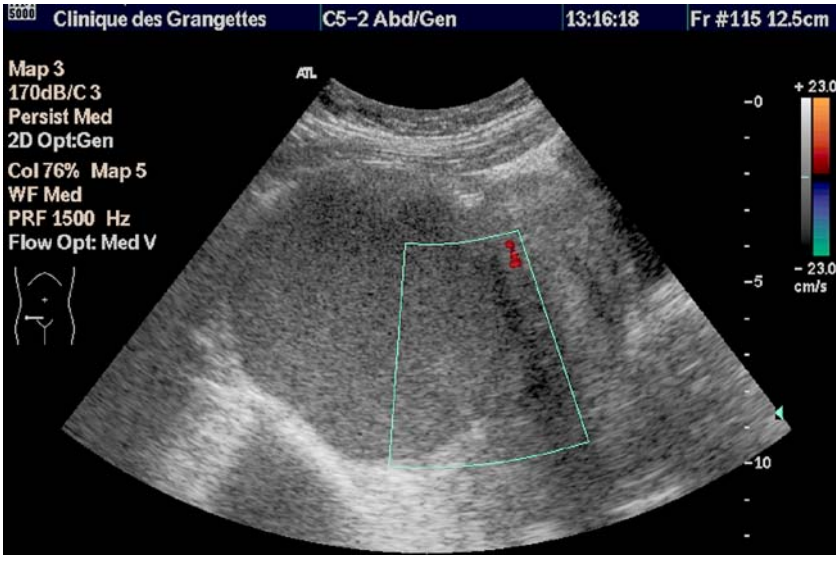

Fig. 1 Transvaginal axial color Doppler sonographic image of the right ovary in a 34-year-old woman with cyclic right pelvic pain. The hypoechoic ovarian mass demonstrates heterogeneous low-level internal echoes without color Doppler flow in the most echogenic portion of the cyst corresponding to blood clots within an endometrioma at surgery

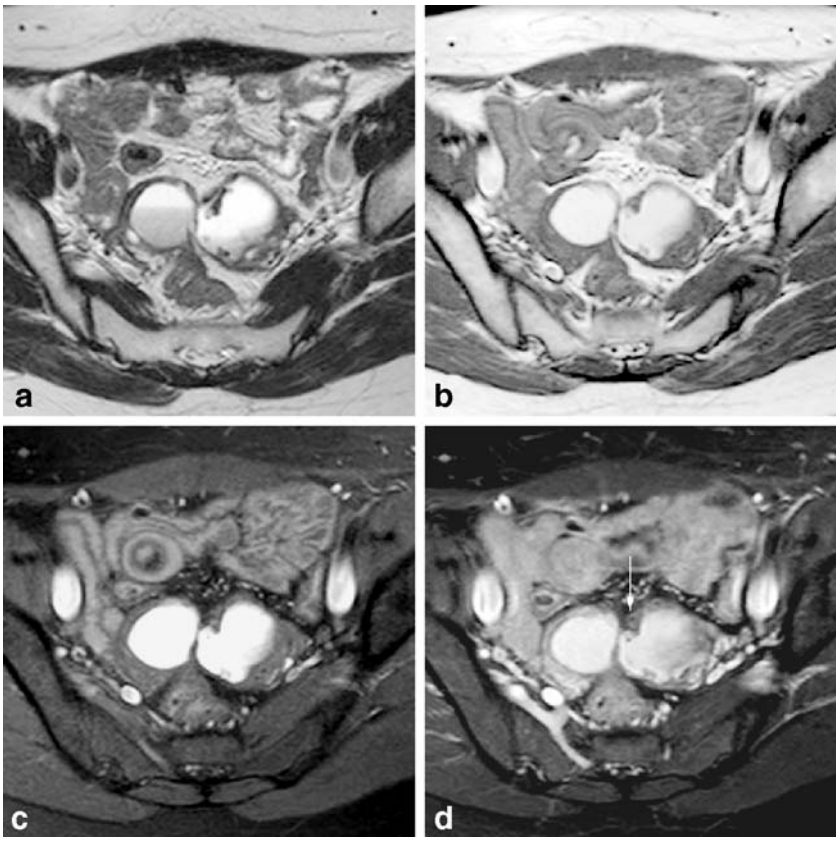

Fig. 2 Magnetic resonance image (MRI) of the pelvis in a 29-year-old woman with dysmenorrhea. **a** Axial T2-weighted image demonstrates bilateral ovarian cysts with an upper hyperintense content and an indistinct internal lesion margin suggestive of interovarian adhesions ("kissing ovaries"). **b**–**d** The same image level as in **a** at different T1-weighted sequences: native T1-weighted (**b**), fat suppressed T1-weighted (**c**), and after intravenous contrast enhancement and fat suppression (**d**). The T1 hyperintense content of both cysts persists after fat suppression while the irregular wall of the cyst does not demonstrate enhancement after intravenous contrast injection (*arrow*). Pathology confirmed the diagnosis of bilateral endometriomas

genic masses with acoustic shadowing due to hairballs or calcifications such as teeth or bone in the Rokitanski protuberance [17]. Layered lines and dots, fat-fluid level, and isolated bright echogenic foci with acoustic shadowing are characteristic sonographic findings of dermoid cysts [18]. Other differential diagnoses include functional cysts, such as corpus luteum or hemorrhagic follicular cysts [19], that will disappear or decrease in size at short-time follow-up [20]. Ovarian fibromas demonstrate small vessels within a hypoechoic attenuating mass at color Doppler examination [17, 21] whereas tubo-ovarian abscesses present with fever and leucorrhea. Ovarian cancer can be difficult to exclude if wall irregularities are present; absence of color Doppler flux within the cyst helps to confirm the benign nature of the lesion [22, 23]. Whenever sonographic features of ovarian masses are indeterminate, MRI is the imaging modality of choice to exclude malignancy [24]. At MRI, typical features of endometriomas include high signal intensity at both T1- and T2-weighted sequences persisting at subsequent fat-suppressed T1-weighted images [25] (Fig. 2). Fat suppression is mandatory, as it helps to differentiate endometriomas from cystic teratomas [26] and to visualize more and smaller endometriomas than without fat-suppression techniques [25]. Gradual variation of signal intensity at T2-weighted images has been described as "shading" and is due to chronic bleeding with accumulation of high concentrations of iron and protein in endometriomas [27, 28] (Fig. 3). This specific feature helps differential diagnosis with functional hemorrhagic cysts that do not demonstrate shading and that disappear at follow-up imaging. When MRI uses diagnostic criteria such as T1 hyperintense cysts with T2 shading or multiple T1 hyperintense cysts regardless of T2 signal intensity, the sensitivity and specificity of a definitive diagnosis of endometriomas have been reported as high as 90% and 98% respectively [27]. Bilateral endometriomas occur in more than 50% of cases [29]; when associated with interovarian adhesions, they are often described as "kissing" ovaries (Fig. 2a).

When atypical features of endometriomas are present, such as localized wall thickening, absent enhancement after intravenous injection of contrast medium at T1-weighted sequences allow confirmation of benign disease (Fig. 2d). The use of intravenous contrast media is mandatory because enhancement of a solid mass within a hemorrhagic ovarian cyst has been described in two patients with ovarian cancer arising within an endometrioma [30].

Endometriosis of uterosacral ligaments and torus uterinus

In a series of 110 patients with histologically proved deep endometriosis infiltrating the uterosacral ligaments, 77.3% (85 patients) complained about severe, deep dyspareunia

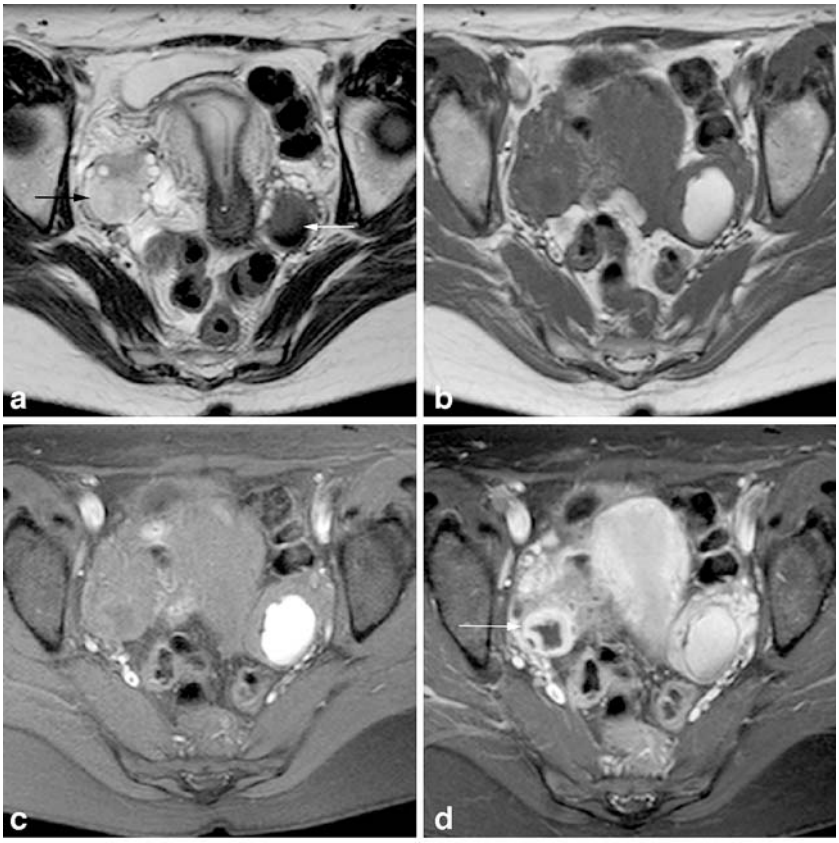

Fig. 3 Magnetic resonance image (MRI) of the pelvis in a 33-year-old woman with left pelvic pain. **a** The axial T2-weighted image show bilateral ovarian cysts. An ill-defined isointense cyst of the right ovary (*black arrow*) and a hypointense cyst of the left ovary (*white arrow*). **b** The left ovarian cyst is hyperintense at the native T1-weighted image, possibly corresponding to blood, confirmed by persistent hyperintensity at the fat-suppressed T1-weighted image in **c**. Absent hyperintensity of the right ovarian cyst at the native T1-weighted sequence is typical of a corpus luteum. After intravenous contrast injection, **d** demonstrates rim enhancement of the right ovarian cysts (*arrow*). No cyst was found at surgery of the right ovary 2 weeks later, and an endometrioma was removed of the left ovary

[31]. Clinical examination has been described as normal in 67% of patients with endometriosis of the uterosacral ligaments [32], making further imaging studies necessary for diagnosis and treatment. In a prospective study of 142 patients, sonography identified a hypoechoic nodule lateral to the upper third of the cervix in 64% (sensitivity) and excluded lesions of uterosacral ligaments adequately in 88% (specificity) [33]. Due to the relative low sensitivity of sonography and the difficulty at clinical and laparoscopic examination to identify subperitoneal lesions, MRI has been used to increase lesion identification. In an initial series of 12 lesions, T2-weighted images identified all lesions as iso- or hypointense to myometrium whereas native T1-weighted images identified only six lesions due to T1 isointensity to myometrium [34]. The proximal portion of the ligament typically presented with asymmetric nodular thickening ranging between 10 and 18 mm in largest diameter (Fig. 4). In a bigger series of 75 surgically verified endometriosis of uterosacral ligaments, the lesion size varied between 4 mm and 20 mm. Therefore, precise size criteria cannot be used alone to identify abnormal uterosacral ligaments. The sensitivity of the diagnostic criteria of "asymmetric nodular irregularity of uterosacral ligaments" has been reported between 76% (12/12) and 86% (44/51) [11, 34]. Uterine retroversion or juxtaposition of an endometrioma or bowel structures can mask a small nodule of deep endometriosis of uterosacral ligaments [11]. In this series of 89 lesions located at the uterosacral ligaments (60% bilateral and 40% unilateral) or the torus uterinus, lesions of the torus uterinus were isolated in 39% and associated to uni- or bilateral involvement of uterosacral ligaments in 61%. The sensitivity of MRI for the diagnosis of deep endometriosis of the torus uterinus was 83%. Lesions of the torus uterinus correspond to the anterior part of the retrouterine excavation and have been described previously as T2 isointense to myometrium [34]. When both uterosacral ligaments and the torus uterinus are involved with deep endometriosis, a typical arciform or stellate pattern of hypointense nodular structures that cover the posterior uterus can be identified [11]. Attraction of the anterior rectal wall can be due to adhesion between the nodule of the torus uterinus and the rectal serosa or direct extension with invasion of the muscle of the rectosigmoid junction [34]. The differentiation of those two entities will be discussed in the section concerning endometriosis of the bowel.

Endometriosis of the vagina

Typical symptoms correspond to painful defecation during menstruation and dyspareunia. Diagnosis is usually clinical and identified at physical examination in 80% of cases [32]. The sensitivity of ultrasound is reported to be as low

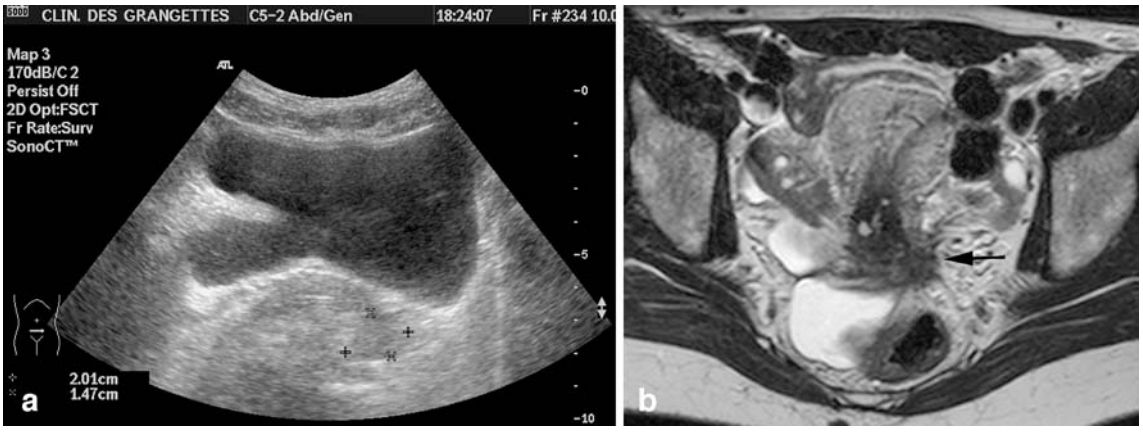

Fig. 4 A 34-year-old woman complaining about dyspareunia. **a** Axial transabdominal sonographic image of the pelvis demonstrates contour irregularity of the left cervical wall where a 2-cm hypoechoic nodule is suspected. **b** The T2-weighted axial image shows a hypointense nodule with stellate margins at the origin of the left uterosacral ligament (*arrow*). The normal right uterosacral ligament is surrounded by fluid. Pathology of the resected left uterosacral ligament confirmed predominantly fibrotic endometriosis

as 29% [33]. This difficulty is due to the configuration of transvaginal ultrasound probes with the receiver oriented toward the vaginal fornix. Orientation of the probe toward the posterior vaginal wall can be limited by the symphysis pubis and associated pain. Dessole et al. have described an increase in the sensitivity of transvaginal ultrasound when a saline solution is instilled in the vagina, a procedure called sonovaginography [35]. In this series of 46 patients scheduled for the resection of a clinically suspected lesion in the rectovaginal wall, sonovaginography identified 91% of the pathologically confirmed lesions compared with 44% with conventional transvaginal sonography alone with a specificity of 86% and 50%, respectively. The problem with vaginal lesions is not the diagnosis but the choice of

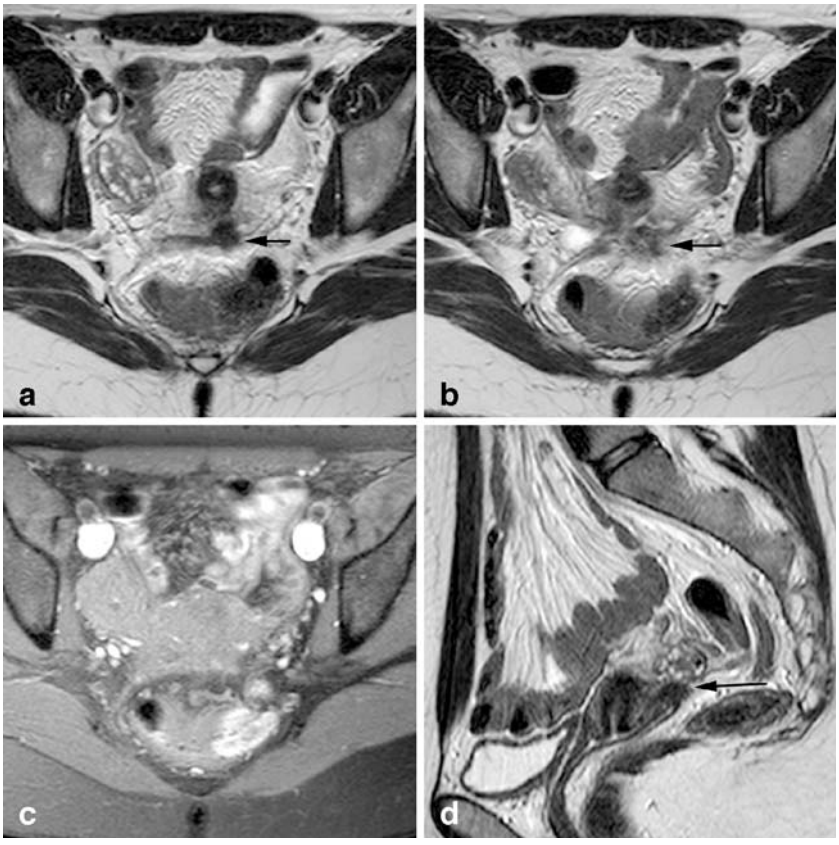

Fig. 5 A 36-year-old woman complaining about dyspareunia and cyclic painful defecation. **a**, **b** The two consecutive axial T2-weighted images demonstrate a small heterogeneous hypointense nodule at the upper posterior cervix extending up to the left uterosacral ligament (*arrow*). **c** The T1-weighted image with fat suppression at the same level as **b** shows no abnormal finding due to T1 isointensity of the nodule. **d** The sagittal T2-weighted image demonstrates elevation of the posterior vaginal fornix toward the retrocervical nodule (*arrow*) and no abnormal findings within the rectovaginal septum or the rectal wall. Surgery excised the nodule at the torus uterinus, extending up to the left uterosacral ligament and the posterior vaginal fornix that were part of a bloc of fibrous tissue with few endometrial glands typical for deep posterior endometriosis of uterosacral ligaments

the appropriate surgical option. For this purpose, other questions such as location, extension, and infiltration of the vaginal lesion are more important than the identification of the lesion. Results of MRI have been described by Bazot et al. in 15 patients with a sensitivity of 80% and a specificity of 93% [11]. To predict the extension of the lesion toward the rectum, the author recommended the use of water enema. The MR presentation of these lesions was similar to lesions located at the uterine torus with T2 hypointensity and variable signal intensity at T1-weighted images (Fig. 5). Most patients with vaginal involvement also demonstrated obliteration of the retrouterine excavation. Therefore, MRI represented the ideal complement to ultrasound and physical examination to predict lesion extension higher upward and posteriorly. Surgical excision of deep lesions depends upon the exact location of the endometriotic lesions. When deep endometriosis is strictly limited to the uterosacral ligaments, complete lesion removal can be performed by laparoscopy without exeresis of the vagina. When the lesion also infiltrates the upper part of the posterior vaginal wall, excision of the upper third of the vaginal wall is essential to prevent recurrence [4].

Endometriosis of the bowel

The most commonly affected areas in decreasing order of frequency are the rectosigmoid colon, the appendix, the cecum, and the distal ileum. The lesion invades the serosa, subserosa, and muscularis propria, reacting with hypertrophia and fibrosis. Due to the normal appearance of the mucosa in most patients with bowel endometriosis, diagnosis by colonoscopy is often false negative [36]. Various imaging techniques have been proposed to diagnose bowel location of endometriosis. At sonography, transabdominal, transrectal [37], and transvaginal [38] approaches have been described. A comparative study between rectal endoscopic (transrectal) sonography and transvaginal ultrasound in 30 patients with clinical suspicion of posterior endometriosis indicated equivalent results with a sensitivity of 84% and a specificity of 99% for transvaginal ultrasound [38]. Diagnostic criteria at sonography for bowel endometriosis include a hypoechoic, irregular-shaped area corresponding to a layer of hypertrophic muscularis propria surrounded by a hyperechoic rim including mucosa, submucosa, and serosa [39]. Nodular masses located within the outer rectal wall are relatively easy to identify at transvaginal sonography. Locations above the rectosigmoid junction might be beyond the field of view of a transvaginal approach and limited by the presence of air for the transabdominal approach. At MRI, a sensitivity of 84% and specificity of 99% has been reported in 60 patients with intestinal involvement [11]. Detailed assessment of local extent of colorectal lesions was reported easier when rectal water enema was used. Diagnostic criteria of rectal invasion at MRI included colorectal wall thickening with anterior triangular attraction of the rectum toward the torus uteri or asymmetric thickening of the lower surface of the sigmoid wall (Figs. 6, 7). No study indicated wall thickness threshold values to identify bowel thickening, as this sign alone can be due to peristaltic contraction and no anatomic lesion.Bazot et al. described the aspect of 60 bowel lesions as mainly fibromuscular with occasional foci of T1 and T2 hyperintensity and better distinction of the lesion from the normal rectal wall after intravenous injection of contrast media [11]. The three main locations of endometriosis of

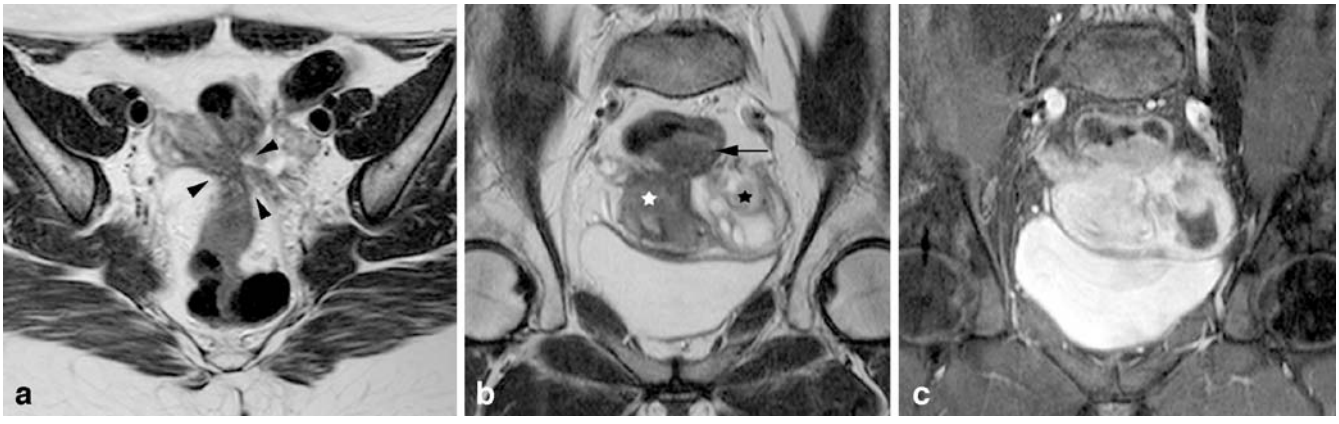

Fig. 6 A 39-year-old patient with noncyclic pelvic pain and a history of previous surgery for bilateral endometriomas. **a** Axial T2-weighted image through the level of the ovaries and the lower wall of the sigmoid. Hypointense strands converge from the right ovary and the left peritoneal fat toward a heterogeneous stricture of the sigmoid demonstrating a stellate nodule (*arrowheads*). **b** Coronal T2-weighted image through the stellate sigmoid nodule (*arrow*) confirms asymmetric thickening of the lower sigmoid wall converging in a triangular shape toward the uterus (*white star*) and the right ovary (*black star*). **c** Coronal T1-weighted, delayed, contrast-enhanced, fat-suppressed image through the same level as in **b** shows decreased enhancement of the sigmoid level compared with normal myometrium and ovarian parenchyma. The nodule is delineated at the upper part by greater linear contrast uptake of the normal mucosa. Pathology of partial sigmoid resection confirmed endometriosis of the sigmoid

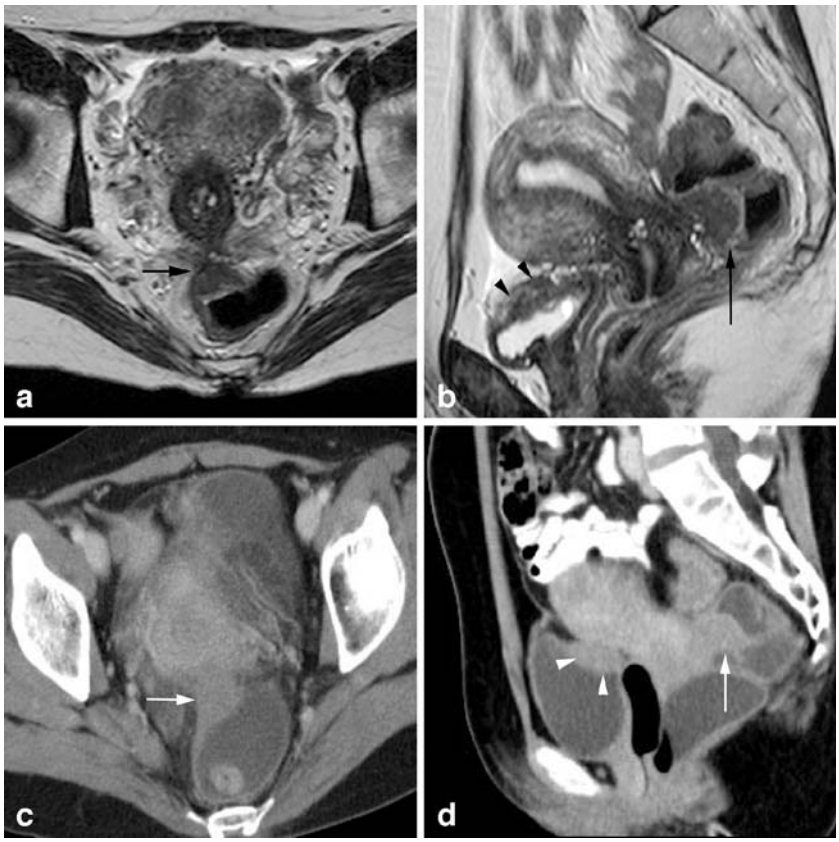

Fig. 7 A 36-year-old woman with cyclic painful defecation and chronic abdominal pain. Transvaginal sonography reported abnormal bladder wall thickening and a possible retrocervical subserosal fibroid. **a** Axial T2-weighted image of the pelvis shows asymmetric thickening of the anterior rectal wall (*arrow*) containing hyperintense spots and converging toward the torus uterinus. **b** Sagittal T2-weighted image confirms the nodule in the anterior rectal wall (*arrow*) and shows abnormal thickening of the upper bladder wall (*arrowheads*). **c** Axial contrast-enhanced helical multidetector computed tomography (CT) image of the pelvis at the portal phase was performed to exclude additional bowel lesions and confirmed rectal wall thickening (*arrow*). **d** Sagittal reconstruction of the multidetector helical CT at the portal phase shows both posterior bladder wall thickening (*arrowheads*) and anterior wall thickening (*arrow*). Rectal and bladder endometriosis was confirmed at partial cystectomy and rectal resection at pathology

the colon in decreasing frequency were the rectosigmoid junction, the anterior portion of the rectum at the level of the retrouterine excavation, and the lower portion of the sigmoid close to the left ovary. Evaluation of the distance of the lower border of the lesion up to the junction of the pelvic and perineal rectum was possible in all patients with rectal involvement. This information is important for surgical decision making. Other series have indicated similar sensitivities of MRI to detect bowel endometriosis ranging from 77 to 93% [40, 41]. The lower performance of one series may be due to absent use of peristaltic inhibitors and intravenous contrast media. Before the systematic use of pelvic phase array coils, transvaginal or transrectal coils have been tested to visualize endometriosis of the rectum [34]. Lesion visualization was not possible above 8 cm from the anus, and coil positioning was limited by associated pain. More recently, Puglielli et al. indicated in a case report that the use of an endorectal coil allowed the ability to distinguish more clearly the relationship of the endometriotic bowel lesion compared with the three layers of the rectal wall (mucosa, submucosa, and muscularis propria [42]. When MRI was compared with rectal endoscopic sonography, both similar [41] and lower sensitivity of MRI compared with rectal endoscopic sonography have been reported [40]. Rectal endoscopic sonography has the advantage of being closer to the region of interest than MRI and allows a more precise diagnosis of the depth of rectal wall extension [40]. The major inconvenience of a small field of view is a less-accurate visualization of uterosacral ligaments and limited lesion visualization in the ovary or the bladder. As unifocal isolated lesions of the intestine are reported to represent less than 21% in woman with intestinal lesions [9], the ideal imaging method should be able to cover at least the entire pelvis to diagnose all associated lesions. Therefore, MRI appears the method of choice to diagnose all sites of possible extension of endometriosis.

When lesion size of colorectal endometriosis was compared with a pain scale, patients demonstrated no correlation between the size of the lesion and the intensity of associated symptoms [41].

In the small-bowel, endometriosis is usually identified within the last 10 cm of the ileum. Radiographic findings at enteroclysis, small-bowel follow-through, or double-contrast barium enema are usually nonspecific and demonstrate an extrinsic mass effect, tethering of folds or presenting as annular lesions with spiculated folds or plaque-like lesions [43]. Locations at the rectosigmoid have been more often described at sonography than at barium enema due to the extrinsic location of the lesion starting at the peritoneum with progressive invasion of the rectal wall. Endometriosis of the bowel can also be identified at computed tomography (CT) where nonspecific wall thickening is present (Fig. 7c). The term "frozen pelvis" is used by clinicians to indicate masking of the retrouterine excavation by a block of tissue with lesions of the posterior pelvis, such as torus uteri, uterosacral ligaments, vaginal, and rectal-wall invasion associated with extensive adnexal adhesions [6, 44]. Severe dysmenorrhea and noncyclic chronic pelvic pain are suggestive of a frozen pelvis.

Bladder endometriosis

Bladder endometriosis occurs in about 6% of patients with endometriosis [44]. The lesion of the bladder detrusor is located anterior to the vesicouterine pouch and sometimes in contact with an adenomyotic nodule of the anterior wall of the uterus [45]. Lower urinary symptoms occur in a cyclic manner in 40% of patients and in a noncyclic manner in 60% [44]. In a small series of six patients' transvaginal

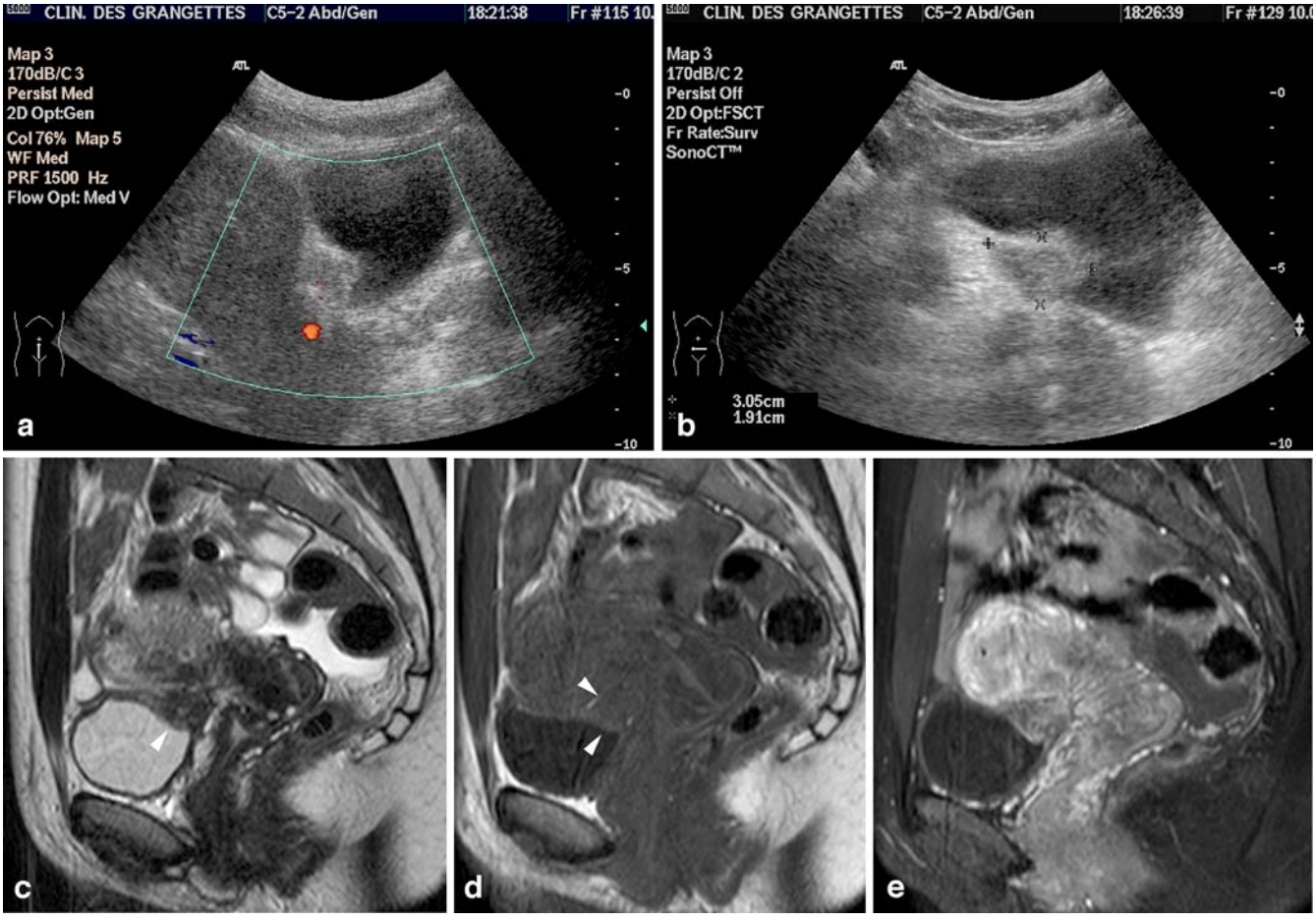

Fig. 8 A 34-year-old woman complaining about painful urinating during menstruation. Sagittal (**a**) and axial (**b**) sonographic images demonstrate a hyperechoic nodule between the bladder and the uterus. The color Doppler image (**a**) shows absent continuity between external uterine vessels and the small vessels of the nodule. Protrusion within the bladder lumen and isoechogenicity with the bladder wall is in favor of an abnormality of the bladder wall. The sagittal T2-weighted image at magnetic resonance imaging (MRI) of the pelvis (**c**) confirms hypointense thickening of the posterior upper-bladder wall (*white arrowhead*). **d** Native sagittal T1-weighted image fails to demonstrate easily the thickened abnormal bladder wall (*white arrowheads*) containing a tiny hyperintense spot. **e** Contrast enhancement after intravenous injection of gadolinium shows moderate uptake of bladder endometriosis compared with normal myometrium. Rim enhancement within the nodule corresponded to cystic glandular dilatation of endometrial glands at pathology

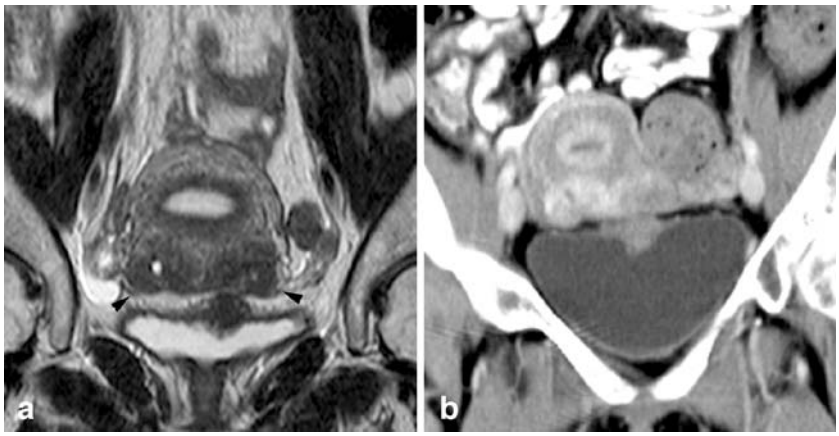

Fig. 9 A 43-year-old woman with dysmenorrhea and irregular urinary symptoms. **a** Coronal T2-weighted image shows nonspecific nodular thickening of the bladder associated with ill-defined hypointense nodules of the lower anterior myometrium (*arrowheads*). The presence of hyperintense spots is in favor of external adenomyomas. **b** Coronal reconstruction of contrast-enhanced helical computed tomography (CT) at the portal phase also demonstrates irregular wall thickening of the bladder wall associated with abnormal myometrial nodules. Pathology of subsequent hysterectomy with partial cystectomy confirmed bladder endometriosis associated with focal external adenomyosis

ultrasound was found more accurate than transabdominal ultrasound to diagnose bladder endometriosis, evaluate lesion size, and extension toward the uterus or the vesicovaginal septum [46]. Localized bladder wall thickening represents the main diagnostic criteria, with occasional protrusion inside the bladder lumen mimicking bladder cancer (Fig. 8). Subserosal anterior leiomyoma of the uterus with extrinsic compression of the bladder is another differential diagnosis. At MRI, the lesion has been described as heterogeneous T2- isointense bladder wall thickening with irregular margins and occasional T1 hyperintense spots [34] (Figs. 8, 9, 10). In this series of seven patients with bladder endometriosis, lesion size varied between 10 mm and 40 mm (mean 26 mm). Contrast enhancement appeared more intense within the lesion of bladder endometriosis than the noninvaded portion of the detrusor [34]. Comparative studies between ultrasound and MRI in six and 12 patients, respectively, have shown both similar [46] and less-accurate results of ultrasound [47]. In a more recent study using MRI in 195 patients with clinical suspicion of endometriosis, Bazot et al. reported a sensitivity of 88% (14/16), a specificity of 99% (177/179), and an accuracy of 98% (191/195) for the diagnosis of bladder endometriosis [11]. In this large study, false-negative and false-positive diagnoses in two patients, respectively, were due to difficulties in adequately appreciating the depth of

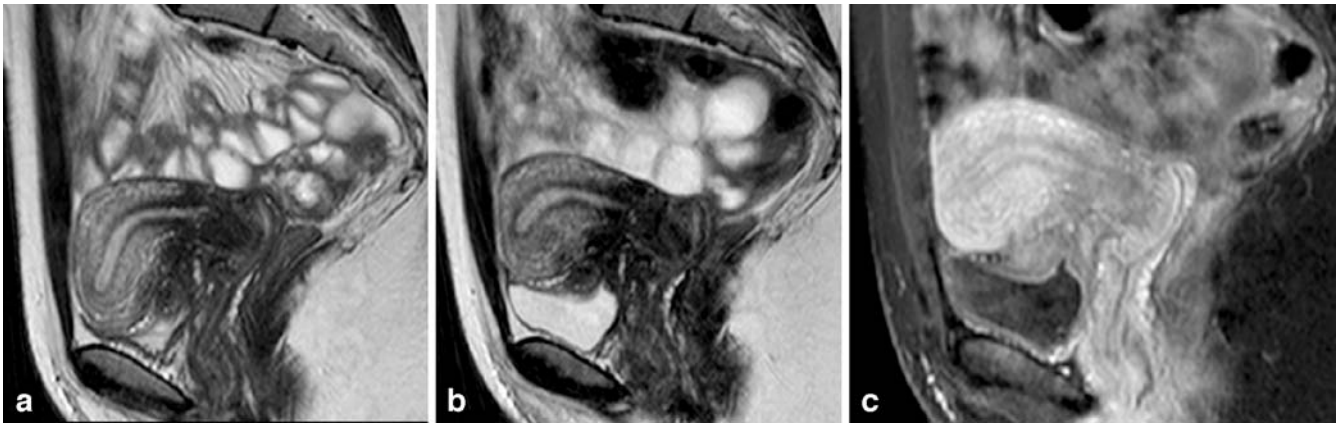

Fig. 10 A 29-year-old woman with a history of partial cystectomy for bladder endometriosis 2 years earlier and recurrence of urinary symptoms during menstruation for 2 months. **a** Sagittal T2-weighted image of the pelvis barely shows an ill-defined posterior bladder wall due to insufficient bladder wall distention and bladder voiding prior to the magnetic resonance (MR) examination. **b** Sagittal T2-weighted image 20 min later after intravenous perfusion of a saline solution. The distended bladder wall now demonstrates recurrence of posterior bladder wall thickening with triangular attraction of the bladder wall toward the uterus. **c** Contrast-enhanced sagittal T1-weighted image helps delineate the bladder wall nodule with decreased contrast enhancement compared with normal myometrium. Subsequent partial cystectomy confirmed bladder recurrence and adhesions toward the isthmus uteri

extension of the vesicouterine pouch up to the detrusor muscle [11]. Diagnosis of the extension toward the detrusor muscle was possible in all 12 patients with bladder endometriosis when an endovaginal coil was applied [47].

An important surgical question concerns possible involvement of the distal ureter requiring ureteral reimplantation during surgery. Direct invasion of the muscularis and lamina propria of the ureter results in luminal narrowing and may cause dilatation and obstruction. It may be the result of periuteral infiltration by local extension of other sites of deep endometriosis, such as uterosacral ligaments. Ureteral obstruction is, however, more often due to external compression by large endometriomas than by direct ureteral invasion. Findings at intravenous pyelography (IVP) or MR urography are nonspecific and usually correspond to hydronephrosis with a stricture of the distal ureter. The clinical and imaging context of other sites of pelvic endometriosis help to suggest ureteral involvement. Direct ureteral endometriosis is, rather, detected at T2-weighted sequences; the most frequent presentation of ureteral endometriosis is a hypointense nodule associated with hyperintense foci close to the ureter at both T2- and T1-weighted sequences [48]. Retractile adhesions are visible as periureteral hypointense lines with angular deviation. Infiltration of the ureter can be suspected when the interface of fat between the nodule and the ureter is no longer visible at T2-weighted sequences. Ureterohydronephrosis is easy to detect with MR urography obtained with either 2D T2-weighted sequences or delayed contrast-enhanced 3D sequences with higher spatial resolution. The sequence should cover both kidneys, ureters, and the bladder. The T2-weighted single-shot turbo spin-echo sequence (TR/TE=667/165 msec, turbo spin factor 74, 20 sections of 4 mm, 256×256 matrix, 13 s) requires subsequent postprocessing using a maximum-intensity projection (MIP) algorithm allowed for removal of superimposed structures with static fluid. The contrast-enhanced MR urography is a 3D gradient echo HI-RES sequence performed during 21 s of apnea (TR/TE=4.9/1.38 ms, flip angle 40°, 50 sections of 1.5 mm, 400×400 matrix) and followed by postprocessing using MIP to superimpose the entire urinary system in one image. Due to the visualization of all components of the urinary system and the possibility of exploring all pelvic locations of endometriosis within the same examination, MRI represents the ideal "all-in-one" examination in patients with suspected bladder endometriosis.

Adhesions

Adhesions are often not visualized at any imaging modality except if fluid is present at both sides. In this circumstance, they correspond to an abnormal "line" or "sheet" within the pelvis. However, during a transvaginal ultrasound, the sonographer can use the transvaginal probe to check organ mobility [28]. In the event of concomitant mobilization of the ovary when gently displacing the uterus during ultrasound, adhesions should be suspected and noted in the sonographic report. Pelvic adhesions were identified in 81% of women with surgically confirmed adhesions at three-dimensional ultrasound [49]. Performance could be increased to 90% when elevated Ca125 levels were combined with abnormal sonographic findings. At MRI, indirect signs of adhesions include anterior rectal triangular attraction, angulation of bowel loops, too large changes in bowel diameter with peritoneal nodules, elevation of the posterior vaginal fornix, posterior displacement of the uterus or the ovaries, loculated fluid collections, and hydrosalpinx [28]. Another sign of possible adhesions corresponds to spiculated low-signal-intensity strands converging toward deep peritoneal lesions of endometriosis [50]. Kinematic images demonstrating organ mobility at MRI can be obtained by a cine-mode display of many images obtained by ultrafast imaging techniques such as fast imaging with steady-state precession (FISP), half Fourier acquisition single-shot turbo spin echo (HASTE), single-shot fast spin echo (SSFSE), and others [50]. MRI using single-shot fast spin-echo images displayed in a cine mode in 52 women with gynecological disorders was able to predict adhesions with a sensitivity of 73% and a specificity of 87% [51]. These results were significantly better than initial reports published in 1989 with a sensitivity of 48% (14/29) [52]. In a randomized trial of 48 women with chronic pelvic pain and laparoscopically proven stages II–IV adhesions, 24 women were randomly allocated to undergo surgical adhesiolysis and 24 to a control group who did not have surgery. After 9–12 months, there were no significant differences between the two groups overall with regard to pelvic pain, except for a subgroup of women with severe, vascularized, and dense adhesions involving the bowel (stage IV), had significantly less pelvic pain after adhesiolysis [53]. Therefore, imaging studies dedicated to visualization of severe adhesions involving the bowel are likely to demonstrate higher sensitivities, as light- or moderate-degree adhesions are more difficult to visualize preoperatively and will have less impact on patient management.

Rare localization of endometriosis

Ectopic endometrial glands and stroma can develop at the site of prior gynecological surgery, such as scars from prior cesarian section or laparoscopy or spontaneously within the abdominal wall at the recti abdomini [54–56]. Clinical symptoms include cyclic pain and swelling of a subcutaneous nodule or permanent lower abdominal pain. At ultrasound, a subcutaneous nodule demonstrates irregular borders, a heterogeneous texture with internal scattered hyperechoic echoes surrounded by a hyperechoic ring of variable width, and vascularity at color Doppler imaging

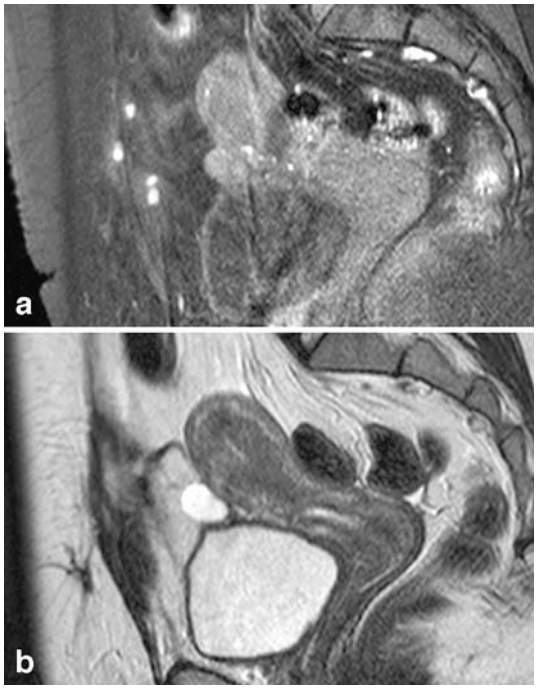

Fig. 11 A 40-year-old patient with cyclic pelvic pain and a history of a complicated cesarian section 2 years earlier. **a** Sagittal fat-suppressed T1-weighted image shows four hyperintense nodules within the rectus abdominus muscle above the cutaneous level of caesarian section. Detailed measurement from the level of the scar at the skin helped the surgeon find several nodules of subcutaneous and intraperitoneal endometriosis in addition to adhesions and an implant of endometriosis in the vesicouterine pouch. **b** Sagittal T2-weighted image of the pelvis at the same level as in **a** shows a hyperintense cyst in the vesicouterine pouch; however, the endometriotic nodules in the abdominal wall are not visible at the T2-weighted compared with the T1-weighted fat-suppressed image

[54]. At MRI, abdominal wall localizations are easily identified at T1-weighted fat-suppressed images as hyperintense spots within the abdominal wall (Fig. 11). The nodule can be hidden at T2-weighted images due to isointensity to muscle. Spiculated borders and associated adhesions facilitate lesion identification. In patients with suspected endometriosis of the abdominal wall, the anterior saturation bands need to be displaced to avoid hiding the lesions, which are often partially covered by the bands placed over the anterior subcutaneous fat. Other sub- or retroperitoneal lesion locations, such as subcutaneaous fat in the fossa ischio-rectalis, at the sciatic nerve, the round ligament, or within lymph nodes have been described [57–59]. Other rare locations include endometriosis in the Nuck canal [60] or the vulva [61, 62]. Cystic locations at the liver surface or within the chest are very rare conditions [63, 64]. Radiographic findings include pneumothorax, hemothorax, and lung nodules occurring during menstruation in a patient with known pelvic endometriosis diagnosed 5 years previously [64].

Malignant transformation

Malignant transformation of endometriosis is an uncommon phenomenon and is estimated at an approximate risk of about 2.5% [65]. Cancer can occur in gonadal and extragonadal sites and results in a wide histological range of tumors, with clear cell and endometrioid ovarian cancer at top frequencies. In a series of three patients with ovarian cancer arising in an ovarian endometrioma, p53 protein abnormalities and chromosomal aberrations were involved in the malignant transformation of endometriosis in the ovary [66]. Diagnosis of malignancy was made at MRI in another series of three patients with mucinous borderline carcinoma arising in endometriomas [67]. MRI features were typical of malignancy and mucinous tumors. In two patients with ovarian cancer arising in an endometrioma, the cancer was evident as an enhancing mass within a blood-filled adnexal cyst [30]. Endometrial stromal sarcoma arising from sciatic nerve endometriosis has been described in a 50-year-old woman with a long history of endometriosis and recent motor deficit of the sciatic nerve [68]. MRI diagnosed a large tumor of the sciatic nerve with pelvic extension.

Conclusion

Endometriosis of the pelvis demonstrates a large distribution of lesion locations and imaging features. The goal of surgical treatment of deep endometriotic lesions is to achieve complete resection of all symptomatic deep lesions during a one-step surgical procedure [4]. The efficiency of surgical management depends on how radical the exeresis is [69]. Although MRI is able to diagnose all sites of endometriosis [11], ultrasound remains the initial imaging modality due to immediate availability and easy access. The diagnosis of endometriomas and bladder endometriosis are reliable at ultrasound. However, in patients with chronic dysmenorrhea, dyspareunia, clinical suspicion of deep endometriosis, or inconclusive sonographic findings, MRI will identify endometriosis in all localizations with a high degree of accuracy, particularly at the torus uterinus, uterosacral ligaments, upper vagina, or bowel. Therefore, MRI represents the optimal imaging modality to diagnose and define the exact extent of endometriosis. Surgical management of deep endometriosis is a complex and high-risk procedure. A satisfactory preoperative work-up is necessary to identify exactly the locations of all the deep lesions. Because of the difficulties of these surgical procedures, it is strongly recommended to refer patients with suspected or diagnosed deep endometriosis to specific centers with a multidisciplinary approach.

Acknowledgements PD Dr. med Karen Kinkel received a salary support for research and education from the Clinique des Grangettes, Chêne-Bougeries, Switzerland.

References

1. Vigano P, Parazzini F, Somigliana E, Vercellini P (2004) Endometriosis: epidemiology and aetiological factors. Best Pract Res Clin Obstet Gynaecol 18:177–200
2. Schindler AE (2004) Pathophysiology, diagnosis and treatment of endometriosis. Minerva Ginecol 56:419–435
3. (1985) Revised American Fertility Society classification of endometriosis: 1985. Fertil Steril 43:351–352
4. Rock JA (1995) The revised American Fertility Society classification of endometriosis: reproducibility of scoring. ZOLADEX Endometriosis Study Group. Fertil Steril 63: 1108–1110
5. Vercellini P, Trespidi L, De Giorgi O, Cortesi I, Parazzini F, Crosignani PG (1996) Endometriosis and pelvic pain: relation to disease stage and localization. Fertil Steril 65:299–304
6. Chapron C, Fauconnier A, Dubuisson JB, Barakat H, Vieira M, Breart G (2003) Deep infiltrating endometriosis: relation between severity of dysmenorrhoea and extent of disease. Hum Reprod 18:760–766
7. Damario MA, Rock JA (1997) Classification of endometriosis. Semin Reprod Endocrinol 15:235–244
8. Valle RF, Sciarra JJ (2003) Endometriosis: treatment strategies. Ann N Y Acad Sci 997:229–239
9. Chapron C, Fauconnier A, Vieira M et al (2003) Anatomical distribution of deeply infiltrating endometriosis: surgical implications and proposition for a classification. Hum Reprod 18:157–161
10. Testut L (1931) Traité d'anatomie topographique avec applications médico-chirurgicales. In: Latarjet A (ed) Traité d'anatomie humaine. Doin, Paris, France
11. Bazot M, Darai E, Hourani R et al (2004) Deep pelvic endometriosis: MR imaging for diagnosis and prediction of extension of disease. Radiology 232:379–389; Epub 2004 Jun 2017
12. Chapron C, Liaras E, Fayet P et al (2002) Magnetic resonance imaging and endometriosis: deeply infiltrating endometriosis does not originate from the rectovaginal septum. Gynecol Obstet Invest 53:204–208
13. Patel MD, Feldstein VA, Chen DC, Lipson SD, Filly RA (1999) Endometriomas: diagnostic performance of US. Radiology 210:739–745
14. Suren A, Osmers R, Dietrich M, Kulenkampff D, Kuhn W (1998) Sonomorphology of endometriotic cysts. Int J Gynaecol Obstet 62:155–165
15. Brown DL, Frates MC, Muto MG, Welch WR (2004) Small echogenic foci in the ovaries: correlation with histologic findings. J Ultrasound Med 23:307–313
16. Caspi B, Appelman Z, Rabinerson D, Zalel Y, Tulandi T, Shoham Z (1997) The growth pattern of ovarian dermoid cysts: a prospective study in premenopausal and postmenopausal women. Fertil Steril 68:501–505
17. Atri M, Nazarnia S, Bret PM, Aldis AE, Kintzen G, Reinhold C (1994) Endovaginal sonographic appearance of benign ovarian masses. Radiographics 14:747–760; discussion 761–742
18. Ekici E, Soysal M, Kara S, Dogan M, Gokmen O (1996) The efficiency of ultrasonography in the diagnosis of dermoid cysts. Zentralbl Gynakol 118:136–141
19. Guerriero S, Ajossa S, Lai MP et al (2003) The diagnosis of functional ovarian cysts using transvaginal ultrasound combined with clinical parameters, CA125 determinations, and color Doppler. Eur J Obstet Gynecol Reprod Biol 110:83–88
20. Christensen JT, Boldsen JL, Westergaard JG (2002) Functional ovarian cysts in premenopausal and gynecologically healthy women. Contraception 66:153–157
21. Bazot M, Ghossain MA, Buy JN et al (1993) Fibrothecomas of the ovary: CT and US findings. J Comput Assist Tomogr 17:754–759
22. Buy JN, Ghossain MA, Hugol D et al (1996) Characterization of adnexal masses: combination of color Doppler and conventional sonography compared with spectral Doppler analysis alone and conventional sonography alone. Am J Roentgenol 166:385–393
23. Kinkel K, Hricak H, Lu Y, Tsuda K, Filly RA (2000) US characterization of ovarian masses: a meta-analysis. Radiology 217:803–811
24. Kinkel K, Lu Y, Mehdizade A, Pelte MF, Hricak H (2005) Indeterminate ovarian mass at US: incremental value of a second imaging test for characterization: meta-analysis and Bayesian analysis. Radiology 236:85–94
25. Sugimura K, Okizuka H, Imaoka I et al (1993) Pelvic endometriosis: detection and diagnosis with chemical shift MR imaging. Radiology 188:435–438
26. Yamashita Y, Torashima M, Hatanaka Y et al (1994) Value of phase-shift gradient-echo MR imaging in the differentiation of pelvic lesions with high signal intensity at T1-weighted imaging. Radiology 191:759–764
27. Togashi K, Nishimura K, Kimura I et al (1991) Endometrial cysts: diagnosis with MR imaging. Radiology 180: 73–78
28. Woodward PJ, Sohaey R, Mezzetti TP Jr (2001) Endometriosis: radiologic-pathologic correlation. Radiographics 21:193–216; questionnaire 288–194
29. Scully R, Young R, Clement P (1998) Tumor-like lesions Tumors of the ovary, maldeveloped gonads, fallopian tube, and broad ligament. Armed Forces Institute of Pathology, Washington, DC, pp 430–434
30. Wu TT, Coakley FV, Qayyum A, Yeh BM, Joe BN, Chen LM (2004) Magnetic resonance imaging of ovarian cancer arising in endometriomas. J Comput Assist Tomogr 28:836–838
31. Chapron C, Dubuisson JB, Fritel X et al (1999) Operative management of deep endometriosis infiltrating the uterosacral ligaments. J Am Assoc Gynecol Laparosc 6:31–37
32. Chapron C, Dubuisson JB, Pansini V et al (2002) Routine clinical examination is not sufficient for diagnosing and locating deeply infiltrating endometriosis. J Am Assoc Gynecol Laparosc 9:115–119
33. Bazot M, Thomassin I, Hourani R, Cortez A, Darai E (2004) Diagnostic accuracy of transvaginal sonography for deep pelvic endometriosis. Ultrasound Obstet Gynecol 24:180–185
34. Kinkel K, Chapron C, Balleyguier C, Fritel X, Dubuisson JB, Moreau JF (1999) Magnetic resonance imaging characteristics of deep endometriosis. Hum Reprod 14:1080–1086
35. Dessole S, Farina M, Rubattu G, Cosmi E, Ambrosini G, Nardelli GB (2003) Sonovaginography is a new technique for assessing rectovaginal endometriosis. Fertil Steril 79:1023–1027
36. Zwas FR, Lyon DT (1991) Endometriosis. An important condition in clinical gastroenterology. Dig Dis Sci 36:353–364
37. Ohba T, Mizutani H, Maeda T, Matsuura K, Okamura H (1996) Evaluation of endometriosis in uterosacral ligaments by transrectal ultrasonography. Hum Reprod 11:2014–2017

38. Bazot M, Detchev R, Cortez A, Amouyal P, Uzan S, Darai E (2003) Transvaginal sonography and rectal endoscopic sonography for the assessment of pelvic endometriosis: a preliminary comparison. Hum Reprod 18:1686–1692
39. Koga K, Osuga Y, Yano T et al (2003) Characteristic images of deeply infiltrating rectosigmoid endometriosis on transvaginal and transrectal ultrasonography. Hum Reprod 18:1328–1333
40. Chapron C, Vieira M, Chopin N et al (2004) Accuracy of rectal endoscopic ultrasonography and magnetic resonance imaging in the diagnosis of rectal involvement for patients presenting with deeply infiltrating endometriosis. Ultrasound Obstet Gynecol 24:175–179
41. Thomassin I, Bazot M, Detchev R, Barranger E, Cortez A, Darai E (2004) Symptoms before and after surgical removal of colorectal endometriosis that are assessed by magnetic resonance imaging and rectal endoscopic sonography. Am J Obstet Gynecol 190:1264–1271
42. Puglielli E, Di Cesare E, Masciocchi C (2004) Rectal endometriosis: MRI study with rectal coil. Eur Radiol 14:2362–2363; Epub 2004 Jul 2329
43. Scarmato VJ, Levine MS, Herlinger H, Wickstrom M, Furth EE, Tureck RW (2000) Ileal endometriosis: radiographic findings in five cases. Radiology 214:509–512
44. Fauconnier A, Chapron C, Dubuisson JB, Vieira M, Dousset B, Breart G (2002) Relation between pain symptoms and the anatomic location of deep infiltrating endometriosis. Fertil Steril 78:719–726
45. Fedele L, Piazzola E, Raffaelli R, Bianchi S (1998) Bladder endometriosis: deep infiltrating endometriosis or adenomyosis? Fertil Steril 69:972–975
46. Fedele L, Bianchi S, Raffaelli R, Portuese A (1997) Pre-operative assessment of bladder endometriosis. Hum Reprod 12:2519–2522
47. Balleyguier C, Chapron C, Dubuisson JB et al (2002) Comparison of magnetic resonance imaging and transvaginal ultrasonography in diagnosing bladder endometriosis. J Am Assoc Gynecol Laparosc 9:15–23
48. Balleyguier C, Roupret M, NGuyen T, Kinkel K, Helenon O, Chapron C (2004) Ureteral endometriosis: the role of magnetic resonance imaging. J Am Assoc Gynecol Laparosc 4:530–536
49. Seow KM, Lin YH, Hsieh BC et al (2003) Transvaginal three-dimensional ultrasonography combined with serum CA 125 level for the diagnosis of pelvic adhesions before laparoscopic surgery. J Am Assoc Gynecol Laparosc 10: 320–326
50. Togashi K (2002) MR imaging in obstetrics and gynecology. Nippon Igaku Hoshasen Gakkai Zasshi 62:7–16
51. Katayama M, Masui T, Kobayashi S et al (2001) Evaluation of pelvic adhesions using multiphase and multislice MR imaging with kinematic display. Am J Roentgenol 177:107–110
52. Arrive L, Hricak H, Martin MC (1989) Pelvic endometriosis: MR imaging. Radiology 171:687–692
53. Peters AA, Trimbos-Kemper GC, Admiraal C, Trimbos JB, Hermans J (1992) A randomized clinical trial on the benefit of adhesiolysis in patients with intraperitoneal adhesions and chronic pelvic pain. Br J Obstet Gynaecol 99:59–62
54. Francica G, Giardiello C, Angelone G, Cristiano S, Finelli R, Tramontano G (2003) Abdominal wall endometriomas near cesarean delivery scars: sonographic and color Doppler findings in a series of 12 patients. J Ultrasound Med 22:1041–1047
55. Balleyguier C, Chapron C, Chopin N, Helenon O, Menu Y (2003) Abdominal wall and surgical scar endometriosis: results of magnetic resonance imaging. Gynecol Obstet Invest 55:220–224
56. Ideyi SC, Schein M, Niazi M, Gerst PH (2003) Spontaneous endometriosis of the abdominal wall. Dig Surg 20: 246–248
57. Vercellini P, Chapron C, Fedele L, Frontino G, Zaina B, Crosignani PG (2003) Evidence for asymmetric distribution of sciatic nerve endometriosis. Obstet Gynecol 102:383–387
58. Lorente Poyatos R, Palacios Perez A, Bravo Bravo F et al (2003) Rectosigmoid endometriosis with lymph node involvement. Gastroenterol Hepatol 26:23–25
59. Kapan M, Kapan S, Durgun AV, Goksoy E (2005) Inguinal endometriosis. Arch Gynecol Obstet 271:76–78; Epub 2004 May 2020
60. Turpin F, Daclin PY, Karam R et al (2001) A case of muscular and canal of Nuck involvement by endometriosis. J Radiol 82:933–935
61. Katz Z, Goldchmit R, Blickstein I (1996) Post-traumatic vulvar endometriosis. Eur J Pediatr Surg 6:241–242
62. Irvin W, Pelkey T, Rice L, Andersen W (1998) Endometrial stromal sarcoma of the vulva arising in extraovarian endometriosis: a case report and literature review. Gynecol Oncol 71:313–316
63. Huang WT, Chen WJ, Chen CL, Cheng YF, Wang JH, Eng HL (2002) Endometrial cyst of the liver: a case report and review of the literature. J Clin Pathol 55:715–717
64. Joseph J, Sahn SA (1996) Thoracic endometriosis syndrome: new observations from an analysis of 110 cases. Am J Med 100:164–170
65. Van Gorp T, Amant F, Neven P, Vergote I, Moerman P (2004) Endometriosis and the development of malignant tumours of the pelvis. A review of literature. Best Pract Res Clin Obstet Gynaecol 18:349–371
66. Mhawech P, Kinkel K, Vlastos G, Pelte MF (2002) Ovarian carcinomas in endometriosis: an immunohistochemical and comparative genomic hybridization study. Int J Gynecol Pathol 21:401–406
67. Kataoka M, Togashi K, Koyama T et al (2002) MR imaging of mullerian mucinous borderline tumors arising from endometriotic cysts. J Comput Assist Tomogr 26:532–537
68. Lacroix-Triki M, Beyris L, Martel P, Marques B (2004) Low-grade endometrial stromal sarcoma arising from sciatic nerve endometriosis. Obstet Gynecol 104:1147–1149
69. Garry R (1997) Laparoscopic excision of endometriosis: the treatment of choice? Br J Obstet Gynaecol 104: 513–515