Original Paper

Urologia Internationalis

Urol Int 2007;79:152–156
DOI: 10.1159/000106330

Received: July 27, 2006
Accepted: October 25, 2006

# Is Antegrade Endopyelotomy Really Less Invasive than Open Pyeloplasty?

E. Dobry P. Usai U.E. Studer H. Danuser

Department of Urology, University of Bern, Bern, Switzerland

Downloaded from http://karger.com/uin/article-pdf/79/2/152/3592660/000106330.pdf by Universitätsbibliothek Bern user on 05 October 2023

source: https://doi.org/10.48350/22039 | downloaded: 27.4.2024

**Key Words**
Ureteropelvic junction obstruction · Pyeloplasty, open · Antegrade endopyelotomy, invasiveness

**Abstract**
***Objective:*** We investigated the invasiveness of antegrade endopyelotomy and open pyeloplasty in two consecutive series of patients with ureteropelvic junction obstruction. ***Patients and Methods:*** 98 patients were treated by open pyeloplasty from 1980 to 1991, and 137 patients by antegrade endopyelotomy from 1991 to 1999. Diagnosis of ureteropelvic junction obstruction was made by excretory urogram and/or antegrade pyelography, diuretic renography and retrograde pyelography. Invasiveness was evaluated by the postoperative need for analgesics, the complication rate and the residual long-term symptoms after surgery. ***Results:*** The postoperative need for opiate analgesics was significantly higher in patients after open pyeloplasty than after antegrade endopyelotomy. Ten percent of the patients complained of problems with the lumbotomy scar after open pyeloplasty, which was not encountered after endopyelotomy. Complications after open pyeloplasty occurred in 24% and were more severe than the 11% seen after endopyelotomy. The primary success rate after open pyeloplasty was 98 and 89% after antegrade endopyelotomy. The long-term success rate, ≥24 month postoperatively, was 96% (median follow-up 37 (24–196) months) and 76% (median follow-up 32 (24–73) months), respectively. ***Conclusion:*** Open pyeloplasty and endopyelotomy both have a high success rate with better patency results after open pyeloplasty. Open pyeloplasty is more invasive and has a higher morbidity. Endopyelotomy is a minimally invasive procedure with faster recovery, fewer and minor complications, significantly less need for peri- and postoperative analgesics, less residual pain due to the access, and no functional and esthetic sequelae of lumbotomy.

Copyright © 2007 S. Karger AG, Basel

## Introduction

Open pyeloplasty was considered the method of choice for treating ureteropelvic junction obstruction until the end of the 1980s. Especially the method described by Anderson-Hynes with resection of the oversized renal pelvis including the stenotic junction was widely implemented. In a meta-analysis of more than 2,000 patients treated by open pyeloplasty, the overall success rate was 90% (71–100%) [1]. In the last 10 years endoscopic and laparoscopic surgical techniques have replaced open pyeloplasty. The reported success rates of antegrade endopyelotomy range from 71 to 88% [2–7], those of retrograde acucise endopyelotomy from 69 to 88% [8–13] and those of the laparoscopic pyeloplasty from 87 to 100% [14–20].

KARGER
Fax +41 61 306 12 34
E-Mail karger@karger.ch
www.karger.com

© 2007 S. Karger AG, Basel
0042–1138/07/0792–0152$23.50/0

Accessible online at:
www.karger.com/uin

E. Dobry, MD
Urologic Clinic
Kantonsspital
CH–6000 Luzern 16 (Switzerland)
Tel. +41 41 205 45 10, Fax +41 41 205 45 31, E-Mail eduard.dobry@ksl.ch

One argument in favor of the endoscopic procedure over open pyeloplasty is the lower invasiveness. The question is whether this invasiveness is really low enough to justify a slightly worse success rate.

For this reason we analyzed parameters of invasiveness in two consecutive series of patients, one treated by open pyeloplasty and the other by antegrade endopyelotomy.

## Patients and Methods

*Open Pyeloplasty: Anderson-Hynes Technique*

Between 1980 and 1991, 98 consecutive patients with ureteropelvic junction obstruction, diagnosed by intravenous urography and/or diuretic renography and retrograde pyelography, were treated at our institution by open pyeloplasty with the Anderson-Hynes technique.

Surgical Technique

The open Anderson-Hynes pyeloplasty was performed in general anesthesia. After resection of the renal pelvis and the stenotic ureteropelvic junction, the renal pelvis was closed, cranial to caudal, with a running suture. The ureteropelvic anastomosis was performed end-to-side at the most caudal point of the renal pelvis. As a teaching hospital, different surgeons performed the operations; residents always under the supervision of a staff member.

The anastomosis was stented with a percutaneous transrenal 8-french catheter for 10–14 days. This stent also drained the pyelocaliceal system. The nephrostomy tube was closed when, after removal of the ureteral stent, antegrade pyelography showed passage of contrast medium from the renal pelvis into the ureter and bladder. The tube was then removed on the following day if the patient remained asymptomatic. If passage of contrast into the bladder could not be documented, antegrade pyelography was repeated at regular intervals, until passage of contrast could be demonstrated. Then the above procedure was carried out. In one patient with a pelvic kidney a transperitoneal approach was chosen. Instead of the percutaneous stenting of the anastomosis, in this case a JJ catheter was placed and after removal the passage of urine was documented by urography.

*Antegrade Endopyelotomy*

From 1991 to 1999 ureteropelvic junction obstruction, diagnosed by intravenous urography and/or diuretic renography and retrograde pyelography, was treated by antegrade endopyelotomy in 137 consecutive patients.

Surgical Technique

Endopyelotomy was usually performed by a percutaneous approach through a middle or, less often, upper or lower calix. A guide wire, placed prior to endopyelotomy, was then pulled through the percutaneous approach. The ureteropelvic junction was incised laterally along the guide wire with a curved (5/137) or a crescent shaped knife (132/137) or endoscopic scissors. As in open pyeloplasty, all procedures were performed by or under supervision of a staff member.

The endopyelotomy was stented for 6 weeks with a percutaneous 14/8.2-french Smith endopyelotomy catheter (78/137 patients) or with a 10/6 or 12/7-french JJ endopyelotomy stent (4/137 patients). In 55 of the 137 patients, a 27-french silicone drainage tube was pulled over a 14/8.2-french Smith catheter 2–3 weeks postoperatively. If antegrade pyelography performed on the 2nd postoperative day did not show any extravasation and free passage of urine into the bladder could be documented, then the percutaneous endopyelotomy catheter was closed. In patients with a JJ catheter the additionally placed percutaneous nephrostomy tube was closed and removed 24 h later. Six weeks after endopyelotomy the percutaneous endopyelotomy catheter was replaced by a nephrostomy tube and passage of urine was documented. After closing the nephrostomy tube it was removed the following day, provided the patients remained symptom-free. In patients with a JJ endopyelotomy stent, urinary passage was documented by intravenous urography 1 day after its transurethral removal.

*Follow-Up*

The need for postoperative pain medication and residual symptoms in the long-term were analyzed from patients' charts. Strong analgesics such as morphine were assessed in milligrams and morphine derivates calculated in morphine equivalents (7 mg pethidine = 1 mg morphine equivalent), whereas metamizol or nonsteroidal anti-inflammatory drugs (NSAID) were assessed as the number of doses.

Patients were controlled 6 and 24 months after surgery by clinical examination, intravenous urography and/or diuretic renography. Success was defined as the absence of pain due to obstruction and the absence of signs of obstruction on the intravenous urogram and/or the diuretic renography.

Paired and unpaired two-tailed Student's t test and the $\chi^2$ test were used for statistical analyses, which were performed in collaboration with the statisticians of our university.

## Results

The preoperative data of the 98 patients with open pyeloplasty and the 137 patients with antegrade endopyelotomy are comparable, except for the female:male ratio, which is higher in the endopyelotomy series (table 1).

The mean postoperative analgesic requirements were 78 ± 41 mg morphine, 20 ± 14 doses of metamizol and 6 ± 11 doses of NSAID after open pyeloplasty, and 15 ± 24 mg morphine, 1 ± 3 doses metamizol and 17 ± 17 doses NSAID after endopyelotomy (fig. 1). The difference for each pain medication group was statistically significant ($p < 0.001$).

*Complications*

There were no lethal postoperative complications in either group. In the pyeloplasty group 24 postoperative complications were noted in 23 of the 98 patients (24%): respiratory insufficiency requiring treatment in the in-

Downloaded from http://karger.com/uin/article-pdf/79/2/152/3592660/000106330.pdf by Universitätsbibliothek Bern user on 05 October 2023

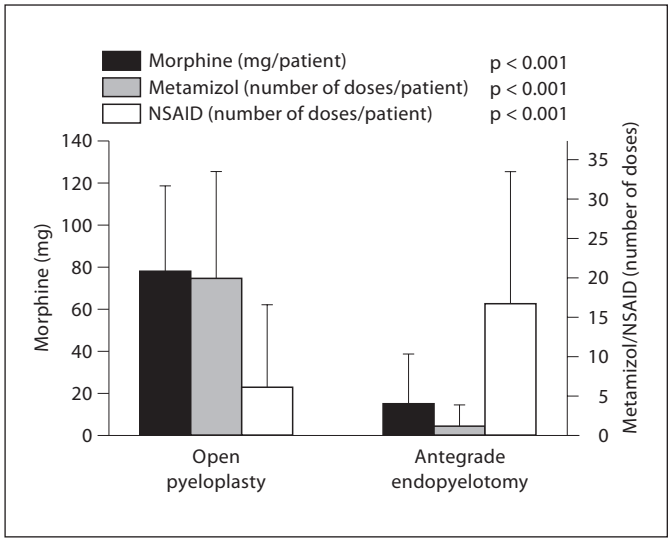


**Fig. 1.** Postoperative analgesic requirements in 98 patients with open pyeloplasty and in 137 patients with antegrade endopyelotomy.

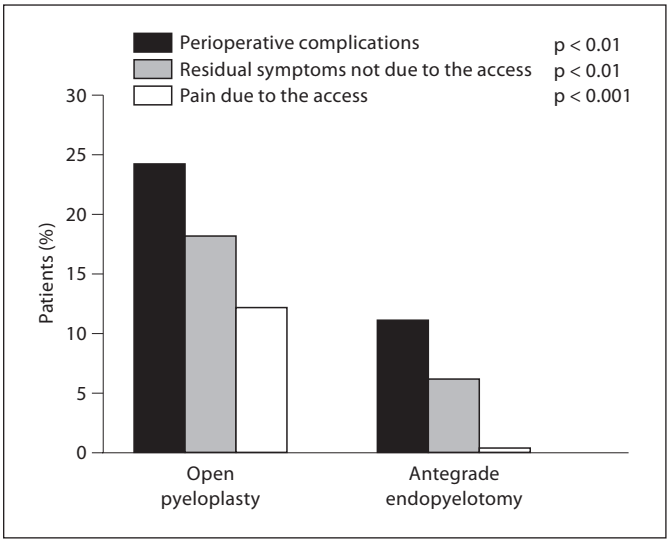


**Fig. 2.** Perioperative complications and residual symptoms 6 months postoperatively in 84 patients after open pyeloplasty and in 115 patients after antegrade endopyelotomy.

**Table 1.** Preoperative characteristics of 98 patients with ureteropelvic junction obstruction undergoing open pyeloplasty and of 137 patients undergoing antegrade endopyelotomy

| | Open pyeloplasty | Antegrade endopyelotomy |
|---|---|---|
| Number | 98 | 137 |
| Sex (f:m), % | 44:56 | 61:39 |
| Median age, years | 34 (15–74) | 38 (13–82) |
| Ipsilateral stones | 24 (24%) | 37 (27%) |
| Preoperative percutaneous nephrostomy | 31 (32%) | 52 (38%) |
| Patients with $^{131}$I-hippuran diuretic-renography | 70 (71%) | 122 (89%) |
| Mean total clearance, ml/min/1.73 m$^2$ | 447 ± 171 | 456 ± 142 |
| Mean split clearance of pathological site, ml/min/1.73 m$^2$ | 187 ± 112 | 186 ± 92 |
| Mean split clearance of pathological site, % of total clearance | 41 ± 18 | 41 ± 13 |
| Primary UPJ obstruction | 84 (86%) | 124 (91%) |
| Secondary UPJ obstruction, due to | 14 (14%) | 13 (9%) |
| Failed open pyeloplasty | 4 | 8 |
| Failed endopyelotomy (Acucise®/retrograde/antegrade) | 0 | 4 |
| Stones and percutaneous surgery | 10 | 1 |

UPJ = Ureteropelvic junction.

tensive care unit (n = 2); pulmonary embolism (n = 1); deep venous thrombosis of the lower extremity (n = 1); minimal pneumothorax requiring conservative treatment only (n = 4); pneumonia (n = 2); wound infection (n = 1); large wound hematoma (n = 1); urinary fistula in the anastomosis with spontaneous closure (n = 1); urosepsis after closure of the nephrostomy tube (n = 2); postoperative fever >38°C (n = 8), and re-obstruction requiring percutaneous drainage after removal of the nephrostomy tube (n = 1).



Downloaded from http://karger.com/uin/article-pdf/79/2/152/3592660/000106330.pdf by Universitätsbibliothek Bern user on 05 October 2023

After endopyelotomy 15 of 137 patients (11%) had complications: conservatively treated postoperative bleeding (n = 1); pyelonephritis (n = 2), or urosepsis (n = 1) treated by drainage and antibiotics; postoperative fever >38°C (n = 4); deep venous thrombosis of the lower extremity (n = 1), and blockage or dislocation of the endopyelotomy catheter (n = 6), all of which could easily be replaced (fig. 2).

*Residual Symptoms*

All of the patients with residual symptoms had no evidence of obstruction in the intravenous urogram or the diuretic renal scan, nor were the symptoms severe enough to justify further treatment. Six months after open pyeloplasty 25 of 84 successfully treated patients (30%) complained of residual symptoms: slight flank pain (n = 8); pain after fluid consumption (n = 2); recurrent colic (n = 5), and pain in the area of the incision (n = 10; fig. 2).

Twenty-four months postoperatively 14 of the 51 successfully treated patients (27%) had residual minor symptoms: flank pain (n = 7); pain after fluid consumption (n = 1); colic (n = 1), and pain in the area of the incision (n = 5).

Six months after endopyelotomy 7 of the 115 successfully treated patients (6%) complained of residual symptoms all of which needed no further intervention: slight pressure in the flank depending on position (n = 5), and intermittent colic (n = 2) (fig. 2).

Twenty-four months postoperatively 10 of the 68 successfully treated patients (15%) mentioned slight residual disorders: feeling of pressure in the flank (n = 8), and slight pain after fluid consumption (n = 2).

*Follow-Up Controls*

The overall success rate after open pyeloplasty was 98% (median follow up of 30 (4–248) months) and 80% after endopyelotomy (median follow-up of 28 (2–108) months.

Six months after open pyeloplasty and antegrade endopyelotomy 98 and 86% of patients, respectively, had a successful outcome. Twenty-four months after open and endoscopic treatment 96 and 76%, respectively, had been successfully treated.

*Management of Failures*

In one of the two open pyeloplasty failures, open revision with a new ureteropelvic anastomosis was successfully performed after 12 weeks. The second patient received a JJ catheter. This was left in place as definitive treatment after unsuccessful retro- and antegrade balloon dilation.

The 28 patients after unsuccessful endopyelotomy were successfully (re)treated by: open pyeloplasty (n = 15); retrograde acucise endopyelotomy (n = 4); antegrade re-endopyelotomy (n = 2); retrograde balloon dilation (n = 2); nephrectomy of kidneys with severely reduced function (n = 4), and permanent JJ catheter (n = 1).

## Discussion

Although the success rate of open pyeloplasty is superior, it is the more invasive procedure. Similar to other series [21, 22] our patients needed significantly more postoperative analgesics such as morphine, its derivatives or metamizol after open pyeloplasty, and this was not compensated by the higher requirement of low pain medication such as NSAID after endopyelotomy (fig. 1).

Time to resumption of 100% work capacity could not be retrospectively analyzed in our study. In other investigations it has been reported to be 10.3 (6–14) weeks [22] and 41.5 days [21] after open pyeloplasty. This is about double the time after antegrade endopyelotomy of 4.7 (1–6) weeks [22] and 19.8 days [21].

Twenty-four months after open surgery 10% of the patients still complained of residual pain in the lumbotomy scar. After endopyelotomy none of the patients had complaints that could be attributed to the renal access. Lumbotomy has a higher potential for residual discomfort due to dividing muscle close to the intercostal nerves [23, 24]. This approach also sometimes results in a cosmetically unpleasant scar. This is not negligible, especially for female and younger patients. Nevertheless, the residual complaints in both groups did not require additional treatment.

Aside from this residual pain in the renal access, 24 months after open pyeloplasty and endopyelotomy 17 and 15% of the patients, respectively, still had residual complaints suggestive of intermittent obstruction or neuralgia of renal origin, but without objective signs of obstruction on the intravenous urogram or the diuretic renal scan. These residual complaints after endopyelotomy were less severe than those after open pyeloplasty.

The final question is: Does the lower invasiveness but higher failure rate of endopyelotomy justify choosing this technique as first-line treatment? In our opinion it does, because a possible endopyelotomy failure can be retreated by the more invasive open pyeloplasty without substantial technical difficulties as compared to a primary open

Downloaded from http://karger.com/uin/article-pdf/79/2/152/3592660/000106330.pdf by Universitätsbibliothek Bern user on 05 October 2023

procedure. Finally the decision has to be made together with the patient after discussion of the advantages and disadvantages of each technique.

## Conclusions

Antegrade endopyelotomy is less invasive than open pyeloplasty, but open pyeloplasty has a higher success rate. Less need for peri- and postoperative analgesics, fewer and minor complications, faster recovery, the possibility of avoiding functional and esthetic sequelae of a lumbotomy, and less residual pain due to the approach are arguments for endopyelotomy. However, they have to be weighed against the higher success rate of open pyeloplasty.

In the future we will perhaps have the combination of minimal invasiveness and excellent results by laparoscopic pyeloplasty. However, the results of the technically demanding procedure are still slightly inferior to open pyeloplasty.

## References


1 Scardino PT, Scardino PL: Obstruction at the ureteropelvic junction; in Bergman H (ed): The Ureter, ed 2. New York, Springer, 1981, pp 697–716.
2 Gupta M, Tuncay OL, Smith AD: Open surgical exploration after failed endopyelotomy: a 12-year perspective. J Urol 1997;157: 1613–1619.
3 Danuser H, Ackermann DK, Bohlen D, et al: Endopyelotomy for primary ureteropelvic junction obstruction: risk factors determine the success rate. J Urol 1998;159:56–61.
4 Khan AM, Holman E, Pasztor I, et al: Endopyelotomy: experience with 320 cases. J Endourol 1997;11:243–246.
5 Van Cangh PJ, Wilmart JF, Opsomer RJ, et al: Long-term results and late recurrence after endoureteropyelotomy: a critical analysis of prognostic factors. J Urol 1994;151:934–937.
6 Kletscher BA, Segura JW, LeRoy AJ, et al: Percutaneous antegrade endopyelotomy: review of 50 consecutive cases. J Urol 1995;153: 701–703.
7 Cuzin B, Abbar M, Dawahra M, et al: 100 endopyélotomies percutanées. Technique, indication, résultats. Prog Urol 1992;2:559–569.
8 Chandhoke PS, Clayman RV, Stone AM, et al: Endopyelotomy and endoureterotomy with the acucise ureteral cutting balloon device: preliminary experience. J Endourol 1993;7:45–51.
9 Nadler RB, Rao GS, Pearle MS, et al: Acucise endopyelotomy: assessment of long-term durability. J Urol 1996;156:1094–1098.
10 Gelet A, Combe M, Ramackers JM, et al: Endopyelotomy with the Acucise cutting balloon device. Early clinical experience. Eur Urol 1997;31:389–393.
11 Shalhav AL, Giusti G, Elbahnasy AM, et al: Adult endopyelotomy: impact of etiology and antegrade versus retrograde approach on outcome. J Urol 1998;160:685–689.
12 Kim FJ, Herrell SD, Jahoda AE, et al: Complications of acucise endopyelotomy. J Endourol 1998;12:433–436.
13 Lechevallier E, Eghazarian C, Ortega JC, et al: Retrograde Acucise endopyelotomy: long-term results. J Endourol 1999;13:575–580.
14 Jarrett TW, Chan DY, Charambura TC, et al: Laparoscopic pyeloplasty: the first 100 cases. J Urol 2002;167:1253–1256.
15 Janetschek G, Peschel R, Frauscher F, et al: Laparoscopic pyeloplasty. Urol Clin North Am 2000;27:695–704.
16 Sundaram CP, Grubb RL 3rd, Rehman J, et al: Laparoscopic pyeloplasty for secondary ureteropelvic junction obstruction. J Urol 2003;169:2037–2040.
17 Soulie M, Salomon L, Patard JJ, et al: Extraperitoneal laparoscopic pyeloplasty: a multicenter study of 55 procedures. J Urol 2001; 166:48–50.
18 Turk IA, Davis JW, Winkelmann B, et al: Laparoscopic dismembered pyeloplasty – the method of choice in the presence of an enlarged renal pelvis and crossing vessels. Eur Urol 2002;42:268–275.
19 Eden CG, Cahill D, Allen JD: Laparoscopic dismembered pyeloplasty: 50 consecutive cases. BJU Int 2001;88:526–531.
20 Peschel R, Neururer R, Bartsch G, et al: Robotic pyeloplasty: technique and results. Urol Clin North Am 2004;31:737–741.
21 Karlin GS, Badlani GH, Smith AD: Endopyelotomy versus open pyeloplasty: comparison in 88 patients. J Urol 1988;140:476–478.
22 Brooks JD, Kavoussi LR, Preminger GM, et al: Comparison of open and endourologic approaches to the obstructed ureteropelvic junction. Urology 1995;46:791–795.
23 Bayazit Y, Aridogan IA, Tansug Z, et al: Morbidity of flank incision in 100 renal donors. Int Urol Nephrol 2001;32:709–711.
24 Aubert J, Koumare K, Dufrenot A: Anatomical study of the twelfth intercostal nerve and oblique lumbotomies (in French). J Urol (Paris) 1981;87:283–289.


Downloaded from http://karger.com/uin/article-pdf/79/2/152/3592660/000106330.pdf by Universitätsbibliothek Bern user on 05 October 2023