Original Article

Sexual Development

Sex Dev 2007;1:59–65
DOI: 10.1159/000096239

Received: June 12, 2006
Accepted after revision: July 17, 2006

A Diploid-Triploid (60,XX/90,XXY) Intersex in a Holstein Heifer

B. Meinecke[a] C. Drögemüller[b, e] H. Kuiper[b] D. Bürstel[a] P. Wohlsein[c]
S. Ebeling[a] A. Wehrend[d] S. Meinecke-Tillmann[a]

[a]Institute for Reproductive Biology, [b]Institute for Animal Breeding and [c]Department of Pathology, School of Veterinary Medicine Hannover, Foundation, Hannover, [d]Large Animal Clinic for Theriogenology and Ambulatory Services, Faculty of Veterinary Medicine, University of Leipzig, Leipzig, Germany; [e]Institute of Genetics, University of Berne, Berne, Switzerland

Key Words
Bovine · Diploidy-triploidy · Intersexuality · Masculine urethra

Abstract
The diploid/triploid (60,XX/90,XXY) condition in *Bos taurus* is very rare and only three cases have been published previously. The present animal exhibited an aplastic vulva, penis and clitoris agenesis, a male-like urethra located in a pseudoprepuce opening between the mammary complexes and a well developed M. rectipeninus. A normal (60,XX) female karyotype was detected in lymphocyte cultures whereas uterus and tendon cells revealed a 60,XX/90,XXY mixoploidy. Quantification of X and Y chromosome-specific sequences using RT-PCR revealed extraordinary high Y chromosome equivalents in the sample recovered from the male-like transformed vestibulum vaginae suggesting a causative relationship. The pathogenesis of the missing clitoris and penis, which is contrasted by the concomitant presence of a well developed M. rectipeninus, remains difficult to explain. A chimeric origin is suggested despite the fact that microsatellite analysis of the animal's blood cells displayed no unusual allele accumulation.

An intersex animal shows one or more features of both sexes (Short, 1969). Anomalous sexual development in domestic farm animals has been recognised since ancient times and in the cow freemartinism – a genetically female fetus masculinised in the presence of a male co-twin – is perhaps the best known derangement syndrome of the reproductive system (Hunter, 1995). Concerning the phenotypically genital ambiguity characterised by an aplastic vulva and a male-like urethra, the spontaneous 60,XX/90,XXY condition in cattle is rare and could be proved cytogenetically in only 3 cases (Dunn et al., 1970; Rieck et al., 1982). This clinical entity is described in the early literature but the cytogenetic status of these cases remained unknown (Hofmeier, 1935; McEntee, 1985). The triploid cell line has been observed in lymphocyte cultures by Dunn et al. (1970) in only 1 out of 700 metaphases, whereas in the remaining cases other tissues had to be karyotyped for detecting the presence of the second cell line. This is of particular importance in order to differentiate the diploidy-triploidy syndrome from freemartins and the 60,XX/60,XY condition which can produce similar intersex features (Dain and Bridge, 1978; Cole et al., 1997; Takagi et al., 2005). Spontaneous diploid-triploid individuals have also been reported in mice (Beatty, 1957), cat (Chu et al., 1964; Centerwall and Benirschke, 1973), mink (Nes, 1966), horse (Power and Leadon, 1990) and man (Tharapel et al., 1983; van de Laar et al., 2002).

KARGER
Fax +41 61 306 12 34
E-Mail karger@karger.ch
www.karger.com

1661–5425/07/0011–0059$23.50/0

Accessible online at:
www.karger.com/sxd

Burkhard Meinecke
Institute for Reproductive Biology, School of Veterinary Medicine Hannover Foundation, Bünteweg 2, D–30559 Hannover (Germany)
Tel. +49 511 953 8506, Fax +49 511 953 7150
E-Mail burkhard.meinecke@tiho-hannover.de

In contrast to man, where the diploid-triploid condition is a well known malformation syndrome, and more than 50% of the patients exhibiting mental and growth retardation, body and/or facial asymmetry, hypotonia, syndactyly, malformed low-set ears and, in male cases, a small phallus (van de Laar et al., 2002), these growth and skeletal malformations have never been reported in other species.

The present study investigated a case of a 4-year-old Holstein intersex with an aplastic vulva, penis and clitoris agenesis, a male-like urethra and carrying two cell lines (60,XX/90,XXY). It was of particular interest to elucidate the possible origin of the intersex condition and to determine genomic information in the sexual ambiguous tissues.

Material and Methods

Case History

A Holstein heifer born as the second singleton calf of a Holstein cow on the 22nd of October 2000 and diagnosed as an intersex by the local veterinarian was presented to the Institute of Reproductive Biology on the 9th of September 2003 for further investigation. Its parents were not available for study. The clinically sound animal weighed 380 kg and exhibited an aplastic vulva and a male-like urethra which opened in a pseudoprepuce between the mammary glands. Micturation was undisturbed.

Clinical Monitoring

Oestrous behaviour was recorded daily by experienced stockmen. The ovaries and uterus were monitored every other day by transrectal ultrasonography beginning on the first day of standing heat (day 1 of the oestrous cycle) for two consecutive oestrous cycles. Ultrasound examination was done by a single operator and recorded on video tapes. The ultrasound scanner was a real-time, B-mode instrument equipped with a 5.0 MHz linear-array, intrarectal transducer (Aloka, Duesseldorf, Germany).

Smears were collected from the mucosa of the pseudoprepuce every other day during one oestrous cycle period. Cytology specimens were fixed with Cyto Fixative® (Merck, Darmstadt, Germany) immediately after collection and stained by the Papanicolaou (1954) technique.

Hormone Analysis

Blood samples were collected from the jugular vein into 10 ml heparinised vacuum tubes (Heiland, Germany, Hamburg) on day 0, 5 and 15 of the oestrous cycle. Following centrifugation (10 min at 1200 *g*), the plasma was stored at –20°C until assayed. Plasma estradiol-17β and progesterone concentrations were determined according to Hoffmann et al. (1992) and Papa (2001), respectively.

Karyotyping

Cell Culture. Samples of the common calcaneal tendon and uterus were used for cytogenetic investigations. The tissues were disaggregated mechanically. Pieces with a diameter less than 1 mm were used and cultured in 25 cm^2 flasks (Sarstedt, Nuembrecht, Germany) in RPMI 1640 supplemented with 20% fetal calf serum, 5% phytohemagglutinin and 5% penicillin-streptomycin (Biochrom, Berlin, Germany). Cells were harvested between 10 and 20 days following the start of culture. The chromosome preparation procedure followed routine methods: cell incubation with 50 μl colcemid (10 μg/ml; Biochrom), cell detachment and isolation with trypsin (0.25% w/v, Biochrom), hypotonic treatment for 20 min with 0.075 M KCl and fixation with 3:1 methanol:glacial acetic acid. 150 μl of fixed cell suspension were dropped onto wet glass slides and processed further.

Blood Culture. Chromosome preparations were obtained from heparinised blood samples incubated with RPMI 1640, antibiotics and phytohemagglutinin for 72 h at 38°C and in 5% CO_2/air. 50 μl colcemid was added 1.5 h before harvesting. Chromosome preparation followed the methods mentioned above without trypsin treatment. Metaphase chromosomes were photographed with a computer-controlled CCD camera and processed with IPLab 2.2.3 software (Scanalytics Inc., Rockville, MA, USA). Identification adhered strictly to the ISCNDB2000 classification (ISCNDB, 2001).

PCR Analysis. Blood samples were taken from the intersex animal and from a normal cow and bull as controls. Genomic DNA of 15 tissue samples belonging to different sections of the urogenital tract was isolated from 25 mg tissue and 75 μl anticoagulated blood, respectively, using the DNeasy Tissue Kit (Qiagen, Hilden, Germany), including the RNase A treatment step according to the instructions of the manufacturer.

A panel of 14 bovine autosomal microsatellite markers belonging to 14 different autosomes (BM1824, BM2113, INRA023, SPS113, SPS115, TGLA53, TGLA122, TGLA126, TGLA227, ETH3, ETH10, ETH121, ETH225, MHCII) routinely used for parentage verification were amplified on genomic DNA isolated from a blood sample of the examined animal within a single multiplex PCR. The genotyping procedure was performed as described before (Glowatzki-Mullis et al., 1995). The glycinamide ribonucleotide formyltransferase *(GART)* gene encoding a trifunctional polypeptide involved in the de novo purine biosynthesis has been mapped on cattle autosome 1 (Wöhlke et al., 2005). The ectodysplasin A *(EDA)* gene encodes a trimeric transmembrane protein with an extracellular TNF-like signalling domain that maps to cattle chromosome Xq22–Xq24 outside the pseudoautosomal region (Drögemüller et al., 2000). The bovine sex determining region Y *(SRY)* gene maps to the distal region of BTAYq outside the pseudoautosomal region (Liu and de Leon, 2004). Primer Express 2.0 software (Applied Biosystems, Darmstadt, Germany) was used to design primers and probes spanning exon/intron boundaries from bovine *EDA* (Genbank Acc. No. AJ300468), *SRY* (Genbank Acc. No. AB039748), and *GART* (Genbank Acc. No. AJ780930): forward *EDA* (5′-GAA CAG CTG CCG GCT CTT T-3′), reverse *EDA* (5′-CAG TTC TAG GTA GCA GCA CAA CGT-3′); forward *SRY* (5′-GGG ATA TGA GTG GAA AAG GCT TAC-3′), reverse *SRY* (5′-AGT CTC TGT GCC TCC TCA AAG AA-3′); forward *GART* (5′-GCC TGT TTG GCT GGA CAA CT-3′), reverse *GART* (5′-TGG ATA ACC TTT ACT TGC CAT GAC-3′) and a specific Taqman minor groove binding probe for each PCR (*EDA*-probe VIC labeled: 5′-TTT CTT TGG CCT CTC CCT-3′; *SRY*-probe FAM labeled: 5′-ATG CTG AAA AGC GCC-3′; *GART*-probe TAMRA labeled: 5′-TGC TGC CGT AAC TGT-3′).

Table 1. Sex chromosome complement in somatic tissues of the intersex heifer

Source of cells	Number of metaphases			Ratio of XX to XXY cells
	with 60,XX	with 90,XXY	total	
Uterus	5	35	40	1:7
Tendo calcaneus communis	75	5	80	15:1
Lymphocytes	180	0	180	100:0

The quantitative real time PCRs were carried out independently with an ABI 7300 sequence detection system (Applied Biosystems) in a 20 μl reaction tube containing TaqMan Universal MasterMix (Applied Biosystems), 90 μM forward, 90 μM reverse primer, and 25 μM Taqman probe using an annealing and elongation temperature of 60°C. All assays were performed separately and in duplicates. Validation experiments from male genomic bovine DNA were arranged for each assay over 5 log levels showing that the efficiencies of the 3 assays used were close to 1.

The basic equation was simplified describing the exponential amplification of PCR: $A_n = A_0 \times (1 + E_x)^n$, where A_n is the number of target molecules at cycle n of the reaction, A_0 is the initial number of target molecules, E_x is the efficiency of target amplification, n is the number of cycles and the threshold cycle (ct) indicates the fractional cycle number at which the amount of amplified target reaches a fixed threshold after performing validation experiments showing efficient assays into: $A_{ct} = A_0 \times 2^{ct}$. To determine the equivalents of sex chromosomes in the different samples the bovine *GART* amplification level was compared by dividing it by the bovine *EDA*, and *SRY* amplification level, respectively, according to this term:

$$GART / EDA(SRY) = 2^{\Delta ct}, \text{ where } \Delta ct = ct_{GART} - ct_{EDA(SRY)}.$$

Pathology. Following euthanasia (Rompun®/T61®, Bayer Vital Leverkusen/Intervet, Unterschleissheim, Germany), necropsy was carried out following standard procedures. Urogenital organs were carefully isolated from connective tissues and recorded with an electronic camera. Tissue samples from the ovaries, oviduct, uterus, cervix, cranial vagina, vestibulum vaginae, M. rectipeninus, rectum and masculinized urethra were collected for genomic DNA extraction (fixed in liquid nitrogen) and for histological examination (fixed in buffered formalin solution). Histological sections (10 μm) were stained with haematoxylin-eosin and evaluated by light microscopy.

Results

Clinically, the animal displayed an aplastic vulva and a masculinized urethra opening in a pseudoprepuce located between the mammary complexes (fig. 1). The pseudoprepuce showed no male-like cavum and the urinary meatus measured 1.5 × 2.5 cm. Oestrous cycles (21 days), follicular wave dynamics (3 waves per oestrous cycle), ovulation and corpus luteum development occurred in a physiological manner. Plasma progesterone concentrations on days 1, 5 and 15 were 1.1, 13.5 and 16.7 nmol/l, respectively, whereas estradiol-17β values were 42.6, 7.3 and 14.4 pmol/l. A 2n = 60,XX/3n = 90,XXY karyotype (fig. 2) was detected in the cells grown from the common calcaneum tendon and the uterus tissue samples, whereas a 2n = 60,XX karyotype was found in peripheral blood lymphocytes (table 1). Microsatellite analysis of peripheral blood cells revealed no unusual accumulation of alleles.

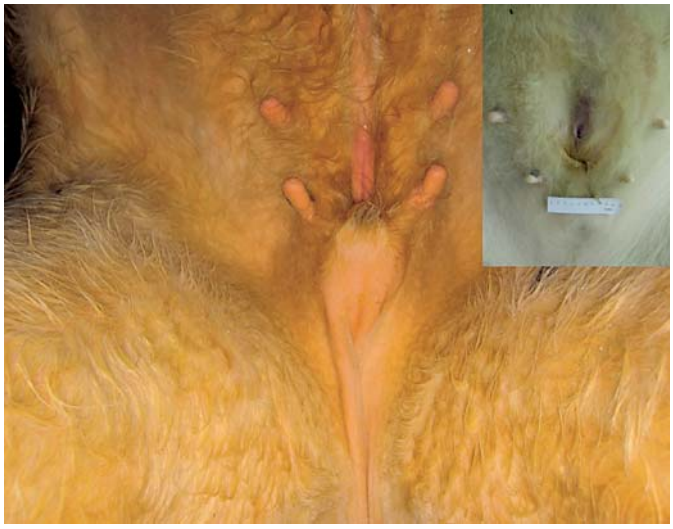

Fig. 1. Ventral aspect of the masculinised urethra opening in a pseudoprepuce located between the mammary complexes. Inset: note the large urethra orifice (scale: cm).

In the blood samples of the control cow and bull, quantitative real time PCRs revealed X chromosome equivalents in relation to chromosome 1 as nearly 1 (cow) and as nearly 0.5 (bull). In the blood sample of the intersex animal, high X chromosome specific equivalents and also very low Y chromosome specific equivalents were

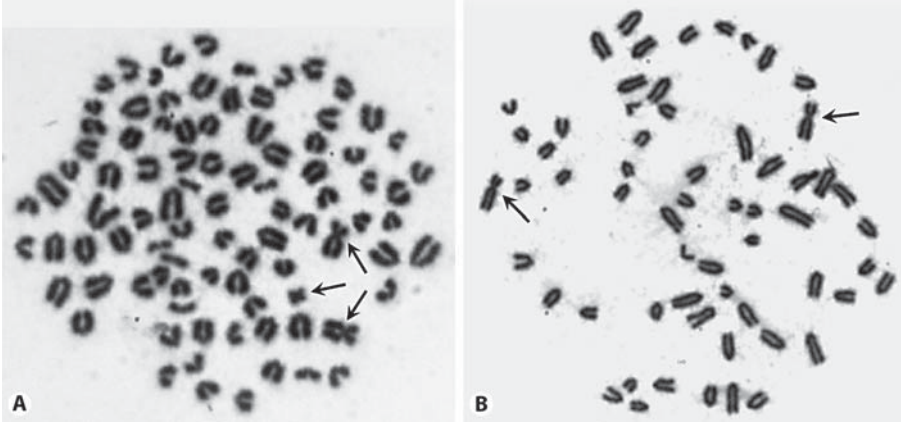

Fig. 2. Fibroblast metaphase with 90,XXY (**A**) and lymphocyte metaphase with 60,XX (**B**). Arrows indicate sex chromosomes.

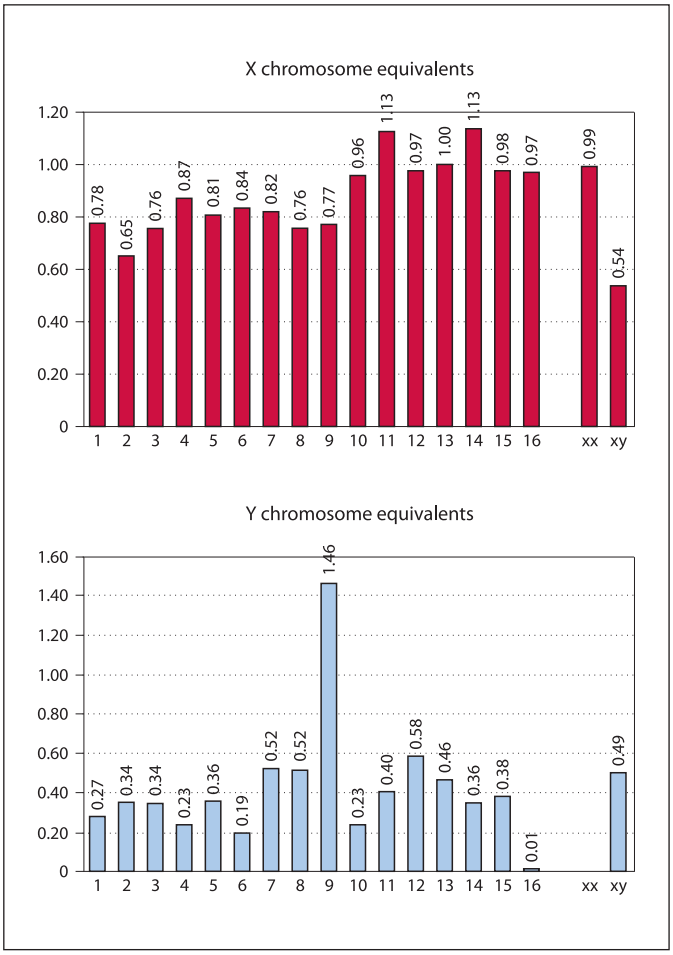

Fig. 3. Quantification of X- (*EDA*), Y- (*SRY*) and chromosome 1- (*GART*) specific sequences of a blood (XXY) and 15 different tissue samples of the intersex animal, as well as of a blood sample of a control cow (XX) and bull (XY). The relative equivalents of X- and Y-specific sequences are shown in relation to *GART* (= 1.0). 1 left ovary, 2 right ovary, 3 tip of the right uterus horn, 4 middle part of the right uterus horn, 5 tip of the left uterus horn, 6 bifurcation of the uterus, 7 cervix, 8 vagina, 9 vestibulum vaginae, 10 urethra, 11 caudal section of the right M. rectipeninus, 12 cranial section of the left M. rectipeninus, 13 caudal section of the left M. rectipeninus, 14 rectum, 15 orificium urinarium externum, 16 a blood sample of the intersex animal.

detected (fig. 3). In the tissue samples taken from different locations of the urogenital tract of the intersex animal, predominantly X chromosome specific equivalents were found (fig. 3). In each of the tissue samples Y chromosome specific equivalents could be detected, too. Samples of the cervix, vagina and the M. retractor penis reached male specific levels (0.40–0.58) whereas the Y chromosome specific equivalents of the tissue sample collected from the vestibulum vaginae were extraordinary elevated (1.46).

The necropsy revealed an anatomical normal developed female internal genital tract (vagina, cervix, uterus). The left ovary exhibited a well developed corpus luteum and a mid-cycle follicle (fig. 4). The cranial part of the vestibulum vaginae was completely developed including the diverticulum suburethrale and the glandulae vestibularis majores. Of the external genital organs, the clitoris or a penis and the labiae vulvae were missing. The caudal ending of the vagina was transformed into an open groove carrying on each side a bulge (fig. 5). The groove ended in the pseudoprepuce and was covered by connective tissue. The well developed M. rectipeninus emanated from the first two caudal vertebrae and inserted in the pseudoprepuce (fig. 6). In the histologic samples of the pseudoprepuce both vaginal- and prepuce-like sections could be

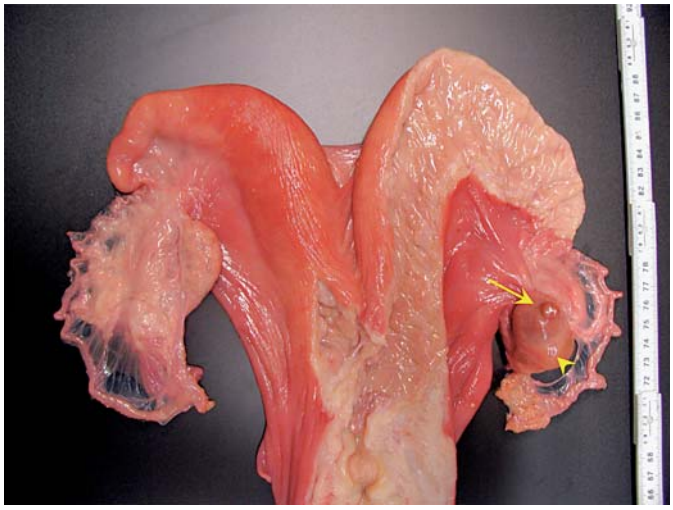

Fig. 4. Female internal genital organs of the intersex animal. The right uterine horn is opened to demonstrate the well developed endometrium. Note the corpus luteum (arrow) and the midcycle follicle (arrow head) on the right ovary.

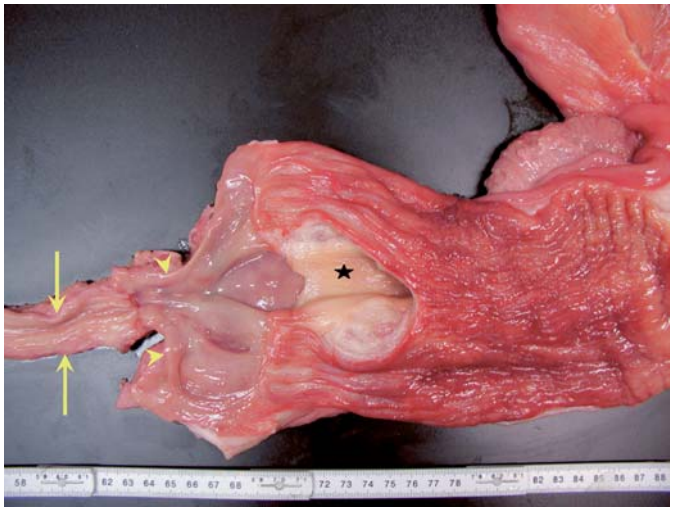

Fig. 5. Transition of the vestibulum vaginae into a male-like urethra. The caudal portion of the vestibulum (arrowheads) is transformed into an open groove carrying a bulge (arrows) on each side. The dorsal connective tissue has been cut open to demonstrate the female-like orificium urethrae externum (*) and the missing clitoris and penis.

identified. The exfoliative cytology smears taken from the pseudoprepuce revealed predominantly intermediate and keratinised acidophil superficial cells.

Discussion

Despite the aplastic vulva and the male-like urethra, the animal described here appeared as a normal heifer. The regular oestrus intervals accompanied by normal follicular waves and continuous ovulations established by ultrasonography and steroid hormone analysis indicate an unperturbed expression of the predominantly female karyotype (60,XX), including the reproductive pattern and internal sexual organs. Earlier reports on spontaneous bovine female diploid-triploid individuals mentioned the presence of testicular and ovarian tissue in the same gonad and/or the formation of a hypoplastic penis without a flexura sigmoidea (Dunn et al., 1970; Rieck et al., 1982). In the present case, neither a penis nor a clitoris could be identified, which is consistent with the findings of Cribiu et al. (1989) in an XY intersex Charolais heifer and those of Dain and Bridge (1978) in a Friesian freemartin calf carrying XX/XXY skin cells and XX/XY/XXY lymphocytes. In addition, Soderdahl et al. (1972) published a report of two human cases of penile agenesis with a predominantly 46,XY cell line but

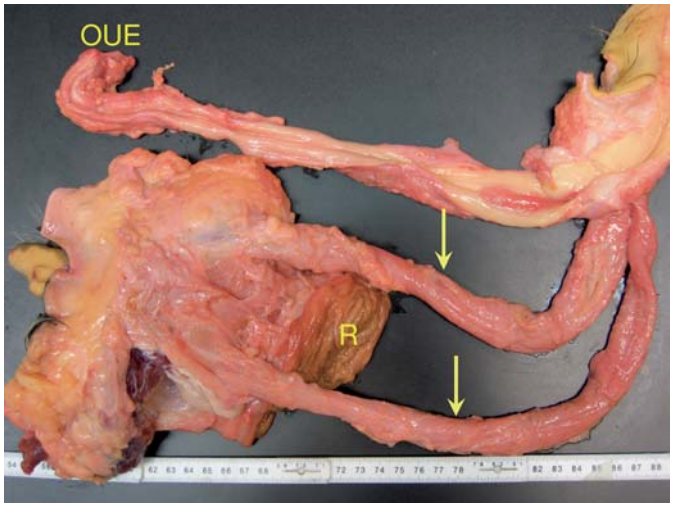

Fig. 6. The left and right part of the M. rectipeninus (arrows) dissected free of connective tissues. The pseudoprepuce has been cut open to demonstrate the missing penis. R = Rectum, OUE = male-like orificium urethrae externum.

with 4 cells and 1 cell, respectively, having a 47,XXY karyotype. In mice it has been demonstrated that the endodermally derived urethral plate epithelium, which is located along the ventral side of genital tubercle, is a site of sonic hedgehog (Shh) expression (Perriton et al., 2002). Shh is required for outgrowth and patterning of

the genital tubercle, and mice with a targeted deletion of Shh have penile and clitoral agenesis (Haraguchi et al., 2001; Perriton et al., 2002). This observation argues in favour of a very early altered event(s) occurring during the first sex independent phase of external genital development leading to an agenesis of penis, clitoris and vulva (George and Wilson, 1994; Yamada et al., 2003). In fetal bovine testis the first Leydig cell generations differentiate at day 40 post conception and 2 days later testosterone appears in the blood and reaches high levels within the following few days (Rüsse, 1991). Thus, the typical mammalian sequence of testicular differentiation followed by genital masculinisation is also shown by cattle. However, in the present case, neither gross morphological nor histological evidence for testicular tissues could be detected whose endocrine products may have induced the formation of the male-like urethra, pseudoprepuce and substantial drawn-out M. rectipeninus. In this context, it is of particular interest to note the exceptionally high Y-chromosome equivalents which were detected in the tissue sample recovered from the vestibulum vaginae. It is possible that *SRY*-sequences have been duplicated in this tissue. These disproportionately high levels of Y-specific genomic information exactly at this location may have disturbed development and led to formation of the observed male-like transformation. The urethra itself carried predominantly X-chromosome equivalents. This quantitative degree is compatible with the gross and histological condition of the urethra. It did not appear as a closed tube within a prepuce cavum but, instead, as a furrow resembling an extended vestibulum vaginae. This interpretation is further supported by the low Y- and high X-chromosome equivalent levels detected in the tissue sample recovered from the large orificium urinarium externum. However, it should be kept in mind that all quantitative data concern genomic information on tissues taken at a fixed time point; these data do not necessarily reflect local or dynamic gene expression.

In the histological preparations, both prepuce- and vagina-like mucosa sections were identified whereas in the smears taken from the pseudoprepuce mucosa the detection of intermediate, superficial and cornified cells indicates a steroid hormone responsive mucosa (Miroud and Noakes, 1990).

Concerning the pathogenesis of a diploid-triploid mammal, a mosaic and a chimera must be considered as two different entities with admixtures of cells in a given individual (Chu et al., 1964; Benirschke, 1974; McLaren, 1976). These terms have often been used synonymously. However, because of their divergent pathogenesis one should try to distinguish between the two events. In the present case, no parental DNA samples were available and microsatellite analysis of blood cell DNA of only the affected animal did not indicate chimerism. However, the negative result of the microsatellite analysis does not exclude the possibility that two sperms participated in fertilisation giving rise to the present animal. According to McLaren (1976), an individual having both an XX and XY cell line is unlikely to be a mosaic, since such a situation cannot arise by any simple non-disjunction event. It is therefore suggested that the animal is a chimera arising via fertilisation of an oocyte by two sperms, one carrying an X and the other a Y chromosome. In the so-formed tripronuclear zygote, the male pronucleus carrying the X chromosome fused with the female pronucleus giving rise to the 60,XX cell line. The second male haploid complement carrying the Y chromosome may have remained in the cytoplasm of the zygote but following a few divisions of the early embryo, it fused with the nucleus of one blastomere and established the triploid cell line (Dewald et al., 1975). An addition of this second male chromosome set to the very early division stages is suggested because, during the first three to four cell cycles, proper cell cycle checkpoint control may not occur (Alberts et al., 2002). Furthermore, pronuclei of tripronuclear zygotes can remain unfused for some time (pig: Han et al., 1999; man: Rosenbusch, 2001).

The fate of the triploid cell clone depends on its ability to colonise the trophoblast and/or the inner cell mass. In the affected animal, Y chromosome specific sequences were determined in ectoderm and mesoderm derived tissues indicating that both the trophoblast and the inner cell mass were colonised by triploid cells. This triploid cell line would not have been detected if routine investigation had ceased after examining metaphases only of lymphocytes. From a clinical point of view, it seems therefore reasonable to stress that several tissues of different embryonic origin have to be karyotyped when an intersex animal is investigated as already stated by Dunn et al. (1970).

Acknowledgement

The authors greatfully acknowledge the constructive review of the manuscript by R.H.F. Hunter.

References

Alberts B, Johnson A, Raff M, Roberts K, Walter P: The cell cycle and programmed cell death, in Molecular Biology of the Cell, 4th ed., pp 984–1026 (Garland Science, New York 2002).

Beatty RA: Parthenogenesis and Polyploidy in Mammalian Development, pp 71–88 (Cambridge University Press, London 1957).

Benirschke K: Chimerism and mosaicism – two different entities. Obstet Gynecol Annu 3: 33–45 (1974).

Centerwall WR, Benirschke K: Male tortoiseshell and calico (T-C) cats. J Hered 64:272–278 (1973).

Chu EHY, Thuline H, Norby DE: Triploid-diploid chimerism in a male tortoiseshell cat. Cytogenetics 3:1–18 (1964).

Cole J, Broadwell M, Rogers G: Intersexuality in a Charolais heifer. Vet Rec 141:656–657 (1997).

Cribiu EP, Chaffaux St, Durand V, Humblot P: Cytogenetic, anatomical, histological and hormonal study of a female pseudohermaphrodite cow. Zuchthyg 24:265–273 (1989).

Dain AR, Bridge PS: A chimearic calf with XX/XXY mosaicism and intersexuality. J Reprod Fert 54:197–201 (1978).

Dewald G, Alvarez MN, Clouthier MD, Kelalis PP, Gordon H: A diploid-triploid human mosaic with cytogenetic evidence of double fertilization. Clin Genet 8:149–160 (1975).

Drögemüller C, Distl O, Leeb T: Identification of a highly polymorphic microsatellite within the bovine ectodysplasin A *(ED1)* gene on BTA Xq22–24. Anim Genet 31:416 (2000).

Dunn HO, McEntee K, Hansel W: Diploid-triploid chimerism in a bovine true hermaphrodite. Cytogenetics 9:245–259 (1970).

George FW, Wilson JD: Sex determination and differentiation, in Knobil E, Neill JD (eds): The Physiology of Reproduction, vol. 1, 2nd ed., pp 3–28 (Raven Press, New York 1994).

Glowatzki-Mullis ML, Gaillard C, Wigger G, Fries R: Microsatellite-based parentage control in cattle. Anim Genet 26:7–12 (1995).

Han Y-M, Wang W-H, Abeydeera LR, Petersen AL, Kim J-H, et al: Pronuclear location before the first cell division determines ploidy of polyspermic pig embryos. Biol Reprod 61: 1340–1346 (1999).

Haraguchi R, Mo R, Hui C, Motoyama J, Makino S, et al: Unique functions of sonic hedgehog signalling during external genitalia development. Development 128:4241–4250 (2001).

Hoffmann B, Höveler R, Hasan SH, Failing K: Ovarian and pituitary function in dogs after hysterectomy. J Reprod Fert 96:837–854 (1992).

Hofmeier CFB: An abnormally placed vulva in a heifer. Onderstepoort J Vet Sci 4:579–580 (1935).

Hunter RHF: Sex Determination, Differentiation and Intersexuality in Placental Mammals, pp 107–174 (Cambridge University Press, Cambridge 1995).

ISCNDB2000. International System for Chromosome Nomenclature of Domestic Bovids. Cribiu EP, Di Berardino D, Di Meo GP, Eggen A, Gallagher DS et al. (eds). Cytogenet Cell Genet 92:283–299 (2001).

Liu WS, de Leon FA: Assignment of *SRY*, *ANT3*, and *CSF2RA* to the bovine Y chromosome by FISH and RH mapping. Anim Biotechnol 15: 103–109 (2004).

McEntee K: Pathology of the female reproductive system, in Stünzi H (ed): Handbuch der speziellen pathologischen Anatomie der Haustiere, Bd IV, 3. Auflage, pp 142–143 (Paul Parey Verlag, Berlin und Hamburg 1985).

McLaren A: Mammalian Chimaeras, pp 92–103 (Cambridge University Press, Cambridge 1976).

Miroud K, Noakes DE: Exfoliative vaginal cytology during the oestrous cycle of the cow, after ovariectomy, and after exogenous progesterone and oestradiol-17β. Br Vet J 146: 387–379 (1990).

Nes N: Diploid-triploid chimerism in a true hermaphrodite mink (*Mustela vison*). Hereditas 56:159–170 (1966).

Papa P: Darstellung von Estradiol-17β und Progesteronrezeptoren im Corpus luteum der Hündin zu definierten Zeitpunkten im Östrus und Diöstrus. Diss Med Vet Gießen (2001).

Papanicolaou GN: Atlas of Exfoliative Cytology, p 6 (Harvard University Press, Cambridge MA 1954).

Perriton CL, Powles N, Chiang C, Maconochie MK, Cohn MJ: Sonic hedgehog signalling from the urethral epithelium controls external genital development. Dev Biol 247:26–46 (2002).

Power MM, Leadon DP: Diploid-triploid chimaerism (64,XX/96,XXY) in an intersex foal. Equine Vet J 22:211–214 (1990).

Rieck GW, Höhn H, Schmidt I: Vulvaaplasie und Urethra masculina: Maskulinisierungseffekte des Sinus urogenitalis bei genetisch weiblichen Rindern durch Chimärismen mit dem XXY-Gonosomen-Komplement. Berl Münch Tierärztl Wschr 95:181–185 (1982).

Rosenbusch B: Digynic triploidy: possible mechanisms. Prenat Diagn 21:234 (2001).

Rüsse I: Harn- und Geschlechtsorgane, in Rüsse I, Sinowatz F (Hrsg.): Lehrbuch der Embryologie der Haustiere, pp 304–337 (Paul Parey Verlag, Berlin und Hamburg 1991).

Short RV: An introduction to some of the problems of intersexuality. J Reprod Fert Suppl 7: 1–8 (1969).

Soderdahl DW, Brosman SA, Goodwin WE: Penile agenesis. J Urol 108:496–499 (1972).

Takagi M, Yamagishi N, Oboshi K, Kageyama S, Hirayama H, et al: A female pseudohermaphrodite Holstein heifer with gonadal mosaicism. Theriogenology 63: 60–71 (2005).

Tharapel AT, Wilroy RS, Martens PR, Holbert JM, Summitt RL: Diploid-triploid mosaicism: delineation of the syndrome. Ann Genet 26:229–233 (1983).

van de Laar I, Rabelink G, Hochstenbach R, Tuerlings J, Hoogeboom J, Giltay J: Diploid/triploid mosaicism in dimorphic patients. Clin Genet 62:376–382 (2002).

Wöhlke A, Drögemüller C, Kuiper H, Leeb T, Distl O: Molecular characterization and chromosomal assignment of the bovine glycinamide ribonucleotide formyltransferase. Gene 348:73–81 (2005).

Yamada G, Satoh Y, Baskin LS, Cunha G: Cellular and molecular mechanisms of development of the external genitalia. Differentiation 71:445–460 (2003).