Neuro-endocrinology

Neuroendocrinology 2008;87:47–62
DOI: 10.1159/000111037

Published online: November 21, 2007

Consensus Guidelines for the Management of Patients with Liver Metastases from Digestive (Neuro)endocrine Tumors: Foregut, Midgut, Hindgut, and Unknown Primary

Thomas Steinmüller[a] Reza Kianmanesh[b] Massimo Falconi[c] Aldo Scarpa[d] Babs Taal[e] Dik J. Kwekkeboom[f] José M. Lopes[g] Aurel Perren[h] George Nikou[i] James Yao[j] Gian Franco Delle Fave[k] Dermot O'Toole[l] all other Frascati Consensus Conference participants[1]

[a]DRK Kliniken Westend, Berlin, Germany; [b]UFR Bichat-Beaujon-Louis Mourier, Service de Chirurgie Digestive, Hôpital Louis Mourier, Colombes, France; [c]Medicine and Surgery, General Surgery Section, MED/18 – General Surgery and [d]Department of Pathology, University of Verona, Verona, Italy; [e]Netherlands Cancer Centre, Amsterdam, and [f]Department of Nuclear Medicine, Erasmus University Medical Center, Rotterdam, The Netherlands; [g]IPATIMUP, Porto, Portugal; [h]Universitätsspital Zürich, Departement Pathologie, Histologielabor PATH F1, Zürich, Switzerland; [i]68, Plataion St, Vrilissia, Athens, Greece; [j]The University of Texas M.D. Anderson Cancer Center, Houston, Tex., USA; [k]Ospedale S. Andrea, Rome, Italy; [l]Service de Gastroentérologie, Centre Hospitalier Universitaire d'Angers, Angers, France

Introduction

Much useful information has already been published in relation to primary neuroendocrine tumors (NETs) of the foregut, midgut and hindgut [1–6]. Due to the frequency of liver metastases and their impact in prognosis, decisions pertaining to management in patients with digestive NETs frequently have to take this factor into consideration prior to therapeutics. This chapter is devoted to management of patients with liver metastases, however, specifics in relation to individual tumors types such as tumor markers and diagnostics should be sought in the relevant chapters [2–6]. The management of patients with NET liver metastases is heterogeneous including surgical, medical, radiological and nuclear medical possibilities; all methods have potential therapeutic benefits and their indications and outcomes are discussed in detail here. The broad range of treatments underlines the need for a multidisciplinary approach in considering therapy for patients with digestive NETs.

Epidemiology

Endocrine tumors are heterogeneous diseases in terms of both biological features and clinical behavior. One of the major prognostic factors that dramatically affects patient survival is the presence of liver metastases. It has been demonstrated that patients with liver metastases have a worse survival rate when compared to those without liver involvement [7–9]. Unfortunately, a large pro-

T. Steinmüller and R. Kianmanesh wrote the paper, which was revised by G.F. Delle Fave and D. O'Toole. They and the other authors listed in alphabetical order equally contributed to the preparation of the Guidelines.

[1] See list at the end of the paper.

KARGER

Fax +41 61 306 12 34
E-Mail karger@karger.ch
www.karger.com

© 2007 S. Karger AG, Basel
0028–3835/08/0871–0047$24.50/0

Accessible online at:
www.karger.com/nen

T. Steinmüller
Department of Surgery, Center for Visceral and Endocrine Surgery
DRK-Kliniken Berlin Westend, Spandauer Damm 130, DE–14050 Berlin (Germany)
Tel. +49 30 30 35 42 05, Fax +49 30 30 35 42 09
E-Mail t.steinmueller@drk-kliniken-westend.de

Downloaded from http://karger.com/nen/article-pdf/87/1/47/3228190/000111037.pdf by Universitätsbibliothek Bern user on 19 September 2023

portion of patients with either midgut or hindgut tumors (up to 60–75%) already present with liver metastases. In particular, patients with tumors not associated with hormonal symptoms (non-functioning tumors) present with liver disease in up to 50% of the cases [7].

The impact of liver metastases on patient survival also depends on the site of the primary tumor. Pancreatic tumors, for example, have a 5-year survival rate of 30–60%, whereas gastrointestinal tumors have a survival rate of 60–90% [7–9]. The site of the primary tumor remains unknown in 5–10% of patients who present with liver metastases, in spite of intensive diagnostic work-up. Additional prognostic factors include histological grading, the extent and lobarity of liver involvement, and the presence of extrahepatic metastases.

Minimal Consensus Statements – Epidemiology

Up to 75% of patients who present with mid- or hindgut tumors also have liver metastases. In particular, patients with non-functioning tumors often already present with liver involvement. The site of the primary tumor is also of prognostic value, with pancreatic tumors exhibiting a much worse prognosis than tumors of the gastrointestinal tract.

Prognosis

The presence of liver metastases confers an overall poor prognosis compared to patients without liver metastases for all NETs regardless of the primary. Some specifics in survival rates in relation to tumor type deserve mention.

Foregut. Hepatic metastases, rare in cases of type 1 gastric carcinoids, may be observed in up to 30% of patients with type 2 tumors [10]. Type 3 gastric tumors present frequently with liver metastases (50–100%). Tumor-related death occurs in 0, 10 and 25–30% of patients with types 1, 2 and 3, respectively [11–14]. 5–10% of duodenal gastrinomas and 20–25% of pancreatic gastrinomas are associated with liver metastases. Liver metastases have a negative impact on survival with a 10–20% 10-year survival compared to 90–100% without liver metastases. The extent of liver metastases also influences survival (10-year survival of 16% for diffuse liver metastases versus 80% for limited disease of <5 metastases per lobe). Development of metachronous liver metastases also reduces survival to 85% [15, 16]. For malignant insulinomas median disease-free survival after curative resection is 5 years, but recurrence occurs in more than 60% at a median interval of 2.5–3 years [17, 18]. For rare functioning pancreatic NETs, not enough data are available to predict prognosis in patients with liver metastases but their presence is a pejorative factor. In patients with non-functioning pancreatic NETs, actuarial 5- and 10-year survival rates after diagnosis of liver metastases were 46 and 38%, respectively [19]. However, aggressive treatment may increase 5-year survival to 63 or 82% [20, 21]. Rapid progression of liver metastases (>25% volume increase within 6–12 months) confers a poor prognosis [19].

Midgut. For NETs involving the jejunum or ileum, the 10-year survival is approximately 45% in the absence of liver metastases at diagnosis, <40% in the presence of liver metastases. Five-year survival decreases from 60–70% in patients with localized or regional disease to 50–60% in those with distant metastases including liver [22–25].

Appendix. Five-year survival of patients with an appendiceal carcinoid decreases from 95% for localized disease to 34% for those with distant metastases including liver [22, 26–28].

Rectal or Colonic NETs. Distant metastases in rectal NETs at diagnosis are uncommon (~1.7 and 8.1% [22]). In the latest subset of SEER (1992–1999) only 1.7% of the 925 tumors had distant metastases. Rectal carcinoids have an overall 5-year survival rate of 75–88% when localized at diagnosis and it decreases to 21–32% with distant disease. Colonic NETs have a poor prognosis due to the advanced stage at which the tumors are diagnosed. Only 16% of cecal tumors are localized at diagnosis in the latest SEER subset, although the figures have improved for the other colonic sites [29]. More than 40% of cecal tumors have distant metastatic disease at diagnosis [30].

Poorly-Differentiated Endocrine Carcinomas. Poorly-differentiated endocrine carcinomas belong to the WHO group 3 of highly malignant tumors; the prognosis for patients with poorly-differentiated endocrine carcinomas is generally poor regardless of the localization of the primary tumor. Patients with treated metastatic disease have an expected survival time of 6–18 months [31].

Minimal Consensus Statements – Prognosis

Presence of liver metastases largely influences prognosis in all types or digestive NETs. In addition, progressive liver metastases as well as the extent of metastases are negative prognostic factors. According to the experts, although no study has compared therapies for liver metastases to the natural history alone, it appears that interventional strategies alter the prognosis with overall 5-year survival increasing from <50% to 60–70% in patients undergoing aggressive treatment (curative liver surgery or effective locoregional therapies) for metastases compared to historical controls. Poorly-differentiated carcinomas have an overall poor prognosis whether presenting with or without liver metastases.

Downloaded from http://karger.com/nen/article-pdf/87/1/47/3228190/000111037.pdf by Universitätsbibliothek Bern user on 19 September 2023

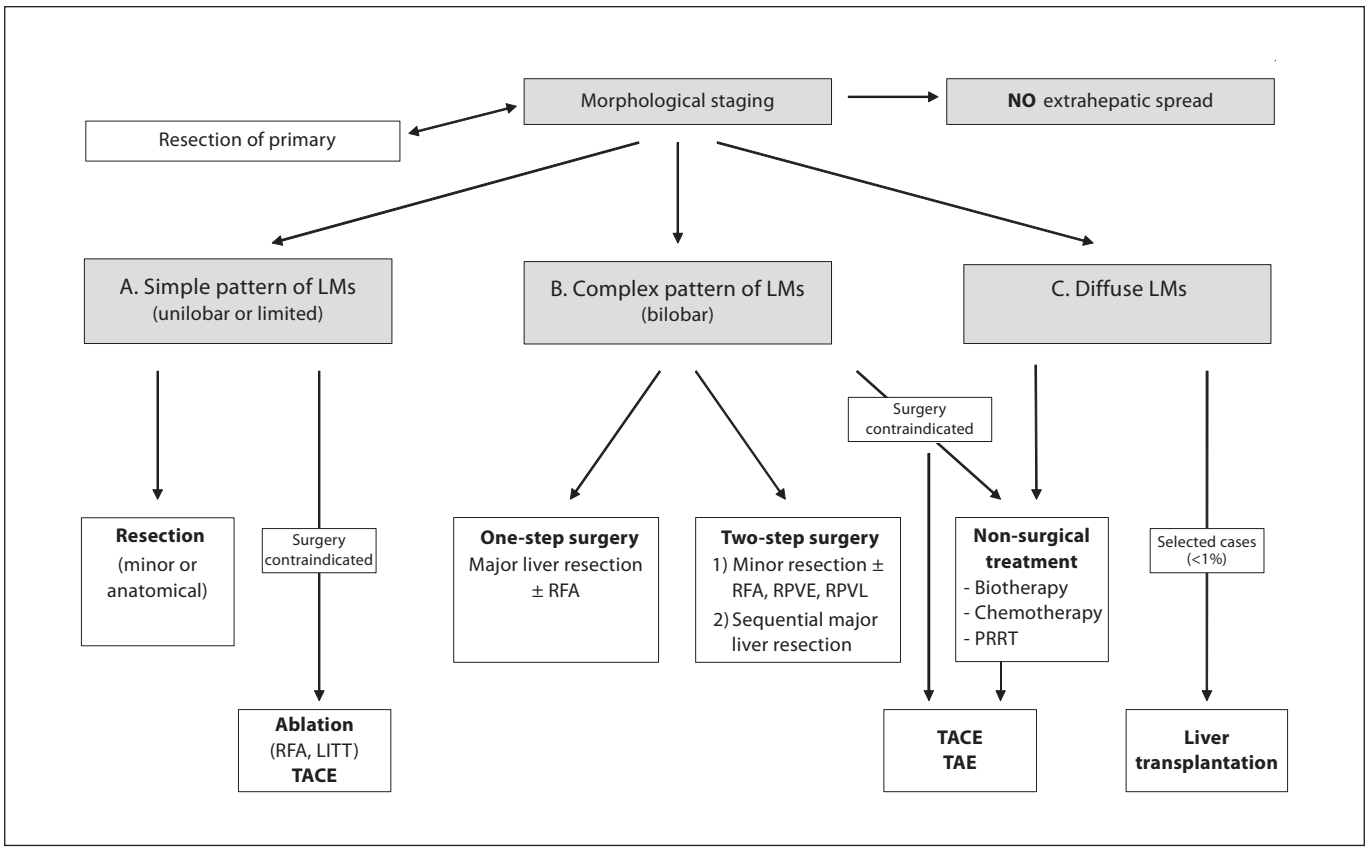

Fig. 1. Treatment approach to liver metastases without extrahepatic spread. The first line of therapy in limited unilobar and complex liver disease without extrahepatic spread is surgical resection with or without local ablative techniques. Patients with diffuse liver disease, and those who are poor surgical candidates, may be treated with biotherapy, or chemotherapy TACE, or TAE. In specially selected candidates with diffuse metastases, liver transplantation may be an option. LM = Liver metastasis; RFA = radiofrequency ablation; RPVE = right portal vein embolization; RPVL = right portal vein ligation; LITT = laser-induced thermotherapy; TACE = trans-catheter arterial chemoembolization; TAE = trans-catheter arterial embolization. See 'Differential Indication'.

Clinical and Pathological Presentation

The clinical presentation of liver metastases from endocrine tumors depends upon the functional status of the tumor. In tumors with associated syndromes, these are related to the hypersecretion of the specific hormones (e.g. Zollinger-Ellison syndrome, carcinoid syndrome, etc.). In patients with non-functional tumors, symptoms depend on tumor load and the location of the metastases (non-specific abdominal pain, weight loss). Due to these non-specific clinical features, diagnosis of liver metastases from non-functioning endocrine tumors may then be an incidental finding (e.g. on ultrasound study performed for cholestasis liver tests). The extent of liver metastases in non-functioning endocrine tumors may be more extensive than in functioning tumors.

Morphologically, three different patterns of liver infiltration by metastases must be differentiated, since they have an impact on the therapeutic approach (fig. 1, 2).

(A) The metastases are confined to one liver lobe or limited to two adjacent segments so that they can be resected by a standard anatomical resection. This 'simple pattern' can be found in 20–25% of the cases.

(B) In the 'complex pattern' there is one major focus but with smaller satellites contralaterally (see fig. 3). Such bilobar patterns occur in 10–15% of the cases and can still be approached surgically.

(C) Diffuse, multifocal liver metastases are found in 60–70% of the cases.

Downloaded from http://karger.com/nen/article-pdf/87/1/47/3228190/000111037.pdf by Universitätsbibliothek Bern user on 19 September 2023

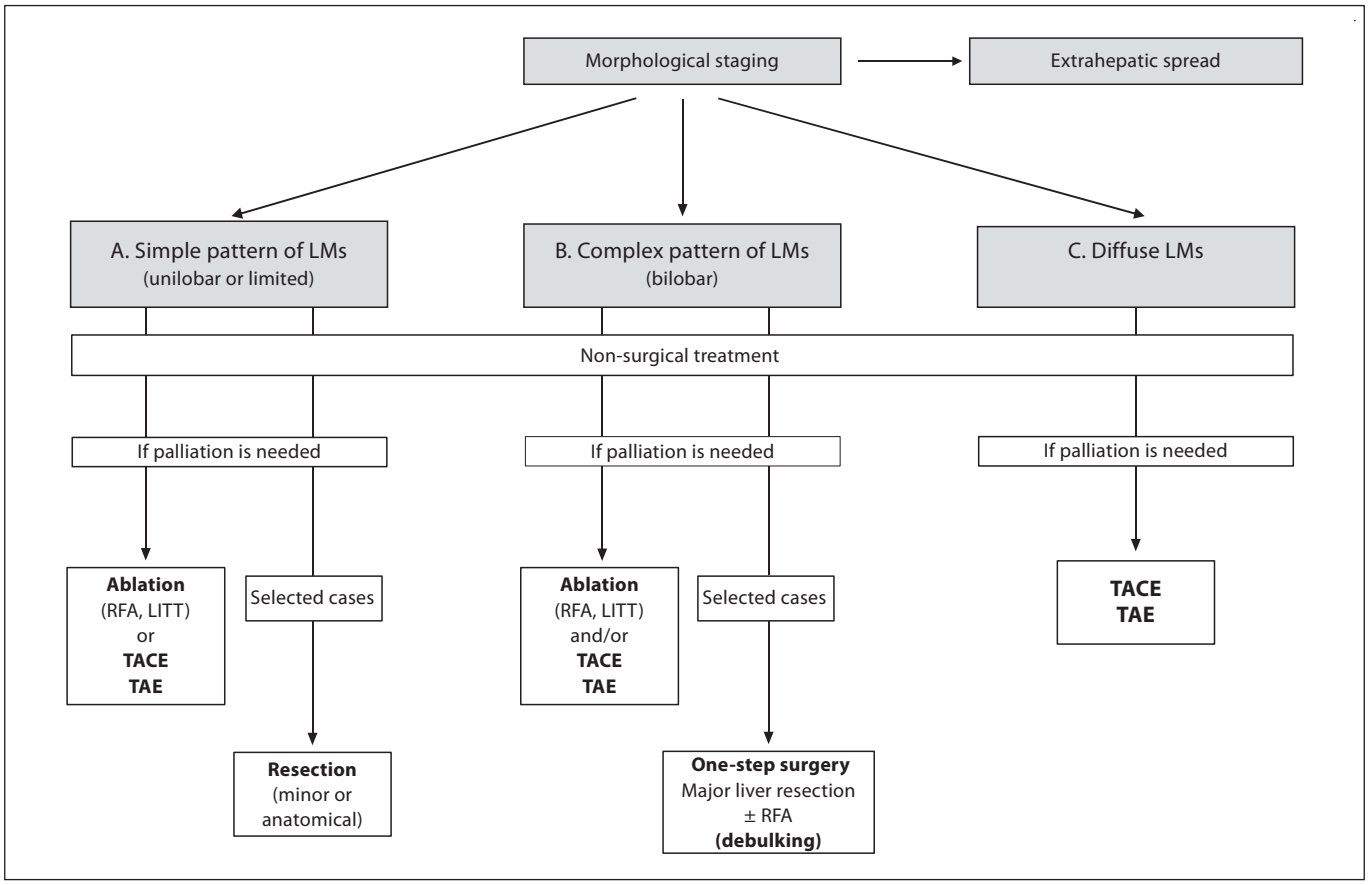

Fig. 2. Treatment approach to liver metastases with extrahepatic spread. Patients with liver metastases with inoperable extrahepatic spread should initially be treated using non-surgical methods (biotherapy, chemotherapy, etc.) regardless of the extent of liver disease. If palliative steps are also required, tumor ablation or embolization may be used in simple and complex liver disease. Surgery (of a debulking nature) may be undertaken for selected candidates. Embolization may be used in diffuse disease if palliation is needed. LM = Liver metastasis; RFA = radiofrequency ablation; LITT = laser-induced thermotherapy; TACE = trans-catheter arterial chemoembolization; TAE = trans-catheter arterial embolization. See 'Differential Indication'.

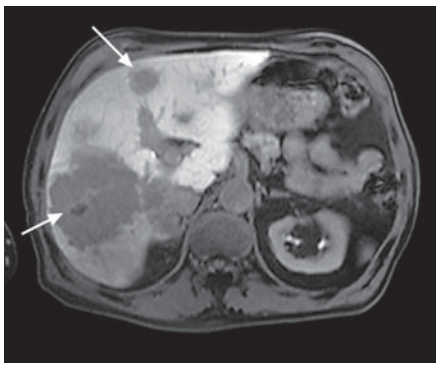

Fig. 3. MRT scan showing a large metastasis in the right lobe and a smaller satellite on the left side in segments III/IV (type B). This pattern can be approached by a sequential or a combined surgical approach (see text and figure 1).

Diagnostic Work-Up

The initial diagnostic approach in patients with liver metastases includes histological examination of the metastases, which is always required prior to planning therapeutic decisions. Cytology may be considered acceptable when histology is not possible.

Further investigations are also required: (a) general markers and detailed histological appreciation; (b) to assess the primary tumor and the extent of extrahepatic spread, and (c) for evaluating the above-mentioned patterns of hepatic infiltration.

(a) *For known primary tumors:* Chromogranin A and synaptophysin; for multiple endocrine neoplasia (MEN) patients, the primary-specific markers (e.g. gastrin, insulin, PP, etc.) [1–6]. *For unknown primary tumors:* Chro-

Downloaded from http://karger.com/nen/article-pdf/87/1/47/3228190/000111037.pdf by Universitätsbibliothek Bern user on 19 September 2023

Table 1. Results of surgical resection therapy in NET liver metastases

Author	Year	Patients	Perioperative mortality, %	Symptom control, %	Survival
Que [51]	1995	74	1.6	90	74% at 4 years
Dousset [53]	1996	17	5.9	88	46% at 4 years
Ahlman [54]	1996	14	0	100	100% at 5 years
Chen [36]	1998	15	0	–	73% at 5 years
Chamberlain [34]	2000	34	0	90	76% at 5 years
Grazi [55]	2000	19	0	–	92% at 4 years
Pascher [56]	2000	25	0	–	76% at 5 years
Jaeck [45]	2001	13	0	–	91% at 3 years
Nave [57]	2001	31	0	–	47% at 5 years
Sarmiento [32]	2003	170	0	96	61% at 5 years
Elias [58]	2003	47	5	–	71% at 5 years

mogranin A, synaptophysin and markers characteristic of specific primary sites (TTF-1-bronchial, CDX2-gastrointestinal, serotonin-midgut, PP-foregut, etc.). The assessment of the mitotic index and Ki-67 should also be performed [14].

(b) Tumor staging in poorly-differentiated tumors should include a chest-abdomen-pelvis computer tomography (CT) and somatostatin receptor scintigraphy (SRS). In well-differentiated tumors where the primary source is unknown, a single photon emission computer tomography (SPECT)-SRS and triphasic CT of the chest, abdomen and pelvis (CT/SPECT) should be performed and, if available, a CT with positron emission tomography (PET) using ^{68}Ga-somatostatin analogue. Investigation of the large bowel may be useful, either by means of a colonoscopy plus ileoscopy or by means of a colon CT with a neutral enema. F-DOPA PET is a promising diagnostic tool, however it is still investigational, and therefore its use in the standard work-up may not be suggested.

(c) If the CT study is inconclusive, T_2-weighted thin-slice dynamic Gd-enhanced magnetic resonance imaging (MRI), and, if available, a contrast-enhanced ultrasonography should be performed.

The minimal biochemical work-up for metastases from endocrine tumors includes circulating chromogranin A and urinary 5-HIAA evaluation. Additional assessment of insulin, C-peptide, gastrin, PP, VIP, glucagons family peptides, calcitonin and somatostatin should be useful depending on the tumor functional status, clinical symptoms, and histological features and has been dealt with elsewhere [2–6].

Minimal Consensus Statements – Clinical Presentation and Diagnosis

Histological examination (with Ki-67 and mitotic index determination) of the metastasis is essential for planning the course of treatment. Biochemistry with chromogranin A and synaptophysin, or primary specific markers depending on the functional status should be assessed. Tumor staging in differentiated tumors requires a chest-abdomen-pelvis CT and SRS. In well-differentiated tumors, a CT/SPECT or CT/PET may be useful for staging. Resectability may be evaluated by CT and/or MR imaging.

Surgery

Resection

A prerequisite prior to undergoing surgery in patients with liver metastases is the assurance that they are in fact well-differentiated lesions. Surgery is generally proposed to all patients with operable well-differentiated metastases from digestive NETs regardless of the site of origin although resection of metastases with hindgut origin is rare. The benefits of surgical resection of liver metastases have been demonstrated in terms of overall survival and quality of life. Complete resection (R0/R1) for both mid- and hindgut tumors is associated with better long-term survival in all series [32–36], survival rates of 60–80% at 5 years may be achieved (table 1). In comparison, historical data demonstrate a survival rate of only 30% in patients whose liver metastases are not resected [37–39]. Resection is also associated with a low mortality rate (0–5%) and an acceptable morbidity (close to 30%). It can also be beneficial in alleviation of symptoms: in a study of 170 patients, 95% of patients with symptoms at the time of

Downloaded from http://karger.com/nen/article-pdf/87/1/47/3228190/000111037.pdf by Universitätsbibliothek Bern user on 19 September 2023

surgery testified to improvement afterward [32]. The most significant factor after resection is the high rate of recurrence after a median time of 16–20 months and close to 50–60% will have recurrent disease at 5 years. Recurrence can be either intrahepatic, extrahepatic or both intra- and extrahepatic. Recurrence depends mainly on the initial completeness of liver resection and requires qualified pre- and intraoperative assessment of small liver metastases.

The minimal criteria required for liver surgery with 'curative intent' are: (1) resectable well-differentiated liver disease with acceptable morbidity and <5% mortality; (2) absence of right heart insufficiency; (3) absence of extra-abdominal metastases (previously assessed by CT scan and SRS), and (4) absence of diffuse peritoneal carcinomatosis. The primary tumor is usually also deemed resectable (or has been resected previously). The presence of local recurrence including abdominal lymph node involvement is not an absolute contraindication for surgery if the removal of both liver metastases and lymph nodes and/or the recurrence site(s) is planned. If heart surgery is also required, it should be undertaken 3 months prior to liver surgery due to the need for anticoagulants after valvular replacement [40].

The type of surgical resection is related to the patient's general condition, the number and location of liver metastases, the complexity of the liver resection, and the estimation of the future remnant liver parenchyma volume. In this regard, specialized surgery can safely remove 65–70% of the whole liver volume (in patients with non-injured liver parenchyma) if inflow, outflow, and the biliary tree of the remnant liver are preserved [41, 42]. In all cases in which the patients have carcinoid syndrome, specific perioperative treatments with somatostatin analogues are indicated to prevent intra- and postoperative carcinoid crisis [43, 44].

The effectiveness of the resection of unilobar and bilobar liver metastases depends on the operative techniques employed as well as the competence of the hepatobiliary surgeon. Intraoperative ultrasonography is essential in defining the extent of any known lesions and to detect smaller lesions occulted at preoperative diagnosis. The presence and extent of steatosis must also be assessed in order to correctly estimate the amount of liver that may be removed without compromising liver function. Using segmental anatomy as a guide, liver resection is undertaken with or without the use of the Pringle maneuver (clamping of the hepatoduodenal ligament). Ultrasonic and water-jet dissection methods have proven effective in the resection of liver parenchyma along anatomical planes.

The presence of bilobar liver metastases (the complex pattern of infiltration, example in figure 3) poses the challenge of achieving adequate tumor resection while maintaining sufficient liver function. Depending upon the size and number of tumors, as well as the condition of the remaining tumor-free tissue, three different approaches may be employed:

(1) The first method involves the resection of the metastases in the left lobe, followed by the percutaneous embolization of the right portal vein (RPVE). Alternatively, the right portal vein can be ligated (RPVL) at the time of the first surgical intervention (e.g. when removing the primary tumor). As a result of embolization, or ligation, the right lobe atrophies and functional hypertrophy of the remaining left lobe occurs. Within 6 weeks the function of the left lobe has typically regenerated (usually assessed by volumetry) to such an extent that a right hepatectomy may be safely undertaken [45].

(2) The second method incorporates both surgical resection and the use of locoablative therapy. Metastases <3 cm can be effectively treated with ablative techniques while concurrent larger tumors that are also present may be surgically resected.

(3) The third approach entails repeated hepatectomies, which have been shown to carry similar mortality and morbidity risks as the initial hepatectomy [45–47].

The timing of surgical procedures may be adjusted depending upon whether the metastases are synchronous or metachronous. In synchronous disease, liver metastases may be resected at the same time as the primary tumor with little additional risk if the metastases are unilobar [33, 35]. However, if major or complex liver resection is required, two-stage surgery is preferable in order to reduce the operative risk. In such a case, the primary tumor is removed first, together with left liver metastases and lymph nodes. In a second step, 8–9 months afterwards, all remaining right liver metastases are removed [45, 48, 49]. For irresectable liver metastases, the resection of the primary tumor may be recommended to avoid local complications such as intestinal occlusion, mesenteric retraction, and hemorrhage. Thereafter, focus can be directed to the treatment of the liver disease. If the primary tumor can be removed and the liver metastases prove irresectable, a cholecystectomy is recommended to prevent ischemic complications of the gallbladder subsequent to chemoembolization and possible further formation of gallstones during somatostatin analogue therapy [33].

For metachronous liver metastases, a one-step procedure can be recommended as a low-risk approach to unilobar disease (<30% morbidity). For bilobar or diffuse

Downloaded from http://karger.com/nen/article-pdf/87/1/47/3228190/000111037.pdf by Universitätsbibliothek Bern user on 19 September 2023

liver metastases, a sequential approach including preoperative portal embolization, percutaneous treatments or intra-arterial chemoembolization may be adopted.

Incomplete debulking surgery (R2) has limited indications, yet it can improve the quality-of-life in selected patients for whom medical treatment has failed. This may apply to several digestive NETs but especially to functioning tumors. However, in order to be efficient, the removal of at least 90% of the tumor volume is required [33, 36, 50, 51]. Even if liver resection with curative intent is seen as first-line treatment, as is often proposed in young patients with low operative risk, it should be part of a predefined multidisciplinary strategy. In selected patients, it can be proposed after down-staging of liver disease in a predefined multidisciplinary strategy. Of patients with functional midgut tumors, 90% attest to an improvement of their symptoms after surgery [32, 36] with a median duration of 19.3–45.5 months [36].

Foregut Origin

Both curative and palliative surgery is indicated for patients with liver metastases of foregut origin. Complete resection should be the aim in curative surgery in both functioning and non-functioning foregut tumors. However, surgery should only be undertaken if at least 90% of the tumor mass can be successfully removed [33, 36, 51]. Palliative resection of foregut tumor metastases has become more widely accepted and the indications have broadened. Patients whose hormonal symptoms do not respond to medical therapy should be considered for palliative debulking. In all cases, extrahepatic spread should be ruled out and sufficient hepatic reserve substantiated prior to surgery.

Midgut Origin

Liver metastases of midgut origin that are causing functional symptoms can be treated with debulking procedures. 90% of the patients attest to an improvement of their symptoms after surgery [32, 36] with a median duration of 19.3–45.5 months [36]. For palliative hepatic surgery, the mortality should not be higher than 3–5% and morbidity not higher than 30% and the metastatic spread should be confined to the liver [52].

Hindgut Origin

Metastases to the liver from hindgut tumors are rarely functional in nature, and extrahepatic metastases are frequent. Consequently, there is rarely an indication for surgery.

Minimal Consensus Statements – Surgery

Surgical resection remains the gold standard in the treatment of liver metastases, achieving a survival rate of 60–80% at 5 years with low mortality (0–5%) and acceptable morbidity (close to 30%). The minimal requirements for resection with 'curative intent' are the following: (1) resectable well-differentiated liver disease with acceptable morbidity and <5% mortality, (2) absence of right heart insufficiency, (3) absence of extra-abdominal metastases, and (4) absence of diffuse peritoneal carcinomatosis. In planning the operation, care should be taken to assess the amount and quality of the postoperative remnant liver parenchyma. In both synchronous and metachronous tumors, one- and two-step procedures may be undertaken, depending upon whether the liver disease is unilobar or complex. Debulking resections can exceptionally be justified in palliative situations; however, removal of at least 90% of the tumor volume is necessary. If the primary tumor is still present, it should be removed at this time as well.

Liver Transplantation

Liver transplantation with total tumor hepatectomy in patients with liver metastases of NETs has proved effective for selected patients for whom standard surgical and medical therapies have failed. While transplantation can be undertaken with intent to cure in carefully chosen candidates, it can also achieve significant palliative results in patients suffering from life-threatening hormonal disturbances. The potential benefit of liver transplantation in patients with malignant NETs needs to be weighed, however, against issues of perioperative morbidity and the ethical distribution of donor organs.

With the exception of hepatocellular carcinoma, NET liver metastases are almost the only indication that justifies liver transplantation as a viable therapy in malignant disease [59, 60]. In spite of this, skepticism remains and many institutions are hesitant to allocate scarce donor organs to patients with metastatic NETs. Recommended indications for liver transplantation therefore restrict the procedure to those patients with widespread liver disease. Likewise, young patients with pain or hormonal symptoms refractory to surgical and medical therapy may be considered for liver transplant [61, 62]. In either case, the exclusion of extrahepatic metastases needs to be guaranteed prior to transplantation [56]. The exclusion of extrahepatic metastases can be accomplished through SRS, and CT, as well as diagnostic laparoscopy.

Although results are functionally good [63], current studies show that though transplants provide initial palliative effect, the long-term cure rates are still very low

Downloaded from http://karger.com/nen/article-pdf/87/1/47/3228190/000111037.pdf by Universitätsbibliothek Bern user on 19 September 2023

Table 2. Single-center studies of patients with liver transplantation for metastatic neuroendocrine tumors

Author	Year	Patients	Median follow-up, months	1-Year survival, %	5-Year survival, %	Disease-free survivors at 5 years
Van Vilsteren [70]	2007	19	22	88	–	2
Olausson [71]	2007	10	67	95	90	2
Frilling [63]	2006	15	61	78	67	0
Florman [64]	2003	11	30		36	1
Rosenau [66]	2002	19	38	89	80	3
Ringe [72]	2001	5	22	80	–	0
Coppa [73]	2001	9	39	100	70	–
Pascher [56]	2000	4	42	100	50	1
Frilling [74]	1998	4	54	50	50	0
Dousset [53]	1996	9	29	33	33	0
Anthuber [75]	1996	4	11	25	0	0

(table 2). In a recent study of 11 patients who underwent liver transplant, a 1-year survival rate of 73% and a 5-year survival rate of 36% were demonstrated [64]. Yet only 1 of the 3 patients who survived 5 years was tumor-free. In another review of 103 patients, a 2-year survival rate of 60% and a 5-year survival rate of 47% in transplanted patients were shown. The number of tumor-free patients at 5 years was not more than 24%, though this figure does not take into account several patients for whom the timing of their tumor recurrence could not be reconstructed [65]. In yet another single-institution review of liver transplants, 19 patients had 5- and 10-year survival rates of 80 and 50%, respectively. Three of the 19 patients were still tumor-free 8 years after transplantation. Twelve of the 19 were diagnosed with recurrent tumors within 48 months of the transplantation [66]. The results of a very recent Swedish series were slightly more favorable [71].

No more than 150 cases involving liver transplants in NET patients are found in published studies, of which the vast majority is retrospective in nature with low case counts. Therefore, judgments regarding transplant therapy remain based on limited evidence. Nonetheless, the very small percentage of tumor-free patients after 5 years reinforces the impression that liver transplant is undertaken with palliation as the realistic goal. Liver transplantation with intent to cure, while possible, remains the exception.

The recommended indications for liver transplantation can be coupled with favorable prognostic markers. It has been proposed that a patient age of less than 50 years is of favorable prognostic value. The importance of high postoperative mortality in patients with extended abdominal surgery in addition to the liver transplant has also been noted. Patients who underwent Whipple's operation had a 5-year survival rate of only 31% [65]. The importance of well-differentiated tumors is underlined by better survival when Ki-67 is <5% (probably reflecting G1 rather than G2 histology) [67]. Patients with tumors that stain for E-cadherin in addition to having a low Ki-67 expression have an increased survival (median 90 months) compared to those with high marker expression (median survival of 46 months) [66]. Favorable results can best be expected when the tumor does not make up more than 40% of the extracted liver [68]. For those who have a long time interval between operations, a staging laparotomy to aid in the detection of possible extrahepatic disease has been recommended [69].

Minimal Consensus Statements – Liver Transplantation

In patients with diffuse unresectable liver metastases or who suffer from life-threatening hormonal disturbances refractory to medical therapy, liver transplantation may be a possible therapy option for the special, carefully selected candidate. Because of the slow-growing nature of NETs and their tendency to metastasize only to the liver, NETs remain one of the few indications for liver transplantation in metastatic disease, particularly if living-related donation is feasible. Patients less than 50 years old who are free of extrahepatic tumor and have low expression of Ki-67 and E-cadherin are those who are most likely to benefit from liver transplantation. However, a long-term cure from the disease by transplantation will be an exceptional event even in this highly selected subgroup.

Downloaded from http://karger.com/nen/article-pdf/87/1/47/3228190/000111037.pdf by Universitätsbibliothek Bern user on 19 September 2023

Local Ablative Techniques

Radiofrequency Ablation

The use of radiofrequency ablation (RFA) has been shown to be effective in both relieving the symptoms of NET liver metastases and in achieving local control of the metastases. RFA has become the preferred local-ablative therapy in most centers, achieving reduced tumor mass in functioning and non-functioning metastases. Both percutaneous and laparoscopic applications of RFA are available, depending upon the location and extent of metastatic spread [76, 77].

The number and scope of studies investigating RFA treatment of NET liver metastases are still limited. In the largest study to date, 34 patients with a total of 234 NET metastases were treated with RFA [78]. 80% of the patients testified to complete or significant relief from their symptoms, lasting for an average of 10 months. 41% of the treated patients showed no evidence of progression. In another study of 25 patients, 69% of the patients reported relief of tumor-related symptoms [79]. As a subgroup from these 25 patients, 19 patients were followed up with imaging diagnostic, of whom 74% exhibited tumor control.

Tumor size poses a significant limit on the effectiveness of RFA. Though ablation may be used repeatedly within the same metastasis [74], it becomes increasingly difficult to fully eradicate with certainty tumors >3 cm in diameter [80], and a tumor >5 cm in diameter is considered to be unsuitable for RFA. RFA is problematic to employ near vital structures or at the surface of the liver in close proximity to the stomach, the colon or the diaphragm. When situated next to larger vessels there may be a cooling effect that may explain the high rate of recurrences.

Though experience with RFA is limited in cases of NET liver metastases, there is ample experience and data in cases of colorectal metastases and hepatocellular carcinoma. RFA has been shown to be a relatively low-risk procedure for treating liver tumors [57]. In a recent study of 608 patients with multiple tumor types treated with RFA, the mortality rate was 0.5%. Patients undergoing RFA at surgery suffered from a higher rate of early complications (8.6%) than those who underwent percutaneous RFA (4.4%). In 2.4% of the patients, later complications were reported [81].

While the safety of RFA makes it an attractive method of treatment, the rate of tumor recurrence after therapy demonstrates the limits of its effectiveness as a single therapy. A recent study compared the recurrence rate of 418 patients treated for colorectal liver metastases. 190 underwent resection alone, 101 patients underwent resection plus RFA, 57 were treated only with RFA, and 70 were treated only with chemotherapy. Therapy with RFA alone resulted in the highest recurrence rate at 84%, compared to 64% recurrence after RFA plus resection. Patients who only underwent resection had a 52% recurrence rate. The recurrence of liver-only tumor was four times higher after RFA treatment alone (44%) than after resection alone (11%). The overall survival was highest after resection alone (58%), and the 4-year survival rates after resection, resection plus RFA, and RFA alone were 65, 36, and 22%, respectively [82]. In another study of 180 patients with solitary colorectal liver metastasis, 150 underwent resection and 30 underwent RFA. The local recurrence rate after resection was 5%, compared to 37% after RFA therapy [83]. These and similar results from other studies show that surgical resection remains the standard therapy for colorectal liver metastases [84, 85].

Though resection remains the therapy of choice in limited tumor disease, RFA can effectively supplement surgical resection. This is particularly the case in patients whose metastases are otherwise irresectable or difficult to access, the combination of resection and RFA provides the opportunity to achieve complete tumor removal [86–88]. The synergistic and complementary effect of RFA, in combination with surgery, depends on the size and topography of the tumor. Only tumors <3 cm should be treated with RFA in combination with resection [89], and the number of tumors should be limited. In one series, the rate of recurrence began to increase with the treatment of four or more tumors [86]. The addition of RFA to resection is generally well tolerated (complication rates reported at 19.8%) with a median actuarial survival of 44.5 months [84].

Laser-Induced Thermotherapy

Laser-induced thermotherapy (LITT) has been used to eradicate liver metastases from colorectal tumors and, to a limited extent, endocrine tumors. In studies of patients with liver metastases of colorectal origin, LITT produced a survival rate of 3.8 years after treatment and 4.4 years after diagnosis of the metastasis [90]. While the range of effect can be more precisely controlled than RFA methods, the heat that is produced from the laser limits LITT application to tumors located at a distance to vital structures [91]. The notable disadvantages are in its ineffectiveness in treating large tumors; though with multiple fibers it has been shown that tumors up to 7 cm in diameter can be successfully treated [92]. Recent studies have also shown that treatment of large tumors with re-

Downloaded from http://karger.com/nen/article-pdf/87/1/47/3228190/000111037.pdf by Universitätsbibliothek Bern user on 19 September 2023

peated transarterial chemoembolization (TACE) can down-size liver metastases to such a degree that LITT treatment can be successfully performed [93]. Due to the fact that LITT is MR imaging-guided, its widespread use is limited and it has been abandoned in favor of RFA in most centers.

Cryotherapy

Cryotherapy has been used since the early 1960s to treat liver metastases by freezing and thawing tumor tissue. Its use today, however, has been eclipsed by the effectiveness of RFA in the therapy of NET liver metastases. Although it still plays a role in some centers in treating tumors >5 cm in diameter that cannot be sufficiently treated with RFA, it is most often used in combination with RFA in order to limit complications such as coagulopathy [75].

Ethanol Injection

Percutaneous ethanol injection (PEI) offers an alternative treatment method for very small metastases or when the tumors are located close to vital structures or vessels [94]. Though experience with ethanol injection in NET liver metastases is limited [75]. PEI has been shown to be effective in dealing with primary hepatic tumors rather than with liver metastases [78, 95] and has been largely abandoned since the advent of RFA.

Brachytherapy

CT-guided brachytherapy for liver metastases has promise in some experienced centers as a means of treating liver metastases that are too large or poorly situated to be treated with RFA. Application of brachytherapy is not limited by vital structures, since it neither damages bile ducts and vessels, nor does it lose efficacy due to vascular cooling effects. Though more experience with brachytherapy is required, it has already been demonstrated that tumors up to 10 cm in diameter can be successfully treated [96].

Minimal Consensus Statements – Ablative Techniques

Ablative techniques such as RFA can be used effectively as anti-tumor treatment and in relieving symptoms in patients with NET liver metastases, either as a sole therapy or in combination with surgery. While surgery remains the therapy of choice in limited tumor disease, RFA may be employed for palliation in order to avoid a major surgical procedure and it can also effectively supplement a surgical resection. In patients with tumors >5 cm in diameter or near vital structures, RFA or other ablative techniques are not the most suitable single therapy.

Chemoembolization

Selective hepatic trans-catheter arterial embolization (TAE) or chemoembolization (TACE) with hepatic artery occlusion can be employed in the treatment of liver metastases from all types of well-differentiated digestive NETs. More data are available using this method for liver metastases of midgut origin than in foregut or hindgut tumors. Selective embolization of peripheral arteries induces temporary, but complete ischemia. The procedure can be performed repeatedly. Median survival in patients treated with TAE is between 59 and 64 months after the occurrence of the first symptoms of the carcinoid syndrome [97]. In two recent series using TACE, overall survival rates at 5 years were 83 and 50%, respectively [96, 97]. For TACE, the cytotoxic agent most often used is doxorubicin [98–104] or streptozotocin. TACE or TAE alone can be used if surgery is not feasible as an antiproliferative treatment modality. TACE can be effective in both symptom control and as an antiproliferative treatment modality. Complete or partial responses for symptoms, tumor markers and imaging occurred in 73–100, 57–91 and 33–35% of the patients, respectively [96–102]. The duration of symptomatic response and mean survival time were 14–22 and 24–32 months, respectively [96–102].

Whether survival is prolonged following TACE has yet to be demonstrated. Mortality (0–3.3%) of the procedure is low in experienced hands [96–102]. As significant morbidity may result from this procedure, TACE should be performed only in experienced centers. Minor side effects such as nausea and vomiting (50–70%), right upper quadrant pain (50–60%), fever (30–60%), and elevation of transaminases (100%) are common [105]. Adequate hydration and analgesics are required and antibiotics are employed for 48 h [103]. The postembolization syndrome is often observed. Major observable side effects include: gallbladder necrosis; hepatorenal syndrome; pancreatitis; liver abscess, and formation of aneurysms. The procedure is contraindicated in patients with complete portal vein thrombosis and hepatic insufficiency [50, 96–102, 106]. The following points remain unclear: whether TACE is preferable to TAE alone; timing of sequential (chemo)embolizations, and choice of cytotoxic agents (e.g. doxorubicin vs. streptozotocin; although a recent retrospective study found streptozotocin to be more efficacious [97]). The only study that compared the results of hepatic resection with TACE demonstrated prolonged survival in the former. However, selection bias may have influenced the outcome towards hepatic surgery [36].

Downloaded from http://karger.com/nen/article-pdf/87/1/47/3228190/000111037.pdf by Universitätsbibliothek Bern user on 19 September 2023

Minimal Consensus Statements – Chemoembolization

Selective hepatic trans-catheter arterial embolization (TAE) or chemoembolization (TACE) may be used to treat liver metastases in patients where surgery is not feasible regardless of the origin of the primary tumor. These modalities are effective in the control of symptoms and tumor growth and result in significant decrease in biochemical markers with objective tumor responses in about half of the patients. No current evidence exists that TACE is superior to TAE. The cytotoxics used include either doxorubicin or streptozotocin (the latter should be used under general anesthesia due to pain induced at injection) in a mixture with lipiodol. Because of its potential morbidity, TAE or TACE should be performed in experienced centers; a common side effect is postembolization syndrome. Major side effects are rare and the procedure is contraindicated in case of complete portal vein thrombosis and hepatic insufficiency. In patients in whom liver transplantation may subsequently be considered, multiple TAE or TACE can induce endoarteritis rendering the vascular reconstruction at transplantation more difficult due to arterial thrombosis.

Medical Therapy

Symptomatic Treatment

As is the case in all functional primary NETs, careful control of symptoms in relation to hormonal hypersecretion should be ensured prior to specific anti-tumoral treatment measures (surgical or locoregional) in patients with liver metastases. In many instances, somatostatin analogues are efficacious (e.g. liver metastases from midgut carcinoids with carcinoid syndrome or rare pancreatic functional NETs such as VIPoma). Specific details related to use of these analogues have been dealt with in a consensus manner elsewhere [43]. Preventative somatostatin analogue therapy (delivered as either a s.c. bolus or an i.v. perfusion) is usually effective [102]. Interferon may also be considered for symptom control in some patients. Other specific related therapies are required according to the primary [4–6].

Minimal Consensus Statements – Symptomatic Treatment

Symptoms from hormonal hypersecretion are frequent in functional tumors with liver metastases. Control of these symptoms is urgent and somatostatin analogues (with or without interferon) are often effective. Locoregional therapies may be required to achieve symptomatic relief. Prophylaxis against carcinoid crisis should be performed prior to surgical or locoregional interventions using adequate doses of somatostatin analogues (usually with bolus subcutaneous therapy or intravenously).

Antiproliferative Treatment

Biotherapy

The anti-tumor efficacy of somatostatin analogues and/or interferon, according to recent data, appears weak with objective tumor responses of <10% [107–109]; however, disease stabilization of up to 40% has been reported and these agents may be of value in subgroups of patients with slowly-progressive well-differentiated NET expressing sst_2 receptor subtypes (i.e., a positive SRS) [105, 107]. In patients with gastric carcinoids, somatostatin analogues have been shown to have antiproliferative effects in animals and in man [6], however, data is not available in cases of liver metastases. In metastatic poorly-differentiated tumors, regardless of the site of origin, somatostatin analogue treatment or interferon therapy is not recommended.

Systemic Chemotherapy

Systemic cytotoxics are indicated in patients with inoperable progressive liver metastases from well-differentiated NET of foregut origin using combinations of streptozotocin and 5-FU and/or doxorubicin with objective response rates in the order of 35% [29, 110]. This is considerably lower than the 69% reported by Moertel et al. [111] in 1992. Chemotherapy in the adjuvant setting has not to date been explored. Experience is accumulating concerning peptide receptor radionuclide therapy (PRRT) in the treatment of digestive NETs with liver metastases where its efficacy in both advanced pancreatic and midgut tumors have been demonstrated, ^{90}Y-DOTATOC and ^{177}Lu-DOTATOC showing particular promise [112–114]. Results with systemic chemotherapy are poor in patients with well-differentiated metastatic midgut NETs with response rates below 10% [1] and for such patients current cytotoxic regimens cannot be recommended. Limited data are available in relation to results of systemic chemotherapy in patients with liver metastases from hindgut tumors. Such treatment can be proposed in progressive disease although the choice of agents needs to be defined in clinical trials. In cases of liver metastases involving poorly-differentiated NETs, regardless of the site of the primary tumor, combination chemotherapy using cisplatin/etoposide (Moertel regimen) [115] is recommended early (provided that the patient has adequate organ function and performance status). Encouraging results using 5-FU (either i.v. or oral) combined with oxaliplatine may be an option in the future [116, 117].

Downloaded from http://karger.com/nen/article-pdf/87/1/47/3228190/000111037.pdf by Universitätsbibliothek Bern user on 19 September 2023

Minimal Consensus Statements – Medical Antiproliferative Therapy

Somatostatin analogues and/or interferon have weak antiproliferative effects. Systemic chemotherapy using combinations of streptozotocin and doxorubicin and 5-fluorouracil should be considered in patients with inoperable well-differentiated progressive foregut NET with liver metastases. Cytotoxics are not efficacious for liver metastases of midgut tumors. Combinations of etoposide and cisplatin are indicated in advanced/metastatic poorly-differentiated NET regardless of the origin of the primary. PRRT may be used to treat metastases of foregut and midgut NET, with ^{90}Y-DOTATOC and ^{177}Lu-DOTATOC showing particular promise.

Differential Indication

There is a variety of approaches and a multitude of techniques that can be employed in the treatment of liver metastases. The difficulty, however, is to select the most appropriate and to determine the specific algorithm according to patient needs. There are currently no randomized studies to aid the decision-making process and the recommendations do not exceed the evidence level of expert opinion. Decisions to use a particular technique are often upon local expertise available. Ideally, a multidisciplinary conference of oncologists, radiologists, internists, and surgeons is available where the case can be presented and the therapy options discussed. The presence of a surgeon with personal experience in hepatobiliary surgery and liver transplantation is critical for properly assessing the tumor resectability and operative risk.

The application of algorithms in the multidisciplinary setting should ensure the best individualized option for patients.

As presented in figure 1, well-differentiated liver metastases with no evidence of extrahepatic spread are treated initially with surgical resection, if possible:

(A) In the event that a liver metastasis can be removed using an anatomical liver resection, the surgical approach should be favored over ablative methods. Randomized studies are required prior to advocating ablative strategies over surgery and indeed by analogy, the former have proven less efficacious compared to traditional surgery in treating liver metastases in colorectal carcinoma [80–83].

(B) If metastases are bilobar or complex, the surgical approach is still to be favored, either in one step or two. The one-step method combines major surgical resection with simultaneous RFA treatment. The two-step approach combines minor surgical resection of the left lobe with RFA, RPVE, or RPVL, followed by surgical resection of the right lobe. If the primary tumor is still present, it should be removed at this time as well. Patients with complex metastases, for whom surgery would not be well tolerated, can be treated with TACE to control tumor growth.

(C) Diffuse metastases throughout the liver pose an indication for systemic therapy, since the benefit of surgical resection in such cases is yet to be demonstrated. For highly selected patients in the latter group, liver transplantation can provide a therapy option.

In case of extrahepatic metastases (fig. 2), systemic treatment is preferable to surgical therapy. In such cases, the liver metastases can serve as a good marker to assess the efficacy of the systemic therapy. A role for palliative removal of liver metastases, however, is justified and can offer patients significant relief of symptoms – especially for hormone-secreting foregut and midgut tumors. The palliative effect of RFA treatment alone must be judged on an individual basis, with larger tumors being more effectively treated through resection. Palliative debulking, in this sense, can also be indicated in certain circumstances.

Minimal Consensus Statements – Differential Indication

If metastases are limited to the liver, then surgical resection is preferable to ablative therapies. Even complex patterns of metastases can often be eliminated through a combination of resection and ablation, as well as sequential intervention. Should extrahepatic metastases be present as well, interventional therapies can have significant palliative value, especially for hormone-secreting tumors.

List of Participants

List of Participants of the 'Consensus Conference on the ENETS Guidelines for the Diagnosis and Treatment of Neuroendocrine Gastrointestinal Tumors, Part 2: Midgut and Hindgut Tumors' Held in Frascati (Rome, Italy), November 1–4, 2006

Hakan Ahlman, Institute for Surgical Sciences, Department of Surgery, Sahlgrenska sjukhuset, SE–41345 Gothenborg (Sweden); Rudolf Arnold, Wittelsbacherstr. 6, DE–80469 Munich (Germany); Christoph Auernhammer, Medizinische Klinik II, Grosshadern Klinikum der Ludwig-Maximilians-Universität München, Marchioninistr. 15, DE–81377 Munich (Germany); Martyn Caplin, Royal Free Hospital London, Centre for Gastroenterology, London NW3 2QG (UK); Emanuel Christ, Endokrinologie für Erwachsene, Inselspital, Freiburgstrasse, CH–3010 Bern (Switzerland); Anne Couvelard, Hôpital Beaujon, Service de Gastroentérologie, Boulevard Général Leclerc 100, FR–92110 Clichy (France); Wouter de Herder, Department of Internal Medicine, Section of Endocrinology, Erasmus MC, Dr. Molewaterplein

Downloaded from http://karger.com/nen/article-pdf/87/1/47/3228190/000111037.pdf by Universitätsbibliothek Bern user on 19 September 2023

40, NL–3015 GD Rotterdam (The Netherlands); Barbro Eriksson, Medical Department, Endocrine Unit, University Hospital, SE–75185 Uppsala (Sweden); Diego Ferone, Departments of Internal Medicine and Endocrinological and Metabolic Sciences, University of Genoa, IT–16132 Genoa (Italy); Peter Goretzki, Städtisches Klinikum Neuss, Lukaskrankenhaus, Chirurgische Klinik I, Preussenstr. 84, DE–41456 Neuss (Germany); David Gross, Department of Endocrinology & Metabolism, Hadassah University Hospital, IL–91120 Jerusalem (Israel); Rudolf Hyrdel, University Hospital Martin, II. Internal Medical Department, Kollarova 2 (Street), SK–03659 Martin (Slovakia); Robert Jensen, National Institutes of Health, Cell Biology Section, Building 10, Room 9C-193, Bethesda, Md. (USA); Gregory Kaltsas, G. Genimatas Hospital, Mesogion Ave., GR–10443 Athens (Greece); Fahrettin Keleştimur, Erciyes University Medical School, Department of Endocrinology and Metabolism, TR–38039 Kayseri (Turkey); Günter Klöppel, Institut für Allgemeine Pathologie und Pathologische Anatomie, Universität Kiel, Michaelisstr. 11, DE–24105 Kiel (Germany); Wolfram Knapp, MHH, Klinik für Nuklearmedizin, Carl-Neuberg-Str. 1, DE–30625 Hannover (Germany); Ulrich-Peter Knigge, Department of Surgery, C2122, Rigshospitalet Blegdamsvej, DK–2100 Copenhagen (Denmark); Paul Komminoth, Institute for Pathology, Kantonsspital, CH–5404 Baden (Switzerland); Meike Körner, Institute of Pathology, University of Bern, Murtenstr. 31, Bern (Switzerland); Beata Kos-Kudła, Slaska Akademia Medyczna, Klinika Endokrynologii, ul. 3 Maja 13/15, PL–41800 Zabrze (Poland); Eric Krenning, Erasmus MC, Dr. Molewaterplein 40, NL–3015 GD Rotterdam (The Netherlands); Matthew Kulke, Dana-Farber Cancer Institute, 44 Binney Street, Dana 1220, Boston, MA 02115 (USA); Larry Kvols, H. Lee Moffitt Cancer Center/University of South Florida, Magnolia Drive 12902, Tampa, FL 33612 (USA); Riccardo Manfredi, Istituto di Radiologia, Policlinco GB Rossi, Piazzale LA Scuro, IT–37134 Verona (Italy); Anne Marie McNicol, Division of Cancer Sciences and Molecular Pathology, Pathology Department, Royal Infirmary, Castle Street, Glasgow G4 0SF (UK); Bruno Niederle, Universität Wien, Abteilung Chirurgie, Allgemeines Krankenhaus Wien, Währinger Gürtel 18–20, Ebene 3L, AT–1090 Vienna (Austria); Ola Nilsson, Department of Pathology, Sahlgrenska sjukhuset, SE–41345 Gothenborg (Sweden); Kjell Öberg, Department of Internal Medicine, Endocrine Unit, University Hospital, SE–75185 Uppsala (Sweden); Juan O'Connor, Instituto Alexander Fleming, Crámer 1180, C1426ANZ, Buenos Aires (Argentina); Ulrich-Frank Pape, Charité Universitätsmedizin, Department of Internal Medicine, Division of Hepatology and Gastroenterology, Campus Virchow Klinikum, Augustenburger Platz 1, DE–13353 Berlin (Germany); Marianne Pavel, Charité Universitätsmedizin, Department of Internal Medicine, Division of Hepatology and Gastroenterology, Campus Virchow Klinikum, Augustenburger Platz 1, DE–13353 Berlin (Germany); Ursula Plöckinger, Charité Universitätsmedizin, Campus Virchow-Klinikum, Department of Hepatology and Gastroenterology, Augustenburger Platz 1, DE–13353 Berlin (Germany); John Ramage, Department of Gastroenterology, North Hampshire Hospital, Aldermaston Rd, Basingstoke, Hants RG24 9NA (UK); Jens Ricke, Otto-von-Guericke-Universität Magdeburg, Klinik für Radiologie und Nuklearmedizin, Leipziger Str. 44, DE–29120 Magdeburg (Germany); Guido Rindi, Dipartimento di Patologia e Medicina di Laboratorio, Sezione di Anatomia Patologica, Università degli Studi, via A. Gramsci, 14, IT–43100 Parma (Italy); Philippe Ruszniewski, Service de Gastroentérologie, Hôpital Beaujon, 100, Boulevard Général Leclerc, FR–92110 Clichy (France); Ramon Salazar, Institut Català d'Oncologia, Av. Gran Via s/n, ES–08907 Barcelona (Spain); Jean-Yves Scoazec, Anatomie Pathologique, Hôpital Edouard-Herriot, Bâtiment 10, 3 place d'Arsonval, FR–69437 Lyon, Cedex 03 (France); Maria Isabel Sevilla Garcia, Hospital Virgen de la Victoria, C/Colonia Santa Ines s/n, ES–29010 Malaga (Spain); Anders Sundin, Uppsala University Hospital, Department of Radiology, SE–75185, Uppsala (Sweden); Marie-Pierre Vullierme, Service de Gastroentérologie, Hôpital Beaujon, 100, Boulevard Général Leclerc, FR–92110 Clichy (France); Bertram Wiedenmann, Charité Universitätsmedizin, Department of Internal Medicine, Division of Hepatology and Gastroenterology, Campus Virchow Klinikum, Augustenburger Platz 1, DE–13353 Berlin (Germany); Stefan Wildi, University Hospital of Zürich, Department of Visceral and Transplantation Surgery, CH–8091 Zürich (Switzerland).

References

1 Plöckinger U, Rindi G, Arnold R, Eriksson B, Krenning E, de Herder W, Goede A, Caplin M, Öberg M, Reubi J, Nilsson O, Delle Fave G, Ruszniewski P, Ahlman H, Wiedenmann B: Guidelines for the diagnosis and treatment of neuroendocrine gastrointestinal tumours. Neuroendocrinology 2004;80:395–424.

2 Jensen RT, Niederle B, Mitry E, Ramage JK, Steinmuller T, Lewington V, Scarpa A, Sundin A, Perren A, Gross D, O'Connor JM, Pauwels S, Kloppel G; Frascati Consensus Conference; European Neuroendocrine Tumor Society. Gastrinoma (duodenal and pancreatic). Neuroendocrinology 2006;84:173–182.

3 Ruszniewski P, Delle Fave G, Cadiot G, Komminoth P, Chung D, Kos-Kudla B, Kianmanesh R, Hochhauser D, Arnold R, Ahlman H, Pauwels S, Kwekkeboom DJ, Rindi G; Frascati Consensus Conference; European neuroendocrine Tumor Society: Well-differentiated gastric tumors/carcinomas. Neuroendocrinology. 2006;84:158–164.

4 Jensen RT, Rindi G, Arnold R, Lopes JM, Brandi ML, Bechstein WO, Christ E, Taal BG, Knigge U, Ahlman H, Kwekkeboom DJ, O'Toole D; Frascati Consensus Conference; European Neuroendocrine Tumor Society: Well-differentiated duodenal tumor/carcinoma (excluding gastrinomas). Neuroendocrinology 2006;84:165–172.

5 De Herder WW, Niederle B, Scoazec JY, Pauwels S, Kloppel G, Falconi M, Kwekkeboom DJ, Oberg K, Eriksson B, Wiedenmann B, Rindi G, O'Toole D, Ferone D; Frascati Consensus Conference; European Neuroendocrine Tumor Society: Well-differentiated pancreatic tumor/carcinoma: insulinoma. Neuroendocrinology 2006;84:183–188.

6 O'Toole D, Salazar R, Falconi M, Kaltsas G, Couvelard A, de Herder W, Hyrdel R, Nikou G, Drenning E, Vullierme M, Caplin M, Jensen R, Eriksson B: Rare functioning pancreatic endocrine tumors. Neuroendocrinology 2006;84:189–195.

Downloaded from http://karger.com/nen/article-pdf/87/1/47/3228190/000111037.pdf by Universitätsbibliothek Bern user on 19 September 2023

7 Panzuto F, Nasoni S, Falconi M, Corleto VD, Capurso G, Cassetta S, Di Fonzo M, Tornatore V, Milione M, Angeletti S, Cattaruzza MS, Ziparo V, Bordi C, Pederzoli P, Delle Fave G: Prognostic factors and survival in endocrine tumor patients: comparison between gastrointestinal and pancreatic localization. Endocr Relat Cancer 2005;12:1083–1092.
8 Madeira I, Terris B, Voss M, Denys A, Sauvanet A, Flejou JF, Vilgrain V, Belghiti J, Bernades P, Ruszniewski P: Prognostic factors in patients with endocrine tumors of the duodenopancreatic area. Gut 1998;43:422–427.
9 Tomassetti P, Campana D, Piscitelli L, Casadei R, Santini D, Nori F, Morselli-Labate AM, Pezzilli R, Corinaldesi R: Endocrine pancreatic tumors: factors correlated with survival. Ann Oncol 2005;16:1806–1810.
10 Borch K, Ahren B, Ahlman H, Falkmer S, Granerus G, Grimelius L: Gastric carcinoids: biologic behavior and prognosis after differentiated treatment in relation to type. Ann Surg 2005;242:64–73.
11 Rindi G, Luinetti O, Cornaggia M, Capella C, Solcia E: Three subtypes of gastric argyrophil carcinoid and the gastric neuroendocrine carcinoma: a clinicopathologic study. Gastroenterology 1993;104:994–1006.
12 Rindi G, Azzoni C, La Rosa S, Klersy C, Paolotti D, Rappel S, Stolte M, Capella C, Bordi C, Solcia E: ECL cell tumor and poorly differentiated endocrine carcinoma of the stomach: prognostic evaluation by pathological analysis. Gastroenterology 1999;116:532–542.
13 Modlin I, Lye K, Kidd M: Carcinoid tumors of the stomach. Surg Oncol 2003;12:153–172.
14 Rindi G, Kloppel G, Alhman H, Caplin M, Couvelard A, de Herder WW, Erikssson B, Falchetti A, Falconi M, Komminoth P, Korner M, Lopes JM, McNicol AM, Nilsson O, Perren A, Scarpa A, Scoazec JY, Wiedenmann B; and all other Frascati Consensus Conference participants; European Neuroendocrine Tumor Society (ENETS): TNM staging of foregut (neuro)endocrine tumors: a consensus proposal including a grading system. Virchows Arch 2006;449:395–401.
15 Yu F, Venzon DJ, Serrano J, Goebel SU, Doppman JL, Gibril F, Jensen RT: Prospective study of the clinical course, prognostic factors, causes of death, and survival in patients with long-standing Zollinger-Ellison syndrome. J Clin Oncol 1999;17:615–630.
16 Jensen R: Natural history of digestive endocrine tumors; in Mignon M, Colombel JF (eds): Recent Advances in Pathophysiology and Management of Inflammatory Bowel Diseases and Digestive Endocrine Tumors. Paris, Libbey Eurotext, 1999, pp 192–219.
17 Hirshberg B, Cochran C, Skarulis MC, Libutti SK, Alexander HR, Wood BJ, Chang R, Kleiner DE, Gorden P: Malignant insulinoma: spectrum of unusual clinical features. Cancer 2005;104:264–272.
18 Danforth D Jr, Gorden P, Brennan M: Metastatic insulin-secreting carcinoma of the pancreas: clinical course and the role of surgery. Surgery 1984;96:1027–1037.
19 Mignon M: Natural history of neuroendocrine enteropancreatic tumors. Digestion 2000;62(suppl 1):51–58.
20 Chu QD, Hill HC, Douglass HO Jr, Driscoll D, Smith JL, Nava HR, Gibbs JF: Predictive factors associated with long-term survival in patients with neuroendocrine tumors of the pancreas. Ann Surg Oncol 2002;9:855–862.
21 Que F, Sarmiento J, Nagorney D: Hepatic surgery for metastatic gastrointestinal neuroendocrine tumors. Cancer Control 2002;9:67–79.
22 Modlin I, Lye K, Kidd M: A five-decade analysis of 13,715 carcinoid tumors. Cancer 2003;97:934–959.
23 McDermott E, Guduric B, Brennan M: Prognostic variables in patients with gastrointestinal carcinoid tumours. Br J Surg 1994;81:1007–1009.
24 Burke A, Thomas R, Elsayed A, Sobin L: Carcinoids of the jejunum and ileum: an immunohistochemical and clinicopathologic study of 167 cases. Cancer 1997;79:1086–1093.
25 Strodel W, Talpos G, Eckhauser F, Thompson N: Surgical therapy for small-bowel carcinoid tumors. Arch Surg 1983;118:391–397.
26 MacGillivray D, Heaton R, Rushin J, Cruess D: Distant metastasis from a carcinoid tumor of the appendix less than one centimeter in size. Surgery 1992;111:466–471.
27 Moertel C, Weiland L, Nagorney D, Dockerty MB: Carcinoid tumor of the appendix: treatment and prognosis. N Engl J Med 1987;317:1699–1701.
28 Thompson GB, van Heerden JA, Martin JK Jr, Schutt AJ, Ilstrup DM, Carney JA: Carcinoid tumors of the gastrointestinal tract: presentation, management, and prognosis. Surgery 1985;98:1054–1063.
29 Kouvaraki MA, Ajani JA, Hoff P, Wolff R, Evans DB, Lozano R, Yao JC: Fluorouracil, doxorubicin, and streptozocin in the treatment of patients with locally advanced and metastatic pancreatic endocrine carcinomas. J Clin Oncol 2004;22:4762–4771.
30 Soga J: Carcinoids of the colon and ileocecal region: a statistical evaluation of 363 cases collected from the literature. J Exp Clin Cancer Res 1998;17:139–148.
31 Nilsson O, Van Cutsem E, Delle Fave G, Yao JC, Pavel ME, McNicol AM, Sevilla Garcia MI, Knapp WH, Kelestimur F, Sauvanet A, Pauwels S, Kwekkeboom DJ, Caplin M; Frascati Consensus Conference; European Neuroendocrine Tumor Society: Poorly differentiated carcinomas of the foregut (gastric, duodenal and pancreatic). Neuroendocrinology 2006;84:212–215.
32 Sarmiento JM, Heywood G, Rubin J, Ilstrup DM, Nagorney DM, Que FG: Surgical treatment of neuroendocrine metastases to the liver: a plea for resection to increase survival. J Am Coll Surg 2003;197:29–37.
33 Sarmiento J, Que F: Hepatic surgery for metastases from neuroendocrine tumors. Surg Oncol Clin N Am 2003;12:231–242.
34 Chamberlain R, Canes D, Brown K, Saltz L, Jarnagin W, Fong Y, Blumgart LH: Hepatic neuroendocrine metastases: does intervention alter outcomes? J Am Coll Surg 2000;190:432–445.
35 Elias D, Lasser P, Ducreux M, Duvillard P, Ouellet JF, Dromain C, Schlumberger M, Pocard M, Boige V, Miquel C, Baudin E: Liver resection (and associated extrahepatic resections) for metastatic well-differentiated endocrine tumors: a 15-year single center prospective study. Surgery 2003;133:375–382.
36 Chen H, Hardacre J, Uzar A, Cameron J, Choti M: Isolated liver metastases from neuroendocrine tumors: does resection prolong survival? J Am Coll Surg 1998;187:88–92.
37 Yao J, Talamonti M, Nemcek A, et al: Indications and results of liver resection and hepatic chemoembolization for metastatic gastrointestinal neuroendocrine tumors. Surgery 2001;130:677–682.
38 Touzios J, Kiely J, Pitt S, Rilling W, Quebbeman E, Wilson S, Pitt H: Neuroendocrine hepatic metastases: does aggressive management improve survival? Ann Surg 2005;241:776–783.
39 Kianmanesh R, O'Toole D, Sauvanet A, Ruszniewski P, Belghiti J: Surgical treatment of gastric, enteric pancreatic endocrine tumors. 2. Treatment of hepatic metastases. J Chir (Paris) 2005;142:208–219.
40 Solorzano C, Lee J, Pisters P, Vauthey J, Ayers G, Jean M, Gagel R, Ajani J, Wolff R, Evans D: Nonfunctioning islet cell carcinoma of the pancreas: survival results in a contemporary series of 163 patients. Surgery 2001;130:1078–1085.
41 Yigitler C, Farges O, Kianmanesh R, Regimbeau J, Abdalla E, Belghiti J: The small remnant liver after major liver resection: how common and how relevant? Liver Transpl 2003;9:S18–S25.
42 Hemming A, Reed A, Howard R, Fujita S, Hochwald S, Caridi J, Hawkins I, Vauthey J: Preoperative portal vein embolization for extended hepatectomy. Ann Surg 2003;237:686–691.
43 Oberg K, Kvols L, Caplin M, Delle Fave G, de Herder W, Rindi G, Ruszniewski P, Woltering EA, Wiedenmann B: Consensus report on the use of somatostatin analogs for the management of neuroendocrine tumors of the gastroenteropancreatic system. Ann Oncol 2004;15:966–973.
44 Farling P, Durairaju A: Remifentanil and anaesthesia for carcinoid syndrome. Br J Anaesth 2004;92:893–895.
45 Jaeck D, Oussoultzoglou E, Bachellier P: Hepatic metastases of gastroenteropancreatic neuroendocrine tumors: safe hepatic surgery. World J Surg 2001;25:689–692.

Downloaded from http://karger.com/nen/article-pdf/87/1/47/3228190/000111037.pdf by Universitätsbibliothek Bern user on 19 September 2023

46 Nordlinger B, Vaillant J, Guiguet M, et al: Survival benefit of repeat liver resections for recurrent colorectal metastases: 143 cases; Association Française de Chirurgie (AFC). J Clin Oncol 1994;12:1491.
47 Adam R, Bismuth H, Castaing D: Repeat hepatectomy for colorectal liver metastases. Ann Surg 1997;225:51.
48 Jaeck D, Oussoultzoglou E, Rosso E, Greget M, Weber J, Bachellier P: A two-stage hepatectomy procedure combined with portal vein embolization to achieve curative resection for initially unresectable multiple and bilobar colorectal liver metastases. Ann Surg 2004;240:1037–1049.
49 Kianmanesh R, Farges O, Abdalla E, Sauvanet A, Ruzniewski P, Belghiti J: Right portal vein ligation: a new planned two-step all-surgical approach for complete resection of primary gastrointestinal tumors with multiple bilateral liver metastases. J Am Coll Surg 2003;197:164–170.
50 Ahlman H, Wängberg B, Jansson S, Friman S, Olausson M, Tylén U, Nilsson O: Interventional treatment of gastrointestinal neuroendocrine tumours. Digestion 2000;62 (suppl 1):59–68.
51 Que F, Nagorney D, Batts K, Linz L, Kvols L: Hepatic resection for metastatic neuroendocrine carcinomas. Am J Surg 1995;169:36–42.
52 Chung MH, Pisegna J, Spirt M, Giuliano AE, Ye W, Ramming KP, Bilchik AJ: Hepatic cytoreduction followed by a novel long-acting somatostatin analog: a paradigm for intractable neuroendocrine tumors metastatic to the liver. Surgery 2001;130:954–962.
53 Dousset B, Saint-Marc O, Pitre J, Soubrane O, Houssin D, Chapuis Y: Metastatic endocrine tumors: medical treatment, surgical resection, or liver transplantation. World J Surg 1996;20:908–914.
54 Ahlman H, Westberg G, Wangberg B, Nilsson O, Tylen U, Schersten T, Tisell LE: Treatment of liver metastasis of carcinoid tumors. World J Surg 1996;20:196–202.
55 Grazi GL, Cescon M, Pierangeli F, Ercolani G, Gardini A, Cavallari A, Mazziotti A: Highly aggressive policy of hepatic resections for neuroendocrine liver metastases. Hepatogastroenterology 2000;47:481–486.
56 Pascher A, Steinmuller T, Radke C, Hosten N, Wiedenmann B, Neuhaus P, Bechstein WO: Primary and secondary hepatic manifestation of neuroendocrine tumors. Langenbecks Arch Surg 2000;385:265–270.
57 Nave H, Mossinger E, Feist H: Surgery as primary treatment in patients with liver metastases from carcinoid tumors: a retrospective, unicentric study over 13 years. Surgery 2001; 129:170–175.
58 Elias D, Lasser P, Ducreux M, Duvillard P, Ouellet JF, Dromain C, Schlumberger M, Pocard M, Boige V, Miquel C, Baudin E: Liver resection (and associated extrahepatic resections) for metastatic well-differentiated endocrine tumors: a 15-year single-center prospective study. Surgery 2003;133:375–382.
59 Bismuth H: Consensus statement on indication for liver transplantation. Hepatology 1994;20:S63–S68.
60 Pfitzmann R, Benscheidt B, Langrehr J, Schumacher G, Neuhaus R, Neuhaus P: Trends and experiences in liver retransplantation over 15 years. Liver Transpl 2007;13: 248–257.
61 Blonski WC, Reddy KR, Shaked A, Siegelman E, Metz DC: Liver transplantation for metastatic neuroendocrine tumor: a case report and review of the literature. World J Gastroenterol 2005;48:7676–7683.
62 Pascher A, Klupp J, Neuhaus P: Transplantation in the management of metastatic endocrine tumours. Best Pract Res Clin Gastroenterol 2005;19:637–648.
63 Frilling A, Malago M, Weber F, Paul A, Nadalin S, Sotiropoulos G, Cicinnati V, Beckebaum S, Bockisch A, Mueller-Brand J, Hofmann M, Schmid K, Gerken G, Broelsch C: Liver transplantation for patients with metastatic endocrine tumors: single-center experience with 15 patients. Liver Transplant 2006;12:1089–1096.
64 Florman S, Toure B, Kim L, Gondolesi G, Roayaie S, Krieger N, Fishbein T, Emre S, Miller C, Schwartz M: Liver transplantation for neuroendocrine tumors. J Gastrointest Surg 2004;8:208–212.
65 Lehnert T: Liver transplantation for metastatic neuroendocrine carcinoma: an analysis of 103 patients. Transplantation 1998;66: 1307–1312.
66 Rosenau J, Bahr MJ, von Wasielewski R, Mengel M, Schmidt HH, Nashan B, Lang H, Klempnauer J, Manns MP, Boeker KH: Ki-67, E-cadherin, and p53 as prognostic indicators of long-term outcome after liver transplantation for metastatic neuroendocrine tumors. Transplantation 2002;73:386–394.
67 Ahlman H, Friman S, Cahlin C, et al: Liver transplantation for treatment of metastatic neuroendocrine tumors. Ann NY Acad Sci 2004;1014:265–269.
68 Lang H, Oldhafer KJ, Weimann A, Schlitt HJ, Scheumann GF, Flemming P, Ringe B, Pichlmayr R: Liver transplantation for metastatic neuroendocrine tumors. Ann Surg 1997;225:347–354.
69 Olausson M, Friman S, Cahlin C, Nilsson O, Jansson S, Wangberg B, Ahlman H: Indications and results of liver transplantation in patients with neuroendocrine tumors. World J Surg 2002;26:998–1004.
70 Van Vilsteren FGI, Baskin-Bey ES, Nagorney DM, Sanderson SO, Kremers WK, Rosen CB, Gores GJ, Hobday TJ: Liver transplantation for gastropancreatic neuroendocrine cancers: defining selection criteria to improve survival. Liver Transplant 2006;12:448–456.
71 Olausson M, Friman S, Herlenius G, Cahlin C, Nilsson O, Jansson S, Wängberg B, Ahlman H: Orthotopic liver or multivisceral transplantation as treatment of metastatic neuroendocrine tumors. Liver Transplant 2007;13:327–333.
72 Ringe B, Lorf T, Dopkens K: Treatment of hepatic metastases from gastroenteropancreatic neuroendocrine tumors: role of liver transplantation. World J Surg 2001;25:697–699.
73 Coppa J, Pulvirenti A, Schiavo M, Romito R, Collini P, Di Bartolomeo M, Fabbri A, Regalia E, Mazzaferro V: Resection versus transplantation for liver metastases from neuroendocrine tumors. Transplant Proc 2001;33: 1537–1539.
74 Frilling A, Rogiers X, Malago M, Liedke O, Kaun M, Broelsch CE: Liver transplantation in patients with liver metastases of neuroendocrine tumors. Transplant Proc 1998;30: 3298–3300.
75 Anthuber M, Jauch K-W, Briegel J: Results of liver transplantation for gastroenteropancreatic tumor metastases. World J Surg 1996; 20:73–76.
76 Siperstein A, Rogers S, Hansen P, Gitomirsky A: Laparoscopic thermal ablation of hepatic neuroendocrine tumor metastases. Surgery 1997;122:1147–1155.
77 Siperstein A, Berber E: Cryoablation, percutaneous alcohol injection, and radiofrequency ablation for treatment of neuroendocrine liver metastases. World J Surg 2001;25:693–696.
78 Berber E, Flesher N, Siperstein A: Laparoscopic radiofrequency ablation of neuroendocrine liver metastases. World J Surg 2002; 26:985–990.
79 Gillams A, Cassoni A, Conway G, Lees W: Radiofrequency ablation of neuroendocrine liver metastases: the Middlesex experience. Abdom Imaging 2005;30:435–441.
80 Livraghi T, Goldberg SN, Lazzaroni S, Meloni F, Ierace T, Solbiati L, Gazelle GS: Hepatocellular carcinoma: radio-frequency ablation of medium and large lesions. Radiology 2000;214:761–768.
81 Curley S, Marra P, Beaty K, Ellis L, Vauthey J, Abdalla E, Scaife C, Raut C, Wolff R, Choi H, Loyer E, Vallone P, Fiore F, Scordino F, De Rosa V, Orlando R, Pignata S, Daniele B, Izzo F: Early and late complications after radiofrequency ablation of malignant liver tumors in 608 patients. Ann Surg 2004;239:450–458.
82 Abdalla E, Vauthey J, Ellis L, Elli V, Pollock R, Broglio K, Hess K, Curley S: Recurrence and outcomes following hepatic resection, radiofrequency ablation, and combined resection/ablation for colorectal metastases. Ann Surg 2004;239:818–827.
83 Aloia T, Vauthey J, Loyer E, Ribero D, Pawlik T, Wei S, Curley S, Zorzi D, Abdalla E: Solitary colorectal liver metastasis: resection determines outcome. Arch Surg 2006;141:460–466.
84 McKay A, Dixon E, Taylor M: Current role of radiofrequency ablation for the treatment of colorectal liver metastases. Br J Surg 2006; 93:1192–1201.

Downloaded from http://karger.com/nen/article-pdf/87/1/47/3228190/000111037.pdf by Universitätsbibliothek Bern user on 19 September 2023

85 Sutherland L, Williams J, Padbury R, Gotley D, Stokes B, Maddern G: Radiofrequency ablation of liver tumors: a systematic review. Arch Surg 2006;141:181–190; comment: 947.
86 Pawlik T, Izzo F, Cohen D, Morris J, Curley M: Combined resection and radiofrequency ablation for advanced hepatic malignancies: results in 172 patients. Ann Surg Oncol 2003; 10:1059–1069.
87 Evard S, Becouarn Y, Fonck M, Brunet R, Mathoulin-Pelissier S, Picot V: Surgical treatment of liver metastases by radiofrequency ablation, resection, or in combination. Eur J Surg Oncol 2004;30:399–406.
88 Fioole B, Jansen M, van Duijnhoven F, van Hillegersberg R, van Gulik T, Borel Rinkes I: Combining partial liver resection and local ablation of liver tumours: a preliminary Dutch experience. World J Surg Oncol 2006; 4:46.
89 Elias D, Baton O, Sideris L, Boige V, Malka D, Liberale G, Pocard M, Lasser P: Hepatectomy plus intraoperative radiofrequency ablation and chemotherapy to treat technically unresectable multiple colorectal liver metastases. J Surg Oncol 2005;90:36–42.
90 Vogl T, Straub R, Eichler K, Söllner O, Mack M: Colorectal metastases in liver: laser-induced interstitial thermotherapy – local tumor control rate and survival data. Radiology 2004;230:450–458.
91 Gillams A: Liver ablation therapy. Br J Radiol 2004;77:713–723.
92 Veenendaal L, de Jager A, Stapper G, Borel Rinkes I, van Hillegersberg R: Multiple fiber laser-induced thermotherapy for ablation of large intrahepatic tumors. Photomed Laser Surg 2006;24:3–9.
93 Vogl T, Mack M, Balzer J, Engelmann K, Straub R, Eichler K, Woitaschek D, Zangos S: Liver metastases: neoadjuvant downsizing with trans-arterial chemoembolization before laser-induced thermotherapy. Radiology 2003;229:457–464.
94 Atwell TD, Charboneau JW, Que FG, Rubin J, Lewis BD, Nagorney DM, Callstrom MR, Farrell MA, Pitot HC, Hobday TJ: Treatment of neuroendocrine cancer metastatic to the liver: the role of ablative techniques. Cardiovasc Intervent Radiol 2005;28:409–421.
95 Lencioni RA, Allgaier HP, Cioni D, Olschewski M, Deibert P, Crocetti L, Frings H, Laubenberger J, Zuber I, Blum HE, Bartolozzi C: Small hepatocellular carcinoma in cirrhosis: randomized comparison of radiofrequency thermal ablation versus percutaneous ethanol injection. Radiology 2003; 228:235–240.
96 Ricke J, Wust P, Wieners G, Beck A, Cho C, Seidensticker M, Pech M, Werk M, Rosner C, Hänninen E, Freund T, Felix R: Liver malignancies: CT-guided interstitial brachytherapy in patients with unfavorable lesions for thermal ablation. J Vasc Interv Radiol 2004; 15:1279–1286.
97 Mitty HA, Warner RR, Newman LH, Train JS, Parnes IH: Control of carcinoid syndrome with hepatic artery embolization. Radiology 1985;155:623–626.
98 Roche A, Girish BV, de Baere T, Baudin E, Boige V, Elias D, Lasser P, Schlumberger M, Ducreux M: Trans-catheter arterial chemoembolization as first-line treatment for hepatic metastases from endocrine tumors. Eur Radiol 2003;13:136–140.
99 Marrache F, Vullierme MP, Roy C, El Assoued Y, Couvelard A, O'Toole D, Mitry E, Hentic O, Hammel P, Levy P, Ravaud P, Rougier P, Ruszniewski P: Arterial phase enhancement and body mass index are predictors of response to chemoembolisation for liver metastases of endocrine tumours. Br J Cancer 2007;96:49–55.
100 Ruszniewski P, Rougier P, Roche A, Legmann P, Sibert A, Hochlaf S, Ychou M, Mignon M: Hepatic arterial chemoembolization in patients with liver metastases of endocrine tumors. A prospective phase II study in 24 patients. Cancer 1993;71:2624–2630.
101 Therasse E, Breittmayer F, Roche A, De Baere T, Indushekar S, Ducreux M, Lasser P, Elias D, Rougier P: Transcatheter chemoembolization of progressive carcinoid liver metastasis. Radiology 1993;189:541–547.
102 Perry L, Stuart K, Stokes K, Clouse M: Hepatic arterial chemoembolization for metastatic neuroendocrine tumors. Surgery 1994;116:1111–1117.
103 Clouse M, Perry L, Stuart K, Stokes K: Hepatic arterial chemoembolization for metastatic neuroendocrine tumors. Digestion 1994;55(suppl 3):92–97.
104 Diaco DS, Hajarizadeh H, Mueller CR, Fletcher WS, Pommier RF, Woltering EA: Treatment of metastatic carcinoid tumors using multimodality therapy of octreotide acetate, intra-arterial chemotherapy, and hepatic arterial chemoembolization. Am J Surg 1995;169:523–528.
105 O'Toole D, Maire F, Ruszniewski P: Ablative therapies for liver metastases of digestive endocrine tumours. Endocr Relat Cancer 2003;10:463–468.
106 Kress O, Wagner HJ, Wied M, Klose KJ, Arnold R, Alfke H: Transarterial chemoembolization of advanced liver metastases of neuroendocrine tumors – a retrospective single-center analysis. Digestion 2003;68: 94–101.
107 Faiss S, Pape UF, Bohmig M, Dorffel Y, Mansmann U, Golder W, Riecken EO, Wiedenmann B; International Lanreotide and Interferon Alfa Study Group: prospective, randomized, multicenter trial on the antiproliferative effect of lanreotide, interferon alfa, and their combination for therapy of metastatic neuroendocrine gastroenteropancreatic tumors – the International Lanreotide and Interferon Alfa Study Group. J Clin Oncol 2003;21:2689–2696.
108 Welin SV, Janson ET, Sundin A, Stridsberg M, Lavenius E, Granberg D, Skogseid B, Oberg KE, Eriksson BK: High-dose treatment with a long-acting somatostatin analogue in patients with advanced midgut carcinoid tumours. Eur J Endocrinol 2004; 151:107–112.
109 Arnold R, Rinke A, Klose KJ, Muller HH, Wied M, Zamzow K, Schmidt C, Schade-Brittinger C, Barth P, Moll R, Koller M, Unterhalt M, Hiddemann W, Schmidt-Lauber M, Pavel M, Arnold CN: Octreotide versus octreotide plus interferon-α in endocrine gastroenteropancreatic tumors: a randomized trial. Clin Gastroenterol Hepatol 2005; 3:761–771.
110 Delaunoit T, Ducreux M, Boige V, Dromain C, Sabourin JC, Duvillard P, Schlumberger M, de Baere T, Rougier P, Ruffie P, Elias D, Lasser P, Baudin E: The doxorubicin-streptozotocin combination for the treatment of advanced well-differentiated pancreatic endocrine carcinoma; a judicious option? Eur J Cancer 2004;40:515–520.
111 Moertel CG, Lefkopoulo M, Lipsitz S, Hahn RG, Klaassen D: Streptozocin-doxorubicin, streptozocin-fluorouracil or chlorozotocin in the treatment of advanced islet-cell carcinoma. N Engl J Med 1992;326:519–523.
112 Frilling A, Weber F, Saner F, Bockisch A, Hofmann M, Mueller-Brand J, Broelsch C: Treatment with ^{90}Y-DOTATOC in patients with metastatic neuroendocrine tumors. Surgery 2006;140:968–976.
113 Waldherr C, Pless M, Maecke HR, Schumacher T, Crazzolara A, Nitzsche EU, Haldemann A, Mueller-Brand J: Tumor response and clinical benefit in neuroendocrine tumors after 7.4 GBq ^{90}Y-DOTATOC. J Nucl Med 2002;43:610–616.
114 Kwekkeboom DJ, Teunissen JJ, Bakker WH, Kooij PP, de Herder WW, Feelders RA, van Eijck CH, Esser JP, Kam BL, Krenning EP: Radiolabeled somatostatin analog [^{177}Lu-DOTA0,Tyr^{3}]octreotate in patients with endocrine gastroenteropancreatic tumors. J Clin Oncol 2005;23:2754–2762.
115 Moertel C, Kvols L, O'Connell M, Rubin J: Treatment of neuroendocrine carcinomas with combined etoposide and cisplatin. Evidence of major therapeutic activity in the anaplastic variants of these neoplasms. Cancer 1991;68:227–232.
116 Pape U, Tiling N, Bartel C, Plöckinger U, Wiedenmann B: Oxaliplatin plus 5-fluorouracil/folinic acid as palliative treatment for progressive malignant gastrointestinal neuroendocrine carcinomas. J Clin Oncol 2006;24(suppl):14074.
117 Bajetta E, Catena L, Procopio G, De Dosso S, Bichisao E, Ferrari L, Martinetti A, Platania M, Verzoni E, Formisano B, Bajetta R: Are capecitabine and oxaliplatin (XELOX) suitable treatments for progressing low-grade and high-grade neuroendocrine tumours? Cancer Chemother Pharmacol 2007;59:637–642.

Downloaded from http://karger.com/nen/article-pdf/87/1/47/3228190/000111037.pdf by Universitätsbibliothek Bern user on 19 September 2023