J Neurol (2002) 249 : 320 – 329

ORIGINAL COMMUNICATION

Peter Höllinger
Matthias Sturzenegger
Johannes Mathis
Gerhard Schroth
Christian W. Hess

Acute disseminated encephalomyelitis in adults: a reappraisal of clinical, CSF, EEG, and MRI findings

Received: 20 April 2001
Received in revised form: 19 July 2001
Accepted: 25 July 2001

P. Höllinger · M. Sturzenegger, MD (✉) · J. Mathis · C. W. Hess
Department of Neurology
University of Bern
Freiburgstr. 10
3010 Bern, Switzerland
Tel.: +41-31/6 32 21 11
Fax: +41-31/6 32 96 79
E-Mail: matthias.sturzenegger@insel.ch

G. Schroth
Department of Neuroradiology
University Hospital
Bern, Switzerland

Abstract *Objectives* To establish an adequate definition of acute disseminated encephalomyelitis (ADEM) in adults, based on our clinical observations of a case-series. *Methods* Over a period of three years 10 adult patients with a para- or postinfectious disseminated (diffuse or multifocal) syndrome of the CNS fulfilling predefined strict criteria for the diagnosis of ADEM were encountered and systematically followed. *Results* The age ranged from 21 to 62 years, two were men. MRI was normal in 5 patients and only mildly abnormal in the remaining patients. CSF was normal in 5 patients and mildly abnormal in the remainder, EEG was abnormal in 7/8 patients. All patients survived and were followed over a period of 30 months (range: 8 to 48 months). Nine patients were left with some residual defects, consisting most often of a mild cognitive impairment. *Conclusions* The EEG as an investigation of brain function can be crucial in establishing the organic nature of disease. MRI is important to exclude other diffuse or multifocal encephalopathies. However, in contrast to previous reports in the literature abnormal MRI should not be considered mandatory in adult ADEM. Difficulties in the diagnosis of ADEM are discussed and the importance of clinical and paraclinical findings for establishing the diagnosis is outlined.

Key words Acute disseminated encephalomyelitis · Electroencephalography · Magnetic resonance imaging

Abbreviations

ADEM = acute disseminated encephalomyelitis; CSF = cerebrospinal fluid; EEG = electroencephalography; MRI = magnetic resonance imaging; CT = computed tomography; CNS = central nervous system; HLA = human leucocyte antigen; PNS = peripheral nervous system; MS = multiple sclerosis; PCR = polymerase chain reaction; IgG = immunoglobulin G; HSV = Herpes simplex virus; EBV = Epstein-Barr-virus.

Introduction

ADEM is an acute disseminated disease of the brain and/or the spinal cord, which has been known for more than 250 years after its initial description following smallpox infections [3]. In most instances the disease follows an exanthematous or unspecific viral infection such as measles, varicella, rubella, mumps, influenza, infectious mononucleosis, gastrointestinal or upper respiratory tract infections [3, 17, 36]. In addition mycoplasma pneumoniae infections and vaccinations are well established precipitating events [17, 36]. However, the spontaneous occurrence of ADEM has also been re-

ported, probably following a clinically silent infection [3]. Although the definition requires a disseminated diffuse or multifocal disease process in the CNS, monofocal lesions have also been repeatedly interpreted as manifestations of ADEM [19, 25, 26].

The disease mainly affects children [7, 14]. There are no published data available about prevalence, but reported mortality is about 20 %. ADEM typically runs a monophasic course with a large variation as to disease duration and extent of recovery. However, recurrent episodes of ADEM were repeatedly claimed to exist [1, 30, 34]. In those instances, the distinction from relapsing-remitting MS may obviously be difficult, because when suspecting a patient to suffer from ADEM one always has to consider the possibility of a first bout of MS [13, 28]. The second most important differential diagnosis in the acute stage of ADEM is an infectious meningoencephalitis of possibly treatable etiology [17, 34]. Third, so-called acute brain swelling must also be considered [4, 32].

In ADEM an autoimmune response against CNS structures is generally assumed to be the underlying pathogenesis, resulting in different immunosuppressive or immunomodulatory treatment strategies, such as high-dose corticosteroids, plasmapheresis or intravenous immunoglobulins [11, 18, 37]. To explain the discrepancy between the high incidence of viral infections (e. g. of the upper respiratory tract) and the comparatively low incidence of ADEM, predisposing factors of the host have been invoked as for example certain HLA patterns in children [24]. Initially, the diagnosis of ADEM was based on clinical and autopsy findings, which later were completed with CSF and EEG results [3, 44]. With the advent of CT and particularly MRI several reports have described unequivocal white matter signal abnormalities throughout the CNS [2, 5, 19, 22, 35]. In the most recently reported largest series of ADEM patients, MRI lesions were a prerequisite criterion for inclusion [33], while EEG findings were not mentioned at all. To our knowledge the possibility of normal MRI findings in ADEM during the whole disease course has not yet been reported.

In summary there is no adequate definition of ADEM in the literature. To rely on the findings of one diagnostic procedure such as MRI or CSF alone is clearly not appropriate to diagnose ADEM. Therefore we chose as minimally required criteria a preceding infection (based on history), a monophasic disease course, neurological findings indicating disseminated CNS disease, and finally absence of metabolic or infectious disorders.

Patients and methods

Over the last three years we observed 10 adult patients presenting with a postinfectious disease of the CNS. There were 2 men. Age ranged from 21 to 62 years (median 34.5). We included patients in whom the final diagnosis of ADEM was based on a typical history as well as on clinical and paraclinical findings (CSF, MRI, EEG), and in whom a confirmatory follow-up of several months was obtained. We excluded all patients with a history of preceding disease bouts affecting the CNS, thus raising the suspicion of MS, as well as patients in whom only a single lesion of the CNS was found clinically or by MRI, such as an isolated unilateral optic neuritis, myelitis, or brainstem lesion.

The history had to comprise an obvious infectious, febrile illness at the beginning with the para- or postinfectious development of unequivocal CNS symptoms and signs. The clinical presentation required the signs of a disseminated, i. e. multifocal or diffuse, CNS involvement. Since diffuse CNS involvement cannot always be diagnosed with certainty on clinical ground alone, corroborative EEG or MRI findings were required in these cases.

A CSF analysis was considered essential to exclude a direct infectious CNS disease and included cell count and differentiation, protein and glucose levels in all patients. CSF specific oligoclonal IgG bands were investigated in 8/10 patients, opening pressure in 9/10. Microbiological examinations of CSF included serology for Lyme disease and syphilis and PCR for the herpes viruses (Herpes simplex, Epstein-Barr, Varicella-Zoster, cytomegalovirus) and for enteroviruses; they were done in most patients according to the clinical presentation.

Blood analysis in all patients included red and white blood cell count and differentiation, platelets, prothrombin time, sodium, potassium, calcium, serum creatinin, liver enzymes, C-reactive protein, sedimentation rate, and glucose. Antinuclear antibodies and rheumafactor where determined in 6/10 patients. Serology against Lyme disease and syphilis was done in 9/10 patients, serology against herpes viruses, hepatitis viruses, *Toxoplasma gondii*, measles, mumps, *Mycoplasma pneumoniae*, and other microbes was determined in several patients according to the clinical presentation.

EEG was done in 8/10 patients and repeated at least once in 5/8 patients.

In 6/10 patients electroneuromyographic examinations and/or evoked potential studies were performed.

During the hospital stay all patients underwent MRI (1.5 T, Siemens, Germany) of the brain, which was repeated at least once in 9 patients. Images included T1, T2 and proton density weighted sequences and application of a paramagnetic contrast agent in all examined patients. The following additional sequences were acquired in certain patients: MR angiography in 2, diffusion weighted imaging in 3, FLAIR sequences in 6. MRI of the cervical and thoracic spine was performed in 1 patient (repeated once), MRI of only the cervical spine was done in 1 patient (not repeated).

All patients were followed clinically and sometimes with a repeated EEG or MRI (see table for details of performed examinations). Special attention was paid to the functional state of the patient, which was scored according to the Rankin scale [40]. The development of excessive daytime sleepiness was particularly inquired after and, if present, was quantified by the Epworth sleepiness scale [15].

Results (see Table)

History

Preceding infection mostly involved the upper respiratory tract (6/10), less often the gastrointestinal tract (2/10). In 2 patients the preceding symptoms were not localizing (fever, headache, myoarthralgia), but nevertheless pointed to a generalized viral infection. Half had a parainfectious and half a postinfectious onset of neurological symptoms and signs. The infectious disease usually lasted for some days, but in one patient it lasted for almost 2 months (case 3).

Table 1 Acute disseminated encephalomyelitis in adults: a reappraisal of clinical, CSF, EEG and MRI findings

Pat.-Nr., gender, age	Infection (time before neurological syndrome)	Neurological symptoms	CSF (interval)	EEG (interval)	Electrophysiology (interval)	MRI (interval)	follow-up	outcome (Rankin scale)
1 (f, 62)	upper respiratory tract (7 days)	Nausea, vertigo, diplopia, facial palsy, tetraparesis, coma	normal; pressure 29, 24, 30, 33 (d 1, 3, 7, 14)	severe generalized slowing with epileptic potentials (s. text)	axonal and demyelinating neuropathy (s. text)	normal (d 2, 14)	18 months	3
2 (f, 21)	gastrointestinal (6 days)	headache, somnolence, seizures, ataxia, myoclonia, hallucinations	mild transient pleocytosis and proteinorrhachia (s. text)	severe transient slowing of background activity (s. text)	VEP, SSEP normal (d 5)	normal (d 2, 9)	22 months	2
3 (f, 39)	upper respiratory tract (2 months)	optic neuritis, nystagmus, fever, locked in-syndrome	19 mono, prot 0.7, pressure 19, no OB (d 3)	somnolent, FIRDA (d 3)	sural and peroneal neurography, EMG of tibialis anterior, all normal (d 15) VEP abnormal on the right side (d 33)	Hyperintense lesions in the pons and the cervical medulla (s. text)	40 months	2
4 (m, 30)	generalized myarthralgia (3 days)	fever, headache, fatigue, vertigo, diplopia	normal incl. pressure (d 450, 810)	somnolent (d 450)	n.d.	pontine lesion with initial enhancement, periventricular lesion (d 7, 82, 292, 450, 810)	34 months	2
5 (f, 53)	upper respiratory tract (2 weeks)	paresthesia left arm	weak OB, otherwise normal (d 65)	n.d.	median neurography normal. Med.SSEP: central conduction deficit on the left side (d 50)	hyperintensities (spinal/cerebral) (d 54/65)	36 months	1
6 (m, 35)	upper respiratory tract (6 days)	headache, nausea, vertigo, tinnitus, diplopia, paresthesia left hemibody	13 mono, prot 0.6, no OB, pressure 27 (d 4)	mild generalized slowing (d 5)	VEP, SSEP normal (d 16)	multiple infratentorial hyperintensities (d 3). Regression (d 18)	48 months	1
7 (f, 27)	gastrointestinal (3 weeks)	somnolence, disorientation, mutism, bilateral Babinski, tetrahyperreflexia	normal (d 4, 6)	severe generalized slowing with epileptic potentials (s. text)	n.d.	normal (d 4, 12, 270)	18 months	2
8 (f, 34)	unspecific (headache, fever) (10 days)	bilateral optic neuritis, bilateral internuclear ophthalmoplegia, left Babinski	19 mono, prot 0.5, no OB, pressure n.d. (d 3)	n.d.	VEP/SSEP, MEP normal (d 8/10)	bilateral optic neuritis, mesencephalic lesion (d 3). Regression (d 50)	35 months	0
9 (f, 32)	upper respiratory tract (7 days)	fever, headache, meningeal irritation, right hemisyndrome	normal, OB n.d. (d 1)	mild generalized slowing, bilateral posterior focal slowing with focal sharp waves (d 1); focal slowing left temporal, otherwise normal (d 12)	n.d.	normal (d 2, d 12)	26 months	3
10 (f, 43)	upper respiratory tract (7 days)	nausea, vomiting, vertigo, gait ataxia, sensorimotor hemisyndrome left	prot 0.7, otherwise normal (d 2)	normal (d 2)	SSEP/MEP: abnormal on the left side (d 2, 4) indicating a central lesion	CT normal (d 1); MRI normal (d 1, 8)	8 months	1

f = female, m = male. Interval in days (d) (calculated from the onset of neurological symptoms). OB = oligoclonal IgG bands. n. d. = not done. mono = mononuclear cells. prot = protein content in g/l. CSF pressure is given in cm H_2O. FIRDA = frontal intermittent rhythmic delta activity. VEP = visually evoked potentials. SSEP = somatosensory evoked potentials of the tibial nerve. EMG = electromyography. Med.SSEP = somatosensory evoked potentials of the median nerve. MEP = motor evoked potentials.

Neurological symptoms and signs

Only one patient (case 5) presented with a monofocal disorder on clinical examination which was due to cervical myelitis, and showed several signal hyperintensities in the T2-weighted brain MRI thus allowing classification of a multifocal disease. Two patients presented with a diffuse (encephalopathic) syndrome (cases 2, 7) and 7 patients showed a multifocal clinical picture. The rate of initial progression and the severity of the disease were very variable, ranging from paresthesias of the left arm (case 5), over bilateral optic neuritis (with internuclear ophthalmoplegia and Babinski sign) (case 8) to a fulminant illness with bilateral optic neuritis and transient locked-in-syndrome (case 3). Generalized seizures occurred in cases 2 and 7, in the latter with a delay period of approximately 9 months after the acute neurological illness.

CSF

CSF examination was completely normal in 5/10 patients. In 5/10 patients there was a mild pleocytosis with predominantly mononuclear cells (ranging from 13–22 cells/microliter), protein content was 0.7 g/l or less. Oligoclonal bands were investigated in 8/10 patients, and weakly positive in one patient only (case 5). Opening pressure was normal in 6/9 and slightly elevated in 3/9 (maximal value 33 cm H_2O). Microbiological analysis including PCR was performed in 7/10 and not indicative of an infectious origin in any patient.

Blood analysis

Blood analysis was unrevealing in 9/10 patients in that it did not provide an etiology of the disease by the means of e. g. antibody conversion against a particular microbe. Only in patient 9 did serology establish the diagnosis of recently acquired EBV-infection: IgG against VCA (viral capsid antigen) was positive, whereas IgG against EBNA (Epstein-Barr nuclear antigen) was still negative. Interestingly in that patient the examination of CSF was normal including PCR against HSV and EBV, thus virtually excluding a direct invasion of the CNS by EBV [38].

Electrophysiology

The EEG was abnormal in 7/8 patients in whom it was performed. Abnormal findings varied greatly and ranged from signs of increased sleepiness (case 4) over mild generalized slowing (case 3) to severe generalized slowing with sometimes additional focal slowing and epileptiform discharges. Severe abnormalities were recorded in 3 patients (cases 1, 2, 7), in whom EEG findings correlated fairly well with the severity and the course of the clinical syndrome (see case descriptions below). EEG was particularly important to prove the organic nature of disordered consciousness in two young female patients (cases 2 and 7), in whom a psychiatric diagnosis was initially suspected. It furthermore proved the additional involvement of the CNS in a patient with severe peripheral demyelinating neuropathy (case 1).

Visually evoked potentials and somatosensory evoked potentials of the tibial nerve were examined in 5 patients, in three of whom they were normal. Somatosensory potentials of the median nerve were done in one patient and motor evoked potentials were done in two patients. The details of electrophysiologic investigations in patient 1 are given below. In two additional patients electroneuromyographic findings were normal (cases 3 and 5).

MRI

Brain MRI was normal in 5/10 patients including a follow-up examination in all those 5 patients. In the remaining five patients, multifocal (i. e. at least two) lesions of the brain were detected, which sometimes showed an initial progression over several days (see case 3 below). In three patients (cases 4, 6, 8) the lesions were clearly diminishing on later follow-up examinations. Partial enhancement after administration of a paramagnetic contrast agent was observed in 3/5 patients with abnormal MRI. The performance of additional sequences as outlined above (FLAIR, diffusion weighted imaging) did not yield any further information. Spinal MRI was abnormal in both patients in whom it was performed. Representative MRI images of the five patients with abnormal findings are shown in Fig. 1.

Therapy

In 8 patients corticosteroids were given; in 5 of them high-dose methylprednisolone (500 mg daily over 5 days) was given intravenously. An antiviral therapy with acyclovir was initiated in 5 patients, 2 patients (cases 1 and 3) received plasma exchange, and 3 patients (cases 1, 2, 3) received intravenous immunoglobulin (0.4 g/kg once a day for five days). Five patients were treated in the intensive care unit during 1 to 60 days (median duration 8 days).

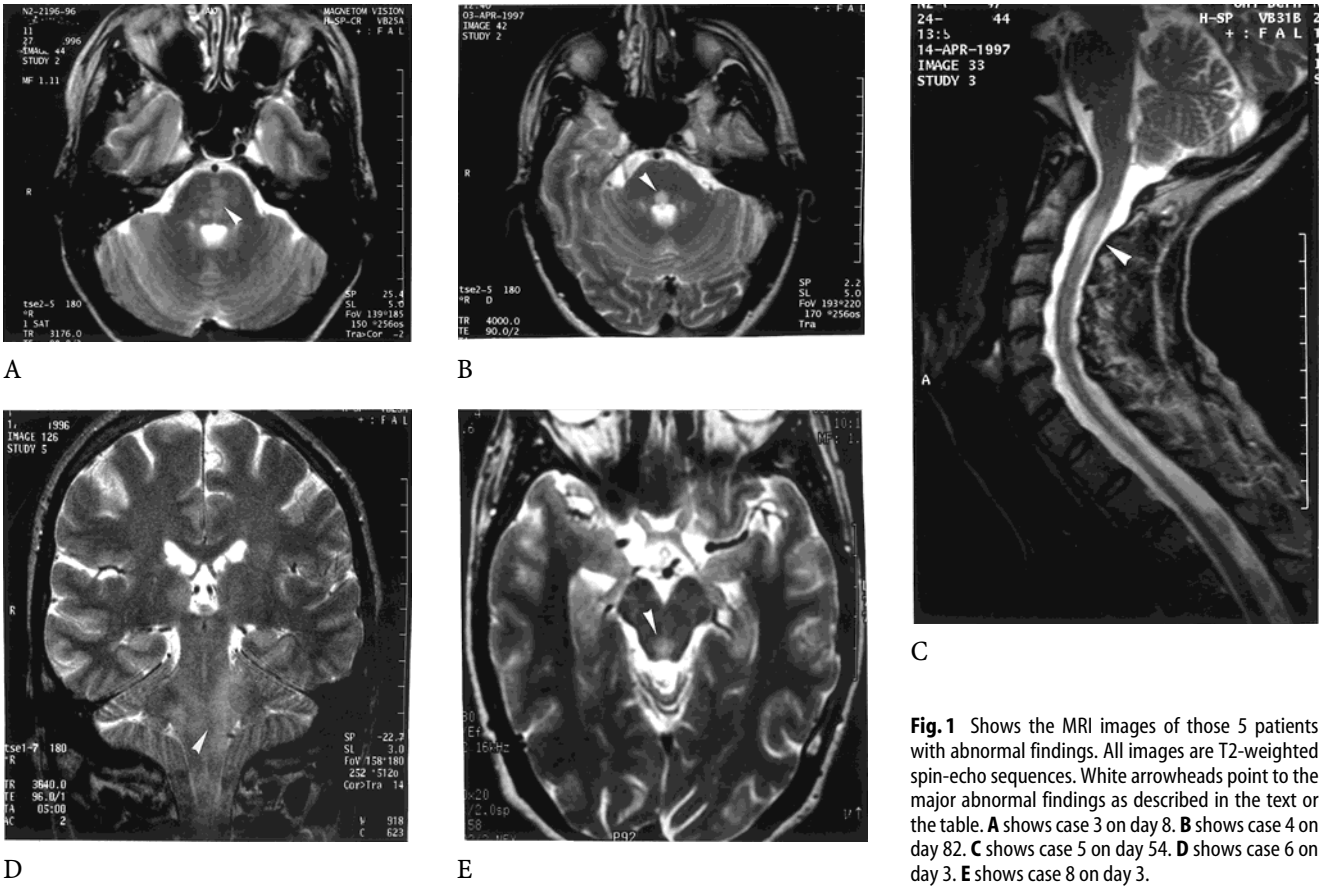

Fig. 1 Shows the MRI images of those 5 patients with abnormal findings. All images are T2-weighted spin-echo sequences. White arrowheads point to the major abnormal findings as described in the text or the table. **A** shows case 3 on day 8. **B** shows case 4 on day 82. **C** shows case 5 on day 54. **D** shows case 6 on day 3. **E** shows case 8 on day 3.

Outcome and follow-up

All patients survived. The follow-up period (calculated from the beginning of neurological symptoms) ranged from 8 to 48 months, with a median value of 30 months. The outcome as measured with the Rankin scale was completely normal in only 1 patient (case 8, Rankin 0), and ranged from 1–3 points on the Rankin scale with a median value of 2 in all other patients. Complaints were in most instances rather vague consisting of impaired memory or concentration, becoming especially apparent in stressful situations. A history of newly acquired excessive daytime sleepiness was obtained in 2 patients (cases 4, 9), in whom the Epworth sleepiness score ranged from 13–15.

Illustrative cases

Case 1

This 62-year old woman developed a mild flu-like syndrome with symptoms of the upper respiratory tract approximately one week before she noticed for the first time ptosis on the right side, disorders of taste and swallowing and paresthesia of the hands. On admission she had difficulties with coughing, there was a left VIth nerve palsy, bilateral ptosis, facial diplegia, and the palate and tongue were paretic. Arm movements were ataxic, all tendon reflexes were very weak and pyramidal signs were absent. She had to be intubated the same day and subsequently developed severe tetraparesis with absent tendon reflexes. At that moment (day 4) she was comatose, the EEG showed a predominance of theta-delta waves with frequent appearance of generalized epileptiform discharges. On day 7 and 11 the EEG showed a theta dominance (6–7 Hz) with some bifrontal delta waves, epileptiform discharges were no longer observed under treatment with valproic acid. The EEG on day 38 revealed a dominating frequency of 7–8 Hz with several epileptiform discharges. Electroneurography on day 3 disclosed a conduction block of the right median nerve at the forearm, facial neurography yielded low amplitudes on peripheral stimulation, which could no longer be reproduced 10 days later. On day 45 a conduction block in the right median nerve at the upper arm was detected, electromyography of facial and hand musles showed many fibrillation potentials and sharp positive waves. MRI of the brain including gadolinium enhanced T1-weighted sequences was normal on days 2 and 14.

CSF was normal on days 1, 3, 7 and 14 with the exception of a slightly elevated opening pressure (see Table). Anti GQ1b IgG antibodies were detected with a titer of 1390 (normal < 800 Units). The patient had to be provided with a tracheostomy and a gastrostomy, a cardiac pacemaker was implanted to overcome recurrent asystoles and AV-block III°. She stayed approximately 60 days in the intensive care unit and was finally transferred to a rehabilitation unit, where she remained 4.5 months. She could then return home where she was soon able to take over her duties in the household. When seen at follow-up 18 months after the onset of neurological symptoms she exhibited severe dysarthria with bilateral facial palsy, tendon reflexes were still missing and she complained of non aching tingling sensations in the fingers. In summary this patient had combined central and peripheral nervous system disseminated predominantly demyelinating lesions.

Case 2

This 21-year old woman suffered from gastrointestinal infection with diarrhea, vomiting and fever for approximately 6 days, until she became afebrile but at the same time a striking adynamia and lethargy were noted. On admission she cooperated poorly, neurological examination was otherwise normal. The syndrome was interpreted as postinfectious exhaustion in a patient with a difficult psychosocial situation. Lumbar puncture on the following day (day 2) disclosed 4 mononuclear cells and a protein of 0.7 g/l. EEG on day 3 showed severe diffuse slowing of the background activity with a prevailing frequency around 2 Hz (Fig. 2a). On day 3 she had one generalized seizure. During the following days she developed an extrapyramidal syndrome with perioral dyskinesia and intermittent dystonic posturing of the right hemibody. Myoclonus of the extremities with predominance on the right side emerged and on day 9 a further generalized seizure occurred. She then complained of blurred vision, strange flash-like visual sensations, memory impairment and difficulty with micturition. Examination at that moment showed bilateral ataxia of the extremities with predominance on the right side in addition to myoclonia. MRI of the brain on day 2 and 9 was normal. CSF on days 8 and 16 showed a slight mononuclear pleocytosis of 22 and 12 cells, protein was normal without oligoclonal banding. CSF on day 37 was completely normal. EEG on day 19 showed a prevailing frequency around 5 Hz with periodic sharp-waves over the left and less frequently also over the right occipital region (Fig. 2b). Liver enzymes at the beginning were mildly and transiently elevated, but no causative organism could be detected in the blood or the CSF. Under an initial treatment with acyclovir, followed by intravenous immunoglobulins and high-dose methyprednisolone together with valproic acid symptoms slowly improved.

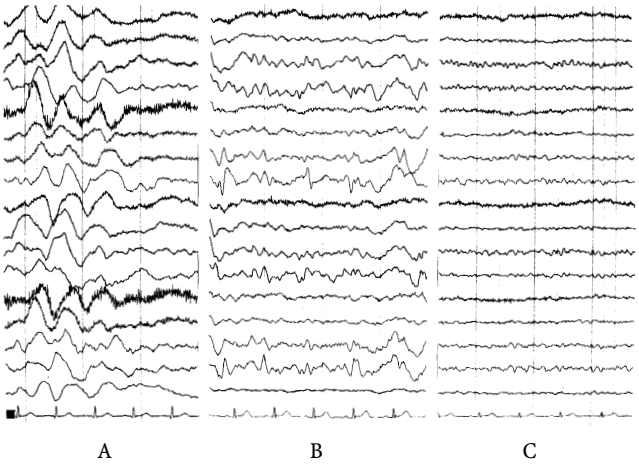

Fig. 2 Serial EEGs of case 2. All EEGs are presented in the same manner: bipolar recordings with the first 4 lines representing right lateral electrodes, the second 4 lines left lateral electrodes, the third 4 lines right parasagittal electrodes, the fourth 4 lines left parasagittal electrodes, line next to the last represents right electrooculogram and the last line is the electrocardiogram. The interval between two thicker vertical lines represents a period of 1 second. **A** shows EEG on day 3, **B** shows EEG on day 19 and **C** shows EEG after 15 months. For details see text.

After a rehabilitation of 6 weeks she was able to resume her work. EEG almost 15 months after the onset of neurological symptoms showed moderate slowing of the background activity without epileptiform discharges (Fig. 2c). At follow-up 22 months after onset of neurological symptoms she complained of mild memory and concentration impairment. Neurological examination was normal.

Case 3

This 39-year-old woman suffered from a flu-like syndrome for almost 2 months, until she developed laryngitis, fever of 39°and an exanthema in the face. At that moment she became apathetic, weak and disoriented and suddenly lost vision on her right eye. On admission she was unable to count fingers with her right eye, the right optic disc was prominent, there was nystagmus when looking to the right side more than to the left and a slight rightsided hemisyndrome. CSF and EEG results are given in the table. Cerebral MRI on days 2 and 5 showed one single lesion in the left gyrus rectus without contrast enhancement. On day 8 there was in addition a leftsided pontine lesion without enhancement. Cervical and thoracic MRI on days 5 and 8 showed a stationary medullary lesion without enhancement at the level of C6/7. Because of rapidly progressive tetraparesis with respiratory exhaustion the patient had to be intubated for one week, during which time she developed a locked-in-syndrome and an additional optic neuritis on the left side. On day 3 a generalized seizure occurred and micturition and defecation became difficult. After initial

therapy with acyclovir she underwent plasma exchange 9 times, followed by intravenous immunoglobulin therapy for five days and finally oral prednison therapy for several weeks. She made a good recovery over 6 weeks and was then able to return home. At follow-up 40 months after the onset of the neurological syndrome she complained of stress-dependent headache, slightly impaired micturition, reduced vision on the right eye and intermittent difficulty with swallowing. On examination the right optic disc was pale and pupillary reaction to light on that side reduced, a subtle rightsided sensorimotor hemisyndrome could still be detected.

Case 7

This 27-year old woman was in the 10th week of her first pregnancy and complained of indigestion with nausea for about 3 weeks. 4 days before admission she became increasingly tired and apathetic and did not eat any longer. 2 days later she did not respond to commands and involuntary movements of the trunk were observed. Under the suspicion of psychosis she was transferred to a psychiatric hospital, where she became incontinent, was somnolent and alternately restless. On admission to our department on day 4 she was disoriented, partially adhered to commands, and was otherwise neurologically normal. Cerebral MRI on days 4, 12 and 270 were normal. EEG on day 4 showed a prevailing frequency of about 5 Hz. CSF on days 4 and 6 was normal. On day 6 she was mute and showed tetrahyperreflexia with bilateral Babinski sign. EEG on day 6 disclosed periodic sharp waves over both occipital regions, which two days later appeared in generalized distribution. After initial treatment with acyclovir followed by oral prednisone she slowly regained spontaneous speech and recognized her relatives. After three months hospitalization including 2 months of rehabilitation her neuropsychological deficits had greatly improved and she could return home. She had an uneventful delivery giving birth to a healthy boy. On follow-up 8 months after the onset of neurological symptoms she still complained of impaired memory and speech, neurological examination was normal. EEG at that moment had worsened again with moderate slowing of the background activity and a focal slowing over the left temporal region with focal epileptiform discharges. 20 days later she had to be hospitalized for 3 generalized seizures in rapid succession. A therapy with carbamazepin was initiated and on follow-up after 18 months she was seizure-free and had already resumed her previous job.

Discussion

The 10 patients described herein presented with an acute para- or postinfectious CNS disease fulfilling the diagnostic criteria of ADEM as outlined above. A uniform definition of ADEM, however, is not available in the literature. The corner-stones of ADEM, which have been described variably, are clinical: acute onset, monophasic and often self-limited course, symptoms and signs of disseminated diffuse or multifocal CNS involvement, a preceding infection (mostly viral of respiratory or gastrointestinal tract) or vaccination. However, any of these criteria alone or in combination have been reported as absent in previous publications describing certain selected aspects of the syndrome.

Previous investigations often reported pediatric and adult patients together [5, 19, 22, 26, 41, 44]. The largest adult ADEM series (26 patients, age range 15 to 68 years) was published very recently [33]. But a preceding infectious syndrome was present in only 37.5 %, whereas demyelinating lesions on MRI were mandatory. In this paper no comments were made about the findings and value of EEG [33]. History, clinical presentation as well as results of paraclinical findings (CSF, EEG, nerve conduction studies, evoked potentials, MRI, serological studies) were very heterogeneous even in our small series. This can perhaps be explained by the great variability of both the potential triggering infections as well as the host-agent interaction, the two main determinants for the immunological cascade considered responsible of the CNS dysfunction. The variable extent of diffuse or multifocal demyelinating lesions determines the individual signs and symptoms observed. Two patients (cases 2, 7) presented with a diffuse or encephalopathic picture, which was reflected by the severe and generalized EEG alterations. In the case of such presentation a metabolic or toxic disorder must be considered and excluded by history and appropriate laboratory investigations.

We do not consider our patients to suffer from MS for the following reasons: an acute multifocal or diffuse clinical syndrome with fever and disturbed consciousness is a very unusual presentation of MS [19]. Paraclinical findings such as MRI and CSF were not typical of MS. Most importantly, the monophasic course of disease without recurrence after a median follow-up time of 30 months makes MS very unlikely, since relapses in MS tend to occur in the first [33] or the first two years after the initial disease bout [19, 27].

A diagnosis of acute fulminant multiple sclerosis (Marburg's type) or of acute hemorrhagic leucoencephalitis (Hurst syndrome) could be discarded owing to the benign course in the present series [12, 16]. Also, there was no reason to suspect the diagnosis of Reye's syndrome in any of our patients. This severe disorder typically affects children and leads to fatty degeneration of the liver and other organs [31, 39].

Compared with MS bouts, ADEM frequently shows sudden onset and rapidly progressive course with evolving symptoms and signs over several days to weeks.

ADEM patients furthermore are younger. However, when comparing adult [33, present series] and children [14] series, adults tend to have a "less aggressive inflammation" with headache, fever (15% vs. 32%), meningism (15% vs. 26%), (bilateral) optic neuritis, and impaired consciousness (19% vs. 68%) being more rare. Thus age at onset seems to be important with respect to the clinical presentation.

The outcome of our patients was generally favorable with no deaths. However, most of them (9/10) reported some residual functional and most often cognitive impairment. Interestingly, two patients developed excessive daytime sleepiness (as assessed by the Epworth sleepiness score) following ADEM, which indicates that excessive daytime sleepiness after encephalitis of varying etiology is probably underreported, since it might not be specifically inquired after. Excessive daytime sleepiness following encephalitis is generally considered to be a rare event.

Again age at onset seems to be an important variable for prognosis with more frequent prolonged recovery and persistent residual sequelae in adults (54% in [33], 90% in our series versus 19% in [14]).

We want to stress that the cerebral MRI was normal in 50% of our series despite using a high-field equipment and modern imaging techniques including diffusion weighted imaging, FLAIR and gadolinium enhanced images. This is in sharp contrast to what was described in the previous literature on MRI in ADEM [2, 5,19, 22, 33, 35]. Furthermore, the abnormal findings on MRI in our 5 patients were rather subtle and did not conform to the gross abnormalities reported before [5, 19, 22, 35]. However, this probably also represents a publication bias due to the fact that only positive (= abnormal) MRI findings were considered worth reporting or were even a diagnostic prerequisite for inclusion [33]. In our patients, the severity of disease clearly did not correlate with the extent of signal abnormalities. This underlines that MRI as a structural imaging method does not necessarily allow for a conclusive assessment of brain function. Therefore we believe that MRI should not be relied upon when defining a diagnosis of ADEM. In this respect our data concur with the conclusions of a recently published editorial: "image isn't everything" [13]. We thus cannot support the recent statement of Hynson et al. "that MRI is the investigation of choice in ADEM" [14]. It could not be confirmed either in the present series that the signal abnormalities on MRI, being theoretically more or less of the same age, show a uniform enhancement after gadolinium application [19]. In our series, a partial contrast enhancement was observed in only 3 of 5 patients with abnormal MRI findings, thereby confirming previous MRI studies in ADEM [5, 22, 33]. Dynamic alterations of MRI signal abnormalities during the course of ADEM could also be found in the present series, for example showing a progression of hyperintensities during the acute stage (case 3) or regression of signal abnormalities on intermediate to longterm follow-up (cases 4, 6 and 8) [5, 19, 20, 33]. According to the literature, MRI findings are extremely variable ranging from space-occupying, gadolinium enhancing large lesions with perifocal edema to no changes at all.

The EEG, as a functional method, allowed a more precise estimation of brain function even in the absence of abnormal findings on MRI and in the CSF. The EEG was abnormal in 7/8 patients of the present series in whom it was performed. It turned out to be particularly important for establishing the organic nature of disease in 2 young female patients (cases 2 and 7) who were initially suspected of suffering from a psychiatric disease. Since mental or neuropsychiatric symptoms are frequently present or may even be the dominant findings and may show a fluctuating course, the assumption of a psychiatric origin is not rare. Normal findings on MRI and CSF examination may corroborate such a false interpretation. In this situation, the EEG is of utmost importance in order to determine CNS dysfunction. On the other hand, the EEG findings broadened the spectrum of the differential diagnosis. For example, in patients 2 and 7 the observation of periodic sharp wave complexes temporarily raised the suspicion of Creutzfeldt-Jakob disease, which later on was discarded due to the favorable disease course. As a rule of thumb we propose that a subacute encephalopathic syndrome in a young adult with normal MRI and CSF but clearly pathologic EEG should raise the differential diagnosis of an ADEM. The degree of abnormality in the EEG correlated well with clinical symptoms, e.g. in patient 2 the occurrence of visual hallucinations was paralleled in the EEG by the appearance of sharp-waves over the occipital regions. It also showed a deterioration with focal epileptic discharges in patient 7, who soon afterwards developed recurrent seizures. This confirms a previous report on deterioration of EEG findings preceding recurrence of clinical symptoms after reduction of steroid therapy [44]. In the two most recently reported series EEG was not adequately evaluated: no findings at all are reported by Schwarz et al. in adults, whereas Hynson et al. reported abnormal findings with mainly diffuse slowing in 6 of 7 patients in whom EEG was performed [14, 33].

The CSF was normal in 5 patients and only mildly abnormal in the remainder. Therefore we cannot confirm a diagnostic value of oligoclonal bands in patients suspected of having ADEM as was previously hypothesized [19], which is in agreement with a most recent study finding oligoclonal bands in 58% of ADEM patients [33]. Assessment of CSF is important to diagnose an infectious disease. Normal findings, however, do not exclude an inflammatory or antibody mediated CNS affection. By definition, in none of our patients an etiological diagnosis of a specific microbe directly causing the neu-

rological syndrome could be established, thus virtually excluding the possibility of microbial encephalitis [17, 32, 36]. The possibility of an infectious encephalitis was further rendered very unlikely by the lack of a marked pleocytosis which never exceeded 22 cells/microliter and was completely absent in most patients [32]. Even in case 9, in whom a recent EBV infection was diagnosed by blood serology, EBV-PCR in the CSF remained negative. The diagnostic value of EBV-PCR in CSF has recently been demonstrated [38]. In our patient this raises the possibility of ADEM accompanying a systemic acute EBV-infection, an entity which is well established in the literature [17, 33].

Case 1 is worth mentioning, because she presented with the simultaneous occurrence of acute demyelinating disease of the central and peripheral nervous system. Although this combination is rare, it has occasionally been mentioned for acute demyelinating disease [10, 23, 38, 43] as well as for chronic demyelinating disease [8, 21, 29]. In our patient, involvement of the CNS (multifocal neurological deficits, severely abnormal EEG) and the PNS (conduction block on neurography) was obvious. In addition, she showed a moderate elevation of anti-GQ1b-antibodies, which are typically increased in demyelinating diseases such as Miller-Fisher-syndrome, Bickerstaff encephalitis, and Guillain-Barré-syndrome [6, 42]. No other cause (e. g. metabolic) for the abnormal EEG could be detected. We therefore postulate that our patient suffered from ADEM simultaneously with a demyelinating disease of the PNS, most probably the Guillain-Barré-syndrome given the electrophysiological and clinical findings [9, 32].

In conclusion we would like to emphasize that establishing the diagnosis of ADEM requires the synopsis of historical and clinical findings together with the results of paraclinical investigations such as CSF, EEG and MRI. MRI findings frequently are normal even with a severe clinical picture and thus should not be considered a diagnostic prerequisite. The EEG is of greatest help in proving encephalopathy and best correlates with the clinical course.

References

1. Alcock NS, Hoffman HL (1962) Recurrent encephalomyelitis in childhood. Arch Dis Child 37:40–44
2. Atlas SW, Grossman RI, Goldberg HI, Hackney DB, Bilaniuk LT, Zimmermann RA (1986) MR diagnosis of acute disseminated encephalomyelitis. J Comp Assist Tomogr 10(5):798–801
3. Behan PO, Moore MJ, Lisak RP (1974) Acute disseminated encephalomyelitis. Br J Clin Pract 28(7):243–245
4. Brown JK, Habel AH (1975) Toxic encephalopathy and acute brain-swelling in children. Develop Med Child Neurol 17:659–679
5. Caldemeyer KS, Smith RR, Harris TM, Edwards MK (1994) MRI in acute disseminated encephalomyelitis. Neuroradiology 36:216–220
6. Chiba A, Kusunoki S, Obata H, Machinami R, Kanazawa I (1993) Serum anti-GQ1b IgG antibody is associated with ophthalmoplegia in Miller Fisher syndrome and Guillain-Barré-syndrome: clinical and immunohistochemical studies. Neurology 43:1911–1917
7. Dale RC, de Sousa C, Chong WK, Cox TCS, Harding B, Neville BGR (2000) Acute disseminated encephalomyelitis, multiphasic disseminated encephalomyelitis and multiple sclerosis in children. Brain 123:2407–2422
8. Feasby TE, Hahn AF, Koopman WJ, Lee DH (1990) Central lesions in chronic inflammatory demyelinating polyneuropathy: an MRI study. Neurology 40: 476–478
9. Fross RD, Daube JR (1987) Neuropathy in the Miller Fisher syndrome: clinical and electrophysiologic findings. Neurology 37:1493–1498
10. Gamstorp I (1974) Encephalo-myeloradiculo-neuropathy: involvement of the CNS in children with Guillain-Barré-syndrome. Develop Med Child Neurol 16:654–658
11. Hahn JS, Siegler DJ, Enzmann D (1996) Intravenous gammaglobulin therapy in recurrent acute disseminated encephalomyelitis. Neurology 46:1173–1174
12. Hart MN, Earle KM (1975) Haemorrhagic and perivenous encephalitis: a clinical-pathological review of 38 cases. J Neurol Neurosurg Psychiatry 38:585–591
13. Hartung HP, Grossman RI (2001) ADEM: distinct disease or part of the MS spectrum? Neurology 56:1257–1260
14. Hynson JL, Kornberg AJ, Coleman LT, Shield L, Harvey AS, Kean MJ (2001) Clinical and neuroradiologic features of acute disseminated encephalomyelitis in children. Neurology 56: 1308–1312
15. Johns MW (1991) A new method for measuring daytime sleepiness: the Epworth sleepiness scale. Sleep 14(6):540–545
16. Johnson MD, Lavin P, Whetsell WO Jr (1990) Fulminant monophasic multiple sclerosis, Marburg's type. J Neurol Neurosurg Psychiatry 53:918–921
17. Johnson RT, Griffin DE, Gendelman HE (1985) Postinfectious encephalomyelitis. Semin Neurol 5(2):180–190
18. Kanter DS, Horensky D, Sperling RA, Kaplan JD, Malachowski ME, Churchill WH Jr (1995) Plasmapheresis in fulminant acute disseminated encephalomyelitis. Neurology 45:824–827
19. Kesselring J, Miller DH, Robb SA, Kendall BE, Moseley IF, Kingsley D, et al. (1990) Acute disseminated encephalomyelitis: MRI findings and the distinction from multiple sclerosis. Brain 113:291–302
20. Kimura S, Nezu A, Ohtsuki N, Kobayashi T, Osaka H, Uehara S (1996) Serial magnetic resonance imaging in children with postinfectious encephalitis. Brain Develop 18:461–465
21. Lassmann H, Budka H, Schnaberth G (1981) Inflammatory demyelinating polyradiculitis in a patient with multiple sclerosis. Arch Neurol 38:99–102
22. Mader I, Stock KW, Ettlin T, Probst A (1996) Acute disseminated encephalomyelitis: MR and CT features. Am J Neuroradiol 17:104–109
23. Maier H, Schmidbauer M, Pfausler B, Schmutzhard E, Budka H (1997) Central nervous system pathology in patients with the Guillain-Barré-syndrome. Brain 120:451–464
24. Marks WA, Shuman RM, Bodensteiner JB (1991) HLA patterns in children with parainflammatory leukoencephalomyelitis. J Child Neurol 6:150–154

25. Miller DH, Scaravilli F, Thomas DCT, Harvey P, Hirsch NP (1993) Acute disseminated encephalomyelitis presenting as a solitary brainstem mass. J Neurolog Neurosurg Psychiatry 56:920–922
26. Murthy JMK, Yangala R, Meena AK, Reddy JJ (1999) Acute disseminated encephalomyelitis: clinical and MRI study from South India. J Neurolog Sci 165:133–138
27. O'Riordan JI, Gomez-Anson B, Moseley IF, Miller DH (1999) Long term MRI follow-up of patients with post infectious encephalomyelitis: evidence for a monophasic disease. J Neurolg Sci 167:132–136
28. Orrell RW, Shakir R, Lane RJM, Kennard C, Wade JPH, Poser CM (1996) Distinguishing acute disseminated encephalomyelitis from multiple sclerosis. BMJ 313:802–804
29. Poser CM (1987) The peripheral nervous system in multiple sclerosis. A review and pathogenetic hypothesis. J Neurol Sci 79:83–90
30. Poser CM, Roman G, Emery S (1978) Recurrent disseminated vasculomyelinopathy. Arch Neurol 35:166–170
31. Reye RDK, Morgan G, Baral J (1963) Encephalopathy and fatty degeneration of the viscera. A disease entity in childhood. Lancet 2:749–752
32. Ropper AH (1981) Case records of the Massachusetts General Hospital, Case 35–1981. N Engl J Med 305(9):507–514
33. Schwarz S, Mohr A, Knauth M, Wildemann B, Storch-Hagenlocher B (2001) Acute disseminated encephalomyelitis. A follow-up study of 40 patients. Neurology 56: 1313–1318
34. Shoji H, Kusuhara T, Honda Y, Hino H, Kojima K, Abe T, et al. (1992) Relapsing acute disseminated encephalomyelitis associated with chronic Epstein-Barr virus infection: MRI findings. Neuroradiol 34:340–342
35. Singh S, Alexander M, Korah IP (1999) Acute disseminated encephalomyelitis: MR imaging features. Am J Roentgenol 173:1101–1107
36. Sriram S, Steinman L (1984) Postinfectious and postvaccinial encephalomyelitis. Neurol Clin 2(2):341–353
37. Straub J, Chofflon M, Delavelle J (1997) Early high-dose intravenous methylprednisolone in acute disseminated encephalomyelitis: a successful recovery. Neurology 49:1145–1147
38. Tselis A, Duman R, Storch GA, Lisak RP (1997) Epstein-Barr virus encephalomyelitis diagnosed by polymerase chain reaction: detection of the genome in the CSF. Neurology 48:1351–1355
39. Van Coster RN, De Vivo DC, Blake D, Lombes A, Barrett R, DiMauro S (1991) Adult Reye's syndrome: a review with new evidence for a generalized defect in intramitochondrial enzyme processing. Neurology 41:1815–1821
40. Van Swieten JC, Koudstaal PJ, Visser MC, Schouten HJA, Van Gijn J (1988) Interobserver agreement for the assessment of handicap in stroke patients. Stroke 19:604–607
41. Wang PN, Fuh JL, Liu HC, Wang SJ (1996) Acute disseminated encephalomyelitis in middle-aged or elderly patients. Eur Neurol 36:219–223
42. Yuki N (1996) Acute paresis of extraocular muscles associated with IgG anti-GQ1b antibody. Ann Neurol 39:668–672
43. Yuki N, Wakabayashi K, Yamada M, Seki K (1997) Overlap of Guillain-Barré syndrome and Bickerstaff's brainstem encephalitis. J Neurol Sci 145:119–121
44. Ziegler DK (1966) Acute disseminated encephalomyelitis. Some therapeutic and diagnostic considerations. Arch Neurol 14:476–488