Respiration

Respiration 2009;77:224–228
DOI: 10.1159/000197806

Received: September 2, 2008
Accepted after revision: November 24, 2008

# A Rare Cause of Acute Respiratory Failure and Elevated Eosinophils in Broncho-Alveolar Lavage Fluid

Lars Knudsen[a] Mathias Gugger[b] Philippe Dumont[a] Laurent Nicod[a] Christophe von Garnier[a]

[a]Division of Pulmonary Medicine, University Hospital, and [b]Institute of Pathology, University of Bern, Bern, Switzerland





## Case Report: History and Clinical Findings

A 41-year-old, previously healthy woman presented with subfebrile temperature (37.5°C), dry cough, vomiting and a sensation of thoracic oppression associated with breathlessness, initially exercise dependent, but subsequently also at rest. Symptoms developed within a few days and began with sleeplessness and dizziness 10 days prior to admission to hospital. The respiratory symptoms worsened the day prior to presentation at the emergency department and were associated with general symptoms such as myalgia, headache and palpitations. With the exception of seasonal hay fever (allergic rhinoconjunctivitis) and a mild rosacea, her past medical history was unrevealing, in particular there was no prior respiratory illness. Thirteen days before presentation to the emergency department, she had started treatment with chloroquine (250 mg per day) for the mild rosacea. Besides chloroquine, there was an established hormone replacement therapy with estradiol and norethisteron for many years, but no regular or sporadic over-the-counter medication utilization. The patient smoked approximately 10 cigarettes per day for a period of 23 years (11.5 pack years), worked as a clerk in a furniture shop and had no relevant travel history abroad or into tropical regions.

Physical examination revealed a tachycardia (heart rate 101 beats/min) and tachypnoe (respiratory rate 34 breaths/min), a central cyanosis and an oxygen saturation of 88% under room air, increasing to 92% with 2 liters of oxygen per minute via nasal prongs. Heart and lung auscultation were unremarkable. Blood tests showed leucocytosis (20,600/μl) with neutrophilia (18,330/μl) and normal eosinophils, elevated C-reactive protein (176 mg/l, range <5 mg/l), and slightly raised D-dimer (635 μg/l, range <500 μg/l). All other laboratory examinations, including liver values, creatinine, electrolytes, thrombocytes and red blood cells, were within normal limits. Arterial blood gas analysis under 2 liters of oxygen per minute showed a severe hypoxemia [$Pa_{O_2}$ = 7.6 kPa (57 mm Hg)] and normocapnia [$Pa_{CO_2}$ = 5.2 kPa (39 mm Hg)], indicating a hypoxic (type 1) respiratory failure with an increased alveolo-arterial gradient [approximately 11 kPa (82.17 mm Hg)]. The chest X-ray showed a mild diffuse acinar pattern and Kerley B lines (fig. 1a). The chest CT revealed a discrete ground-glass pattern and slightly prominent reticular lines, predominantly situated in subpleural regions of the upper lobes (fig. 1b), whereas alveolar infiltrations were seen in the lingula. Right-sided hilar lymph node enlargement was noted, but vascular filling defects were not seen up to subsegmental

KARGER

Fax +41 61 306 12 34
E-Mail karger@karger.ch
www.karger.com


0025–7931/09/0772–0224$26.00/0

Accessible online at:
www.karger.com/res

Lars Knudsen, MD
Division of Pulmonary Medicine, University Hospital
Freiburgstrasse 4
CH–3010 Bern (Switzerland)
Fax +41 31 6322 1404, E-Mail lars.knudsen@insel.ch

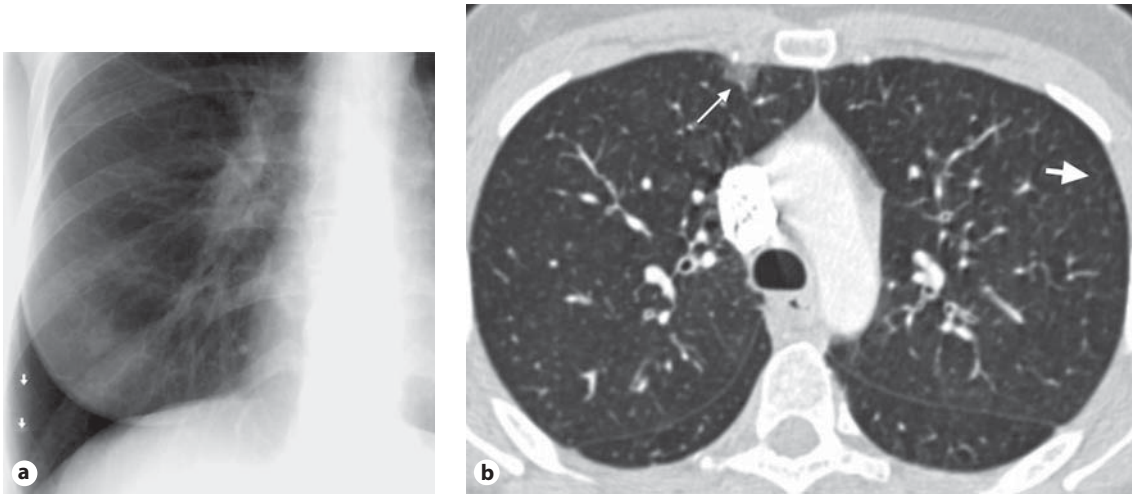

**Fig. 1. a** Chest X-ray on admission: basolateral Kerley B lines (arrows) and blurred vessels. **b** Thorax CT: despite respiratory distress with tachypnoea, hypoxaemia and cyanosis at first presentation, there were only discrete subpleurally localized ground-glass opacities (small arrow). There seemed to be a slightly marked interstitial pattern (large arrow) in the peripheral areas.

pulmonary arteries. A calculated initial treatment consisted of an antibiotic therapy (clarithromycin), oxygen titrated to a saturation of 90–94% and discontinuation of chloroquine. Bronchoscopy was performed 1 day after hospital admission and showed normal macroscopic findings with the exception of discrete inflammatory changes (erythema) of the mucosa. As the most prominent radiological changes were observed in the lingula, bronchoalveolar lavage fluid (BALF) was obtained from this location and transbronchial biopsies were taken from the left lower lobe. Microbiological analysis of BALF failed to identify an infectious agent. The analysis included both antigens and PCR for respiratory viruses (HSV I and II, adenovirus, respiratory syncytial virus, influenca A and B virus, enterovirus, parainfluenza virus, human metapneumovirus), general cultures for bacteria, PCR for mycoplasma and chlamydia, selective cultures for legionella and mycobacteria as well as fungi. Cytological analysis of BALF revealed a predominant increase in the number of eosinophilic granulocytes (17% in cell differentiation, normal range <3%) and a less pronounced elevation of neutrophilic granulocytes (11.5% in cell differentiation, normal range <5%). Both lymphocytes and macrophages were within the normal range, and the CD4-to-CD8 ratio was 2.1. The cytological findings were confirmed with the histopathological evaluation of transbronchial biopsies (fig. 2) demonstrating a moderate eosinophilic inflammation within the bronchial walls, in the interstitium and alveoli, but failed to show evidence

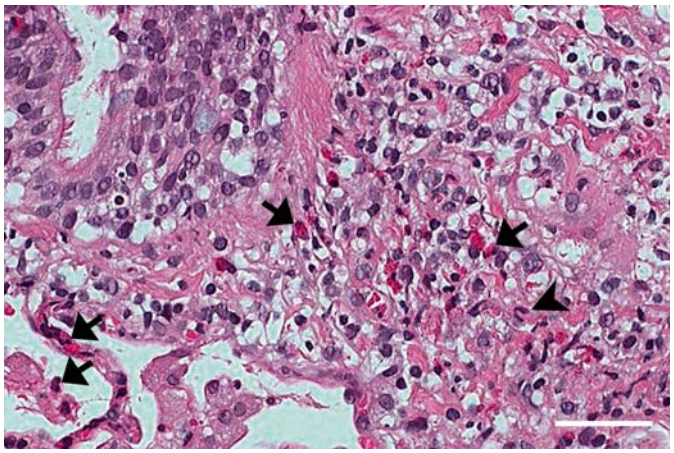

**Fig. 2.** Eosinophilic granulocytes (arrows) in moderate numbers in the submucosa of a bronchiole, in alveolar septa and in the alveolar lumen. Few neutrophilic granulocytes (arrowhead) in the submucosa. Scale bar = 50 μm. Hemalaun-eosin staining.

for granulomatous disease, vasculitis or fungal agents. HIV testing was negative. The pulmonary function test 7 days after admission revealed a moderate obstruction with a normal diffusion, but gave no evidence for a restrictive pattern. Respiratory symptoms rapidly subsided after a few days. In follow-up consultations, the lung function normalized again.

*What is your diagnosis?*

## Discussion

The diagnosis of acute eosinophilic pneumonitis was based on 2 criteria. Firstly, an elevated eosinophil cell count of more than 5% in the BALF differential. Secondly, the finding of an eosinophilic infiltration of both the lung parenchyma and the airway walls in histopathological sections [1]. Furthermore, Kerley B lines are considered to be an important diagnostic clue in the early stage of the disease [1, 2]. Our Pubmed and Pneumotox query revealed only 3 reports on acute chloroquine-induced pneumonitis and toxicity [3–5]. The reported latency (1–3 weeks) and course of events were similar to our case and a salient feature was an increase in eosinophilic granulocytes in the BALF [3, 4] (tables 1–3). The most common diagnoses associated with increased BALF eosinophilic granulocytes (>5%) are idiopathic interstitial lung disease, AIDS-associated pneumonia, idiopathic eosinophilic pneumonia and drug-induced lung disease [6]. A community-acquired pneumonia rarely causes BALF eosinophilia [6, 7]. Additional diagnoses reportedly associated with BALF eosinophilia are: Churg-Strauss-syndrome, asthma, hypereosinophilic syndrome and allergic bronchopulmonary aspergillosis [8]. In our case, the absence of asthma in the patient's history and the lack of eosinophilia in peripheral blood make a Churg-Strauss syndrome, a hypereosinophilic syndrome or a chronic eosinophilic pneumonia unlikely. The skin testing showed no hypersensitivity for aspergillus antigen, thus the diagnosis of allergic bronchopulmonary aspergillosis is very improbable. In idiopathic acute eosinophilic pneumonia, values of more than 25% of eosinophils in BALF are suggestive and a drug-induced pulmonary side effect has to be excluded for the diagnosis [2, 9]. Asthma is an important differential diagnosis, but there is no evidence in the literature that chloroquine can provoke asthma symptoms [10, 11]. Similar to our case, reports dealing with minocycline-induced eosinophilic pneumonitis showed that skin testing was unreliable to diagnose hypersensitivity [12, 13]. Though these 2 reports stated that the lym-

**Table 1.** Summarized patients' histories, chest X-ray findings and pulmonary function test data of published cases of chloroquine-induced pneumonia

| | Case 1, present case | Case 2 [3] | Case 3 [4] |
|---|---|---|---|
| Age, years | 41 | 41 | 49 |
| Gender | female | male | male |
| Pack years | 11.5 | 20 | 30 |
| Atopy in history | hay fever | unknown | unknown |
| Indication for chloroquine | rosacea | discoid lupus erythematosus | sun dermatitis |
| Latency until onset, days | 13 | 14/5 (1st/2nd exposition) | 3–4 |
| Daily dosage, mg | 250 | 300 | 300 |
| Temperature, °C | 37.5 | 39 | 39 |
| Symptoms | dry cough, dyspnea, myalgia, arthralgia, headache, sleeplessness | productive cough, chest pain, dyspnea, headache, somnolence, arthralgia, papulous dermatitis | cough, dyspnea, arthralgia, myalgia, headache, papulous dermatitis |
| Crackles | no | yes | yes |
| Chest X-ray | Kerley B lines, bilateral slightly blurred vessels | bilateral peripheral infiltration | bilateral alveolar and interstitial pattern |
| Intensive care unit | no | yes | yes |
| Obstruction, $FEV_1$, % | yes, 62 | no | no |
| Vital capacity, % | 103 | 50 | restriction |
| DLCO, % | 90 | 63 | 12 |
| Therapy | clarithromycin, prednisolone (40 mg/day) for 7 days, budenosid/formoterol turbohaler for 4 weeks | clarithromycin, methylprednisolone (8 mg/day) | roxythromycin, methylprednisolone (2 mg/kg/day) |

**Table 2.** Summarized laboratory findings

| | Case 1, present case | Case 2 [3] | Case 3 [4] |
|---|---|---|---|
| Blood leucocytes, n/μl | 20,600 (91% neutrophils) | 28,900 (91% neutrophils) | 30,000 |
| Blood eosinophils, n/μl | 100 | after 6 days, 1,207 | after 6 days, 1,790 |
| CRP, mg/l | 176 | 97 | unknown |
| $Pa_{O_2}$, kPa | 7.6 | 6.2 | 2.3 |
| IgE | 4 weeks after admission: 252 kU/l (range <70 kU/l) | unknown | 15 days after admission: 6,432 UI/ml |

If not otherwise marked, the data are related to initial analysis.

**Table 3.** Summarized BALF differential

| | Case 1 present case | Case 2 [3] | Case 3 [4] |
|---|---|---|---|
| Total cell count, n/μl | 150 | 250 | 1,500 |
| Alveolar macrophages, % | 68.5 | 44 | 50 |
| Lymphocytes, % | 3.0 | 6 | 22 |
| Eosinophils, % | 17 | 50 | 22 |
| Neutrophils, % | 11.5 | <1 | 6 |
| CD4/CD8 | 2.1 | 0.9 | unknown |

phocyte stimulation test did not facilitate the diagnosis of drug-related pulmonary hypersensitivity [12, 13], this test was positive in our case. Therefore, a positive lymphocyte stimulation test confirms the existence of circulating drug-specific T cells which might play a role in the pathogenesis of eosinophilic pneumonitis [1], but it does neither prove nor exclude the pulmonary hypersensitivity [13]. Regarding acute eosinophilic pneumonia, newly onset smoking has been reported to be a possible trigger for this disease [1]. Both in our case and in the reports of chloroquine-induced acute eosinophilic pneumonia published before, the patients were active smokers. This might indicate that active smoking could increase the susceptibility for drug-induced eosinophilic pneumonia [3, 4]. As the patient in our case had a long history of smoking, the acute eosinophilic pneumonia is unlikely to result from her smoking habit alone.

In our case, the most important element to suspect chloroquine-related pulmonary disease results from the exposure history, the latency of 12–13 days from first administration of the drug to initial respiratory symptoms as well as rapid subjective and objective improvement following discontinuation of chloroquine [14, 15].


## Acknowledgement

The authors thank the patient herein reported for her agreement to publication of details from her patient file.

## Key Words

Chloroquine · Eosinophilic pneumonia · Drug-induced pulmonary disease


## References


1 Allen J: Acute eosinophilic pneumonia. Semin Respir Crit Care Med 2006;27:142–147.
2 Pope-Harman AL, Davis WB, Allen E, Christoforids AJ, Allen JN: Acute eosinophilic pneumonia: a summary of 15 cases and review of the literature. Medicine (Baltimore) 1996;75:334–342.
3 Mitja K, Izidor K, Music E: Chloroquine-induced drug hypersensitivity alveolitis. Pneumologie 2000;54:395–397.
4 Coetmeur D, Guivarch G, Briens E, Lopes C: Acute eosinophilic pneumonia. Possible role of chloroquine. Rev Mal Respir 1998;15:657–660.
5 Davidson AC, Bateman C, Shovlin C, Marrinan M, Burton GH, Cameron IR: Pulmonary toxicity of malaria prophylaxis. BMJ 1988;297:1240–1241.
6 Allen JN, Davis WB, Pacht ER: Diagnostic significance of increased bronchoalveolar lavage fluid eosinophils. Am Rev Respir Dis 1990;142:642–647.

7 Davis WB, Wilson HE, Wall RL: Eosinophilic alveolitis in acute respiratory failure: a clinical marker for a non-infectious etiology. Chest 1986;90:7–10.
8 Costabel U, Guzman J: Bronchoalveolar lavage in interstitial lung disease. Cur Opinion Pulm Med 2001;7:255–261.
9 Philit F, Etienne-Mastroianni B, Parrot A, Guerin C, Robert D, Cordier JF; Groupe d'Études et de Recherche sur les Maladies 'Orphelines' Pulmonaires: Idiopathic acute eosinophilic pneumonia: a study of 22 patients. Am J Respir Crit Care Med 2002;166:1235–1239.
10 Dewey A, Dean T, Bara A, Lasserson TJ, Walters EH: Chloroquine as a steroid sparing agent for asthma. Cochrane Database Syst Rev 2003;4:CD003275.
11 Szczeklik A, Gryglewski RJ, Czerniawska-Mysik G: Relationship of inhibition of prostaglandin biosynthesis by analgesics to asthma attacks in aspirin-sensitive patients. BMJ 1975;1:67–69.
12 Toyoshima M, Sato A, Hayakawa H, Taniguchi M, Imokawa S, Chida K: A clinical study of minocycline-induced pneumonitis. Intern Med 1996;35:176–179.
13 Matsuno O, Okubo T, Hiroshige S, Takenaka R, Ono E, Ueno T, Nureki S, Ando M, Miyazaki E, Kumamoto T: Drug-induced lymphocyte stimulation test is not useful for the diagnosis of drug-induced pneumonia. Tohoku J Exp Med 2007;212:49–53.
14 Solomon J, Schwarz M: Drug-, toxin-, and radiation therapy-induced eosinophilic pneumonia. Semin Respir Crit Care Med 2006;27:192–198.
15 Camus P, Fanton A, Bonniaud P, Canus C, Foucher P: Interstitial lung disease induced by drugs and radiation. Respiration 2004;71:301–326.