Case Report

Dermatology

Dermatology 2009;219:353–356
DOI: 10.1159/000252853

Received: May 2, 2009
Accepted after revision: August 8, 2009
Published online: October 23, 2009

Marked Improvement in Nail Psoriasis during Treatment with Adalimumab

N. Irla N. Yawalkar

Department of Dermatology, Bern University Hospital and University of Bern, Bern, Switzerland

Downloaded from http://karger.com/drm/article-pdf/219/4/353/2656152/000252853.pdf by UniversitÄtsbibliothek Bern user on 21 June 2023

source: https://doi.org/10.48350/30395 | downloaded: 12.10.2024

Key Words
Nail psoriasis, treatment · Biologics · Adalimumab

Abstract
Background: Nail involvement is known as a common finding in psoriatic patients and represents a significant impact on patients' quality of life. The treatment of nail psoriasis is often challenging, and there is a need for new therapeutic options. Biologicals effective in the treatment of moderate to severe chronic plaque psoriasis may represent a new therapeutic modality for this disease. Adalimumab is a fully human IgG1 monoclonal antibody that binds to tumor necrosis factor α with high affinity and specificity. ***Observations:*** We report two cases of rapid improvement in nail psoriasis under adalimumab monotherapy with maintained effectiveness despite intermittent treatment as well as long remission after therapy discontinuation. ***Conclusion:*** The marked improvement of our two cases indicates that adalimumab may also help ameliorate nail psoriasis and warrants further controlled studies to establish the effectiveness and therapeutic regimes. Copyright © 2009 S. Karger AG, Basel

N.Y. has served as a consultant to Abbott.

Nail psoriasis represents an important aspect of psoriasis, affecting up to 55 and 90% of patients with cutaneous psoriasis [1] and psoriatic arthritis [2, 3], respectively. Nail involvement has a physical and psychological impact on patients with impairment in daily living activities, pain and emotional stress. Topical treatments including topical steroids, vitamin D derivates, topical cyclosporine, 5-fluorouracil and anthralin are frequently ineffective, and application remains difficult. Nevertheless, topical agents are often prescribed in patients with limited nail involvement, and a recent paper has indeed shown nail psoriasis improvement under calcipotriol plus betamethasone dipropionate two-compound ointment [4]. Although traditional systemic agents such as methotrexate, cyclosporine and acitretin can also be relatively effective, their use is limited by a serious toxicity potential [5, 6].

In recent years much attention has been paid to the use of biologic therapies developed for immune-mediated inflammatory skin diseases like psoriasis. Recent reports have demonstrated that biologicals such as tumor necrosis factor (TNF) antagonists (etanercept [7], infliximab [8, 9]) may have significant influence on psoriatic nail disease. Adalimumab is a fully human IgG1 monoclonal antibody of the IgG1 isotype that binds to human TNF-α with high affinity and specificity, suppressing TNF-associated biologic responses by blocking its interaction with the p55 and p75 cell surface TNF receptors [10]. Clinical studies [11, 12] have demonstrated that adalimumab is efficient and safe in the treatment of moderate to severe plaque-type psoriasis and psoriatic arthritis, but so far experience with nail psoriasis has been limited.

We share our knowledge about two cases with severe disabling nail psoriasis responding dramatically to the TNF antagonist adalimumab.

Patient 1

A 36-year-old male with severe plaque psoriasis was referred to our department with psoriatic nail dystrophy in all finger and toe nails (fig. 1a, b). Previous treatments with potent topical steroids, vitamin D_3 analogues, narrow-band UVB and acitretin for his nails and skin lesions had failed. The patient's pain and discomfort were now affecting his ability to work. Therapy with adalimumab (80 mg loading dose and thereafter 40 mg every other week) was initiated. A marked improvement in his psoriasis was observed within 3 and 6 months (PASI = 75 and 90, respectively). In parallel, practically complete resolution of the lesions on his finger nails (fig. 1c–f) was seen within 3–4 months of

KARGER
Fax +41 61 306 12 34
E-Mail karger@karger.ch
www.karger.com

© 2009 S. Karger AG, Basel
1018–8665/09/2194–0353$26.00/0

Accessible online at:
www.karger.com/drm

N. Yawalkar
Department of Dermatology
Bern University Hospital and University of Bern
CH–3010 Bern (Switzerland)
Tel. +41 31 632 80 42, Fax +41 31 632 42 08, E-Mail nikhil.yawalkar@insel.ch

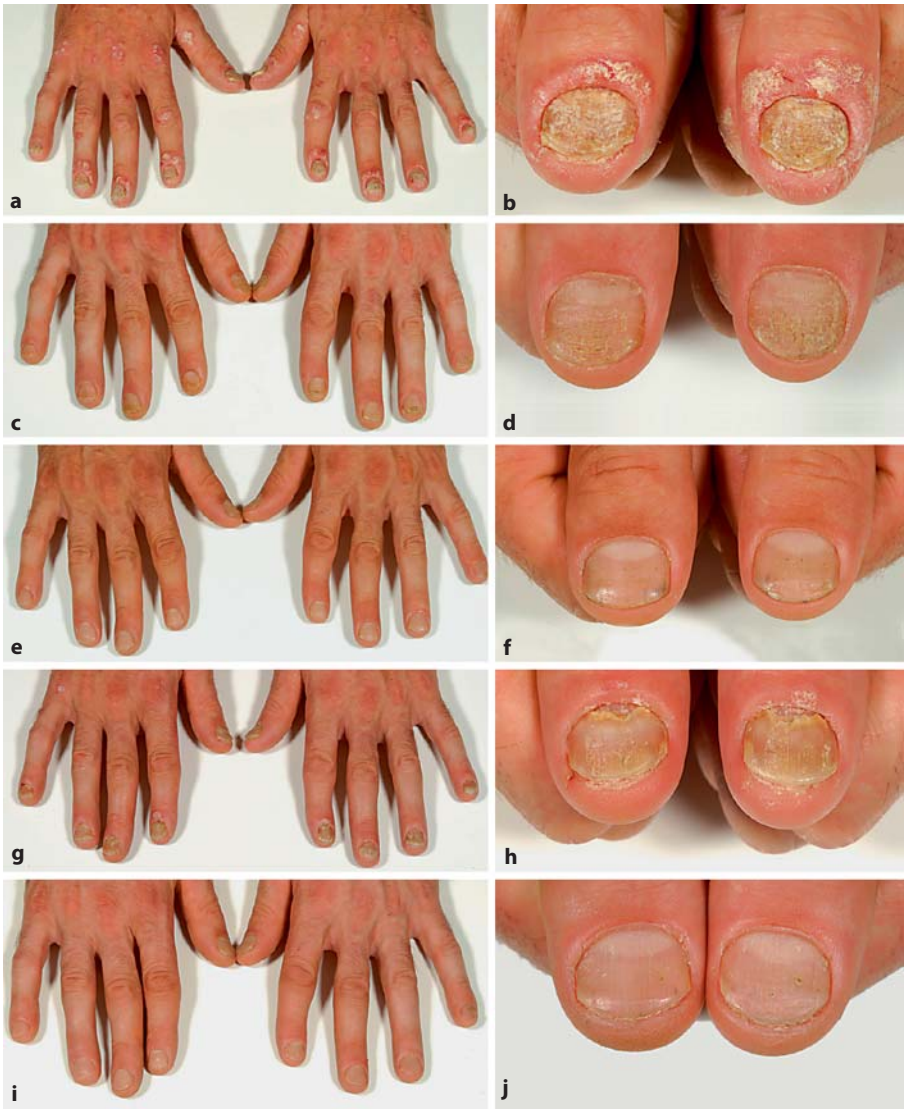

Fig. 1. Clinical findings of patient 1 before (**a**, **b**), after 3 months (**c**, **d**) and 6 months (**e**, **f**) under adalimumab (40 mg every other week) monotherapy as well as 4 months after treatment discontinuation (**g**, **h**) and 5 months of retreatment (**i**, **j**).

treatment and marked improvement in his toe nails (not shown) after 7 months of therapy. Since the patient did not wish continuous therapy, adalimumab was discontinued after 7 months. A relapse of his cutaneous and nail psoriasis occurred within 4 months after the treatment had been stopped (fig. 1g, h). A retreatment with adalimumab induced a reimprovement in his cutaneous lesions and particularly finger nail psoriasis by 3–4 months. Practically complete remission of the lesions on his finger nails (fig. 1i, j) together with a marked improvement in his toe nails (not shown) was found after 5 months. Thereafter, the patient again wished to discontinue the therapy. The treatment duration and nail psoriasis severity index score of a target nail are shown in figure 2a.

Patient 2

The second patient was a 46-year-old male with a history of plaque psoriasis and psoriatic arthritis, referred to our department with severe psoriatic nail dystrophy in all finger and toe nails (fig. 3a–c). He had previously undergone different treatments including potent topical steroids, vitamin D_3 analogues and narrow-band UVB for his skin lesions as well as potent topical steroids for his nails, all of which were ineffective. Due to the severity of his psoriasis with joint involvement, we initiated a therapy with adalimumab (80 mg loading dose and thereafter 40 mg every other week). This led to a marked improvement in his psoriasis (PASI = 75 and 90 after 3 and 6 months, respectively) and psoriatic arthritis as well as an almost complete resolution of his nail involvement after 8 months of treatment (fig. 3d–f). Thereafter, the patient wished to discontinue the treatment and has remained practically clear of disease (skin, joints and especially finger nails) for 8 months after

Downloaded from http://karger.com/drm/article-pdf/219/4/353/2656152/000252853.pdf by UniversitÃ¤tsbibliothek Bern user on 21 June 2023

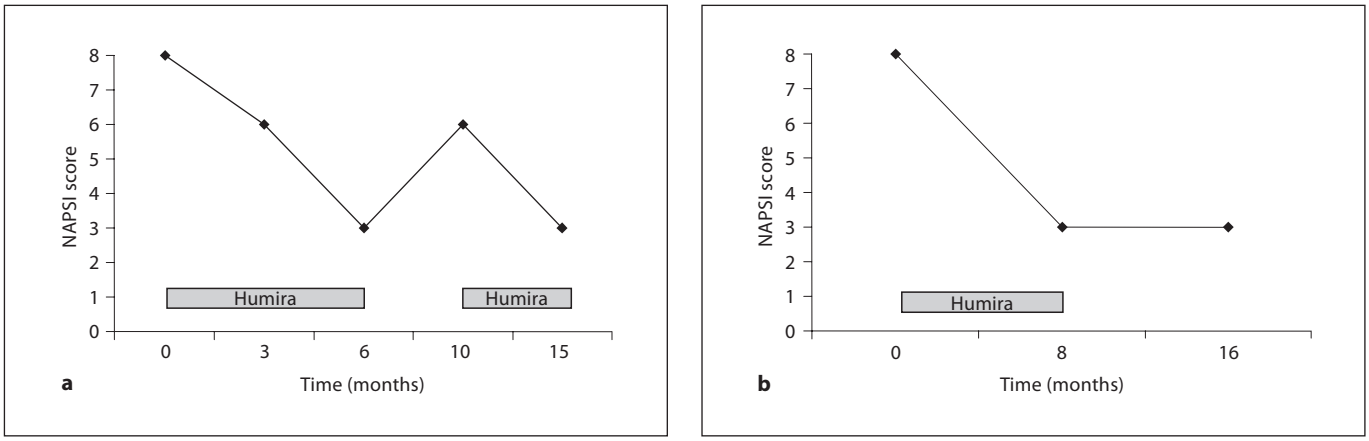

Fig. 2. Nail psoriasis severity index (NAPSI) score evolution of target nail of patient 1 from baseline to 15 months (**a**) as well as of patient 2 from baseline to 16 months (**b**). Therapy duration is indicated with bars below the graphics.

Fig. 3. Clinical findings of patient 2 before treatment (**a–c**), with 8 months of adalimumab therapy (**d–f**), as well as 8 months after adalimumab therapy (**g–i**).

Downloaded from http://karger.com/drm/article-pdf/219/4/353/2656152/000252853.pdf by UniversitÃ¤tsbibliothek Bern user on 21 June 2023

stopping the therapy with adalimumab (fig. 3g–i). Treatment duration and nail psoriasis severity index score of a target nail are shown in figure 2b.

Discussion

The treatment of nail psoriasis is often difficult and remains challenging. New strategies for optimizing the therapy modalities are necessary. Recent reports have been published on the use of biologicals as new therapeutic options for nail psoriasis. In a phase III, randomized, double-blind, placebo-controlled study, Rich et al. [8] evaluated the response of nail psoriasis to treatment with infliximab (Remicade®), a TNF inhibitor. 305 patients with nail psoriasis were enrolled. Significant nail improvement was demonstrated, with complete clearing of the nails in 45% of patients after 1 year of treatment. Rallis et al. [7] reported a complete cure of nail lesions in a patient receiving injections of etanercept (Enbrel®) for his plaque psoriasis. In addition, Lamerson et al. [13] presented four subjects achieving clearance of their nail psoriasis under efalizumab (Raptiva®) therapy. On the contrary, other reports showed varying response of nail psoriasis treated with alefacept (Amevive®), although both studies had clear limitations [14–15].

Adalimumab is a fully human IgG1 monoclonal antibody that binds TNF and is approved for the treatment of rheumatoid arthritis, psoriatic arthritis, ankylosing spondylitis and Crohn's disease in the USA, Canada and Europe. Clinical studies have been published on the efficacy of adalimumab in the treatment of moderate to severe chronic plaque psoriasis for up to 60 weeks of continuous therapy [12]. Recent data showed a significant loss of adequate response of skin psoriasis after discontinuing adalimumab, suggesting that continuous treatment may be required to maintain efficacy over time [11]. A relapse occurred after 4 months of discontinued treatment in our first patient, but the same significant improvement of his nail psoriasis was reached after restarting therapy. So far relapse rates after treatment discontinuation have been poorly evaluated as biologicals are primarily used for the skin and/or joint involvement and most patients continue therapy at the end of the studies. It is particularly noteworthy that our second patient remained practically free of psoriatic lesions 8 months after treatment stop.

Our first patient discontinued treatment after improvement of his nail psoriasis because of family planning. At present it is not known whether or not TNF-α inhibitors have an influence on spermatogenesis or pregnancy [16]. Therefore, experts disagree on their use in pregnant women, and the manufacturers of the TNF-α inhibitor adalimumab advise discontinuing therapy about 5 months prior to a planned pregnancy.

In summary, we report two cases of nail psoriasis successfully treated with adalimumab. Of particular importance are the quick clearance of the nail involvement in both patients, the maintained effectiveness despite intermittent treatment as well as long remission after therapy discontinuation in the first and second case, respectively. Adalimumab may represent a promising therapeutic option in the treatment of patients with severe disabling psoriatic nail dystrophy. The optimal dosage regimen for maintenance of response requires further investigation.

References

1 Scher RK: Psoriasis of the nail. Dermatol Clin 1985;3:387–394.
2 Cassell S, Kavanaugh AF: Therapies for psoriatic nail disease. J Rheumatol 2006;33:1452–1456.
3 McGonagle D, Tan AL, Benjamin M: The nail as a musculoskeletal appendage – implications for an improved understanding of the link between psoriasis and arthritis. Dermatology 2009;218:97–102.
4 Rigopoulos D, Gregoriou D, Daniel CR III, et al: Treatment of nail psoriasis with a two-compound formulation of calcipotriol plus betamethasone dipropionate ointment. Dermatology 2009;218:338–341.
5 De Berker D: Management of nail psoriasis. Clin Exp Dermatol 2000;25:357–362.
6 Mahrle G, Schulze HJ, Farber L, et al: Low-dose short-term cyclosporine versus etretinate in psoriasis: improvement of skin, nail and joint involvement. J Am Acad Dermatol 1995;32:78–88.
7 Rallis E, Stavropoulou E, Rigopoulos D, et al: Rapid response of nail psoriasis of etanercept. J Rheumatol 2008;35:544–545.
8 Rich P, Griffiths CEM, Reich K, et al: Baseline nail disease in patients with moderate to severe psoriasis and response to treatment with infliximab during 1 year. J Am Acad Dermatol 2008;58:224–231.
9 Rigopoulos D, Gregoriou S, Stratigos A, et al: Evaluation of the efficacity and safety of infliximab on psoriatic nails: an unblinded, nonrandomized, open-label study. Br J Dermatol 2008;159:453–456.
10 Calabrese LH: Molecular differences in anticytokine therapies. Clin Exp Rheumatol 2003;21:241–248.
11 Menter A, Tyring SK, Gordon K, et al: Adalimumab therapy for moderate to severe psoriasis: a randomized, controlled phase III trial. J Am Acad Dermatol 2008;58:106–115.
12 Saurat JH, Stingl G, Dubertret L, et al: Efficacy and safety results from the randomized controlled comparative study of adalimumab vs. methotrexate vs. placebo in patients with psoriasis (CHAMPION). Br J Dermatol 2008;158:558–566.
13 Lamerson C, Stevens G, Sax K: Treatment of nail psoriasis with efalizumab: a preliminary study. Cutis 2008;82:217–220.
14 Körver JEM, Langewouters AMG, Van De Kerkhof PCM, et al: Therapeutic effects of a 12-week course of alefacept on nail psoriasis. J Eur Acad Dermatol Venereol 2006;20:1252–1255.
15 Cassetty CT, Alexis AF, Shupack JL, et al: Alefacept in the treatment of psoriatic nail disease: a small case series. J Am Acad Dermatol 2005;52:1101–1102.
16 Østensen M, Lockshin M, Doria A, et al: Update on safety during pregnancy of biological agents and some immunosuppressive antirheumatic drugs. Rheumatology 2008;47:iii28–iii31.

Downloaded from http://karger.com/drm/article-pdf/219/4/353/2656152/000252853.pdf by UniversitÃ¤tsbibliothek Bern user on 21 June 2023