

# High-resolution ultrasound confirms reduced synovial hyperplasia following rituximab treatment in rheumatoid arthritis

Hans-Rudolf Ziswiler<sup>1</sup>, Daniel Aeberli<sup>1</sup>, Peter M. Villiger<sup>1</sup> and Burkhard Möller<sup>1</sup>

**Objective.** To assess the response of RA patients to rituximab (RTX) treatment using a sensitive imaging technique for synovitis.

**Methods.** Twenty-three RA patients were treated with two 1000-mg infusions of the B-cell depleting antibody, RTX, in an observational protocol. Clinical response was assessed by the European League Against Rheumatism (EULAR) response criteria. High-resolution grey-scale and colour-coded power Doppler (PD) ultrasonography was performed at baseline and 6 months after RTX. The second to fifth MCP and PIP joints were bilaterally examined with joints in a neutral 0 position from a palmar view and scored from 0 to 3.

**Results.** Median disease activity score (DAS28) improved from 5.03 to 3.56 ( $P=0.001$ ), which corresponded to a EULAR moderate response in 11 of 23 patients and a EULAR good response in another 6 patients. Improved control of disease activity by RTX was also indicated by tapering of median daily corticosteroid doses from 10 to 5 mg, without flare ups. Mean grey-scale scores correlated with the swollen joint count at baseline ( $r=0.484$ ,  $P=0.022$ ) and month 6 ( $r=0.519$ ,  $P=0.011$ ). Mean grey-scale scores improved upon RTX from a 0.90 median (range 0.13–1.87) to 0.75 (range 0.19–1.50,  $P=0.023$ ). Frequency of PD positive joints was low (6.1%) at baseline and did not significantly change following RTX treatment.

**Conclusions.** High-resolution grey-scale ultrasonography (US) examination confirmed reduced synovial hyperplasia, but the applied PD method displayed no significant changes. Therefore, only grey-scale US is recommended in follow-up examinations after RTX treatment.

**KEY WORDS:** Arthritis, B cell, Depletion, Doppler, Grey scale, Hyperplasia, Rheumatoid, Rituximab, Synovitis, Vascularity.

## Introduction

Rituximab (RTX) is a chimeric monoclonal antibody directed against the CD20 antigen expressed on pre-B and mature B cells. RTX belongs to the new ‘beyond anti-TNF’ biologics. Clinical efficacy of RTX for the treatment of active RA has been documented in randomized controlled trials for patients with inappropriate response to conventional DMARDs, such as low-dose MTX, as well as TNF blocking agents [1–3]. B cells provide multiple important functions by antigen presentation, co-stimulation of T cells and antibody production related to their derivatives, the plasma cells [4, 5]; yet, the predominant mode of action of RTX in autoimmunity is still unclear.

Recent radiographic data proved for the first time that RTX ameliorates structural damage in RA in terms of erosions and joint space narrowing [6]. Macroscopic changes in synovitis upon anti-TNF treatment could be accurately graded by MRI and high-resolution ultrasonography (US). The data obtained by these methods correlated with subsequent disease progression in conventional X-rays [7–12]. To date, no studies have addressed the short-term effect of RTX treatment on the morphological level of synovitis with either one of these modern imaging techniques. In this study, we monitored synovial morphology in therapeutic B-cell depletion with US and compared the results with established clinical parameters for response.

## Patients and methods

### Patients

Twenty-three patients diagnosed with RA according to the ACR classification criteria [13] were treated with two infusions of 1000 mg chimeric anti-CD20 antibody RTX (Roche Pharma, Reinach, Switzerland) 14 days apart from each other in an

observational protocol. All patients had previously failed to respond to at least one conventional DMARD. In addition, all but three patients also failed to respond to at least one TNF blocking agent, in agreement with the Swiss licence for RTX in RA. Clinical disease activity was assessed by swollen joint count (SJC), tender joint count (TJC), ESR, serum CRP and disease activity composite score DAS28 [14] at baseline and 6 months after treatment with RTX. The European League Against Rheumatism (EULAR) response criteria were calculated 6 months after treatment with RTX [15]. Methylprednisolone (80 mg intravenously, Pfizer Zurich, Switzerland), 5 mg levocetirizin-dihydrochloride (UCB-Pharma AG, Bulle, Switzerland) and 1000 mg acetaminophen tablets (Bristol-Myers Squibb, Baar, Switzerland) were concomitantly given with RTX infusions. Subcutaneous low-dose MTX was used in 21 of 23 patients; it was kept stable for at least 6 weeks, in maximal tolerated doses up to 25 mg/week, before RTX infusions and during the observational phase. TNF blocking agents were discontinued at least one treatment interval before B-cell depletion. Orally administered corticosteroids were continued in a stable dose and then carefully tapered, according to improved disease activity. Local corticosteroid injections into the joints of interest were prohibited. The patient cohort is described in more detail in Table 1. Written informed consent was obtained according to the Declaration of Helsinki from all participants. The study was approved by the cantonal ethics committee of Bern.

### Ultrasound technique

Grey-scale (synonymous for brightness or B mode), as well as colour-coded power Doppler (PD) US were performed on the first day of RTX infusion and again 6 months later with an Esaote MyLab 70 x-vision (Esaote S.p.a., Genova, Italy) supply using the 4-cm linear-array transducer 6–18 MHz (L4 35). MCP and PIP joints of digits 2–5 on both hands were examined according to the method of Scheel *et al.* [16] from a palmar view, with joints in neutral 0 or in maximal extended position. The colour box in PD was adjusted to the region of interest. The pulse repetition frequency was set to 750 MHz, with wall filter and persistence at the lowest possible level; colour priority included all colours. The colour gain was adapted according to published recommendations [17]. Grey-scale and PD images with

<sup>1</sup>Inselspital, Bern University Hospital, Clinics for Rheumatology, Clinical Immunology and Allergy, Bern, Switzerland.

Submitted 21 October 2008; revised version accepted 23 April 2009.

Correspondence to: Burkhard Möller, Inselspital, Bern University Hospital, Clinics for Rheumatology, Clinical Immunology and Allergy, Freiburgstrasse, 3010 Bern, Switzerland. E-mail: burkhard.moeller@insel.ch

TABLE 1. Patient baseline characteristics ( $n=23$ )

	$n$ (%)
Number of female patients	17 (74)
RF positive	16 (70)
CCP antibody positive	20 (87)
RF and anti-CCP positive	16 (70)
Erosive disease	19 (83)
Extra-articular manifestations	4 (17)
Age at disease onset, years <sup>a</sup>	44
Disease duration at inclusion, months <sup>a</sup>	106
Previous conventional DMARD <sup>b</sup>	2.8
Previous anti-TNF <sup>b</sup>	1.5

<sup>a</sup>The median value is given. <sup>b</sup>The mean value is given. CCP: cyclic citrullinated peptide.

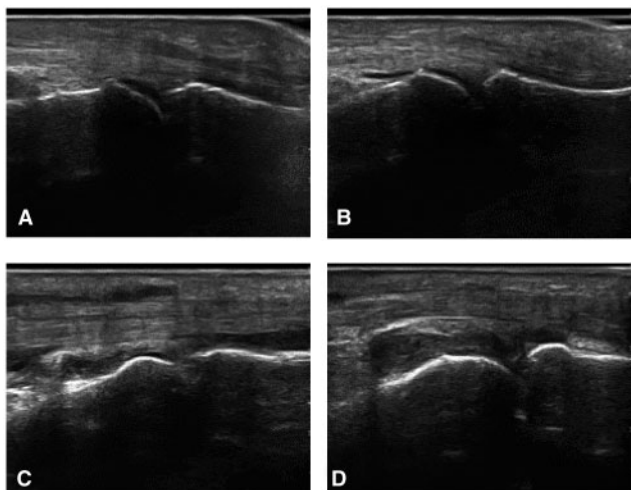


FIG. 1. Reference grey-scale photographs of MCP joints taken from a palmar longitudinal view with joints in maximal extension. (A) Score 0=no synovial membrane detectable or at most as a very thin, usually discontinuous hypoechoic line. Small intra-articular effusions are an/hypoechoic and undistinguishable from synovial hyperplasia. This thin line may become somewhat more prominent during joint flexion. (B) Score 1=synovial membrane is clearly detectable palmar to the metacarpal diaphysis. Superficial and basal synovial boundaries take a parallel course or may be slightly distended, but collapse at the epiphysis of the proximal phalanx. (C) Score 2=superficial and deep synovial margins form an ellipse and synovial structures do not reach the base of the proximal phalanx. (D) Score 3=superficial and deep synovial boundary form an ellipse and distal synovial structures are clearly identifiable at the base of the proximal phalanx.

maximal colour activity of each joint were saved as digital images and scored from 0 to 3 by one of the participating experienced assessors who was blind to the clinical data. Excluded from evaluation were joints with extension deficits  $>20^\circ$ , replaced joints as well as those with radiographic evidence for ankylosis or major joint deformations, such as large osteophytes. Subluxation, luxation and mutilation were also excluded. Synovitis of PIP joints was defined according to reference images [16]. Reference photographs used in this study for MCP scoring are shown in Fig. 1. PD-Mode images were scored in a semi-quantitative manner from 0 to 3 according to a previous study [12].

### Statistical analysis

Data were evaluated on single joint and patient levels. The frequency of results in percentage was calculated on the basis of all joints in evaluation at baseline and after 6 months set to 100%. Data on patient level are given as the mean of all joints in evaluation at baseline and month 6. Unless otherwise stated, non-parametric data were presented by the median and range. Correlation of metric data was calculated by two-sided Spearman's coefficient of correlation. The relationship of nominal

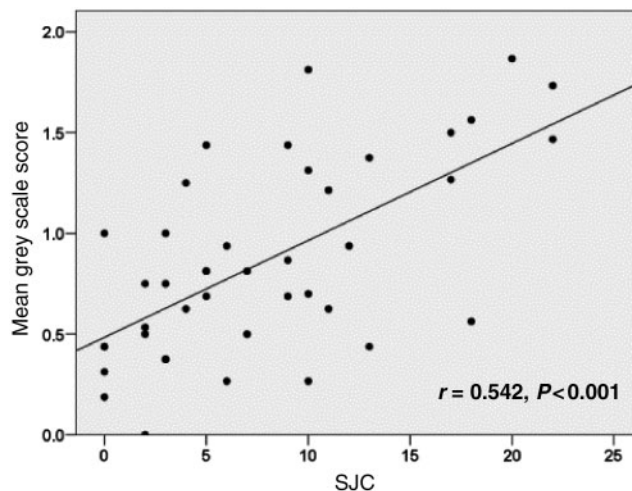


FIG. 2. Grey-scale scores are correlated with SJC. Cross-sectional data were accumulated from all 23 patients at both time points.

parameters was presented by likelihood ratios (LRs) with indicated degrees of freedom (DFs). Significance of differences between two tailed groups was calculated by Wilcoxon's test of the median and of two untailed groups by Mann-Whitney U-test. Prediction of clinical response was estimated by calculating linear regression models based on baseline parameters for the change of DAS28 over time and by ordinal regression for no, moderate and good EULAR response. Statistical analysis was performed with SPSS version 15.0.

## Results

### Clinical baseline characteristics

Median DAS at baseline was 5.03 (range 3.41–7.69). Of the evaluated MCP and PIP joints, 27.6% were judged as tender and 34.6% were swollen, with significant coincidence of these items (LR = 59.0, DF = 1,  $P < 0.001$ ). Comparison of individual left and right hand joints indicated symmetry for swollen (LR = 44.4, DF = 1,  $P < 0.001$ ) as well as tender joints (LR = 31.9, DF = 1,  $P < 0.001$ ).

### Sonography at baseline

Of the 184 theoretically available joints, 158 MCP (85.9%) and 167 PIP (90.8%) were selected, after application of the exclusion criteria, and evaluated at baseline and after 6 months. At baseline, 138 of these joints (42.5%) were free of any detectable synovial thickening (score 0), according to corresponding reference images for PIP joints as previously published [16], and for MCP joints as presented in Fig. 1. Seventy-nine joints (24.3%) showed 1°, 88 joints (27.1%) 2° and 20 joints (6.2%) 3° synovitis. The median of baseline grey-scale scores per individual was 0.902 (range 0.00–1.87). Grey-scale scoring of single joints correlated significantly with tenderness (LR = 12.71,  $P = 0.005$ ) and more closely with swollen joint status (LR = 43.64,  $P < 0.001$ ). Mean grey-scale scores of patients correlated significantly with SJC (Fig. 2;  $r = 0.484$ ,  $P = 0.022$ ), but not with TJC, DAS28, ESR or CRP. Eighteen joints (5.5%) showed 1° and two joints (0.6%) showed 2° hyperperfusion signals in PD at baseline. These flow signals were only demonstrable in joints with 2° and 3° grey-scale scoring. Positive PD results were correlated with joint tenderness (LR = 7.26, DF = 1,  $P = 0.026$ ). It is interesting to note that synovial hyperplasia detected by grey scale (LR = 24.10, DF = 1,  $P = 0.004$ ), but not the pathological perfusion signals in PD, were symmetrically distributed.

### Clinical response

Single parameters of RA disease activity improved significantly over time (TJC:  $Z = -2.975$ ,  $P = 0.003$ ; SJC:  $Z = -3.137$ ,  $P = 0.002$ ; ESR:  $Z = -3.681$ ,  $P < 0.001$ ; CRP:  $Z = -3.402$ ,  $P = 0.001$ ) despite tapering of the daily corticosteroid intake from a median of 10 mg at baseline to a median of 5 mg, 6 months after RTX. When breaking down the cumulative data to single joints, the swollen joint status was stable in 68.3%, improved in 27.1% and worsened in 4.6% of evaluated joints. A similar distribution of stable (64.6%), improved (28.6%) and worsened (6.8%) joints was seen in respect to tenderness. DAS28 improved in accordance with the single items from a 5.03 median at baseline to 3.56 (range 1.38–6.65) in therapeutic B-cell depletion ( $Z = -4.076$ ,  $P < 0.001$ ). Of the 23 patients, 11 patients thereby met the EULAR criteria for moderate clinical response and another 6 patients met the criteria for good response. DAS28 improved by a 0.52 median in the remaining six EULAR non-responders.

### Sonographic response

In B-cell depletion, 158 joints (47.6%) were free of significant synovial thickening (score 0); whereas 100 joints (30.1%) showed 1°, 65 joints (19.6%) 2° and 9 joints (2.7%) 3° synovitis. Grey-scale scoring remained unchanged in 175 (53.7%) joints, improved by 1 point in 70 joints, by 2 points in 20 joints and by 3 points in 7 joints. In contrast, the grey-scale scoring worsened by 1 point in 44 joints, by 2 points in 8 joints and by 3 points in 1 joint. The median of grey-scale scores on patient level improved from 0.902 to 0.75 (range 0.19–1.50,  $Z = -2.582$ ,  $P = 0.010$ ). As at baseline, PD positivity of 1° in 11 (3.3%) and of 2° in 5 joints (1.5%) was limited to joints with at least 2° grey-scale scoring. The mean grey-scale scores correlated with SJC (Fig. 2,  $r = 0.519$ ,  $P = 0.011$ ). In contrast to the results at baseline, we found additional significant correlations of mean grey-scale scores in B-cell depletion with DAS28 ( $r = 0.529$ ) and ESR ( $r = 0.416$ ,  $P = 0.048$ ).

### No predictability of clinical response to RTX

Based on sonography and clinical and laboratory parameters at baseline, we were not able to identify any significantly contributing parameter in linear regression models for the development of DAS28, or for the best achieved level of EULAR response in ordinal regression models.

## Discussion

This study shows for the first time that therapeutic B-cell depletion leads to reduced synovial hyperplasia and that this process can be displayed by grey-scale US. Implications and consequences of these findings are discussed here.

First, remission of RA and halt of radiographic progression are linked mechanisms [18] that can be disconnected under poorly defined conditions [19, 20]. Grey-scale US provides new information, which may lead to a better understanding of the relationship between immune mediated inflammatory disease processes and joint inflammation.

Secondly, it has been shown that RTX treatment can lead to both clinical improvement and reduced radiographic disease progression [1–3, 6]. It is not known whether the recommended RTX re-treatment intervals, which are highly variable when based on an individual's disease activity [21], will result in optimal control of disease progression. The applied grey-scale US method provides information on synovial morphology, which may contribute to rational disease monitoring after RTX. A prospective longitudinal study, with repeat courses of RTX, would be necessary to determine if this method is useful in predicting ongoing joint damage.

Thirdly, post-marketing data from RA patients with rather low DAS28, when starting RTX, suggested that improvement in SJC might be less with RTX than that reported from clinical trial cohorts with substantially higher baseline disease activity [22]. Therefore, it is important to note that the proportion of patients in our study clinically responding to RTX after 6 months was similar to controlled trials [1–3, 22], despite rather low baseline activity. Thus, in less active arthritis, lack of response to RTX could be ruled out by applying a novel imaging technique [16]. It is important to note that the present data are limited to a single time point 6 months after RTX treatment that was selected after consideration of delayed synovial B-cell depletion [23–25].

Changes in grey-scale scoring were not limited to joints with clinically detectable swelling; they were also observed in 1° synovial hyperplasia (Fig. 3). This finding would have been missed without US monitoring. Despite improvement of synovial hyperplasia in a significant number of joints after RTX, a substantial proportion of joints with different degrees of synovial hyperplasia at baseline did not respond. This observation might be due to location-dependent primary resistance to RTX and corticosteroid tapering. Moreover, we occasionally observed worsening of normal joints from grey-scale score 0 to 1° in therapeutic B-cell depletion, which may also indicate spontaneous fluctuation between these two states (Fig. 3). Nevertheless, notable agreement of grey-scale US results with joint swelling status in four separate cross-sectional analyses from two visits and in MCP and PIP joints by different blinded investigators document the validity of the data. In addition, significant improvement in grey-scale scoring, along with change of joint swelling status, indicates the sensitivity of this method to change.

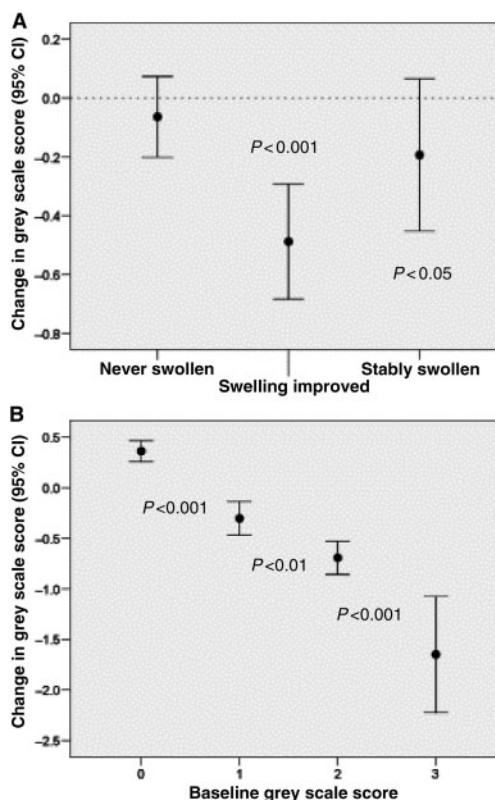


FIG. 3. Change of grey-scale scores in (A) joints that were clinically swollen at baseline but improved upon treatment (middle), in contrast to joints that were clinically assessed as not swollen at baseline and in B-cell depletion (left) or joints that were swollen at baseline and in B-cell depletion (right). (B) Average grey-scale scoring is significantly improved upon RTX in 2° and 3° synovial hyperplasia, but can change between normal and 1° synovial hyperplasia in both directions. Circles represent median change in grey-scale scores over time and error bars depict the 95% CI.

There are some critical issues from the present study that warrant further discussion. Correlation of grey-scale US with DAS28 is, at best, moderate. This divergence may be explained by differences in the number of joints assessed. Furthermore, DAS28 is affected more by the number of tender joints and ESR than the SJC, due to its mathematical formula. As expected, grey-scale mode US correlated better with joint swelling than with DAS28. Therefore, grey-scale US provides information in addition to the DAS28. It is currently speculative whether DAS28 or one of the novel imaging methods will be more accurate and suitable for diagnostic or prognostic purposes in the future.

As with grey scale, we decided to limit PD assessment in the present study to the palmar side, according to a publication available at the initiation of our study [16]. In the meantime, other investigators reported that PD signals could be detected from a dorsal view, that they were modifiable by anti-TNF treatment and that destruction was more likely to progress in PD positive joints [26, 27]. It was also reported that the palmar view of finger joints was rather insensitive to PD ultrasound signals [12, 28]. Positive PD results appear more prevalent in wrist joint synovitis than finger joint synovitis [12]. Although there is surprisingly little change after clinically effective treatments, including local corticosteroids and anti-TNF, in wrist joints [29], there is notable reported sensitivity of PD signals to change in finger joints [26]. The validation process of PD US for arthritis is presently not completed [10]. Nevertheless, it is necessary to comment on the missing impact of RTX on PD signals in our patient cohort despite potentially method-dependent implications, rather low clinical disease activity and low number of PD-positive joints at baseline.

Due to well-established changes in B-cell aggregates in the synovium [23–25, 30], we primarily examined synovial hyperplasia and hyperperfusion, pathologies detectable by US and MRI [12, 27, 31, 32]. However, with our methods, intraosseous processes such as bone oedema, the best predictive parameter for erosions in MRI studies [27, 33, 34], could not be addressed.

In summary, high-resolution US provided evidence of significant reductions in synovial hyperplasia after RTX treatment. Yet, we also noted persistence of synovial hyperplasia in several joints for currently unknown reasons. Use of a validated novel imaging tool, such as US, could further substantiate improvement in RA by B-cell depletion. This method displays response, but also resistance, to RTX and provides an objective and clinically applicable link between B-cell-directed immune modulation and arthritis symptoms. Based on these characteristics, grey-scale US is recommended for monitoring synovial hyperplasia after RTX therapy. It remains speculative whether more relevant information might be obtained by optimizing the PD method.

### Rheumatology key messages

- Grey-scale US provides evidence of reduced synovial hyperplasia and improved RA disease activity after RTX treatment.
- This finding further substantiates the known beneficial effects of therapeutic B-cell depletion in RA.

### Acknowledgements

We are grateful to Marianne Rotzetter for her excellent technical assistance. We also acknowledge manuscript editing assistance provided by San Francisco Edit.

**Funding:** We are grateful to Roche Pharma, Switzerland for supporting our data collection with a research grant of 10 000 CHF.

**Disclosure statement:** B.M. has received honorary fees of less than 10 000 Swiss Francs from Roche Pharma, Switzerland for attending advisory board meetings. All other authors have declared no conflicts of interest.

### References

- 1 Edwards JC, Szczepanski L, Szechinski J *et al.* Efficacy of B-cell-targeted therapy with rituximab in patients with rheumatoid arthritis. *N Engl J Med* 2004;350:2572–81.
- 2 Emery P, Fleischmann R, Filipowicz-Sosnowska A *et al.* The efficacy and safety of rituximab in patients with active rheumatoid arthritis despite methotrexate treatment: results of a phase IIB randomized, double-blind, placebo-controlled, dose-ranging trial. *Arthritis Rheum* 2006;54:1390–400.
- 3 Cohen SB, Emery P, Greenwald MW *et al.* Rituximab for rheumatoid arthritis refractory to anti-tumor necrosis factor therapy: results of a multicenter, randomized, double-blind, placebo-controlled, phase III trial evaluating primary efficacy and safety at twenty-four weeks. *Arthritis Rheum* 2006;54:2793–806.
- 4 Takemura S, Klimiuk PA, Braun A, Goronzy JJ, Weyand CM. T cell activation in rheumatoid synovium is B cell dependent. *J Immunol* 2001;167:4710–8.
- 5 Taylor RP, Lindorfer MA. Drug insight: the mechanism of action of rituximab in autoimmune disease—the immune complex decoy hypothesis. *Nat Clin Pract Rheumatol* 2007;3:86–95.
- 6 Keystone EC, Emery P, Peterfy CG *et al.* Rituximab inhibits structural joint damage in rheumatoid arthritis patients with an inadequate response to tumour necrosis factor inhibitor therapies. *Ann Rheum Dis* 2009;68:216–21.
- 7 Zikou AK, Argyropoulou MI, Voulgari PV *et al.* Magnetic resonance imaging quantification of hand synovitis in patients with rheumatoid arthritis treated with adalimumab. *J Rheumatol* 2006;33:219–23.
- 8 Iagnocco A, Filippucci E, Perella C *et al.* Clinical and ultrasonographic monitoring of response to adalimumab treatment in rheumatoid arthritis. *J Rheumatol* 2008;35:35–40.
- 9 Quinn MA, Conaghan PG, O'Connor PJ *et al.* Very early treatment with infliximab in addition to methotrexate in early, poor-prognosis rheumatoid arthritis reduces magnetic resonance imaging evidence of synovitis and damage, with sustained benefit after infliximab withdrawal: results from a twelve-month randomized, double-blind, placebo-controlled trial. *Arthritis Rheum* 2005;52:27–35.
- 10 Albrecht K, Grob K, Lange U, Muller-Ladner U, Strunk J. Reliability of different Doppler ultrasound quantification methods and devices in the assessment of therapeutic response in arthritis. *Rheumatology* 2008;47:1521–6.
- 11 Hau M, Kneitz C, Tony HP, Keberle M, Jahns R, Jenett M. High resolution ultrasound detects a decrease in pannus vascularisation of small finger joints in patients with rheumatoid arthritis receiving treatment with soluble tumour necrosis factor alpha receptor (etanercept). *Ann Rheum Dis* 2002;61:55–8.
- 12 Naredo E, Collado P, Cruz A *et al.* Longitudinal power Doppler ultrasonographic assessment of joint inflammatory activity in early rheumatoid arthritis: predictive value in disease activity and radiologic progression. *Arthritis Rheum* 2007;57:116–24.
- 13 Arnett FC, Edworthy SM, Bloch DA *et al.* The American Rheumatism Association 1987 revised criteria for the classification of rheumatoid arthritis. *Arthritis Rheum* 1988;31:315–24.
- 14 Prevoo ML, van't Hof MA, Kuper HH, van Leeuwen MA, van de Putte LB, van Riel PL. Modified disease activity scores that include twenty-eight-joint counts. Development and validation in a prospective longitudinal study of patients with rheumatoid arthritis. *Arthritis Rheum* 1995;38:44–8.
- 15 van Gestel AM, Prevoo ML, van't Hof MA, van Rijswijk MH, van de Putte LB, van Riel PL. Development and validation of the European League Against Rheumatism response criteria for rheumatoid arthritis. Comparison with the preliminary American College of Rheumatology and the World Health Organization/International League Against Rheumatism criteria. *Arthritis Rheum* 1996;39:34–40.
- 16 Scheel AK, Hermann KG, Kahler E *et al.* A novel ultrasonographic synovitis scoring system suitable for analyzing finger joint inflammation in rheumatoid arthritis. *Arthritis Rheum* 2005;52:733–43.
- 17 Torp-Pedersen ST, Terslev L. Settings and artefacts relevant in colour/power Doppler ultrasound in rheumatology. *Ann Rheum Dis* 2008;67:143–9.
- 18 Voskuyl AE, Dijkmans BA. Remission and radiographic progression in rheumatoid arthritis. *Clin Exp Rheumatol* 2006;24:S37–40.
- 19 Cohen G, Gossec L, Dougados M *et al.* Radiological damage in patients with rheumatoid arthritis on sustained remission. *Ann Rheum Dis* 2007;66:358–63.
- 20 Smolen JS, Han C, Bala M *et al.* Evidence of radiographic benefit of treatment with infliximab plus methotrexate in rheumatoid arthritis patients who had no clinical improvement: a detailed subanalysis of data from the anti-tumor necrosis factor trial in rheumatoid arthritis with concomitant therapy study. *Arthritis Rheum* 2005;52:1020–30.
- 21 Smolen JS, Keystone EC, Emery P *et al.* Consensus statement on the use of rituximab in patients with rheumatoid arthritis. *Ann Rheum Dis* 2007;66:143–50.
- 22 Finckh A, Ciurea A, Brulhart L *et al.* B cell depletion may be more effective than switching to an alternative anti-tumor necrosis factor agent in rheumatoid arthritis patients with inadequate response to anti-tumor necrosis factor agents. *Arthritis Rheum* 2007;56:1417–23.
- 23 Kavanaugh A, Rosengren S, Lee SJ *et al.* Assessment of rituximab's immunomodulatory synovial effects (arise trial). 1: Clinical and synovial biomarker results. *Ann Rheum Dis* 2008;67:402–8.

- 24 Teng YK, Levarht EW, Hashemi M *et al.* Immunohistochemical analysis as a means to predict responsiveness to rituximab treatment. *Arthritis Rheum* 2007;56:3909–18.
- 25 Thurlings RM, Vos K, Wijbrandts CA, Zwiderman AH, Gerlag DM, Tak PP. Synovial tissue response to rituximab: mechanism of action and identification of biomarkers of response. *Ann Rheum Dis* 2008;67:917–25.
- 26 Taylor PC, Steuer A, Gruber J *et al.* Ultrasonographic and radiographic results from a two-year controlled trial of immediate or one-year-delayed addition of infliximab to ongoing methotrexate therapy in patients with erosive early rheumatoid arthritis. *Arthritis Rheum* 2006;54:47–53.
- 27 Brown AK, Conaghan PG, Karim Z *et al.* An explanation for the apparent dissociation between clinical remission and continued structural deterioration in rheumatoid arthritis. *Arthritis Rheum* 2008;58:2958–67.
- 28 Naredo E, Rodriguez M, Campos C *et al.* Validity, reproducibility, and responsiveness of a twelve-joint simplified power doppler ultrasonographic assessment of joint inflammation in rheumatoid arthritis. *Arthritis Rheum* 2008;59:515–22.
- 29 Boesen M, Boesen L, Jensen KE *et al.* Clinical outcome and imaging changes after intraarticular (IA) application of etanercept or methylprednisolone in rheumatoid arthritis: magnetic resonance imaging and ultrasound-Doppler show no effect of IA injections in the wrist after 4 weeks. *J Rheumatol* 2008;35:584–91.
- 30 Vos K, Thurlings RM, Wijbrandts CA, van Schaardenburg D, Gerlag DM, Tak PP. Early effects of rituximab on the synovial cell infiltrate in patients with rheumatoid arthritis. *Arthritis Rheum* 2007;56:772–8.
- 31 Conaghan PG, O'Connor P, McGonagle D *et al.* Elucidation of the relationship between synovitis and bone damage: a randomized magnetic resonance imaging study of individual joints in patients with early rheumatoid arthritis. *Arthritis Rheum* 2003;48:64–71.
- 32 Ostergaard M, Hansen M, Stoltenberg M *et al.* Magnetic resonance imaging-determined synovial membrane volume as a marker of disease activity and a predictor of progressive joint destruction in the wrists of patients with rheumatoid arthritis. *Arthritis Rheum* 1999;42:918–29.
- 33 Hetland ML, Ejlberg BJ, Horslev-Petersen K *et al.* MRI bone oedema is the strongest predictor of subsequent radiographic progression in early rheumatoid arthritis. Results from a 2 year randomized controlled trial (CIMESTRA). *Ann Rheum Dis* 2009;68:384–90.
- 34 McQueen FM, Benton N, Perry D *et al.* Bone edema scored on magnetic resonance imaging scans of the dominant carpus at presentation predicts radiographic joint damage of the hands and feet six years later in patients with rheumatoid arthritis. *Arthritis Rheum* 2003;48:1814–27.